creative commons

COMMONS DEED

저작자표시-비영리-변경금지 2.0 대한민국

이용자는 아래의 조건을 따르는 경우에 한하여 자유롭게

- 이 저작물을 복제, 배포, 전송, 전시, 공연 및 방송할 수 있습니다.

다음과 같은 조건을 따라야 합니다:

저작자표시. 귀하는 원저작자를 표시하여야 합니다.

비영리. 귀하는 이 저작물을 영리 목적으로 이용할 수 없습니다.

변경금지. 귀하는 이 저작물을 개작, 변형 또는 가공할 수 없습니다.

- 귀하는, 이 저작물의 재이용이나 배포의 경우, 이 저작물에 적용된 이용허락조건을 명확하게 나타내어야 합니다.
- 저작권자로부터 별도의 허가를 받으면 이러한 조건들은 적용되지 않습니다.

저작권법에 따른 이용자의 권리는 위의 내용에 의하여 영향을 받지 않습니다.

이것은 이용허락규약(Legal Code)을 이해하기 쉽게 요약한 것입니다.

Disclaimer

dCollection

의학박사 학위논문

유리체강 내 요오드산나트륨 주입을 통한 토끼 망막변성 모델 연구

2016 년 2 월

서울대학교 대학원

의학과 안과학 전공

조 범 주

A thesis of the Degree of Doctor of Philosophy

Investigation of a Retinal Degeneration Model in Rabbit Eyes Using Intravitreal Injection of Sodium Iodate

February 2016

Department of Ophthalmology,

Seoul National University College of Medicine

Bum-Joo Cho

Abstract

Investigation of a Retinal Degeneration Model in Rabbit Eyes Using Intravitreal Injection of Sodium Iodate

Bum-Joo Cho

Medicine, Ophthalmology

The Graduate school

Seoul National University

Purpose: To evaluate the retinal changes following intravitreal injection of sodium iodate (SI) and explore a monocular retinal degeneration model in rabbit eyes.

Methods: Twenty New Zealand white rabbits were divided into four groups, and received intravitreal injection of SI in one eye using one of four different doses (0.1, 0.2, 0.4, and 0.8 mg). Before, and for 28 days after injection, the eyes were examined anatomically and functionally using fundus photography, optical coherence tomography (OCT), and electroretinography (ERG). At post-injection days 2, 7, and 28, the eyes were enucleated and underwent histological examination.

Results: Visible changes in the fundi were not significant except the attenuation of chorioretinal vessels in the 0.8-mg group. In the 0.1-mg and 0.2-mg groups, no significant anatomical changes were seen except transient hyper-reflective dots over

vitreoretinal interface on OCT. In the 0.4-mg and 0.8-mg groups, disruption of ellipsoid zone and diffuse retinal swelling were observed in the early period on OCT. In the 0.4-mg group, the outer retina remained destroyed at day 28, whereas inner retina was relatively preserved. In the 0.8-mg group, the entire retina was severely destroyed and thinned at day 7, which did not recover afterward. The b-wave of ERG was reduced instantaneously after injection in all groups, which recovered completely in the 0.1-mg and 0.2-mg groups and partially in the 0.4-mg group. ERG was extinguished completely and did not recover in the 0.8-mg group. Histological findings corresponded to OCT results, showing a selective destruction of outer retina in the 0.4-mg group at day 7 and day 28. No structural or functional abnormalities were found in the non-injected fellow eyes.

Conclusions: Retinal degeneration following intravitreal injection of SI is dependent on the injection dose. The structural and functional retinal changes are reversible at low doses but irreversible at high doses. At a certain dose of SI, the outer retina can be ablated more selectively in rabbit eyes.

Keywords: sodium iodate, intravitreal injection, retinal degeneration, animal model

Student Number: 2012-31131

Contents

List of Tables

List of Figures

Introduction

Experimental animal models for retinal degeneration have been required to investigate the diseases involving retinal pigment epithelium (RPE) and photoreceptors.[1] Transgenic animal models have been developed to meet this need,[2-4] and a laser-induced model has also been promoted.[5] Most commonly, several retinotoxic agents including iodoacetate, nitroprusside, or N-methyl-N-nitrosourea, have been used to induce retinal degeneration.[6-8]

Among these, sodium iodate (SI) is widely adopted to induce outer retinal degeneration in various animals.[9] Systemic injection of SI has been reported to damage the RPE and photoreceptors selectively,[10,11] and has been used in many researches on retinal physiology, stem cell therapy, and retinal prostheses.[12-16]

However, the intravenous administration of SI always induces bilateral retinal degeneration and does not leave a healthy eye that can be used as a normal control. Systemic toxicity may also occur after the intravenous delivery.[17] To settle these issues, a few researchers have tried monocular intravitreal injection of SI,[18] but the detailed assessment of retinal changes over time and dose-response relationship is yet to be explored.

In this study, we investigated the sequential anatomical and functional changes of the retina after intravitreal delivery of several different doses of SI. The agent was injected into one eye, and the other non-injected eyes were examined as controls. Rabbits, which have an eyeball size similar to humans, were chosen to facilitate successive studies. Elucidating the process of retinal degeneration would

provide a better understanding of the mechanism of SI retinal toxicity and the physiology of retinal regeneration after toxic damages. To our knowledge, this is the first comprehensive study on the retinal degeneration after intravitreal injection of SI in animals.

Pilot Studies

Before the main study, pilot studies were performed to determine the dose of SI to be used in the main study.

Intravitreal injection of 1 mg SI

Based on the research of Siu et al that reported the whole retinal destruction one week after intravitreal injection of 10 mg SI,[18] we delivered 1 mg of SI intravitreally into the right eye of an adult albino rabbit, and observed the anatomical and functional changes of the retina for 7 days.

After intravitreal injection of SI, mild vitreous haze was seen in the fundus examination at day 4, and a minute vascular attenuation was observed at day 7 (Fig. 1). Optical coherence tomography (OCT) showed a significant reduction of retinal thickness at day 7. Electroretinography (ERG) showed complete extinguishment of a- and b-wave at the first examination day (day 4) that did not recover afterwards. On histological examination, retinal structure was destroyed almost completely.

By contrast, the non-injected contralateral eye did not show any remarkable changes in the fundus as well as on the OCT and ERG. Histological examination showed well-preserved normal retinal structures (Fig. 1).

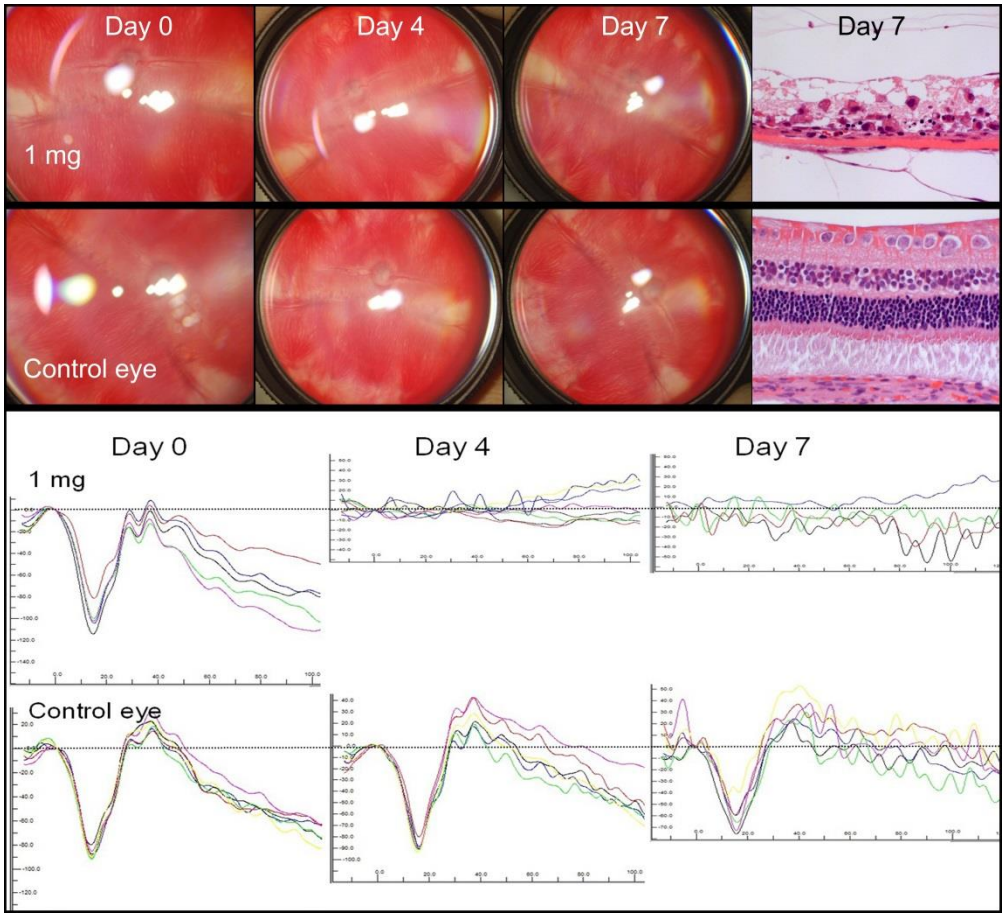

Figure 1. Fundus photography, histological sections, and electroretinography after intravitreal injection of 1 mg sodium iodate.

Intravitreal injection of 0.1 mg SI

After the first pilot study, we reduced the dose of SI by ten times and performed a second pilot study. An albino rabbit underwent a monocular intravitreal injection of 0.1 mg SI in the left eye and was followed up for 11 days to explore the anatomical and functional changes of the retina.

After the injection of 0.1 mg SI, no significant changes were found on the fundus examination during follow-up (Fig. 2). OCT showed no remarkable changes except sparse hyper-reflective dots on the internal limiting membrane (ILM) and in the vitreous cavity. The ERG showed no significant changes on the examination days. Histological examination using hematoxylin and eosin staining showed normal retinal structures at post-injection day 11 (Fig. 2). The contralateral eye showed no abnormal findings in all the examinations.

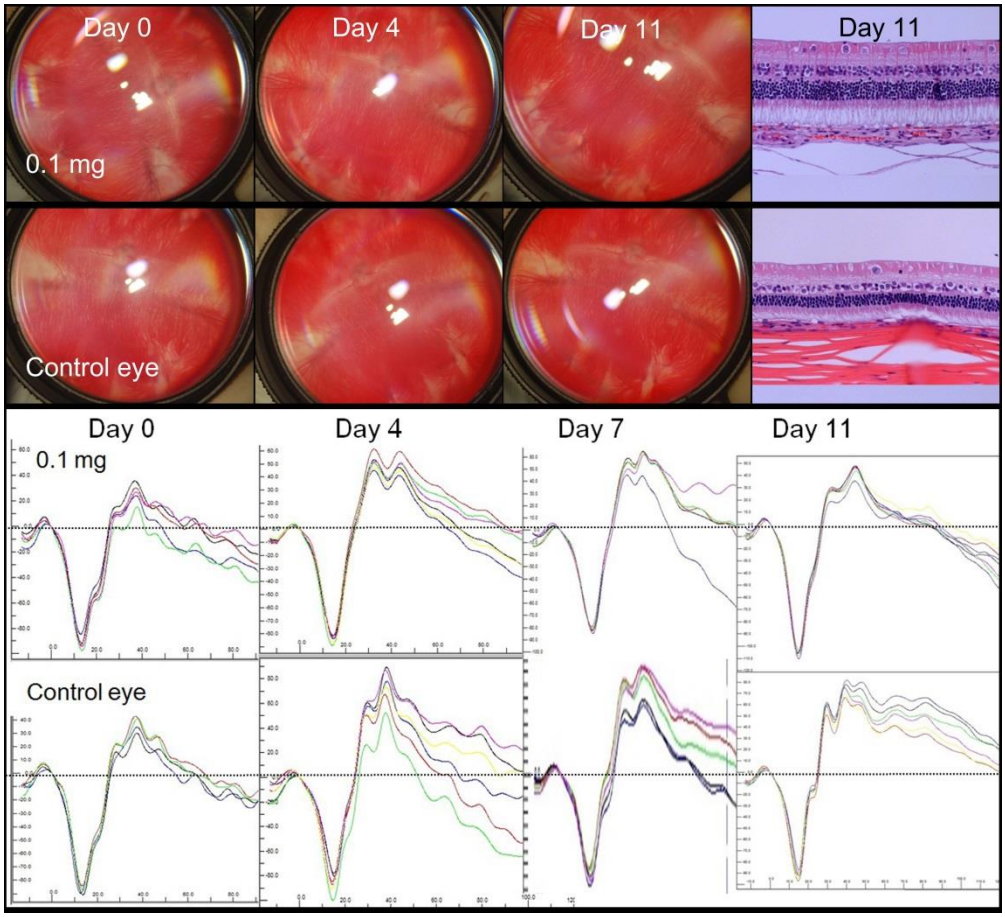

Figure 2. Fundus photography, histological sections, and electroretinography after intravitreal injection of 0.1 mg sodium iodate.

Intravitreal injection of 0.5 mg SI

After the second pilot study, we raised the dose of SI up to 0.5 mg and performed the third pilot study extending follow-up period to 15 days.

During the follow-up period, no significant changes were seen on the fundus examination (Fig. 3). On the other hand, OCT showed disruption of the outer retina from the post-injection day 1, which worsened until day 7 and recovered partially thereafter. Inner retina was also disrupted at day 5. The ERG showed reduction of both a-wave and b-wave amplitude, which recovered partially during follow-up (Fig. 3).

Summary of pilot studies

After 3 pilot studies, the scheduled dose of SI in the main study was determined as 0.1, 0.2, 0.4, and 0.8 mg for each group. To discern the differences in retinal damages according to different doses of SI, the experimental doses were doubled exponentially among groups.

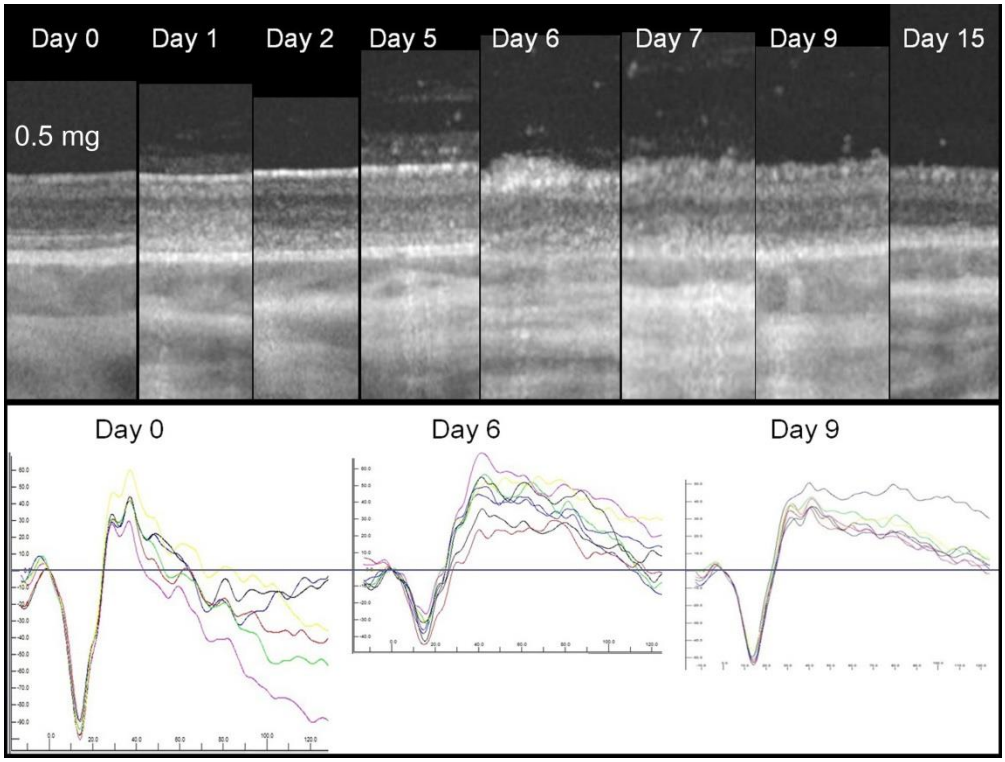

Figure 3. Sequential optical coherence tomography and electroretinography after intravitreal injection of 0.5 mg sodium iodate.

Materials and Methods

Animals

For the main study, adult female New Zealand White rabbits weighing 2.5–3.5 kg were used. The animals were 2 months of age and were reared in a temperature and light controlled environment that provided 12 h of light and 12 h of dark. Rabbits with any ocular pathology under pre-experimental examination were excluded; 20 rabbits were included in the study.

The study design and experimental protocols were approved by the Institutional Animal Care and Use Committee of the Seoul National University Hospital. All experimental procedures involving animals adhered to the ethical guidelines of the Laboratory Animal Care and Use Committee of the Association for Research in Vision and Ophthalmology.

Intravitreal Injection of SI

Sterile solutions of SI were freshly prepared at four concentrations (2, 4, 8, and 16 mg/ml) using solid SI powder (S4007, Sigma-Aldrich, St. Louis, MO) dissolved in 0.9% normal saline. Rabbits were anesthetized using a mixture of tiletamine hypochloride/zolazepam hypochloride (Zoletil®, Virbac, Carros, France; 15 mg/kg) and xylazine hydrochloride (Rompun®, Bayer Corp., Shawnee Mission, KA; 0.2 mL/kg). Topical proparacaine hydrochloride (Alcaine®, Alcon laboratories, Inc., Fort Worth, TX) and a diluted povidone-iodine solution were applied to the eye before injection.

Twenty rabbits were randomly allocated to four groups (N = 5 for each group). The rabbits were injected with a volume of 0.05 mL corresponding to the doses of 0.1, 0.2, 0.4, or 0.8 mg that were assigned to each group. The injections were administered intravitreally to the right eye using a 30 gauge needle syringe inserted 2 mm posterior to the limbus. No injections were administered to the left eyes. The injected right eyes were treated with a daily application of topical fluoroquinolone solution for up to 3 days after injection. All eyes were evaluated anatomically and functionally, before injection (day 0), and after injection on days 1, 2, 4, 7, 14, 21, and 28.

Anatomical Assessment Using Fundus Photography and OCT

To observe apparent anatomical retinal changes, the fundi were examined using a SuperQuad® 160 lens (Volk Optical, Inc., Mentor, OH) positioned over the cornea after applying topical phenylephrine hydrochloride and tropicamide drops (Mydrin®-P, Santen, Osaka, Japan) to achieve maximal pupillary dilation. Color fundus photographs were obtained from all eyes using a 35˚ fundus camera.

After fundus photography, in-vivo swept-source OCT was performed using a DRI OCT-1 Atlantis® imaging system (Topcon, Tokyo, Japan) and following a 9-mm high-resolution volume scan protocol. The SS-OCT system used a light source with a wavelength-sweeping laser centered at 1050 nm and had an axial resolution of 8 μm.[19] The area of visual streak below the optic disc, 3 mm ventral to the inferior edge of the optic nerve head, was scanned in cross-section without any lens.

Functional Assessment Using ERG

All eyes were evaluated using ERG during each follow-up examination. Before ERG, rabbits were dark-adapted for at least 30 min and were anesthetized by intramuscular injection using Zoletil® and Rompun.® The pupils were maximally dilated with Mydrin®-P 20 min before the ERG recording, and the cornea was anesthetized with topical Alcaine® drops. The ERGs were recorded using a handheld multispecies ERG unit (RetVet Corporation, Inc., Columbia, MO). A contact lens electrode with a built-in light-emitting diode (EW-202/LS-C, Mayo Corp., Inazawa, Japan) was used on a drop of 2% methyl cellulose over the cornea. A reference electrode was placed on the occipital area subcutaneously halfway between the base of the ear and eye, and the ground electrode was placed in the ear.[20] The ERG signals were filtered between a low-pass 300-Hz filter and high-pass 0.3-Hz filter.[21]

The ERGs were performed using the scotopic 3.0 protocol for maximal combined rod and cone response with a flash intensity of 1000 cd/m^2 and a duration of 3 ms, according to the International Society for Clinical Electrophysiology of Vision standard protocol.[21] All examinations were monocular with the companion eye occluded, carried out at room temperature, and with no evident tachypnea observed. Five responses were measured in each eye with an interval of more than 10 s. Each measurement was averaged with four responses with a stimulus interval of 10 s.

The ERG analysis was based on amplitude measurements of the a-wave (from baseline to negative trough) and b-wave (from the trough of the a-wave to the positive peak of the b-wave). ERG changes were considered significant if the difference in the amplitude of a-wave or b-wave was higher than 30% of the baseline amplitude.[22]

Histological Examination Using Light and Electron Microscopy

On day 2, 7, and 28, one rabbit from each group was euthanized using a lethal dose of potassium chloride (35 mg/kg) injected intravenously into the marginal auricular vein. Just after death, both eyes were enucleated and immersed in a mixture of 10% neutral-buffered formalin and 2.5% glutaraldehyde for 4 days. After fixation, the globes were cut into two pieces bisecting the visual streak perpendicularly.

One of the bisected pieces was dehydrated using a series of 95% ethanol baths and embedded in paraffin. Retinal 5-μm–thick trans-sections were obtained by microtome sectioning on poly-L-lysine-coated microscopic slides and stained with hematoxylin and eosin. The slides were examined to detect pathological changes in the retina using a light microscope (BX-50, Olympus Corp., Tokyo, Japan) and were photographed with a digital video camera (DP-71 CCD, Olympus Corp., Tokyo, Japan). The consistency of the retinal layers, loss of cellular elements, cell disorganization, apoptotic or necrotic degeneration, and the density of stained nuclei within each layer were assessed.[22]

To determine the ultra-microscopic pathologic changes, the other bisected piece was immersed in a 2.5% glutaraldehyde solution and processed with osmium tetroxide for transmission electron microscopy (TEM). The consistency of intracellular organelles such as mitochondria, endoplasmic reticulum, or nucleoli was carefully examined.

Statistical Analysis

Continuous variables are expressed as the mean ± the standard deviation. Data were analyzed using the Wilcoxon signed-rank test, Mann–Whitney U test, or repeated measure Kruskal–Wallis test. All statistical tests were 2-tailed, and statistical significance was defined by a $P < 0.05$. Statistical analyses were performed using SPSS 20.0 for Windows (IBM Corp., Armonk, NY).

Results

Anatomical Changes on Fundus Examination

Color fundus photographs of the eyes are presented in Fig. 4. In low dose groups (0.1 mg and 0.2 mg), no apparent retinal changes were observed during the follow-up examinations. On the other hand, there was transient vitreous haze at day 7 in the 0.4-mg group, which cleared thereafter. In the 0.8-mg group, attenuation of choroidal and retinal vasculature was observed after 7 days, as well as the atrophy of the retina and choroid. The chorioretinal atrophy and vascular attenuation progressed during the follow-up period, leading to retinal detachment in one eye at day 21. The anterior segment showed no distinct abnormal findings in all dose groups.

In the non-injected control eyes, no abnormalities were found in the fundi of all dose groups throughout the follow-up period, even in the highest dose (0.8 mg) group (Fig. 4E).

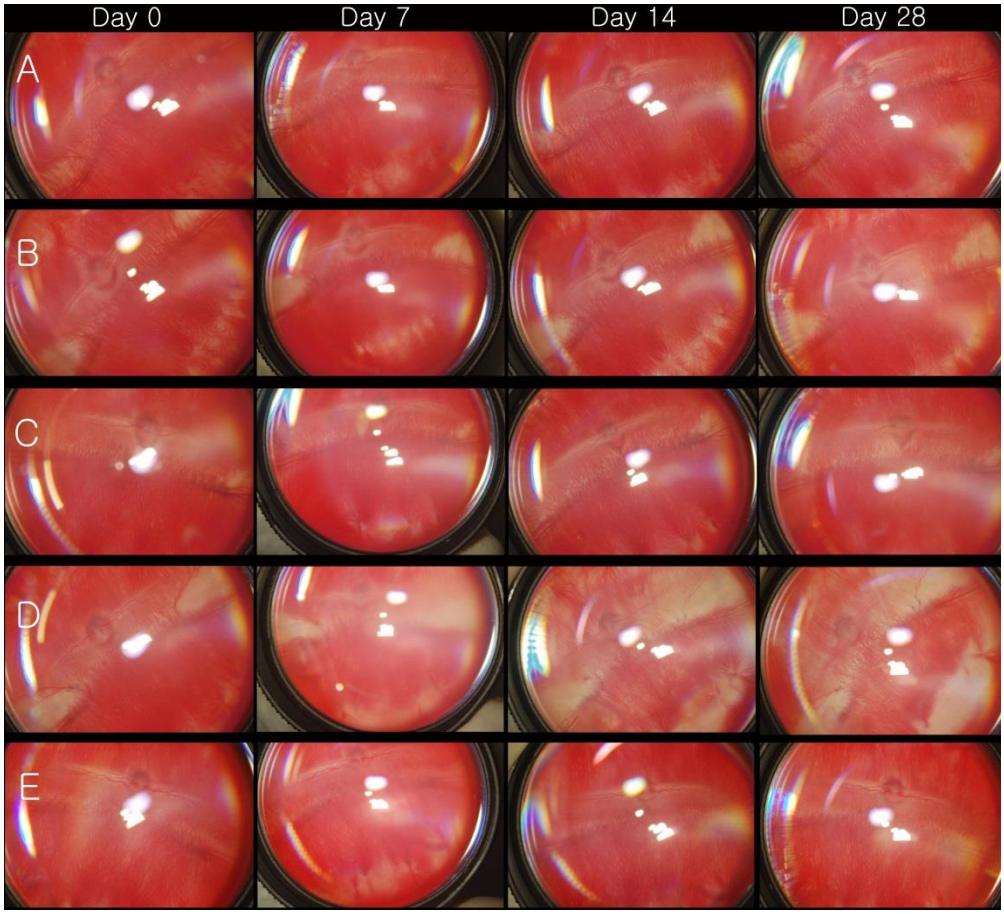

Figure 4. Sequential fundus photographs at day 0, 7, 14, and 28 of the rabbits that received monocular intravitreal injection of sodium iodate (SI). (A-D) Fundus images of the eyes injected with 0.1, 0.2, 0.4, and 0.8 mg of SI, respectively. (E) Fundus images of the non-injected fellow eye of the rabbit that received intravitreal injection of 0.8 mg SI.

Anatomical Changes on OCT

The OCT images over time are presented in Fig. 5. In low dose groups (0.1 mg and 0.2 mg), hyper-reflective dots were observed over the vitreoretinal surface and in the posterior vitreous cavity on OCT examination. In the 0.1-mg group, sparse hyper-reflective dots appeared at day 7, but no other anatomical abnormality was seen on OCT during the follow-up period. At day 28 after injection, the OCT images returned to normal as same as the image of day 0 (Fig. 5A).

In the 0.2-mg group, multiple hyper-reflective dots appeared at day 4, accompanied by mild blurring of the ellipsoid zone. These changes recovered over time, achieving normal retinal structures at day 7 except few remnant hyper-reflective dots (Fig. 5B).

In the 0.4-mg group, the disruption of ellipsoid zone was observed at day 1 (Fig. 5C). The whole retinal layers showed an increased signal reflectance as well as mild swelling. The swelling of retinal nerve fiber layer (RNFL) and ganglion cell layer (GCL) was more prominent. At day 2, ILM was split from the RNFL in part of the retina. Seven days after intravitreal injection, outer nuclear layer (ONL) was found to be reduced significantly. However, inner nuclear layer (INL) was identified well. After 2 weeks, the inner plexiform layer (IPL) and INL were slightly thinned. By contrast, the outer plexiform layer (OPL) was significantly reduced and the ONL nearly disappeared. This outer retinal thinning was persistent until day 28. At day 28, the increased signal reflectance on OCT return to normal and hyper-reflective dots disappeared.

In the highest dose (0.8 mg) group, significant swelling of the inner retina was observed at post-injection day 1 (Fig. 5D). The swollen inner retina eventually

split the next day, and after that, the outer retina was destroyed progressively. The retina became almost completely atrophied by day 7, which did not recover by day 28. At day 28, the retinal layers were hardly visible on OCT, and the underneath choroid was also thinned. By contrast, the fellow eye did not show any abnormalities on OCT during the follow-up period (Fig. 5E).

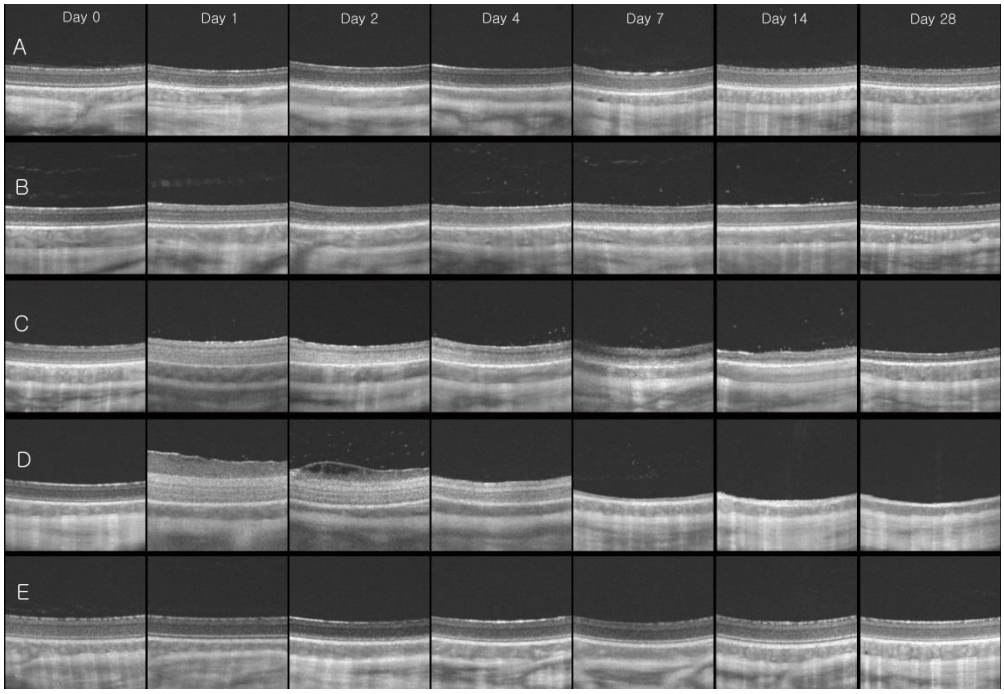

Figure 5. Sequential optical coherence tomography (OCT) images at day 0, 1, 2, 4, 7, 14, and 28 of the rabbits that received monocular intravitreal injection of sodium iodate (SI). (A-D) OCT images of the eyes injected with 0.1, 0.2, 0.4, and 0.8 mg of SI, respectively. (E) OCT images of the non-injected fellow eye of the rabbit that received intravitreal injection of 0.8 mg SI.

Functional Changes in ERG

The changes in ERG waveform of each dose group are demonstrated in Fig. 6. Even in the lowest dose group (0.1 mg), an instantaneous change was observed in the ERG waveform beginning one day after injection (Fig. 6A). The instantaneous change was the loss of the b-wave in all dose groups, and also included the loss of a-wave in the 0.2-mg or higher dose groups. These changes recovered completely in the low dose groups (0.1 mg and 0.2 mg), but only partially in the 0.4-mg group. In the 0.8-mg group, ERG was extinguished from the next day after injection, and never recovered (Fig. 6D).

The changes over time in the amplitude of a- and b-wave of ERG in each group are suggested in Fig. 7 and Fig. 8. The a-wave amplitude was reduced in all dose groups in the early period (Fig. 7). The decrease of a-wave amplitude was reversible in the 0.1-mg and 0.2-mg group, but irreversible in the 0.8-mg group until day 28.

The amplitude of the b-wave decreased significantly at day 1 in all groups (Fig. 8). The decrease was reversible in low dose groups (0.1 mg and 0.2mg). In the 0.4-mg group, mean amplitude of b-wave at baseline was 178.7 ± 37.1 μV, but the magnitude was significantly decreased to one fifth (35.5 ± 16.2 μV) at day 28 ($P = 0.005$). In comparison, the a-wave and b-wave were extinguished completely and were never restored in the 0.8-mg group.

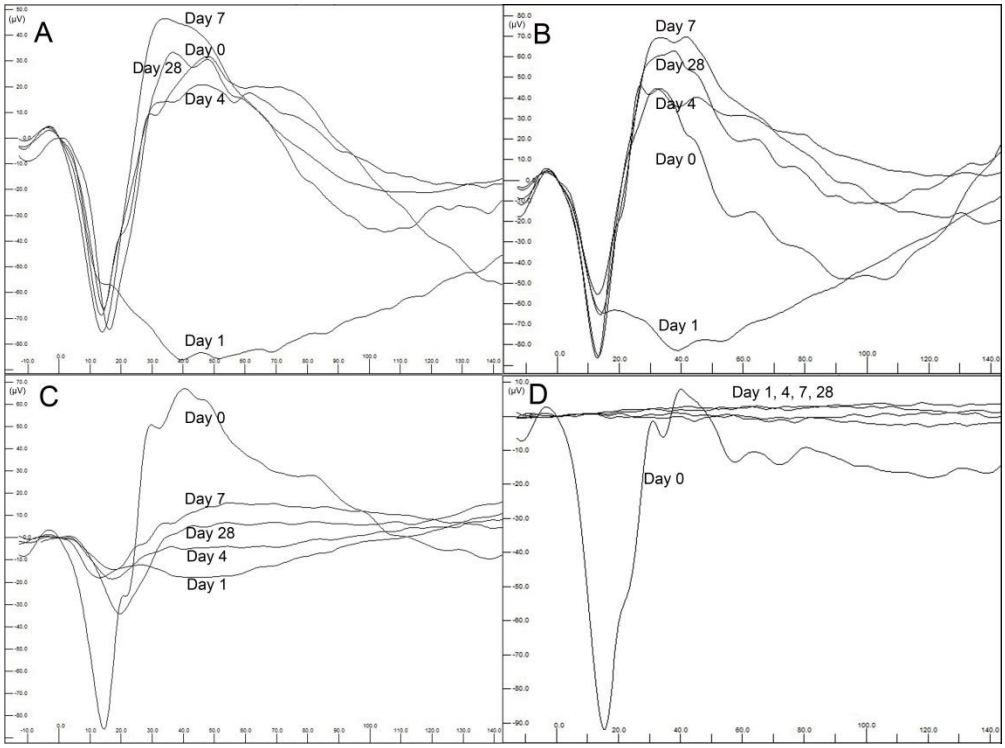

Figure 6. Electroretinographic (ERG) waves of rabbits before (day 0) and after (day 1, 4, 7, and 28) intravitreal injection of sodium iodate (SI). (A-D) ERG waveforms of the eyes injected with 0.1, 0.2, 0.4, and 0.8 mg of SI, respectively.

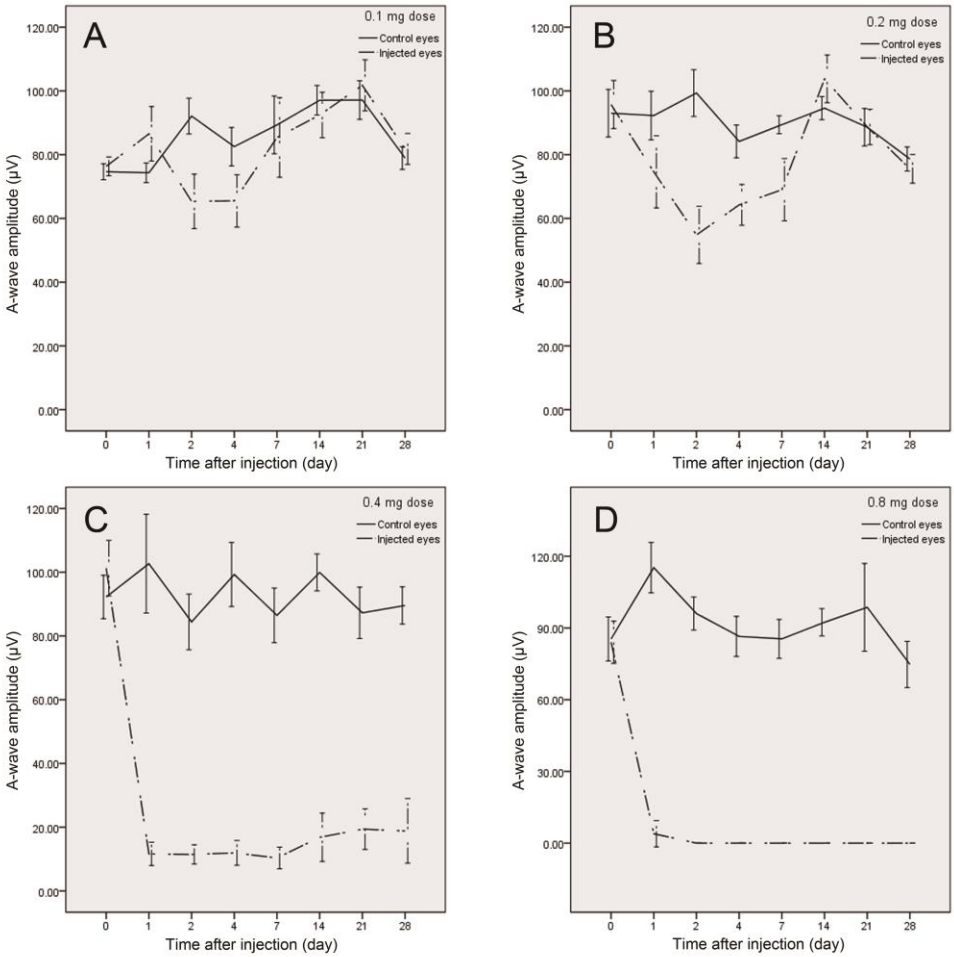

Figure 7. The a-wave amplitude of electroretinography in rabbits before and after intravitreal injection of sodium iodate (SI). (A-D) The change of a-wave amplitude over time after injection with 0.1, 0.2, 0.4, and 0.8 mg dose of SI, respectively.

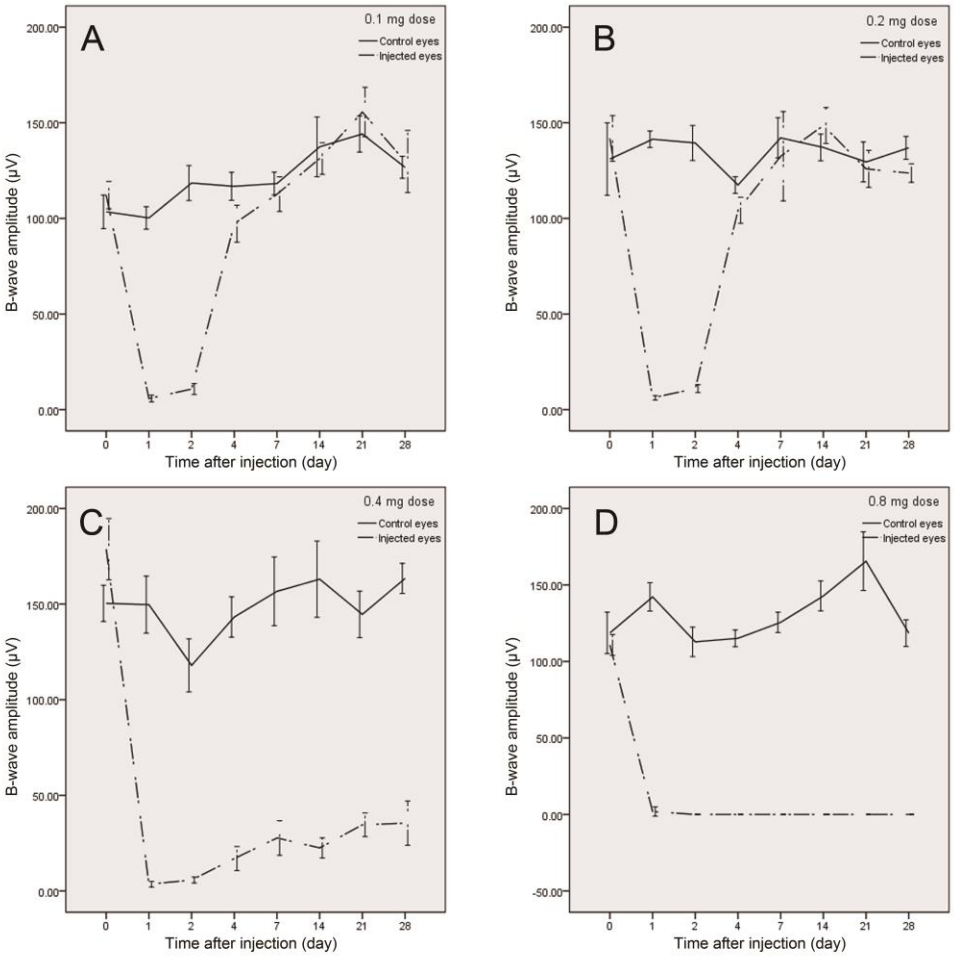

Figure 8. The b-wave amplitude of electroretinography in rabbits before and after intravitreal injection of sodium iodate (SI). (A-D) The change of b-wave amplitude over time after injection with 0.1, 0.2, 0.4, and 0.8 mg dose of SI, respectively.

Histological Changes on Light Microscopy

Histological examination using hematoxylin and eosin staining under light microscopy is presented in Fig. 9. There were no remarkable abnormalities in the RPE or neurosensory retina in the eyes injected with SI at doses of 0.1 or 0.2 mg (Fig. 9A and 9B). All retinal layers showed normal cellularity and intact structures.

In the 0.4-mg group, there was photoreceptor destruction at day 7 showing only scanty photoreceptor nuclei (Fig. 9C). The ONL and OPL thicknesses were significantly decreased. After one month, the photoreceptor layers, including the ONL and OPL, had hardly recovered, but the inner retinal layers including the INL, IPL, and GCL were quite preserved. In the highest dose group (0.8 mg), the retinal specimen at day 2 showed the split of ILM and the destruction of the inner retina (Fig. 9D). At day 7, the entire retina was destroyed almost completely, which did not recover by day 28.

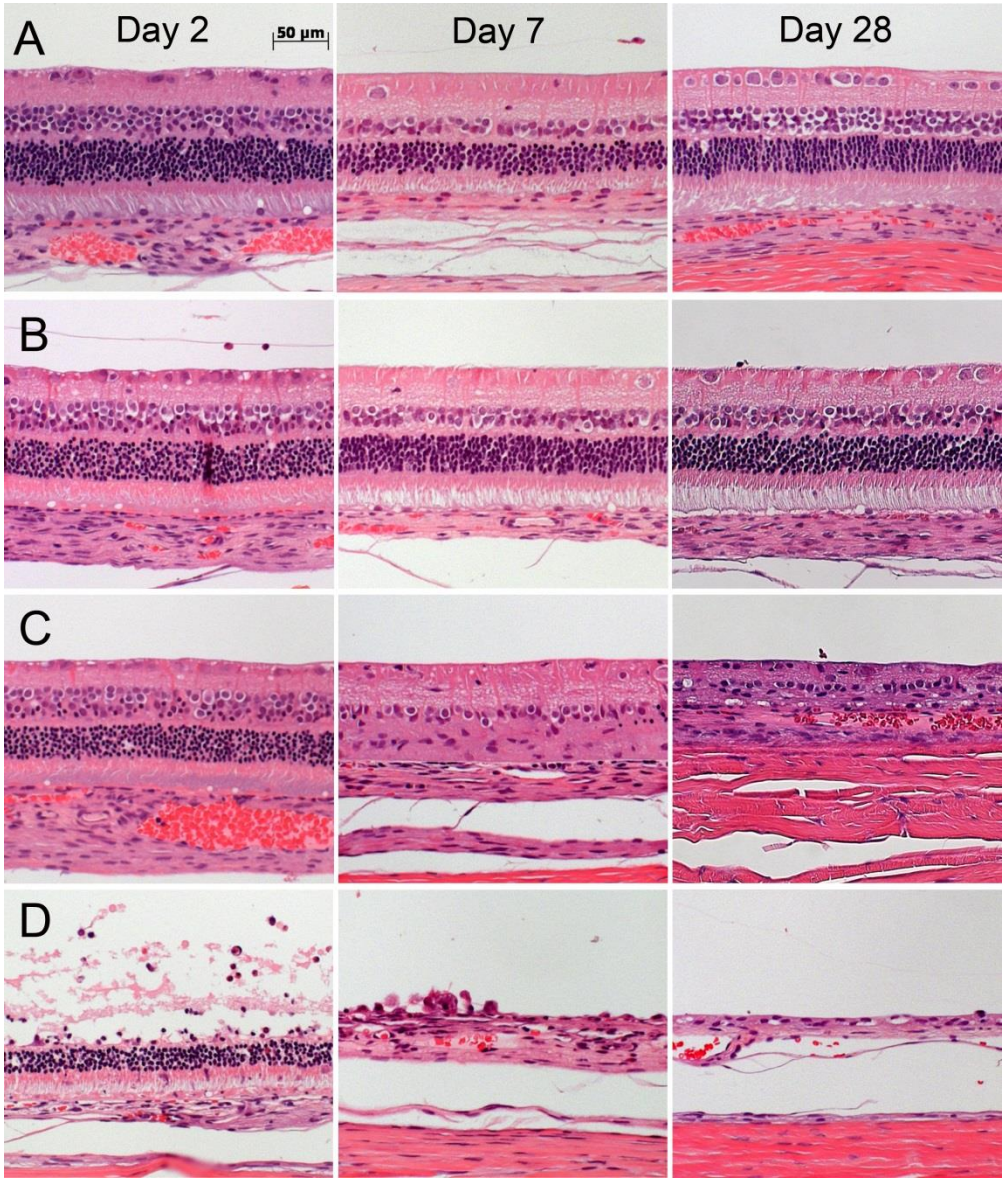

Figure 9. Sequential retinal histological sections at day 2, 7, and 28 on light microscopy using hematoxylin and eosin staining in rabbits that received intravitreal injection of sodium iodate (SI). (A-D) Histological sections of the eyes injected with 0.1, 0.2, 0.4, and 0.8 mg dose of SI, respectively.

Histologic Changes on Electron Microscopy

The TEM images at day 2 and day 28 of each group are shown in Fig. 10. Electron microscopic examination showed no remarkable changes in the RPE and photoreceptors of the eyes injected with 0.1 mg of SI. The pigmentation as well as intracellular organelle was not influenced by 0.1 mg of SI (Fig. 10A and 10E). When 0.2 mg of SI was injected, photoreceptors did not show significant changes, but some RPE cells showed increased number of intracellular vacuoles at day 28 (Fig. 10F).

In the eyes injected with 0.4 mg of SI, multiple vacuoles were found in the cytoplasm of the RPE cells at day 2 (Fig. 10C). After one month, photoreceptors were very scarce, and the RPE cells were observed to be partly covering between the INL and choroid. The nucleolus was less prominent compared to baseline and the number of cytoplasmic pigmentary bodies was increased (Fig. 10G).

In the eyes injected with 0.8 mg of SI, the nuclear envelope of RPE cell was partly destroyed at day 2 (Fig. 10D). At day 28, the RPE cells had a lengthy nucleus, and composed a thin layer over the choroid (Fig. 10D).

Systemic Side Effects

No apparent systemic side effects or dysfunction related to the injection of SI were observed during the follow-up period.

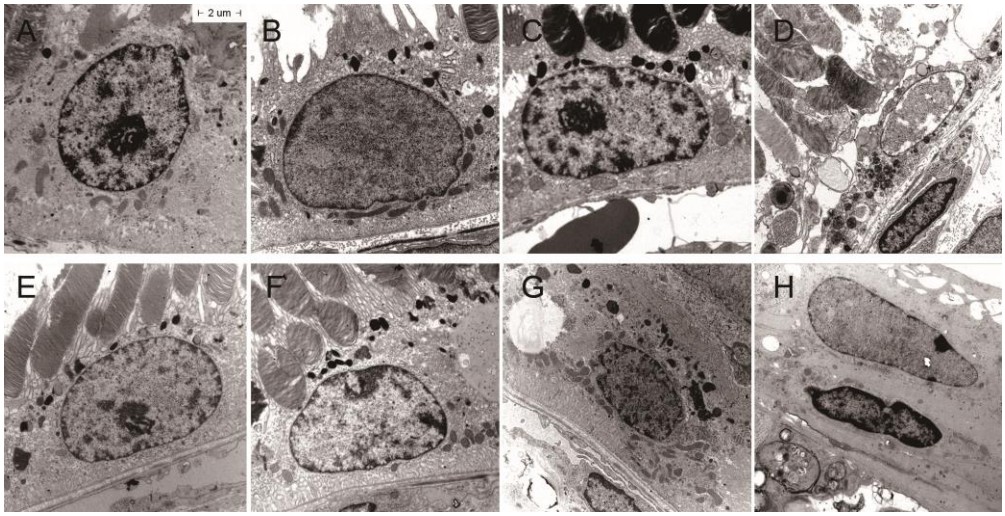

Figure 10. Transmission electron microscopy images of rabbits that received intravitreal injection of sodium iodate (SI). (A-D) Retinal pigment epithelium (RPE) at day 2 of the eyes injected with 0.1, 0.2, 0.4, and 0.8 mg dose of SI, respectively. (E-H) RPE at day 28 the eyes injected with 0.1, 0.2, 0.4, and 0.8 mg dose of SI, respectively.

Discussion

In the present study, we tried a novel approach to induce retinal degeneration using intravitreal injection of SI, and investigated the anatomical and functional changes over time for several different doses of SI. Both anatomical and functional changes appeared in a dose-dependent manner, and the retinal degeneration was reversible on low doses and irreversible on high doses. There were no anatomical or functional changes in the non-injected fellow eyes. The ratio of the concentration resulting in acute entire destruction to the concentration inducing minimal or no anatomical changes was within 8. This ratio was higher than that in the intravenous injection of SI.[23]

A merit of this study is the use of OCT in the evaluation of structural changes over time as in-vivo images. Most researches on the retinal toxicity of SI were performed before the development of OCT, and thus could not measure serial anatomical changes in the same individual.[24-29] Recently, OCT enabled in-vivo evaluation of the retina after the administration of SI in mice and rats without sacrificing animals,[10,30,31] but the OCT data after SI injection are not widely available in rabbits,[15] especially in albino rabbits. This study is the first that presented the OCT data after SI injection in albino rabbit eyes.

The use of OCT in the current study enabled the detection of early significant changes in the inner retina such as pronounced RNFL swelling and split of ILM from RNFL. Main structural changes during the first few days after intravenous injection were necrotic destruction of RPE and photoreceptors, and not

that of inner retina.[2,11,15,32,33] The intense inner retinal reaction in this study has not been reported in previous studies using intravenous delivery of SI,[2,11,15,32,33] and might be attributed to intravitreal route of administration, considering that intravitreally-injected SI meets inner retina first before meeting outer retina. Intravenous injection would deliver chemical agents to the inner and outer retinae simultaneously through retinal vessels, or to the outer retina more in abundance considering the blood flow of choriocapillaris is more plentiful than that of retinal vessels.[24]

The structural changes on OCT in the present study were very subtle when low dose of SI was given, and prominent when high dose was delivered. In high dose groups, retinal swelling and disruption of ellipsoid zone were observed immediately from day 1, as reported for intravenous injection.[3,10] Retinal degeneration including breakage of RPE barrier has been reported to appear as early as within 24 hr after intravenous injection of SI.[25,34] The active destruction process on OCT within the first week in this study became alleviated thereafter. Previous studies have reported the recovery of RPE cells 1–2 weeks after SI injection.[25,35,36] Korte el al reported a subsequent recovery of the breakdown of RPE barrier one week after injection.[37] It is also reported that RPE cells regenerate or are replaced by a heterogeneous cell layer one week after intravenous injection of SI.[38] After vigorous destruction, necrotic RPEs are removed by macrophages, and the spared RPEs regenerate.[39] Similarly, retinal destruction began to decline one week after intravitreal injection of SI in this study.

Regenerating RPE shows changes in cell shape, polarity and intercellular adhesion.[37] Regenerated RPE cells of flat shape with short microvilli were observed

over Bruch's membrane in rats after 2 weeks from SI injection.[40] The regenerated RPE cells support the surviving photoreceptors and help their recovery.[41] The mechanisms of RPE regeneration are not fully understood yet, but it is suggested that retinal cells might retain an intrinsic capacity to divide and regenerate in the post-injury period when SI is used in low doses.[42] It has been suggested that the regenerative process in the retina involves the expression of multiple genes involved in retinal neurogenesis, cell differentiation, and re-establishment of the morphologic structure.[42]

The structural changes over time after intravitreal injection in this study were similar to those after intravenous administration except for the inner retinal changes.[35] The slow recovery following the destruction period within one week were also similar in intravenous and intravitreal models.[41] The retinal status one month after intravitreal injection of high dose of SI included retinal thinning, reduction of RPE and photoreceptors, retinal vascular attenuation, and atrophy of choriocapillaris which were observed in the intravenous injection models.[11,31,37]

Interestingly, fundus changes visible to the naked eye were not distinct in most groups except the highest dose (0.8 mg) group. While there were depigmentation of RPE and the atrophy of RPE and choriocapillaris in pigmented rabbits after the injection of SI,[9,15] visible fundus changes in albino rabbits were suggested to be indistinct,[9] probably because of the absence of melanin pigments in the RPEs. However, we were able to identify the attenuation of chorioretinal vasculature as well as retinal detachment in the eyes of 0.8-mg group. Therefore, a close fundus examination would enable to detect the fundus changes caused by SI toxicity.

The early electron microscopy findings after intravenous injection of SI included mitochondrial swelling,[24] defragmentation of RPE cell nuclei,[33] disorganization of the rod outer segment,[43] the loss of smooth endoplasmic reticulum and vesicles,[24] disappearance of cytoplasmic structures and basal infoldings,[12,24] granular debris, and fibrin-like materials.[12] When a high dose is injected, the change occurs as early as 7-10 hr after injection, from in the RPEs.[24] The microscopic changes of high dose groups in the present study were similar to those in previous studies.[12,24] The changes at day 2 in the 0.8-mg group were very similar to those at 24 hr after intravenous injection of 50 mg/kg SI.[24] The changes at day 7 in the 0.8-mg group were very similar to those at day 6.[24]

Notably, functional changes occurred instantaneously in all investigated doses, whereas structural changes were not apparent in low dose groups. The early functional change was an abrupt vanishment of b-wave in ERG which had appeared immediately after intravenous injection of SI in previous studies.[31,44] In the 0.2 mg- or higher dose groups, the loss of a-wave, which might be considered as the dysfunction of photoreceptors,[3] was also observed. While the histologic findings at day 2 as well as the OCT findings at day 1 and day 2 appeared to be nearly normal in the low-dose groups, the ERG waveform dramatically changed beginning the day after injection. In previous studies, ERG change appeared within 1 hr after intravenous injection of SI.[45] It is possible that hidden microscopic cellular changes may have existed. The ERG might be helpful in detecting subtle degenerative change after toxic retinal damage.

One of the interesting findings in this study is that the outer retina was selectively ablated and the inner retina relatively preserved at a certain dose. After

the injection of 0.4 mg SI, the inner retina was not fully destroyed by day 7, and the damage did not worsen much after that period. Meanwhile, the outer retina remained significantly destroyed at day 28. The ERG also showed a remaining response in this group, and the response recovered slightly at day 28. The intact structure of the ganglion and bipolar cell layers resembled the histological finding in retinitis pigmentosa (RP).[46] This could imply the usefulness of this model in researches for RP patients.

Thus far, the effect of SI on photoreceptors has been suggested to be secondary to the damage of RPE cells.[11,23,47] After the breakdown of blood-retinal barrier supported by RPE, photoreceptors are exposed to choroidal circulation directly and could be harmed continuously.[11] The destruction of photoreceptors is considered as a process of apoptosis.[11] However, recent experiments proposed that neuronal cells are also sensitive to SI toxicity and the intravenous administration of SI has a direct effect on photoreceptors.[31,48] Further experiments would be required to elucidate the mechanism of SI toxicity more in detail.

The precise pathogenesis of the damage on RPE cells by SI is yet to be determined, but has been attributed to several mechanisms.[44] Suggested mechanisms include inhibition of various enzymes such as triose phosphate dehydrogenase or lactate dehydrogenase,[23] destruction of zonula occludens and alterations in the strength of adhesion,[44,49] breakdown of the basal membrane of RPE cell,[50] increased ability of melanin to convert glycine to glyoxylate which is a cytotoxic compound,[51] and denaturation of some retinal protein involved in metabolic cycles.[24] These reactions might be due to the oxidizing property of SI considering the co-administration of anti-oxidants such as cysteine reduces the damage of RPE.[45,52] The

degeneration process of RPE cells is supposed as necrosis combined with kariolysis and melanin clumping.[11,24]

Since Sorsby reported pigmentary degeneration in the rabbit retina following intravenous injection of SI,[9] the SI-induced animal models have been used in numerous studies on the physiology and pathology of RPE and photoreceptors.[12,25,53] The SI-induced retinal degeneration model has been adopted in mice,[2,11,23,30,41,44] rats,[48,54] sheep,[55] and rabbits.[15,24,27,28,45,47,56,57] Previous important studies investigating SI-induced retinal degeneration in rabbit eyes are summarized in Table 1. These studies used intravenous administration of SI, and the injection doses have ranged from 20 to 50 mg/kg.[32,36] Intravitreal delivery has been rarely used.

Table 1. Retinal degeneration induced by sodium iodate in previous studies using rabbits.

Authors	Year	Animal	Intravenous injection dose (mg/kg)	Time at investigation after injection
Sorsby[9]	1941	Pigmented rabbit	5 ml of the 2% solution	2 – 15 day
Sorsby et al[34]	1964	Himalayan rabbit	25	8 – 24 hr
Negi et al[26]	1983	New Zealand pigmented rabbit	40	1 hr
Korte et al[37]	1984	New Zealand pigmented rabbit	25, 2 times	24 hr – 11 wk
Kitano et al[12]	1988	Pigmented Dutch rabbit	30	2 – 36 hr
Korte et al[32]	1993	New Zealand White rabbit	50	6 – 7 day
Humayun et al[14]	1994	Pigmented Dutch	40	5 mo
Takeuchi et al[58]	1995	Pigmented Dutch	30	1 – 4 hr
Korte et al[39]	1995	Albino rabbits	25, 2 times	7 day
Obata et al[36]	2005	Pigmented Dutch rabbit	20	4 – 21 day
Siu et al[18]	2007	Pigmented rabbit	40	1 week
Siu et al[16]	2008	Pigmented Dutch rabbit	40	1 week
Amirpour et al[13]	2012	albino and pigmented rabbits	50	7 day

The comparison between intravenous injection and intravitreal injection of SI is presented in Table 2. In both administration models, the SI-induced retinal changes are dose-dependent.[11] The onset of damage is instantaneous in both,[44] which starts within one hour after the injection.[26] On the other hand, there are some differences between two models. First, there is an obvious damage to the innermost retina in the acute phase when using intravitreal injection of SI. Whereas a marked RPE damage preceded the neurosensory retinal damage in the intravenous model,[11] the inner retinal damage was more prominent than the RPE damage in the early period after intravitreal delivery of SI. This could be attributed to the administration route as mentioned above. Secondly, the preservation of the contralateral eye as a control is possible in the intravitreal injection model.

Of note, the retinal architecture and function are fully preserved in the non-injected contralateral eyes of the intravitreal administration model, as seen in this study as well as in previous studies.[18] Recently, the intravitreal injection of N-methyl-N-nitrosourea was used to induce retinal degeneration.[8] Intravenous verteporfin injection followed by photodynamic therapy, or intravitreal injection of sodium nitroprusside has also been suggested as a monocular photoreceptor degeneration model for rabbits.[5,7] The benefits of a monocular model for retinal degeneration include the use of the companion eye as a control, which provides a more controlled comparison within the same individual. It also reduces the number of animals required for the experiment, and is more compatible with current ethical considerations for animal experiments. The current study suggests a new way of establishing monocular retinal degeneration using SI in rabbits.

Table 2. Comparison of retinal degeneration animal models using intravenous or intravitreal administration of sodium iodate.

	Intravenous injection model	Intravitreal injection model
Onset of action	Instantaneous	Instantaneous
Destruction period	Usually within 1 week Followed by recovery period	Usually within 1 week Followed by recovery period
Dose-dependence	Yes	Yes
Selective outer retinal destruction	Unclear	Possible
Commonly-used or recommended dose	40 mg/kg in rabbits	0.4 mg for an eye in rabbits
Monocular retinal destruction	Impossible	Possible
Possible Complications	Systemic side effects	Cataract, endophthalmitis, etc.

There might be some shortcomings in the intravitreal administration of drugs. One possible disadvantage would be the unequal distribution of SI in the vitreous cavity due to uneven liquefaction of vitreous gel. This may reduce the reproducibility of the effect of SI on the retina. Nevertheless, the reproducibility in this study was quite good. The high water solubility of SI and the abundant content of water in the vitreous gel might explain the results. To the contrary, the margin between the effective and lethal dose was greater compared to that for intravenous injection.[9]

A recent study explored the retinal changes after intravenous injection of SI in rabbits for a long period.[15] Wang et al injected 40 mg/kg of SI into pigmented rabbits intravenously, and observed the retinal destruction for 18 months.[15] In their study, a significant loss of INL and the migration of RPE cells were observed at one month after injection, but much part of the retina still remained.[15] Fundus examination showed RPE degeneration and atrophy of the choroid which were found in 0.8-mg group of the present study. [15] The visually evoked potential was not extinguished after one week, but eventually extinguished after two weeks.[15] Considering that the 0.4-mg group in the present study showed no gross fundus changes, the 40 mg/kg dose of SI for intravenous injection might correspond to a higher dose than 0.4 mg for intravitreal injection and to a lower dose than 0.8 mg. A higher dose, 50 mg/kg, is suggested to be lethal in high percentage of the subjects,[24] and 60 mg/kg is reported to be fatal.[9] Some researchers tried a lower dose of intravenous SI injection than 40 mg/kg,[12,58] but these studies were performed before the development of OCT, and the selectivity of outer retinal destruction was not well demonstrated.

The limitations of the present study may include the small number of subjects and the individual differences in the responses to SI toxicity. The strength of this study may include the use of in-vivo OCT images with histological sections. We determined that in-vivo OCT images have good correlation with histologic findings. Based on this study, future studies would be able to use the OCT images not sacrificing subjects for histological examination. Using cheap chemical agent, SI, to induce retinal degeneration might be also better than adopting expensive genetically-engineered models from an economic perspective. We identified the possibility of a monocular retinal degeneration model, especially the outer retinal degeneration model using an appropriate dose of SI.

Conclusion

In conclusion, the retinal degeneration over time following intravitreal injection of SI was dependent on the injection dose. The anatomical and functional retinal changes were reversible at low doses, and irreversible at high doses. The outer retina was selectively damaged after injecting a certain dose of SI.

By contrast, the non-injected fellow eyes did not show any distinct changes both anatomically and functionally, even in rabbits that received a devastating dose of SI for the retina in the present study. Therefore, these eyes might be used as normal controls in the future researches.

This study provided a novel approach for the induction of retinal degeneration by using intravitreal injection of SI. This method might be useful in the investigation of outer retinal diseases such as RP or age-related macular degeneration.

References

1. Chader GJ. Animal models in research on retinal degenerations: past progress and future hope. Vision Res 2002;42(4):393-9.

2. Kiuchi K, Yoshizawa K, Shikata N, et al. Morphologic characteristics of retinal degeneration induced by sodium iodate in mice. Curr Eye Res 2002;25(6):373-9.

3. Muraoka Y, Ikeda HO, Nakano N, et al. Real-time imaging of rabbit retina with retinal degeneration by using spectral-domain optical coherence tomography. PLoS One 2012;7(4):e36135.

4. Jones BW, Kondo M, Terasaki H, et al. Retinal remodeling in the Tg P347L rabbit, a large-eye model of retinal degeneration. J Comp Neurol 2011;519(14):2713-33.

5. Nishida K, Kamei M, Kondo M, et al. Efficacy of suprachoroidal-transretinal stimulation in a rabbit model of retinal degeneration. Invest Ophthalmol Vis Sci 2010;51(4):2263-8.

6. Yamauchi Y, Agawa T, Tsukahara R, et al. Correlation between high-resolution optical coherence tomography (OCT) images and histopathology in an iodoacetic acid-induced model of retinal degeneration in rabbits. Br J Ophthalmol 2011;95(8):1157-60.

7. Isago H, Sugano E, Murayama N, et al. Establishment of monocular-limited photoreceptor degeneration models in rabbits. BMC Ophthalmol 2013;13:19.

8. Rosch S, Johnen S, Mataruga A, et al. Selective photoreceptor degeneration by intravitreal injection of N-methyl-N-nitrosourea. Invest Ophthalmol Vis Sci 2014;55(3):1711-23.

9. Sorsby A. Experimental pigmentary degeneration of the retina by sodium iodate. Br J Ophthalmol 1941;25(2):58-62.

10. Yang Y, Ng TK, Ye C, et al. Assessing sodium iodate-induced outer retinal changes in rats using confocal scanning laser ophthalmoscopy and optical coherence tomography. Invest Ophthalmol Vis Sci 2014;55(3):1696-705.

11. Machalinska A, Lubinski W, Klos P, et al. Sodium iodate selectively injuries the posterior pole of the retina in a dose-dependent manner: morphological and electrophysiological study. Neurochem Res 2010;35(11):1819-27.

12. Kitano S, Hori S, Nagataki S. Transport of fluorescein in the rabbit eye after treatment with sodium iodate. Exp Eye Res 1988;46(6):863-70.

13. Amirpour N, Karamali F, Rabiee F, et al. Differentiation of human embryonic stem cell-derived retinal progenitors into retinal cells by Sonic hedgehog and/or retinal pigmented epithelium and transplantation into the subretinal space of sodium iodate-injected rabbits. Stem Cells Dev 2012;21(1):42-53.

14. Humayun M, Propst R, de Juan E, Jr., et al. Bipolar surface electrical stimulation of the vertebrate retina. Arch Ophthalmol 1994;112(1):110-6.

15. Wang K, Li XX, Jiang YR, Dong JQ. Influential factors of thresholds for electrically evoked potentials elicited by intraorbital electrical stimulation of the optic nerve in rabbit eyes. Vision Res 2007;47(23):3012-24.

16. Siu T, Morley J. Implantation of episcleral electrodes via anterior orbitotomy for stimulation of the retina with induced photoreceptor degeneration: an in vivo feasibility study on a conceptual visual prosthesis. Acta Neurochir (Wien) 2008;150(5):477-85; discussion 85.

17. Murray MM. The effects of administration of sodium iodate to man and animals.

Bull World Health Organ 1953;9(2):211-6.

18. Siu TL, Morley JW. Influence of callosal transfer on visual cortical evoked response and the implication in the development of a visual prosthesis. Graefes Arch Clin Exp Ophthalmol 2007;245(12):1797-803.

19. Matsuo Y, Sakamoto T, Yamashita T, et al. Comparisons of choroidal thickness of normal eyes obtained by two different spectral-domain OCT instruments and one swept-source OCT instrument. Invest Ophthalmol Vis Sci 2013;54(12):7630-6.

20. Patane MA, Schubert W, Sanford T, et al. Evaluation of ocular and general safety following repeated dosing of dexamethasone phosphate delivered by transscleral iontophoresis in rabbits. J Ocul Pharmacol Ther 2013;29(8):760-9.

21. Marmor MF, Fulton AB, Holder GE, et al. ISCEV Standard for full-field clinical electroretinography (2008 update). Doc Ophthalmol 2009;118(1):69-77.

22. Dolz-Marco R, Gallego-Pinazo R, Pinazo-Duran MD, et al. Intravitreal docosahexaenoic acid in a rabbit model: preclinical safety assessment. PLoS One 2014;9(5):e96872.

23. Enzmann V, Row BW, Yamauchi Y, et al. Behavioral and anatomical abnormalities in a sodium iodate-induced model of retinal pigment epithelium degeneration. Exp Eye Res 2006;82(3):441-8.

24. Grignolo A, Orzalesi N, Calabria GA. Studies on the fine structure and the rhodopsin cycle of the rabbit retina in experimental degeneration induced by sodium iodate. Exp Eye Res 1966;5(1):86-97.

25. Ringvold A, Olsen EG, Flage T. Transient breakdown of the retinal pigment epithelium diffusion barrier after sodium iodate: a fluorescein angiographic and morphological study in the rabbit. Exp Eye Res 1981;33(4):361-9.

26. Negi A, Marmor MF. The resorption of subretinal fluid after diffuse damage to the retinal pigment epithelium. Invest Ophthalmol Vis Sci 1983;24(11):1475-9.

27. Textorius O, Welinder E, Nilsson SE. Combined effects of DL-alpha-aminoadipic acid with sodium iodate, ethyl alcohol, or light stimulation on the ERG c-wave and on the standing potential of albino rabbit eyes. Doc Ophthalmol 1985;60(4):393-400.

28. Korte GE, Gerszberg T, Pua F, Henkind P. Choriocapillaris atrophy after experimental destruction of the retinal pigment epithelium in the rat. A study in thin sections and vascular casts. Acta Anat (Basel) 1986;127(3):171-5.

29. Yoon YH, Marmor MF. Retinal pigment epithelium adhesion to Bruch's membrane is weakened by hemicholinium-3 and sodium iodate. Ophthalmic Res 1993;25(6):386-92.

30. Machalinska A, Lejkowska R, Duchnik M, et al. Dose-dependent retinal changes following sodium iodate administration: application of spectral-domain optical coherence tomography for monitoring of retinal injury and endogenous regeneration. Curr Eye Res 2014;39(10):1033-41.

31. Wang J, Iacovelli J, Spencer C, Saint-Geniez M. Direct effect of sodium iodate on neurosensory retina. Invest Ophthalmol Vis Sci 2014;55(3):1941-53.

32. Korte GE, Wanderman MC. Distribution of Na+ K(+)-ATPase in regenerating retinal pigment epithelium in the rabbit. A study by electron microscopic cytochemistry. Exp Eye Res 1993;56(2):219-29.

33. Redfern WS, Storey S, Tse K, et al. Evaluation of a convenient method of assessing rodent visual function in safety pharmacology studies: effects of sodium iodate on visual acuity and retinal morphology in albino and pigmented rats and

mice. J Pharmacol Toxicol Methods 2011;63(1):102-14.

34. Sorsby A, Reading HW. Experimental degeneration of the retina. XI. The effect of sodium iodate on retinal -SH levels. Vision Res 1964;4(10):511-4.

35. Korte GE, Rappa E, Andracchi S. Localization of alkaline phosphatase on basolateral plasma membrane of normal and regenerating retinal pigment epithelium. A cytochemical study in rabbits. Invest Ophthalmol Vis Sci 1991;32(13):3187-97.

36. Obata R, Yanagi Y, Tamaki Y, et al. Retinal degeneration is delayed by tissue factor pathway inhibitor-2 in RCS rats and a sodium-iodate-induced model in rabbits. Eye (Lond) 2005;19(4):464-8.

37. Korte GE, Reppucci V, Henkind P. RPE destruction causes choriocapillary atrophy. Invest Ophthalmol Vis Sci 1984;25(10):1135-45.

38. Flage T, Ringvold A. The retinal pigment epithelium diffusion barrier in the rabbit eye after sodium iodate injection. A light and electron microscopic study using horseradish peroxidase as a tracer. Exp Eye Res 1982;34(6):933-40.

39. Korte GE, Mrowiec E, Landzberg KS, Youssri A. Reorganization of actin microfilaments and microtubules in regenerating retinal pigment epithelium. Exp Eye Res 1995;61(2):189-203.

40. Ogata N, Kanai K, Ohkuma H, Uyama M. [Pathologic response of the regenerated retinal pigment epithelium (RPE)--affected by sodium iodate (NaIO3)]. Nihon Ganka Gakkai Zasshi 1989;93(4):466-74.

41. Mizota A, Adachi-Usami E. Functional recovery of retina after sodium iodate injection in mice. Vision Res 1997;37(14):1859-65.

42. Machalinska A, Kawa MP, Pius-Sadowska E, et al. Endogenous regeneration of damaged retinal pigment epithelium following low dose sodium iodate

administration: an insight into the role of glial cells in retinal repair. Exp Eye Res 2013;112:68-78.

43. Hariri S, Moayed AA, Choh V, Bizheva K. In vivo assessment of thickness and reflectivity in a rat outer retinal degeneration model with ultrahigh resolution optical coherence tomography. Invest Ophthalmol Vis Sci 2012;53(4):1982-9.

44. Franco LM, Zulliger R, Wolf-Schnurrbusch UE, et al. Decreased visual function after patchy loss of retinal pigment epithelium induced by low-dose sodium iodate. Invest Ophthalmol Vis Sci 2009;50(8):4004-10.

45. Heike M, Marmor MF. L-cystein protects the pigment epithelium from acute sodium iodate toxicity. Doc Ophthalmol 1990;75(1):15-22.

46. Stone JL, Barlow WE, Humayun MS, et al. Morphometric analysis of macular photoreceptors and ganglion cells in retinas with retinitis pigmentosa. Arch Ophthalmol 1992;110(11):1634-9.

47. Noell WK. Experimentally induced toxic effects on structure and function of visual cells and pigment epithelium. Am J Ophthalmol 1953;36(6 2):103-16.

48. Tao Z, Dai J, He J, et al. The influence of NaIO(3)-induced retinal degeneration on intra-retinal layer and the changes of expression profile/morphology of DA-ACs and mRGCS. Mol Neurobiol 2013;47(1):241-60.

49. Ashburn FS, Jr., Pilkerton AR, Rao NA, Marak GE. The effects of iodate and iodoacetate on the retinal adhesion. Invest Ophthalmol Vis Sci 1980;19(12):1427-32.

50. Konda BR, Pararajasegaram G, Wu GS, et al. Role of retinal pigment epithelium in the development of experimental autoimmune uveitis. Invest Ophthalmol Vis Sci 1994;35(1):40-7.

51. Baich A, Ziegler M. The effect of sodium iodate and melanin on the formation of

glyoxylate. Pigment Cell Res 1992;5(6):394-5.

52. Sorsby A, Harding R. Protective effect of cysteine against retinal degeneration induced by iodate and by iodoacetate. Nature 1960;187:608-9.

53. Campochiaro PA, Bryan JA, 3rd, Conway BP, Jaccoma EH. Intravitreal chemotactic and mitogenic activity. Implication of blood-retinal barrier breakdown. Arch Ophthalmol 1986;104(11):1685-7.

54. Anstadt B, Blair NP, Rusin M, et al. Alteration of the blood-retinal barrier by sodium iodate: kinetic vitreous fluorophotometry and horseradish peroxidase tracer studies. Exp Eye Res 1982;35(6):653-62.

55. Nilsson SE, Knave B, Persson HE. Changes in ultrastructure and function of the sheep pigment epithelium and retina induced by sodium iodate. I. The ultrastructure of the normal pigment epithelium of the sheep. Acta Ophthalmol (Copenh) 1977;55(6):994-1006.

56. Suyama T. Electron microscopic study on experimental retinal degeneration induced by sodium iodate injection. Yonago Acta Med 1967;11(3):222-31.

57. Flage T. Changes in the juxtapapillary retinal pigment epithelium following intravenous injection of sodium iodate. A light and electron microscopic study using horseradish peroxidase as a tracer. Acta Ophthalmol (Copenh) 1983;61(1):20-8.

58. Takeuchi A, Kricorian G, Marmor MF. Albumin movement out of the subretinal space after experimental retinal detachment. Invest Ophthalmol Vis Sci 1995;36(7):1298-305.

국문 초록

목적: 본 연구는 백색가토에서 유리체강 내에 요오드산나트륨을 주입하였을 때 나타나는 망막의 해부학적, 기능적 변화들을 규명하고, 아울러 백색가토의 단안 망막변성모델 제작의 가능성에 대해 조사하고자 하였다.

방법: 백색가토 20 마리를 5마리씩 4군으로 나누어, 각 가토의 단안에 요오드산나트륨을 군별로 0.1, 0.2, 0.4, 0.8 mg씩 유리체강 내로 주사 투여하였다. 투여 전 및 투여 후 28일 간, 각 가토에 대해 안저 검사, 빛간섭단층촬영 및 망막전위도 검사를 시행하였다. 투여 후 2, 7, 28일째에 각 군당 한 마리씩 가토를 희생시켜 안구를 적출한 뒤, 광학현미경 및 투과전자현미경으로 조직학적 검사를 시행하였다.

결과: 요오드산나트륨 0.8 mg을 유리체강 내에 투여한 군에서는 투여 후 1주일 이상 경과하면서 맥락망막혈관의 감쇄가 관찰되었으나, 그 외의 군에서는 육안으로 뚜렷한 망막의 변화가 관찰되지 않았다. 모든 군에서 투여 다음 날부터 망막전위도 b 파의 급격한 감소가 관찰되었으며, 이는 0.1 mg 및 0.2 mg 군에서는 이후 정상 수준으로 회복되었고, 0.4 mg 군에서는 부분적으로 회복되었으며, 0.8 mg 군에서는 회복되지 않았다.

빛간섭단층촬영 결과, 0.1 mg 및 0.2 mg 군에서 투여 후 수 일 뒤 망막의 가장 내층에 약간의 과반사점들이 관찰되었고, 0.2 mg 군에서 타원구역의 일부가 흐려졌으나, 이들 군에서 그 밖의 특별한 이상소견은 관찰되지 않았다. 0.4 mg 군에서는 투여 후 1주일 내에 망막내층의 부종 및 분리와 망막외층의 파괴가 관찰되었는데, 이러한 변화는 이후 상당히 회복되었으나, 망막외층은 28일째에도 부분적으로만 회복되었다. 0.8 mg 군은 투여 후 1주일 내에 망막의 전층이 파괴되었고, 이는 다시 회복되지 않았다. 조직학적 검사에서 0.1 mg 및 0.2 mg 군에서는 특별한 변화가 관찰되지 않았으나, 0.4 mg 군에서는 28일째에 망막의 외층이 선택적으로 파괴된 모습이 관찰되었다.

결론: 백색가토에서 유리체강 내 요오드산나트륨 투여 후 나타나는 망막의 변성은 투여 용량 및 투여 후 경과기간에 따라 다르게 나타났다. 약물을 저용량으로 투여할 경우 망막의 구조 및 기능이 정상 수준으로 회복되었으나, 고용량 투여 시에는 회복되지 않았다. 투여 후 망막외층이 비교적 선택적으로 파괴되는 요오드산나트륨의 용량이 존재하였다.

주요어: 요오드산나트륨, 유리체강내 주사, 망막변성, 동물모델

학 번: 2012-31131