Abstract

Radiographic Reclassification of Ameloblastoma and Evaluation of the Local Effects Using CT Images

Jun-Bum Cho, DDS.

Department of Oral and Maxillofacial Radiology,

Graduate School, Seoul National University

(Directed by Prof. Kyung-Hoe Huh, DDS, MSD, PhD)

1. Objective

The objectives of this research were to perform multi-planar evaluation of ameloblastoma using computerized tomography (CT) images, reclassify the lesions in terms of locularity, and investigate the differences in the local effects according to the locularity, volume of lesion, and distribution of solid tumor nodules.

2. Materials and Methods

CT and panoramic images of 144 patients that were histologically diagnosed as ameloblastoma from 2003 to 2013 were reviewed

retrospectively. The lesions were classified radiographically as unilocular, pseudo-multilocular, or multilocular group according to the presence and completeness of septum on CT images. Then, each respective panoramic image was examined, and the radiographic appearances on both images were compared. The prevalence of each group was calculated.

Incidence rates of local effects, such as cortical perforation and external root resorption, were calculated for each radiographic group. The volumes of lesions were also measured and then tested for correlation with locularity, cortical perforation, and external root resorption, respectively.

Twenty-seven cases with contrast-enhanced CT images were studied to verify any correlation between the volume of the solid tumor nodule and the total volume of the entire lesion, locularity, cortical perforation, and external root resorption. The relationship between the location of the solid tumor nodule and cortical perforation/root resorption was also investigated.

3. Results

Unilocular ameloblastoma was the most frequently encountered radiographic group in this study. Out of 144 ameloblastoma cases, sixty-three (43.7%), forty-five (31.3%), and thirty-six (25.0%) lesions were classified as unilocular, pseudo-multilocular, and multilocular ameloblastomas, respectively, under examination with CT images. Cortical perforation was found most commonly in multilocular ameloblastoma (83.3%), pseudo-multilocular ameloblastoma (62.2%), and unilocular

ameloblastoma (41.3%), in decreasing order of incidence rate. External root resorption was found most commonly in unilocular ameloblastoma (72.6%), pseudo-multilocular ameloblastoma (70.5%), and multilocular ameloblastoma (68.8%), in decreasing order of incidence rate.

Volumes of the lesions were also measured. The correlations between volume of lesion and locularity, cortical perforation, and root resorption were all tested to be statistically not significant ($P>0.05$).

Different amounts of solid tumor nodules were verified within the lesions on contrast-enhanced CT images. Correlation between the volume of lesion and solid tumor nodules was tested positive and statistically significant ($P<0.05$). These solid nodules were found in adjacent areas of cortical perforation rather than the areas of root resorption.

4. Conclusion

Different locularities, and distribution of solid nodules resulted in different effects on the surrounding structures. Therefore, examination with CT images is essential for the exact evaluation of ameloblastomas, proper treatment planning, and better prognosis of the patients.

Keywords: Ameloblastoma, CT, unilocular, multilocular

Student Number: 2010-22012

Radiographic Reclassification of Ameloblastoma and Evaluation of the Local Effects Using CT Images

Jun-Bum Cho, DDS

Department of Oral and Maxillofacial Radiology,

Graduate School, Seoul National University

(Directed by Prof. Kyung-Hoe Huh, DDS, MSD, PhD)

- Contents -

I. Introduction

Ameloblastoma is the most common benign odontogenic tumor, accounting for 1% of all tumors in the head and neck region and approximately 11% to 29% of all odontogenic tumors.[1-9] They are usually locally aggressive and destructive tumors with a strong tendency for recurrence.[10] Therefore, exact examination and diagnosis are essential for the correct choice of surgical method and subsequent optimal results.

Ameloblastomas can be classified histologically into (1) the 'conventional' solid or multicystic ameloblastoma, (2) the unicystic ameloblastoma, (3) the peripheral ameloblastoma, and (4) the desmoplastic ameloblastoma.[11-12] The conventional multicystic ameloblastoma is the most common, comprising 80~92% in one large series.[10,13] However, this method of classification has limits in the sense that the exact histological examination cannot be obtained preoperatively.

On the other hand, ameloblastomas can be classified radiographically as either unilocular or multilocular ameloblastoma, according to the presence of septum.[13] Generally, conventional multicystic ameloblastomas appear as multilocular or "soap-bubble" radiolucencies, and unicystic ameloblastomas appear as unilocular radiolucencies.[14] A panoramic radiograph is a good tool for radiographic examination of ameloblastoma since it demonstrates the entire extent of the lesion and its relationship with the surrounding structures.[15] However, the established previous classification of

ameloblastoma with these two-dimensional radiographs has been performed without consideration of the three-dimensional appearance of septum.

This limitation gives rise to a problem where a lesion with incomplete septum may appear as a multilocular lesion with septated compartments in panoramic radiographs, even though it is not originally multilocular.[16] As result, information on the prevalence of each group of ameloblastoma found in literature is considered inaccurate. Exact classification and evaluation of each group is needed.

We hypothesized that there would be a difference in behavior between these lesions with incomplete septa (so called “pseudo-multilocular” ameloblastoma) and those true multilocular ameloblastomas with complete internal septa. The objectives of this research were to perform multi-planar evaluation of ameloblastoma using computerized tomography (CT) images, reclassify the lesions in terms of locularity, and investigate the differences in the effects on surrounding structures according to locularity, volume of lesions, and distribution of solid tumor nodules.

II. Materials and Methods

A total of 221 ameloblastoma cases of the last 10 years retrieved from the files of Seoul National University Dental Hospital between 2003 and 2013 were studied retrospectively. The pathological diagnoses were confirmed with the hematoxylin-eosin slides by the Department of Oral Pathology. Seventy seven cases of recurrent and peripheral ameloblastomas were excluded from the study. This study was approved by Seoul National University Dental Hospital Institutional Review Board.

Panoramic and CT images of 144 patients were studied by an Oral and Maxillofacial radiologist with over 10 years of experience. The lesions were classified into three groups according to the presence and completeness of septum: unilocular ameloblastomas, lesions with no internal septum (Fig 1); pseudo-multilocular ameloblastomas, single locule with incomplete septum or septa and thus giving an illusion of multilocular spaces rather than representing truly septated compartments (Fig 2); multilocular ameloblastomas, lesions with complete septum (Fig 3). Then, the panoramic radiographs of each case were examined, and the lesions were classified in terms of locularity: either unilocular (Fig 4) or multilocular (Fig 5 and 6), since accurate evaluation of the internal septum was not available. The comparison of the radiographic appearances of the lesions on CT and panoramic images were performed. Then, the incidence rates of local effects, such as cortical perforation (abrupt discontinuity of cortical lining)

and external root resorption, were calculated and compared between the radiographic groups. Those cases where the lesions had occurred in edentulous areas were excluded from the calculation regarding external root resorption.

The volumes of the lesions were calculated by measuring the surface area of the lesion on each axial CT image using PACS viewer software (π-View STAR, Infinitt Co., Seoul, Korea) and multiplying the sum of the surface areas by the distance between each slide, which was 1~3 mm, depending on the settings.

Contrast-enhanced CT images were found in 27 cases. These cases were reviewed to verify the effects of the solid tumor nodules on the surrounding structures (Fig 7a and b). The volumes of the solid tumor nodules were calculated in the same method as mentioned above and tested for correlation with the volume of the entire lesion, locularity, cortical perforation, and root resorption, respectively. Then, the location of the solid tumor nodule was also investigated; the numbers of each of the cases where the nodules were found adjacent to the cortical perforation and those adjacent to the root resorption sites were counted.

Statistical analysis

Using the software of IBM SPSS Statistics 21.0 (SPSS, Chicago, IL, USA), comparison of local effects between the three groups was carried out by Chi-square test. Pearson correlation test was used to compare the

relationships between volume of lesion and locularity, cortical perforation, and external root resorption; relationships between volume of solid tumor nodule and volume of entire lesion, locularity, cortical perforation, and external root resorption were also compared. Significance was set at $P<0.05$.

III. Results

CT and panoramic images of 144 ameloblastoma cases were reviewed in this study. Under examination with CT images, 63 cases (43.7%) were classified as unilocular ameloblastomas; 45 cases (31.3%) were classified as pseudo-multilocular ameloblastomas; 36 cases (25.0%) were classified as multilocular ameloblastomas (Table 1).

On panoramic radiographs, 75 cases were classified as unilocular ameloblastomas, whereas 69 were classified as multilocular ameloblastomas (Table 1). The results revealed that CT and panoramic images showed 82.7% concurrence (62 out of 75 cases) regarding radiographic interpretation of unilocular ameloblastoma, 52.2% (36 out of 69 cases) for pseudo-multilocular ameloblastoma, and 46.4% (32 out of 69 cases) for multilocular ameloblastoma (Table 1).

Table 2 showed the effects of each group on surrounding cortical bones. It was found that 37 cases (58.7%) of the unilocular ameloblastoma group (n=63) showed cortical expansion without perforation. In pseudo-multilocular ameloblastoma group (n=45), 28 cases (62.2%) showed cortical perforation. In multilocular ameloblastoma group (n=36), 30 cases (83.3%) showed cortical perforation. The statistic difference was considered significant between the three groups ($P<0.05$).

Table 3 showed the number of cases where external resorption of roots was found. In unilocular ameloblastoma group (n=62), 45 cases (72.6%)

presented with resorption of adjacent tooth roots; 31 cases (70.5%) in pseudo-multilocular group (n=44); 22 cases (68.8%) in multilocular ameloblastoma group (n=32). The differences in the prevalence of root resorption between the three groups were not statistically significant (P>0.05).

The volumes of the 144 lesions ranged from 0.3 cm^3 to 184.3 cm^3. The mean was 22.6 cm^3. However, the correlation test results between volume of lesion and locularity, cortical perforation, and root resorption did not show statistical significance (P>0.05).

Contrast-enhanced CT images of 27 patients were reviewed. Six lesions were filled with fluid attenuation without solid tumor nodules and 21 cases presented with internal solid tumor nodules. The enhanced solid tumor nodules were found to have different volumes, ranging from 0.3 cm^3 to 77.2 cm^3, while the volume of the entire lesions ranged from 1.3 cm^3 to 84.4 cm^3. To test the correlation between the volumes of the solid tumor nodules and the entire lesions, the data was log transformed for better fits, and a positive and significant correlation was observed (r = 0.583). However, each of the correlations between the volume of solid tumor nodule and locularity, cortical perforation, and root resorption was not statistically significant (P>0.05).

Twenty out of 21 cases where solid tumor nodules were found presented cortical perforation. Solid tumor nodules were found in adjacent areas of cortical perforation in 15 cases out of these 20 cases (75%). Thirteen cases

presented with root resorption, and only 6 cases (46%) presented solid tumor nodules adjacent to the site of root resorption.

IV. Discussion

It is well recognized that multilocular ameloblastoma is the most common and prevalent form.[17-18] However, for some reason, unilocular radiolucency was the most frequently encountered radiographic appearance (43.7%) in the present study. On the other hand, true multilocular ameloblastomas accounted for only 25.0% of the lesions in this study. This is probably due to the fact that the precise internal morphology including the completeness of septum was not considered with much importance in the past, and all the ameloblastomas exhibiting multilocular radiolucencies, including true multilocular ameloblastomas and pseudo-multilocular ameloblastomas were classified as one group when examined with panoramic radiographs. However, the two types were classified as different groups in this study, which resulted in decreased rate of incidence for multilocular ameloblastoma. Even considering this fact, however, the large number of unilocular group was noteworthy.

It has been stated that unilocular ameloblastomas typically occur more often in younger patients than multilocular ameloblastomas.[19] There is always an on-going debate regarding the origin of unilocular ameloblastoma, but it could be hyphothesized that unilocular ameloblastoma develops into multilocular ameloblastoma in advanced stages. If so, early detection of lesion due to easy access to dental clinics, improvement of diagnostic tools, and high standard of living of patients

compared to previous days may be considered as possible reasons for the high rate of incidence of unilocular ameloblastoma in the present study.

However, if late detection of lesion was responsible for high incidence rate of multilocular ameloblastoma in the past, increased volume of lesion should have resulted in increased locularity. In the present study, however, no statistically significant correlation between volume of lesion and locularity was found.

The limitations of the present study lie in the fact that growth rate of lesion and time concept were not considered. Questions regarding the relationship between volume of lesion and growth rate still remain. Moreover, volume of lesion was neither correlated with cortical perforation or root resorption, which implies that other factors such as differences of behavior or growth rate are probably related with local effects rather than the size of lesion.

Our findings show that lesions found to be unilocular under CT examination are generally unilocular, as well, when examined with panoramic images. However, pseudo-multilocular and multilocular ameloblastomas were found to share similar radiographic appearances under panoramic examination. Thirty-six out of 45 pseudo-multilocular ameloblastomas (80.0%) and 32 out of 36 multilocular ameloblastomas (88.9%) exhibited multilocular radiolucency on panoramic images. The two groups were not distinguishable under panoramic examination. This, in turn, meant that only 46.4% of lesions exhibiting multilocular radiolucency on

panoramic radiographs were classified as true multilocular ameloblastomas when examined with CT images; 52.2% of the lesions were classified as pseudo-multilocular group.

Inaccurate classification of ameloblastomas carried out with panoramic radiographs may bring confusion to clinicians regarding the nature of lesions. We encourage examination and exact classification using CT images. Furthermore, these groups of ameloblastomas classified with CT images need to be re-classified according to the histological subtypes; local effects and biological behaviors, including aggressiveness and proliferative ability, of each radiographic group need to be studied.

According to the present study, the effects of each group on surrounding structures were different. Multilocular ameloblastoma group showed the highest prevalence of cortical perforation, whereas external root resorption was found most commonly in unilocular ameloblastoma group, although it was not statistically significant. This indicates that different factors are responsible for changes in the cortical bone and resorption of tooth roots. Further studies on these factors that characterize the behavior of lesions and the mechanisms that the lesions undergo for changes in the cortical bone and roots of teeth are necessary to fully understand the nature of ameloblastoma.

We hypothesized that the soft mass nodules found in the contrast-enhanced CT images could also aid us in understanding the nature of ameloblastoma regarding its local effects on the cortical bone and roots of

teeth. It may be questionable to give a conclusion without including the concept of time and growth rate of the expanding lesion at this point, but our results showed that the correlation between the volume of the solid tumor nodules and the volume of the entire lesion was positive and statistically significant, which indicates that the soft mass nodules grow in size as time passes. On the other hand, the volume of the solid tumor nodule was irrelevant to the locularity, cortical perforation, and resorption of root. The locations of these nodules are thought to be associated with cortical perforation, since most of the solid tumor nodules were found adjacent to the cortical perforation sites. However, the sample size used in the present study was small, and we think that further studies with comprehensive sample sizes are required.

There are several reports that reveal relationship between the biological behaviors, mainly proliferative ability and recurrence, and the histological type, such as multicystic, unicystic, peripheral and desmoplastic ameloblastoma.[10,18,20-22] However, histological classification of ameloblastoma has certain limitations in the sense that the exact histological types of lesions cannot be determined preoperatively. Biopsy can be carried out before surgery, but it brings additional injuries to patients. Moreover, a preoperative biopsy can only be representative for a small portion of the lesion, and there are chances that it will result in incorrect classification, especially when the lesions are embedded deeply in the bone.[23] The present study provides multi-planar radiographic information

based on CT images regarding the behavior of lesions that can be used during the process of diagnosis and treatment planning without additional injuries to patients.

Treatment modalities for ameloblastomas are many and controversial; they may be divided mainly into conservative and radical therapies.[24] Many authors agree that radical therapies are needed for lesions exhibiting multilocular radiolucencies in panoramic radiographs.[20] Classification of pseudo-multilocular ameloblastoma is important in the sense that it discourages the choice of radical surgery as a routine way for multilocular lesions just because of their two-dimensional radiographic appearance. Although additional studies regarding the proliferative ability and recurrence rate of the specific radiographic subtypes are needed, we think that our study provides new insights regarding classification and general knowledge of ameloblastomas.

V. Conclusion

We were able to reclassify ameloblastoma into three different radiographic groups using CT images. Most of the lesions classified as unilocular or multilocular radiographic group on CT images were also found to exhibit unilocular or multilocular radiolucencies, respectively, on panoramic images. However, most of the lesions in pseudo-multilocular group also exhibited multilocular radiolucencies on panoramic images. Pseudo-multilocular and multilocular groups were not distinguishable under panoramic examination.

Different locularities and distribution of solid nodules resulted in different effects on the surrounding structures. Therefore, examination with CT images is essential for the exact evaluation of ameloblastomas, proper treatment planning, and subsequent better prognosis of the patients.

VI. References

1. Sciubba JJ, Fantasia JA, Kahn LB. Benign odontogenic tumors. In: Atlas of tumor pathology-tumors and cysts of the jaw. Washington, DC: AFIP, 1999: 1-85.
2. Regezi JA, Sciubba J. Odontogenic tumors. In: Oral Pathology: Clinical Pathological Correlations (ed 2). Philadelphia: Saunders Elsevier, 1993: 363–371.
3. Cawson RA, Binnie WH, Spieght PM, Barrett AW, Wright JM. Ameloblastoma. In: Lucas's Pathology of Tumors of the Oral Tissues (ed 5). London: Churchill Livingstone, 1998: 25–44.
4. Eversole LR, Tomich CE, Cherrick HM. Histogenesis of odontogenic tumors. Oral Surg Oral Med Oral Pathol 1971; 32: 569–581.
5. Gold L. Biologic behaviour of ameloblastoma. Oral MaxillofacSurgClin North Am 1991; 3: 21–30.
6. Lee SK, Kim YS. Current concepts and occurrence of epithelial odontogenic tumors: I. Ameloblastoma and adenomatoid odontogenic tumor. Korean Journal of Pathology 2013; 47(3): 191–202.
7. Osterne RL, Alves AP, Cavalcante RB. Odontogenic Tumors: a 5-Year Retrospective Study in a Brazilian Population and Analysis of 3406 Cases Reported in the Literature. Oral surgery, oral medicine,

oral pathology, oral radiology, and endodontics 2011; 111: 474–481.

8. Barnes L, Eveson JW, Reichert P. World Health Organization classification of tumours. Pathology and genetics of head and neck tumours. Lyon: IARC Press, 2005.
9. Costa DO, Maurício AS, Faria PA, Silva LE, Mosqueda-Taylor A, Lourenço SQ. Odontogenic tumors: a retrospective study of four Brazilian diagnostic pathology centers. Med Oral Pathol Oral Cir Bucal 2012; 17: e389–e394.
10. Reichart PA, Philipsen HP, Sonner S. Ameloblastoma: biological profile of 3677 cases. Eur J Cancer 1995; 31B(2): 86–99.
11. Sherlin HJ, Natesan A, Ram P, Ramani P, Thiruvenkadam C. Immunohistochemical profiling of Ameloblastomas using cytokeratin, vimentin, smooth muscle actin, CD34 and S100. Annals of maxillofacial surgery 2013; 3(1): 51–57.
12. Mahadesh J, Rayapati DK, Maligi PM, Ramachandra P. Unicystic ameloblastoma with diverse mural proliferation - a hybrid lesion. Imaging science in dentistry 2011; 41(1): 29–33.
13. Koenig LS. Neoplasm, Benign, Odontogenic. In: Diagnostic Imaging: Oral and Maxillofaical (ed1). Manitoba: Amirsys, 2012: II-3-107.
14. Nakamura US, Mushimoto K, Shirasu R. A clinicopathologic study of ameloblastoma. J Oral MaxillofacSurg 1986; 44: 361-365.
15. Black CC, Addante RR, Mohila CA. Intraosseous ameloblastoma.

Oral surgery, oral medicine, oral pathology, oral radiology, and endodontics 2010; 110(5): 585–592.

16. Ricci M, Mangano F, Tonelli P, Barone A, Galletti C, Covani U. An unusual case of unicystic intramural ameloblastoma and review of the literature. Contemporary Clinical Dentistry 2012; 3(6): 233-239.
17. Sehdev MK, Huvos AG, Strong EW. Proceedings: Ameloblastoma of maxilla and mandible. Cancer 1974; 33: 324-333.
18. Gardner DG. A pathologist's approach to the treatment of ameloblastoma. J Oral Maxillofac Surg 1984; 42(3): 161–166.
19. Gardner DG. Some current concepts on the pathology of ameloblastomas. Oral Surg Oral Med Oral Pathol Oral Radiol Endod 1996; 82: 660-669.
20. Ueno S, Mushimoto K, Shirasu R. Prognostic evaluation of ameloblastoma based on histologic and radiographic typing. J Oral Maxillofac Surg 1989; 47(1): 11–15.
21. Otero D, Lourenço S, Ruiz-Ávila I, Bravo M, Sousa T, de Faria P, González-Moles MA. Expression of proliferative markers in ameloblastomas and malignant odontogenic tumors. Oral Diseases 2012; 19(4): 360–365.
22. Bologna-Molina R, Mosqueda-Taylor A, Molina-Frechero N, Mori-Estevez A-D, Sánchez-Acuña G. Comparison of the value of PCNA and Ki-67 as markers of cell proliferation in ameloblastic tumors. Medicina oral, patología oral y cirugíabucal 2013; 18(2): e174–9.

23. Li Y, Han B, Li LJ. Prognostic and proliferative evaluation of ameloblastoma based on radiographic boundary. International journal of oral science 2012; 4(1): 30–33.
24. Ghandhi D, Ayoub AF, Pogrel MA, MacDonald G, Brocklebank LM, Moos KF. Ameloblastoma: A Surgeon's Dilemma. Journal of Oral and Maxillofacial Surgery 2006; 64(7): 1010–1014.

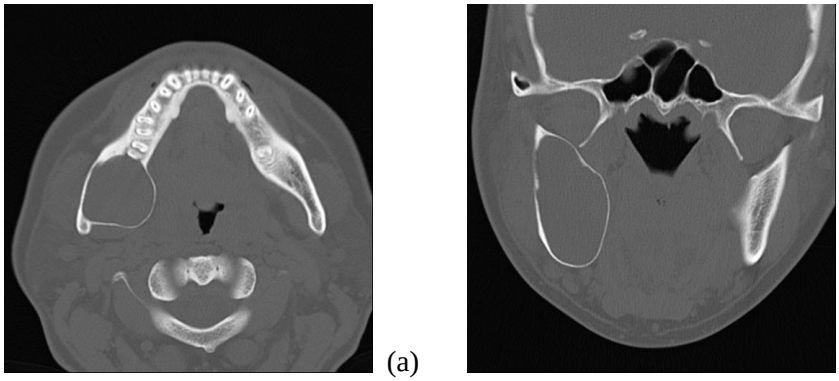

(a) (b)

Fig 1. An example of unilocular ameloblastoma on CT image.

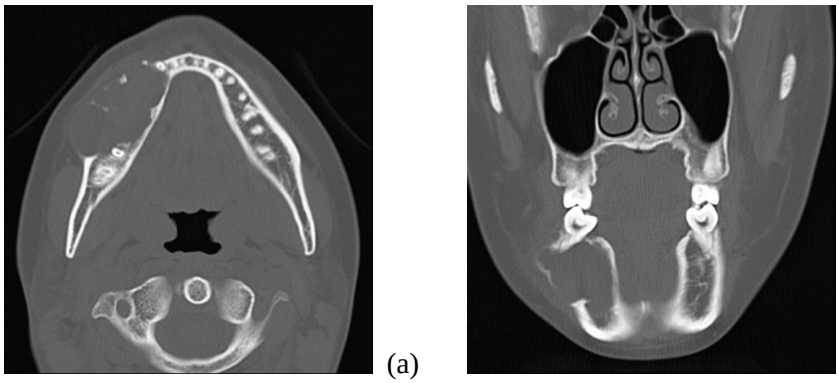

(a) (b)

Fig 2. An example of pseudo-multilocular ameloblastoma on CT image. Note the incomplete septa within the lesion.

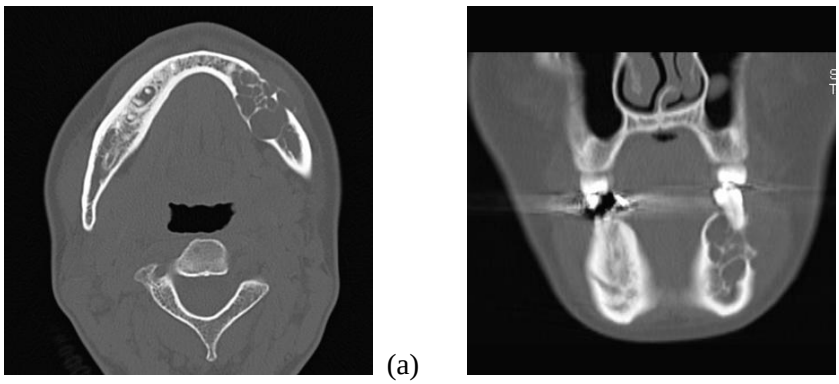

(a) (b)

Fig 3. An example of multilocular ameloblastoma on CT image.

Fig 4. Panoramic image of the same case in Fig 1, showing unilocular radiolucency.

Fig 5. Panoramic image of the same case in Fig 2, classified as pseudo-multilocular ameloblastoma on CT image, exhibiting multilocular radiolucency.

Fig 6. Panoramic image of the same case in Fig 3, classified as multilocular ameloblastoma on CT image, demonstrating multilocular radiolucency.

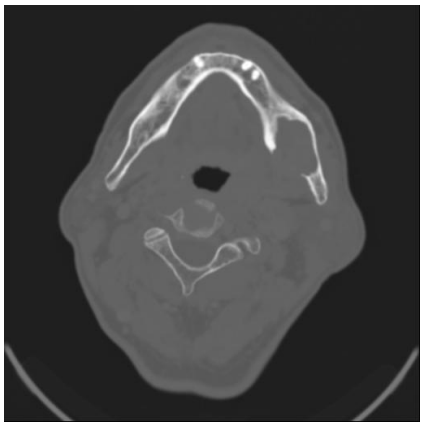

(a)

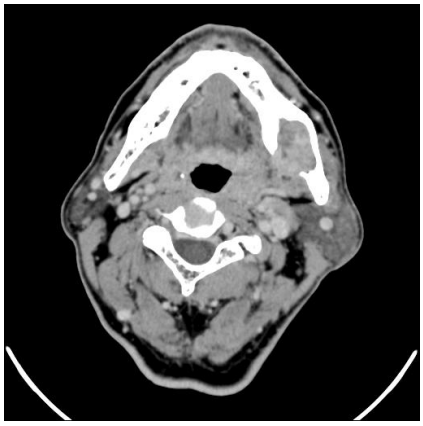

(b)

Fig 7. (a) CT image with bone window showing cortical perforation. (b) Contrast-enhanced CT image demonstrating solid tumor nodule occupying the perforation site.

Table 1. Comparison of panoramic and CT images

	Unilocular on CT	Pseudo-multilocular on CT	Multilocular on CT	Total
Unilocular on panoramic radiograph	62	9	4	75
Multilocular on panoramic radiograph	1	36	32	69
Total (%)	63 (43.7%)	45 (31.3%)	36 (25.0%)	144

Table 2. Prevalence of cortical perforation according to the radiographic groups on CT image

Radiographic group	Cortical perforation
Unilocular (n=63)	26 (41.3%)
Pseudo-multilocular (n=45)	28 (62.2%)
Multilocular (n=39)	30 (83.3%)

Chi-square: $p<0.05$ between each group

Table 3. Prevalence of root resorption according to the radiographic groups on CT image

Radiographic group	Root resorption
Unilocular (n=62)	45 (72.6%)
Pseudo-multilocular (n=44)	31 (70.5%)
Multilocular (n=32)	22 (68.8%)

Chi-square: $p>0.05$ between each group
Edentulous cases were excluded from the count.

국문 초록

CT영상을 이용한 법랑모세포종의 방사선학적 재분류 및 국소적 영향의 평가

조준범

서울대학교 대학원 치의과학과 구강악안면방사선학 전공

(지도교수: 허경회)

1. 목적

본 연구의 목적은 CT 영상을 이용하여 법랑모세포종을 3차원적으로 평가하여 중격 여부 및 완전성에 따라 병소를 재분류한 후 각 군, 병소의 크기 및 solid tumor nodule의 분포에 따라 피질골이나 치근과 같은 주변 구조물에 미치는 공격적 양상의 차이가 있는지 알아보는 것이다.

2. 방법

2003년부터 2013년까지 조직학적으로 진단된 법랑모세포종 144 증례의 CT와 파노라마 영상에 대한 후향적 조사를 시행하였다.

CT 영상을 이용하여 내부 중격의 완전성을 기준으로 병소를 단방성, 위다방성 그리고 다방성의 세 군으로 분류한 후, 각 병소의 파노라마 사진을 관찰하여 CT와 파노라마 영상의 방사선 소견을 비교하였다.

각 군의 빈도수를 계산하였고, 각 군의 피질골 소실 혹은 천공 그리고 치근 외흡수에 대한 영향에 대해서도 조사하였다. 병소의 부피와 병소의 locularity, 피질골 천공 및 치근 외흡수 사이의 상관관계를 분석하였다.

조영증강 CT가 있는 27증례에 대해서는 solid tumor nodule의 체적을 조사하여 전체 병소의 부피, 병소의 locularity, 피질골 천공 및 치근 외흡수와의 상관관계를 분석하였다. 또 solid tumor nodule의 위치와 피질골 천공 및 치근 외흡수와의 관련성을 조사하였다.

3. 결과

본 연구에서는 단방성 법랑모세포종이 가장 많이 발견되었다.

CT 영상을 통해 63개의 (43.7%) 단방성, 45개의 (31.3%) 위다방성 그리고 36개의 (25.0%) 다방성 법랑모세포종 증례를 분류할 수 있었다. 피질골 천공은 다방성 법랑모세포종 (83.3%) 에서 가장 많이 발견되었으며 위다방성 (62.2%), 단방성 (41.3%) 순

으로 감소하였다. 치근 외흡수는 단방성 법랑모세포종 (72.6%)에서 가장 많이 발견되었으며 위다방성 (70.5%), 다방성 (68.8%) 순으로 감소하였다.

전체 병소의 부피를 측정한 결과, 병소의 locularity, 피질골 천공, 그리고 치근 외흡수와 모두 통계학적으로 유의미한 상관관계가 관찰되지 않았다.

조영증강 CT 영상을 통해 병소내부에 다양한 양의 solid tumor nodule을 확인할 수 있었는데, 병소 크기가 클수록 nodule의 크기가 유의하게 커진 것을 확인할 수 있었다. 또 nodule은 치근 외흡수와는 별다른 연관성이 없었으나, solid tumor nodule에 인접한 부위에서 피질골 소실이 더 많이 관찰되었다.

4. 결론

병소의 locularity 혹은 solid nodule의 유무에 따라 주위 구조물에 미치는 영향이 다르므로 CT 영상을 통한 정확한 평가가 법랑모세포종의 치료방법 결정 및 환자 예후에 도움을 줄 수 있을 것이다.

주요어: 법랑모세포종, 컴퓨터단층촬영, 단방성, 다방성

학번: 2010-22012

Abstract

Radiographic Reclassification of Ameloblastoma and Evaluation of the Local Effects Using CT Images

Jun-Bum Cho, DDS.

Department of Oral and Maxillofacial Radiology,

Graduate School, Seoul National University

(Directed by Prof. Kyung-Hoe Huh, DDS, MSD, PhD)

1. Objective

The objectives of this research were to perform multi-planar evaluation of ameloblastoma using computerized tomography (CT) images, reclassify the lesions in terms of locularity, and investigate the differences in the local effects according to the locularity, volume of lesion, and distribution of solid tumor nodules.

2. Materials and Methods

CT and panoramic images of 144 patients that were histologically diagnosed as ameloblastoma from 2003 to 2013 were reviewed

retrospectively. The lesions were classified radiographically as unilocular, pseudo-multilocular, or multilocular group according to the presence and completeness of septum on CT images. Then, each respective panoramic image was examined, and the radiographic appearances on both images were compared. The prevalence of each group was calculated.

Incidence rates of local effects, such as cortical perforation and external root resorption, were calculated for each radiographic group. The volumes of lesions were also measured and then tested for correlation with locularity, cortical perforation, and external root resorption, respectively.

Twenty-seven cases with contrast-enhanced CT images were studied to verify any correlation between the volume of the solid tumor nodule and the total volume of the entire lesion, locularity, cortical perforation, and external root resorption. The relationship between the location of the solid tumor nodule and cortical perforation/root resorption was also investigated.

3. Results

Unilocular ameloblastoma was the most frequently encountered radiographic group in this study. Out of 144 ameloblastoma cases, sixty-three (43.7%), forty-five (31.3%), and thirty-six (25.0%) lesions were classified as unilocular, pseudo-multilocular, and multilocular ameloblastomas, respectively, under examination with CT images. Cortical perforation was found most commonly in multilocular ameloblastoma (83.3%), pseudo-multilocular ameloblastoma (62.2%), and unilocular

ameloblastoma (41.3%), in decreasing order of incidence rate. External root resorption was found most commonly in unilocular ameloblastoma (72.6%), pseudo-multilocular ameloblastoma (70.5%), and multilocular ameloblastoma (68.8%), in decreasing order of incidence rate.

Volumes of the lesions were also measured. The correlations between volume of lesion and locularity, cortical perforation, and root resorption were all tested to be statistically not significant ($P>0.05$).

Different amounts of solid tumor nodules were verified within the lesions on contrast-enhanced CT images. Correlation between the volume of lesion and solid tumor nodules was tested positive and statistically significant ($P<0.05$). These solid nodules were found in adjacent areas of cortical perforation rather than the areas of root resorption.

4. Conclusion

Different locularities, and distribution of solid nodules resulted in different effects on the surrounding structures. Therefore, examination with CT images is essential for the exact evaluation of ameloblastomas, proper treatment planning, and better prognosis of the patients.

Keywords: Ameloblastoma, CT, unilocular, multilocular

Student Number: 2010-22012

Radiographic Reclassification of Ameloblastoma and Evaluation of the Local Effects Using CT Images

Jun-Bum Cho, DDS

Department of Oral and Maxillofacial Radiology,

Graduate School, Seoul National University

(Directed by Prof. Kyung-Hoe Huh, DDS, MSD, PhD)

- Contents -

I. Introduction

Ameloblastoma is the most common benign odontogenic tumor, accounting for 1% of all tumors in the head and neck region and approximately 11% to 29% of all odontogenic tumors.[1-9] They are usually locally aggressive and destructive tumors with a strong tendency for recurrence.[10] Therefore, exact examination and diagnosis are essential for the correct choice of surgical method and subsequent optimal results.

Ameloblastomas can be classified histologically into (1) the 'conventional' solid or multicystic ameloblastoma, (2) the unicystic ameloblastoma, (3) the peripheral ameloblastoma, and (4) the desmoplastic ameloblastoma.[11-12] The conventional multicystic ameloblastoma is the most common, comprising 80~92% in one large series.[10,13] However, this method of classification has limits in the sense that the exact histological examination cannot be obtained preoperatively.

On the other hand, ameloblastomas can be classified radiographically as either unilocular or multilocular ameloblastoma, according to the presence of septum.[13] Generally, conventional multicystic ameloblastomas appear as multilocular or "soap-bubble" radiolucencies, and unicystic ameloblastomas appear as unilocular radiolucencies.[14] A panoramic radiograph is a good tool for radiographic examination of ameloblastoma since it demonstrates the entire extent of the lesion and its relationship with the surrounding structures.[15] However, the established previous classification of

ameloblastoma with these two-dimensional radiographs has been performed without consideration of the three-dimensional appearance of septum.

This limitation gives rise to a problem where a lesion with incomplete septum may appear as a multilocular lesion with septated compartments in panoramic radiographs, even though it is not originally multilocular.[16] As result, information on the prevalence of each group of ameloblastoma found in literature is considered inaccurate. Exact classification and evaluation of each group is needed.

We hypothesized that there would be a difference in behavior between these lesions with incomplete septa (so called “pseudo-multilocular” ameloblastoma) and those true multilocular ameloblastomas with complete internal septa. The objectives of this research were to perform multi-planar evaluation of ameloblastoma using computerized tomography (CT) images, reclassify the lesions in terms of locularity, and investigate the differences in the effects on surrounding structures according to locularity, volume of lesions, and distribution of solid tumor nodules.

II. Materials and Methods

A total of 221 ameloblastoma cases of the last 10 years retrieved from the files of Seoul National University Dental Hospital between 2003 and 2013 were studied retrospectively. The pathological diagnoses were confirmed with the hematoxylin-eosin slides by the Department of Oral Pathology. Seventy seven cases of recurrent and peripheral ameloblastomas were excluded from the study. This study was approved by Seoul National University Dental Hospital Institutional Review Board.

Panoramic and CT images of 144 patients were studied by an Oral and Maxillofacial radiologist with over 10 years of experience. The lesions were classified into three groups according to the presence and completeness of septum: unilocular ameloblastomas, lesions with no internal septum (Fig 1); pseudo-multilocular ameloblastomas, single locule with incomplete septum or septa and thus giving an illusion of multilocular spaces rather than representing truly septated compartments (Fig 2); multilocular ameloblastomas, lesions with complete septum (Fig 3). Then, the panoramic radiographs of each case were examined, and the lesions were classified in terms of locularity: either unilocular (Fig 4) or multilocular (Fig 5 and 6), since accurate evaluation of the internal septum was not available. The comparison of the radiographic appearances of the lesions on CT and panoramic images were performed. Then, the incidence rates of local effects, such as cortical perforation (abrupt discontinuity of cortical lining)

and external root resorption, were calculated and compared between the radiographic groups. Those cases where the lesions had occurred in edentulous areas were excluded from the calculation regarding external root resorption.

The volumes of the lesions were calculated by measuring the surface area of the lesion on each axial CT image using PACS viewer software (π-View STAR, Infinitt Co., Seoul, Korea) and multiplying the sum of the surface areas by the distance between each slide, which was 1~3 mm, depending on the settings.

Contrast-enhanced CT images were found in 27 cases. These cases were reviewed to verify the effects of the solid tumor nodules on the surrounding structures (Fig 7a and b). The volumes of the solid tumor nodules were calculated in the same method as mentioned above and tested for correlation with the volume of the entire lesion, locularity, cortical perforation, and root resorption, respectively. Then, the location of the solid tumor nodule was also investigated; the numbers of each of the cases where the nodules were found adjacent to the cortical perforation and those adjacent to the root resorption sites were counted.

Statistical analysis

Using the software of IBM SPSS Statistics 21.0 (SPSS, Chicago, IL, USA), comparison of local effects between the three groups was carried out by Chi-square test. Pearson correlation test was used to compare the

relationships between volume of lesion and locularity, cortical perforation, and external root resorption; relationships between volume of solid tumor nodule and volume of entire lesion, locularity, cortical perforation, and external root resorption were also compared. Significance was set at $P<0.05$.

III. Results

CT and panoramic images of 144 ameloblastoma cases were reviewed in this study. Under examination with CT images, 63 cases (43.7%) were classified as unilocular ameloblastomas; 45 cases (31.3%) were classified as pseudo-multilocular ameloblastomas; 36 cases (25.0%) were classified as multilocular ameloblastomas (Table 1).

On panoramic radiographs, 75 cases were classified as unilocular ameloblastomas, whereas 69 were classified as multilocular ameloblastomas (Table 1). The results revealed that CT and panoramic images showed 82.7% concurrence (62 out of 75 cases) regarding radiographic interpretation of unilocular ameloblastoma, 52.2% (36 out of 69 cases) for pseudo-multilocular ameloblastoma, and 46.4% (32 out of 69 cases) for multilocular ameloblastoma (Table 1).

Table 2 showed the effects of each group on surrounding cortical bones. It was found that 37 cases (58.7%) of the unilocular ameloblastoma group (n=63) showed cortical expansion without perforation. In pseudo-multilocular ameloblastoma group (n=45), 28 cases (62.2%) showed cortical perforation. In multilocular ameloblastoma group (n=36), 30 cases (83.3%) showed cortical perforation. The statistic difference was considered significant between the three groups ($P<0.05$).

Table 3 showed the number of cases where external resorption of roots was found. In unilocular ameloblastoma group (n=62), 45 cases (72.6%)

presented with resorption of adjacent tooth roots; 31 cases (70.5%) in pseudo-multilocular group (n=44); 22 cases (68.8%) in multilocular ameloblastoma group (n=32). The differences in the prevalence of root resorption between the three groups were not statistically significant (P>0.05).

The volumes of the 144 lesions ranged from 0.3 cm^3 to 184.3 cm^3. The mean was 22.6 cm^3. However, the correlation test results between volume of lesion and locularity, cortical perforation, and root resorption did not show statistical significance (P>0.05).

Contrast-enhanced CT images of 27 patients were reviewed. Six lesions were filled with fluid attenuation without solid tumor nodules and 21 cases presented with internal solid tumor nodules. The enhanced solid tumor nodules were found to have different volumes, ranging from 0.3 cm^3 to 77.2 cm^3, while the volume of the entire lesions ranged from 1.3 cm^3 to 84.4 cm^3. To test the correlation between the volumes of the solid tumor nodules and the entire lesions, the data was log transformed for better fits, and a positive and significant correlation was observed (r = 0.583). However, each of the correlations between the volume of solid tumor nodule and locularity, cortical perforation, and root resorption was not statistically significant (P>0.05).

Twenty out of 21 cases where solid tumor nodules were found presented cortical perforation. Solid tumor nodules were found in adjacent areas of cortical perforation in 15 cases out of these 20 cases (75%). Thirteen cases

presented with root resorption, and only 6 cases (46%) presented solid tumor nodules adjacent to the site of root resorption.

IV. Discussion

It is well recognized that multilocular ameloblastoma is the most common and prevalent form.[17-18] However, for some reason, unilocular radiolucency was the most frequently encountered radiographic appearance (43.7%) in the present study. On the other hand, true multilocular ameloblastomas accounted for only 25.0% of the lesions in this study. This is probably due to the fact that the precise internal morphology including the completeness of septum was not considered with much importance in the past, and all the ameloblastomas exhibiting multilocular radiolucencies, including true multilocular ameloblastomas and pseudo-multilocular ameloblastomas were classified as one group when examined with panoramic radiographs. However, the two types were classified as different groups in this study, which resulted in decreased rate of incidence for multilocular ameloblastoma. Even considering this fact, however, the large number of unilocular group was noteworthy.

It has been stated that unilocular ameloblastomas typically occur more often in younger patients than multilocular ameloblastomas.[19] There is always an on-going debate regarding the origin of unilocular ameloblastoma, but it could be hyphothesized that unilocular ameloblastoma develops into multilocular ameloblastoma in advanced stages. If so, early detection of lesion due to easy access to dental clinics, improvement of diagnostic tools, and high standard of living of patients

compared to previous days may be considered as possible reasons for the high rate of incidence of unilocular ameloblastoma in the present study.

However, if late detection of lesion was responsible for high incidence rate of multilocular ameloblastoma in the past, increased volume of lesion should have resulted in increased locularity. In the present study, however, no statistically significant correlation between volume of lesion and locularity was found.

The limitations of the present study lie in the fact that growth rate of lesion and time concept were not considered. Questions regarding the relationship between volume of lesion and growth rate still remain. Moreover, volume of lesion was neither correlated with cortical perforation or root resorption, which implies that other factors such as differences of behavior or growth rate are probably related with local effects rather than the size of lesion.

Our findings show that lesions found to be unilocular under CT examination are generally unilocular, as well, when examined with panoramic images. However, pseudo-multilocular and multilocular ameloblastomas were found to share similar radiographic appearances under panoramic examination. Thirty-six out of 45 pseudo-multilocular ameloblastomas (80.0%) and 32 out of 36 multilocular ameloblastomas (88.9%) exhibited multilocular radiolucency on panoramic images. The two groups were not distinguishable under panoramic examination. This, in turn, meant that only 46.4% of lesions exhibiting multilocular radiolucency on

panoramic radiographs were classified as true multilocular ameloblastomas when examined with CT images; 52.2% of the lesions were classified as pseudo-multilocular group.

Inaccurate classification of ameloblastomas carried out with panoramic radiographs may bring confusion to clinicians regarding the nature of lesions. We encourage examination and exact classification using CT images. Furthermore, these groups of ameloblastomas classified with CT images need to be re-classified according to the histological subtypes; local effects and biological behaviors, including aggressiveness and proliferative ability, of each radiographic group need to be studied.

According to the present study, the effects of each group on surrounding structures were different. Multilocular ameloblastoma group showed the highest prevalence of cortical perforation, whereas external root resorption was found most commonly in unilocular ameloblastoma group, although it was not statistically significant. This indicates that different factors are responsible for changes in the cortical bone and resorption of tooth roots. Further studies on these factors that characterize the behavior of lesions and the mechanisms that the lesions undergo for changes in the cortical bone and roots of teeth are necessary to fully understand the nature of ameloblastoma.

We hypothesized that the soft mass nodules found in the contrast-enhanced CT images could also aid us in understanding the nature of ameloblastoma regarding its local effects on the cortical bone and roots of

teeth. It may be questionable to give a conclusion without including the concept of time and growth rate of the expanding lesion at this point, but our results showed that the correlation between the volume of the solid tumor nodules and the volume of the entire lesion was positive and statistically significant, which indicates that the soft mass nodules grow in size as time passes. On the other hand, the volume of the solid tumor nodule was irrelevant to the locularity, cortical perforation, and resorption of root. The locations of these nodules are thought to be associated with cortical perforation, since most of the solid tumor nodules were found adjacent to the cortical perforation sites. However, the sample size used in the present study was small, and we think that further studies with comprehensive sample sizes are required.

There are several reports that reveal relationship between the biological behaviors, mainly proliferative ability and recurrence, and the histological type, such as multicystic, unicystic, peripheral and desmoplastic ameloblastoma.[10,18,20-22] However, histological classification of ameloblastoma has certain limitations in the sense that the exact histological types of lesions cannot be determined preoperatively. Biopsy can be carried out before surgery, but it brings additional injuries to patients. Moreover, a preoperative biopsy can only be representative for a small portion of the lesion, and there are chances that it will result in incorrect classification, especially when the lesions are embedded deeply in the bone.[23] The present study provides multi-planar radiographic information

based on CT images regarding the behavior of lesions that can be used during the process of diagnosis and treatment planning without additional injuries to patients.

Treatment modalities for ameloblastomas are many and controversial; they may be divided mainly into conservative and radical therapies.[24] Many authors agree that radical therapies are needed for lesions exhibiting multilocular radiolucencies in panoramic radiographs.[20] Classification of pseudo-multilocular ameloblastoma is important in the sense that it discourages the choice of radical surgery as a routine way for multilocular lesions just because of their two-dimensional radiographic appearance. Although additional studies regarding the proliferative ability and recurrence rate of the specific radiographic subtypes are needed, we think that our study provides new insights regarding classification and general knowledge of ameloblastomas.

V. Conclusion

We were able to reclassify ameloblastoma into three different radiographic groups using CT images. Most of the lesions classified as unilocular or multilocular radiographic group on CT images were also found to exhibit unilocular or multilocular radiolucencies, respectively, on panoramic images. However, most of the lesions in pseudo-multilocular group also exhibited multilocular radiolucencies on panoramic images. Pseudo-multilocular and multilocular groups were not distinguishable under panoramic examination.

Different locularities and distribution of solid nodules resulted in different effects on the surrounding structures. Therefore, examination with CT images is essential for the exact evaluation of ameloblastomas, proper treatment planning, and subsequent better prognosis of the patients.

VI. References

1. Sciubba JJ, Fantasia JA, Kahn LB. Benign odontogenic tumors. In: Atlas of tumor pathology-tumors and cysts of the jaw. Washington, DC: AFIP, 1999: 1-85.
2. Regezi JA, Sciubba J. Odontogenic tumors. In: Oral Pathology: Clinical Pathological Correlations (ed 2). Philadelphia: Saunders Elsevier, 1993: 363–371.
3. Cawson RA, Binnie WH, Spieght PM, Barrett AW, Wright JM. Ameloblastoma. In: Lucas's Pathology of Tumors of the Oral Tissues (ed 5). London: Churchill Livingstone, 1998: 25–44.
4. Eversole LR, Tomich CE, Cherrick HM. Histogenesis of odontogenic tumors. Oral Surg Oral Med Oral Pathol 1971; 32: 569–581.
5. Gold L. Biologic behaviour of ameloblastoma. Oral MaxillofacSurgClin North Am 1991; 3: 21–30.
6. Lee SK, Kim YS. Current concepts and occurrence of epithelial odontogenic tumors: I. Ameloblastoma and adenomatoid odontogenic tumor. Korean Journal of Pathology 2013; 47(3): 191–202.
7. Osterne RL, Alves AP, Cavalcante RB. Odontogenic Tumors: a 5-Year Retrospective Study in a Brazilian Population and Analysis of 3406 Cases Reported in the Literature. Oral surgery, oral medicine,

oral pathology, oral radiology, and endodontics 2011; 111: 474–481.

8. Barnes L, Eveson JW, Reichert P. World Health Organization classification of tumours. Pathology and genetics of head and neck tumours. Lyon: IARC Press, 2005.
9. Costa DO, Maurício AS, Faria PA, Silva LE, Mosqueda-Taylor A, Lourenço SQ. Odontogenic tumors: a retrospective study of four Brazilian diagnostic pathology centers. Med Oral Pathol Oral Cir Bucal 2012; 17: e389–e394.
10. Reichart PA, Philipsen HP, Sonner S. Ameloblastoma: biological profile of 3677 cases. Eur J Cancer 1995; 31B(2): 86–99.
11. Sherlin HJ, Natesan A, Ram P, Ramani P, Thiruvenkadam C. Immunohistochemical profiling of Ameloblastomas using cytokeratin, vimentin, smooth muscle actin, CD34 and S100. Annals of maxillofacial surgery 2013; 3(1): 51–57.
12. Mahadesh J, Rayapati DK, Maligi PM, Ramachandra P. Unicystic ameloblastoma with diverse mural proliferation - a hybrid lesion. Imaging science in dentistry 2011; 41(1): 29–33.
13. Koenig LS. Neoplasm, Benign, Odontogenic. In: Diagnostic Imaging: Oral and Maxillofaical (ed1). Manitoba: Amirsys, 2012: II-3-107.
14. Nakamura US, Mushimoto K, Shirasu R. A clinicopathologic study of ameloblastoma. J Oral MaxillofacSurg 1986; 44: 361-365.
15. Black CC, Addante RR, Mohila CA. Intraosseous ameloblastoma.

Oral surgery, oral medicine, oral pathology, oral radiology, and endodontics 2010; 110(5): 585–592.

16. Ricci M, Mangano F, Tonelli P, Barone A, Galletti C, Covani U. An unusual case of unicystic intramural ameloblastoma and review of the literature. Contemporary Clinical Dentistry 2012; 3(6): 233-239.
17. Sehdev MK, Huvos AG, Strong EW. Proceedings: Ameloblastoma of maxilla and mandible. Cancer 1974; 33: 324-333.
18. Gardner DG. A pathologist's approach to the treatment of ameloblastoma. J Oral Maxillofac Surg 1984; 42(3): 161–166.
19. Gardner DG. Some current concepts on the pathology of ameloblastomas. Oral Surg Oral Med Oral Pathol Oral Radiol Endod 1996; 82: 660-669.
20. Ueno S, Mushimoto K, Shirasu R. Prognostic evaluation of ameloblastoma based on histologic and radiographic typing. J Oral Maxillofac Surg 1989; 47(1): 11–15.
21. Otero D, Lourenço S, Ruiz-Ávila I, Bravo M, Sousa T, de Faria P, González-Moles MA. Expression of proliferative markers in ameloblastomas and malignant odontogenic tumors. Oral Diseases 2012; 19(4): 360–365.
22. Bologna-Molina R, Mosqueda-Taylor A, Molina-Frechero N, Mori-Estevez A-D, Sánchez-Acuña G. Comparison of the value of PCNA and Ki-67 as markers of cell proliferation in ameloblastic tumors. Medicina oral, patología oral y cirugíabucal 2013; 18(2): e174–9.

23. Li Y, Han B, Li LJ. Prognostic and proliferative evaluation of ameloblastoma based on radiographic boundary. International journal of oral science 2012; 4(1): 30–33.
24. Ghandhi D, Ayoub AF, Pogrel MA, MacDonald G, Brocklebank LM, Moos KF. Ameloblastoma: A Surgeon's Dilemma. Journal of Oral and Maxillofacial Surgery 2006; 64(7): 1010–1014.

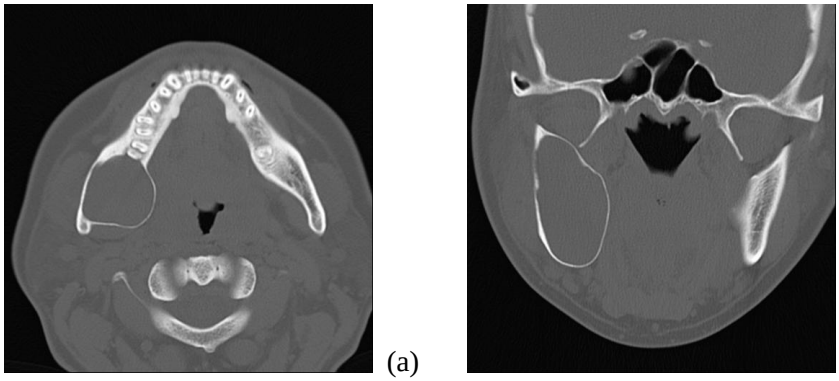

(a) (b)

Fig 1. An example of unilocular ameloblastoma on CT image.

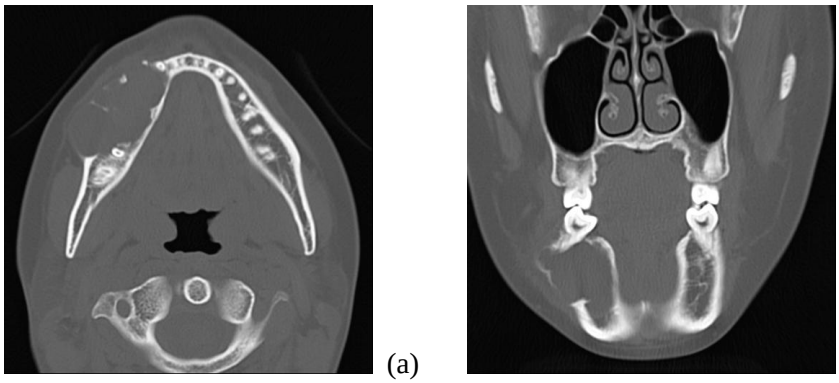

(a) (b)

Fig 2. An example of pseudo-multilocular ameloblastoma on CT image. Note the incomplete septa within the lesion.

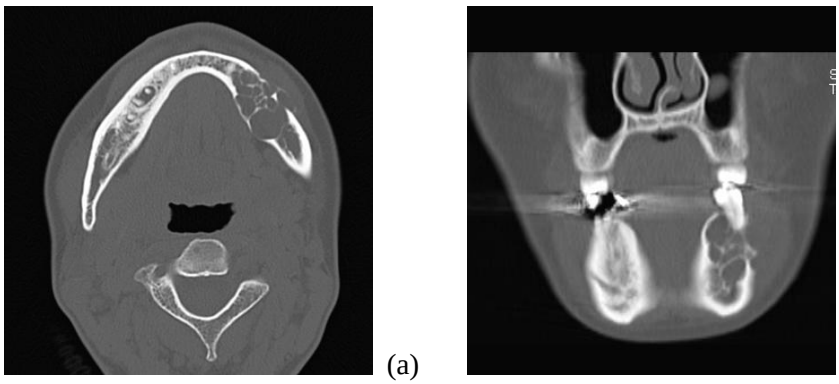

(a) (b)

Fig 3. An example of multilocular ameloblastoma on CT image.

Fig 4. Panoramic image of the same case in Fig 1, showing unilocular radiolucency.

Fig 5. Panoramic image of the same case in Fig 2, classified as pseudo-multilocular ameloblastoma on CT image, exhibiting multilocular radiolucency.

Fig 6. Panoramic image of the same case in Fig 3, classified as multilocular ameloblastoma on CT image, demonstrating multilocular radiolucency.

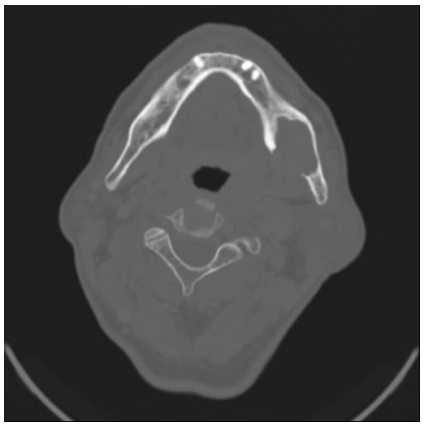

(a)

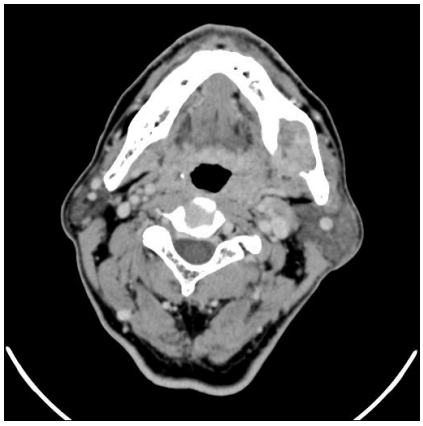

(b)

Fig 7. (a) CT image with bone window showing cortical perforation. (b) Contrast-enhanced CT image demonstrating solid tumor nodule occupying the perforation site.

Table 1. Comparison of panoramic and CT images

	Unilocular on CT	Pseudo-multilocular on CT	Multilocular on CT	Total
Unilocular on panoramic radiograph	62	9	4	75
Multilocular on panoramic radiograph	1	36	32	69
Total (%)	63 (43.7%)	45 (31.3%)	36 (25.0%)	144

Table 2. Prevalence of cortical perforation according to the radiographic groups on CT image

Radiographic group	Cortical perforation
Unilocular (n=63)	26 (41.3%)
Pseudo-multilocular (n=45)	28 (62.2%)
Multilocular (n=39)	30 (83.3%)

Chi-square: $p<0.05$ between each group

Table 3. Prevalence of root resorption according to the radiographic groups on CT image

Radiographic group	Root resorption
Unilocular (n=62)	45 (72.6%)
Pseudo-multilocular (n=44)	31 (70.5%)
Multilocular (n=32)	22 (68.8%)

Chi-square: $p>0.05$ between each group
Edentulous cases were excluded from the count.

국문 초록

CT영상을 이용한 법랑모세포종의 방사선학적 재분류 및 국소적 영향의 평가

조준범

서울대학교 대학원 치의과학과 구강악안면방사선학 전공

(지도교수: 허경회)

1. 목적

본 연구의 목적은 CT 영상을 이용하여 법랑모세포종을 3차원적으로 평가하여 중격 여부 및 완전성에 따라 병소를 재분류한 후 각 군, 병소의 크기 및 solid tumor nodule의 분포에 따라 피질골이나 치근과 같은 주변 구조물에 미치는 공격적 양상의 차이가 있는지 알아보는 것이다.

2. 방법

2003년부터 2013년까지 조직학적으로 진단된 법랑모세포종 144 증례의 CT와 파노라마 영상에 대한 후향적 조사를 시행하였다.

CT 영상을 이용하여 내부 중격의 완전성을 기준으로 병소를 단방성, 위다방성 그리고 다방성의 세 군으로 분류한 후, 각 병소의 파노라마 사진을 관찰하여 CT와 파노라마 영상의 방사선 소견을 비교하였다.

각 군의 빈도수를 계산하였고, 각 군의 피질골 소실 혹은 천공 그리고 치근 외흡수에 대한 영향에 대해서도 조사하였다. 병소의 부피와 병소의 locularity, 피질골 천공 및 치근 외흡수 사이의 상관관계를 분석하였다.

조영증강 CT가 있는 27증례에 대해서는 solid tumor nodule의 체적을 조사하여 전체 병소의 부피, 병소의 locularity, 피질골 천공 및 치근 외흡수와의 상관관계를 분석하였다. 또 solid tumor nodule의 위치와 피질골 천공 및 치근 외흡수와의 관련성을 조사하였다.

3. 결과

본 연구에서는 단방성 법랑모세포종이 가장 많이 발견되었다.

CT 영상을 통해 63개의 (43.7%) 단방성, 45개의 (31.3%) 위다방성 그리고 36개의 (25.0%) 다방성 법랑모세포종 증례를 분류할 수 있었다. 피질골 천공은 다방성 법랑모세포종 (83.3%) 에서 가장 많이 발견되었으며 위다방성 (62.2%), 단방성 (41.3%) 순

으로 감소하였다. 치근 외흡수는 단방성 법랑모세포종 (72.6%)에서 가장 많이 발견되었으며 위다방성 (70.5%), 다방성 (68.8%) 순으로 감소하였다.

전체 병소의 부피를 측정한 결과, 병소의 locularity, 피질골 천공, 그리고 치근 외흡수와 모두 통계학적으로 유의미한 상관관계가 관찰되지 않았다.

조영증강 CT 영상을 통해 병소내부에 다양한 양의 solid tumor nodule을 확인할 수 있었는데, 병소 크기가 클수록 nodule의 크기가 유의하게 커진 것을 확인할 수 있었다. 또 nodule은 치근 외흡수와는 별다른 연관성이 없었으나, solid tumor nodule에 인접한 부위에서 피질골 소실이 더 많이 관찰되었다.

4. 결론

병소의 locularity 혹은 solid nodule의 유무에 따라 주위 구조물에 미치는 영향이 다르므로 CT 영상을 통한 정확한 평가가 법랑모세포종의 치료방법 결정 및 환자 예후에 도움을 줄 수 있을 것이다.

주요어: 법랑모세포종, 컴퓨터단층촬영, 단방성, 다방성

학번: 2010-22012