의학석사 학위논문

한국형 원위 요골 해부학적 수장 금속판 시스템에 대한 초기 결과 보고

2014년 2월

서울대학교 대학원

의학과 정형외과학 전공

김 정 환

The Preliminary Report on Korean-type Distal Radius Anatomical Volar Plate System

February, 2014

Seoul National University

College of Medicine

Orthopedic Surgery

Jeong Hwan Kim

한국형 원위 요골 해부학적 수장 금속판 시스템에 대한 초기 결과 보고

지도교수 **백 구 현**

이 논문을 의학석사 학위논문으로 제출함.

2013년 10월

서울대학교 대학원

의학과 정형외과학 전공

김 정 환

김정환의 의학석사 학위논문을 인준함.

2014년 1월

위 원 장 _____(인)

부위원장 _____(인)

위　　원 _____(인)

The Preliminary Report on Korean-type Distal Radius Anatomical Volar Plate System

by

Jeong Hwan Kim, M.D.

A thesis submitted to the Department of Medicine in partial fulfillment of the requirements for the Degree of Master of Science in Medicine (Orthopedic Surgery) at the Seoul National University College of Medicine

January, 2014

Approved by Thesis Committee

Professor _____Chairman

Professor _____Vice chairman

Professor _____

Abstract

Introduction: Distal radius fracture is the most common fracture of the upper extremity, and approximately 60,000 distal radius fractures occur annually in Korea. Internal fixation with an anatomical volar locking plate is widely used in the treatment of unstable distal radius fractures. However, most of the currently used distal radius anatomical plate systems were designed based on the anatomical characteristics of Western populations. Recently, the Korean-type distal radius anatomical volar plate (K-DRAVP) system was designed and developed based on the anatomical characteristics of the distal radius of Koreans. The purpose of this study was to evaluate the preliminary results of the new K-DRAVP system, and to compare the radiologic and functional results with those of other systems.

Methods: From March 2012 to October 2012, 46 patients with acute distal radius fractures who were treated with the K-DRAVP system at 3 hospitals were enrolled in this study. Standard posteroanterior and lateral radiographs were obtained to assess fracture healing, and three radiologic parameters (volar tilt, radial inclination, and radial length) were assessed to evaluate radiologic outcomes. The range of motion and grip strength, the Gartland and Werley scoring system, and the Disabilities of the Arm, Shoulder and Hand (DASH) questionnaire were used to assess clinical and functional outcomes.

Results: Bony union was achieved in all fractures with a mean time of 42 days. All

radiologic parameters were restored to normal ranges, and maintained without any loosening or collapse by the time of final follow-up. Grip strength was restored to 84% of the value of the unaffected side. The mean range of motion of the wrist at final follow-up was 56.2° extension, 51.3° flexion, 15.6° radial deviation, 25.9° ulnar deviation, 81.0° pronation, and 79.6° supination (77–95% of the value of the unaffected side). According to the Gartland and Werley scoring system, there were 16 excellent, 26 good, and 4 fair results. The mean DASH score was 8.4 points. There were no complications after surgery.

Conclusion: The newly developed K-DRAVP system could be used to restore and maintain good anatomical parameters, and provide good clinical outcomes with low complication rates. This system is a promising surgical option for the treatment of distal radius fractures in the Korean population.

Key Words: Radius, distal radius fractures, volar locking plate, anatomical plate

Student number*: *2012-21682

Contents

List of Table

List of Figures

Introduction

Distal radius fracture is the most common fracture in the upper extremity, with an annual incidence of 2 to 4 per 1000 persons.[1] The annual incidence of these fractures is increasing in the elderly population because of increased life expectancy, and in young population owing to sports activities. Approximately 60,000 distal radius fractures occur annually in Korea, and the residual lifetime risk is about 21.7% for women aged 50 years old.[2]

Variable treatment options are available for distal radius fractures. Stable distal radius fractures can be successfully treated by splinting or casting. However, some cases of unstable distal radius fractures and displaced intra-articular fractures require surgical treatment. Surgical options include percutaneous pinning, internal fixation, and external fixation. Among these methods, internal fixation using a volar locking plating system is most common.[3,4] At present, a volar locking plate is generally used for treating unstable distal radius fractures because of the advantages and the advancements presented with plate fixation systems.

Various types of distal radius anatomical plates have been developed and are in widespread use. However, these anatomical plates have been designed in Western countries, based on the anatomical characteristics of Western populations. Koreans have different anatomical features from those of the

Western populations, such as a relatively small and short radius, especially in elderly women. And the angle of the volar cortex is comparatively more acute than that of the Western populations.[5] Therefore, the conventional anatomical plate systems specific for the Western populations do not always anatomically fit Korean patients. In some patients, although the smallest conventional anatomical plate system was chosen, the plate size was too large for small elderly Korean women. In some patients, the pre-contoured plates do not appropriately contact the volar cortex. These mismatches of the anatomically pre-contoured plate system may cause complications such as failure to achieve anatomic reduction, failure of firm contact between the plate and the cortex, and tendon or nerve irritation.[6] Thus, the Korean type of anatomical volar plate system was required to solve these problems. The Korean-type distal radius anatomical volar plate (K-DRAVP) system was designed and developed based on the anatomical characteristics of distal radius of Koreans.[5]

The purpose of this study was to evaluate the preliminary results from the new K-DRAVP system, and to compare the radiologic and functional results with those of other systems.

Materials and Methods

Materials

From March 2012 to October 2012, 46 patients with acute distal radius fractures who were treated with the K-DRAVP system at 3 hospitals (Seoul National University Hospital, Seoul National University Bundang Hospital, and Seoul National University Boramae Hospital) were enrolled in this study. Indications for surgical treatment of the distal radius fracture were as follows: (1) failure of initial closed reduction or maintenance in a cast; (2) an intra-articular step-off of greater than 2 mm; and (3) the requirement for surgical treatment to allow for early movement. Exclusion criteria were as follows: (1) inability to attend follow-up examinations for more than 6 months; (2) treatment with other surgical options, such as pinning and other plate systems; (3) presence of additional injuries on the affected upper limb; and (4) refusal to enroll in this study.

The participants included 16 men and 30 women with a mean age of 62 years (range, 28 to 90) at the time of injury. The mean period from injury to surgery was 4.6 days (range, 1 to 12). The mean follow-up time was 10.1 months (range, 6 to 14). The left wrist was affected in 25 patients, and the right wrist, in 21 patients. The fractures affected the dominant hand in 27 patients (59%). The most common cause of fracture was a simple slip and fall

on an outstretched hand (39 patients, 85%). Other causes of fractures were a fall down from more than 2-meter height (3 patients, 7%), a traffic accident (2 patients, 7%), and an injury caused by twisting (1 patient, 2%). All fractures were categorized and classified according to the Association for Osteosynthesis / Association for the Study of Internal Fixation (AO/ASIF) classification. (Fig. 1) All fractures were closed fractures, and there were 11 patients with an A2, 9 with an A3, 7 with a C1, 4 with a C2, and 15 of a C3 classification. Three patients had other injuries in addition to the distal radius fracture: one had a traumatic intracranial hemorrhage with facial bone fractures; one had a femoral intertrochanteric fracture; and one had a liver laceration with rib and facial bone fractures.

Surgical technique

Under general or regional anesthesia, a volar approach with an 8 cm zigzag skin incision along the radial side of the flexor carpi radialis (FCR) tendon was used. After splitting the forearm fascia, the FCR tendon, flexor tendons, and median nerve were retracted to the ulnar side, and the pronator quadratus muscle was detached from the radius. Reduction was performed under direct vision and confirmed with an image intensifier, and the bone was fixed temporarily with Kirschner wires. Then, the plate was inserted and fixed using a 2.7-mm cortical screw in the gliding hole. Correct positioning was

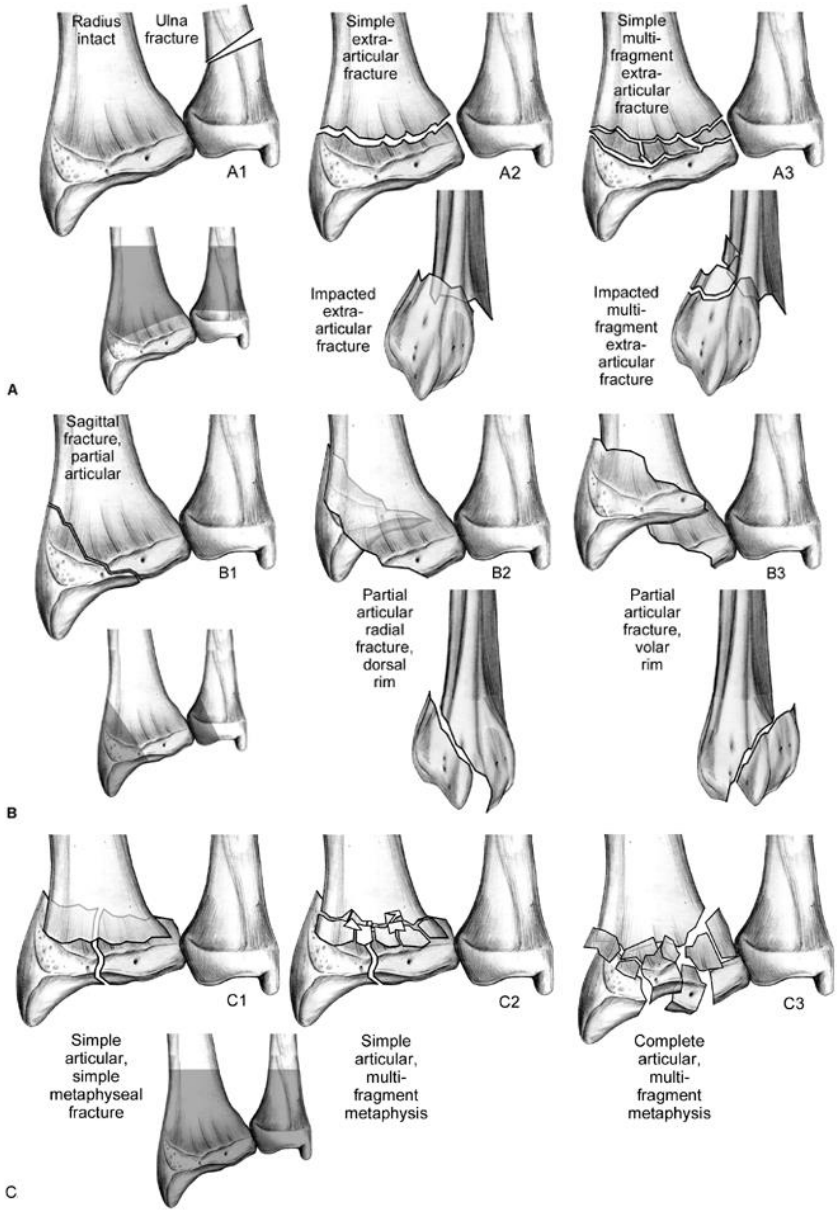

Figure 1. AO/ASIF classification of distal radius fractures. (From Berger RA, Weiss APC: Hand Surgery. Philadelphia, Lippincort Williams and Wilkins, 2003)

verified using an image intensifier. The distal portion of the plate was fixed to the radius using 2.4-mm locking screws, and proximal portion was fixed using 2.7-mm locking screws. After placement of the plate, the detached pronator quadratus muscle was re-attached with absorbable sutures. After wound closure, compressive dressings and a splint were applied. Postoperatively, the wrist was immobilized for 6 weeks with 3-week application of a long-arm cast and 3-week application of a short-arm cast. Range-of-motion exercises for the wrist were started 6 weeks after surgery.

Plate system

The K-DRAVP system (BK Meditech, Hwasung, Korea) was developed by the department of orthopedic surgery of Seoul National University Hospital, and is patented in Korea. (Patent No. 10-0784362) This system is fabricated from titanium alloy (Ti-6Al-4V ELI) that conforms to the standards of the American Society for Testing and Materials (ASTM) F136. This system has some advantages over other plate systems. First, this low-profile plate system is pre-contoured to provide the best position on the radius based on the anatomic characteristics of Koreans.[5)] Second, the distal edge of the plate is specially contoured to follow the watershed line. Third, the plate has a specially contoured thin and narrow end at the distal margin to minimize tendon or nerve irritations. The plate is of a single size and is available for the

right and left wrists. The distal portion of the plate has threaded locking holes that can accept 2 locking and non-locking 2.4-mm screws. In addition, the plate system has a dynamic compression hole for 2.7-mm cortical screws at the shaft of the plate, and 3 threaded locking holes for locking and non-locking 2.7-mm screws (Fig. 2).

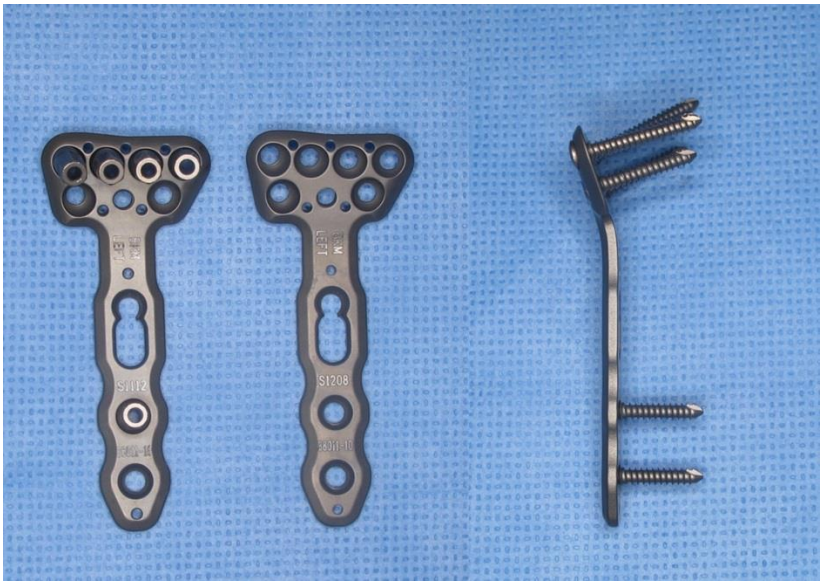

Figure 2. Korean-type distal radius anatomical volar plate (K-DRAVP) system.

Radiologic examination and clinical evaluation

All patients were assessed every other week until union was achieved. After fracture union, the patients were assessed at 3 months, 6 months, and 1 year after surgery. Standard posteroanterior and lateral radiographs of the wrist were obtained to assess fracture healing. Three radiologic parameters volar tilt,

radial inclination, and radial length) were measured: before surgery, immediate after surgery, and at the final follow-up evaluation. The intra-observer reliability was evaluated by repeating all radiologic assessments after 2 weeks, and was tested using interclass correlation coefficients (ICCs). ICC value of the intra-observer reliability of radiologic assessment was 0.922 (95% confidence interval).

The range of motion on the affected wrist and the contralateral side was measured using a goniometer. Grip strength was measured using a Jamar dynamometer (Asimow Engineering, Los Angeles, CA) with the elbow flexed at 90° and the forearm in the neutral position. The Disabilities of the Arm, Shoulder and Hand (DASH) questionnaire was used to assess functional outcomes in daily living. Final clinical and functional outcomes were assessed and graded using the scoring system of Gartland and Werley[7)] modified by Sarmiento et al.[8)] (Table 1)

Statistical analysis

The paired t-test was used to compare each radiographic parameter. P values of < 0.05 were considered statistically significant. The intra-observer reliability of radiologic assessments was tested using ICCs. An ICC value of > 0.8 was considered as excellent reliability. Statistical analyses were performed using SPSS version 20.0 (SPSS Inc., Chicago, IL).

	Points
Residual deformity (range, 0 to 3 points)	
Prominent ulnar styloid	1
Residual dorsal tilt	2
Radial deviation of hand	2 or 3
Subjective evaluation (range, 0 to 6 points)	
Excellent - no pain, disability, or limitation of motion	0
Good - occasional pain slight limitation of motion, and no disability	2
Fair - occasional pain, some limitation of motion, feeling of weakness in wrist, no particular disability if careful, and activities slightly restricted	4
Poor - pain, limitation of motion, disability, and activities more or less markedly restricted	6
Objective evaluation* (range, 0 to 5 points)	
Loss of extension	5
Loss of ulnar deviation	3
Loss of supination	2
Loss of flexion	1
Loss of radial deviation	1
Loss of circumduction	1
Pain in distal radio-ulnar joint	1
Grip strength - 60% or less than on opposite side†	1
Loss of pronation†	2
Complications (range, 0 to 5 points)	
Arthritic change	
Minimum	1
Minimum with pain	3
Moderate	2
Moderate with pain	4
Severe	3
Severe with pain	5
Nerve complications (median)	1 to 3
Poor finger function due to cast	1 or 2

Final results (ranges of points)	
Excellent	0 to 2
Good	3 to 8
Fair	9 to 20
Poor	≥ 21

* The objective evaluation is based on the following ranges of motion as being the minimum for normal function: extension (45 °), flexion (30 °), radial deviation (15 °), ulnar deviation (15 °), pronation (50 °), and supination (50 °)

† Criteria added by Sarmiento et al.[8)]

Table 1. Gartland and Werley demerit point system.

Results

Radiologic outcomes

Bony union was achieved in all patients with a mean time for union of 42 days (range, 37 to 50) (Figs. 2 and 3). No patient required an autologous or artificial bone graft. The preoperative volar tilt was -8.0° ± 16.3° (range, -47.4° to 34.2°), the immediate postoperative volar tilt was 8.5° ± 2.8° (range 1.2° to 13.7°), and the final follow-up volar tilt was 8.4° ± 2.7° (range, 1.2° to 13.4°). The preoperative radial inclination was 16.3° ± 6.2° (range, 2.5° to 27.9°), the immediate postoperative radial inclination was 22.4° ± 2.3° (range 17.7° to 26.4°), and the final follow-up radial inclination was 22.2° ± 2.3° (range, 17.7° to 26.3°). Preoperative radial length was 8.3° ± 3.2° (range, 1.6° to 14.8°), the immediate postoperative radial length was 11.3° ± 1.6° (range, 8.7° to 14.2°), and the final follow-up radial length was 11.3° ± 1.6° (range, 8.7° to 14.2°). There was a significant difference in each parameter between the preoperative and immediate postoperative values ($p < 0.001$). However, there was no statistically significant difference between each parameter immediately postoperative and the final follow-up evaluation (Fig. 4).

Figure 3. Initial radiograph of C1 fracture in a 73-year-old woman.

Figure 4. Radiograph taken at postoperative 6 months. Anatomical reduction was restored and well maintained.

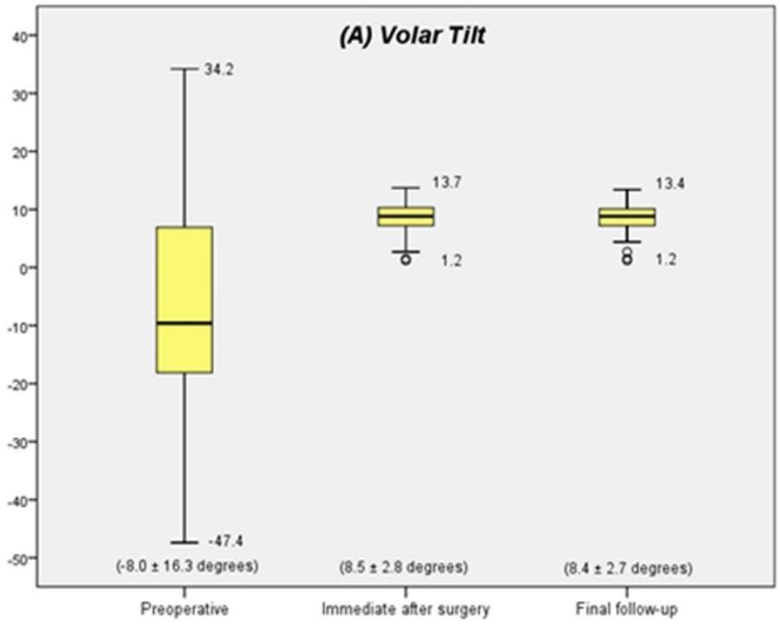
(A) Volar Tilt
40
30
20
10
0
-10
-20
-30
-40
-50
34.2
-47.4
13.7
1.2
13.4
1.2
(-8.0 ± 16.3 degrees)
(8.5 ± 2.8 degrees)
(8.4 ± 2.7 degrees)
Preoperative
Immediate after surgery
Final follow-up

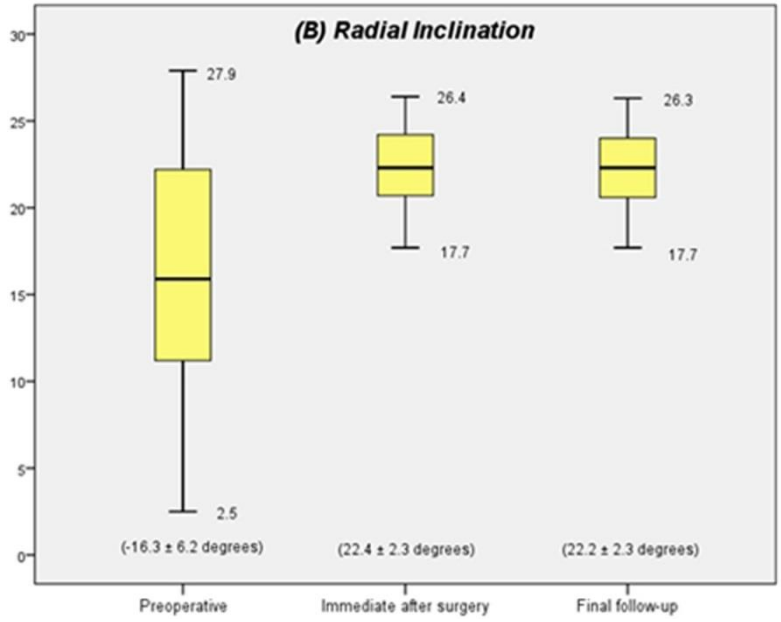
(B) Radial Inclination
30
25
20
15
10
5
0
27.9
2.5
26.4
17.7
26.3
17.7
(-16.3 ± 6.2 degrees)
(22.4 ± 2.3 degrees)
(22.2 ± 2.3 degrees)
Preoperative
Immediate after surgery
Final follow-up

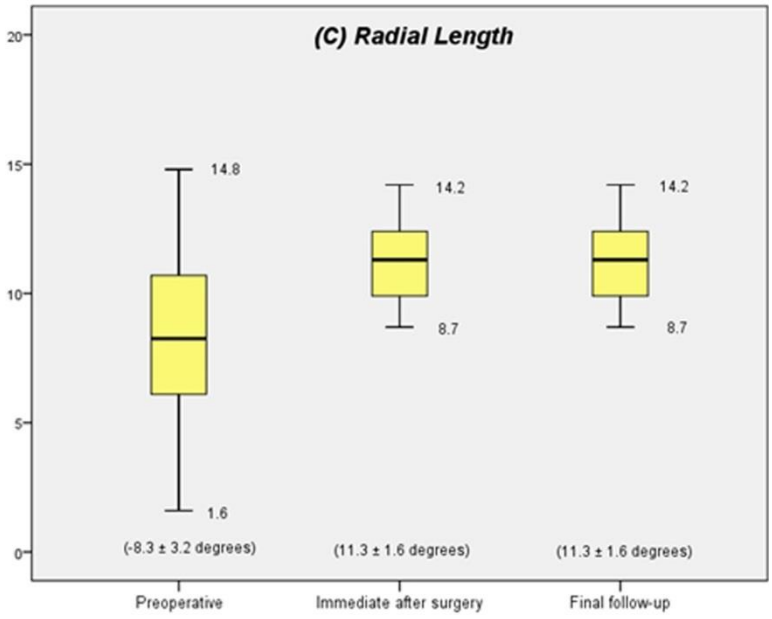

Figure 5. Changes of radiologic parameters.

(A) Volar tilt (B) Radial inclination (C) Radial length

Clinical outcomes

Grip strength was restored to 84% (range, 69 to 100) of the value of the unaffected side at the final follow-up evaluation. The mean values for range of motion of the wrist at the final follow-up were 56.2° ± 13.2° extension (range, 25° to 80°; 86% compared with the unaffected side), 51.3° ± 11.2° flexion (range, 25° to 75°; 77% compared with the unaffected side), 15.6° ± 4.3° radial deviation (range, 10° to 20°; 85% compared with the unaffected side), 25.9° ± 7.8° ulnar deviation (range, 15° to 35°; 87% compared with

the unaffected side), 81.0° ± 10.9° pronation (range, 65° to 85°; 95% compared with the unaffected side), and 79.6° ±11.7° supination (range, 60° to 90°; 87% compared with the unaffected side). According to the Gartland and Werley scoring system, there were 16 excellent, 26 good, and 4 fair results. The mean follow-up time for patients who showed excellent or good results was the same (10.4 months, range 7 to 14). The mean follow-up period for patients with fair results was relatively shorter compared with other patients with excellent or good results (7 months, range 6 to 8). The mean DASH score was 8.4 points (range, 0 to 20). The clinical outcomes results are shown in Table 2.

Varialbes	mean ±SD	range	restoration*
Range of motion			
Extension	56.2 ±13.2°	25 – 80°	86%
Flexion	51.3 ±11.2°	25 – 75°	77%
Radial deviation	15.6 ±4.3°	10 – 20°	85%
Ulnar deviation	25.9 ±7.8°	15 – 35 °	87%
Pronation	81.0 ±10.9°	25 – 80°	95%
Supination	79.6 ±11.7°	25 – 80°	87%
Grip power		69 – 100 %	84%
DASH score	8.4 points	0 – 20 points	

Gartland and Werley scoring system: excellent (16), good (26), fair (4)
* compared with the unaffected side

Table 2. Clinical outcomes.

Complications

One patient requested removal of the plate 10 months after surgery. There were no cases of infection, complex regional pain syndrome, tendon rupture, nerve irritation, or implant failure.

Discussion

In this study, the K-DRAVP system appropriately fit the anatomy of the distal radius of Korean patients. The system provided good maintenance of the anatomic alignment after reduction of the fracture, as observed radiologically, and most patients (91%) achieved excellent or good results according to the Gartland and Werley scoring system. There was no statistically significant deterioration in any of the radiologic parameters, such as volar tilt, radial inclination, and radial length. Grip strength and range of motion at the final follow-up were restored to approximately 85% of the values of the unaffected side. The mean DASH score (8.4 points) indicated little discomfort in daily living.

Volar plating with a locking screw system has the advantages of being an easy surgical procedure, having a relatively low risk of complications, and early functional mobilization. Several authors have reported good outcomes from various types of volar plates for distal radius fractures. Drobetz et al. reported the results from 50 patients treated with a locking plate system (Mathys®, Salzburg, Austria).[9] According to the Gartland and Werley scoring system, 26 patients had excellent results, 20 had good results, 3 had fair results, and 1 had a poor result after a mean follow-up of 26 months. Kamano et al. reported the results from 40 patients with distal radius fractures treated

with palmar plates (Biotechini Co., Ltd., Ciotat, France).[10] They reported 12 excellent and 28 good results after a mean follow-up of 12 months, according to the Gartland and Werley scoring system. Wong et al. reported the results of 35 patients with dorsally displaced distal radius fractures using the Stryker plating system with SmartLock locking screws after a mean follow-up of 10 months.[11] The mean Mayo clinic wrist score was 90 points, and 20 patients achieved an excellent result. Figl, et al. reported the results from 80 patients with unstable distal radius fractures treated using the APTUS plate (Medartis AG, Basel, Switzerland) with a mean follow-up of 7 months.[12] The mean DASH score was 25 points, and according to the Castaing score, 30 patients had perfect results, 49 had good results, and 1 had an adequate result. Minegishi et al. reported the results of 15 patients with unstable distal radius fractures treated using the Acu-Loc distal radius plate (Acumed, Oregon, USA) with a mean follow-up of 15.5 months.[13] In their study, according to Cooney's clinical scoring chart, 5 patients had excellent results, 7 had good results, and 3 had fair results. Lattmann et al. reported a relatively large series of 228 patients with distal radius fractures treated with LC-T plates (Synthes, Bettlach, Switzerland).[14] Grip strength was 91% of that on the contralateral side, and the assessed Patient-Rated Wrist Evaluation (PRWE) score was 8 points. Few studies have evaluated Asian-type distal radius volar plates. Osada et al. reported the results of 49 patients with distal radius fractures treated with a distal radius volar locking plate (DRV-LP [Mizuho Ikakogyo

Co., Ltd., Tokyo, Japan]).[15] After 1 year of follow-up, the mean DASH score was 6.1 points (range, 0 to 30) and all patients showed excellent or good results according to the Gartland and Werley scoring system. Yasuda et al. also reported good outcomes with a new variable angle distal screw locking volar plate system (Nakashima Propeller Co., Ltd., Okayama, Japan)[16].

Our radiologic and clinical results are similar to those of other studies using different types of distal radius volar plates (Table 3). Furthermore, in our study, there were no mechanical complications such as irritations of flexor tendons or the median nerve. Some studies have reported on mechanical irritations after volar plate fixation.[18-20] Kim et al. reported 2 cases of multiple flexor tendon ruptures after volar plate (LC-T plate; Synthes, Bettlach, Switzerland) fixation for distal radius fractures.[18] They reported that the prominent distal part of the volar plate could cause damage to the flexor tendons. Lee et al. reported 2 complications of mechanical irritations after volar plate (Acu-Loc System; Acumed, Oregon, USA) fixation for distal radius fractures.[19] Lee et al. reported mechanical irritation of the median nerve after volar plate fixation for distal radius fractures.[20] In this case, there were no mechanical complications because the K-DRAVP system was initially designed as a low-profile system with a specially contoured thin and narrow end of the distal margin in order to minimize these mechanical complications, such as tendon or nerve irritations.

This study has some limitations. First, this was not a randomized controlled

study, and we did not compare our results with patients who were treated with other types of distal radius plates. Therefore, we compared our data with those of previous reports. Further prospective randomized controlled studies are required. Second, we included a relatively short follow up period because our study was a preliminary report. Patients who had fair outcomes according to the Gartland and Werley scoring system had relatively shorter follow-up periods (7 months; range 6 to 8) than those of patients who had excellent or good outcomes (10.4 months; range 7 to 14). This finding suggests that outcomes are more favorable with a longer follow-up period. Third, K-DRAVP plate system had some problems. On the basis of our experience with the K-DRAVP system, we recommended some improvements in the plate. First, the drilling guides for the screws were small and separated, and management of these guides was difficult and time-consuming. Second, plates of variable sizes and lengths should be designed. One female patient could not be treated with the K-DRAVP system because the diameter of her radius was smaller than that of the plate. Third, another plate designed for juxta-articular distal radius fractures is needed for fixation of small distal juxta-articular fragments. After we reported our suggestions to the manufacturer, a revised version of the K-DRAVP system has been developed and is in use. Further reports on the results of the revised version of the plate will be published in due course.

Authors	Case number	Plate system	Mean follow- up period (months)	Results (used functional scoring system)
Drobetz el al. (2003)[9]	50	Mathys plate system (Salzburg, Austria)	26	Excellent (26), Good (20), Fair (3), Poor (1) (by Gartland and Werley score)
Kamano et al. (2005)[10]	40	Palmar plate (Biotechini Co., Ltd., Ciotat, France)	12	Excellent (12), Good (28) (by Gartland and Werley score)
Wong et al. (2009)[11]	35	SmartLock (Stryker, Kalamazoo, MI)	10	Excellent (20), Good (12), Fair (2), Poor (1) (by Mayo wrist score)
Figl et al. (2009)[12]	80	APTUS (Medartis AG, Basel, Switzerland)	7	DASH 25 points Perfect (30), Good (49), Adequate (1) (by Castaing score)
Minegishi et al. (2011)[13]	15	Acu-Loc (Acumed, Hillsboro, Oregon)	15.5	Excellent (5), Good (7), Fair (3) (by Cooney's Clinical scoring chart)
Matschke et al. (2011)[17]	117	3.5mm LCP-DR (Synthes, Bettlach, Switzerland)	24	DASH 11.2 points Excellent (59), Good (37), Fair/Poor (12) (by Gartland and Werley score)
Lattmann et al. (2011)[14]	228	LC-T plates (Synthes, Bettlach, Switzerland)	12	Grip strength 91% PRWE 8 points
Osada et al. (2008)[15]	49	DRV Locking Plate (Mizuho Ikakogyo Co., Ltd., Tokyo, Japan)	12	DASH 6.1 Excellent (47), Good (2) (by Gartland and Werley score)
Current Study	46	Korean type distal radius anatomical volar plate (BK Meditech, Hwasung, Korea)	10.1	DASH 8.4 Excellent (16), Good (26), Fair (4) (by Gartland and Werley score)

Table 3. Results of recent studies of volar locking plate systems

Conclusion

Although this study was only a preliminary report on the newly developed K-DRAVP system, we found that this plate system could be used to restore and maintain good anatomical parameters, and provide good clinical outcomes with low complication rates because it is the first anatomical distal radius volar plate based on the anatomical characteristics of Koreans. The K-DRAVP system is a promising surgical option for distal radius fractures for the Korean population.

References

1. Thompson PW, Taylor J, Dawson A. The annual incidence and seasonal variation of fractures of the distal radius in men and women over 25 years in Dorset, UK. Injury. 35(5):462-6, 2004.

2. Park C, Ha Y-C, Jang S, Jang S, Yoon H-K, Lee Y-K. The incidence and residual lifetime risk of osteoporosis-related fractures in Korea. J Bone Miner Metab. 29(6):744-51, 2011.

3. Orbay JL. The treatment of unstable distal radius fractures with volar fixation. Hand Surg. 5(02):103-12, 2000.

4. Chung KC, Shauver MJ, Birkmeyer JD. Trends in the United States in the treatment of distal radial fractures in the elderly. J Bone Joint Surg Am. 91(8):1868-73, 2009.

5. Lim ST, Yeom JS, Lee CH, Lee YH, Chang CB, Baek GH. Development of anatomical plating system for treatment of distal radius fractures. The Journal of the Korean Society for Surgery of the Hand. 12(3):95-104, 2007.

6. Arora R, Lutz M, Hennerbichler A, Krappinger D, Espen D, Gabl M. Complications following internal fixation of unstable distal radius

fracture with a palmar locking-plate. J Orthop Trauma. 21(5):316-322, 2007.

7. Gartland JJ, Werley CW. Evaluation of healed Colles' fractures. J Bone Joint Surg. 33(4):895-907, 1951.

8. Sarmiento A, Pratt GW, Berry NC, Sinclair WF. Colles' fractures: functional bracing in supination. J Bone Joint Surg. 57A:311-7, 1975.

9. Drobetz H, Kutscha-Lissberg E. Osteosynthesis of distal radial fractures with a volar locking screw plate system. Int Orthop. 27(1):1-6, 2003.

10. Kamano M, Koshimune M, Toyama M, Kazuki K. Palmar plating system for Colles' fractures - a preliminary report. J Hand Surg Am. 30(4):750-5, 2005.

11. Wong TC, Yeung CC, Chiu Y, Yeung SH, Ip FK. Palmar fixation of dorsally displaced distal radius fractures using locking plates with Smartlock locking screws. J Hand Surg Eu. 34(2):173-8, 2009.

12. Figl M, Weninger P, Liska M, Hofbauer M, Leixnering M. Volar fixed-angle plate osteosynthesis of unstable distal radius fractures: 12 months results. Arch Orthop Trauma Surg. 129(5):661-9, 2009.

13. Minegishi H, Dohi O, An S, Sato H. Treatment of unstable distal radius

fractures with the volar locking plate. Ups J Med Sci. 116(4):280-4, 2011.

14. Lattmann T, Meier C, Dietrich M, Forberger J, Platz A. Results of volar locking plate osteosynthesis for distal radial fractures. J Trauma. 70(6):1510-8, 2011.

15. Osada D, Kamei S, Masuzaki K, Takai M, Kameda M, Tamai K. Prospective study of distal radius fractures treated with a volar locking plate system. J Hand Surg Am. 33(5):691-700, 2008.

16. Yasuda M, Ando Y. A new variable angled locking volar plate system for Colles' fracture: Outcome study and time-course improvement of objective clinical variables. Hand Surg. 14(2 & 3):93-8, 2009.

17. Matschke S, Marent-Huber M, Audigé L, Wentzensen A. The surgical treatment of unstable distal radius fractures by angle stable implants: a multicenter prospective study. J Orthop Trauma. 25(5):312-7, 2011.

18. Kim JY, Kang HJ, Yi Y. Multiple flexor tendon injuries after volar plate fixation for distal radius fractures. J Korean Soc Surg Hand. 17(1):47-51, 2012.

19. Lee SJ, Bae JY, Cho HJ, Suh KT. Short term results of AO type C fractures of the distal radius treated with volar locking plate system. J Korean Soc Surg Hand. 16(4):191-197, 2011.

20. Lee SU, Park IJ, Kim HM, Lee JY, Yoo HH, Jeong C. K-wire fixation supplemented with external fixator versus volar locked plating for unstable fractures of the distal radius. J Korean Soc Surg Hand. 15(4):157-163, 2010.

국문 초록

서론: 원위 요골 골절은 상지에 발생하는 골절 중 가장 흔한 골절로, 한국에서만 1년에 60,000례 정도 발생한다. 이 중 불안정성 원위 요골 골절의 치료에 있어, 해부학적 수장 잠김 금속판을 이용한 내고정술이 흔히 사용되고 있다. 하지만 현재 사용되고 있는 해부학적 수장 잠김 금속판 대부분은 서양인의 해부학적 특성에 맞추어 개발된 제품들이었다. 최근, 한국인 원위 요골의 해부학적 특성을 바탕으로 한국형 원위 요골 해부학적 수장 금속판이 개발되어 사용되기 시작하였다. 본 연구는 한국형 원위 요골 해부학적 수장 금속판의 사용에 따른 초기 결과를 보고하고, 그 방사선학적 및 기능적 결과를 다른 금속판 시스템과 비교하여 보고자 한다.

방법: 2012년 3월부터 2012년 10월까지 서울대학교 병원, 분당 서울대학교 병원, 서울 보라매 병원에서 원위 요골 골절로 진단받은 후, 한국형 원위 요골 해부학적 수장 금속판을 이용한 수술적 치료를 받은 환자 46명을 대상으로 하였다. 모든 환자는 방사선학적으로 골유합 및 결과 평가를 위해 표준 후전면 및 측면

사진을 촬영하였고, 수술 전, 수술 후, 최종 추시 시 3회에 걸쳐 각각 방사선학적 지표인 수장 경사, 요골 경사, 요골 길이를 측정하였다. 임상적 및 기능적 결과를 위해서 손목 관절의 운동 범위, 파악력을 측정하였고, Gartland and Werley scoring system과 Disabilities of the Arm, Shoulder and Hand (DASH) 설문지를 사용하였다.

결 과: 모든 골절은 평균 42일에 골유합을 보였다. 수장 경사, 요골 경사, 요골 길이로 측정한 방사선학적 지표 모두 수술 후 정상 범위로 교정되었으며, 최종 추시 때까지 금속물의 이완이나 정복 소실 등은 관찰되지 않았다. 파악력은 최종 추시 때 정상측의 84%까지 회복되었다. 최종 추시 때 손목 관절의 평균 운동 범위는 신전 56.2°, 굴곡 51.3°, 요측 사위 15.6°, 척측 사위 25.9°, 회내전 81.0°, 회외전 79.6°였으며 정상측의 77-95% 범위로 회복되었다. Gartland and Werley scoring system에 따르면 16명은 매우 우수(excellent), 26명은 우수(good), 4명은 양호(fair)한 결과를 보였다. 평균 DASH 점수는 8.4 점이었으며, 수술 후 합병증은 관찰되지 않았다.

결 론: 새로이 개발된 한국형 원위 요골 해부학적 수장 금속판은 정상적 해부학적 지표들의 유지를 가능하게 하며, 낮은 합병증

발생율과 함께 좋은 임상적 결과를 보였다. 한국인의 해부학적 지표에 바탕을 둔 한국형 원위 요골 해부학적 수장 금속판은 한국인의 원위 요골 골절의 치료에 있어 좋은 치료법 중의 하나로 생각된다.

색인 단어: 요골, 원위 요골 골절, 수장 잠김 금속판, 해부학적 금속판

학 번: 2012-21682

의학석사 학위논문

한국형 원위 요골 해부학적 수장 금속판 시스템에 대한 초기 결과 보고

2014년 2월

서울대학교 대학원

의학과 정형외과학 전공

김 정 환

The Preliminary Report on Korean-type Distal Radius Anatomical Volar Plate System

February, 2014

Seoul National University

College of Medicine

Orthopedic Surgery

Jeong Hwan Kim

한국형 원위 요골 해부학적 수장 금속판 시스템에 대한 초기 결과 보고

지도교수 **백 구 현**

이 논문을 의학석사 학위논문으로 제출함.

2013년 10월

서울대학교 대학원

의학과 정형외과학 전공

김 정 환

김정환의 의학석사 학위논문을 인준함.

2014년 1월

위 원 장 _____(인)

부위원장 _____(인)

위　　원 _____(인)

The Preliminary Report on Korean-type Distal Radius Anatomical Volar Plate System

by

Jeong Hwan Kim, M.D.

A thesis submitted to the Department of Medicine in partial fulfillment of the requirements for the Degree of Master of Science in Medicine (Orthopedic Surgery) at the Seoul National University College of Medicine

January, 2014

Approved by Thesis Committee

Professor _____Chairman

Professor _____Vice chairman

Professor _____

Abstract

Introduction: Distal radius fracture is the most common fracture of the upper extremity, and approximately 60,000 distal radius fractures occur annually in Korea. Internal fixation with an anatomical volar locking plate is widely used in the treatment of unstable distal radius fractures. However, most of the currently used distal radius anatomical plate systems were designed based on the anatomical characteristics of Western populations. Recently, the Korean-type distal radius anatomical volar plate (K-DRAVP) system was designed and developed based on the anatomical characteristics of the distal radius of Koreans. The purpose of this study was to evaluate the preliminary results of the new K-DRAVP system, and to compare the radiologic and functional results with those of other systems.

Methods: From March 2012 to October 2012, 46 patients with acute distal radius fractures who were treated with the K-DRAVP system at 3 hospitals were enrolled in this study. Standard posteroanterior and lateral radiographs were obtained to assess fracture healing, and three radiologic parameters (volar tilt, radial inclination, and radial length) were assessed to evaluate radiologic outcomes. The range of motion and grip strength, the Gartland and Werley scoring system, and the Disabilities of the Arm, Shoulder and Hand (DASH) questionnaire were used to assess clinical and functional outcomes.

Results: Bony union was achieved in all fractures with a mean time of 42 days. All

radiologic parameters were restored to normal ranges, and maintained without any loosening or collapse by the time of final follow-up. Grip strength was restored to 84% of the value of the unaffected side. The mean range of motion of the wrist at final follow-up was 56.2° extension, 51.3° flexion, 15.6° radial deviation, 25.9° ulnar deviation, 81.0° pronation, and 79.6° supination (77–95% of the value of the unaffected side). According to the Gartland and Werley scoring system, there were 16 excellent, 26 good, and 4 fair results. The mean DASH score was 8.4 points. There were no complications after surgery.

Conclusion: The newly developed K-DRAVP system could be used to restore and maintain good anatomical parameters, and provide good clinical outcomes with low complication rates. This system is a promising surgical option for the treatment of distal radius fractures in the Korean population.

Key Words: Radius, distal radius fractures, volar locking plate, anatomical plate

Student number*: *2012-21682

Contents

List of Table

List of Figures

Introduction

Distal radius fracture is the most common fracture in the upper extremity, with an annual incidence of 2 to 4 per 1000 persons.[1] The annual incidence of these fractures is increasing in the elderly population because of increased life expectancy, and in young population owing to sports activities. Approximately 60,000 distal radius fractures occur annually in Korea, and the residual lifetime risk is about 21.7% for women aged 50 years old.[2]

Variable treatment options are available for distal radius fractures. Stable distal radius fractures can be successfully treated by splinting or casting. However, some cases of unstable distal radius fractures and displaced intra-articular fractures require surgical treatment. Surgical options include percutaneous pinning, internal fixation, and external fixation. Among these methods, internal fixation using a volar locking plating system is most common.[3,4] At present, a volar locking plate is generally used for treating unstable distal radius fractures because of the advantages and the advancements presented with plate fixation systems.

Various types of distal radius anatomical plates have been developed and are in widespread use. However, these anatomical plates have been designed in Western countries, based on the anatomical characteristics of Western populations. Koreans have different anatomical features from those of the

Western populations, such as a relatively small and short radius, especially in elderly women. And the angle of the volar cortex is comparatively more acute than that of the Western populations.[5] Therefore, the conventional anatomical plate systems specific for the Western populations do not always anatomically fit Korean patients. In some patients, although the smallest conventional anatomical plate system was chosen, the plate size was too large for small elderly Korean women. In some patients, the pre-contoured plates do not appropriately contact the volar cortex. These mismatches of the anatomically pre-contoured plate system may cause complications such as failure to achieve anatomic reduction, failure of firm contact between the plate and the cortex, and tendon or nerve irritation.[6] Thus, the Korean type of anatomical volar plate system was required to solve these problems. The Korean-type distal radius anatomical volar plate (K-DRAVP) system was designed and developed based on the anatomical characteristics of distal radius of Koreans.[5]

The purpose of this study was to evaluate the preliminary results from the new K-DRAVP system, and to compare the radiologic and functional results with those of other systems.

Materials and Methods

Materials

From March 2012 to October 2012, 46 patients with acute distal radius fractures who were treated with the K-DRAVP system at 3 hospitals (Seoul National University Hospital, Seoul National University Bundang Hospital, and Seoul National University Boramae Hospital) were enrolled in this study. Indications for surgical treatment of the distal radius fracture were as follows: (1) failure of initial closed reduction or maintenance in a cast; (2) an intra-articular step-off of greater than 2 mm; and (3) the requirement for surgical treatment to allow for early movement. Exclusion criteria were as follows: (1) inability to attend follow-up examinations for more than 6 months; (2) treatment with other surgical options, such as pinning and other plate systems; (3) presence of additional injuries on the affected upper limb; and (4) refusal to enroll in this study.

The participants included 16 men and 30 women with a mean age of 62 years (range, 28 to 90) at the time of injury. The mean period from injury to surgery was 4.6 days (range, 1 to 12). The mean follow-up time was 10.1 months (range, 6 to 14). The left wrist was affected in 25 patients, and the right wrist, in 21 patients. The fractures affected the dominant hand in 27 patients (59%). The most common cause of fracture was a simple slip and fall

on an outstretched hand (39 patients, 85%). Other causes of fractures were a fall down from more than 2-meter height (3 patients, 7%), a traffic accident (2 patients, 7%), and an injury caused by twisting (1 patient, 2%). All fractures were categorized and classified according to the Association for Osteosynthesis / Association for the Study of Internal Fixation (AO/ASIF) classification. (Fig. 1) All fractures were closed fractures, and there were 11 patients with an A2, 9 with an A3, 7 with a C1, 4 with a C2, and 15 of a C3 classification. Three patients had other injuries in addition to the distal radius fracture: one had a traumatic intracranial hemorrhage with facial bone fractures; one had a femoral intertrochanteric fracture; and one had a liver laceration with rib and facial bone fractures.

Surgical technique

Under general or regional anesthesia, a volar approach with an 8 cm zigzag skin incision along the radial side of the flexor carpi radialis (FCR) tendon was used. After splitting the forearm fascia, the FCR tendon, flexor tendons, and median nerve were retracted to the ulnar side, and the pronator quadratus muscle was detached from the radius. Reduction was performed under direct vision and confirmed with an image intensifier, and the bone was fixed temporarily with Kirschner wires. Then, the plate was inserted and fixed using a 2.7-mm cortical screw in the gliding hole. Correct positioning was

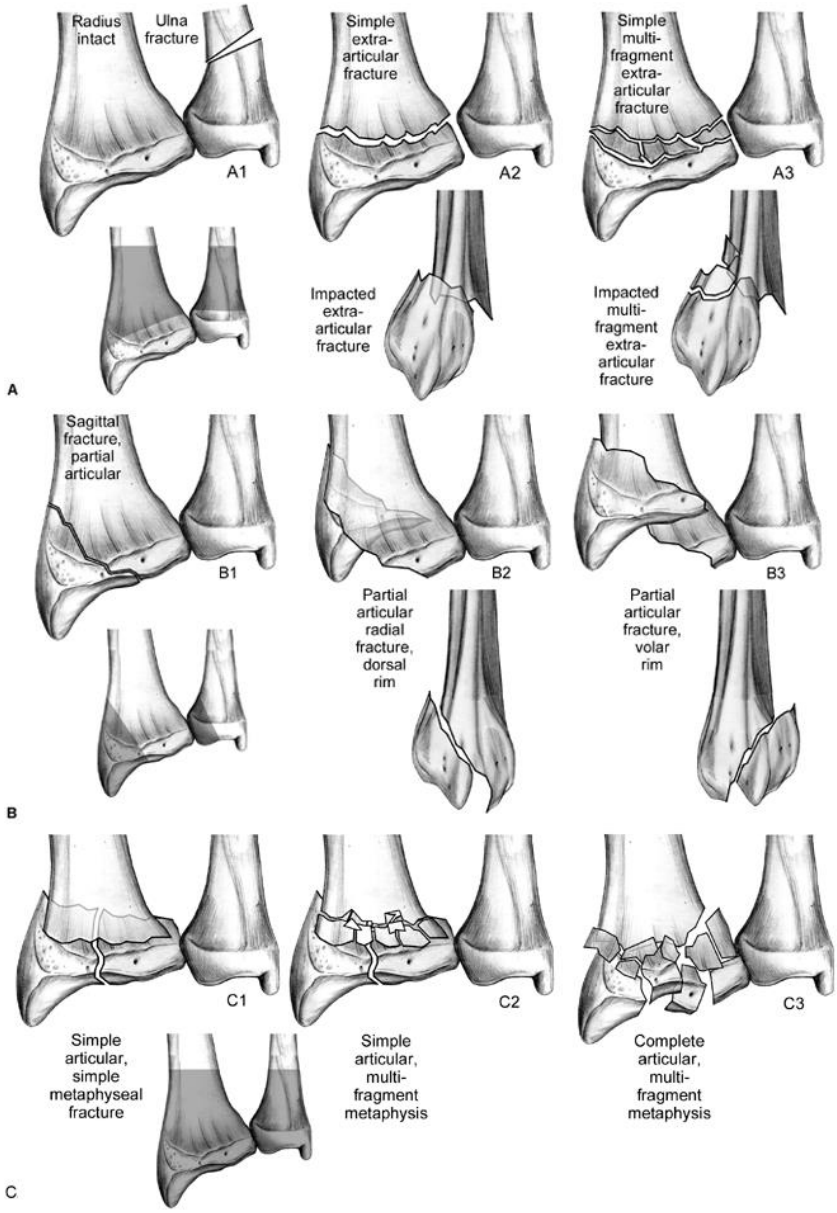

Figure 1. AO/ASIF classification of distal radius fractures. (From Berger RA, Weiss APC: Hand Surgery. Philadelphia, Lippincort Williams and Wilkins, 2003)

verified using an image intensifier. The distal portion of the plate was fixed to the radius using 2.4-mm locking screws, and proximal portion was fixed using 2.7-mm locking screws. After placement of the plate, the detached pronator quadratus muscle was re-attached with absorbable sutures. After wound closure, compressive dressings and a splint were applied. Postoperatively, the wrist was immobilized for 6 weeks with 3-week application of a long-arm cast and 3-week application of a short-arm cast. Range-of-motion exercises for the wrist were started 6 weeks after surgery.

Plate system

The K-DRAVP system (BK Meditech, Hwasung, Korea) was developed by the department of orthopedic surgery of Seoul National University Hospital, and is patented in Korea. (Patent No. 10-0784362) This system is fabricated from titanium alloy (Ti-6Al-4V ELI) that conforms to the standards of the American Society for Testing and Materials (ASTM) F136. This system has some advantages over other plate systems. First, this low-profile plate system is pre-contoured to provide the best position on the radius based on the anatomic characteristics of Koreans.[5)] Second, the distal edge of the plate is specially contoured to follow the watershed line. Third, the plate has a specially contoured thin and narrow end at the distal margin to minimize tendon or nerve irritations. The plate is of a single size and is available for the

right and left wrists. The distal portion of the plate has threaded locking holes that can accept 2 locking and non-locking 2.4-mm screws. In addition, the plate system has a dynamic compression hole for 2.7-mm cortical screws at the shaft of the plate, and 3 threaded locking holes for locking and non-locking 2.7-mm screws (Fig. 2).

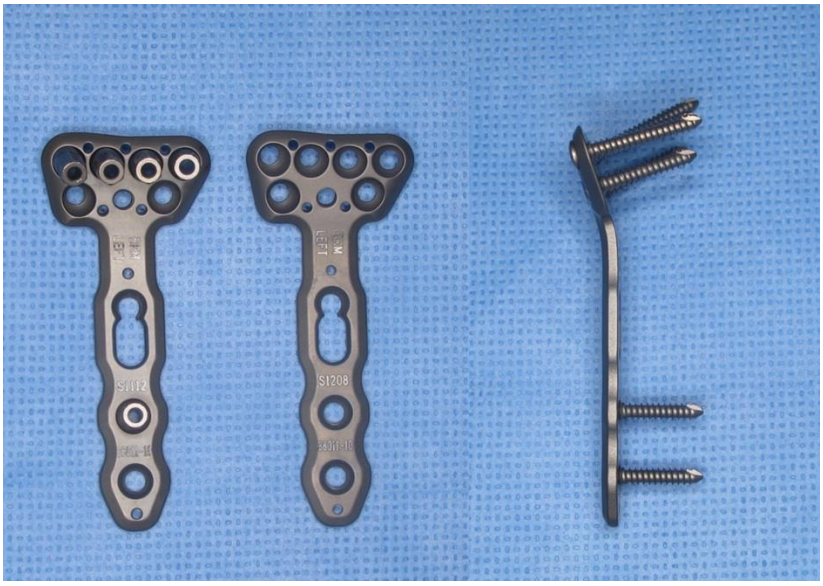

Figure 2. Korean-type distal radius anatomical volar plate (K-DRAVP) system.

Radiologic examination and clinical evaluation

All patients were assessed every other week until union was achieved. After fracture union, the patients were assessed at 3 months, 6 months, and 1 year after surgery. Standard posteroanterior and lateral radiographs of the wrist were obtained to assess fracture healing. Three radiologic parameters volar tilt,

radial inclination, and radial length) were measured: before surgery, immediate after surgery, and at the final follow-up evaluation. The intra-observer reliability was evaluated by repeating all radiologic assessments after 2 weeks, and was tested using interclass correlation coefficients (ICCs). ICC value of the intra-observer reliability of radiologic assessment was 0.922 (95% confidence interval).

The range of motion on the affected wrist and the contralateral side was measured using a goniometer. Grip strength was measured using a Jamar dynamometer (Asimow Engineering, Los Angeles, CA) with the elbow flexed at 90° and the forearm in the neutral position. The Disabilities of the Arm, Shoulder and Hand (DASH) questionnaire was used to assess functional outcomes in daily living. Final clinical and functional outcomes were assessed and graded using the scoring system of Gartland and Werley[7)] modified by Sarmiento et al.[8)] (Table 1)

Statistical analysis

The paired t-test was used to compare each radiographic parameter. P values of < 0.05 were considered statistically significant. The intra-observer reliability of radiologic assessments was tested using ICCs. An ICC value of > 0.8 was considered as excellent reliability. Statistical analyses were performed using SPSS version 20.0 (SPSS Inc., Chicago, IL).

	Points
Residual deformity (range, 0 to 3 points)	
Prominent ulnar styloid	1
Residual dorsal tilt	2
Radial deviation of hand	2 or 3
Subjective evaluation (range, 0 to 6 points)	
Excellent - no pain, disability, or limitation of motion	0
Good - occasional pain slight limitation of motion, and no disability	2
Fair - occasional pain, some limitation of motion, feeling of weakness in wrist, no particular disability if careful, and activities slightly restricted	4
Poor - pain, limitation of motion, disability, and activities more or less markedly restricted	6
Objective evaluation* (range, 0 to 5 points)	
Loss of extension	5
Loss of ulnar deviation	3
Loss of supination	2
Loss of flexion	1
Loss of radial deviation	1
Loss of circumduction	1
Pain in distal radio-ulnar joint	1
Grip strength - 60% or less than on opposite side†	1
Loss of pronation†	2
Complications (range, 0 to 5 points)	
Arthritic change	
Minimum	1
Minimum with pain	3
Moderate	2
Moderate with pain	4
Severe	3
Severe with pain	5
Nerve complications (median)	1 to 3
Poor finger function due to cast	1 or 2

Final results (ranges of points)	
Excellent	0 to 2
Good	3 to 8
Fair	9 to 20
Poor	≥ 21

* The objective evaluation is based on the following ranges of motion as being the minimum for normal function: extension (45 °), flexion (30 °), radial deviation (15 °), ulnar deviation (15 °), pronation (50 °), and supination (50 °)

† Criteria added by Sarmiento et al.[8)]

Table 1. Gartland and Werley demerit point system.

Results

Radiologic outcomes

Bony union was achieved in all patients with a mean time for union of 42 days (range, 37 to 50) (Figs. 2 and 3). No patient required an autologous or artificial bone graft. The preoperative volar tilt was -8.0° ± 16.3° (range, -47.4° to 34.2°), the immediate postoperative volar tilt was 8.5° ± 2.8° (range 1.2° to 13.7°), and the final follow-up volar tilt was 8.4° ± 2.7° (range, 1.2° to 13.4°). The preoperative radial inclination was 16.3° ± 6.2° (range, 2.5° to 27.9°), the immediate postoperative radial inclination was 22.4° ± 2.3° (range 17.7° to 26.4°), and the final follow-up radial inclination was 22.2° ± 2.3° (range, 17.7° to 26.3°). Preoperative radial length was 8.3° ± 3.2° (range, 1.6° to 14.8°), the immediate postoperative radial length was 11.3° ± 1.6° (range, 8.7° to 14.2°), and the final follow-up radial length was 11.3° ± 1.6° (range, 8.7° to 14.2°). There was a significant difference in each parameter between the preoperative and immediate postoperative values ($p < 0.001$). However, there was no statistically significant difference between each parameter immediately postoperative and the final follow-up evaluation (Fig. 4).

Figure 3. Initial radiograph of C1 fracture in a 73-year-old woman.

Figure 4. Radiograph taken at postoperative 6 months. Anatomical reduction was restored and well maintained.

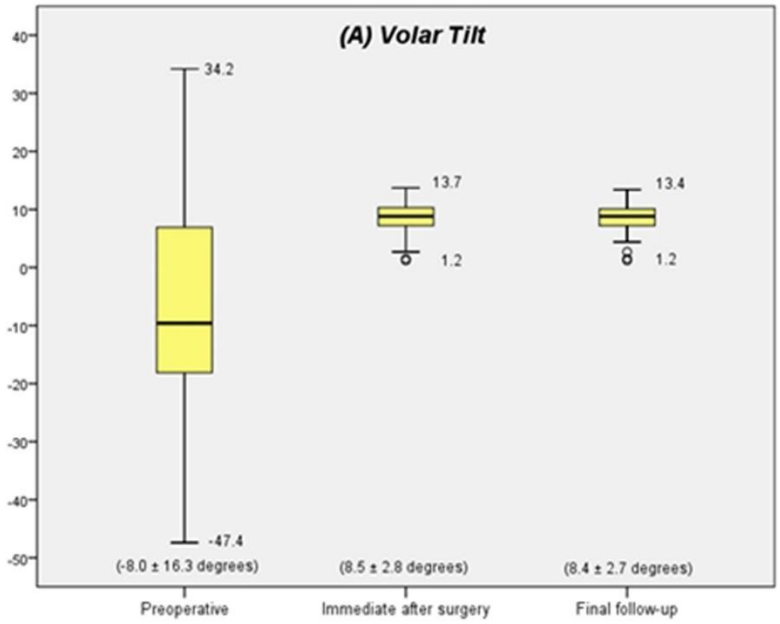
(A) Volar Tilt
40
30
20
10
0
-10
-20
-30
-40
-50
34.2
-47.4
13.7
1.2
13.4
1.2
(-8.0 ± 16.3 degrees)
(8.5 ± 2.8 degrees)
(8.4 ± 2.7 degrees)
Preoperative
Immediate after surgery
Final follow-up

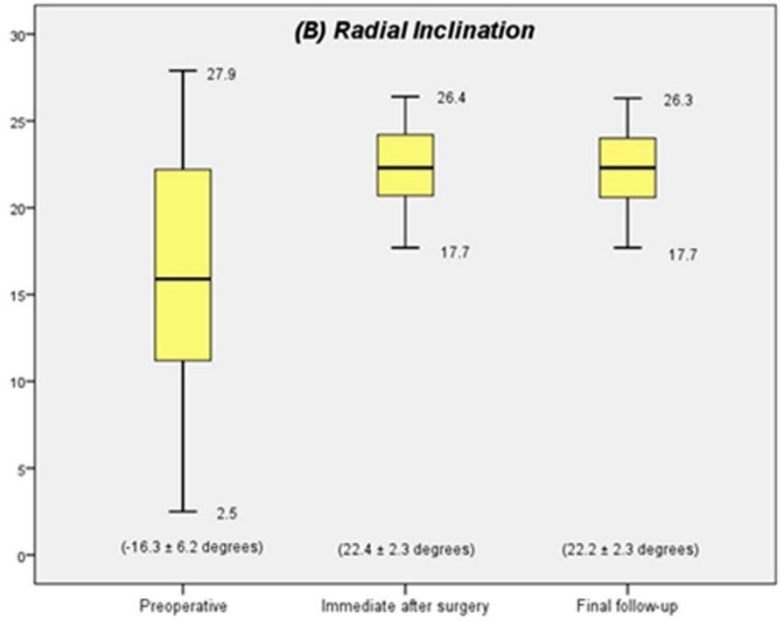
(B) Radial Inclination
30
25
20
15
10
5
0
27.9
2.5
26.4
17.7
26.3
17.7
(-16.3 ± 6.2 degrees)
(22.4 ± 2.3 degrees)
(22.2 ± 2.3 degrees)
Preoperative
Immediate after surgery
Final follow-up

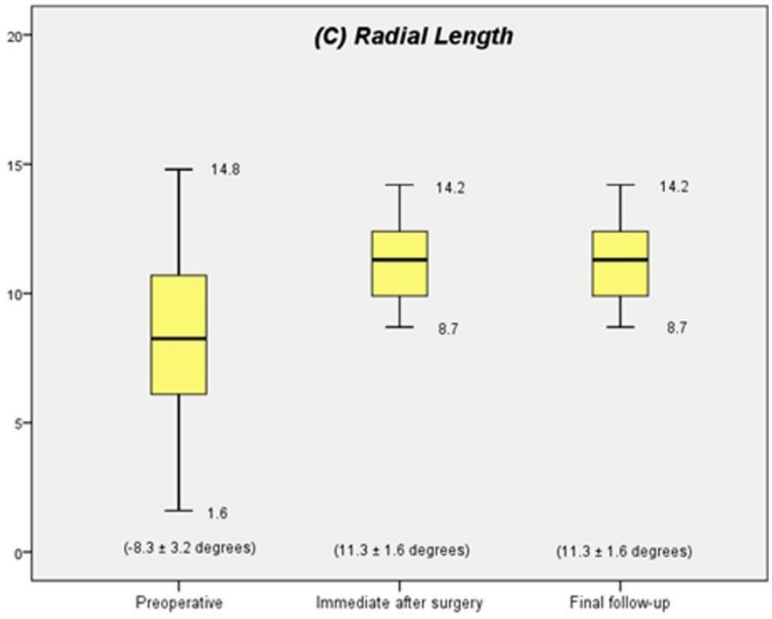

Figure 5. Changes of radiologic parameters.

(A) Volar tilt (B) Radial inclination (C) Radial length

Clinical outcomes

Grip strength was restored to 84% (range, 69 to 100) of the value of the unaffected side at the final follow-up evaluation. The mean values for range of motion of the wrist at the final follow-up were 56.2° ± 13.2° extension (range, 25° to 80°; 86% compared with the unaffected side), 51.3° ± 11.2° flexion (range, 25° to 75°; 77% compared with the unaffected side), 15.6° ± 4.3° radial deviation (range, 10° to 20°; 85% compared with the unaffected side), 25.9° ± 7.8° ulnar deviation (range, 15° to 35°; 87% compared with

the unaffected side), 81.0° ± 10.9° pronation (range, 65° to 85°; 95% compared with the unaffected side), and 79.6° ±11.7° supination (range, 60° to 90°; 87% compared with the unaffected side). According to the Gartland and Werley scoring system, there were 16 excellent, 26 good, and 4 fair results. The mean follow-up time for patients who showed excellent or good results was the same (10.4 months, range 7 to 14). The mean follow-up period for patients with fair results was relatively shorter compared with other patients with excellent or good results (7 months, range 6 to 8). The mean DASH score was 8.4 points (range, 0 to 20). The clinical outcomes results are shown in Table 2.

Varialbes	mean ±SD	range	restoration*
Range of motion			
Extension	56.2 ±13.2°	25 – 80°	86%
Flexion	51.3 ±11.2°	25 – 75°	77%
Radial deviation	15.6 ±4.3°	10 – 20°	85%
Ulnar deviation	25.9 ±7.8°	15 – 35 °	87%
Pronation	81.0 ±10.9°	25 – 80°	95%
Supination	79.6 ±11.7°	25 – 80°	87%
Grip power		69 – 100 %	84%
DASH score	8.4 points	0 – 20 points	

Gartland and Werley scoring system: excellent (16), good (26), fair (4)
* compared with the unaffected side

Table 2. Clinical outcomes.

Complications

One patient requested removal of the plate 10 months after surgery. There were no cases of infection, complex regional pain syndrome, tendon rupture, nerve irritation, or implant failure.

Discussion

In this study, the K-DRAVP system appropriately fit the anatomy of the distal radius of Korean patients. The system provided good maintenance of the anatomic alignment after reduction of the fracture, as observed radiologically, and most patients (91%) achieved excellent or good results according to the Gartland and Werley scoring system. There was no statistically significant deterioration in any of the radiologic parameters, such as volar tilt, radial inclination, and radial length. Grip strength and range of motion at the final follow-up were restored to approximately 85% of the values of the unaffected side. The mean DASH score (8.4 points) indicated little discomfort in daily living.

Volar plating with a locking screw system has the advantages of being an easy surgical procedure, having a relatively low risk of complications, and early functional mobilization. Several authors have reported good outcomes from various types of volar plates for distal radius fractures. Drobetz et al. reported the results from 50 patients treated with a locking plate system (Mathys®, Salzburg, Austria).[9] According to the Gartland and Werley scoring system, 26 patients had excellent results, 20 had good results, 3 had fair results, and 1 had a poor result after a mean follow-up of 26 months. Kamano et al. reported the results from 40 patients with distal radius fractures treated

with palmar plates (Biotechini Co., Ltd., Ciotat, France).[10] They reported 12 excellent and 28 good results after a mean follow-up of 12 months, according to the Gartland and Werley scoring system. Wong et al. reported the results of 35 patients with dorsally displaced distal radius fractures using the Stryker plating system with SmartLock locking screws after a mean follow-up of 10 months.[11] The mean Mayo clinic wrist score was 90 points, and 20 patients achieved an excellent result. Figl, et al. reported the results from 80 patients with unstable distal radius fractures treated using the APTUS plate (Medartis AG, Basel, Switzerland) with a mean follow-up of 7 months.[12] The mean DASH score was 25 points, and according to the Castaing score, 30 patients had perfect results, 49 had good results, and 1 had an adequate result. Minegishi et al. reported the results of 15 patients with unstable distal radius fractures treated using the Acu-Loc distal radius plate (Acumed, Oregon, USA) with a mean follow-up of 15.5 months.[13] In their study, according to Cooney's clinical scoring chart, 5 patients had excellent results, 7 had good results, and 3 had fair results. Lattmann et al. reported a relatively large series of 228 patients with distal radius fractures treated with LC-T plates (Synthes, Bettlach, Switzerland).[14] Grip strength was 91% of that on the contralateral side, and the assessed Patient-Rated Wrist Evaluation (PRWE) score was 8 points. Few studies have evaluated Asian-type distal radius volar plates. Osada et al. reported the results of 49 patients with distal radius fractures treated with a distal radius volar locking plate (DRV-LP [Mizuho Ikakogyo

Co., Ltd., Tokyo, Japan]).[15] After 1 year of follow-up, the mean DASH score was 6.1 points (range, 0 to 30) and all patients showed excellent or good results according to the Gartland and Werley scoring system. Yasuda et al. also reported good outcomes with a new variable angle distal screw locking volar plate system (Nakashima Propeller Co., Ltd., Okayama, Japan)[16].

Our radiologic and clinical results are similar to those of other studies using different types of distal radius volar plates (Table 3). Furthermore, in our study, there were no mechanical complications such as irritations of flexor tendons or the median nerve. Some studies have reported on mechanical irritations after volar plate fixation.[18-20] Kim et al. reported 2 cases of multiple flexor tendon ruptures after volar plate (LC-T plate; Synthes, Bettlach, Switzerland) fixation for distal radius fractures.[18] They reported that the prominent distal part of the volar plate could cause damage to the flexor tendons. Lee et al. reported 2 complications of mechanical irritations after volar plate (Acu-Loc System; Acumed, Oregon, USA) fixation for distal radius fractures.[19] Lee et al. reported mechanical irritation of the median nerve after volar plate fixation for distal radius fractures.[20] In this case, there were no mechanical complications because the K-DRAVP system was initially designed as a low-profile system with a specially contoured thin and narrow end of the distal margin in order to minimize these mechanical complications, such as tendon or nerve irritations.

This study has some limitations. First, this was not a randomized controlled

study, and we did not compare our results with patients who were treated with other types of distal radius plates. Therefore, we compared our data with those of previous reports. Further prospective randomized controlled studies are required. Second, we included a relatively short follow up period because our study was a preliminary report. Patients who had fair outcomes according to the Gartland and Werley scoring system had relatively shorter follow-up periods (7 months; range 6 to 8) than those of patients who had excellent or good outcomes (10.4 months; range 7 to 14). This finding suggests that outcomes are more favorable with a longer follow-up period. Third, K-DRAVP plate system had some problems. On the basis of our experience with the K-DRAVP system, we recommended some improvements in the plate. First, the drilling guides for the screws were small and separated, and management of these guides was difficult and time-consuming. Second, plates of variable sizes and lengths should be designed. One female patient could not be treated with the K-DRAVP system because the diameter of her radius was smaller than that of the plate. Third, another plate designed for juxta-articular distal radius fractures is needed for fixation of small distal juxta-articular fragments. After we reported our suggestions to the manufacturer, a revised version of the K-DRAVP system has been developed and is in use. Further reports on the results of the revised version of the plate will be published in due course.

Authors	Case number	Plate system	Mean follow- up period (months)	Results (used functional scoring system)
Drobetz el al. (2003)[9]	50	Mathys plate system (Salzburg, Austria)	26	Excellent (26), Good (20), Fair (3), Poor (1) (by Gartland and Werley score)
Kamano et al. (2005)[10]	40	Palmar plate (Biotechini Co., Ltd., Ciotat, France)	12	Excellent (12), Good (28) (by Gartland and Werley score)
Wong et al. (2009)[11]	35	SmartLock (Stryker, Kalamazoo, MI)	10	Excellent (20), Good (12), Fair (2), Poor (1) (by Mayo wrist score)
Figl et al. (2009)[12]	80	APTUS (Medartis AG, Basel, Switzerland)	7	DASH 25 points Perfect (30), Good (49), Adequate (1) (by Castaing score)
Minegishi et al. (2011)[13]	15	Acu-Loc (Acumed, Hillsboro, Oregon)	15.5	Excellent (5), Good (7), Fair (3) (by Cooney's Clinical scoring chart)
Matschke et al. (2011)[17]	117	3.5mm LCP-DR (Synthes, Bettlach, Switzerland)	24	DASH 11.2 points Excellent (59), Good (37), Fair/Poor (12) (by Gartland and Werley score)
Lattmann et al. (2011)[14]	228	LC-T plates (Synthes, Bettlach, Switzerland)	12	Grip strength 91% PRWE 8 points
Osada et al. (2008)[15]	49	DRV Locking Plate (Mizuho Ikakogyo Co., Ltd., Tokyo, Japan)	12	DASH 6.1 Excellent (47), Good (2) (by Gartland and Werley score)
Current Study	46	Korean type distal radius anatomical volar plate (BK Meditech, Hwasung, Korea)	10.1	DASH 8.4 Excellent (16), Good (26), Fair (4) (by Gartland and Werley score)

Table 3. Results of recent studies of volar locking plate systems

Conclusion

Although this study was only a preliminary report on the newly developed K-DRAVP system, we found that this plate system could be used to restore and maintain good anatomical parameters, and provide good clinical outcomes with low complication rates because it is the first anatomical distal radius volar plate based on the anatomical characteristics of Koreans. The K-DRAVP system is a promising surgical option for distal radius fractures for the Korean population.

References

1. Thompson PW, Taylor J, Dawson A. The annual incidence and seasonal variation of fractures of the distal radius in men and women over 25 years in Dorset, UK. Injury. 35(5):462-6, 2004.

2. Park C, Ha Y-C, Jang S, Jang S, Yoon H-K, Lee Y-K. The incidence and residual lifetime risk of osteoporosis-related fractures in Korea. J Bone Miner Metab. 29(6):744-51, 2011.

3. Orbay JL. The treatment of unstable distal radius fractures with volar fixation. Hand Surg. 5(02):103-12, 2000.

4. Chung KC, Shauver MJ, Birkmeyer JD. Trends in the United States in the treatment of distal radial fractures in the elderly. J Bone Joint Surg Am. 91(8):1868-73, 2009.

5. Lim ST, Yeom JS, Lee CH, Lee YH, Chang CB, Baek GH. Development of anatomical plating system for treatment of distal radius fractures. The Journal of the Korean Society for Surgery of the Hand. 12(3):95-104, 2007.

6. Arora R, Lutz M, Hennerbichler A, Krappinger D, Espen D, Gabl M. Complications following internal fixation of unstable distal radius

fracture with a palmar locking-plate. J Orthop Trauma. 21(5):316-322, 2007.

7. Gartland JJ, Werley CW. Evaluation of healed Colles' fractures. J Bone Joint Surg. 33(4):895-907, 1951.

8. Sarmiento A, Pratt GW, Berry NC, Sinclair WF. Colles' fractures: functional bracing in supination. J Bone Joint Surg. 57A:311-7, 1975.

9. Drobetz H, Kutscha-Lissberg E. Osteosynthesis of distal radial fractures with a volar locking screw plate system. Int Orthop. 27(1):1-6, 2003.

10. Kamano M, Koshimune M, Toyama M, Kazuki K. Palmar plating system for Colles' fractures - a preliminary report. J Hand Surg Am. 30(4):750-5, 2005.

11. Wong TC, Yeung CC, Chiu Y, Yeung SH, Ip FK. Palmar fixation of dorsally displaced distal radius fractures using locking plates with Smartlock locking screws. J Hand Surg Eu. 34(2):173-8, 2009.

12. Figl M, Weninger P, Liska M, Hofbauer M, Leixnering M. Volar fixed-angle plate osteosynthesis of unstable distal radius fractures: 12 months results. Arch Orthop Trauma Surg. 129(5):661-9, 2009.

13. Minegishi H, Dohi O, An S, Sato H. Treatment of unstable distal radius

fractures with the volar locking plate. Ups J Med Sci. 116(4):280-4, 2011.

14. Lattmann T, Meier C, Dietrich M, Forberger J, Platz A. Results of volar locking plate osteosynthesis for distal radial fractures. J Trauma. 70(6):1510-8, 2011.

15. Osada D, Kamei S, Masuzaki K, Takai M, Kameda M, Tamai K. Prospective study of distal radius fractures treated with a volar locking plate system. J Hand Surg Am. 33(5):691-700, 2008.

16. Yasuda M, Ando Y. A new variable angled locking volar plate system for Colles' fracture: Outcome study and time-course improvement of objective clinical variables. Hand Surg. 14(2 & 3):93-8, 2009.

17. Matschke S, Marent-Huber M, Audigé L, Wentzensen A. The surgical treatment of unstable distal radius fractures by angle stable implants: a multicenter prospective study. J Orthop Trauma. 25(5):312-7, 2011.

18. Kim JY, Kang HJ, Yi Y. Multiple flexor tendon injuries after volar plate fixation for distal radius fractures. J Korean Soc Surg Hand. 17(1):47-51, 2012.

19. Lee SJ, Bae JY, Cho HJ, Suh KT. Short term results of AO type C fractures of the distal radius treated with volar locking plate system. J Korean Soc Surg Hand. 16(4):191-197, 2011.

20. Lee SU, Park IJ, Kim HM, Lee JY, Yoo HH, Jeong C. K-wire fixation supplemented with external fixator versus volar locked plating for unstable fractures of the distal radius. J Korean Soc Surg Hand. 15(4):157-163, 2010.

국문 초록

서론: 원위 요골 골절은 상지에 발생하는 골절 중 가장 흔한 골절로, 한국에서만 1년에 60,000례 정도 발생한다. 이 중 불안정성 원위 요골 골절의 치료에 있어, 해부학적 수장 잠김 금속판을 이용한 내고정술이 흔히 사용되고 있다. 하지만 현재 사용되고 있는 해부학적 수장 잠김 금속판 대부분은 서양인의 해부학적 특성에 맞추어 개발된 제품들이었다. 최근, 한국인 원위 요골의 해부학적 특성을 바탕으로 한국형 원위 요골 해부학적 수장 금속판이 개발되어 사용되기 시작하였다. 본 연구는 한국형 원위 요골 해부학적 수장 금속판의 사용에 따른 초기 결과를 보고하고, 그 방사선학적 및 기능적 결과를 다른 금속판 시스템과 비교하여 보고자 한다.

방법: 2012년 3월부터 2012년 10월까지 서울대학교 병원, 분당 서울대학교 병원, 서울 보라매 병원에서 원위 요골 골절로 진단받은 후, 한국형 원위 요골 해부학적 수장 금속판을 이용한 수술적 치료를 받은 환자 46명을 대상으로 하였다. 모든 환자는 방사선학적으로 골유합 및 결과 평가를 위해 표준 후전면 및 측면

사진을 촬영하였고, 수술 전, 수술 후, 최종 추시 시 3회에 걸쳐 각각 방사선학적 지표인 수장 경사, 요골 경사, 요골 길이를 측정하였다. 임상적 및 기능적 결과를 위해서 손목 관절의 운동 범위, 파악력을 측정하였고, Gartland and Werley scoring system과 Disabilities of the Arm, Shoulder and Hand (DASH) 설문지를 사용하였다.

결 과: 모든 골절은 평균 42일에 골유합을 보였다. 수장 경사, 요골 경사, 요골 길이로 측정한 방사선학적 지표 모두 수술 후 정상 범위로 교정되었으며, 최종 추시 때까지 금속물의 이완이나 정복 소실 등은 관찰되지 않았다. 파악력은 최종 추시 때 정상측의 84%까지 회복되었다. 최종 추시 때 손목 관절의 평균 운동 범위는 신전 56.2°, 굴곡 51.3°, 요측 사위 15.6°, 척측 사위 25.9°, 회내전 81.0°, 회외전 79.6°였으며 정상측의 77-95% 범위로 회복되었다. Gartland and Werley scoring system에 따르면 16명은 매우 우수(excellent), 26명은 우수(good), 4명은 양호(fair)한 결과를 보였다. 평균 DASH 점수는 8.4 점이었으며, 수술 후 합병증은 관찰되지 않았다.

결 론: 새로이 개발된 한국형 원위 요골 해부학적 수장 금속판은 정상적 해부학적 지표들의 유지를 가능하게 하며, 낮은 합병증

발생율과 함께 좋은 임상적 결과를 보였다. 한국인의 해부학적 지표에 바탕을 둔 한국형 원위 요골 해부학적 수장 금속판은 한국인의 원위 요골 골절의 치료에 있어 좋은 치료법 중의 하나로 생각된다.

색인 단어: 요골, 원위 요골 골절, 수장 잠김 금속판, 해부학적 금속판

학 번: 2012-21682