의학석사 학위논문

Effect of angiopoietin-2 and vascular endothelial growth factor on function and neovascularization of xenografted bovine ovarian tissue

소 난소조직 이종이식 시 angiopoietin-2 와 vascular endothelial growth factor 가 이식조직 기능과 신생혈관형성에 미치는 영향 연구

2015 년 2 월

서울대학교 대학원
의학과 분자유전체의학 전공

공 현 선

소 난소조직 이종이식 시 angiopoietin-2 와 vascular endothelial growth factor 가 이식조직 기능과 신생혈관형성에 미치는 영향 연구

지도교수 서 창 석

이 논문을 의학석사 학위논문으로 제출함

2015 년 02 월

서울대학교 대학원

의학과 분자유전체의학 전공

공 현 선

공현선의 의학석사 학위논문을 인준함

2014 년 12 월

위 원 장 _____(인)

부위원장 _____(인)

위 원 _____(인)

ABSTRACT

Objectives: As fertility preservation options for oncological female patients, ovarian tissue (OT) cryopreservation and transplantation have been used to restore their fertility and as a result, over 30 deliveries were recorded by these techniques. Even though such successes, it is difficult to prevent ischemic injury which occurs right after transplantation. As a result, a massive follicle loss and stromal cell destruction arise in the graft. Thus, it is necessary to shorten the ischemic period and promote neo-vascularization to overcome the ischemic injury. The aim of this study was to assess the impact of angiogenic factors, especially angiopoietin-2 (Ang-2) and vascular endothelial growth factor (VEGF) on bovine OT after xenotransplantation (XT).

Methods: A total of 6 bovine ovaries were transported from the local slaughter house to our laboratory within 2 hours. The OT cortex was separated and sliced into 5 x 5 x 1 mm^3 size strips, and the OT strips were vitrified-warmed or remained fresh for further procedure. For the XT experiment using bovine OT, 9-week-old BALB/c nude mice (n=30) were ovariectomized, and subcutaneously xenografted with fresh (XT-Fresh), or vitrified-warmed OTs. Before XT with vitrified OTs, the nude mice were randomly subdivided into 4 groups and intraperitoneally injected with saline (XT-Vitri), 500 ng Ang-2 (XT-Ang-2), 200 ng VEGF (XT-VEGF) and a combination of 500 ng Ang-2 and 200 ng VEGF (XT-Combined) before 18 hours and 30 minutes of XT. After 7 or 28 days of XT, the grafts were retrieved, and follicle normality, density, angiogenesis, and fibrosis of grafted OT were evaluated with histological evaluation, CD31 immunostaining, and Masson's trichrome

staining, respectively.

Results: Improvement of primordial follicle (PF) normality was found in angiogenic factor treated groups when compared to the XT-Vitri group 7 and 28 days after grafting. Growing follicle (GF) normality was also significantly increased among angiogenic factor treated groups on day 7. On day 28, only the XT-VEGF and the XT-Combined group showed significantly increased GF normality when compared to the XT-Vitri group. With regards of follicle density, the PFs were significantly well preserved in the XT-Combined group on day 7 when compared with XT-Vitri group, which was comparable to the result of the XT-Fresh group. For the angiogenic factor treated groups, the mean numbers of GF were remarkably increased which was comparable to the XT-Fresh group on day 28. Among the 5 XT groups, the highest microvessel density was observed in the XT-Combined group on day 7 and 28. The most extensive fibrosis was detected in the XT-Vitri group on day 7 and 28, and was reduced in angiogenic factor treated groups, but this difference did not reach the statistical significance.

Conclusions: In this study, well preserved PF and GF, and remarkably improved microvessel densities were appeared in the angiogenic factor treated groups; especially in the combination of Ang-2 and VEGF treated groups. Thus, we propose that the angiogenic factors have beneficial effects on OT transplantation outcome and help to overcome the ischemic damage during the early grafting process. However further studies are necessary to clarify exact mechanisms of Ang-2 and VEGF effects in OT grafts.

Keywords: ovarian tissue / xenotransplantation/ vitrification / angiogenesis / fertility preservation

Student number: 2013-21717

CONTENTS

LIST OF TABLES

LIST OF FIGURES

LIST OF ABBREVIATIONS

Ang: Angiopoietin

ANOVA : one-way analysis of variance

DMSO: Dimethyl Sulfoxide

EG: Ethylene glycol

FBS: Fetal bovine serum

GF: Growing follicle

H&E: Hematoxylin and Eosin

HPF: High-power field

L-15: Leibovitz-15

OT: Ovarian tissue

PF: Primordial follicle

RT: Room temperature

VEGF: Vascular endothelial growth factor

XT: Xenotransplantation

INTRODUCTION

Remarkable progress in cancer treatment has been introduced to oncological patients and it promoted them to survive more. However, reduced fertility is frequently observed after cancer treatment in young patients (1, 2). Especially, in women patients, the cancer treatment can cause premature ovarian failure or subfertility, which threatening their quality of life (3, 4). To overcome these problems, several fertility preservation options have been developed, including oocyte/embryo or ovarian tissue (OT) cryopreservation (5). Among those options, the OT cryopreservation has advantages over the other two options of oocyte and embryo cryopreservation in that it can be used without a spouse and delaying of chemotherapy unlike other fertility preservation options (6). Additionally, for the pre-pubertal girl patients, it could be the only fertility preservation option that they can consider (7). Up to date, over 30 children have been born by this technique (8), however, the procedure has been still considered as an experimental stage of procedure.

Ovarian tissue and transplantation procedures are not perfectly established yet. Several factors would affect the quality of OT grafts, above all, ischemic injury after the transplantation was documented to be a major reason causing ovarian follicle depletion, and poor stromal cell quality (9). According to several reports, neovascularization after grafting emerged within 48 hours in the rat (10), 1 week in the sheep (11, 12), and 5 days in human (13). Before the completion of neovascularization, the OT grafts should endure the ischemia and hypoxic environments. Therefore, it is necessary to shorten the ischemic period and promote neovascularization to overcome the ischemic injury and recover the OT

function successfully. So the great efforts have been made to promote neovascularization during the early ischemic periods. Many studies were worked on determining the most suitable grafting site (14, 15), seeking for the best ovarian cortex size (5), or searching for the effective treatment substances for enhancing neovascularization for OT graft survival and function restoration (16-19). But, more efforts on OT cryopreservation and transplantation are needed for optimization.

Vascular endothelial growth factor (VEGF) is one of the major angiogenic factors which was used in many studies to enhance neovascularization, and showed beneficial effects in auto- or xeno-transplantation of mouse, rabbit, and human OTs (16, 17, 20). Angiopoietin (Ang) is also one of the angiogenic factors as a vascular growth factor family. But unlike VEGF, the exact mechanisms or physiological roles of Ang have not been well proved yet. So far, it is found that Ang-1 has role in embryonic stage of angiogenesis, meanwhile Ang-2 play a role in postnatal angiogenesis (21-23). Especially, the Ang-2 has been reported to have function in wound healing process and exist abundantly at hypoxic and ischemic sites together with VEGF (24, 25). Our previous study demonstrated that the treatment of Ang-2 to mice after transplantation of cryopreserved OTs had beneficial effects on facilitating neovascularization of OT grafts. Furthermore, Asahara et al., reported that the co-administration of Ang-2 and VEGF showed the highest level of vessel formation at the eye site when compared to Ang-2 or VEGF alone treatment (26). However, there has been no previous study for the effect of combination treatment of Ang-2 and VEGF in OT transplantation.

This study was performed to evaluate the effects of angiogenic factors, Ang-2

and VEGF alone and in combination, on bovine OT transplantation and to improve OT graft survival and quality by enhancing neovascularization and reducing ischemic injury.

MATERIALS AND METHODS

Study scheme

Flow of this experiment is simply depicted in the figure 1. Briefly, the bovine OT preparation and cryopreservation, administration of angiogenic factor or normal saline to the mice, and xenografting procedure are illustrated in a time-dependent manner. After the procedure, the mice were sacrificed for the graft retrieval and sample analysis.

Preparation of bovine ovarian tissue

Bovine ovaries (n=6) immersed in Leibovitz's L-15 (L-15) medium (WelGene, Dae-gu, Korea) of 4℃ were transported from a local slaughterhouse to our laboratory within 2 hours. The ovaries were swapped with 70% alcohol to get rid of the remaining blood and contaminants, and washed once more with L-15 medium. After that, the ovary was cut in half, and the medulla part was removed by curved scissors and forceps. Then the OT cortex was sliced into approximately 5 x 5 x 1 mm^3 size, and some of the fresh OTs were used for fresh OT (w/o vitrification) transplantation and some of the OTs were vitrified for the next procedures.

Vitrification and warming

As previously described by Youm et al., OTs were vitrified by two-step vitrification method with slight modification (14). Briefly, the OTs were submerged into 7.5% ethylene glycol (EG; sigma-aldrich, Missouri, US) and 7.5% dimethyl

sulfoxide (DMSO; sigma-aldrich, Missouri, US) in L-15 medium with 20% fetal bovine serum (FBS; Gibco, Paisley, UK) for 15 minutes at room temperature (RT). For the second step, the OTs were moved to 20% EG, 20% DMSO, and 0.5 M of sucrose (sigma-aldrich, Missouri, US) in L-15 medium with 20% FBS for 10 minutes at RT. Right after the second step, they were placed on a metallic cryopreservation device and directly plunged into liquid nitrogen (LN_2), and stored in LN_2 tank for over one day.

For warming, the OTs were proceeded in serially diluted medium containing 1 M, 0.5 M, 0.25 M, and 0 M of sucrose in L-15 medium with 20% FBS. The first step was performed for 1 minute at 37℃, and the each other step was performed for 5 minutes at RT.

Xenotransplantation to nude mice

Nine-week-old BALB/c nude mice (Orient Co., Seoul, South Korea) for this study were housed under a 12-h light/dark cycle at 22℃ and fed ad libitum. The guidelines for animal welfare were approved by the Institutional Animal Care and Use Committee of Seoul National University Bundang Hospital.

The nude mice (n=30) were randomly divided into 5 different XT groups as described in table 1. Of those five groups, one group was xenotransplanted with non-vitrified fresh OT (XT-Fresh). For the other 4 groups, the nude mice were xenotransplanted with vitrified-warmed OTs. Before transplantation with vitrified-warmed OTs, saline (XT-Vitri), 500 ng Ang-2 (R&D systems, Minnesota, USA)(XT-Ang-2), 200 ng VEGF (R&D systems, Minnesota, USA)(XT-VEGF) and a combination of 500 ng Ang-2 and 200 ng VEGF (XT-Combined) were

intraperetoneally injected. The injection dose of Ang-2 was determined by our previous study for the effect of Ang-2 on autotransplanted mouse ovary. Mouse VEGF-A, mouse $VEGF_{164}$ isoform, treatment showed improvement of neovascularization in the previous study (15), so the $VEGF_{164}$ was adopted in this study. And the effective dose of VEGF injection on mouse model was determined by referring to the study of Hiratsuka et al. (25). The half-life of Ang-2 is known to be 18 hours (27) and the half-life of VEGF that we use are not tested yet. In other study, VEGF was injected into mouse eye and it showed its effect 6 hours after the injection (28). We assumed that Ang-2 has longer half-life than VEGF; therefore, injection timing was determined followed by Ang-2 half-life as 18 hours and 30 minutes before XT.

For removal of mice's own ovaries and xenotransplantation of bovine OT, the nude mice were anesthetized with zoletil (Virbac, Carros, France) and rumpon (Bayer, Leverkusen, Germany) solution. The bilateral ovariectomy of mice was performed through small incision made at the middle dorsal part along with the spinal line. Then the bovine OTs (5 x 5 x 1 mm^3) were transplanted into the dorsal subcutaneous sites, and the OTs were sutured with 5/0 nylon. The skin wounds were clipped with 9 mm auto clip (Jeungdo Bio & Plant, Seoul, Korea), and gentamicin (0.75mg/mouse) was injected intraperitoneally.

Graft retrieval

Seven or 28 days after grafting, the nude mice were sacrificed by cervical dislocation and the bovine OT grafts were retrieved. The residuals of mouse origin tissue were eliminated from the OT grafts, and washed in normal saline several

times. Then the OT grafts were immediately fixed in Bouin's solution (sigma-aldrich, Missouri, US) for more than one day followed by embedding in paraffin block for histological analysis.

Histological analysis

The bovine OT grafts embedded in paraffin blocks were serially sectioned at 5 μm thicknesses with 100 μm intervals. The first 3 slides were stained with hematoxylin (DAKO, Seoul, Korea) and eosin (Merck, Darmstadt, Germany) (H&E), and the other remaining slides were used for immunostaining.

The H&E stained slides were read twice by a single experienced inspector for follicular stage/normality/density measurement with a light microscopy (Nikon, Tokyo, Japan). Total fields were evaluated for the follicular stage and normality. The developmental stages of follicles were classified according to the following categories (29):

1) Primordial: single layer of flattened pre-granulosa cells
2) Primary: single layer of granulosa cells, one or more being cuboidal cells
3) Secondary: two or more layers of cuboidal granulosa cells, with the antrum absent
4) Antral: multiple layers of cuboidal granulosa cells, with the antrum present

Only follicle with a clearly visible oocyte encircled by a granulosa cell layer were counted (30), and the follicles were classified as morphologically normal or degenerated. Follicles were considered degenerated when presenting pycnotic bodies in granulosa cells, condensed oocyte nucleus, shrunken oocyte, oocyte

cytoplasm vacuolization or low cellular density (6). For the follicle density measurement, follicles were examined at 3 high-power fields (HPF; x 400 magnification) per each OT graft.

Evaluation of angiogenesis

To count the numbers of microvessels, CD31 immunostaining was performed. First, the paraffinized OT slides were deparaffined and rehydrated in xylene and ethanol, respectively. The rehydrated slides were microwaved with pH 9.0 Tri/EDTA buffer (DAKO, Seoul, Korea) of target antigen retrieval solution for 20 min. After cooling the slides, peroxidase-blocking solution (DAKO, Seoul, Korea) was treated for 10 minutes followed by incubation with CD31 antibody (1:400, Bioss, Massachusetts, USA) for 1 hour at RT. After treatment of primary antibody (CD31), the slides were washed and treated with EnVision/HRP solution (DAKO, Seoul, Korea) for 30 min and substrate-chromogen solution (DAKO, Seoul, Korea) for 10 min. All slides were counterstained with hematoxylin (DAKO, Seoul, Korea), and CD31 positive blood vessels were counted under a light microscopy (Nikon, Tokyo, Japan) at 3 sites (x 400) per each OT graft.

Evaluation of fibrosis

The fibrotic areas were characterized by poor cellularity, evidenced by a reduced number of cell nuclei and collagen deposits (17). To evaluate the fibrotic surface area, Masson's trichrome staining was performed with Roche Trichrome lll Blue Staining Kit (Roche, Basel, Switzerland). The fibrotic surface, nuclei and cytoplasm were stained as blue, black and red, respectively. The slides were

scanned with a light microscopy at x 100 magnification, and fibrotic area ratios were analyzed using i-Solution image analysis software (IMT i-Solution Inc., Daejeon, Korea).

Statistical analysis

The outcomes of follicle normality were compared by Chi-square test. The follicle and microvessel densities were analyzed by one-way analysis of variance (ANOVA). Analysis of the ratio of fibrotic areas was carried out with Kruskal-Wallis test. Statistical software package SPSS 18.0 (SPSS Inc., Chicago, USA) and GraphPad Prism were used (Graph-Pad, San Diego, CA, USA). The values were considered significant when $p < 0.05$.

Table 1. **Different groups and treatments used in this experiment**

Groups	Vitrification	Treatment before grafting
XT-Fresh	No	None
XT-Vitri	Yes	Saline
XT-Ang-2	Yes	500 ng of Ang-2
XT-VEGF	Yes	200 ng of VEGF
XT-Combined	Yes	500 ng of Ang-2 + 200 ng of VEGF

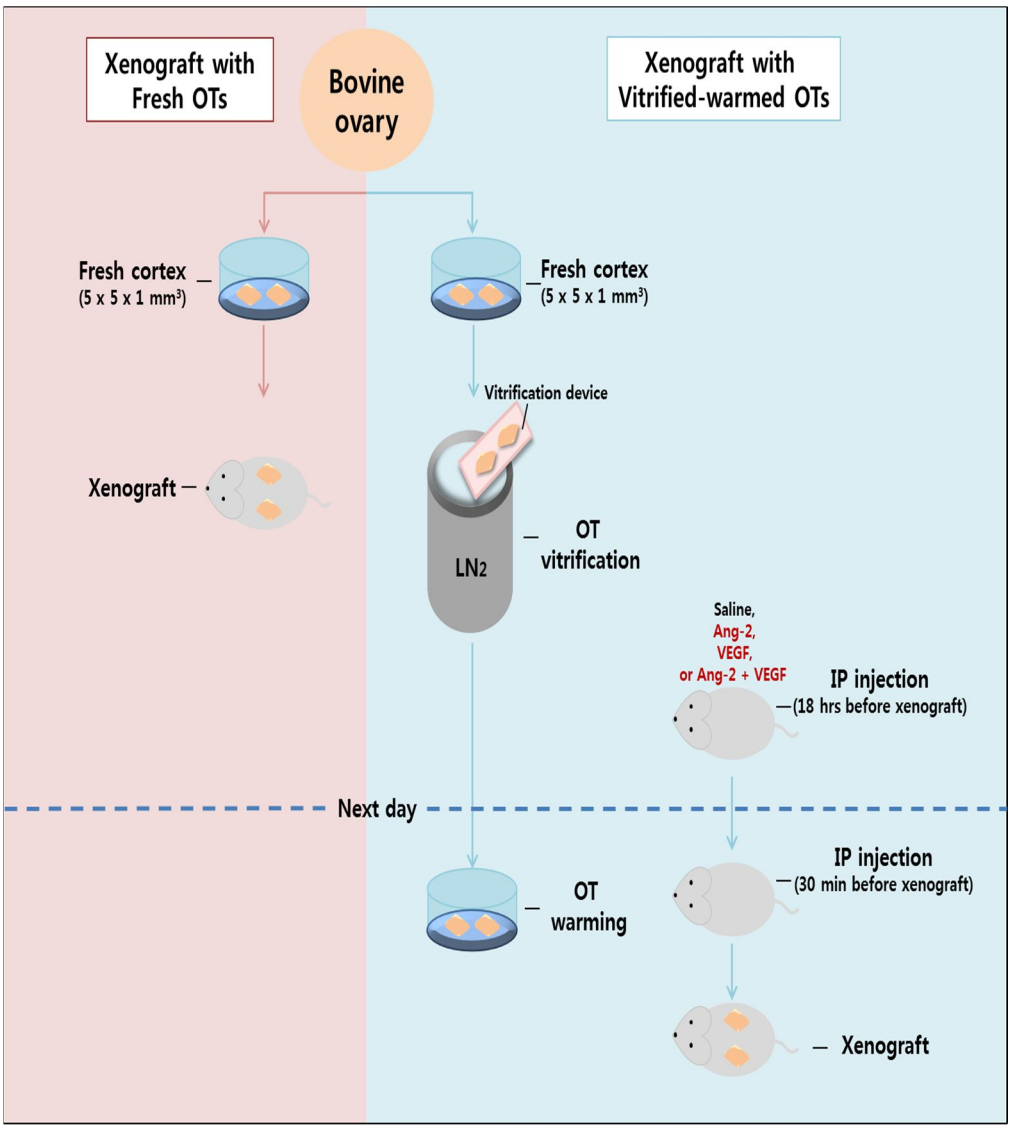

Figure 1. Experimental scheme of this study

Flow of this study is shown as simple diagram. Xenografting procedures with fresh OTs and vitrified-warmed OTs are described on the left side and right side of the figure, respectively.

OT: Ovarian tissue
LN_2: Liquid nitrogen
IP: Intraperitoneally

RESULTS

Histological evaluation

The histological figures of the grafts are shown in figure 2. On day 7, the primordial and primary stage follicles are observed in all the 5 groups, and low stromal cell density and damaged structure are shown in the XT-Vitri group, while the angiogenic factor treated groups, especially the XT-Combined group, shows more intact stromal cell features when compared with the XT-Vitri group. Secondary follicles and improved stromal cell condition are found in all of the XT groups 28 days after grafting.

The normal (intact) follicle ratios of primordial follicle (PF) and growing follicle (GF) were significantly increased in the angiogenic factor treated groups when compared with the XT-Vitri group on day 7 (Fig. 3A and B). On day 28, the normal follicle ratios of PF were also higher in the angiogenic factor treated groups than the XT-Vitri group (Fig. 3C), and the GF integrities were higher in the XT-VEGF and XT-Combined groups, which was comparable to the result of the XT-fresh group, than the other two XT groups (Fig. 3D).

Ovarian follicle density

A significant increase in PF density was observed in the XT-Combined group (2.71±0.28/HPF) when compared with the XT-Vitri group (1.62±0.20/HPF), followed by no significant difference among the 5 groups on day 28 (Fig. 4A and C). For the GF densities, there was no statistical difference among the groups on day 7 (Fig. 4B), however as time advanced, the GF densities were increased in the

angiogenic factor treated groups (XT-Ang-2: 2.95±0.31, XT-VEGF: 2.54±0.22, XT-Combined: 3.35±0.30) and their outcomes became similar to the result of XT-Fresh group (2.92±0.27) (Fig. 4D).

Microvessel density

The mean numbers of microvessels were significantly increased up to the level of the XT-fresh group in the XT-VEGF and XT-Combined groups on day 7 (Fig. 5A). On day 28, all the 5 groups show higher numbers of vessels compared with the result of day 7, and more microvessels were developed in the angiogenic factor treated groups than the XT-Vitri group (Fig. 5B). Especially, the XT-Combined group represented the highest mean numbers of vessels among the 5 groups on both day 7 and 28.

Evaluation of fibrosis

The ratios of fibrotic area were highest in the XT-Vitri group on both day 7 (15.16 ± 2.59%) and day 28 (16.96 ± 1.77%), and the difference of the fibrotic area ratios between the XT-Vitri group and the other 4 groups were increased on day 28. However, no statistical difference was found among the 5 groups on day 7 and 28 (Fig. 6A and B).

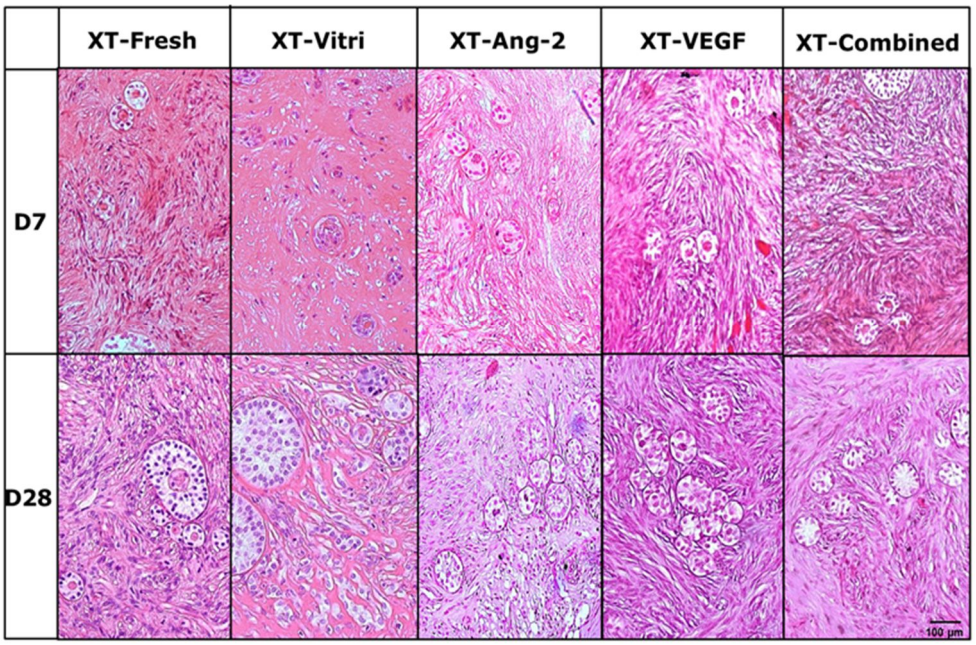

Figure 2. Representative figures of H&E stained slides

The magnification was 400 x and scale bar indicates 100 μm.

D7: 7 days after grafting
D28: 28 days after grafting
XT-Fresh: Transplanted with non-vitrified fresh OT
XT-Vitri: Transplanted with vitrified-warmed OT
XT-Ang-2: Transplanted with vitrified-warmed OT followed by 500 ng of Ang-2 injection
XT-VEGF: Transplanted with vitrified-warmed OT followed by 200 ng of VEGF injection
XT-Combined: Transplanted with vitrified-warmed OT followed by Ang-2 (500 ng)/VEGF (200 ng) injection

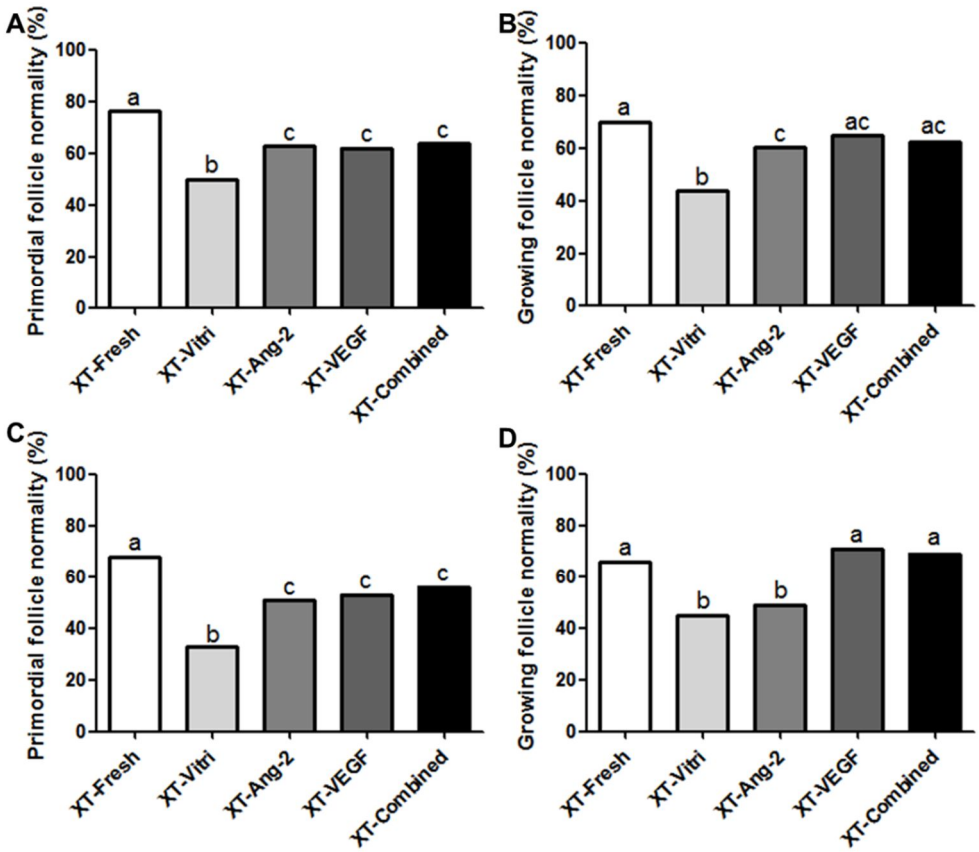

Figure 3. Comparison of the normal follicle ratios in accordance with 5 different groups

X-axis shows the types of 5 different groups and Y–axis represents the normal (intact) follicle ratios after ovarian tissue transplantation (A and B: 7 days after grafting, C and D: 28 days after grafting). Columns with different superscripts indicate statistically significant differences ($p<0.05$).

XT-Fresh: Transplanted with non-vitrified fresh OT
XT-Vitri: Transplanted with vitrified-warmed OT
XT-Ang-2: Transplanted with vitrified-warmed OT followed by 500 ng of Ang-2 injection
XT-VEGF: Transplanted with vitrified-warmed OT followed by 200 ng of VEGF injection
XT-Combined: Transplanted with vitrified-warmed OT followed by Ang-2 (500 ng)/VEGF (200 ng) injection

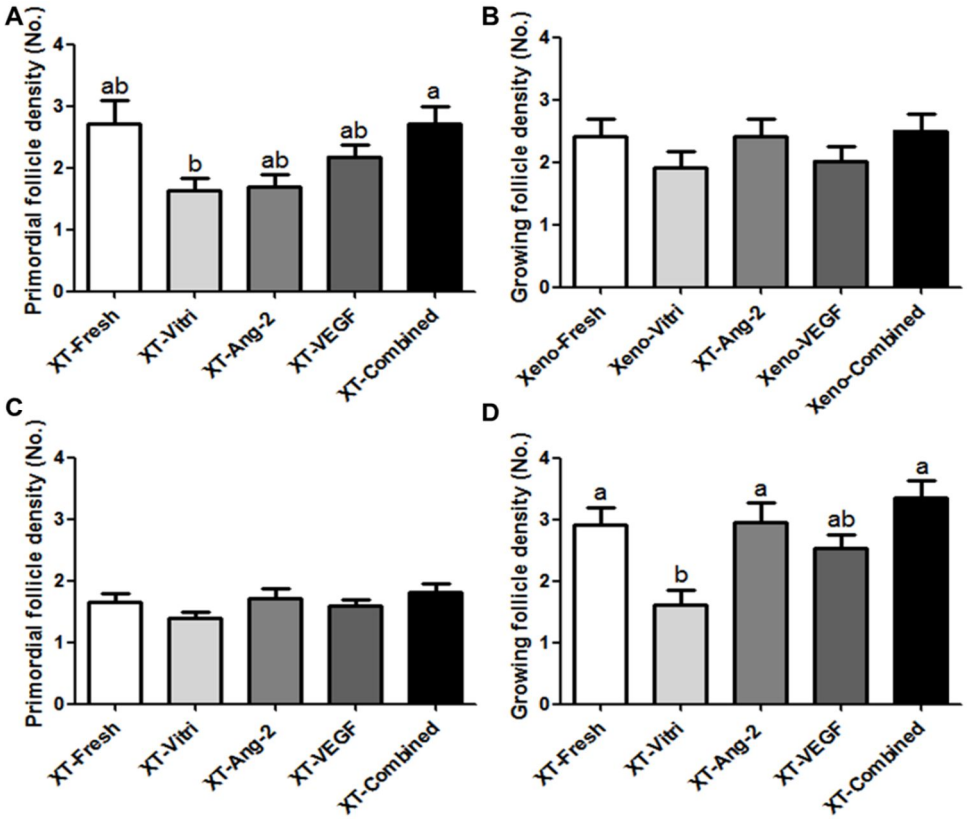

Figure 4. Primordial and growing follicle densities in accordance with 5 different groups

X-axis shows the types of 5 different groups and Y–axis represents the primordial and growing follicle densities after ovarian tissue transplantation (A and B: 7 days after grafting, C and D: 28 days after grafting). Columns with different superscripts indicate statistically significant differences ($p<0.05$).

XT-Fresh: Transplanted with non-vitrified fresh OT
XT-Vitri: Transplanted with vitrified-warmed OT
XT-Ang-2: Transplanted with vitrified-warmed OT followed by 500 ng of Ang-2 injection
XT-VEGF: Transplanted with vitrified-warmed OT followed by 200 ng of VEGF injection
XT-Combined: Transplanted with vitrified-warmed OT followed by Ang-2 (500 ng)/VEGF (200 ng) injection

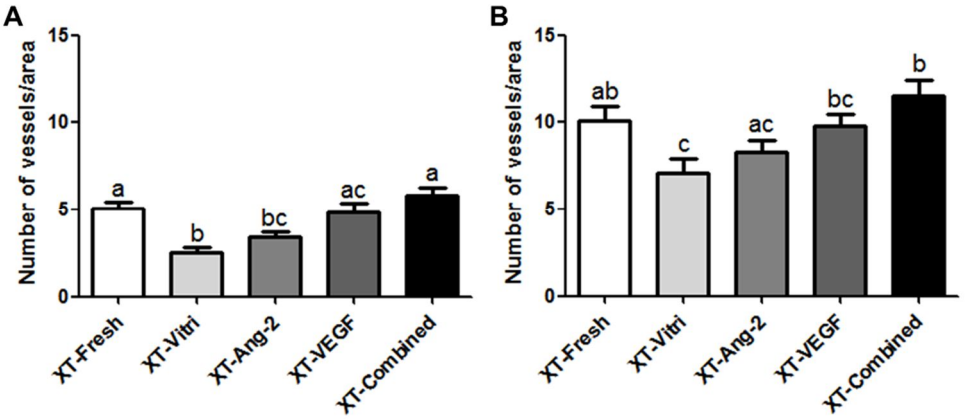

Figure 5. Mean numbers of microvessels per high-power field (x 400)

X-axis shows the types of 5 different groups and Y–axis represents the mean numbers of microvessels after ovarian tissue transplantation (A: 7 days after grafting, B: 28 days after grafting). Columns with different superscripts indicate statistically significant differences ($p<0.05$).

XT-Fresh: Transplanted with non-vitrified fresh OT
XT-Vitri: Transplanted with vitrified-warmed OT
XT-Ang-2: Transplanted with vitrified-warmed OT followed by 500 ng of Ang-2 injection
XT-VEGF: Transplanted with vitrified-warmed OT followed by 200 ng of VEGF injection
XT-Combined: Transplanted with vitrified-warmed OT followed by Ang-2 (500 ng)/VEGF (200 ng) injection

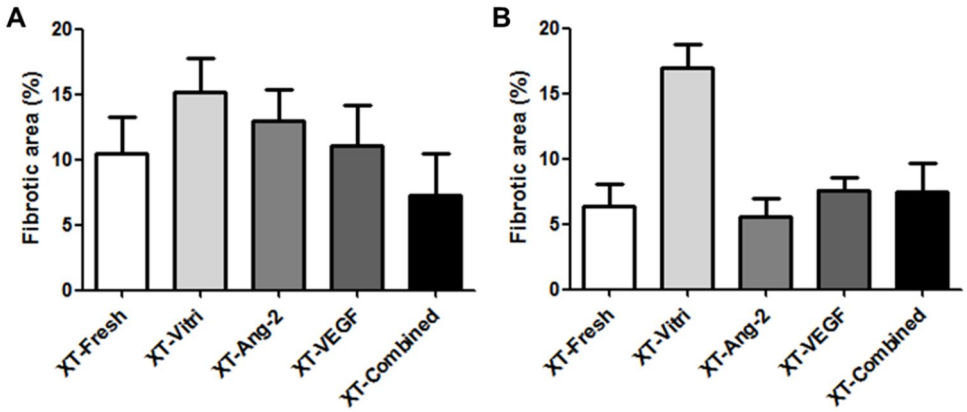

Figure 6. Fibrotic area ratios in accordance with 5 different groups

X-axis shows the types of 5 different groups and Y–axis represents the ratios of fibrotic area after ovarian tissue transplantation (A: 7 days after grafting, B: 28 days after grafting). Columns with different superscripts indicate statistically significant differences ($p<0.05$).

XT-Fresh: Transplanted with non-vitrified fresh OT
XT-Vitri: Transplanted with vitrified-warmed OT
XT-Ang-2: Transplanted with vitrified-warmed OT followed by 500 ng of Ang-2 injection
XT-VEGF: Transplanted with vitrified-warmed OT followed by 200 ng of VEGF injection
XT-Combined: Transplanted with vitrified-warmed OT followed by Ang-2 (500 ng)/VEGF (200 ng) injection

DISCUSSION

OT cryopreservation and transplantation could be the only fertility preservation option for the young female patients who need immediate cancer therapy (1). Since the ovary is a big organ which consisted of variety type of cells, cryopreservation of whole ovary has been considered to be very difficult procedure (31). So, majority of studies have been worked on cryopreservation of OT cortex (5, 32). Because the thin OT cortex contains a great number of follicle at primordial (70-90%) and primary (20-30%) stages, the most resistant stages to cryoinjury (33). It seems feasible and reasonable to cryopreserve the OT cortex; however, a major problem occurs after OT transplantation. Because of the avascular grafting, the graft should be going through the ischemic condition during the early post-transplantation periods, and the detrimental ischemic impact on the graft quality and survival (13). To improve the outcome of OT transplantation followed by revascularization, Ang-2 and/or VEGF were used to reduce post-transplantation ischemic injury via up-regulate neo-angiogenesis.

As a xenografting model, bovine OTs were xeno-grafted to the nude mice instead of human OTs, because it was hard to obtain human OT for this experiment, and there were ethical issues in xeno-transplantation of human OT to mice. Additionally, several experiments demonstrated that bovine OT was similar to human OT in many aspects such as the size and texture of ovary and the morphology and density of OT follicles (34, 35). Since there were no evident differences between human and bovine OT, bovine OT was selected and xenografted.

Histologically normal follicle ratio was measured among the XT groups.

Regardless of the graft retrieval day, a significant decrease in PF and GF normality was detected in XT-Vitri group when compare to the XT-fresh group. After the OT cryopreservation, unavoidable cryodamage is occurred on the OT, and the avascular grafting procedure seems to deteriorate the OT quality even worse. The similar phenomena were also found in other OT xenografting studies (36, 37). In the previous study of Amorim et al., vitrified-warmed OTs of baboon were autografted for 5 months, and the morphologically normal follicles of OT grafts were significantly decreased when compared with the fresh OT (36). Herraiz et al. have reported that about a two-fold reduction of morphologically normal follicle ratio was observed in cryopreserved and grafted human OT when compared with the fresh OT (37). Although the outcomes of follicle normality were poor in the XT-Vitri group, the increased follicle normality was observed in the angiogenic factor treatment groups, and the increase was significant except the GF normality in the XT-Ang-2 group on day 28. We suggest that increased microvessels modulated by exogenous angiogenic factors had beneficial effects on follicle morphology of the cryopreserved OT grafts. Microvessel density was gradually increased in XT-Ang-2, XT-VEGF, and XT-Combined groups, and relatively low microvessels in XT-Ang-2 group seemed to affect low GF normality on day 28.

A significant reduction of follicle density in the cryopreserved grafts was reported in the previous studies (30, 36) and also in this study of XT-Vitri group when compared to the XT-Fresh group. However, among the vitrified-warmed OT grafted groups, the PF density of the XT-Combined group showed significantly increased on day 7 when compared with the XT-Vitri group, and the increasing trend among angiogenic factor treated groups was very similar to that of the

microvessel density. In accordance with our study, Wu et al. showed that increased PF density was observed in the well vascularized graft treated with Salviae miltiorrhizae when compared with the non-treated cryopreserved OT graft (38). So we propose that the angiogenic factor treatment followed by angiogenesis acceleration has preventive effects on early PF loss, and Ang-2 /VEGF co-treatment was most effective in prevent PF depletion. On the contrary, no significant differences were observed among the groups in GF densities on day 7. In previous study, fresh bovine OT cortex was grafted to the chick chorio-allantoic membrane to study primordial to primary follicle transition and the result shows that the primary follicle density showed no significant difference until 10 days of grafting when compared with the ungrafted tissue (39). Therefore, it seems too early to observe the significant difference in GF density on day 7. In contrast with the result of day 7, remarkably increased GF densities were found in angiogneic factor treatment groups which were comparable to the XT-Fresh group whereas the PF density showed no significance among the XT groups on day 28. Disappeared significance of PF density among XT groups on day 28 might be due to the PF recruitment and growth in early post-transplantation periods so that the well preserved PFs were grown and made the significant difference in GF densities on day 28. Based on the results, we consider that preserved PFs in the angiogenic factor treatment group are well grown until day 28, and it was due to the sufficient blood supply containing the follicle growth factors, hormones, and/or nutrients. Thus, we propose that promoted angiogenesis in angiogenic factor treated group, especially XT-Combined group, results in increased PF density on day 7, and the well preserved PFs in angiogenic factor treatment group made the significant

difference in GF densities on day 28.

The OTs which grafted after cryopreservation showed significantly lower microvessel density when compared with the fresh graft. The reduction of microvessel numbers in the cryopreserved grafts might be due to the unavoidable cryoinjury. Cryopreservation of human saphenous vein endothelial cells followed by in vitro culture showed decreased cell count and slow proliferation when compared with the fresh endothelial cells (40). With this aspect, reduced endothelial cell proliferation after cryopreservation might be one of the reasons for the lower vessel numbers after XT. However, in this study, angiogenic factor treatment had shown the elevated microvessel density of the cryopreserved OT after grafting, when compared with the XT-Vitri group. Based on these results, we concluded that treatment of angiogenic factor, especially Ang-2 and VEGF co-treatment could compensate the harmful effect of cryopreservation on the grafts and promote their revascularization more effectively so that the cryopreserved graft could have the improved follicle morphology and density.

The Ang-2 and the VEGF have a role in angiogenesis with different ways. VEGF promotes angiogenesis by endothelial cell proliferation and migration (22). Unlike VEGF, Ang-2 is known not to have a mitogenic feature of endothelial cells, whereas, has a role in vessel destabilization to initiate neovascularization and facilitates the activities of other endothelial-acting cytokines like VEGF (23, 24). In accordance with these reports, the Ang-2 treated group showed only slightly increased microvessel density, which had no statistical difference with the XT-Vitri group, because Ang-2 did not have a role in endothelial cell proliferation. Asahara et al. reported that Ang-2 injection to the mouse eye for micropocket assay showed

no significantly increased microvessels, which correspond with our results (41). More increased microvessel density was found in the XT-VEGF group than the XT-Vitri and XT-Ang-2 groups, and there was significant difference between the XT-VEGF and XT-Vitri groups on day 7. It was similar to the previous results of Wang et al. in that the angiogenic effect of VEGF on xenografted human OTs (26). Furthermore, the most increased microvessel density was detected in the XT-Combined group when compared to the XT-Vitri group on both day 7 and 28 like as the study of Asahara et al. in which the modulatory effect of Ang-2 on VEGF-induced neovascularization validated its synergistic effect (41).

Several studies have reported that extensive fibrosis was documented after XT caused by ischemic damage (42, 43). In our study, no significantly differences were evaluated after fibrotic area analysis among the 5 groups. Although there was no statistical difference in fibrosis ratios, which might be due to the lack of OT graft numbers and more experiments are needed, the XT-Vitri group showed the highest ratios of fibrotic area. However, fibrosis was gradually decreased meanwhile microvessel density was gradually increased in angiogenic factor treatment groups on day 7 in the following order: XT-Ang-2, XT-VEGF and XT-combined group. Based on these results, we assumed that enhanced neovascularization by angiogenic factor treatment could reduce the fibrosis of the grafts. The report of Wang et al. which showed significantly decreased fibrosis in the human OT graft after injection of angiogenic factor (VEGF or VEGF and bFGF co-treatment) to the recipients (26) could support the result of our study for the reduced fibrotic area in the angiogenic factor treatment groups. On day 28, only the XT-Vitri group showed the highest fibrosis ratio while the fresh and angiogenic

factor treatment groups represented very low level of fibrosis ratios. Opposite to the fibrosis results, microvessel densities of the angiogenic factor treatment groups were comparably increased to that of the XT-Fresh group on day 28. Therefore, we supposed that the neovascularization was almost completely established and stabilized in the XT-Fresh and the angiogenic factor treatment groups on day 28, whereas the XT-Vitri group had not completed the neovascularization process. This could be explaining the highest fibrosis ratio in the XT-Vitri group and low ratios in the other 4 groups on day 28.

To our knowledge, this is the first study that documents the effect of Ang-2 and/or VEGF on the OT xenografted recipients. Based on the results, administration of the angiogenic factors to the recipient before XT seem to alleviate the ischemic damage via enhancing the angiogenesis and which result in improvement of follicle normality and density, and reduction of fibrosis of the grafts. However, the exact roles and mechanisms of Ang-2 and VEGF in OT grafts should be identified in further studies.

REFERENCES

1. De Vos M, Smitz J, Woodruff TK. Fertility preservation in women with cancer. Lancet 2014;384:1302-10.
2. Tournaye H, Dohle GR, Barratt CL. Fertility preservation in men with cancer. Lancet 2014;384:1295-301.
3. Schmidt KT, Larsen EC, Andersen CY, Andersen AN. Risk of ovarian failure and fertility preserving methods in girls and adolescents with a malignant disease. BJOG : an international journal of obstetrics and gynaecology 2010;117:163-74.
4. S L. Offspring from heterotopic transplantation of newborn mice ovaries. Reproduction in domestic animals = Zuchthygiene 2009.
5. Amorim CA, Curaba M, Van Langendonckt A, Dolmans MM, Donnez J. Vitrification as an alternative means of cryopreserving ovarian tissue. Reprod Biomed Online 2011;23:160-86.
6. Borges EN, Silva RC, Futino DO, Rocha-Junior CM, Amorim CA, Bao SN et al. Cryopreservation of swine ovarian tissue: effect of different cryoprotectants on the structural preservation of preantral follicle oocytes. Cryobiology 2009;59:195-200.
7. Poirot CJ, Martelli H, Genestie C, Golmard JL, Valteau-Couanet D, Helardot P et al. Feasibility of ovarian tissue cryopreservation for prepubertal females with cancer. Pediatric blood & cancer 2007;49:74-8.
8. Macklon KT, Jensen AK, Loft A, Ernst E, Andersen CY. Treatment

history and outcome of 24 deliveries worldwide after autotransplantation of cryopreserved ovarian tissue, including two new Danish deliveries years after autotransplantation. Journal of assisted reproduction and genetics 2014.

9. Liu J, Elst JVd, Broecke RVd, Dhont M. Early massive follicle loss and apoptosis in heterotopically grafted newborn mouse ovaries Human reproduction 2002;17:605-11.

10. Dissen GA, Lara HE, Fahrenbach WH. Immature rat ovaries revascularized rapidly after autotransplantation and show a gonadotrop independent increase in angiogenic factor gene expression. Endocrinology 1994;134:1146-54.

11. Gosden RG, Boulton MI, Grant K, Webb R. Follicular development from ovarian xenografts in SCID mice. J Reprod Fertil 1994;101:619-23.

12. Torrents E, Boiso I, Barri PN, Veiga A. Applications of ovarian tissue transplantation in experimental biology and medicine. Hum Reprod Update 2003;9:471-81.

13. Van Eyck AS, Jordan BF, Gallez B, Heilier JF, Van Langendonckt A, Donnez J. Electron paramagnetic resonance as a tool to evaluate human ovarian tissue reoxygenation after xenografting. Fertility and sterility 2009;92:374-81.

14. Youm HWea, Lee JR, Lee J, Jee BC, Suh CS, Kim SH. Optimal vitrification protocol for mouse ovarian tissue cryopreservation: effect of cryoprotective agents and in vitro culture on vitrified-

warmed ovarian tissue survival. Human reproduction 2014.

15. Teitelbaum AA, Qi X, Osherov AB, Fraser AR, Ladouceur-Wodzak M, Munce N et al. Therapeutic angiogenesis with VEGF164 for facilitation of guidewire crossing in experimental arterial chronic total occlusions. EuroIntervention : journal of EuroPCR in collaboration with the Working Group on Interventional Cardiology of the European Society of Cardiology 2013;8:1081-9.

16. Lucci CM, Kacinskis MA, Lopes LH, Rumpf R, Bao SN. Effect of different cryoprotectants on the structural preservation of follicles in frozen zebu bovine (Bos indicus) ovarian tissue. Theriogenology 2004;61:1101-14.

17. Labied S, Delforge Y, Munaut C, Blacher S, Colige A, Delcombel R et al. Isoform 111 of vascular endothelial growth factor (VEGF111) improves angiogenesis of ovarian tissue xenotransplantation. Transplantation 2013;95:426-33.

18. Wang Y, Chang Q, Sun J, Dang L, Ma W, Hei C et al. Effects of HMG on revascularization and follicular survival in heterotopic autotransplants of mouse ovarian tissue. Reproductive biomedicine online 2012;24:646-53.

19. Schubert B, Canis M, Darcha C, Artonne C, Smitz J, Grizard G. Follicular growth and estradiol follow-up after subcutaneous xenografting of fresh and cryopreserved human ovarian tissue. Fertility and sterility 2008;89:1787-94.

20. Shikanov A, Zhang Z, Xu M, Smith RM, Rajan A, Woodruff TK et al.

Fibrin encapsulation and vascular endothelial growth factor delivery promotes ovarian graft survival in mice. Tissue engineering Part A 2011;17:3095-104.

21. Mahmoodi M, Soleimani Mehranjani M, Shariatzadeh SM, Eimani H, Shahverdi A. Effects of erythropoietin on ischemia, follicular survival, and ovarian function in ovarian grafts. Reproduction 2014;147:733-41.

22. Asahara T, Takahashi T, Masuda H, Kalka C, Chen D, Iwaguro H et al. VEGF contributes to postnatal neovascularization by mobilizing bone marrow-derived endothelial progenitor cells. The EMBO journal 1999;18:3964-72.

23. Gale NW, Thurston G, Hackett SF, Renard R, Wang Q, McClain J et al. Angiopoietin-2 is required for postnatal angiogenesis and lymphatic patterning, and only the latter role is rescued by Angiopoietin-1. Developmental cell 2002;3:411-23.

24. Fiedler U, Reiss Y, Scharpfenecker M, Grunow V, Koidl S, Thurston G et al. Angiopoietin-2 sensitizes endothelial cells to TNF-alpha and has a crucial role in the induction of inflammation. Nature medicine 2006;12:235-9.

25. Hiratsuka S, Minowa O, Kuno J, Noda T, Shibuya M. Flt-1 lacking the tyrosine kinase domain is sufficient for normal development and angiogenesis in mice. Proceedings of the National Academy of Sciences of the United States of America 1998;95:9349-54.

26. Wang L, Ying YF, Ouyang YL, Wang JF, Xu J. VEGF and bFGF

increase survival of xenografted human ovarian tissue in an experimental rabbit model. J Assist Reprod Genet 2013;30:1301-11.

27. Fiedler U, Scharpfenecker M, Koidl S, Hegen A, Grunow V, Schmidt JM et al. The Tie-2 ligand angiopoietin-2 is stored in and rapidly released upon stimulation from endothelial cell Weibel-Palade bodies. Blood 2004;103:4150-6.

28. Trichonas G, Manola A, Morizane Y, Thanos A, Koufomichali X, Papakostas TD et al. A novel nonradioactive method to evaluate vascular barrier breakdown and leakage. Investigative ophthalmology & visual science 2010;51:1677-82.

29. Lundy T, Smith P, O'Connell A, Hudson NL, McNatty KP. Populations of granulosa cells in small follicles of the sheep ovary. Journal of reproduction and fertility 1999.

30. Gavish Z, Peer G, Hadassa R, Yoram C, Meirow D. Follicle activation and 'burn-out' contribute to post-transplantation follicle loss in ovarian tissue grafts: the effect of graft thickness. Human reproduction 2014;29:989-96.

31. Courbiere B, Odagescu V, Baudot A, Massardier J, Mazoyer C, Salle B et al. Cryopreservation of the ovary by vitrification as an alternative to slow-cooling protocols. Fertility and sterility 2006;86:1243-51.

32. Desvignes F, Pouly JL, Janny L, Canis M, Sanfilippo S, Kanold J et al. Cryoconservation of ovarian tissue: indications and outcome of the patients. Gynecologie, obstetrique & fertilite 2014;42:334-42.

33. Hovatta O. Methods for cryopreservation of human ovarian tissue. Reproductive biomedicine online 2005;10:729-34.

34. Visser JA, Themmen AP. Anti-Mullerian hormone and folliculogenesis. Molecular and cellular endocrinology 2005;234:81-6.

35. Li F, Tao Y, Zhang Y, Li Y, Fang F, Liu Y et al. Follicle growth and oocyte development after ovary transplantation into back muscle of immune-intact adult castrated male mice. Reproduction 2010;140:465-76.

36. Amorim CA, Jacobs S, Devireddy RV, Van Langendonckt A, Vanacker J, Jaeger J et al. Successful vitrification and autografting of baboon (Papio anubis) ovarian tissue. Human reproduction 2013;28:2146-56.

37. Herraiz S, Novella-Maestre E, Rodríguez B, Díaz C, Sánchez-Serrano M, Mirabet V et al. Improving ovarian tissue cryopreservation for oncologic patients: slow freezing versus vitrification, effect of different procedures and devices. Fertility and sterility 2014;101:775-84.e1.

38. Wu D, Lei Y, Tong Y, Tang F, Qian Y, Zhou Y. Angiogenesis of the frozen-thawed human fetal ovarian tissue at the early stage after xenotransplantation and the positive effect of Salviae miltiorrhizae. Anatomical record (Hoboken, NJ : 2007) 2010;293:2154-62.

39. Fortune JE, Cushman RA, Wahl CM, Kito S. The primordial to primary follicle transition. Molecular and cellular endocrinology

2000;163:53-60.

40. Bambang LS, Mazzucotelli JP, Moczar M, Beaujean F, Loisance D. Effects of cryopreservation on the proliferation and anticoagulant activity of human saphenous vein endothelial cells. The Journal of thoracic and cardiovascular surgery 1995;110:998-1004.

41. Asahara T, Chen D, Takahashi T, Fujikawa K, Kearney M, Magner M et al. Tie2 receptor ligands, angiopoietin-1 and angiopoietin-2, modulate VEGF-induced postnatal neovascularization. Circ Res 1998;83:233-40.

42. Nisolle M, F C-R, J Q, P M, J D. Histologic and ultrastructural evaluation of fresh and frozen-thawed human ovarian xenografts in nude mice Histologic and ultrastructural evaluation of fresh and frozen-thawed human ovarian xenografts in nude mice. Fertility and sterility 2000.

43. Dath C, Van Eyck AS, Dolmans MM, Romeu L, Delle Vigne L, Donnez J et al. Xenotransplantation of human ovarian tissue to nude mice: comparison between four grafting sites. Hum Reprod 2010;25:1734-43.

국 문 초 록

목적: 여성 암환자를 위한 가임력보존 방법으로 난소조직의 동결과 이식 방법이 이용되고 있고, 최근까지 30명 이상의 출산이 보고되었다. 이러한 성공에도 불구하고, 아직까지 조직의 이식 후 발생하는 허혈성 손상을 방지하는 데에는 많은 어려움이 있다. 허혈성 손상은 이식된 난소조직에서 대량 난포의 손실과 stromal 세포의 파괴를 유발한다. 따라서 허혈성 손상을 줄이기 위해, 허혈 기간은 줄이고 신생혈관 형성은 촉진하는 것이 중요하다. 이 연구의 목적은 소의 난소조직을 nude mouse에 이종 이식한 뒤, 혈관형성 인자인 angiopoietin-2 (Ang-2)와 vascular endothelial growth factor (VEGF)을 처리하여 혈관형성 인자가 이식 후 난소조직에 미치는 영향을 평가하고자 한다.

방법: 도축장에서 얻은 소 난소 6개는, 2시간 이내에 연구실로 이동하였다. 난소조직의 피질은 분리하여 5 x 5 x 1 mm^3 크기의 조각으로 자른 후 자른 난소조직의 일부는 신선한 상태로 남겨두고, 다른 일부는 유리화동결 한다. 소 난소의 이종이식을 위하여, 9주령 BALB/c nude mouse 30 마리로부터 생쥐 자신의 난소를 제거하고 소의 난소를 등 부위의 피하에 이식한다. 이때 신선한 난소를 이식하는 군을 XT-Fresh로 구분하고, 나머지 4개의 군에는 유리화동결 후 해동한 소의 난소조직을 이식한다. 또한 동결-해동 난소 이식 전 18시간과 30분에

복강으로 saline을 주사한 군은 XT-Vitri, 500 ng의 Ang-2를 주입한 군은 XT-Ang-2, 200 ng의 VEGF를 처리한 군은 XT-VEGF, 500 ng의 Ang-2와 200 ng의 VEGF를 함께 처리한 군은 XT-Combined로 분류한다. 소의 난소 조직은 이식 후 7일 또는 28일에 적출하여 이식 난소조직에서 난포의 정상 여부, 난포의 밀도, 미세혈관의 수, 섬유화 정도 등을 각각 조직학적 평가방법과, CD31 면역 염색, Masson's trichrome 염색법으로 평가한다.

결과: 이식조직에서 형태학적으로 정상인 원시난포의 비율은 이식 후 7일과 28일 모두 성장인자를 처리한 3군에서 XT-Vitri군보다 높았다. 성장난포의 정상비율 또한 이식 후 7일에 성장인자 처리군에서 유의하게 증가하였다. 이식 후 28일째, 성장난포의 정상비율은 XT-VEGF군과 XT-Combined군에서 XT-Vitri군보다 유의하게 증가되었다. 원시난포의 밀도는 이식 후 7일째 XT-Combined군에서 XT-Fresh군과 비슷한 정도로 잘 보존되었다. 혈관형성인자를 처리한 3개 군에서는 이식 후 28일째 성장난포의 평균 난포수가 XT-Fresh군의 수준으로 유의하게 증가하였다. 미세혈관의 밀도는 이식 후 7일과 28일 모두 XT-Combined군이 가장 높았다. 난소조직의 섬유화 비율은 이식 후 7일과 28일째 XT-Vitri군에서 가장 높았으나 이식군 간 유의한 차이는 보이지 않았다.

결론: 본 연구에서는 난소조직에 혈관형성인자를 처리한 군, 특히 XT-Combined군에서 잘 보존된 원시난포 및 성장난포와 확연히 개선된 미세혈관의 밀도를 확인하였다. 따라서 혈관형성인자의 처리가 난소조직 이식결과에 유익한 효과를 줄 수 있을 것이라 사료되며, 이는 이식 후 초반의 허혈성 손상을 극복하는데 도움을 줄 수 있을 것으로 사료된다. 하지만 Ang-2와 VEGF가 이식된 난소조직에 미치는 정확한 역할과 기전을 확립하기 위해 더 많은 연구가 필요하다.

주요어: 난소 조직 / 이종 이식 / 유리화동결 / 신혈관형성 / 가임력 보존

학 번: 2013-21717