의학 석사 학위 논문

The significance of TOF MRA as non-invasive imaging of intraplaque hemorrhage in patients with acute symptomatic carotid disease

급성 증상성 경동맥 질환 환자에서 비침습적으로 판내 출혈을 확인할 수 있는 TOF MRA 영상의 중요성

2015년 2월

서울대학교 대학원

의학과 뇌신경과학 전공

곽 동 석

급성 증상성 경동맥 질환 환자에서 비침습적으로 판내 출혈을

확인할 수 있는 TOF MRA 영상의 중요성

The significance of TOF MRA as non-invasive imaging of intraplaque hemorrhage in patients with acute symptomatic carotid disease

지도교수 한문구

이 논문을 의학석사 학위논문으로 제출함.

2014년 12월

서울대학교 대학원

의학과 뇌신경과학 전공

곽동석

곽동석의 석사학위논문을 인준함

2014년 12월

위원장 김상윤 (인)

부위원장 한문구 (인)

위원 권오기 (인)

Abstract

Carotid intraplaque hemorrhage (IPH) is well known for a risk factor of ischemic stroke. In patient with hyperacute stage of symptomatic carotid stenosis, Time of flight (TOF) MR angiography (MRA) can screen carotid disease rapidly in addition to taking routine MRI. Using TOF MRA, we evaluated carotid IPH, and we also examined associated stroke patterns and clinical outcomes. We reviewed 59 patients who had symptomatic carotid artery disease detected by TOF MRA. They visited SNUBH within 12 hours of stroke symptom onset. Patients were assigned to those who had IPH or had not on TOF MRA. The degree of carotid stenosis was evaluated according to the NASCET criteria. Diffusion weighted imaging (DWI) MRI lesion patterns were classified as (1) large territorial infarction, (2) disseminated small infarction, and (3) border-zone infarction. Also, we observed early neurological deterioration (END) and clinical outcomes (recurrence of stroke, myocardial infarction, or death from any cause) at 3 months and 1 year. IPH was detected in 28.8% of total enrolled patients (17/59). The patients with mild to moderate symptomatic carotid stenosis are more in the IPH positive group (70.6%) than the IPH negative group (42.8%). The patients with the IPH positive group more frequently demonstrated disseminated small infarction pattern (76.5% in the IPH(+) group, 47.6% in the IPH(-) group), and less frequently showed border-zone infarction pattern (0% in the IPH(+) group, 16.7% in the IPH(-) group) than the patients with the IPH negative

group. END and clinical outcomes at 3 months were not different between the two groups. In conclusion, the patients with IPH positive group are more likely to cause symptomatic stroke than IPH negative group even if they have smaller degree of carotid stenosis. TOF MRA can detect this stenosis in the hyperacute stage, so it is possible to determine the mechanism of stroke and establish treatment plan early with this method. And our results suggest that disseminated small infarction pattern is more frequent in the IPH positive group than the IPH negative group, and border-zone infarct pattern is less specific for the IPH positive group. Clinical outcomes were similar in both two groups.

Key words: Carotid intraplaque hemorrhage, Time-Of-Flight sequence, Infarct pattern.

Student Number : 2013-21719

Introduction

Extracranial carotid stenosis is a major risk factor of ischemic stroke.[1] It accounts for 20 to 30% of causes of ischemic stroke. However, around 70 to 80% of symptomatic patients with 50% or more carotid stenosis will not recur ipsilateral stroke at 5 years.[2] So, carotid disease should not be evaluated on the basis of degree of stenosis alone. Not only degree of stenosis, but also vulnerability of carotid plaque causes a subsequent stroke event.[3-5] Vulnerable plaque is characterized by lipid rich necrotic core, thin fibrous cap, and remarkably, intraplaque hemorrhage (IPH).[6, 7] IPH induces growth of lipid rich necrotic core and destabilizes atherosclerotic plaque.[8] And carotid IPH is highly associated with recurrent ischemic symptoms.[9]

Carotid IPH can be measured by variable methods such as high-resolution multicontrast MRI, Time-Of-Flight MRA (TOF MRA), and duplex sonography. Among these methods, TOF MRA image evaluate carotid IPH rapidly without any additional sequence of MRI. IPH seems high signal intensity around the carotid artery on this technique, so can be detected straightforwardly. TOF MRA also detects IPH noninvasively and accurately compared with high-resolution multicontrast MRI.[10] Because of these advantages of TOF MRA sequence, it is a suitable method for evaluating acute stage of ischemic stroke. It can help to determine the mechanism of stroke by elucidating relevant carotid artery stenosis and establish treatment

plan early.

Carotid IPH is estimated to be a risk factor of ischemic stroke, but its influence on the development of specific stroke patterns is unclear. Also, there is limited evidence of clinical outcomes of stroke in patients with carotid IPH,[11] especially acute stage of index stroke event. Using TOF MRA method, we evaluate carotid IPH and its association of stroke patterns and clinical outcomes.

Methods

Subjects

We retrospectively analyzed 4907 ischemic stroke patients who were admitted to the Seoul National University Bundang Hospital between April 2006 and July 2012, from institutional stroke registry. Among them, we selected 59 patients who visited our hospital within 12 hours of symptom onset, had symptomatic carotid artery disease, and took Brain MRI with TOF MRA sequence. Symptomatic carotid disease means carotid plaque which causes focal neurologic symptoms like ipsilateral transient ischemic attacks or ipsilateral hemispheric stroke. Patients who had cardioembolic source such as atrial fibrillation were excluded, because the possible etiologies of stroke of these patients were two or more. We also excluded patients who underwent endovascular treatment before taking diffusion weighted MRI, which could influence the infarct patterns. Baseline demographic and clinical information including age, sex, body mass index, hypertension, diabetes, dyslipidemia, atrial fibrillation, smoking history, previous stroke history, previous medication history including antiplatelet agents and statins, statin use on admission, and baseline National Institutes of Health Stroke Scale (NIHSS) score were gathered from the stroke registry. Laboratory data such as fasting blood glucose (FBS), glycated hemoglobin (HbA1c), Total cholesterol (TC), triglyceride (TG), high density lipoprotein (HDL), and low density lipoprotein

(LDL) were also collected. Patients who were treated with intravenous or intra-arterial thrombolysis were checked. We also collected data on early neurological deterioration (END). END is defined as to fulfill at least one of the following four criteria[12, 13]: (1) worsening of 2 or more points in the total NIHSS score, (2) worsening of 1 or more point in the LOC items of the NIHSS score, (3) worsening of 1 or more point in the motor items of the NIHSS score, and (4) any new neurological symptoms during admission. It could be caused by stroke recurrence, stroke progression, symptomatic hemorrhagic transformation, other medical conditions like pulmonary embolism, deep vein thrombosis. Clinical outcomes consist of stroke recurrence, myocardial infarct, and death was gathered at 3 months and 1 year later after the index stroke.

Analysis of carotid disease

Carotid IPH and degree of stenosis of carotid artery were measured by neurologist. The patients who showed high signal intensity halo around the carotid artery on the TOF MRA image were classified as IPH positive group, whereas the patients who did not were classified as IPH negative group.[10] (Figure 1) Carotid stenosis on the TOF MRA or conventional angiography was evaluated according to the North american symptomatic carotid endarterectomy trial (NASCET) criteria.[2] The severity of carotid stenosis was

divided into four categories: mild (less than 50% of stenosis), moderate (50 to 69% of stenosis), severe (70 to 99% of stenosis), and occlusion (100% of stenosis).

Analysis of infarct patterns

We review the patterns of DWI lesions. Infarct lesions were classified as three patterns based on lesion size, location, and distribution: large territorial lesion, disseminated small lesions, border zone infarction. (Figure 2) Large territorial lesion is defined as wedge-shaped lesion involving the cerebral cortex and subcortex. Disseminated small lesions are randomly scattered in the distal MCA or ACA territory. Border zone infarction represents lesions mainly located between the territories of two major cerebral arteries. This infarct pattern consists of anterior cortical (between the MCA and ACA) or posterior cortical (between the MCA and PCA) or internal border zone (between the superficial and deep arterial systems).

Statistical Analysis

Data were summarized as number (%), mean ± standard deviation (SD). To compare the baseline characteristics between the IPH positive and negative groups, chi-square test or Fisher's exact test was used for parametric

variables, Mann Whitney U test for non-parametric variables, and student's t-test for continuous variables. The chi-square test was used to find the relationship between IPH and incidence of infarct patterns, END, clinical outcomes at 3 months, 1 year. Imbalanced variables in bivariate analysis ($P<0.10$) were adjusted in the logistic regression model to eliminate the effects of confounding. A value of two-tailed $P<0.05$ was considered as statistically significant, and all the statistical analyses were made with SPSS for Windows, version 18.0.

Results

Patient Characteristics

A total of 59 patients with symptomatic carotid disease were enrolled in this study. There were 45 men (76.3%) and 14 women (23.7%). The mean age was 70.9 ±11.4 years-old. The interval time between onset of stroke and arrival of hospital is 4.10 ± 3.38 hours.

At TOF MRA imaging, 17 patients (28.8%) demonstrated high signal intensity halo sign on the proximal part of the internal carotid artery and those were classified as the IPH positive group (Figure 1), and the other 42 patients (71.2%) who did not show HSI halo sign on the proximal part of the ICA were classified as the IPH negative group. Baseline characteristics of both groups are compared at table 1. The previous history of stroke was less prevalent in the IPH positive group (5.9%) than the IPH negative group (31.0%) (p=0.048) Other characteristics including cerebrovascular risk factors, initial laboratory data, the proportion of patients who treated with IV or IA thrombolysis, history of medication use were not significantly different between the two groups.

Analysis of carotid disease

Table 2 showed the degree of carotid stenosis of IPH positive and

negative group. The IPH positive group had lower degree of carotid stenosis compared with the IPH negative group (0.025). Mild to moderate symptomatic carotid stenosis in the IPH positive group is 70.6% (12/17) and the IPH negative group is 42.8% (18/42).

Infarct Pattern

Table 3 showed the different patterns of infarct on DWI between the IPH positive and negative group. More disseminated small infarct patterns (odds ratio [OR]: 3.58, 95% confidence interval [CI]: 1.00-12.78; p=0.043) were seen in the IPH positive group than the IPH negative group. The IPH positive group less frequently demonstrated border-zone infarction pattern than the IPH negative group (0% vs. 16.7%). The large territorial lesion pattern was not different between the two groups (OR: 0.55, CI: 0.15-2.00; p=0.364).

Clinical Outcomes

Table 4 shows clinical outcomes of the IPH positive and negative group. 15 of 59 (25.9%) patients experienced END during admission. Among them, 5 patients were the IPH positive group (2 patients experienced stroke recurrence, 2 patients experienced stroke progression, and the other 1 patient

experienced symptomatic hemorrhagic transformation (HT)). The other 10 patients were the IPH negative group (6 patients experienced stroke recurrence, 3 patients experienced stroke progression, and the other 1 patient experienced symptomatic HT). The occurrence of END was similar between the two groups (OR: 1.29, CI: 0.37-4.60, p=0.747). After adjusting the imbalanced variables that showed p<0.10 in bivariate analysis, there also was no significance difference between the two groups (Adjusted OR: 1.45, CI: 0.25-8.36, p=0.676).

Clinical outcomes such as stroke recurrence, myocardial infarct, death at 3 months from index stroke were detected in 2 of 17 (11.8%) in the IPH positive group (2 patients experienced stroke recurrence), as compared with 2 of 42 (4.8%) in the IPH negative group (1 patient experienced stroke recurrence, and the other was dead). There was no statistically significant difference between the two groups (OR: 2.67, CI: 0.34-20.67, p=0.571). And the adjusted value showed also no statistically significant difference between the two groups (Adjusted OR: 1.86, CI: 0.20-17.66, p=0.588).

Clinical outcomes at 1 year from index stroke were detected in 1 of 17 (5.9%) in the IPH positive group (1 patient experienced stroke recurrence), as compared with 2 of 42 (4.8%) in the IPH negative group (1 patient experienced stroke recurrence, and the other was dead). There was no statistically significant difference between the two groups (OR: 1.25, CI: 0.11-14.77, p=1.000). And the adjusted value showed also no statistically

significant difference between the two groups (Adjusted OR: 1.13, CI: 0.05-23.61, p=0.937).

Discussion

In this study, we used TOF MRA sequence to evaluate the carotid IPH. As mentioned above this method has several advantages for evaluating hyperacute stage of stroke patients in that it can detect IPH easily, fast, and noninvasively. If carotid IPH of patient with mild to moderate degree of symptomatic carotid stenosis is detected early using TOF MRA, then it is possible to determine the etiology of stroke (artery to artery thromboembolism from carotid artery) and establish treatment plan early with this method.

We found that the carotid IPH may influence the infarct patterns of the patients with symptomatic carotid disease. The patients with carotid IPH were more likely to have disseminated small infarct patterns. Because multiple small disseminated lesions are caused by the fragmentation of thrombi or multiple emboli,[14] we could deduce that carotid plaque with IPH have a tendency to produce more microthromi than other characteristics of carotid plaque. The patient without carotid IPH tended to have border-zone infarction patterns, but careful attention is required to apply this result to clinical situation, because the degree of carotid stenosis can be a potential confounder.[15, 16]

As the carotid IPH is vulnerable to plaque rupture[8, 17], we hypothesized that the IPH positive group would experience more cerebrovascular events than the IPH negative group in the early and late stage

of stroke, especially mild to moderate degree of carotid stenosis. Previous reports supported our hypothesis,[9, 11, 18] but had several limitations because of poor methodological qualities and bias. So, we rechecked clinical outcomes. Contrary to the result of previous reports[9, 11, 18], ours did not satisfy the study hypothesis. Because of small sample size and limited study design, we cannot rule out our initial thoughts and further well-designed studies might be required to elucidate whether the carotid IPH is a strong predictor for recurrent cerebrovascular event or not.

Our study has some limitations. This is a retrospective observational study that is susceptible to bias in data collection and analysis. And this study design cannot prove causal relationship among variables, although it is possible to show some associations among them. Confounding variables which can adversely affect the relation between the independent variable and dependent variable may be existent. For example, because both carotid IPH and ulcerative plaque raise plaque rupture risk, the etiology of stroke in patient who have symptomatic carotid IPH and ulcerative plaque is undetermined. We did not adjust such variables. And if the degree of carotid stenosis is mild or the IPH is not made recently, the halo sign of carotid IPH could be false negative.[19] This is another limitation of this study.

In summary, our study demonstrated that TOF MRA sequence is a significant method to evaluate IPH in patients with acute symptomatic carotid disease. And we also observed that the IPH positive and negative groups

might have different infarct patterns. Small infarction pattern was more frequent in the IPH positive group than the IPH negative group, which suggested the IPH could have tendency to produce more microthrombi than other characteristics of plaque. Clinical outcomes were not significantly different in both two groups. But further well-designed clinical studies are needed to evaluate the relationship between the presence of the carotid IPH and Clinical outcomes.

References

1. Sacco RL. Clinical practice. Extracranial carotid stenosis. *The New England journal of medicine*. 2001;345:1113-1118
2. Barnett HJ, Taylor DW, Eliasziw M, Fox AJ, Ferguson GG, Haynes RB, et al. Benefit of carotid endarterectomy in patients with symptomatic moderate or severe stenosis. North american symptomatic carotid endarterectomy trial collaborators. *The New England journal of medicine*. 1998;339:1415-1425
3. Barnett HJ, Eliasziw M, Meldrum H. Plaque morphology as a risk factor for stroke. *JAMA : the journal of the American Medical Association*. 2000;284:177
4. Mathiesen EB, Bonaa KH, Joakimsen O. Echolucent plaques are associated with high risk of ischemic cerebrovascular events in carotid stenosis: The tromso study. *Circulation*. 2001;103:2171-2175
5. Polak JF, Shemanski L, O'Leary DH, Lefkowitz D, Price TR, Savage PJ, et al. Hypoechoic plaque at us of the carotid artery: An independent risk factor for incident stroke in adults aged 65 years or older. Cardiovascular health study. *Radiology*. 1998;208:649-654
6. Falk E. Morphologic features of unstable atherothrombotic plaques underlying acute coronary syndromes. *The American journal of cardiology*. 1989;63:114E-120E
7. Kolodgie FD, Gold HK, Burke AP, Fowler DR, Kruth HS, Weber DK,

et al. Intraplaque hemorrhage and progression of coronary atheroma. *The New England journal of medicine*. 2003;349:2316-2325

8. Michel JB, Virmani R, Arbustini E, Pasterkamp G. Intraplaque haemorrhages as the trigger of plaque vulnerability. *European heart journal*. 2011;32:1977-1985, 1985a, 1985b, 1985c

9. Altaf N, MacSweeney ST, Gladman J, Auer DP. Carotid intraplaque hemorrhage predicts recurrent symptoms in patients with high-grade carotid stenosis. *Stroke*. 2007;38:1633-1635

10. Yim YJ, Choe YH, Ko Y, Kim ST, Kim KH, Jeon P, et al. High signal intensity halo around the carotid artery on maximum intensity projection images of time-of-flight mr angiography: A new sign for intraplaque hemorrhage. *Journal of magnetic resonance imaging : JMRI*. 2008;27:1341-1346

11. Gao P, Chen ZQ, Bao YH, Jiao LQ, Ling F. Correlation between carotid intraplaque hemorrhage and clinical symptoms: Systematic review of observational studies. *Stroke*. 2007;38:2382-2390

12. Hong KS, Kang DW, Koo JS, Yu KH, Han MK, Cho YJ, et al. Impact of neurological and medical complications on 3-month outcomes in acute ischaemic stroke. *European journal of neurology : the official journal of the European Federation of Neurological Societies*. 2008;15:1324-1331

13. Weimar C, Mieck T, Buchthal J, Ehrenfeld CE, Schmid E, Diener HC, et al. Neurologic worsening during the acute phase of ischemic stroke.

Archives of neurology. 2005;62:393-397

14. Roh JK, Kang DW, Lee SH, Yoon BW, Chang KH. Significance of acute multiple brain infarction on diffusion-weighted imaging. *Stroke*. 2000;31:688-694

15. Bogousslavsky J, Regli F. Borderzone infarctions distal to internal carotid artery occlusion: Prognostic implications. *Annals of neurology*. 1986;20:346-350

16. Del Sette M, Eliasziw M, Streifler JY, Hachinski VC, Fox AJ, Barnett HJ. Internal borderzone infarction: A marker for severe stenosis in patients with symptomatic internal carotid artery disease. For the north american symptomatic carotid endarterectomy (nascet) group. *Stroke*. 2000;31:631-636

17. Virmani R, Kolodgie FD, Burke AP, Finn AV, Gold HK, Tulenko TN, et al. Atherosclerotic plaque progression and vulnerability to rupture: Angiogenesis as a source of intraplaque hemorrhage. *Arteriosclerosis, thrombosis, and vascular biology*. 2005;25:2054-2061

18. Hosseini AA, Kandiyil N, Macsweeney ST, Altaf N, Auer DP. Carotid plaque hemorrhage on magnetic resonance imaging strongly predicts recurrent ischemia and stroke. *Annals of neurology*. 2013;73:774-784

19. Yamada K, Song Y, Hippe DS, Sun J, Dong L, Xu D, et al. Quantitative evaluation of high intensity signal on mip images of carotid atherosclerotic plaques from routine tof-mra reveals elevated volumes of intraplaque hemorrhage and lipid rich necrotic core.

Journal of cardiovascular magnetic resonance : official journal of the Society for Cardiovascular Magnetic Resonance. 2012;14:81

Table 1. Baseline characteristics

Variable	Total (N=59)	IPH(+) (N=17)	IPH(-) (N=42)	P-value
Male, n (%)	45 (76.3%)	14 (82.4%)	31 (73.8%)	0.737
Mean age (years±SD)	70.9±11.4	73.9±12.7	69.6±10.7	0.197
BMI(kg/m^2±SD)	23.0±3.1	23.1±3.3	22.9±3.0	0.770
Interval from onset to presentation (hour±SD)	4.10±3.38	3.73±3.50	4.25±3.37	0.498
Within 3hr, n (%)	28 (47.5%)	9 (52.9%)	19 (45.2%)	0.931
3-6hr, n (%)	14 (23.7%)	4 (23.5%)	10 (23.8%)	
6-12hr, n (%)	17 (28.8%)	4 (23.5%)	13 (31.0%)	
Initial NIHSS (mean±SD)	4.29± 4.33	4.00±4.39	4.40±4.36	0.794
Concomitant disease, n (%)				
History of stroke	14 (23.7%)	1 (5.9%)	13 (31.0%)	0.048*
Hypertension	47 (79.7%)	16 (94.1%)	31 (73.8%)	0.150
Diabetes mellitus	18 (30.5%)	7 (41.2%)	11 (26.2%)	0.350
Hyperlipidemia	18 (30.5%)	5 (29.4%)	13 (31.0%)	1.000
Smoking	26 (44.1%)	6 (35.3%)	20 (47.6%)	0.563
Atrial fibrillation	0 (0%)	0 (0%)	0 (0%)	-
Thrombolysis, n (%)	12 (20.3%)	3 (17.6%)	9 (21.4%)	1.000
IV	6 (10.2%)	2 (11.7%)	4 (9.5%)	
IA	4 (6.8%)	0 (0%)	4 (9.5%)	

IV+IA	2 (3.4%)	1 (5.9%)	1 (2.4%)	
Laboratory data				
FBS (mg/dl±SD)	111.4±39.6	117.5±37.3	108.9±40.6	0.162
HbA1c (%±SD)	6.4±1.7	6.95±2.64	6.18±1.10	0.435
Total Cholesterol (mg/dl±SD)	180.4±51.0	171.7±42.3	184.0±54.1	0.405
TG (mg/dl±SD)	121.3±65.6	111.2±64.1	125.4±66.6	0.186
HDL (mg/dl±SD)	44.3±13.2	45.6±13.3	43.8±13.2	0.446
LDL (mg/dl±SD)	111.8±44.7	103.8±33.6	115.1±48.5	0.386
Previous statin use, n (%)	12 (20.3%)	3 (17.6%)	9 (21.4%)	1.000
Antiplatelet drug use (Initial), n (%)				0.396
Aspirin	12 (20.3%)	3 (17.6%)	9 (21.4%)	
Plavix	0 (0%)	0 (0%)	0 (0%)	
Aspirin + Plavix	46 (78.0%)	13 (76.5%)	33 (78.6%)	
Others	1 (1.7%)	1 (5.9%)	0 (0%)	
Statin use on admission. n (%)	55 (93.2%)	14 (82.4%)	41 (97.6%)	0.068*
Intervention within 1 year, n (%)	31 (52.5%)	8 (47.1%)	23 (54.8%)	0.774

Values are presented as mean±standard deviation for continuous variables or as number (%) of subjects for categorical variables.

P-values were calculated by Pearson chi-square test, Fisher's exact test, Whitney Mann U test and Student's t-test according to variable's characteristics

Abbreviation: IPH, intraplaque hemorrhage; BMI, body mass index; IV, intravenous; IA, intra-arterial; FBS, fasting blood glucose; HbA1c, glycated hemoglobin; TG, triglyceride; HDL, high density lipoprotein; LDL, low density lipoprotein

Table 2. Degree of stenosis of carotid artery in the IPH positive or negative group.

Variable	Total (N=59)	IPH(+) (N=17)	IPH(-) (N=42)	P-value
Degree of carotid stenosis, n (%)				0.025*
Mild	14 (23.7%)	4 (23.5%)	10 (23.8%)	
Moderate	16 (27.1%)	8 (47.1%)	8 (19.0%)	
Severe	15 (25.4%)	5 (29.4%)	10 (23.8%)	
Occlusion	14 (23.7%)	0 (0%)	14 (33.3%)	

Values are presented as number (%), P-values were calculated by Fisher's exact test

Table 3. Infarct pattern

Variable	Total (N=59)	IPH(+) (N=17)	IPH(-) (N=42)	OR (95% CI)	P value
Large territorial lesion	19 (32.2%)	4 (23.5%)	15 (35.7%)	0.55 (0.15-2.00)	0.364
Disseminated small lesions	33 (55.9%)	13(76.5%)	20 (47.6%)	3.58 (1.00-12.78)	0.043
Border zone infarction	7 (11.9%)	0 (0%)	7 (16.7%)	-	-

P-values were calculated by Pearson chi-square test, Fisher's exact test according to variable's characteristics

Odds ratio for IPH positive group over IPH negative group.

Table 4. Clinical outcomes.

Variable	Total (N=59)	IPH(+) (N=17)	IPH(-) (N=42)	OR unadjusted (95% CI)	OR adjusted (95% CI)	P-value
END	15 (25.9%)	5 (29.4%)	10 (24.4%)	1.29 (0.37-4.60)	1.45 (0.25-8.36)	0.747
Stroke recur	8 (13.6%)	2 (11.8%)	6 (14.3%)			
Stroke progression	5 (8.5%)	2 (11.8%)	3 (7.1%)			
Symptomatic HT	2 (3.4%)	1 (5.9%)	1 (2.4%)			
Clinical outcome at 3mo	4 (6.8%)	2 (11.8%)	2 (4.8%)	2.67 (0.34-20.67)	1.86 (0.20-17.66)	0.571
Stroke recur	3 (5.1%)	2 (11.8%)	1 (2.4%)			
MI	0 (0%)	0 (0%)	0 (0%)			
Vascular deaths	1 (1.7%)	0 (0%)	1 (2.4%)			
Clinical outcome at 1yr	3 (5.1%)	1 (5.9%)	2 (4.8%)	1.25 (0.11-14.77)	1.13 (0.05-23.61)	1.000
Stroke recur	2 (3.4%)	1 (5.9%)	1 (2.4%)			
MI	0 (0%)	0 (0%)	0 (0%)			
Vascular deaths	1 (1.7%)	0 (0%)	1 (2.4%)			

P-values were calculated by Pearson chi-square test, Fisher's exact test according to variable's characteristics

Odds ratio for IPH positive group over IPH negative group.

Imbalanced variables in bivariate analysis (P<0.10) including previous stroke history, statin use on admission, and degree of carotid stenosis were adjusted.

Abbreviation: END, early neurological deterioration; HT, hemorrhagic transformation; MI, myocardial infarction

Figure Legends

Figure 1.

TOF MRA images of the carotid arteries. Intraplaque hemorrhage showed high signal intensity halo around the proximal portion of the left internal carotid artery (white arrows).

Figure 2.

Three patterns of infarct on DWI. A. Large territorial lesion. B. Disseminated small lesions. C. Border zone infarction

Figure 1.

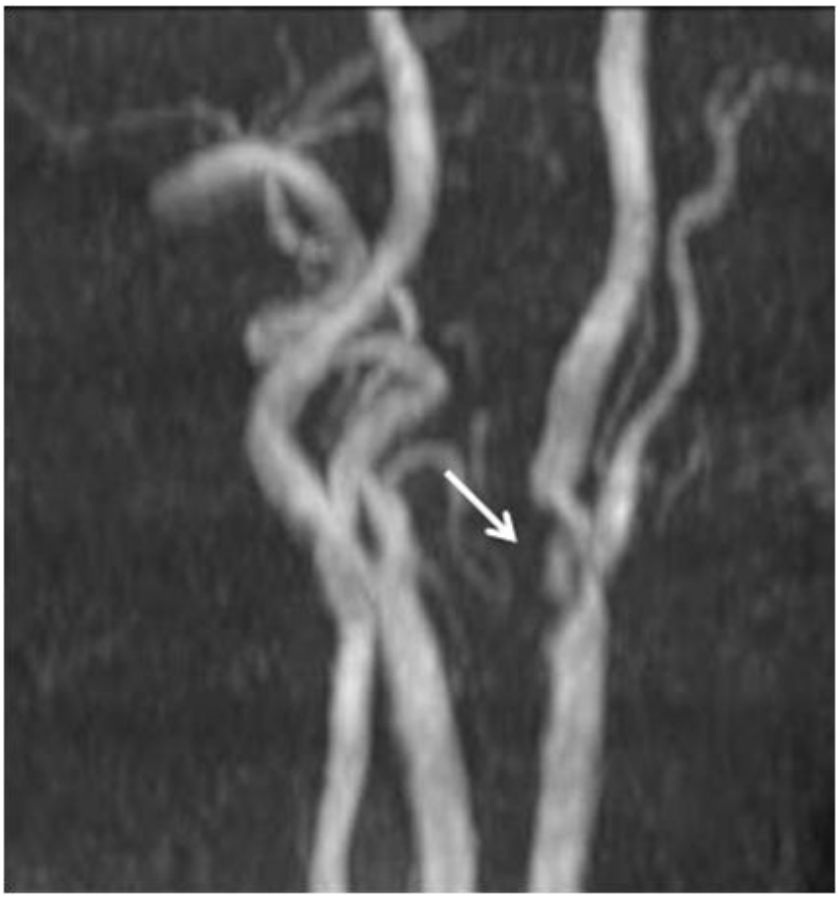

Figure 2.

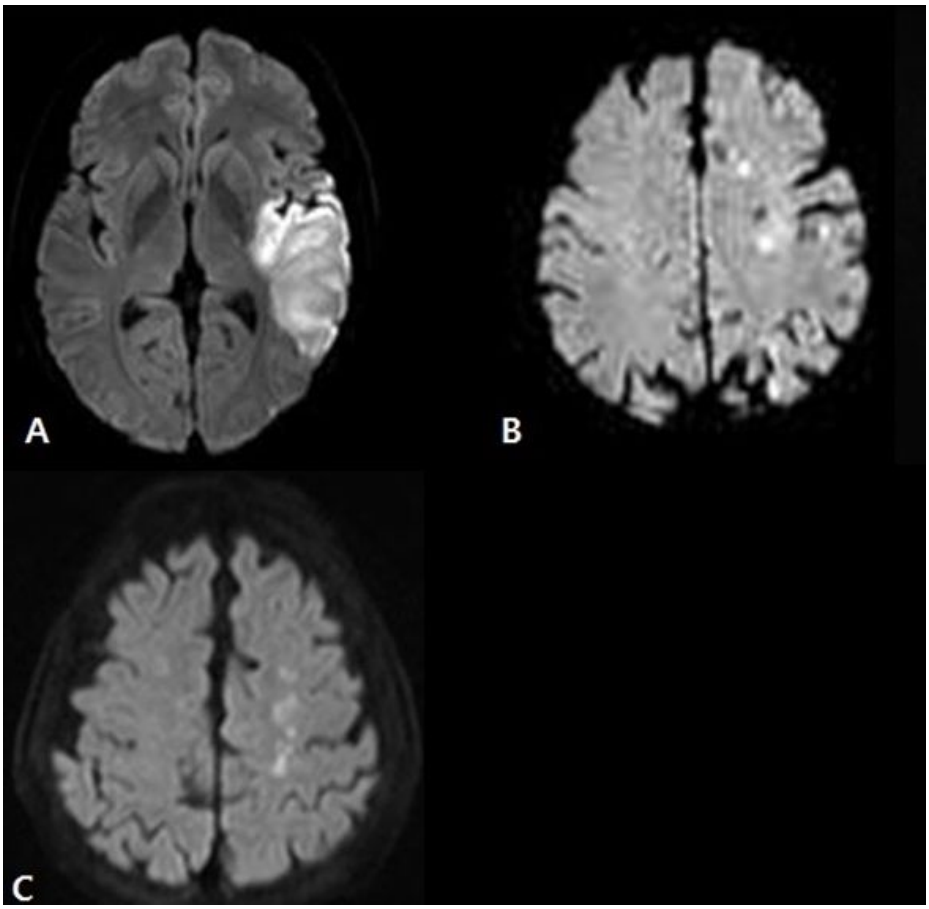

국문초록

경동맥의 판내 출혈은 허혈뇌졸중의 잘 알려진 위험인자이다. 증상성 경동맥 질환을 가진 초급성기 뇌졸중 환자에서 TOF 자기공명혈관조영술은 기존 자기공명영상검사 촬영에 추가하여 경동맥 질환을 빠르게 평가할 수 있는 방법이다. 이 연구에서는 TOF 자기공명혈관조영술을 이용하여 경동맥 판내 출혈에 대해 평가하였고, 이와 연관된 뇌경색 양상 및 그 임상적인 결과에 대해 알아보고자 하였다. 내원하여 TOF 자기공명 혈관조영술을 한 59 명의 증상성 경동맥 환자를 대상으로 하였고, 뇌경색 증상으로부터 12 시간 내에 내원한 환자를 등록하였다. 경동맥의 협착 정도는 NASCET 기준에 따라 측정되었다. 뇌자기공명영상 확산계수영상에서 보인 뇌경색 양상은 다음과 같이 분류하였다. (1) 큰 동맥영역을 침범하는 뇌경색, (2) 여러 군데 흩어진 작은 병변들, (3) 혈관의 경계영역 병변. 또한 결과변수로 초기 신경학적 악화와 뇌경색이 있은 후로 3 개월 및 1 년 후의 임상적인 결과 (뇌졸중의 재발, 심근경색, 또는 사망)를 살펴보았다. 판내 출혈은 총 환자의 28.8%에서 관찰되었다. 판내 출혈이 관찰된 환자 중 경도 또는 중등도 경동맥 협착이 동반된 환자의 비율은 70.6%로 그렇지 않은 환자의 42.8%보다 높았다. 판내 출혈이

관찰된 환자는 그렇지 않은 환자에 비해 여러 군데 흩어진 작은 병변들이 더 흔하게 관찰되었다. (76.5% 대 16.7%) 초기 신경학적 악화 및 3 개월 및 1 년 후 임상적인 결과는 모두 양 군에서 차이가 없었다. 결론적으로, 경동맥의 판내 출혈 양성인 환자는 음성인 환자에 비해 경동맥 협착 정도가 작아도 뇌경색을 유발시키는 경향성을 가지며, 이를 급성기 TOF 자기공명혈관조영술을 통하여 일찍 발견할 수 있다. 아울러 그 뇌경색 양상이 여러 군데 흩어진 작은 병변들 형태가 많으며, 이는 판내 출혈이 죽상경화판을 불안정화시켜 작은 혈전색전증을 잘 유발시킬 가능성이 있다.

주요어: 판내 출혈, TOF, 뇌경색 패턴.

학 번: 2013-21719