



ORIGINAL RESEARCH

# Clinical Factors Affecting the Effectiveness of 1550-nm Erbium-Doped Fractional Photothermolysis Laser for Individual Atrophic Acne Scar Types

Soo Ran Lee · Soyun Cho

Received: November 27, 2022 / Accepted: December 29, 2022  
© The Author(s) 2023

## ABSTRACT

**Introduction:** Although non-ablative fractional resurfacing is frequently used for atrophic acne scars, few studies have examined clinical factors affecting the effectiveness of non-ablative fractional laser in individual atrophic acne scar types (icepick, rolling, and boxcar scars). Herein, we evaluated the clinical factors affecting the effect of non-ablative fractional laser for individual atrophic acne scar types using objective assessment tools.

**Methods:** Thirty-one patients who had been treated by 1550-nm erbium-doped fractional laser for atrophic acne scars were retrospectively reviewed. Icepick, rolling, and boxcar scars were counted using photographs, and acne scar

reduction efficiency (ASRE%; the percentage reduction of post-acne scar count from baseline counts) was calculated.

**Results:** The median count of each scar type was significantly reduced at the end of the final session. Boxcar scars responded better (median ASRE 59.2%) than rolling (ASRE 40.6%,  $p = 0.017$ ) and icepick scars (ASRE 19.1%,  $p = 0.010$ ). Concomitant isotretinoin use resulted in a greater ASRE and a significantly greater improvement in icepick scars. Patients aged 25 years or younger showed a higher ASRE, with a greater improvement in boxcar scars.

**Conclusion:** 1550-nm fractional laser treatment for atrophic acne scars was more effective in patients who were younger and taking isotretinoin concurrently.

**Keywords:** 1550-nm erbium-doped fractional laser; Atrophic acne scar; Boxcar scar; Rolling scar; Icepick scar; Isotretinoin; Age

---

S. R. Lee · S. Cho (✉)  
Department of Dermatology, Seoul Metropolitan  
Government-Seoul National University Boramae  
Medical Center, 20 Boramae Road 5-gil, Dongjak-gu,  
Seoul 07061, South Korea  
e-mail: sycho@snu.ac.kr; vickycho@hanmail.net

S. R. Lee  
e-mail: lsr0206@naver.com; lsr0206@snu.ac.kr;  
5D605@snuh.org

## Key Summary Points

### *Why carry out this study?*

Atrophic acne scars are the most common type of acne scars and cause significant physical and psychological distress.

1550-nm fractional laser is frequently used for atrophic acne scars; however, few studies have examined the clinical factors affecting the efficacy of non-ablative fractional laser in individual atrophic acne scar types.

### *What was learned from the study?*

We found that 1550-nm fractional laser improved atrophic acne scars, significantly so for boxcar and rolling scars, using an objective evaluation tool.

The improvement was greater in patients 25 years or younger. Synergistic treatment efficacy can be achieved by combining fractional laser with isotretinoin in acne scars, especially icepick scars.

## INTRODUCTION

Atrophic acne scars are the most common type of acne scars and cause significant physical and psychological distress [1]. They usually develop as a result of abnormal collagen formation and degradation during wound healing after inflammatory acne. The scarring mechanisms include overexpression of transforming growth factor- $\beta$ 1 (TGF $\beta$ ) and destruction of sebaceous glands [2]. Atrophic acne scars can be classified into icepick, rolling, and boxcar scars on the basis of the depth and size of the destroyed area [3]. Non-ablative fractional resurfacing is frequently used for atrophic acne scars owing to its efficacy and reduced side effects. However, few studies have examined the clinical factors affecting the efficacy of non-ablative fractional laser in individual atrophic acne scar types.

Herein, we evaluated the clinical factors affecting the effect of 1550-nm erbium-doped fractional photothermolysis laser for the treatment of individual atrophic acne scar types using objective assessment tools.

## METHODS

### Patients

We conducted a retrospective analysis of patients treated with 1550-nm erbium-doped fractional photothermolysis lasers for atrophic acne scars at SMG-SNU Boramae Medical Center from 2010 to 2021. Patients were included if they received at least one treatment session. Patients did not have photographs taken before and after each treatment session or who received other types of laser or treatment on affected skin areas were excluded. The study was approved by the Institutional Review Board of SMG-SNU Boramae Medical Center (No. 30-2022-42).

### Fractional Laser Treatment

Patients treated with 1550-nm erbium-doped fractional photothermolysis laser (Fraxel<sup>®</sup> Restore and Fraxel<sup>®</sup> Dual; Solta Medical Inc., Hayward, CA, USA) at 30 mJ, treatment level 8 and eight passes. The same physician performed all treatments.

### Clinical Assessment

Photographs taken before and after each treatment session were assessed by a single dermatologist. To ensure consistency and avoid bias, the physician rater was not the treating physician. Atrophic acne scars were classified into icepick, rolling, and boxcar type, and each scar type was counted. We used acne scar reduction efficiency (ASRE%) for the objective assessment of treatment efficacy. ASRE% was defined as the percentage reduction of post-acne scar count from baseline counts [4]. In addition, the information associated with acne scars, including sex, age, treatment sessions, concomitant

**Table 1** Patient characteristics

Characteristics	Number
Sex	31
Male	18 (58.1%)
Female	13 (42.0%)
Age (years)	25 (IQR 19–31)
≤ 25	16 (51.6%)
> 25	15 (48.4%)
Number of treatments	2 (IQR 1–5)
1	9 (29.0%)
2	9 (29.0%)
3	5 (16.1%)
> 4	8 (25.8%)
Use of isotretinoin	
Isotretinoin use	16 (51.6%)
Isotretinoin non-use	15 (48.4%)

Values are presented as number (percentage) or median (interquartile range, IQR)

medications, and adverse events, was collected via electronic medical records.

### Statistical Analysis

Statistical analysis was performed using SPSS version 25.0 (IBM Co., Armonk, NY, USA). Data were shown as median (interquartile range, IQR), frequencies and proportions (%), as appropriate. Qualitative or categorical variables (proportions) were compared using chi-square or Fisher's exact test, whichever was applicable. Quantitative variables were analyzed by using the Mann–Whitney test. All statistical tests were two-sided and performed at a significance level of  $p < 0.05$ .

## RESULTS

Thirty-one patients were included (Table 1). Eighteen (58.1%) were male and 13 (41.0%)

were female. The median age was 25 years (IQR 19–31 years) and the median number treatment sessions was 2 (IQR 1–5). Sixteen (51.6%) used concomitant isotretinoin, with the majority of them taking isotretinoin 20 mg/day; three received 10 mg/day, twelve 20 mg/day, and one 30 mg/day.

Boxcar scars were seen in 16 (51.6%), rolling in 30 (96.8%), icepick in 20 (64.5%) patients. The median scar count at baseline was 45 for total scars, 8.5 for boxcar scars, 28 for rolling scars, and 12 for icepick scars. Median count of each scar type was significantly reduced at the end of the final session. Boxcar scars responded better (median ASRE 59.2%) than rolling (ASRE 40.6%,  $p = 0.017$ ) and icepick scars (ASRE 19.1%,  $p = 0.010$ ). Although rolling scars responded better than icepick scars, the difference was not statistically significant ( $p = 0.172$ ) (Table 2, Fig. 1).

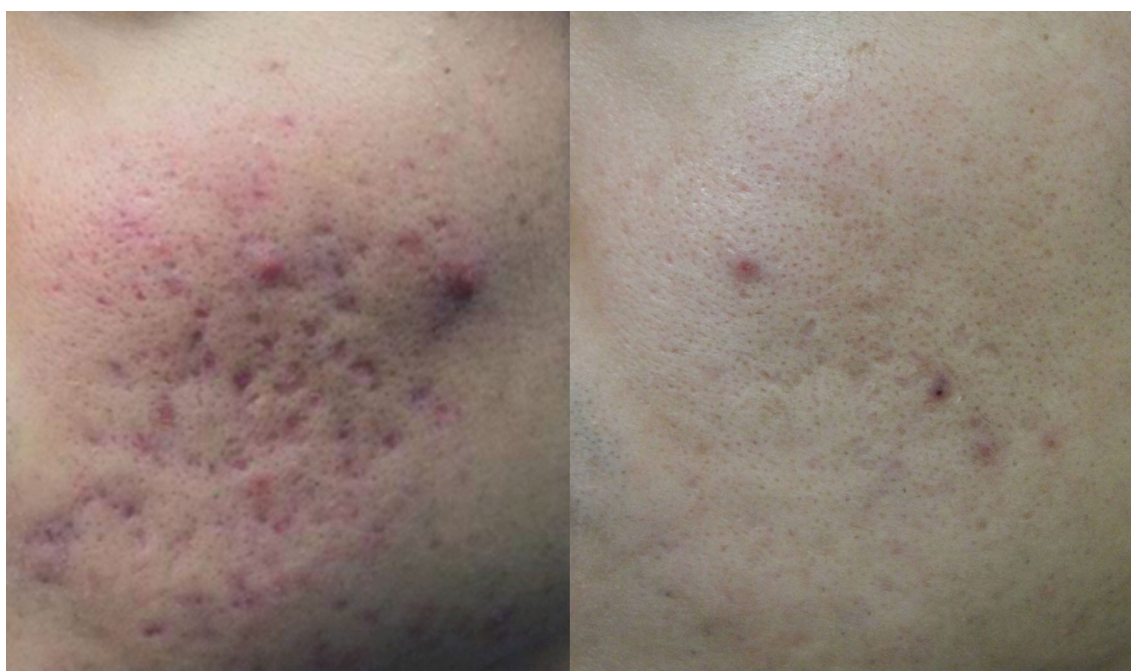With respect to isotretinoin use, isotretinoin users showed a greater ASRE, and the difference was more noticeable in rolling and icepick scars than in boxcar scars (isotretinoin use: total median ASRE 45.0, boxcar 58.2, rolling 42.2, icepick 36.8; isotretinoin non-use: total ASRE 26.0, boxcar 64.0, rolling 27.7, icepick 15.4). There was a significant difference in icepick scar improvement ( $p = 0.029$ ) (Table 3, Fig. 2). There was no significant difference in the median number of treatments between isotretinoin user group and non-user group (median number of treatments was 2 for each group;  $p = 0.446$ ). Additionally, there was no significant difference in the median ages of isotretinoin users and non-users (median age [IQR] 24 [19.5–30.5] and 26 [19–41], respectively;  $p = 0.401$ ).

With regards to age, patients aged 25 years or younger showed a higher ASRE for each scar type than those over 25 years ( $\leq 25$  years: total median ASRE 45.9, boxcar 71.0, rolling 46.0, icepick 35.7;  $> 25$  years: total median ASRE 31.7, boxcar 44.4, rolling 35.1, icepick 16.7), and the difference in boxcar scar improvement was statistically significant ( $p = 0.023$ ) (Table 3, Fig. 2). There was no significant difference in the median number of treatments and isotretinoin user proportions between patients aged 25 years or younger and those over 25 years (median number of treatments 2 and 3,

**Table 2** Acne scar count and acne scar reduction efficiency by acne scar type

Acne scar type	Patient number	Initial scar count	Final scar count	Acne scar reduction efficiency
Total	31	45.0 (31.0–84.0)	28.0 (11.0–42.0)	35.1 (17.9–56.5)
Boxcar	16 (51.6%)	8.5 (5.0–12.0)	5.0 (2.3–6.0)	59.2 (42.4–92.8)
Rolling	30 (96.8%)	28.0 (14.5–65.8)	20.5 (5.5–43.0)	40.6 (15.6–52.6)
Icepick	20 (64.5%)	12.0 (7.5–15.5)	8.0 (5.5–11.0)	19.1 (12.2–41.7)

Values are presented as number (percentage) or median (interquartile range, IQR)



**Fig. 1** Clinical photographs of a 19-year-old male patient with acne scars before and after treatment with fractional laser (left: before treatment, right: after three sessions of fractional laser treatment)

respectively;  $p = 0.247$ . Isotretinoin user proportions 56.3% and 46.7%, respectively;  $p = 0.594$ ).

The laser treatments were well tolerated. Side effects were observed in 7 patients (22.5%) and all were transient; pain was seen in two patients (6.5%), crusting for 2 weeks in one (3.2%), erythema for 2 weeks in one (3.2%), edema for 1 month in one (3.2%), erosion in one (3.2%), and allergic contact dermatitis to topical anesthetic cream in one (3.2%).

## DISCUSSION

Atrophic acne scars, the most common type of acne scars, are subclassified into icepick, rolling, and boxcar scars [5]. Icepick scars are usually narrow (less than 2 mm), sharply delineated tracts that can penetrate deep into the dermis or even the subcutaneous tissue. They are usually broader near the epithelial surface and narrow as they go deeper. Rolling scars are shallower and wider (4–5 mm), with an undulating appearance in otherwise normal-looking skin.

**Table 3** Acne scar reduction efficiency by use of isotretinoin and age

	Use of isotretinoin			Age (years)		
	Isotretinoin use	Isotretinoin non-use	<i>p</i> value	≤ 25	> 25	<i>p</i> value
Number of patients	16 (51.6%)	15 (48.4%)		16 (51.6%)	15 (48.4%)	
Number of treatment	2 (2–5)	2 (1–3)	0.446	2 (1–4)	3 (2–5)	0.247
Final acne scar reduction efficiency	45.0 (24.7–67.7)	26.0 (15.4–50.0)	0.083	45.9 (15.5–67.7)	31.7 (23.5–50.0)	0.260
Final boxcar scar reduction efficiency	58.2 (43.8–100.0)	64.0 (25.0–78.3)	0.690	71.0 (54.2–100.0)	44.4 (0.0–60.0)	0.015*
Final rolling scar reduction efficiency	42.2 (26.7–63.1)	27.7 (12.7–50.0)	0.076	46.0 (10.7–65.2)	35.1 (25.0–50.0)	0.186
Final icepick scar reduction efficiency	36.8 (16.7–81.3)	15.4 (5.6–21.5)	0.029*	35.7 (5.6–75.7)	16.7 (15.4–23.1)	0.096

Values are presented as number (percentage) or median (interquartile range, IQR)

\* $p < 0.05$

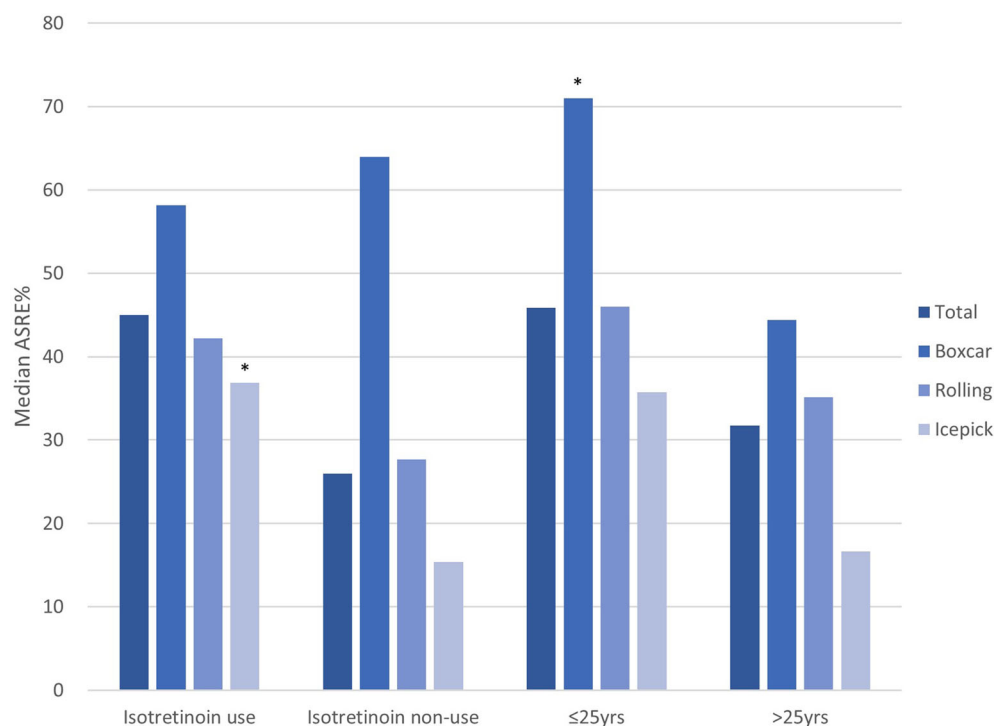
Boxcar scars are wider at the base than icepick scars but do not taper [6].

Non-ablative fractional lasers have been used for all types of atrophic acne scars owing to their efficiency and few side effects [3]. In the present study, we observed significant decrease in the median count of all types of atrophic acne scars using 1550-nm erbium-doped fractional laser. In particular, boxcar scars responded significantly better than rolling and icepick scars, with the ASRE being 59.2% for boxcar scars, 40.6% for rolling scars, and 19.1% for icepick scars. The results of this study are consistent with those of previous studies [4]. A recent review found that for the 1550-nm fractional laser, for every millijoule, the depth of coagulation increased roughly by a factor of 10  $\mu\text{m}$  (10 mJ/100–150  $\mu\text{m}$ ) [7]. Thus, 1550-nm fractional laser could improve most superficial and some deep atrophic scars. Boxcar scars are amenable to fractional lasers, while most icepick scars are deeper than the depth of fractional lasers [4].

Also, we found that when combined with isotretinoin, the overall scar improvement was greater than laser treatment alone, and the difference was more noticeable in rolling and icepick scars than in boxcar scars. There was a

significantly greater improvement in icepick scars. It suggests that isotretinoin might assist in improving the limited efficacy of non-ablative fractional laser on icepick scars. Isotretinoin is a very effective drug for the treatment of severe acne since it affects the epidermis, sebaceous gland, and collagen formation [8]. However, several early reports suggested that recent use of isotretinoin in combination with laser resurfacing can, ironically, yield hypertrophic scarring, due to isotretinoin's effects including impaired wound healing and inhibition of collagenase production [9]. This has led to the recommendation that laser resurfacing should be delayed until at least 6 months after discontinuing isotretinoin. However, this recommendation is controversial, and recent studies on the subject established that performing such procedures is safe [10]. Leal [14] evaluated the safety and the efficacy of non-ablative fractional 1550-nm erbium-doped fiber laser treatment with 20 mg/day of isotretinoin for the treatment of acne scars in 30 patients, compared with 30 control patients who were treated with laser only. No difference in adverse outcomes including erythema, scarring, or hyperpigmentation was noted between the groups. There was no difference in treatment efficacy between the





**Fig. 2** Comparison of acne scar reduction efficiency by use of isotretinoin and age (\* $p < 0.05$ )

two groups. Yoon et al. [15] reported that the combination of non-ablative fractional 1550-nm erbium-doped fiber laser with 10 mg/day of isotretinoin is a safe and effective treatment for acne and acne scars. There was no worsening of acne scars, or induction of hypertrophic scars or keloids in the combination treatment group (35 patients) compared to the laser treatment only group (18 patients). The isotretinoin-administered group showed a greater difference in the scores by global acne scarring classification suggested by Goodman and Baron [16] compared with the control group, but there was no statistically significant difference. Our findings not only support that the concomitant use of non-ablative fractional lasers and isotretinoin is safe but also demonstrate that isotretinoin maximizes the treatment efficacy of laser resurfacing for atrophic acne scars.

Of note also, the improvement was greater in patients 25 years or younger. The difference in boxcar scar improvement was statistically significant. This is assumed to be because the shorter the scar duration, the better the laser

efficacy. The laser effect on dermal remodeling was better in younger scars with some residual inflammation, i.e., erythema, than in older static scars where active inflammation was not present any longer. In addition, it is assumed that the younger the age, the better the collagen remodeling ability. Collagen content in the skin tends to increase until approximately the mid-20s, followed by a progressive decline through the decades [17]. Aging can slow down tissue repair and cell regeneration, with a decrease in collagen and elastin fiber production, and an increase in cross-linked fibers. In aged skin, the post-laser dermal remodeling may be altered, and efficacy may decrease [18]. Our results provide evidence for the need to treat acne scars as early as possible.

There are some limitations in this study. Firstly, it is limited by the small sample size and the absence of a control group. Secondly, because of the three-dimensional nature of acne scars, it is challenging to accurately assess them using clinical photographs. Additionally, there is no objective instrument for evaluating the

outcome of the treatment. Further prospective studies with a larger sample size are needed.

## CONCLUSIONS

We found that non-ablative fractional laser improved atrophic acne scars, markedly so for boxcar and rolling scars, using an objective evaluation tool. The improvement was greater in patients 25 years or younger. Synergistic treatment efficacy can be achieved by combining fractional laser with isotretinoin in acne scars, especially icepick scars.

## ACKNOWLEDGEMENTS

We thank the participants of the study.

**Funding.** No funding or sponsorship was received for this study or publication of this article. The Rapid Service Fee was funded by the authors.

**Author Contributions.** SC conceived and designed the analysis. Data were analyzed and the initial manuscript developed by SRL. All authors reviewed the manuscript.

**Disclosures.** Soo Ran Lee has nothing to disclose. Soyun Cho has nothing to disclose.

**Compliance with Ethics Guidelines.** The study was approved by the Institutional Review Board of SMG-SNU Boramae Medical Center (No. 30–2022-42).

**Data Availability.** The data sets generated during and/or analyzed during the current study are available from the corresponding author on reasonable request.

**Open Access.** This article is licensed under a Creative Commons Attribution-NonCommercial 4.0 International License, which permits any non-commercial use, sharing, adaptation, distribution and reproduction in any medium or format, as long as you give appropriate credit to the original author(s) and the source, provide

a link to the Creative Commons licence, and indicate if changes were made. The images or other third party material in this article are included in the article's Creative Commons licence, unless indicated otherwise in a credit line to the material. If material is not included in the article's Creative Commons licence and your intended use is not permitted by statutory regulation or exceeds the permitted use, you will need to obtain permission directly from the copyright holder. To view a copy of this licence, visit <http://creativecommons.org/licenses/by-nc/4.0/>.

## REFERENCES

1. Taylor M, Gonzalez M, Porter R. Pathways to inflammation: acne pathophysiology. *Eur J Dermatol.* 2011;21:323–33.
2. Jennings T, McLarney M, Renzi M, et al. Acne scarring-pathophysiology, diagnosis, prevention and education—part 1. *J Am Acad Dermatol.* 2022. <https://doi.org/10.1016/j.jaad.2022.04.021>.
3. Bhargava S, Cunha PR, Lee J, Kroumpouzos G. Acne scarring management: systematic review and evaluation of the evidence. *Am J Clin Dermatol.* 2018;19:459–77.
4. Sardana K, Manjhi M, Garg VK, Sagar V. Which type of atrophic acne scar (ice-pick, boxcar, or rolling) responds to nonablative fractional laser therapy? *Dermatol Surg.* 2014;40:288–300.
5. Layton AM, Henderson CA, Cunliffe WJ. A clinical evaluation of acne scarring and its incidence. *Clin Exp Dermatol.* 1994;19:303–8.
6. Fabbrocini G, Annunziata MC, D'Arco V, et al. Acne scars: pathogenesis, classification and treatment. *Dermatol Res Pract.* 2010;2010:893080.
7. Sardana K, Garg VK, Arora P, Khurana N. Histological validity and clinical evidence for use of fractional lasers for acne scars. *J Cutan Aesthet Surg.* 2012;5:75–90.
8. Levy LL, Zeichner JA. Management of acne scarring, part II: a comparative review of non-laser-based, minimally invasive approaches. *Am J Clin Dermatol.* 2012;13:331–40.
9. Zachariae H. Delayed wound healing and keloid formation following argon laser treatment or

- dermabrasion during isotretinoin treatment. *Br J Dermatol*. 1988;118:703–6.
10. Mysore V, Omprakash HM, Khatri GN. Isotretinoin and dermatosurgical procedures. *Indian J Dermatol Venereol Leprol*. 2019;85:18–23.
  11. Spring LK, Krakowski AC, Alam M, et al. Isotretinoin and timing of procedural interventions: a systematic review with consensus recommendations. *JAMA Dermatol*. 2017;153:802–9.
  12. Waldman A, Bolotin D, Arndt KA, et al. ASDS guidelines task force: consensus recommendations regarding the safety of lasers, dermabrasion, chemical peels, energy devices, and skin surgery during and after isotretinoin use. *Dermatolog Surg*. 2017;43:1249–62.
  13. Xia J, Hu G, Hu D, Geng S, Zeng W. Concomitant use of 1,550-nm nonablative fractional laser with low-dose isotretinoin for the treatment of acne vulgaris in Asian patients: a randomized split-face controlled study. *Dermatolog Surg*. 2018;44:1201–8.
  14. Leal H. Fractionated erbium laser during oral isotretinoin treatment. *J Am Acad Dermatol*. 2011;64:AB18. <https://doi.org/10.1016/j.jaad.2010.09.096>.
  15. Yoon JH, Park EJ, Kwon IH, et al. Concomitant use of an infrared fractional laser with low-dose isotretinoin for the treatment of acne and acne scars. *J Dermatolog Treat*. 2014;25:142–6.
  16. Goodman GJ, Baron JA. Postacne scarring—a quantitative global scarring grading system. *J Cosmet Dermatol*. 2006;5:48–52.
  17. Reilly DM, Lozano J. Skin collagen through the lifestages: importance for skin health and beauty. *Plastic Aesthetic Res*. 2021;8:2.
  18. Helou J, Korkomaz J, Stephan F, Soutou B. Searching predictive factors of efficacy and safety in a fractional CO2 laser. *Dermatol Ther*. 2020;33:e13985.