치의과학 박사 학위논문

Effect of polydeoxyribonucleotide on early bone formation in sinus floor elevation via lateral window with simultaneous implant placement

측방접근법을 통한 상악동저 거상술을 동반한 임플란트 식립에서 polydeoxyribonucleotide 가 골형성 초기에 미치는 영향

2023 년 2 월

서울대학교 대학원

치의과학과 치주과학 전공

이 동 섭

Effect of polydeoxyribonucleotide on early bone formation in sinus floor elevation via lateral window with simultaneous implant placement

지도 교수 이 용 무

이 논문을 치의과학 박사 학위논문으로 제출함
2022 년 12 월

서울대학교 대학원
치의과학과 치주과학 전공
이 동 섭

이동섭의 치의과학 박사 학위논문을 인준함
2023 년 1 월

위 원 장 _____ (인)

부위원장 _____ (인)

위 원 _____ (인)

위 원 _____ (인)

위 원 _____ (인)

Abstract

Effect of polydeoxyribonucleotide on early bone formation in sinus floor elevation via lateral window with simultaneous implant placement

Dongseob Lee

Program in Periodontology, Department of Dental Science, Graduate School, Seoul National University
(Directed by Professor Yong-Moo Lee, D.D.S., Ph.D)

Objective: To evaluate the impact of polydeoxyribonucleotide (PDRN) on histological outcomes when implant placement and lateral sinus floor elevation are performed simultaneously.

Materials & Methods: Three bimaxillary premolars (P2, P3, and P4) were extracted from four beagle dogs two months before lateral sinus floor elevation. After lateral elevation of the sinus membrane, each sinus was allocated to either the test or control group. Sinuses underwent either (a) collagenated synthetic bone graft with PDRN

following lateral sinus floor elevation (test group) or (b) collagenated synthetic bone graft without PDRN after lateral sinus floor elevation (control group). Eight weeks after the surgical procedure, all animals were euthanized for histological and histomorphometric assessment. Augmented height (AH), protruding height (PH) and bone-to-implant contact in pristine (BIC_p) and augmented (BIC_a) bone were measured. The composition of the augmented area, which was divided into three areas of interest located in coronal, middle and apical area (AOI_C, AOI_M, and AOI_A), was calculated with three parameters: the area percentage of new bone (pNB), residual bone graft particle (pRBP) and fibrovascular connective tissue (pFVT).

Results: AH, PH, BIC_p, BIC_a total, BIC_a coronal, and BIC_a middle values were not significantly different between sinuses in the control and test groups (all $p > 0.05$). BIC_a apical of sinuses in the test group (76.7 ± 9.3%) showed statistically higher values than those of sinuses in the control group (55.6 ± 22.1%) ($p = 0.038$). pNB, pRBP, and pFVT showed statistically significant differences between two groups in AOI_A ($p=0.038$, 0.028, and 0.007 respectively). pNB, pRBP, and pFVT in the AOI_C and AOI_M were not significantly different between samples in the control and test groups (all $p>0.05$). In intragroup analysis, pNB was significantly higher in AOI_C

compared with AOI_M and AOI_A (p=0.014 and <0.001, respectively). pFVT was statistically higher in AOI_A than AOI_M (p=0.001). There was no significant difference within test group.

Conclusion: Histologic findings revealed that lateral sinus floor elevation with PDRN might improve early new bone formation and bone-to-implant contact.

Keyword : Polydeoxyribonucleotide; Bone regeneration; Bone substitutes; Osteogenesis; Sinus floor augmentation

Student Number : 2020-31221

Table of Contents

1. Introduction

Maxillary molar tooth extraction causes resorption of the alveolar bone and sinus pneumatization. It is known to contribute to implant placement difficulty[1]. To increase the available bone height in the posterior maxilla, some surgical approaches have been proposed. In particular, a lateral sinus floor elevation procedure was first proposed by Boyne & James[2]. In long-term follow-up studies, the lateral sinus floor elevation procedure showed predictable results and higher survival rates[3]. Sinus floor elevation via the lateral approach showed better results in endo-sinus bone gain than transalveolar sinus floor elevation[4].

The use of growth factors was suggested to promote bone formation to shorten treatment periods in lateral sinus floor elevation even though sinus floor elevation already showed high predictability and success rates[5]. Osteoinductive growth factors, especially bone morphogenetic protein-2 (BMP-2), have been introduced in sinus floor elevation procedures in many studies[6,7]. However, BMP-2 has not been widely used for clinical situations because of adverse effects, such as facial swelling. Meanwhile, platelet-rich fibrin (PRF) has been investigated to expedite new bone formation, asserting that

several growth factors within PRF could improve hard tissue regeneration[8,9]. However, a recent meta-analysis demonstrated that scientific evidence is limited supporting the use of PRF for sinus floor elevation[10].

Polydeoxyribonucleotide (PDRN) is a compound containing polymers of various lengths obtained from salmon sperm. PDRN has been known to accelerate cell growth and activation, thus promoting tissue healing[11,12]. PDRN binds to adenosine A2A receptors as an agonist to increase the expression of vascular endothelial growth factor (VEGF) and angiopoietin-1, resulting in an improved healing process[11,13-15]. PDRN also has advantages as a regulator in preventing overgrowth associated with tissue repair despite promoting tissue healing. This makes PDRN relatively safe to use[16].

In addition, PDRN is reported in various studies to be involved in bone regeneration. Particularly, in the bone regeneration process, purinergic receptors play an important role in promoting new bone tissue formation. As a result, PDRN shortens the overall bone healing period[17-19]. In recent studies, it has been confirmed that the use of PDRN with or without other biomaterials promotes bone regeneration[20,21]. However, it has not yet been revealed whether

PDRN promotes the regeneration of bone tissue in sinus floor elevation procedures with simultaneous implant placement.

The aim of this study was to evaluate the efficacy of PDRN in early bone formation in lateral sinus floor elevation with a synthetic bone substitute material through histomorphometric analysis.

2. Materials & Methods

Animals

Four male adult beagle dogs, weighing approximately 10 to 14 kg, aged approximately 1 year, were included. This study was approved by the Seoul National University Institutional Animal Care and Use Committee on June 8th, 2021 (No. 210514-2). The ARRIVE guidelines were followed for preclinical in vivo studies as previously reported [22].

Experimental design

Due to the nature of pilot study, sample size calculation was not performed in this study. The timeline and schematic diagram of the experiment are described in Figure 1. At the site of extracted premolars in the maxilla, implants were placed in each dog with a sinus elevation procedure (lateral approach) in accordance with a split-mouth design. Sinuses were randomly allocated to one of the following groups: (i) one in which collagenated synthetic bone was grafted with PDRN into an elevated sinus floor (test) and (ii) one in which collagenated synthetic bone was grafted without PDRN

(control).

Surgical protocol

The surgical procedure in this study was conducted with reference to previous studies. In the beagle dog model, sinus anatomy and surgical procedures for sinus floor elevation (lateral approach) have been previously introduced[23,24]. Briefly, surgeries were performed under general anaesthesia by intravenous injection of a mixture of tiletamine/zolazepam (0.1 mg/kg) (Zoletil 50, Virbac, France), xylazine (2.3 mg/kg) (Rompun, Bayer Korea, Korea) and atropine sulfate hydrate (0.05 mg/kg) (Atropine sulfate injection, JEIL Pharmaceutical, Korea). After disinfection of the surgical site with iodine solution, 2% lidocaine (lidocaine HCl, Huons, Korea) was applied at the respective buccal and palatal sides of the surgical sites for infiltration anaesthesia.

Surgical phase 1 (tooth extraction). Both premolars (P2, P3, and P4) in the maxilla were extracted. Then, primary closure was performed with resorbable sutures. Alveolar ridges were allowed to heal for 2 months.

Surgical phase 2 (implant placement with sinus floor elevation). A mid-crestal incision was made in the P2, P3, and P4 molar areas along with a vertical releasing incision on the distobuccal side of P1 and the mesiobuccal side of M1. The full thickness flap was elevated to expose the buccal lateral wall of the infraorbital tube. The infraorbital tube was detached and protected after the lateral wall was removed using a round bur. Then, a rectangular osteotomy measuring approximately 12 x 6 mm was prepared on the buccal lateral wall of the sinus cavity. Inferior border of osteotomy was tried to set 1~2 mm over the inferior border of sinus cavity using plain x-ray. Superior border was set to elevate about 6 mm vertically, considering residual bone height (about 1.5 mm) and implant length (8 mm). Distal border of osteotomy line was set near mesial side of M1. Because most of sinus cavities had septum near P3 site, mesial border of osteotomy was expanded enough to detach the Schneiderian membrane safely. The Schneiderian membrane was detached meticulously using a sinus curette (DASK kit, Dentium, Korea) to secure space for bone augmentation (Figure 2A). For grafting same volume, collagenated synthetic bone (OSTEON 3 collagen 6 x 10 mm, GENOSS, Korea) was applied in each sinus and bone graft was absorbed priorly liquid form PDRN (5.625 mg/3 ml,

GENOSS, Korea) in metal tray for 10 minutes as previous study [25]. Then, two implants (Φ 3.44 mm, 8 mm length, SimpleLine II; Dentium, Korea) were installed simultaneously in each augmented sinus (Figure 2B). The distance between two implants placed in each hemimaxilla was 10 mm. Finally, a resorbable collagen membrane (20 x 30 mm, GENOSS, Korea) was placed on the bony window to protect the grafted materials (Figure 2C). The flap was sutured with 5/0 monosyn (Figure 2C). The animals were monitored carefully; in addition, antibiotics (Cefazoline Injection, 20 mg/kg, Chongkundang, Korea) and analgesia (Toranzin Injection, 5 mg/kg, Samsung Pharmaceutical, Korea) were injected within the first days following all surgical procedures. There were no adverse events during the healing periods. The animals were euthanized 8 weeks postsurgery.

Histologic processing

The specimens were dehydrated and embedded in a methyl-methacrylate resin block to obtain undecalcified sections. Histology sections were made with bucco-palatal direction. Each block was cut using a diamond cutter (Exakt, Apparatebau, Germany). Sections were sawed to an approximately 100 μm thick specimens. Then, these specimens were ground and polished to a thickness of 30 μm

with a diamond grinder. Finally, the specimens were stained with Goldner's trichrome, and all histologic images were saved as digital images for histomorphometric analysis.

Histological and histomorphometric analysis

Histologic observations were performed in three areas: the Schneiderian membrane area, lateral window area, and augmented area. Linear measurements were performed using CaseViewer 2.2 software (3DHISTECH Ltd., Budapest, Hungary). For the analysis of the composition of the augmented area, ImageJ (National Institutes of Health, Bethesda, MD, USA) was used. The histomorphometric measurements including linear measurement and composition of augmented area were performed as described below (Figure 1B).

Linear measurements

- Residual bone height (RBH, mm): distance from most coronal to apical point of pristine bone.
- Augmented height (AH, mm): distance from the lowest to the highest point of augmented bone.
- Protruding height (PH, mm): distance from the lowest point of the exposed fixture surrounded by the sinus membrane to the implant

apex.

- Bone-to-implant contact in pristine bone (BIC_p, %): The percentage of pristine bone in contact with the implant surface.
- Bone-to-implant contact in augmented bone (BIC_a, %): The percentage of newly formed bone in contact with the implant surface. BIC_a was divided into three parts (coronal, middle and apical) depending on the implant's vertical position in the sinus.

Composition of the augmented area

To evaluate the deposition of new bone and residual bone graft particles, three rectangular areas of interest (1 mm × 1 mm) were set within the augmented sinus area: the most coronal region (AOI_C), middle region (AOI_M), and most apical region (AOI_A). The AOI was set 0.5 mm lateral to the pitch of the implant thread.

- New bone area percentage (pNB, %)
- Residual bone graft particle area percentage (pRBP, %)
- Fibrovascular connective tissue area percentage (pFVT, %)

Statistical analysis

Data obtained from linear analysis and the composition of the augmented area in each AOI are presented as the means ± standard

deviation (SD), and median values. For inter-group analyses, the Mann-Whitney U test was performed to compare the difference between the control and test groups. For intra-group analyses, the Kruskal-Wallis test and Bonferroni correction were performed. All statistical analyses were performed using SPSS software (version 25.0, Chicago, Illinois). Statistical significance was set at $P<0.05$ for both linear and surface analyses.

3. Results

Clinical observations

None of the animals showed any serious complications, including infection and postoperative bleeding around the surgical wound area, after the operation. On gross examination of the sample, all sinus membranes were intact, and the augmented area showed a dome shape (Figure 3A).

Histological findings

Schneiderian membrane area

The Schneiderian membrane in both groups was lined with normal cells consisting of pseudostratified columnar ciliated epithelial cells and basal cells (Figure 3B). The epithelial lining was approximately 30~40 μm. The lamina propria, including blood vessels and mucous glands, was approximately 0.7~1.3 mm.

Lateral window area

In both control and test groups, new bone formation was observed around the remaining bone graft particle near the lateral window.

The regeneration of the lateral window, which was removed to elevate the sinus floor, was observed. However, the regeneration of the lateral window seemed incomplete, and it was considered to be in the bone bridging stage. Additionally, the regenerated lateral window had a collapsed appearance. The resorbable collagen membrane covering the lateral window was not absorbed completely (Figures 3D and E).

Augmented area

New bone formation was observed in the augmented sinus cavity of both groups. Substantial new bone was observed in the surrounding pristine bone, while sparse bone was observed subjacent to the sinus floor area. Comparing apical section with coronal section of augmented area, it tends to form more new bone in test group (Figures 4B and F). Orange-stained osteoids adjacent to osteoblasts lined the new bone (Figures 3F and G).

Histomorphometric analysis

Linear measurements

Average residual bone height (RBH) was about 1.5±0.4 mm. There was no statistical difference between groups. AH, PH, BIC_p, BIC_a total,

BIC_a coronal, and **BIC_a middle** were not significantly different between samples in the control group and those in the test group (all $p > 0.05$). However, **BIC_a apical** of samples in the test group (76.7 ± 9.3%) showed a statistically higher value than that of samples in the control group (55.6 ± 22.1%) ($p = 0.038$) (Table 1).

Composition of the augmented area

pNB, pRBP, and pFVT were not significantly different in AOI_C and AOI_M between samples in the control and test groups. However, pNB, pRBP, and pFVT in AOI_A showed statistically significant differences between samples in the two groups ($p=0.038$, 0.028 and 0.007, respectively). In intragroup analysis, pNB and pFVT showed statistical differences within control group ($p=0.001$ and 0.003, respectively). pNB was significantly higher in AOI_C compared with AOI_M and AOI_A ($p=0.014$ and <0.001, respectively). pFVT was statistically higher in AOI_A than AOI_M ($p=0.001$). There was no significant difference within test group (Table 2).

4. Discussion

To date, the impact of PDRN on sinus floor elevation has not been fully investigated. This study was first study to reveal the impact of PDRN on early bone formation in lateral window sinus floor elevation. Significantly more new bone formation was observed subjacent to the Schneiderian membrane area at 2 months in samples in the PDRN group than in the control group (p=0.038) (Table 2). At the same time, samples in the PDRN group had a significantly higher BIC value in the augmented area of the subjacent Schneiderian membrane than other samples had (p=0.038) (Table 1). From these results, the osteoinductive potential of PDRN was confirmed in an unfavorable area, where was far from pristine bone and subjacent to the Schneiderian membrane, for new bone formation.

In general, osteoprogenitor cells originate from pristine bone, especially the lateral window or sinus floor[26]. In other words, new bone formation decreases as the distance from pristine bone increases. Meanwhile, some studies have suggested that the Schneiderian membrane may promote new bone formation, providing additional osteogenic cells[27,28]. However, several studies have

demonstrated that its contribution to new bone formation is incidental compared to the bone wall[29,30]. In our study, new bone formation was decreased in the apical direction, which is concurrent with previous studies, suggesting that the Schneiderian membrane may not play an osteoinductive role in sinus floor elevation.

When samples in the test and control groups were compared, there was no difference in pNB, pRBP, or pFVT in the coronal and middle areas. However, in the apical area subjacent to the Schneiderian membrane, there was a statistically significant difference in pNB, pRBP, and pFVT values between samples in the two groups. This trend is similar to the results of a previous study that observed new bone formation after 2 weeks using BMP-2[31]. These results may be attributed to the distance from the bone wall, which has osteogenic potential. It seems that the osteoinductive effect of BMP-2 or PDRN might be masked around the bone wall with high osteogenic potential; however, the effect is extended below the Schneiderian membrane with low osteogenic potential. It is known that PDRN involves in adenosine A2a receptor mediated angiogenesis which could promote bone regeneration. In previous study, PDRN treatment group show enhanced angiogenesis resulting in movement of human bone-marrow mesenchymal stem cells[32]. In addition, adenosine A2a

receptor agonist could accelerate new bone formation. Adenosine A2a receptor agonist showed more bone regeneration in rat calvaria defect model. Rapid angiogenesis might promote new bone regeneration via increasing osteogenic potential in middle and apical regions comparing with control group[33]. In this regard, PDRN can be utilized as a tool to promote bone regeneration for patients or in environments where osteogenic potential is complicated.

Although BIC_p, BIC_a total, BIC_a coronal, and BIC_a middle were not significantly different between the control and test groups, BIC_a apical in samples in the test group showed a statistically higher value than that in samples in the control group (Table 1). This trend might be attributed to new bone formation. The positive correlation between new bone formation and BIC has been reported in a previous study[34]. To reduce the treatment time for functional loading following implant placement, it is important to ensure that the BIC is above the threshold value. Based on the results of our study, a strategy to increase the BIC by using a PDRN that promotes new bone formation can be used.

As there was no difference in AH between samples in the two groups, it seems that the volume change at the bone graft site did not occur when PDRN was used. Conversely, there is a report in the

literature showing that the samples in group that received BMP-2 exhibited an increase in the total augmented area compared to that of samples in the group in which BMP-2 was not used because BMP-2 primarily causes tissue swelling followed by bone regeneration. In the case of PDRN, bone regeneration may not include swelling in the bone grafted area. In a previous study, it was reported that PDRN binds to adenosine A2A receptors as agonists to enhance the expression of VEGF and angiopoietin-1[11,13-15]. The process is related to angiogenesis and improving the wound healing process. The wound healing process seems to enhance bone regeneration without swelling.

In our study, protrusion was observed in 4 of 8 specimens in the control group and 2 of 8 specimens in the test group after implant placement with simultaneous sinus floor elevation. It has been reported that this protruding phenomenon may occur as time passes followed by sinus floor elevation and implant placement simultaneously. Although bone graft materials were applied upside the apex of the implants in the sinus cavity, protrusion of the implant in samples in the control and test groups was observed by histologic observation in both groups without significant differences (0.4 ± 0.6 mm in samples in the control group and 0.1 ± 0.2 mm in samples in

the test group). This result may be attributed to the intrasinus air pressure during respiration, inducing shrinkage of the grafted sinus volume. The reduced graft height was reported in previous studies, especially when the residual bone height was less than 7 mm[35]. In our study, the residual bone height was approximately 1.5 mm; as a result, protrusion was processed significantly. When performing sinus floor elevation, it is recommended to overfill the graft material, considering that the augmented bone volume will be reduced.

BMP-2 is considered the most reliable biomolecule that can promote bone regeneration[36]. The application of BMP-2 has been investigated, and osteoinductive effects were confirmed in a sinus floor elevation model[31,34]. Although its efficacy has been suggested, clinical applications of BMP-2 have not yet been widely implemented. This might be attributed to side effects, such as inflammatory reactions, seroma, or oedema, when BMP-2 was applied at high doses[37,38]. To check the safety of PDRN in this study, a total of three areas were defined and examined in histological observations: the Schneiderian membrane, lateral window, and augmented area. All animals in both groups healed without any severe inflammation. First, a normal Schneiderian membrane composed of epithelial lining, lamina propria, and periosteum was observed in

animals in both groups (Figure 3B). Bone graft particles were incorporated into the lamina propria; however, no inflammatory cells were observed around them in samples in either the test or control group. Previous study reported mean thickness of epithelium and lamina propria of were 45 μm and 354 μm, in intact Schneiderian membrane for mongrel dog[39]. In this study, thickness of epithelium and lamina propria were measured as 30~40 μm and 0.7~1.3 mm, respectively. In 2 months after sinus floor elevation, thickness of epithelium was shown as normal epithelium thickness. However, thickness of lamina propria was observed to be slightly increased compared with normal lamina propria in our study. It is presumed that blood vessel and mucous gland might be increased in postoperative healing process resulting in thickening of lamina propria layer. Histologic and dimensional change evaluation of Schneiderian membrane, especially lamina propria layer, in 4 to 6 months after sinus floor elevation, would be needed in further study. Second, the lateral window area was usually covered with a resorbable collagen membrane. Bony wall regeneration occurred surrounding the lateral window, however, incomplete corticalization was shown in both groups (Figure 3D). This may be affected by the size of the lateral window[40] and insufficient healing time during the investigation of

the osteogenic potential of PDRN in the early stage. Third, new bone formation and bone remodelling were observed in the augmented area in both groups without any specific side effects. In this study, osteoids lying on new bone were observed to be surrounded by a rim of osteoblasts (Figure 3G).

In summary, for sinus floor elevation, the osteoinductive effect of the subjacent Schneiderian membrane (apical area) of PDRN was demonstrated in this animal model. It could be applied into low osteogenic potential area to promote bone regeneration. However, this study was performed with a small sample size due to the nature of this pilot study. In addition, the results should be interpreted with caution due to confounding factors, including diverse sinus cavity sizes and morphologies. Further investigation with an increased sample size and a variety of PDRN dosages should be explored for proper clinical application of PDRN.

5. Conclusion

Within the limits of this study, histologic findings revealed that sinus floor elevation via lateral window with PDRN might improve early new bone formation and bone-to-implant contact demonstrating the osteoinductive effect of the subjacent Schneiderian membrane (apical area) in this animal model.

Bibliography

1. Pietrokovski J, Starinsky R, Arensburg B, Kaffe I. Morphologic characteristics of bony edentulous jaws. J Prosthodont 2007;16:141-7.
2. Boyne PJ, James RA. Grafting of the maxillary sinus floor with autogenous marrow and bone. J Oral Surg 1980;38:613-6.
3. Kim HJ, Yea S, Kim KH, Lee YM, Ku Y, Rhyu IC, et al. A retrospective study of implants placed following 1-stage or 2-stage maxillary sinus floor augmentation by the lateral window technique performed on residual bone of <4 mm: Results up to 10 years of follow-up. J Periodontol 2020;91:183-93.
4. Zhou Y, Shi Y, Si M, Wu M, Xie Z. The comparative evaluation of transcrestal and lateral sinus floor elevation in sites with residual bone height </=6 mm: A two-year prospective randomized study. Clin Oral Implants Res 2021;32:180-91.
5. Freitas RM, Spin-Neto R, Marcantonio Junior E, Pereira LA, Wikesjo UM, Susin C. Alveolar ridge and maxillary sinus augmentation using rhBMP-2: a systematic review. Clin Implant Dent Relat Res 2015;17 Suppl 1:e192-201.
6. Boyne PJ, Lilly LC, Marx RE, Moy PK, Nevins M, Spagnoli DB, et al. De novo bone induction by recombinant human bone morphogenetic protein-2 (rhBMP-2) in maxillary sinus floor augmentation. J Oral Maxillofac Surg 2005;63:1693-707.
7. Kim HJ, Chung JH, Shin SY, Shin SI, Kye SB, Kim NK, et al. Efficacy of rhBMP-2/Hydroxyapatite on Sinus Floor Augmentation: A Multicenter, Randomized Controlled Clinical Trial. J Dent Res 2015;94:158S-65S.
8. Pichotano EC, de Molon RS, de Souza RV, Austin RS, Marcantonio E, Zandim-Barcelos DL. Evaluation of L-PRF combined with deproteinized bovine bone mineral for early implant placement after maxillary sinus augmentation: A randomized clinical trial. Clin Implant Dent Relat Res 2019;21:253-62.
9. Kumar N, Prasad K, Ramanujam L, K R, Dexith J, Chauhan A. Evaluation of treatment outcome after impacted mandibular third molar surgery with the use of autologous platelet-rich fibrin: a randomized controlled clinical

study. J Oral Maxillofac Surg 2015;73:1042-9.

10. Liu R, Yan M, Chen S, Huang W, Wu D, Chen J. Effectiveness of Platelet-Rich Fibrin as an Adjunctive Material to Bone Graft in Maxillary Sinus Augmentation: A Meta-Analysis of Randomized Controlled Trails. Biomed Res Int 2019;2019:7267062.
11. Thellung S, Florio T, Maragliano A, Cattarini G, Schettini G. Polydeoxyribonucleotides enhance the proliferation of human skin fibroblasts: involvement of A2 purinergic receptor subtypes. Life Sci 1999;64:1661-74.
12. Koo Y, Yun Y. Effects of polydeoxyribonucleotides (PDRN) on wound healing: Electric cell-substrate impedance sensing (ECIS). Mater Sci Eng C Mater Biol Appl 2016;69:554-60.
13. Bitto A, Polito F, Altavilla D, Minutoli L, Migliorato A, Squadrito F. Polydeoxyribonucleotide (PDRN) restores blood flow in an experimental model of peripheral artery occlusive disease. J Vasc Surg 2008;48:1292-300.
14. Minutoli L, Antonuccio P, Squadrito F, Bitto A, Nicotina PA, Fazzari C, et al. Effects of polydeoxyribonucleotide on the histological damage and the altered spermatogenesis induced by testicular ischaemia and reperfusion in rats. Int J Androl 2012;35:133-44.
15. Lee DW, Hong HJ, Roh H, Lee WJ. The Effect of Polydeoxyribonucleotide on Ischemic Rat Skin Flap Survival. Ann Plast Surg 2015;75:84-90.
16. Altavilla D, Bitto A, Polito F, Marini H, Minutoli L, Di Stefano V, et al. Polydeoxyribonucleotide (PDRN): a safe approach to induce therapeutic angiogenesis in peripheral artery occlusive disease and in diabetic foot ulcers. Cardiovasc Hematol Agents Med Chem 2009;7:313-21.
17. Bowler WB, Buckley KA, Gartland A, Hipskind RA, Bilbe G, Gallagher JA. Extracellular nucleotide signaling: a mechanism for integrating local and systemic responses in the activation of bone remodeling. Bone 2001;28:507-12.
18. Nakamura E, Uezono Y, Narusawa K, Shibuya I, Oishi Y, Tanaka M, et al. ATP activates DNA synthesis by acting on P2X receptors in human osteoblast-like MG-63 cells. Am J Physiol Cell Physiol 2000;279:C510-9.
19. Guizzardi S, Galli C, Govoni P, Boratto R, Cattarini G, Martini D, et al. Polydeoxyribonucleotide (PDRN) promotes human osteoblast

proliferation: a new proposal for bone tissue repair. Life Sci 2003;73:1973-83.

20. Buffoli B, Favero G, Borsani E, Boninsegna R, Sancassani G, Labanca M, et al. Sodium-DNA for Bone Tissue Regeneration: An Experimental Study in Rat Calvaria. Biomed Res Int 2017;2017:7320953.
21. Kim SK, Huh CK, Lee JH, Kim KW, Kim MY. Histologic study of bone-forming capacity on polydeoxyribonucleotide combined with demineralized dentin matrix. Maxillofac Plast Reconstr Surg 2016;38:7.
22. Kilkenny C, Browne WJ, Cuthill IC, Emerson M, Altman DG. Improving bioscience research reporting: the ARRIVE guidelines for reporting animal research. PLoS biology 2010;8:e1000412.
23. Liu N, Sun F, Xu C, Lin T, Lu E. A comparative study of dog models for osteotome sinus floor elevation and dental implants in posterior maxilla subjacent to the maxillary sinus. Oral Surgery, Oral Medicine, Oral Pathology and Oral Radiology 2013;115:e15-e20.
24. Zhu L, Yang J, Gong J, Zhang C, Wang H. Optimized beagle model for maxillary sinus floor augmentation via a mini-lateral window with simultaneous implant placement. Journal of International Medical Research 2018;46:4684-92.
25. Kim YK, Lee JY, Yun PY, Park JC, Ahn KJ, Kim S. Evaluation of bone healing capacity of xenogenic tooth bone graft material with polydeoxyribonucleotide in bone defect surrounding an implant. Oral Biology Research (OBR) 2014;38:9-16.
26. Haas R, Baron M, Donath K, Zechner W, Watzek G. Porous hydroxyapatite for grafting the maxillary sinus: a comparative histomorphometric study in sheep. Int J Oral Maxillofac Implants 2002;17:337-46.
27. Srouji S, Kizhner T, Ben David D, Riminucci M, Bianco P, Livne E. The Schneiderian membrane contains osteoprogenitor cells: in vivo and in vitro study. Calcified tissue international 2009;84:138-45.
28. Guo J, Weng J, Rong Q, Zhang X, Zhu S, Huang D, et al. Investigation of multipotent postnatal stem cells from human maxillary sinus membrane. Scientific reports 2015;5:1-12.
29. Scala A, Botticelli D, Faeda RS, Garcia Rangel I, Jr., Américo de Oliveira J, Lang NP. Lack of influence of the Schneiderian membrane in forming new bone apical to implants simultaneously installed with sinus floor elevation:

an experimental study in monkeys. Clin Oral Implants Res 2012;23:175-81.

30. Jungner M, Cricchio G, Salata LA, Sennerby L, Lundqvist C, Hultcrantz M, et al. On the Early Mechanisms of Bone Formation after Maxillary Sinus Membrane Elevation: An Experimental Histological and Immunohistochemical Study. Clin Implant Dent Relat Res 2015;17:1092-102.
31. Kim JS, Cha JK, Cho AR, Kim MS, Lee JS, Hong JY, et al. Acceleration of Bone Regeneration by BMP-2-Loaded Collagenated Biphasic Calcium Phosphate in Rabbit Sinus. Clin Implant Dent Relat Res 2015;17:1103-13.
32. Kim D-S, Lee J-K, Jung J-W, Baek S-W, Kim JH, Heo Y, et al. Promotion of bone regeneration using bioinspired PLGA/MH/ECM scaffold combined with bioactive PDRN. Materials 2021;14:4149.
33. Mediero A, Wilder T, Perez-Aso M, Cronstein BN. Direct or indirect stimulation of adenosine A2A receptors enhances bone regeneration as well as bone morphogenetic protein-2. The FASEB Journal 2015;29:1577-90.
34. Jhin MJ, Kim KH, Kim SH, Kim YS, Kim ST, Koo KT, et al. Ex vivo bone morphogenetic protein-2 gene delivery using bone marrow stem cells in rabbit maxillary sinus augmentation in conjunction with implant placement. J Periodontol 2013;84:985-94.
35. Kim DH, Ko MJ, Lee JH, Jeong SN. A radiographic evaluation of graft height changes after maxillary sinus augmentation. J Periodontal Implant Sci 2018;48:174-81.
36. James AW, LaChaud G, Shen J, Asatrian G, Nguyen V, Zhang X, et al. A Review of the Clinical Side Effects of Bone Morphogenetic Protein-2. Tissue Eng Part B Rev 2016;22:284-97.
37. Zara JN, Siu RK, Zhang X, Shen J, Ngo R, Lee M, et al. High doses of bone morphogenetic protein 2 induce structurally abnormal bone and inflammation in vivo. Tissue Eng Part A 2011;17:1389-99.
38. Garrett MP, Kakarla UK, Porter RW, Sonntag VK. Formation of painful seroma and edema after the use of recombinant human bone morphogenetic protein-2 in posterolateral lumbar spine fusions. Neurosurgery 2010;66:1044-9; discussion 9.
39. Sul S-H, Choi B-H, Li J, Jeong S-M, Xuan F. Histologic changes in the

maxillary sinus membrane after sinus membrane elevation and the simultaneous insertion of dental implants without the use of grafting materials. Oral Surgery, Oral Medicine, Oral Pathology, Oral Radiology, and Endodontology 2008;105:e1-e5.

40. Zhu L, Yang J, Gong J, Zhang C, Ganss B, Wang H. Early bone formation in mini-lateral window sinus floor elevation with simultaneous implant placement: An in vivo experimental study. Clinical Oral Implants Research 2021;32:448-59.

Tables and Figures

Table 1. The linear measurements of histomorphometric analysis

	RBH (mm)	AH (mm)		PH (mm)		BIC_p (%)		BIC_a total (%)		BIC_a coronal (%)		BIC_a middle (%)		BIC_a apical (%)	
	Mean±SD	Mean±SD	Median	Mean±SD	Median	Mean±SD	Median	Mean±SD	Median	Mean±SD	Median	Mean±SD	Median	Mean±SD	Median
Control group (n=8)	1.3±0.3	6.5±1.5	6.8	0.4±0.6	0.1	84.1±9.0	83.2	70.7±8.5	73.4	89.7±8.0	90.9	70.4±11.4	71.2	55.6±22.1	64.2
PDRN group (n=8)	1.6±0.5	7.1±1.1	6.9	0.1±0.2	0	80.7±8.4	82.3	78.3±11.1	79.6	85.4±10.7	86.4	73.3±22.9	70.6	76.7±9.3	77.4
P-value	0.236	0.574		0.279		0.534		0.161		0.505		1.000		0.038 [a)]	

The Mann-Whitney U test was performed. There was a statistically significant difference in BIC_a apical values between samples in the PDRN-treated and control groups. RBH: residual bone height, AH: augmented height, PH: protruding height, BIC_p: bone implant contact on pristine bone, BIC_a: bone implant contact on augmented area.

Table 2. The surface histomorphometric measurements of each AOI in the augmented area

Location of the AOI		Control group (n=8)		PDRN group (n=8)		
		Mean±SD (%)	Median	Mean±SD (%)	Median	*P*-value
Coronal (AOI_C)	pNB	49.9±16.7	51.4	40.5±16.5	42.3	0.328
	pRBP	13.3±12.6	13.4	21.4±7.9	21.7	0.161
	pFVT	36.8±15.9	40.1	38.2±16.9	31.3	0.798
Middle (AOI_M)	pNB	27.4±15.0 [b)]	25.1	25.4±16.4	28.1	0.721
	pRBP	23.6±13.5	25.3	23.0±6.8	25.0	0.721
	pFVT	49.1±19.2	50.1	51.6±18.1	50.8	0.878
Apical (AOI_A)	pNB	12.1±10.0 [b)]	12.9	26.3±12.3	29.9	0.038 [a)]
	pRBP	14.8±9.9	18.6	24.5±4.3	17.5	0.028 [a)]
	pFVT	73.1±17.1 [b) c)]	68.6	49.2±11.1	50.3	0.007 [a)]

Values are presented as mean±standard deviation and median.

pNB: percentage of new bone, pRBP: percentage of residual bone graft particle, pFVT: percentage of fibro vascular connective tissue. Surface areas of all selected regions (coronal, middle and apical) were 1 mm^3.

a) Statistically different difference between control and test group ($P<0.05$).

b) Statistically different from AOI_C within the control group ($P<0.05$).

c) Statistically different from AOI_M within the control group ($P<0.05$).

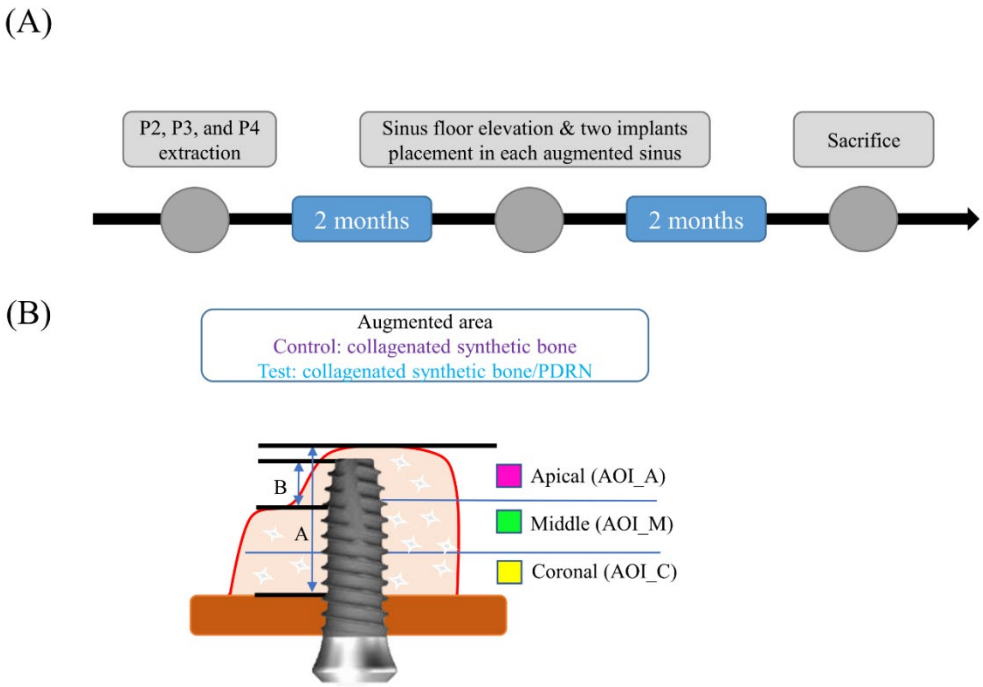

Figure 1. (A) Timeline of the experiment. (B) Schematic diagram of the experiment. Coloured rectangles show the area of interest (AOI) (1 mm^3) in the augmented area. A: Augmented height (AH), from the lowest to the highest point of augmented bone. B: Protruding height (PH), from the lowest point of the exposed fixture surrounded by the sinus membrane to the implant apex. P2, maxillary second premolar; P3, maxillary third premolar; P4, maxillary fourth premolar.

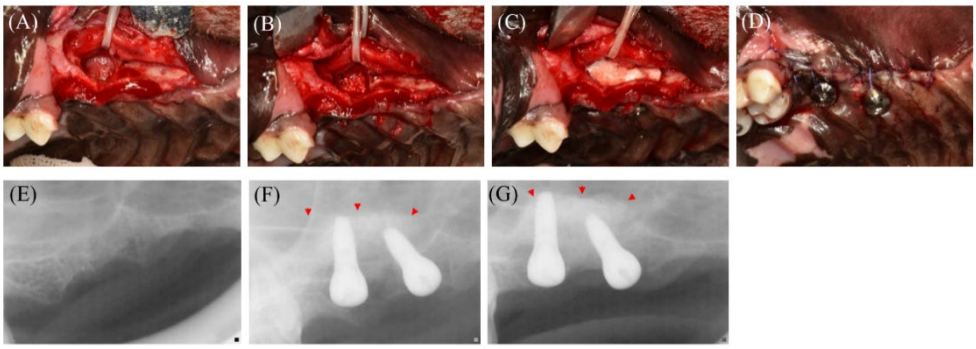

Figure 2. Clinical photographs and radiographs. (A) A full thickness flap was reflected. The Schneiderian membrane was elevated, followed by lateral window preparation. (B) Collagenated synthetic bone with or without PDRN was applied in the sinus cavity. After collagenated synthetic bone augmentation, two implants were installed in each side of the maxilla. (C) The crosslinked collagen membrane was placed to cover the lateral window. (D) Sutures were performed with 5/0 monosyn. (E) Radiograph 2 months after maxillary tooth extraction. (F) Radiograph after implant placement. (G) Radiograph 2 months after implant placement. Note the increased radiopacity of collagenated synthetic bone (arrowheads) in the maxillary sinus. The augmented area was well maintained for 2 months.

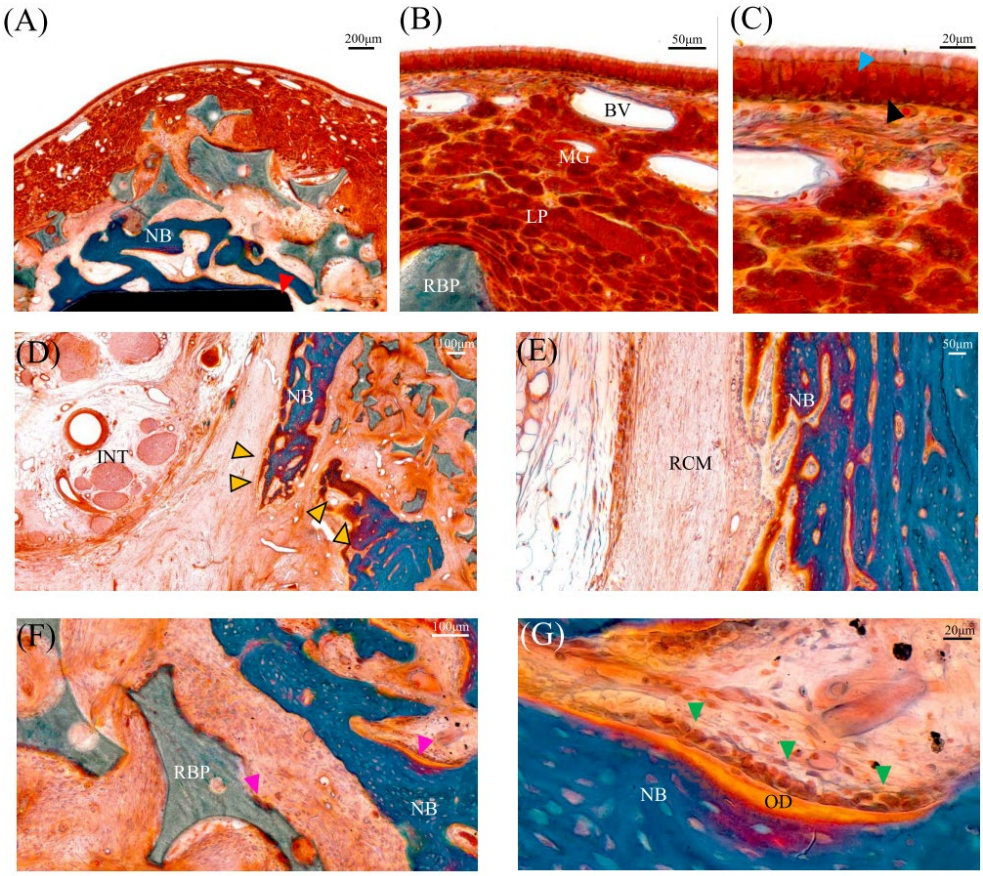

Figure 3. Histologic findings. (A) Histologic view of the Schneiderian membrane area. Above the implant, the remaining bone graft particles support the elevated Schneiderian membrane. The red arrowhead indicates the implant. (B) The higher magnifications for the Schneiderian membrane structure composed of the lamina propria, mucous gland, basal cell, and pseudostratified ciliated columnar epithelium. These structures are observed in both groups. (C) Higher magnifications of the epithelial layer. Blue and black arrowheads indicate the pseudostratified ciliated columnar epithelium and basal cells, respectively. (D) Histologic view of the lateral window area. Note that the lateral window near the infraorbital nerve tube (INT) is not completely regenerated, forming bone bridging (orange

arrowheads). Incomplete regeneration of lateral wall is observed in both groups. (E) Higher magnification of the lateral window. The remaining collagen membrane (RCM) is observed adjacent to the lateral wall. (F) Histologic view of augmented area. Note the orange-stained osteoid (OD) adjacent to new bone and remaining bone graft particle is observed (pink arrowheads). Osteoid is shown in both groups. (G) Higher magnification of the augmented area. Note that the rim of the orange-stained osteoid is covered with the lining of the osteoblast (green arrowheads). NB, new bone; RBP, residual bone graft particle; LP, lamina propria; MG, mucous gland; BV, blood vessel; INT, infraorbital nerve tube; RCM, resorbable collagen membrane; OD, osteoid.

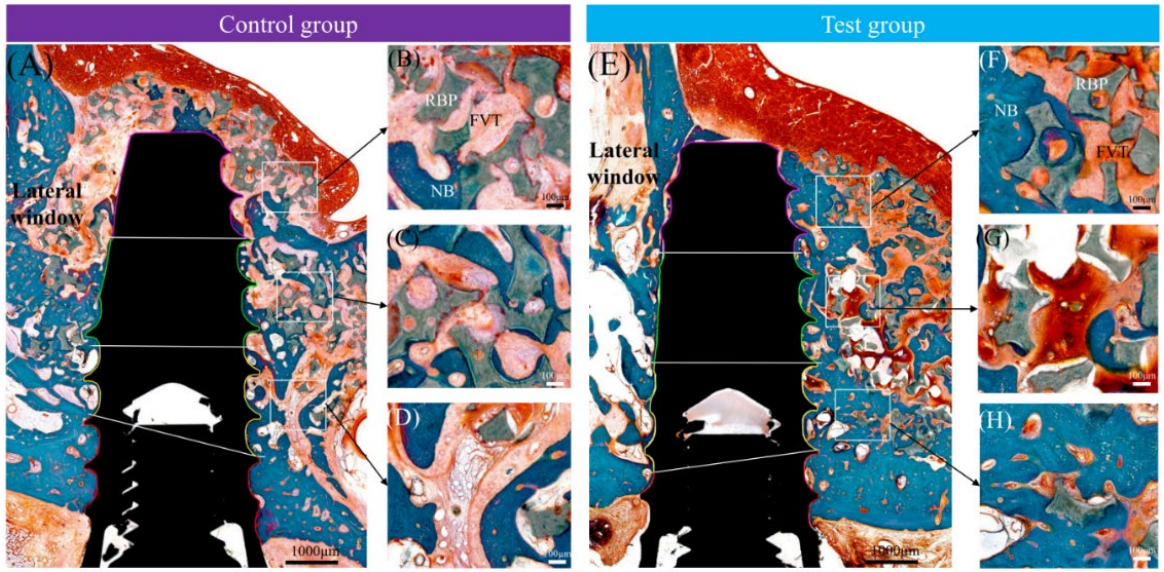

Figure 4. Histologic views of samples in the control and test groups. (A, E) Overall view (scale bar=1000 μm). Pristine and augmented bone regions are separated and marked as colour (pristine: red, augmented bone coronal: yellow; middle: green; apical: pink). New bone formation seems to decrease as distance increases from pristine bone (B, F) Higher magnification view of AOI_A (scale bar=100 μm). More residual bone graft particle is observed and not enough to be converted into new bone than in AOI_C (C, G) Higher magnification view of AOI_M (scale bar=100 μm). (D, H) Higher magnification view of AOI_C (scale bar=100 μm). NB, new bone; RBP, residual bone graft particle; FVT, fibrous vascular connective tissue.

국문초록

측방접근법을 통한 상악동저 거상술을 동반한 임플란트 식립에서 polydeoxyribonucleotide가 골형성 초기에 미치는 영향

이 동 섭
서울대학교 대학원 치의과학과 치주과학 전공
(지도교수 이 용 무)

1. 연구목적

본 연구의 목적은 측방접근법을 통한 상악동저 거상술을 동반한 임플란트 동시 식립에서 polydeoxyribonucleotide(PDRN)가 골형성 초기에 미치는 영향을 알아보는 것이다.

2. 연구방법

네 마리의 비글견을 대상으로 하였으며, 양쪽 상악 제2 소구치, 제3 소구치, 제4 소구치를 발치하였다. 발치 2개월 후 측방접근법을 통한

상악동 거상술이 시행되었으며, 각 거상된 상악동은 (a) PDRN 을 포함하여 콜라겐화 합성골을 이식한 군 (시험군, n=8) 혹은 (b) PDRN 을 포함하지 않고 콜라겐화 합성골을 이식한 군 (대조군, n=8), 두 군 중 무작위 배정되었다. 각 상악동은 상악동 거상술과 두 개의 임플란트 식립이 동시에 시행되었다. 모든 동물은 8주 후에 희생되었다. 각각의 샘플은 조직학적, 조직형태학적 분석이 시행되었다. Residual bone height (RBH), augmented height (AH), protruding height (PH), bone-to-implant contact on pristine bone (BIC_p), bone-to-implant contact on augmented bone (BIC_a total) 값을 측정하여 조직형태학적 분석을 시행하였다. 특히 augmented bone 의 수직적인 위치에 따라 BIC_a total는 BIC_a coronal, BIC_a middle, BIC_a apical 세 부위로 나누어 선형 분석을 시행하고, 동일한 면적을 가지는 area of interest (AOI) 또한 수직적 위치에 따라 coronal (AOI_C), middle (AOI_M), apical (AOI_A) 세 부위로 나누어 신생골 (pNB), 잔존 골이식재 (pRBP), 섬유혈관조직(pFVT)을 비교한 면적 분석을 시행하였다.

3. 결 과

실험기간 동안 특이할 만한 부작용이 관찰되지 않았다. AH, PH, BIC_p, BIC_a total , BIC_a coronal , BIC_a middle 는 그룹 간에 통계적으로 유의한 차이가 관찰되지 않았다. 그러나 BIC_a apical 값은 시험군 (76.7 ± 9.3%)에서 대조군 (55.6 ± 22.1%)에 대해 통계적으로 유의한 값을

보였다 (p=0.038). 그리고 AOI_C 와 AOI_M 에서 신생골, 잔존골이식재, 섬유혈관조직의 조성에 있어 차이가 없었다. 그러나 AOI_A 에서 시험군 (26.3 ± 12.3%)이 대조군 (12.1 ± 10.0%)에 대해 유의하게 많은 신생골이 관찰되었다 (p=0.038). 그룹 내 분석에서, 대조군에서는 AOI_M 과 AOI_A 에서 AOI_C 보다 유의하게 적은 신생골 형성이 관찰되었다 (각각 p=0.014, <0.001). 시험군 내에서는 유의한 항목이 관찰되지 않았다.

4. 결 론

본 연구의 범위 내에서, 조직학적 관찰을 통해 측방 접근 상악동저 거상술에서 PDRN 의 사용은 초기 골형성 및 bone-to-implant contact 측면에서 향상된 결과를 보일 수 있을 것으로 생각된다.

주요어 : Polydeoxyribonucleotide; 골재생; 골대체재; 골형성; 상악동 거상술
학번 : 2020-31221