

## 골수에서 동시에 발견된 랑게르한스세포 조직구증과 B계열 림프구 증식

김미영<sup>1</sup> · 강형진<sup>2,3</sup> · 신희영<sup>2,3</sup> · 안효섭<sup>2,3</sup> · 이동순<sup>1,3</sup>

서울대학교 의과대학 검사의학교실<sup>1</sup> · 소아과학교실<sup>2</sup> · 암연구소<sup>3</sup>

### Concurrent Langerhans Cell Histiocytosis and B-Lineage Lymphoid Proliferation in the Bone Marrow

Miyoung Kim, M.D.<sup>1</sup>, Hyoung Jin Kang, M.D.<sup>2,3</sup>, Hee Young Shin, M.D.<sup>2,3</sup>, Hyo Seop Ahn, M.D.<sup>2,3</sup>, and Dong Soon Lee, M.D.<sup>1,3</sup>

Department of Laboratory Medicine<sup>1</sup>, Division of Hematology/Oncology, Department of Pediatrics<sup>2</sup>, Cancer Research Institute<sup>3</sup>, Seoul National University College of Medicine, Seoul, Korea

We present three cases of concurrent Langerhans cell histiocytosis (LCH) and B-lineage lymphoid cell infiltrations and/or nodules in the bone marrow. The first patient was a 25-month-old boy who presented with LCH on the right shoulder and multiple osteolytic lesions. Bone marrow biopsy showed the presence of LCH and two large lymphoid nodules of B-lineage, which were located in the paratrabecular region. Both LCH and the lymphoid nodules resolved after treatment with prednisone, vinblastine, methotrexate, and cyclophosphamide. The second patient was a 7-month-old girl who presented with LCH in the scalp and bone marrow. In spite of the treatment, a follow-up bone marrow analysis performed after 16 months showed LCH and increased B-lineage lymphoid cells in the interstitial area. The third patient was a 26-month-old girl, and imaging studies revealed reddish skin lesions and multiple osteolytic lesions. Skin biopsy and bone marrow biopsy did not show the presence of LCH; however, we initiated the treatment on the basis of the results of imaging studies. The follow-up study after 6 months showed the presence of LCH and large, patchy infiltration of B-lymphoid cells. We report three rare cases of concurrent bone marrow involvement of LCH and B-lineage lymphoid proliferation, which strongly suggest lymphoid malignancy. Further, clonal changes should be studied to elucidate the common pathogenic mechanism between the two diseases. (*Korean J Lab Med* 2009;29:402-5)

**Key Words** : *Langerhans cell histiocytosis, Lymphoid proliferation, Bone marrow*

## INTRODUCTION

Langerhans cell histiocytosis (LCH) is diagnosed by the

presence of the S100 protein-positive cells and Birbeck granules in ultrastructural examination [1, 2]. LCH can be localized or disseminated [2]. Although the association between LCH and lymphoid malignancies has been reported, simultaneous LCH and B-lineage lymphoma in the bone marrow is a rare finding. In this case report, we introduce three cases of concurrent LCH and B-lineage lymphoid cell infiltrations and/or nodules in the bone marrow.

Received : April 28, 2009

Manuscript No : KJLM09-061

Revision received : September 1, 2009

Accepted : September 4, 2009

Corresponding author : Dong Soon Lee, M.D.

Department of Laboratory Medicine, Seoul National University Hospital, 28 Yeongeun-dong, Jongro-gu, Seoul 110-744, Korea  
Tel : +82-2-2072-3986 Fax : +82-2-747-0359  
E-mail : soonlee@plaza.snu.ac.kr

## CASE REPORT

### 1. Case 1

A 25-month-old boy presented with a 1 yr history of torticollis (deviation of the head to the left side) and erythematous papular rash at multiple sites, including the scalp, bilateral postauricular area, right external meatus, anterior side of the neck, bilateral inguinal area, scrotum, and right axilla. The complete blood count was within the normal range (white blood cells,  $8.3 \times 10^9/L$ ; hemoglobin, 11.1 g/dL; and platelets,  $511 \times 10^9/L$ ). Magnetic resonance imaging revealed multiple lymph node enlargements with soft tissue mass on the right shoulder. Plain radiographic images showed multiple round osteolytic lesions in the skull and mid-shaft of the left femur. Bone scans showed multiple bony metastases in the skull, right scapula, right clavicle, and upper T spines. The microscopic findings of the biopsy specimen of the right shoulder mass were similar to those of the LCH specimen; electron microscopic examination showed round to oval shaped plump cells with oval or irregular nuclei with heterochromatin and prominent nucleoli and Birbeck granules in the cytoplasm. The biopsy specimen was S100- and cluster of differentiation 1a (CD1a)-positive in immunohistochemical staining. Bone marrow aspiration for both tibia did not reveal any specific findings. The bone marrow biopsy section of left tibia

showed diffuse epithelioid infiltration that was positive for CD68, CD45, S100, and vimentin (Fig. 1A). In the interstitial area, the number of CD20-positive cells was slightly high and scattered. The lesion was negative for CD3, epithelial membrane antigen (EMA), CD1a, and CD15. The bone marrow biopsy section of right tibia showed two extremely large lymphoid nodules, three large nodules, and perinodular granulomatous lesions. These nodules were positive for CD45 and CD20 (Fig. 1B), and the perinodular lymphoid cells were CD3-positive. Both lymphoid nodules showed negative staining for vimentin, EMA, S100, CD68, CD10, CD1a, and CD15. After treatment with prednisone, vinblastine, methotrexate, and cyclophosphamide for 7 months, the lymphoid nodules with perinodular granuloma and epithelioid infiltration were not present in the bone marrow. The patient is currently asymptomatic, and all the lesions have been resolved.

### 2. Case 2

A 7-month-old girl presented with a 5 month history of multiple reddish skin lesions on the scalp and both inguinal areas and a 1 month history of recurrent and unresolved fever. She had severe anemia and thrombocytopenia (white blood cells,  $2.99 \times 10^9/L$ ; hemoglobin, 3.1 g/dL; and platelets,  $26 \times 10^9/L$ ). Abdominal sonography showed marked splenomegaly. Other imaging studies showed non-spe-

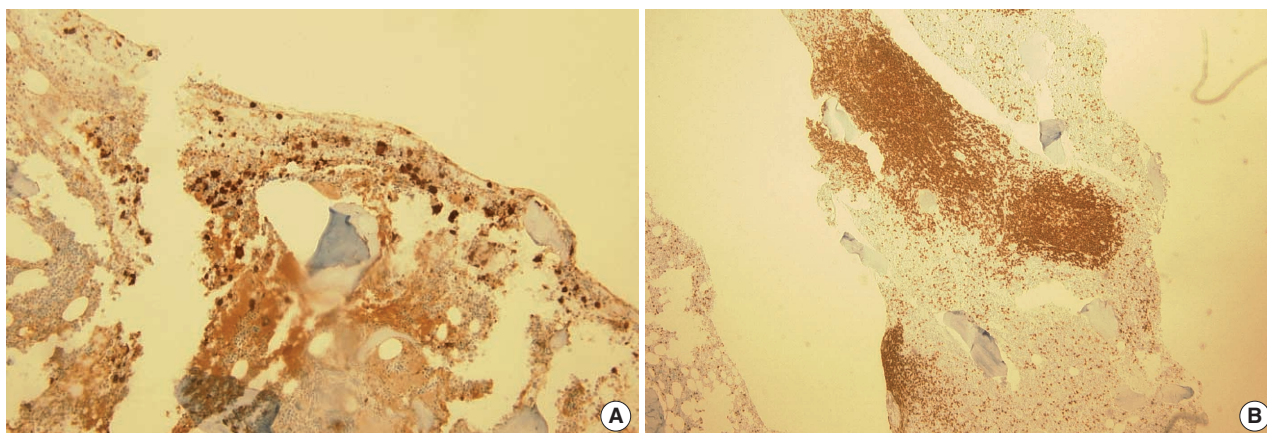


Fig. 1. Langerhans cell histiocytosis and multiple large cluster of differentiation 20 (CD20)-positive, B-lineage lymphoid nodules in the bone marrow of patient 1. (A) The left bone marrow biopsy section shows diffuse S100-positive epithelioid infiltration ( $\times 100$ ). (B) The right bone marrow biopsy section shows two extremely large lymphoid nodules and three large CD20-positive nodules ( $\times 40$ ).

cific findings without any osteolytic lesions. The specimen from the scalp was positive for S100 and CD1a. Bone marrow aspiration of both tibia did not reveal any notable findings. In the right bone marrow biopsy section, a few CD1- and S100-positive histiocytes with abundant cytoplasm were observed in the interstitial area. The left bone marrow section did not show any remarkable findings. Induction chemotherapy was initiated with prednisone, vinblastine, methotrexate, and cyclophosphamide. LCH was not present in the follow-up bone marrow studies conducted after 3 and 7 months. In spite of maintenance therapy, the patient showed anemia and thrombocytopenia. The follow-up bone marrow study after 9 months

showed increased number of CD1a- and S100-positive cells (Fig. 2A) and interstitial infiltration of CD79a- and CD20-positive cells (Fig. 2B). Currently, the patient is undergoing a repetition of her initial treatment regimen.

### 3. Case 3

A 26-month-old girl presented with a 6 week history of neck stiffness. The complete blood count was within the normal range (white blood cells,  $8.56 \times 10^9/L$ ; hemoglobin, 10.4 g/dL; and platelets,  $436 \times 10^9/L$ ). Plain radiographs of the spine showed multiple osteolytic lesions and magnetic resonance imaging showed a paravertebral soft tis-

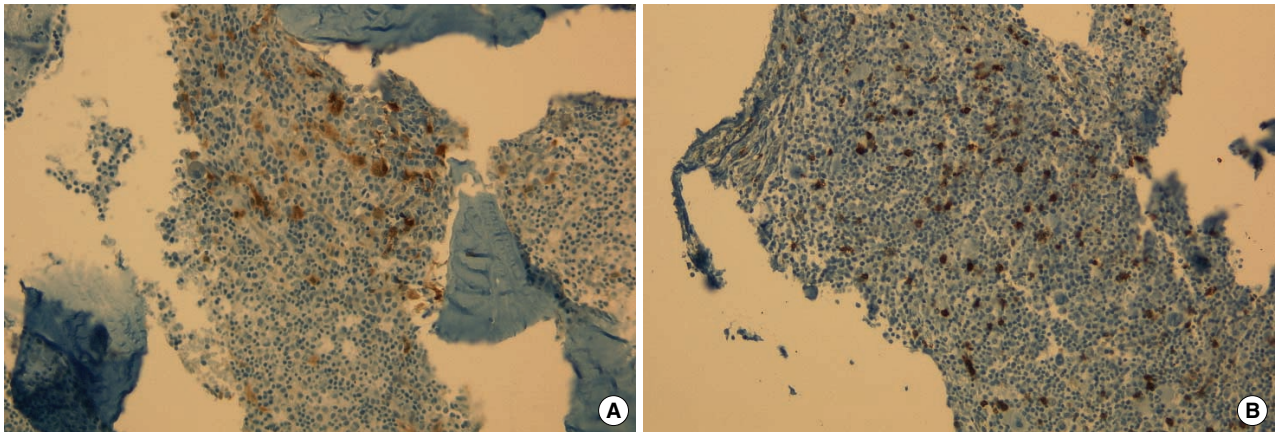


Fig. 2. Langerhans cell histiocytosis and interstitially scattered cluster of differentiation 20 (CD20)-positive B-lymphoid cells in the bone marrow of patient 2. (A) The left bone marrow biopsy section showed increased number of S100-positive cells ( $\times 200$ ). (B) The right bone marrow biopsy section showed interstitial infiltration of CD20-positive cells ( $\times 200$ ).

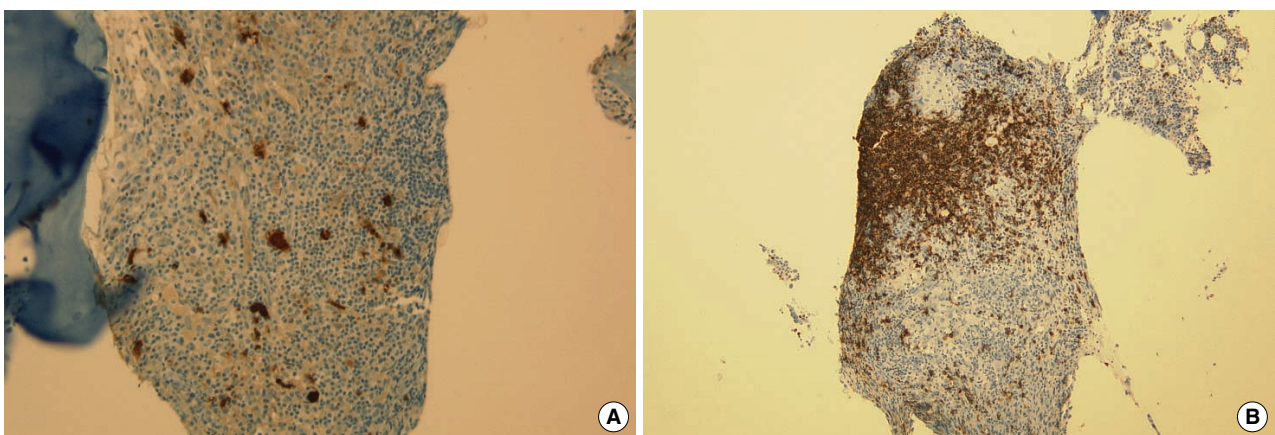


Fig. 3. Langerhans cell histiocytosis and cluster of differentiation 20 (CD20)-positive B-lymphoid cell infiltration in the bone marrow of patient 3. (A) The left bone marrow biopsy section showed increased number of S100-positive cells ( $\times 200$ ). (B) The left bone marrow biopsy section showed large, patchy infiltration of CD20-positive cells ( $\times 100$ ).



sue mass invading the cervical–thoracic–lumbar (CTL) spine, indicating LCH. Biopsy of the skin (unknown site) and iliac bone did not yield any remarkable results. LCH was not present in the bone marrow. Induction chemotherapy was initiated with prednisone, vinblastine, methotrexate, and cyclophosphamide on the basis of the results of imaging studies. In a follow-up study performed after 6 months, the bone marrow samples from both sides showed increased number of CD1a–, S100–, CD68–, CD14–, and vimentin–positive cells (Fig. 3A). In the left biopsy section, CD20–positive cells were present in a large, patchy infiltration pattern (Fig. 3B). The patient is currently receiving treatment with prednisone, vinblastin, methotrexate, and cyclophosphamide.

## DISCUSSION

The diagnosis of LCH is based on the detection of the S100 protein–positive immunophenotype and/or the presence of Birbeck granules in the electron microscopy samples [1, 2]. Langerhans cells are also positive for CD1a, vimentin, CD68, and human leucocyte antigen (HLA)–DR. CD45 expression is low, and B– and T–cell lineage markers are absent [2].

The association between LCH and other neoplasms, including leukemia and lymphoma, has been reported; however, the biological basis for this association remains to be clarified. LCH may precede, occur with, or follow the lymphoma [1]. An association between LCH and T–lymphoblastic leukemia was confirmed by the elucidation of the rearrangement of the T–cell receptor gene [3]. Few reports indicate the association between LCH and B–lineage lymphomas. The association between LCH and Hodgkin’s disease involving nasopharynx and breast and that between LCH and mucosa–associated lymphoid tissue (MALT) lymphoma in thyroid gland has also been reported [1, 4]. However, concurrent bone marrow involvement of LCH and B–lineage lymphoma has not been reported thus far.

We were unable to prove the clonality of the B–lymphoid cell proliferation due to the unavailability of appro-

priate samples for additional tests, including conventional G–banding, fluorescence *in situ* hybridization, or immunoglobulin heavy chain gene rearrangement. However, the composition, location, size, and demarcation of the lymphoid aggregates in the three cases strongly suggest bone marrow involvement of lymphoma rather than a reactive nodule: 1) the lymphoid nodules in those cases showed a uniform pattern with a predominance of B–lymphoid cells; the lymphoid nodules were not composed of a mixture of B– and T–lymphocytes; 2) the size of the lymphoid nodules was relatively large; 3) the lymphoid nodules were located in the paratrabecular–endosteal region and not in central–perivascular region; and 4) the lymphoid nodules were not well defined and demarcated [5].

We presented three rare cases of LCH and B–lineage lymphoid proliferation, which strongly suggest lymphoma. Further studies to assess the clonal changes must be performed to elucidate the pathogenic mechanism between the two diseases.

## REFERENCES

1. Adu-Poku K, Thomas DW, Khan MK, Holgate CS, Smith ME. Langerhans cell histiocytosis in sequential discordant lymphoma. *J Clin Pathol* 2005;58:104-6.
2. Swerdlow SH, Campo E, Harris NL, Jaffe ES, Pileri SA, Stein H et al. WHO classification of tumors of hematopoietic and lymphoid tissues. 2nd ed. Lyon, France: IARC Press 2008:358-60.
3. Feldman AL, Berthold F, Arceci RJ, Abramowsky C, Shehata BM, Mann KP, et al. Clonal relationship between precursor T-lymphoblastic leukemia/lymphoma and Langerhans-cell histiocytosis. *Lancet Oncol* 2005;6:435-7.
4. Licci S, Boscaino A, De Palma M, Del Nonno F, D’Antonio A. Concurrence of marginal zone B-cell lymphoma MALT-type and Langerhans cell histiocytosis in a thyroid gland with Hashimoto disease. *Ann Hematol* 2008;87:855-7.
5. Thiele J, Zirbes TK, Kvasnicka HM, Fischer R. Focal lymphoid aggregates (nodules) in bone marrow biopsies: differentiation between benign hyperplasia and malignant lymphoma—a practical guideline. *J Clin Pathol* 1999;52:294-300.