

A Novel *DHCR7* Mutation in a Smith-Lemli-Opitz Syndrome Infant Presenting with Neonatal Cholestasis

Smith-Lemli-Opitz syndrome (SLOS) is an autosomal recessive malformation syndrome caused by a defect in cholesterol biosynthesis. The incidence is very low in Asians and only one case has been reported in Korea thus far. Recently, we found an infant with neonatal cholestasis. He had microcephaly, ambiguous genitalia, cleft palate, syndactyly of toes, patent ductus arteriosus and hypertrophic pyloric stenosis. The serum cholesterol was decreased and serum 7-dehydrocholesterol was markedly elevated. Genetic analysis of the *DHCR7* gene identified a novel missense mutation (Pro227Ser) as well as a known mutation (Gly303Arg) previously identified in a Japanese patient with SLOS. Although rare in Korea, SLOS should be considered in the differential diagnosis of neonatal cholestasis, especially in patients with multiple congenital anomalies and low serum cholesterol levels.

Key Words : Smith-Lemli-Opitz Syndrome; Cholestasis; 7-dehydrocholesterol reductase; Mutation

Jae Sung Ko¹, Byung Sam Choi¹,
Jeong Kee Seo¹, Jee Yeon Shin¹,
Jong Hee Chae¹, Gyeong Hoon Kang²,
Ran Lee³, Chang-Seok Ki⁴,
and Jong-Won Kim⁴

Departments of Pediatrics¹ and Pathology², Seoul National University College of Medicine, Seoul; Department of Pediatrics³, Kunkuk University School of Medicine, Seoul; Department of Laboratory Medicine⁴, Sungkyunkwan University School of Medicine, Seoul, Korea

Received : 22 February 2008

Accepted : 18 August 2008

Address for correspondence

Jeong Kee Seo, M.D.
Department of Pediatrics, Seoul National University
Children's Hospital, 101 Daehang-no, Jongno-gu,
Seoul 110-769, Korea
Tel : +82.2-2072-3467, Fax : +82.2-743-3455
E-mail : jkseo@snu.ac.kr

This work was Supported by grant no 04-2007-0230 from SNUH Research Fund.

© 2010 The Korean Academy of Medical Sciences.

This is an Open Access article distributed under the terms of the Creative Commons Attribution Non-Commercial License (<http://creativecommons.org/licenses/by-nc/3.0>) which permits unrestricted non-commercial use, distribution, and reproduction in any medium, provided the original work is properly cited.

INTRODUCTION

Smith-Lemli-Opitz syndrome (SLOS, OMIM 270400) is an autosomal recessive disorder caused by mutations of 7-dehydrocholesterol reductase gene (*DHCR7*) (1-4). *DHCR7* deficiency impairs cholesterol production, resulting in accumulation of precursor sterols, 7-dehydrocholesterol (7DHC) (5). The estimated incidence of SLOS is 1 in 20,000-40,000 births in the Caucasian population (6-8). On the other hand, the incidence is low in African and Asian populations (9-11) and only one case has been reported in Korea thus far (12).

Patients with SLOS show a wide variability of congenital anomalies, including dysmorphic facies, microcephaly, cleft palate, syndactyly of toes 2 and 3, visceral malformations, congenital heart defects, and ambiguous genitalia (7). Failure to thrive, behavior problems, and mental retardation are hallmarks of the disorder. The spectrum of phenotype is variable, from early embryonal non-viability to patients with minimal physical abnormalities and normal intelligence or minimal intellectual impairment. Liver disease has been reported infrequently in SLOS (13). We found a case of SLOS who presented with neonatal cholestasis and identified a novel mutation of the *DHCR7* gene.

CASE REPORT

Patient

A boy, weighing 1,780 g at birth, was born in a breech presentation by cesarian section to a 27-yr-old primigravida at 36 weeks of gestation. An obstetrical ultrasound evaluation had shown oligohydramnios and ambiguous genitalia. Apgar scores were 2 at one minute and 5 at five minutes. He was intubated for poor respiratory function and positive airway pressure was administered. Physical examination disclosed microcephaly, micrognathia, a small nose with anteverted nares, ambiguous genitalia, cleft palate, simian line, and bilateral syndactyly of the second and third toes. Chromosomal analysis showed a 46,XY karyotype. Echocardiography revealed large patent ductus arteriosus (PDA) and atrial septal defect. PDA ligation was done because of progressive heart failure. At 1 month of age, he exhibited feeding intolerance. Abdominal ultrasonography and upper GI series showed hypertrophic pyloric stenosis, and pyloromyotomy was done.

Persistent jaundice and failure to thrive were noted at 4 months of age. The infant weighed 2,900 g. Physical examination showed ptosis and hypotonia. The hard liver was pal-

table 3 cm below the costal margin. Blood chemistry showed a total bilirubin of 8.6 mg/dL direct bilirubin of 4.7 mg/dL, aspartate aminotransferase of 176 IU/L, alanine aminotransferase of 86 IU/L, and GGT of 13 IU/L. Prothrombin time was prolonged (INR 1.85). Leukocytosis (white blood cell count 20,000/ μ L) and anemia (hemoglobin 8.8 g/dL) were noted. Serology for hepatitis A, B, and C, toxoplasma, rubella, cytomegalovirus, herpes simplex was negative. Screening tests for metabolic disorders were negative. The serum cholesterol level was reduced (21 mg/dL) and serum 7DHC level by gas chromatography-mass spectrometry was markedly elevated (567 μ g/mL).

Ultrasonography of the abdomen showed hepatomegaly with increased echogenicity and bilateral cystic renal disease. A liver biopsy revealed the ballooning or feathery degeneration and macro-vesicular fatty change of hepatocytes, periportal fibrosis, and ductular proliferation associated with neutrophilic infiltration (Fig. 1). He developed fever, and broad-spectrum antibiotics were given. Dietary cholesterol (egg yolk)

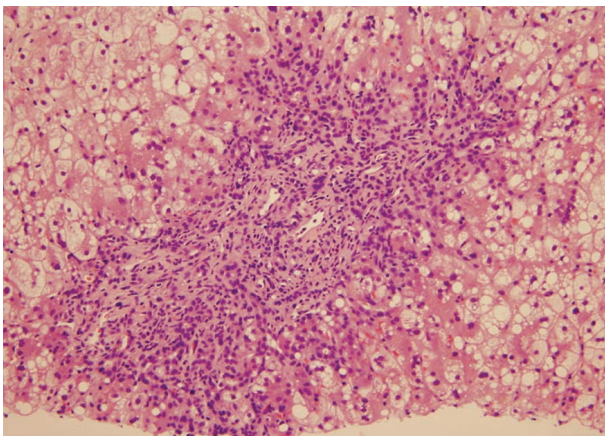


Fig. 1. Percutaneous liver biopsy exhibited ballooning or feathery degeneration and macrovesicular fat droplets in lobular hepatocytes and periportal fibrosis and ductular proliferation in a portal space.

and fat soluble vitamins were supplemented. Generalized tonic seizure with apnea developed and electroencephalography revealed a partial seizure. The disease severity was scored as reported previously (14). The clinical severity score was 55 and he was classified into the severe phenotype.

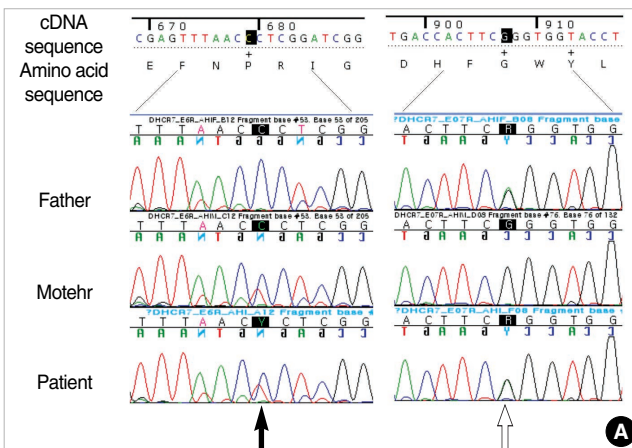
Genetic analysis

Genomic DNA was extracted from whole blood, in accordance with standard methods. Informed consent was obtained from the parents. Mutation analysis of *DHCR7* was performed using PCR amplification and direct sequencing of *DHCR7* coding exons and their intron/exon boundaries as previously described (12).

DISCUSSION

Two missense variations were identified in the patient. One was a C to T transition at nucleotide 679 (c.679C>T) in exon 7, resulting in a Pro to Ser substitution at the 227th residue (Pro227Ser; Fig. 2A). The other was a G to A transition at nucleotide 907 (c.907G>A) in exon 8, resulting in a Gly to Arg substitution at the 303rd residue (Gly303Arg; Fig. 2A). Both variations were inherited from the patient's mother and father, respectively. While Gly303Arg has been reported in a Japanese patient with SLOS (15), Pro227Ser variation has not been reported previously and it alters conserved residue among different species (Fig. 2B).

The frequency of hepatic manifestation in SLOS was reported to be low, ranged from 2.5% to 16% (9, 13, 15). Although cholestatic liver disease and isolated hypertransaminasemia were reported in SLOS, there are few studies investigating the histological abnormalities of the liver. In the present study, histologic findings showed septal fibrosis, ductular proliferation, and ballooning degeneration of hepatocytes, which are consistent with those of Rossi et al. (13). Since bile acids are synthesized from cholesterol, cholestasis may be caused by im-



<i>H. sapiens</i> <i>DHCR7</i> (NP_001351.2)	E	F	N	P	R	I	G
<i>M. musculus</i> <i>Dhcr7</i> (NP_031882.1)	E	F	N	P	R	I	G
<i>G. gallus</i> <i>Dhcr7</i> (XP_420914.1)	E	F	N	P	R	I	G
<i>D. rerio</i> <i>dhcr7</i> (NP_958487.1)	E	F	N	P	R	I	G
<i>B. taurus</i> <i>DHCR7</i> (NP_001014927.1)	E	F	N	P	R	I	G
<i>X. tropicalis</i> <i>dhcr7</i> (NP_989235.1)	E	F	N	P	R	I	G
<i>R. norvegicus</i> <i>Dhcr7</i> (NP_071784.1)	E	F	N	P	R	I	G

Fig. 2. (A) Direct sequencing of the *DHCR7* gene. A novel missense mutation (c.679C>T; Pro227Ser) was identified in the patient and his mother (filled arrow) and a known mutation was found in the patient and his father (open arrow). (B) The Pro227Ser mutation was evolutionary conserved residue among different species. (<http://www.ncbi.nlm.nih.gov/sites/entrez?db=protein>)

paired bile acid synthesis due to a severe deficiency of DHCR. Severe cholestasis in SLOS was reported to be associated with severe phenotypes, while isolated hypertransaminasemia was associated with milder phenotypes (16). Our patient presented with severe cholestasis and severe phenotype. Serum GGT levels were normal in our case in spite of severe cholestasis. Normal GGT with neonatal cholestasis is also shown in progressive familial intrahepatic cholestasis 1 and 2, ARC syndrome, and inborn errors of bile acid synthesis.

To date more than 120 mutations have been identified (17). The missense mutations account for 87% of the total mutations. Fifty percent of the missense mutations are located in one of the nine predicted transmembrane domains. The p-Gly303Arg mutation was previously reported in Japanese SLOS patients and it is located in the seventh transmembrane domain, which represent a highly conserved sterol-sensing domain (14). The p.Pro227Ser mutation is located in the second cytoplasmic loop, and previously described mutations in this loop are p.Gln224Lys and p.Arg228Trp (18). Three mutations including IVS-1G→C, p.Thr93Met, and p.Val326Leu account for 50% of the spectrum of mutations in Caucasian patients (19). On the other hand, p.Arg325Gln is the most common mutation in Japanese SLOS patients (14). The previously reported case of SLOS in Korea harbored compound heterozygous mutations including p.Arg352Trp and p.Lys376ArgfsX37 (12). *DHCR7* mutation patterns in Asian patients are different from those observed among Caucasians.

The genotype-phenotype analysis showed that most homozygotes for frameshift and nonsense mutations had the severe phenotypes (20). However, Yu et al. (17) showed that there was great variation in severity in patients that had the same type of mutations.

In summary, we found a case of SLOS with mutations of the *DHCR7* gene and neonatal cholestasis. SLOS should be considered in the differential diagnosis of neonatal cholestasis, especially in patients with multiple congenital anomalies and low serum cholesterol levels.

REFERENCES

1. Moebius FF, Fitzky BU, Lee JN, Paik YK, Glossmann H. *Molecular cloning and expression of the human delta7-sterol reductase. Proc Natl Acad Sci USA* 1998; 95: 1899-902.
2. Fitzky BU, Witsch-Baumgartner M, Erdel M, Lee JN, Paik YK, Glossmann H, Utermann G, Moebius FF. *Mutations in the Delta7-sterol reductase gene in patients with the Smith-Lemli-Opitz syndrome. Proc Natl Acad Sci USA* 1998; 95: 8181-6.
3. Wassif CA, Maslen C, Kachilele-Linjewile S, Lin D, Linck LM, Connor WE, Steiner RD, Porter FD. *Mutations in the human sterol delta7-reductase gene at 11q12-13 cause Smith-Lemli-Opitz syndrome. Am J Hum Genet* 1998; 63: 55-62.
4. Waterham HR, Wijburg FA, Hennekam RC, Vreken P, Poll-The BT, Dorland L, Duran M, Jira PE, Smeitink JA, Wevers RA, Wanders RJ. *Smith-Lemli-Opitz syndrome is caused by mutations in the 7-dehydrocholesterol reductase gene. Am J Hum Genet* 1998; 63: 329-38.
5. Tint GS, Irons M, Elias ER, Batta AK, Frieden R, Chen TS, Salen G. *Defective cholesterol biosynthesis associated with the Smith-Lemli-Opitz syndrome. N Engl J Med* 1994; 330: 107-13.
6. Opitz JM. *RSH/SLO ("Smith-Lemli-Opitz") syndrome: historical, genetic, and developmental considerations. Am J Med Genet* 1994; 50: 344-6.
7. Kelley RI. *RSH/Smith-Lemli-Opitz syndrome: mutations and metabolic morphogenesis. Am J Hum Genet* 1998; 63: 322-6.
8. Ryan AK, Bartlett K, Clayton P, Eaton S, Mills L, Donnai D, Winter RM, Burn J. *Smith-Lemli-Opitz syndrome: a variable clinical and biochemical phenotype. J Med Genet* 1998; 35: 558-65.
9. Cunniff C, Kratz LE, Moser A, Natowicz MR, Kelley RI. *Clinical and biochemical spectrum of patients with RSH/Smith-Lemli-Opitz syndrome and abnormal cholesterol metabolism. Am J Med Genet* 1997; 68: 263-9.
10. Kelley RI. *A new face for an old syndrome. Am J Med Genet* 1997; 68: 251-6.
11. Tsukahara M, Fujisawa K, Yamamoto K, Hasui M, Saito C, Yamamaka T, Honda A, Honda M, Tint GS, Salen G, Opitz JM. *Smith-Lemli-Opitz syndrome in Japan. Am J Med Genet* 1998; 75: 118-9.
12. Chae JH, Kim KJ, Hwang YS, Ki CS, Kim JW. *Identification of a novel DHCR7 mutation in a Korean patient with Smith-Lemli-Opitz syndrome. J Child Neurol* 2007; 22: 1297-300.
13. Rossi M, Vajro P, Iorio R, Battagliese A, Brunetti-Pierri N, Corso G, Di Rocco M, Ferrari P, Rivasi F, Vecchione R, Andria G, Parenti G. *Characterization of liver involvement in defects of cholesterol biosynthesis: long-term follow-up and review. Am J Med Genet A* 2005; 132: 144-51.
14. Matsumoto Y, Morishima K, Honda A, Watabe S, Yamamoto M, Hara M, Hasui M, Saito C, Takayanagi T, Yamanaka T, Saito N, Kudo H, Okamoto N, Tsukahara M, Matsuura S. *R352Q mutation of the DHCR7 gene is common among Japanese Smith-Lemli-Opitz syndrome patients. J Hum Genet* 2005; 50: 353-6.
15. Herman GE. *Disorders of cholesterol biosynthesis: prototypic metabolic malformation syndromes. Hum Mol Genet* 2003; 12 Spec No 1: R75-88.
16. Kelley RI, Hennekam RC. *The Smith-Lemli-Opitz syndrome. J Med Genet* 2000; 37: 321-35.
17. Yu H, Patel SB. *Recent insights into the Smith-Lemli-Opitz syndrome. Clin Genet* 2005; 68: 383-91.
18. Witsch-Baumgartner M, Clayton P, Clusellas N, Haas D, Kelley RI, Krajewska-Walasek M, Lechner S, Rossi M, Zschocke J, Utermann G. *Identification of 14 novel mutations in DHCR7 causing the Smith-Lemli-Opitz syndrome and delineation of the DHCR7 mutational spectra in Spain and Italy. Hum Mutat* 2005; 25: 412.
19. Yu H, Lee MH, Starck L, Elias ER, Irons M, Salen G, Patel SB, Tint GS. *Spectrum of Delta(7)-dehydrocholesterol reductase mutations in patients with the Smith-Lemli-Opitz (RSH) syndrome. Hum Mol Genet* 2000; 9: 1385-91.
20. Witsch-Baumgartner M, Fitzky BU, Ogorelkova M, Kraft HG, Moe-

buis FF, Glossmann H, Seedorf U, Gillissen-Kaesbach G, Hoffmann GF, Clayton P, Kelley RI, Utermann G. *Mutational spectrum in the Delta7-sterol reductase gene and genotype-phenotype correlation*

in 84 patients with Smith-Lemli-Opitz syndrome. Am J Hum Genet 2000; 66: 402-12.