



*This is an enhanced PDF from The Journal of Bone and Joint Surgery*

*The PDF of the article you requested follows this cover page.*

---

## **Ulnar Shortening Osteotomy in Idiopathic Ulnar Impaction Syndrome. Surgical Technique**

Goo Hyun Baek, Moon Sang Chung, Young Ho Lee, Hyun Sik Gong, Sanglim Lee and Hyung Ho Kim  
*J Bone Joint Surg Am.* 2006;88:212-220. doi:10.2106/JBJS.F.00320

---

**This information is current as of August 28, 2009**

### **Reprints and Permissions**

Click here to [order reprints or request permission](#) to use material from this article, or locate the article citation on [jbjs.org](http://jbjs.org) and click on the [Reprints and Permissions] link.

### **Publisher Information**

The Journal of Bone and Joint Surgery  
20 Pickering Street, Needham, MA 02492-3157  
[www.jbjs.org](http://www.jbjs.org)

# Ulnar Shortening Osteotomy in Idiopathic Ulnar Impaction Syndrome

## Surgical Technique

BY GOO HYUN BAEK, MD, MOON SANG CHUNG, MD, YOUNG HO LEE, MD,  
HYUN SIK GONG, MD, SANGLIM LEE, MD, AND HYUNG HO KIM, MD

*Investigation performed at the Department of Orthopaedic Surgery, Seoul National University College of Medicine, Seoul, South Korea*

*The original scientific article in which the surgical technique was presented was published in JBJS Vol. 87-A, pp. 2649-2654, December 2005*

### ABSTRACT

#### BACKGROUND:

Idiopathic ulnar impaction syndrome can be defined as a degenerative condition of the ulnar aspect of the wrist in patients with congenital or dynamic positive ulnar variance without a history of fracture or premature physal arrest. The purpose of this study was to evaluate the clinical features of idiopathic ulnar impaction syndrome and the outcomes of ulnar shortening osteotomy for this group of patients.

#### METHODS:

Thirty-one wrists in twenty-nine patients with idiopathic ulnar impaction syndrome were treated with an ulnar shortening osteotomy. Ulnar variance was measured on an anteroposterior radiograph of the wrist, and radio-ulnar distance was measured

*continued*

### INTRODUCTION

Ulnar shortening osteotomy is a well-established procedure used primarily for patients with ulnar impaction syndrome associated with ulna-plus variance and/or a tear of the triangular fibrocartilage complex<sup>1,2</sup>. The rationale for the procedure is that extra-articular ulnar shortening unloads the ulnocarpal joint without violating the articular surface of the distal part of the ulna and has the effect of tightening the extrinsic ulnocarpal ligaments, thus stabilizing the distal part of the ulna and the lunotriquetral articulation<sup>3</sup>. Although the procedure seems to be relatively simple and straightforward, several recent reports on the technique reflect the difficulties that are sometimes encountered<sup>4-8</sup>. Here we describe, with a focus on the technical details, our procedure for conventional transverse shortening osteotomy combined with arthroscopy.

### SURGICAL TECHNIQUE

#### *Patient Positioning and Preparation*

After the administration of either an axillary block or general anesthesia, the patient is placed supine on the operating table and a pneumatic tourniquet is placed around the arm. The whole upper limb is prepared with standard antiseptic solutions and is draped free. For the arthroscopic procedure, a vertical traction device is set on the handtable, which is positioned so that it is draped outside of the operative field and can subsequently be removed in a sterile manner when it is time for the open osteotomy procedure. After removal of the handtable, the patient's arm is placed across his or her chest to expose the subcutaneous border of the ulna.

## Arthroscopy

Arthroscopy is indicated for patients who are seen to have cystic changes of the carpus on radiographs or evidence of a degenerative tear of the triangular fibrocartilage complex on magnetic resonance images. The arthroscopy is usually performed before the ulnar shortening osteotomy, to decrease the time of tourniquet use and to avoid the risk that the distraction that is necessary for the arthroscopy will jeopardize the osteotomy fixation. In patients with severe ulna-plus variance, however, a prior ulnar shortening osteotomy can facilitate placement of arthroscopic instruments in the ulnocarpal joint.

We use a vertical distraction arthroscopy tower, and the patient's long and ring fingers are placed in finger-traps to obtain more ulnar-side distraction. A towel is placed between the tower and the elbow and forearm to protect the ulnar nerve. Velcro straps are used to secure the arm and the forearm to the tower. The wrist is flexed 10° in accordance with the volar tilt of the distal radial articular surface, and 15 lb (6.8 kg) of distraction is applied. The anatomic landmarks are drawn at the Lister tubercle, extensor pollicis longus, extensor digitorum communis, and extensor carpi ulnaris (Fig. 1). After injection of 10 mL of saline solution through the 3-4 portal, the skin is incised longitudinally. A 2.9-mm small-joint arthroscope is placed into the 3-4 portal, and then the 4-5 portal is

established, with the outflow system in the 6R portal. A 2.9-mm motorized shaver in the 4-5 portal is used to débride inflamed synovium to visualize the joint.

Degenerative lesions associated with ulnar impaction syndrome almost always occur in the center of the articular disk. Arthroscopic treatment includes débridement of the unstable central portion of the articular disk, any lunotriquetral ligament tear, and/or the lunate and the triquetrum. If there is no obvious tear of the triangular fibrocartilage complex, the complex is palpated with the probe to check for normal trampoline-like tension, and any loss of tension is suggestive of wear or a peripheral tear. If a tear is identified, its unstable portion is débrided back to a stable rim, preferably with preservation of the peripheral 2 mm of the disk for stability. A radiofrequency ablation probe may be used to smooth the contour of the rim.

In patients seen to have cystic changes in the lunate and/or triquetrum on the preoperative radiograph and more than grade-III chondromalacia (definite fibrillation with fissuring of articular cartilage extending down to the subchondral bone) at arthroscopy, a subchondral microfracture of the involved carpal bone is performed. With the arthroscope in the 3-4 portal and the working instrument in the 6R portal, the crater is exposed after a cartilage flap, if present, is lifted and débrided. Then the crater is cleared, and,

## ABSTRACT | continued

on a lateral radiograph, with the forearm in neutral rotation, to evaluate any displacement of the ulnar head from the distal aspect of the radius. All patients were followed clinically and radiographically for a mean of thirty-two months.

## RESULTS:

An average preoperative ulnar variance of +4.6 mm (range, 2 to 7.5 mm) was reduced to an average of -0.7 mm (range, -4 to +1 mm) postoperatively. Preoperatively, the modified Gartland and Werley score was an average (and standard deviation) of  $69.5 \pm 7.6$ , with twenty-four wrists rated poor and seven rated fair. Postoperatively, the score improved to an average of  $92.5 \pm 8.0$ , with twenty-four wrists rated excellent; five, good; one, fair; and one, poor. Dorsal subluxation of the distal aspect of the ulna was found concomitantly in nine wrists, and it was found to be reduced by the shortening osteotomy. Seven patients had cystic changes in the carpal bones preoperatively, but these were not evident one to two years after the operation.

## CONCLUSIONS:

Ulnar shortening osteotomy improved wrist function in patients with idiopathic ulnar impaction syndrome and reduced the subluxation of the distal radioulnar joint, which is commonly found in these patients. Degenerative cystic changes of the ulnar carpal bones appear to resolve following the shortening osteotomy.

with a banana knife (Linvatec, Largo, Florida), multiple microfractures are made into the subchondral bone down to bleeding cancellous bone (Fig. 2).

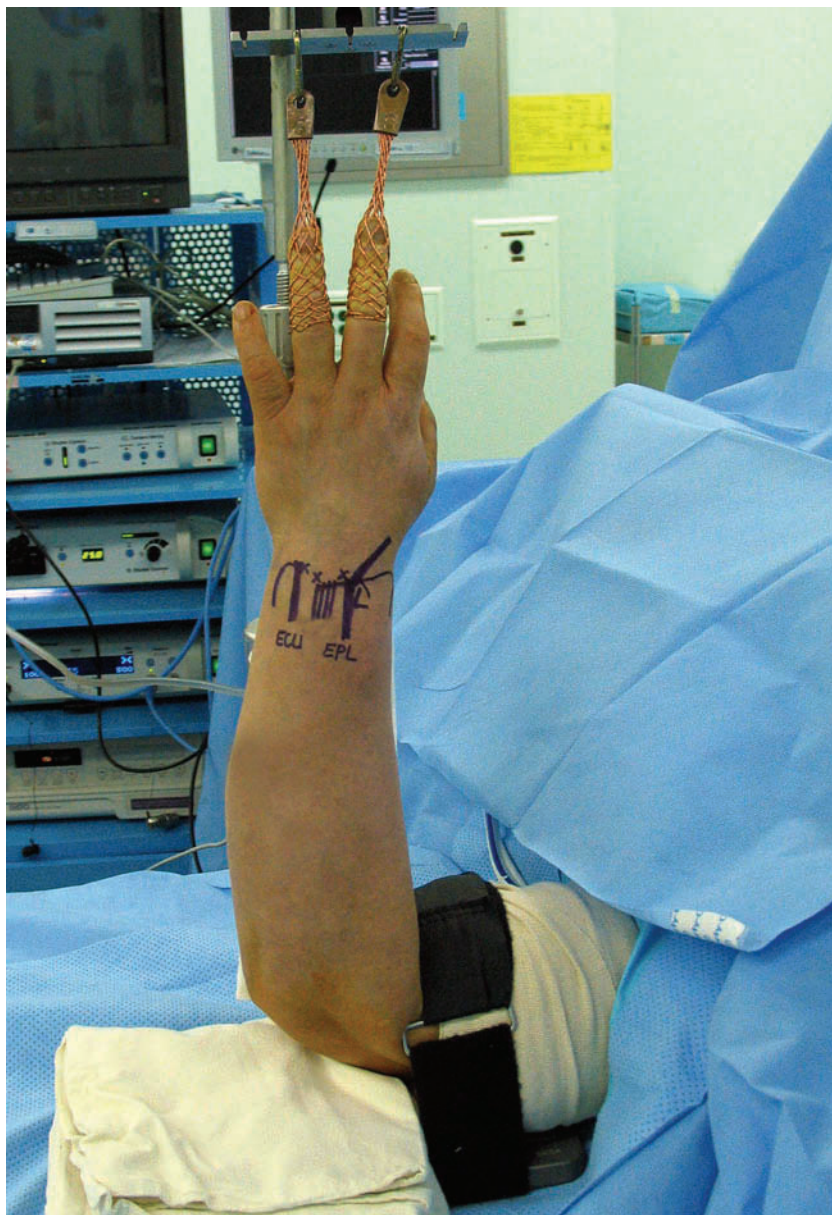Next, arthroscopic examination is performed through the radial and ulnar midcarpal portal to assess the congruity and stability of the lunotriquetral joint. The probe is inserted into the lunotriquetral articulation, and attempts are made to separate the two bones to assess joint stability. If no lunotriquetral instability is noted and the positive ulnar variance is minimal, an arthroscopic wafer procedure, which we do not routinely perform, may be an alternative to the ulnar shortening osteotomy. If there is evidence of lunotriquetral instability or an ulnocarpal ligament tear, an ulnar shortening osteotomy is the preferred approach to allow concurrent tightening of the extrinsic ligaments. It can be combined with fixation of the lunotriquetral joint with percutaneous placement of Kirschner wires, but that has not been necessary in our experience.

### *Ulnar Shortening Osteotomy*

A longitudinal incision is drawn on the skin along the subcutaneous border of the ulna, starting 1.5 in (3.8 cm) proximal to the tip of the ulnar styloid, according to the shape of the distal part of the ulna. Because the ulnar head and neck are not straight, bending of the plate may be necessary with a more distal incision. Bending of the plate can prolong the operation and make it difficult to

achieve correct compression of the osteotomy site. Placement of the plate on the straight part of the distal aspect of the ulna may allow one to avoid bending the plate. Furthermore, a more distal

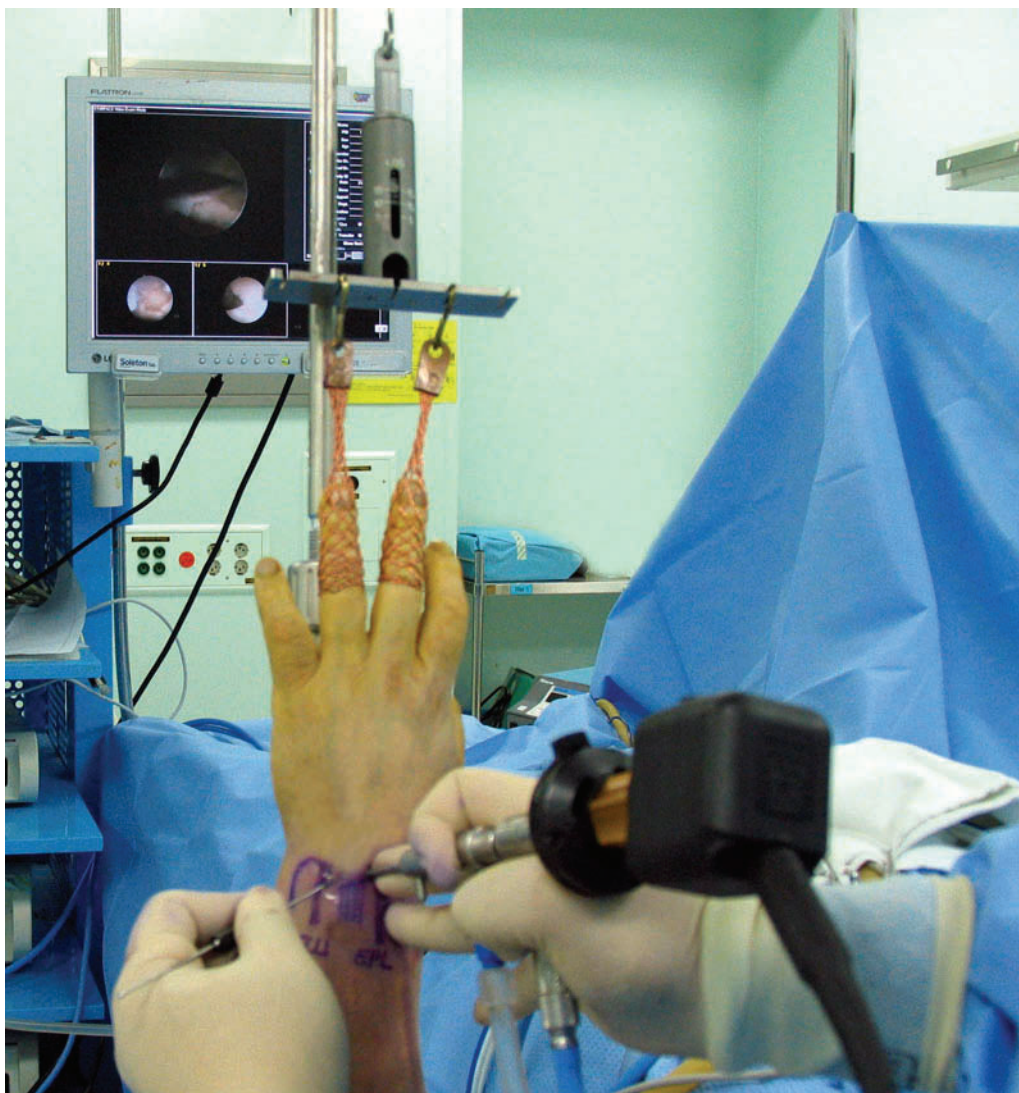
incision may injure the dorsal sensory branch of the ulnar nerve. One can easily recognize the straight part of the distal aspect of the ulna on an anteroposterior radiograph of the forearm. The in-



**FIG. 1**

An intraoperative photograph illustrating the arthroscopy setup for a left wrist. (L = Lister tubercle, EPL = extensor pollicis longus, ECU = extensor carpi ulnaris, and X = 6R, 4-5, and 3-4 portals from the left.)



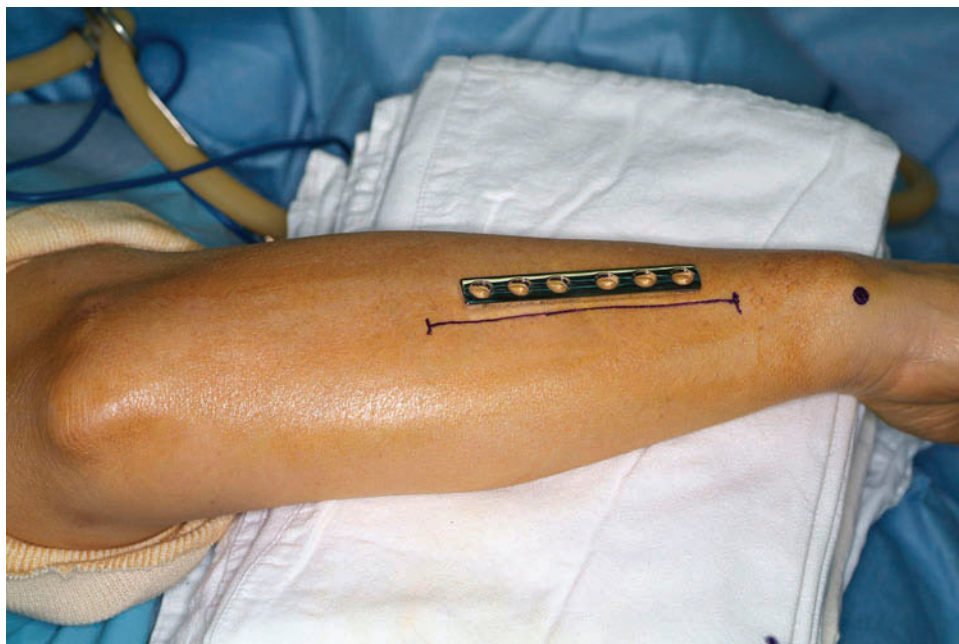
**FIG. 2**

An intraoperative photograph showing the arthroscopic approach for subchondral microfracture of the carpal bone with the arthroscope in the 3-4 portal and a banana knife in the 6R portal.

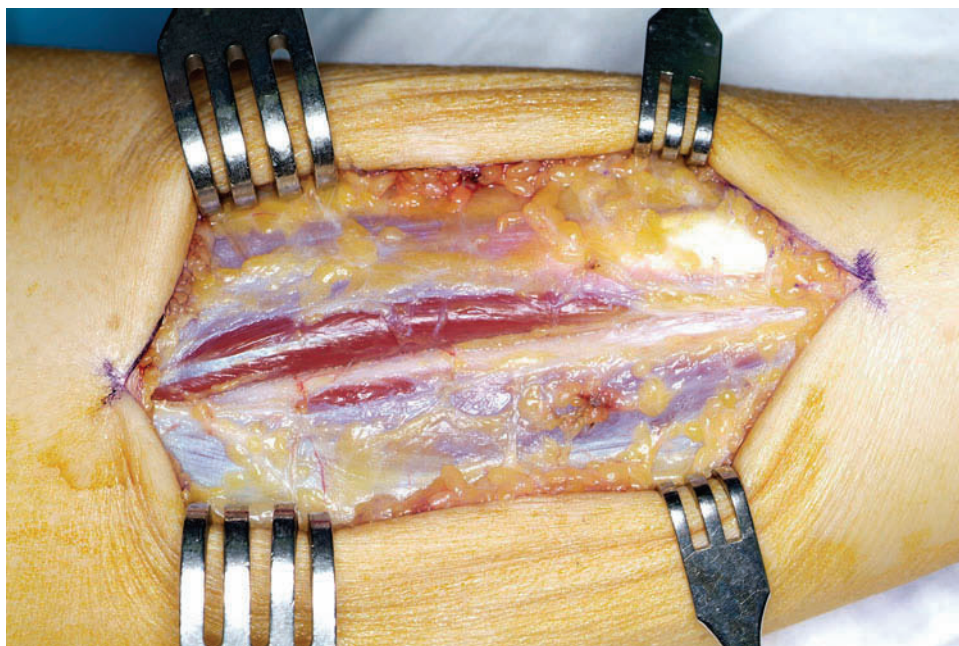
cision is made of sufficient length to allow application of a six-hole 3.5-mm standard compression plate (Stryker Trauma, Selzach, Switzerland), or a one-third tubular plate (Stryker Trauma) when the ulna is too small for a standard compression plate. The plate can be used to guide

the length of the incision (Fig. 3). The incision is made with use of a number-15 blade. The approach is made through the plane between the extensor carpi ulnaris and the flexor carpi ulnaris until the periosteum of the ulna is reached (Fig. 4). The periosteum is incised and elevated circum-

ferentially to the interosseous membrane, which is kept intact. Volar placement of the plate is preferred as that results in less irritation, especially in a thin patient or a person who works at a desk, because the plate will be covered with muscle bellies on the volar side of the forearm.

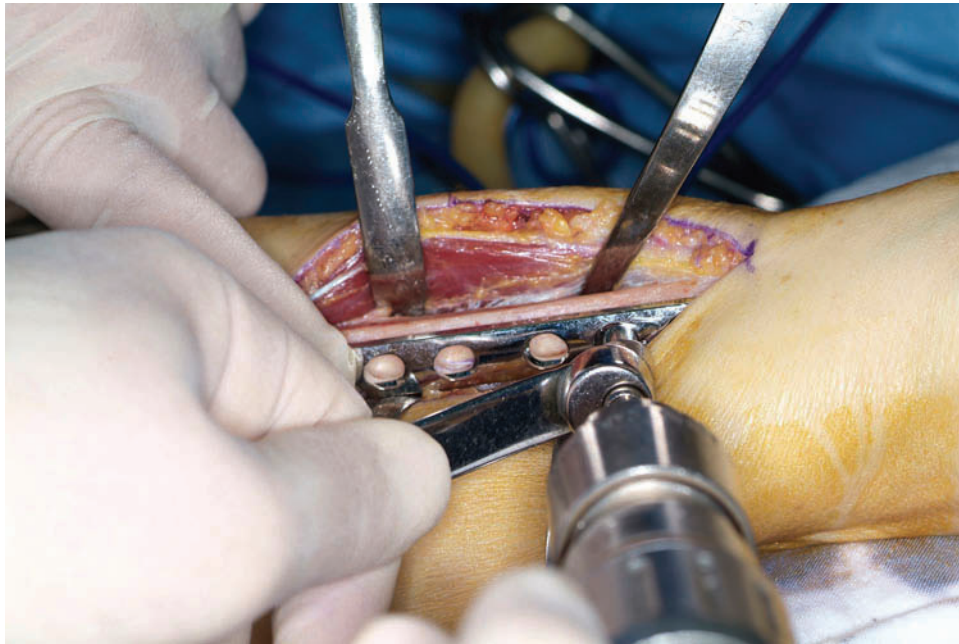
**FIG. 3**

Planning for the incision in a right ulna. The bullet point indicates the ulnar styloid process. Because of the curvature of the distal part of the ulna, the incision is designed to start 1.5 in (3.8 cm) proximal to the ulnar styloid.

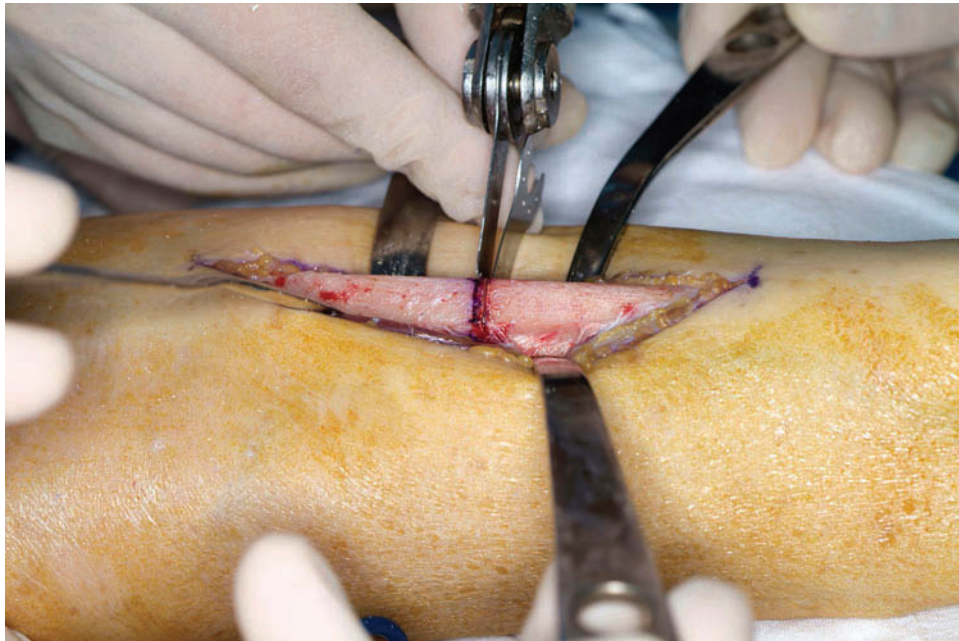
**FIG. 4**

The periosteum is reached through the plane between the extensor carpi ulnaris and the flexor carpi ulnaris.



**FIG. 5**

The second hole from the distal end is drilled before the osteotomy is done because it is difficult to screw the plate to the mobile distal fragment after the osteotomy has been completed.

**FIG. 6**

During the osteotomy, a free saw blade can be used as a guide for parallel cutting.

When the plate sits well on the surface, the second hole from the distal end is drilled for later insertion because it is diffi-

## CRITICAL CONCEPTS

### INDICATIONS:

Ulnar shortening osteotomy is indicated primarily for patients with ulnar impaction syndrome, which includes (1) a history of ulnar wrist pain that is worsened by rotation and ulnar deviation of the wrist with such activities as opening a jar, squeezing a wet towel, typing, or changing a gearshift, (2) a positive provocation test (an ulnocarpal stress test in which the wrist is deviated ulnarward and the forearm is pronated<sup>4</sup>), and (3) a positive ulnar variance with or without cystic changes of the carpus seen on plain radiographs.

Concomitant arthroscopy is indicated for patients who are seen to have cystic changes of the carpus on radiographs or evidence of a degenerative triangular fibrocartilage complex tear on magnetic resonance images.

### CONTRAINDICATIONS:

Ulnar shortening osteotomy is contraindicated for patients with advanced arthritis of the distal radioulnar joint, and this procedure alone is not recommended for wrists with severe structural abnormalities, such as Madelung deformity or severe malunion of the forearm or wrist, although the procedure may be combined with a corrective osteotomy in those instances<sup>10</sup>.

cult to fix the plate to a mobile distal fragment after the osteotomy (Fig. 5). With care taken to ensure that the plate is parallel to the bone for its whole length, the osteotomy site and the amount of bone resection are marked by placing the distal osteotomy cut at a point midway between the third and fourth screw-holes. A longitudinal mark on the ulna at the site of the osteotomy can help to maintain correct rotation of the two fragments. The amount of bone to be removed is determined on the preoperative anteroposterior radiograph. We usually try to obtain a final ulnar variance of between 0 and -1 mm. Two parallel osteotomy cuts are made along the marked line with a small oscillating saw and adequate irrigation with saline solution to reduce heat

production<sup>9</sup>. One must consider the saw-blade thickness when calculating the osteotomy cuts; we use a saw blade from Hall Surgical (Linovatec, Largo, Florida), the thickness of which is 0.4 mm. Thus, 0.8 mm of ulnar shortening is accomplished by the two osteotomy cuts alone. The distal osteotomy is completed first, which makes the second cut through the proximal fragment easier. A free saw blade can be used as a guide for parallel cutting (Fig. 6). The resected bone segment is then removed, the plate is attached to the distal ulnar fragment, and a screw is inserted into the pre-drilled second hole. An assistant holds the hand and forearm and applies manual compression across the osteotomy while maintaining alignment with the previously made longitudinal

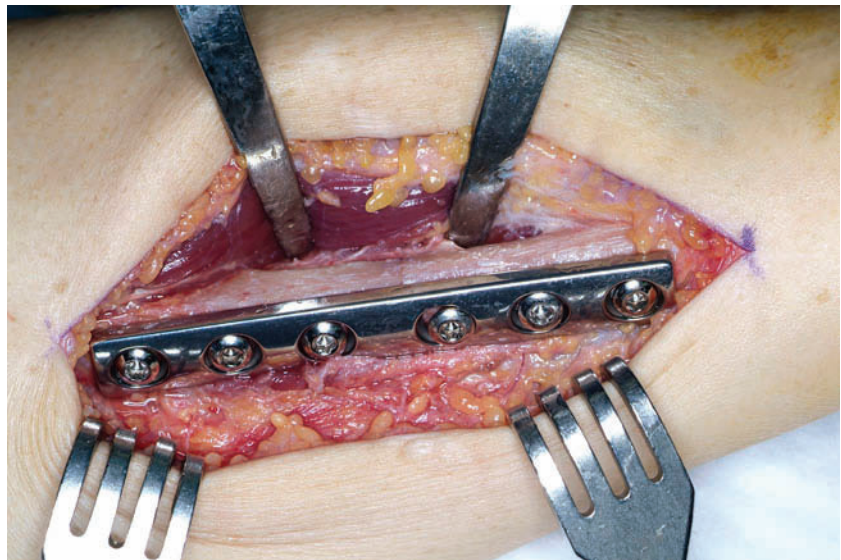


FIG. 7

The osteotomy site is compressed by a single distal loading screw.



mark or groove, and the operating surgeon holds the plate and the proximal ulnar fragment with a bone-holding clamp. The proximal two holes are drilled, and screws are placed. After the bone-holding clamp is released, the third proximal hole is also fixed with a screw. Then the distal hole nearest to the osteotomy site is drilled by using an eccentric drill guide and is tapped; after slight loosening of the previously inserted middle distal screw,

the compression screw is inserted and is tightened to achieve axial compression of the bone as the screw head slides downward along the geometry of the screw hole. This one load screw usually achieves sufficient compression across the osteotomy site, and a neutral screw is then inserted into the remaining hole (Figs. 7, 8-A, and 8-B). If necessary, the most distal screw can also be used as a second load screw. The AO tension device may be used, but we do

not use it because this dynamic-compression-plate technique achieves sufficient compression across the ulna, and the tensioning device requires a more extensive incision. Any resected bone can be morselized and used as local bone graft around the osteotomy site. The wound is irrigated and is closed in layers, and the skin is closed by an intracuticular suture. Use of a drain is optional. A compression dressing and a long-arm splint are applied.

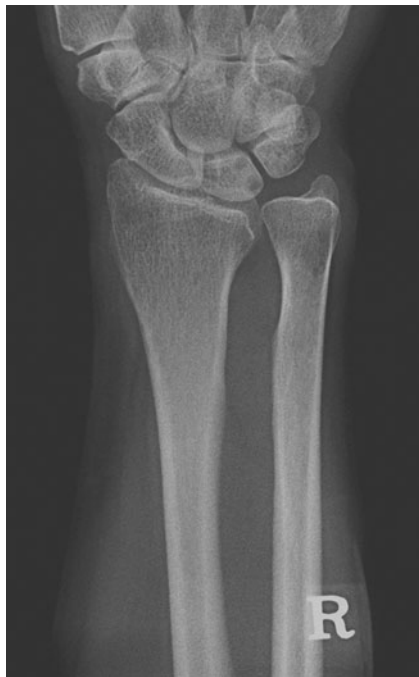

FIG. 8-A

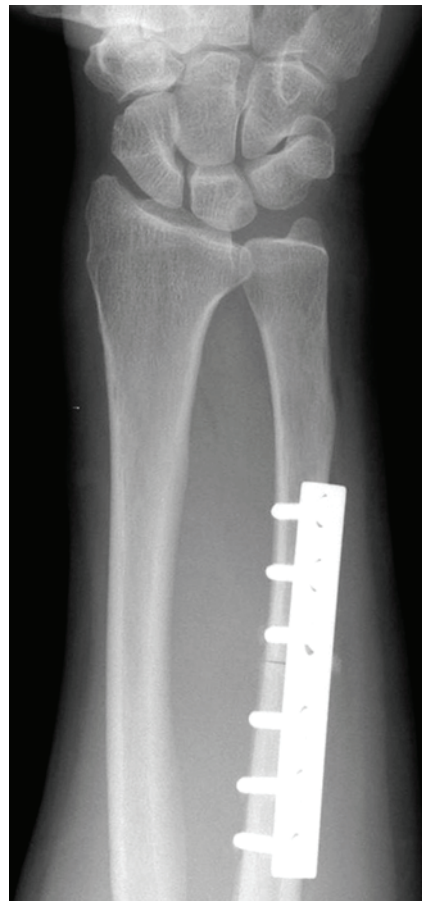

FIG. 8-B

Preoperative and immediate postoperative radiographs of the patient shown in Figures 3 to 7. Note the curvature of the distal part of the ulna. To prevent unnecessary bending, the plate is placed 1.5 in (3.8 cm) from the ulnar styloid process.

### CRITICAL CONCEPTS | continued

#### PITFALLS:

- Within the distal incision, care should be taken to avoid the dorsal sensory branch of the ulnar nerve, which usually crosses the wrist from volar to dorsal just distal to the ulnar styloid at an angle of 45° to the long axis of the forearm.
- Vigorous irrigation with saline solution is necessary to prevent heat necrosis of the osteotomy site.
- Failure to obtain adequate fixation can result in nonunion of the osteotomy site.
- Placement of the plate to the dorsal surface of the ulna can cause tendinitis of the extensor carpi ulnaris or irritation from a prominent screw head and plate under the thin dorsal skin.

#### AUTHOR UPDATE:

There have been no changes in the surgical technique since the time of publication of the original paper.

## AFTERCARE

The arm is elevated for twenty-four hours, and the patient is encouraged to move the fingers as much as possible. The patient is discharged from the hospital on the second postoperative day, after the wound is examined and the bandage is changed to a light dressing. Ten to fourteen days later, the sutures are removed and the patient starts range-of-motion exercises of the elbow and wrist and is fitted with a removable long-arm splint (an ulnar forearm-based thermoplastic orthosis attached with Velcro straps), which is usually worn for an additional four weeks.

Goo Hyun Baek, MD  
Moon Sang Chung, MD  
Young Ho Lee, MD

Hyun Sik Gong, MD  
Sanglim Lee, MD  
Hyung Ho Kim, MD  
Department of Orthopaedic Surgery, Seoul  
National University College of Medicine, 28  
Yongon-Dong, Chongno-Gu, Seoul 110-744,  
South Korea. E-mail address for G.H. Baek:  
ghbaek@snu.ac.kr

The authors did not receive grants or outside funding in support of their research for or preparation of this manuscript. They did not receive payments or other benefits or a commitment or agreement to provide such benefits from a commercial entity. No commercial entity paid or directed, or agreed to pay or direct, any benefits to any research fund, foundation, educational institution, or other charitable or nonprofit organization with which the authors are affiliated or associated.

doi:10.2106/JBJS.F.00320

## REFERENCES

1. Friedman SL, Palmer AK. The ulnar impaction syndrome. *Hand Clin.* 1991;7:295-310.
2. Boulas HJ, Milek MA. Ulnar shortening for tears of the triangular fibrocartilaginous complex. *J Hand Surg [Am].* 1990;15:415-20.
3. Nagle DJ. Arthroscopic treatment of degenerative tears of the triangular fibrocartilage. *Hand Clin.* 1994;10:615-24.
4. Rayhack JM, Gasser SI, Latta LL, Ouellette EA, Milne EL. Precision oblique osteotomy for shortening of the ulna. *J Hand Surg [Am].* 1993;18:908-18.
5. Wehbe MA, Cautilli DA. Ulnar shortening using the AO small distractor. *J Hand Surg [Am].* 1995;20:959-64.
6. Chen NC, Wolfe SW. Ulna shortening osteotomy using a compression device. *J Hand Surg [Am].* 2003;28:88-93.
7. Horn PC. The long ulnar sliding osteotomy. *J Hand Surg [Am].* 2004;29:871-6.
8. Darlis NA, Ferraz IC, Kaufmann RW, Sotereanos DG. Step-cut distal ulnar shortening osteotomy. *J Hand Surg [Am].* 2005;30:943-8.
9. Firoozbakhsh K, Moneim MS, Mikola E, Haltom S. Heat generation during ulnar osteotomy with microsagittal saw blades. *Iowa Orthop J.* 2003;23:46-50.
10. Oskam J, Bongers KM, Karthaus AJ, Frima AJ, Klasen HJ. Corrective osteotomy for malunion of the distal radius: the effect of concomitant ulnar shortening osteotomy. *Arch Orthop Trauma Surg.* 1996;115:219-22.