A DISSERTATION

FOR THE DEGREE OF DOCTOR OF PHILOSOPHY

Evaluation of Bronchial Wall Thickness using High Resolution CT in Healthy and Asthmatic Cats

정상 및 천식 고양이에서

고해상도 전산화 단층 촬영을 통한 기관지 벽 두께 평가

by

Sungjun Won

(Major in Veterinary Clinical Sciences)

DEPARTMENT OF VETERINARY MEDICINE

GRADUATE SCHOOL

SEOUL NATIONAL UNIVERSITY

FEBRUARY, 2016

Evaluation of Bronchial Wall Thickness using High Resolution CT in Healthy and Asthmatic Cats

by

Sungjun Won

Supervised by
Professor Junghee Yoon

Thesis
Submitted to the Faculty of the Graduate School
of Seoul National University
in partial fulfillment of the requirements
for the degree of
Doctor of Philosophy in Veterinary Medicine

October 2015

Major in Major in Veterinary Clinical Sciences
Department of Veterinary Medicine
Graduate School
Seoul National University
December 2015

ABSTRACT

Evaluation of Bronchial Wall Thickness using high resolution CT in Healthy and Asthmatic Cats

by

Sungjun Won

Supervised by
Professor Junghee Yoon

Feline asthma syndrome (FAS) is a respiratory disease with clinical symptoms such as wheezing and coughing due to airway hyper-responsiveness. The airway hyper-responsiveness is generally caused by allergic reactions. FAS is very similar to asthma syndrome in human. Cat has been used as animal model of asthma for human medicine. Asthma in human can be diagnosed with pulmonary function tests or methacholine challenge test. However, voluntary pulmonary function tests are impossible for animals such as cats. The gold standard for FAS is currently unavailable. In veterinary medicine, the diagnosis of FAS can be through excluding other diseases such as infectious disease or cardiac disease. In human medicine, bronchial walls can be measured and evaluated through high-resolution

computed tomography (HRCT) to assess the severity of asthma or therapeutic response of patient with asthma. However, HRCT has not been used to measure bronchial walls of cats. Therefore, the objective of this study was to use HRCT to determine the thickness of bronchial walls of clinically diagnosed asthmatic cats compared to that of clinically healthy cats.

Effects of different ventilation techniques under general anesthesia on the bronchial lumen and bronchial wall were evaluated. Under general anesthesia, bronchial lumen to the adjacent artery ratio (BA ratio), the ratio of bronchial wall thickness to whole bronchial diameter (TD ratio) and ratio of bronchial wall thickness to adjacent pulmonary artery (TA ratio) were measured in positive pressure inspiration and in end expiration. To evaluate the usefulness of HRCT, computed tomographic scans were performed under both high resolution and conventional conditions using the same experimental animals. Images and measured indices obtained from conventional CT (CCT) and HRCT were compared and analyzed. To compare HRCT and CCT, TD ratio, percentage of bronchial wall area to whole bronchial area (WA%) and TA ratio were measured. Coefficient of variation was performed in values from HRCT and CCT to compare size of variation between two groups. To compare reproducibility in two observers, intraclass correlation coefficient (ICC) was performed in TD ratio, WA% and TA ratio in CCT and HRCT separately. To determine the differences of clinically healthy cats and asthmatic cats, TD ratio, WA%, and TA ratio were measured. Images of 64 bronchi from 16 healthy cats and 16 bronchi from 4 clinically asthmatic cats were obtained.

In positive pressure induced inspiration, mean BA ratio was 0.87 ± 0.12. In end-expiration, mean BA ratio was 0.74 ± 0.11. BA ratio between the two different ventilation techniques were significantly (p<0.01) different. The mean TD ratio during positive pressure inspiration and end expiration were 0.18 ± 0.02 and 0.21 ± 0.03 and were significantly different (p<0.01). The mean TA ratio during positive pressure inspiration and end expiration were 0.25 ± 0.05 and 0.26 ± 0.06 and were not significantly different. The coefficient of variation from indices of HRCT was lower than that of CCT. The ICC of HRCT in TD ratio, WA% and TA ratio between two observers was higher than ICC of CCT. In addition, the thickness of bronchial wall measured from the axial image at same level of both HRCT and CCT was manually measured to compare image qualities between CCT and HRCT. Due to delineation of images, bronchial wall thickness measured with HRCT was significantly thinner than that with CCT. The bronchial walls and pulmonary arteries were measured in clinically healthy 16 cats and clinically asthmatic 4 cats under general anesthesia with positive pressure inspiration using HRCT. As a result, the mean TD ratio, WA%, and TA ratio in healthy cats were 0.18 ± 0.02, 62 % ± 6.27 %, and 0.25 ± 0.05, respectively. Under the same condition, the mean TD ratio, WA%, and TA ratio in asthmatic cats were 0.22 ± 0.24, 68.98 % ± 5.57, and 0.37 ± 0.06, respectively. The three indices in clinically diagnosed asthmatic cats were significantly higher than those in healthy cats (p<0.01). However, no significant difference was found in gender or age between the two groups of cats.

These results revealed that HRCT could be a useful method to assess bronchial wall thickness of cats with FAS. And among the four indices, TA ratio showed

higher reproducibility, sensitivity and specificity. Although the limitation of this study was that asthma group of cats was clinically diagnosed with asthmatic syndrome, the evaluation of bronchial wall thickness by HRCT could be very useful for the diagnosis of FAS.

Keywords: high resolution computed tomography, cat, bronchial wall thickness, asthma

Student number: 2011-30492

Contents

List of Abbreviations

BA ratio	Bronchial lumen to artery ratio
CBC	Complete blood count
CT	Computed tomography
CCT	Conventional computed tomography
$ETCO_2$	End tidal carbon dioxide
FAS	Feline asthma syndrome
FEV1	Forced expiratory volume in 1 second
HRCT	High resolution computed tomography
HU	Hounsfield unit
TA ratio	Bronchial wall thickness to adjacent pulmonary artery ratio
TD ratio	Bronchial wall thickness to whole bronchial diameter ratio
WA%	The percentage of wall area to whole bronchial area

GENERAL INTRODUCTION

In veterinary medicine, feline asthma syndrome (FAS) has been used to describe a respiratory condition in cat characterized by the combination of recurrent episode of paroxysm coughing, wheezing, and dyspnea that respond to glucocorticoid therapy (Corcoran *et al.*, 1995). For several reasons, it has been impossible to diagnose asthma clearly in veterinary medicine without invasive biopsy or post-mortem examination. The diagnosis of FAS is typically based on changes on plain radiography and therapeutic response to glucocorticoid after excluding other known causes of respiratory distress, such as pneumonia, neoplasia, infectious bronchitis, and cardiac disease (Adamama-Moraitou *et al.*, 2004; Padrid, 2000).

High resolution computed tomography (HRCT) is a useful non-invasive diagnostic modality to determine bronchial luminal changes in bronchiectasis and bronchial wall thickness changes in asthmatic patients of human (Carroll *et al.*, 1993; Young *et al.*, 1991). Since bronchial wall is a small structure, it is difficult to make clear images from CT scan depending on its generation. For this reason, high resolution computed tomography (HRCT), a scan protocol that maximizes the spatial resolution while minimizing artifact of volume using bone reconstruction algorithm in place of lung algorithm, can be used (Webb *et al.*, 1984). In human medicine, HRCT is the most useful tool to identify bronchial disease and pulmonary disease without being invasive. In veterinary field, HRCT has been used

to assess bronchial lumen to artery ratio in healthy cats or to diagnose idiopathic pulmonary fibrosis in dogs (Johnson *et al.*, 2005; Reid *et al.*, 2012). In veterinary medicine, diagnosis of several bronchial diseases is dependent on conventional radiography. Respiratory diseases such as canine chronic bronchitis, bronchiectasis, and feline asthma syndrome (FAS) have been diagnosed with the method of exclusion (Padrid, 2000). Recently, computed tomography (CT) examination has been performed routinely in veterinary clinical field to assess the bronchus. However, CT is only used to evaluate BA ratio in bronchial diseases. Bronchial lumen to adjacent pulmonary arterial ratio (BA ratio) with computed tomography (CT) was studied in healthy dogs and BA ratio in healthy cat with CT was also established (Cannon *et a*l., 2009; Reid *et al.*, 2012). The BA ratio in specific breed such as brachycephalic dogs was studied (Won *et al.*, 2015). And quantitative assessment with BA ratios by CT in dogs with bronchiectasis was also studied. There was marked increase of BA ratio in dogs with bronchiectasis which was diagnosed by bronchoscopy or necropsy definitely. Therefore, availability of BA ratio in disease model was approved (Cannon *et al.*, 2013). But, in bronchial disease with luminal thickening such FAS, it has limitation to evaluate by BA ratio only.

In human medicine, CT has been used to assess bronchial wall thickness in various diseases, including asthma and chronic bronchitis. In human patients, various indices have been measured by CT examination, including TD ratio (wall thickness T divided by the total diameter of the bronchus D), wall area percentage (WA%, the ratio of the bronchial wall area and the total area of bronchial wall area

and bronchial lumen area), and the ratio to compare the bronchial wall thickness to the adjacent pulmonary artery diameter (Boulet *et al.*, 1995; de Jong *et al.*, 2004; Niimi *et al.*, 2000). However, such study has not been carried out in the veterinary field. Only one study has reported bronchial reactiveness to histamine in a canine model (McNamara *et al.*, 1992).

Therefore, the aim of this study was to determine whether HRCT could produce more accurate results with higher reproducibility than conventional CT (CCT) in the assessment of feline bronchial wall thickness (Chapter 1). The aim of second study was to determine whether bronchial indices such as BA ratio, TD ratio and TA ratio of healthy cats using single breath hold technique with positive pressure were different from those obtained with end expiration and manual hyperventilation with HRCT. (Chapter 2). According to result of previous two study, the objectives of this study were: 1) use HRCT to determine the bronchial wall thickness in healthy cats, and 2) identify bronchial wall changes between healthy cats and clinically diagnosed asthmatic cats (Chapter 3).

Chapter 1: Bronchial wall thickness comparison with high resolution computed tomography and conventional computed tomography

1. INTRODUCTION

In veterinary medicine, computed tomography (CT) has been established as one of the most common diagnostic modalities. CT seems to be superior in diagnosing diseases involving lung parenchyma and mediastinal structures. Diagnosis of bronchial disease with CT has been commonly used in human medicine. The bronchial lumen to pulmonary artery diameter ratio (BA ratio), one of criteria to quantify airway abnormalities, is widely used in human medicine (Kim *et al.*, 1995). In the past, bronchial disease in veterinary medicine was rarely dependent on laboratory examination or conventional radiographic examination. Instead, it was based on the diagnosis of exclusion. However, CT scan is used commonly recently in veterinary medicine.

In veterinary medicine, diagnosis of several bronchial diseases is dependent on conventional radiography. Respiratory diseases such as canine chronic bronchitis, bronchiectasis, and feline asthma syndrome (FAS) have been diagnosed with the method of exclusion (Padrid, 2000). Recently, computed tomography (CT) examination has been performed routinely in veterinary clinical field to assess the bronchus. However, CT is only used to evaluate BA ratio in

bronchial diseases with luminal thickening.

Bronchial lumen to adjacent pulmonary arterial ratio (BA ratio) with computed tomography (CT) was studied in healthy dogs and BA ratio in healthy cat with CT was also established (Cannon *et a*l., 2009; Reid *et al*., 2012). The BA ratio in specific breed such as brachycephalic dogs was studied (Won *et al.*, 2015). In addition, quantitative assessment with BA ratios by CT in dogs with bronchiectasis was also studied. There was marked increase of BA ratio in dogs with bronchiectasis which was diagnosed by bronchoscopy or necropsy definitely. Therefore, availability of BA ratio in disease model was approved (Cannon *et al.*, 2013). However, in bronchial disease with luminal thickening such FAS, it has limitation to evaluate by BA ratio only.

In human medicine, CT has been used to assess bronchial wall thickness in various diseases, including asthma and chronic bronchitis. In human patients, various indices have been measured by CT examination, including TD ratio (wall thickness T divided by the total diameter of the bronchus D), wall area percentage (WA%, the ratio of the bronchial wall area and the total area of bronchial wall area and bronchial lumen area), and the ratio to compare the bronchial wall thickness to the adjacent pulmonary artery diameter (Boulet *et al.*, 1995; de Jong *et al.*, 2004; Niimi *et al.*, 2000). However, such study has not been carried out in the veterinary field. Only one study has reported bronchial reactiveness to histamine in a canine model (McNamara *et al.*, 1992).

High resolution computed tomography (HRCT) is a useful non-invasive

diagnostic modality to determine bronchial luminal changes in bronchiectasis and bronchial wall thickness changes in asthmatic patients of human (Carroll *et al.*, 1993; Young *et al.*, 1991).

Since bronchial wall is a small structure, it is difficult to make clear images from CT scan depending on its generation. For this reason, high resolution computed tomography (HRCT), a scan protocol that maximizes the spatial resolution while minimizing artifact of volume using bone reconstruction algorithm in place of lung algorithm, can be used (Webb *et al.*, 1984).

In human medicine, HRCT was widely used in diagnosis of asthma and chronic obstructive pulmonary disease (Herold *et al.*, 1991; Mclean *et al.*, 1998). Optimizing spatial resolution by employing the narrowest feasible collimation beam and a high spatial frequency reconstruction algorithm has improved resolution such that features of 100-200 μm size can be identified, allowing assessment of small airways in the region of 1.5-2 mm diameter. Airway wall thickening was noted in post mortem studies of asthmatic patients and the development of HRCT had provided a potential non-invasive technique for its measurement in vivo (Carroll *et al.*, 1993). A comparative study about bronchial wall thickness value using HRCT and histological bronchial wall thickness value using planimetry has been reported in human medicine (Bankier *et al.*, 1996).

In human medicine, HRCT is the most useful tool to identify bronchial and pulmonary diseases without being invasive. In veterinary field, HRCT has been used to assess bronchial lumen to artery ratio in healthy cats or to diagnose

idiopathic pulmonary fibrosis in dogs (Johnson *et al.*, 2005; Reid *et al.*, 2012). However, HRCT is not commonly used in clinical field yet. Moreover, bronchial wall thickness of cat using HRCT has not been reported in veterinary medicine yet.

Therefore, the aim of this study was to determine whether HRCT could produce more accurate results with higher reproducibility than conventional CT (CCT) in the assessment of feline bronchial wall thickness. The first hypothesis was that bronchial wall thickness measurement using CCT was not accurate because the deviation was larger due to low resolution. The second hypothesis was that the reproducibility and reliability of HCRT were higher than those of CCT.

2. MATERIALS AND METHODS

2-1. Experimental animals

Sixteen client-owned cats, presented to the Irion Animal Hospital, Seoul, Korea, over a period of 6 month (November 2014-May 2015) were included in the study. The study population consists of client owned clinically healthy cats. All of these cats were undergoing minor dental treatment and all of owners of these cats were participated in this study voluntarily. The mean age of cats was 3.8 years (range 1-7 years) with a mean body weight of 4.0kg (range 2.8-6.0 kg). Fifteen cats were Domestic short hair and 1 cat was Persian cat. The detailed information of experimental animals about breed, gender, body weight and age was described (Table1). All cats were considered clinically healthy except minor dental disease such as periodontitis, by the owners at the time of the investigation and this observation was supported by findings on physical examination, complete blood cell count, serum chemistry and thorax radiography. After CT examination, microscopic examination via tracheal washing was performed and animal with suspected infectious condition was excluded. In addition, cats with abnormal CT findings were excluded.

2-2. Animal preparation and anesthesia

The animals were fasted approximately 8 hours for general anesthesia. Twenty four gauged intravenous catheter was placed in cephalic vein for propofol (Provive® 1%, Myungmoon Pharm. Co., Ltd., Seoul, Korea) and iohexol (Omnihexol®, Korea United Pharm. Inc., Seoul, Korea) injection. The antibiotic for minor dental treatment was administrated. Propofol was injected rapidly (6 mg/ kg, IV) for induction. The tracheal tube was intubated and anesthesia was maintained with isoflurane (Ifran®, Hana Pharm. Co. Ltd., Seoul, Korea) and oxygen. Heart rate, respiratory rate, body temperature and end tidal carbon dioxide (EtCo2) were monitored continuously during anesthesia. Minor dental treatment was performed after CT examination.

2-3. CT examination

2-3-1. General CT scan

Studies were performed with 4 channel CT scanner (Lightspeed Plus®, General Electric Medical System, CA, USA). The thoracic CT images of study were obtained in sternal recumbency. CT power injector (Mallinckrodt®, Liebel-Flarsheim, OH, USA) was used to control injection of contrast media. Contrast media was infused for 20 seconds and infused volume was 600 mgI/kg. Single breathe hold technique was performed that airway pressure maintained at 15cm of water to the airway through an endotracheal tube. Positive pressure was maintained

during the all CT scan.

2-3-2. High resolution computed tomography (HRCT) and conventional thoracic CT

First CT scan was performed using high resolution technique: 1.25 mm thick transverse images spaced 5 mm apart. CT images were acquired and reconstructed using a bone algorithm. The scan time was 1 second, kV 120 and mAs 200.

Second helical scan was performed with same CT scanner using detector-row width 1.25 mm (4 x 1.25 mm), 0.75:1 pitch, 120 kV tube potential and 230 mA tube current. Scan was performed 1.25 mm sliced thickness and spacing 1.25 mm.The CT images were acquired and reconstructed using a lung algorithm. HRCT and routine CT scans were performed in same animal in order.

2-4. Image analyses

Analysis of DICOM CT images was performed using a commercially available viewing and analysis software (Spectra®, Infinitt Healthcare Co. Ltd., Seoul, Korea). All measurements were obtained on contrast enhanced transverse images, using moderately edge enhancing reconstruction algorithm at the lung

window (window width = 1500 Hounsfield unit (HU), window level = -600 HU). All measurements were performed with image magnification of 1000%.

2-4-1. Evaluation bronchial wall indices

Bronchial lumen, entire bronchial diameter and adjacent arterial diameter were measured in four locations: left cranial, left caudal, right cranial and right caudal lung lobes. Right middle lung lobe was excluded because of bronchus of right middle lung lobe was visible parallel in transverse image. Therefore bronchial lumen diameter could be obtained but exact bronchial wall thickness could not be obtained. The caudal part of left cranial lobe was also excluded cause of lacking reproducibility and image quality.

A second segmental bronchus from the primary bronchus to each lobe was evaluated and the secondary bronchus that was best visualized, was measured. Pulmonary artery, bronchial lumen and whole bronchial diameter were measured entire hyperdense region associated with wall and artery. All measurements were tried to caliper bronchi or arteries those were most circular. However, if circular bronchus and artery were not identified, the oval representing bronchus and artery were measured in its smallest diameter to avoid any effect of obliquity in determining the exact diameter (Figure 1).

By measuring the overall bronchial diameter, bronchial lumen and adjacent artery, total four values were calculated (Figure 2). The bronchial lumen to

artery ratio (BA ratio) was calculated, which is bronchial diameter divided by the diameter of the adjacent artery. Because of bronchial wall thickness is relatively small values than other values, measuring bronchial wall thickness directly was could be erroneous. Therefore, wall thickness (T) was derived indirectly from overall (D) and luminal (L) diameter of bronchus (T = (D-L)/2). Bronchial wall to whole bronchial diameter ratio (TD ratio) was calculated by bronchial wall thickness (T) divided by diameter of adjacent whole bronchial diameter (D). The third measurement was the percentage of total airway cross sectional area (WA%), which is the area of the lumen to that of overall bronchus. Bronchial wall thickness to pulmonary artery ratio (TA ratio) was calculated by bronchial wall thickness (T) divided by diameter of adjacent pulmonary artery (A). These four calculated values were as follows (Figure 3).

All these measurements were acquired from HRCT and CCT scan separately, and two investigators measured all values independently for analysis of reproducibility.

2-4-2. Evaluation of bronchial wall thickness

To compare HRCT and CCT, bronchial wall thickness was measured directly in axial image of same position (Figure 4). All measurements were obtained using moderately edge enhancing reconstruction algorithm at lung window (window width = 1500 HU, window level = -600 HU). All measurements were performed with image magnification of 1000%.

Table 1. Age, body weight, gender and breed of all experimental animals

Number	Age	Body weight (kg)	Gender	Breeds
1	4	5.4	castrated male	domestic shorthair
2	6	5.5	castrated male	domestic shorthair
3	5	3.8	spayed female	Persian
4	7	4.9	spayed female	domestic shorthair
5	1	3.0	spayed female	domestic shorthair
6	1	3.0	spayed female	domestic shorthair
7	1	2.8	spayed female	domestic shorthair
8	3	3.9	spayed female	domestic shorthair
9	6	3.3	castrated male	domestic shorthair
10	6	4.9	spayed female	domestic shorthair
11	3	3.3	spayed female	domestic shorthair
12	2	3.3	spayed female	domestic shorthair
13	6	5.0	castrated male	domestic shorthair
14	3	2.8	castrated male	domestic shorthair
15	3	6.0	castrated male	domestic shorthair
16	4	4.0	castrated male	domestic shorthair

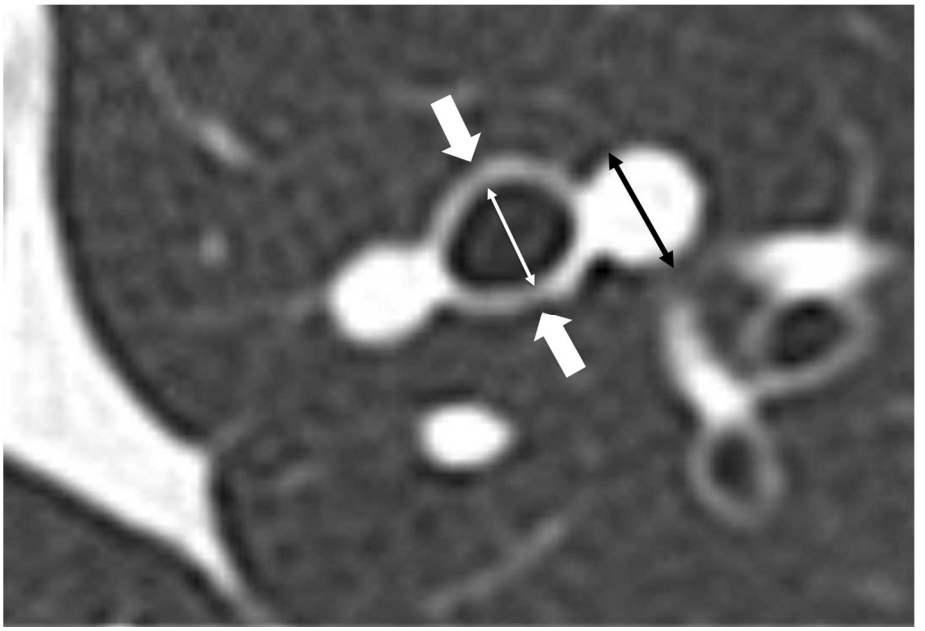

Figure 1. High resolution computed tomography image of the caudal lung lobe. The whole diameter (thick arrows) and internal diameter (thin white arrows) of caudal bronchus and the diameter of the adjacent pulmonary artery (black thin arrow) in axial image were measured to determine the BA ratios. The patient's left is to the right of the images in this paper.

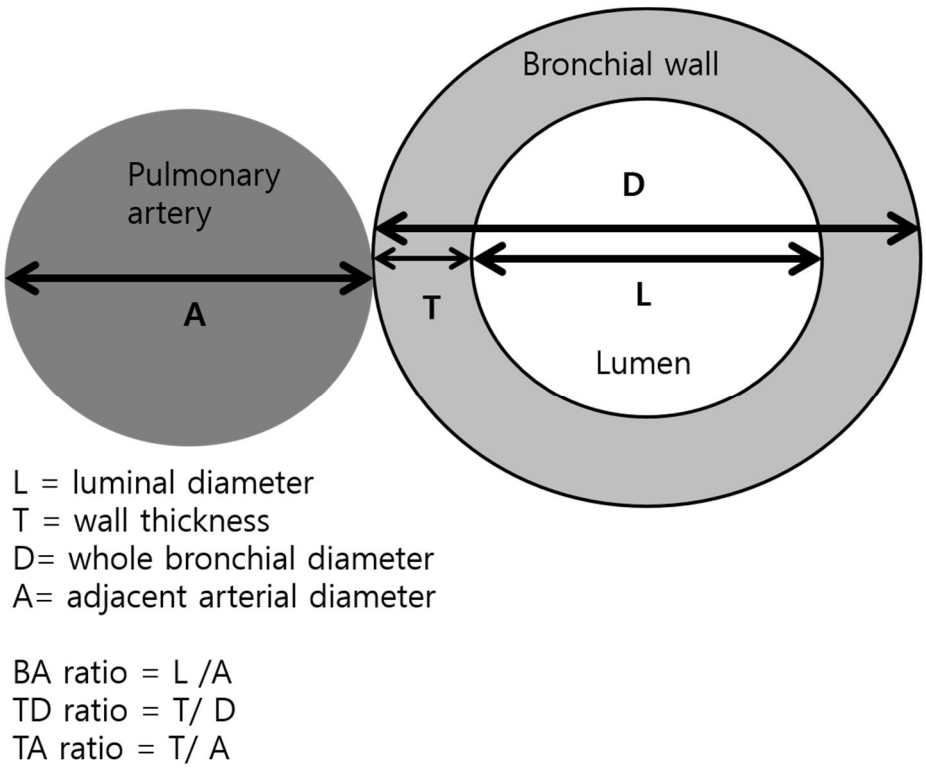

Figure 2. Measurement schemes of bronchial lumen, wall thickness and adjacent pulmonary artery. The calculation of bronchial wall and lumen were described.

$$T = \frac{D - L}{2}$$

BA ratio = L/A

TD ratio = T/ D

TA ratio = T/ A

$$\text{WA\%} = \left[\frac{\pi\left(\frac{D}{2}\right)^2 - \pi\left(\frac{L}{2}\right)^2}{\pi\left(\frac{D}{2}\right)^2}\right] \times 100$$

Figure 3. All calculated indices of bronchial lumen and bronchial wall thickness in this study. T = wall thickness, L = lumen diameter, D = overall bronchial diameter, A = diameter of adjacent pulmonary artery.

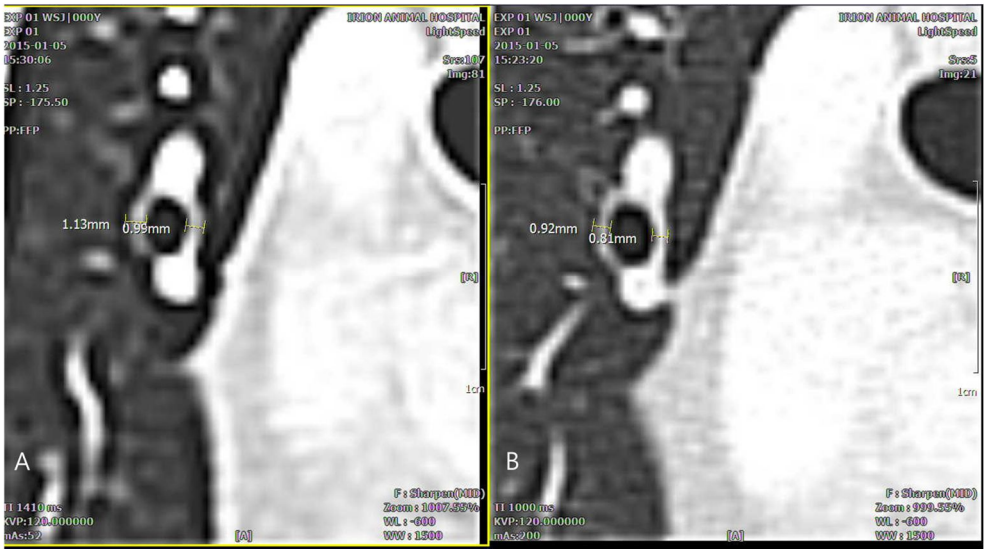

Figure 4. Direct wall measurement in CCT (A) and HRCT (B) were performed in same position of lung. Bronchial wall measurements were performed at most thin region of bronchus in CCT and HRCT. All measurements were performed electrical caliper with 1000% magnification.

2-5. Statistical analyses

Statistical analyses were performed by the author (WSJ). All calculations were performed using non-commercial software (R, The R Foundation) and commercial software (SPSS 19®, SPSS Inc., Chicago, IL, USA). Paired T test was used in comparing means of each value from CCT and HRCT. Coefficient of variation (CV) was performed in values from HRCT and CCT to compare size of variation between two groups. To compare reproducibility in two observers, intraclass correlation coefficient (ICC) was performed in TD ratio, WA% and TA ratio in CCT and HRCT separately. These statistical analyses were perform to compare BA ratio, TD ratio, WA% and Ta ratio each other. Paired T test was performed to compare bronchial wall thickness in same level axial image. For all statistical analyses, a p value of less than 0.05 was considered significant.

3. RESULTS

The 3 indices (TD ratio, WA%, TA ratio) of bronchial wall thickness and BA ratio were obtained in16 cats and 64 bronchi and artery. These values were obtained in CCT and HRCT in order. Mean in each value was listed in table (Table 2). There was no significant (p=0.696) difference in BA ratio between HRCT and CCT (Figure 5). However, TD ratio and WA% were significantly (p=0.006) different between HRCT and CCT (Figure 5). In addition, the TA ratio was significantly (p<0.01) different between HRCT and CCT (Figure 5)

To evaluate difference depending on variation of each scan protocol (CCT and HRCT), coefficient of variation (CV) was calculated in 4 indices (T/D ratio, WA%, T/A ratio, BA ratio). The values were same as below (Table 3). In 4 indices (T/D ratio, WA%, T/A ratio, BA ratio), CV was lower in HRCT than CCT.

The intraclass correlation coefficiency (ICC) of TD ratio, WA% and TA ratio was analyzed in each values measured by two observers (WSJ, YJH). In TD ratio, ICC of HRCT was 0.67 and that of CCT was 0.52 (p<0.01). In WA%, ICC of HRCT was 0.66 and that of CCT was 0.54 (p<0.01). In TA ratio, ICC of HRCT was 0.83 and that of CCT was 0.61 (p<0.01). All values of ICC and 95% confidence interval (CI) of ICC were listed below (Figure 6, 7, 8).

Values which were directly measured bronchial wall thickness in same level of axial image were also obtained from 16 cats and 64 bronchi. The mean of bronchial wall thickness from CCT was 1.29 ± 0.16 mm and the mean of bronchial

wall thickness from HRCT was 1.06 ± 0.13 mm. The measurements of bronchial wall thickness between CCT and HRCT were significantly different ($p<0.01$, Figure 9).

Table 2. Comparison of BA ratio, TD ratio, WA% and TA ratio in CCT and HRCT (Mean ± SD).

	CCT	HRCT
BA ratio	0.89 ± 0.16	0.87 ± 0.12
TD ratio	0.21 ± 0.03	0.18 ± 0.02 *
WA%	0.65 ± 0.07	0.60 ± 0.06 *
TA ratio	0.31 ± 0.07	0.25 ± 0.05 *

* indicates significance ($p<0.01$). (BA ratio = bronchial lumen to artery ratio, TD ratio = bronchial wall thickness to whole bronchial diameter, WA% = percentage of bronchial wall area to whole bronchus area, TA ratio = bronchial wall thickness to pulmonary artery ratio)

Table 3. Comparison of Coefficient of variation (CV) of 4 indices (BA ratio, TD ratio, WA% and TA ratio) in CCT and HRCT

	CCT	**HRCT**
BA ratio	0.18	0.13
TD ratio	0.14	0.13
WA%	0.11	0.10
TA ratio	0.23	0.21

(BA ratio = bronchial lumen to artery ratio, TD ratio = bronchial wall thickness to whole bronchial diameter, WA% = percentage of bronchial wall area to whole bronchus area, TA ratio = bronchial wall thickness to pulmonary artery ratio)

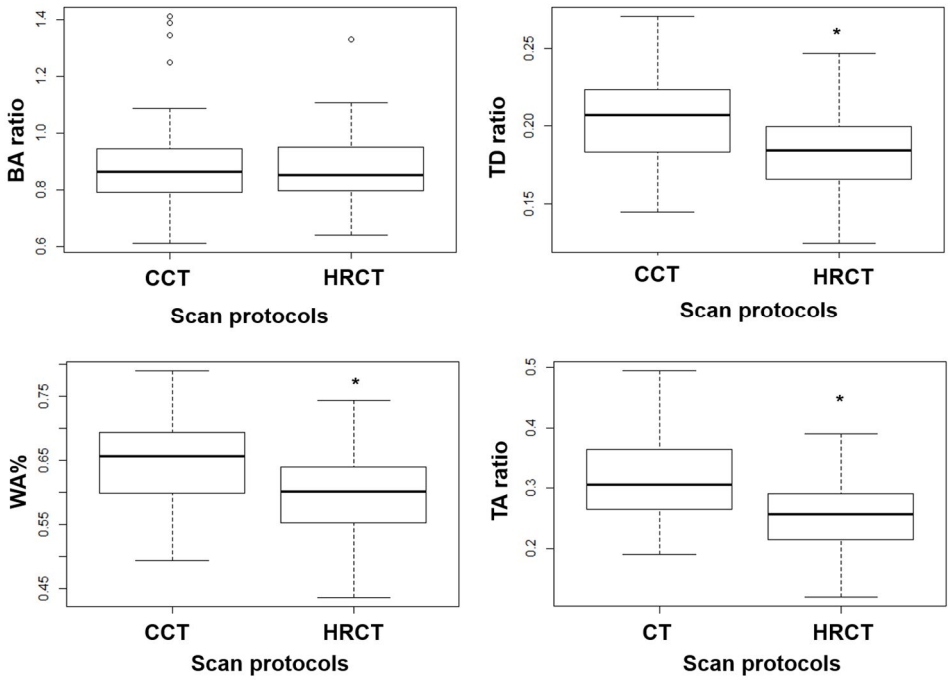

Figure 5. Comparison of each indices between CCT and HRCT. There was no significant difference in BA ratio, while significant difference was identified in TD, WA% and TA ratio. (CCT = conventional computed tomography, HRCT = high resolution computed tomography, BA ratio = bronchial lumen to artery ratio, TD ratio = bronchial wall thickness to whole bronchial diameter, WA% = percentage of bronchial wall area to whole bronchus area, TA ratio = bronchial wall thickness to pulmonary artery) * indicates significance (p<0.01).

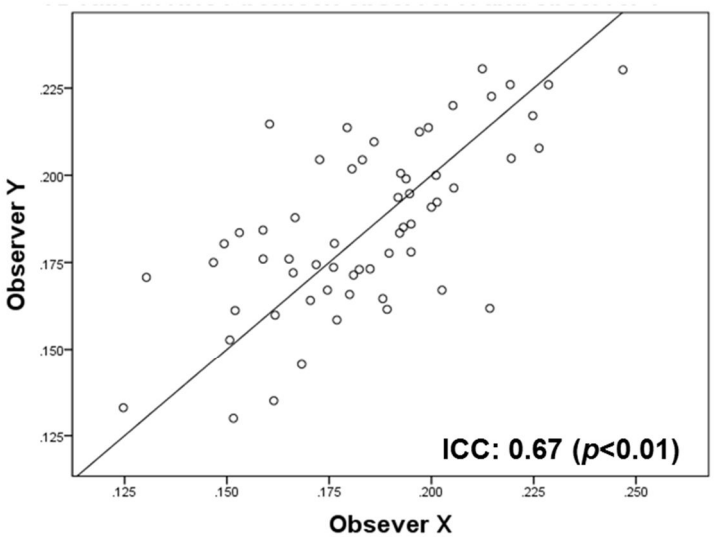

TD ratio in HRCT between observer X and Y

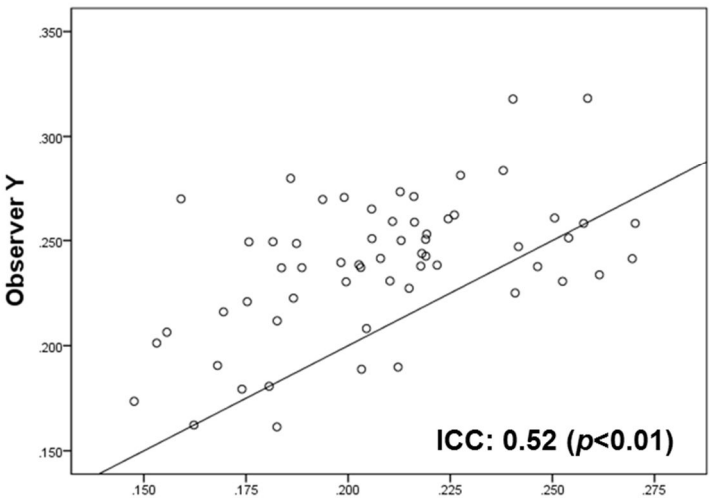

TD ratio in CCT between observer X and Y

Figure 6. Association of TD ratio measured by two observers (X, Y). In HRCT, ICC of TD ratio between two observers was 0.67 (p<0.01). In CCT, ICC of TD ratio between two observers was 0.52 (p<0.01). ICC in HRCT was calculated higher than CCT.

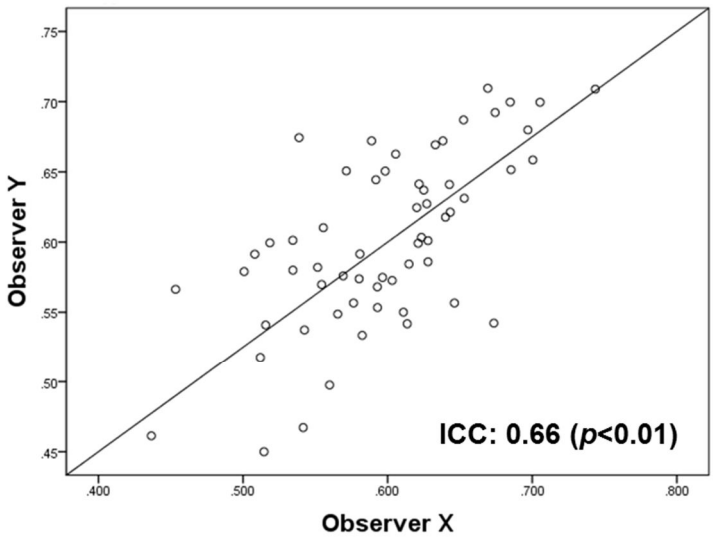

WA% in HRCT between observer X and Y

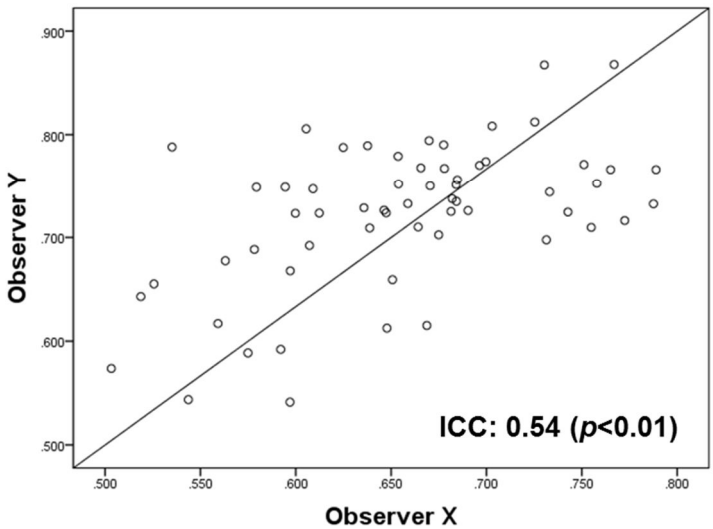

WA% in CCT between observer X and Y

Figure 7. Association of WA% measured by two observers (X, Y). In HRCT, ICC of WA% between two observers was 0.66 (p<0.01). In CCT, ICC of WA% between two observers was 0.54 (p<0.01). The ICC in HRCT was calculated higher than CCT.

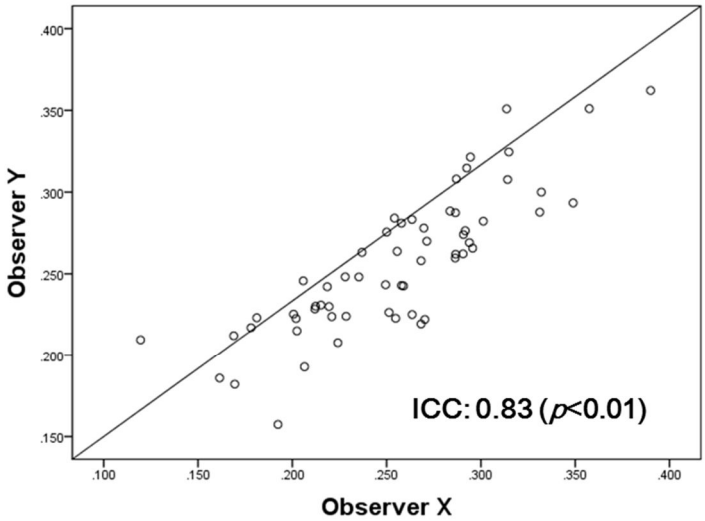

TA ratio in HRCT between observer X and Y

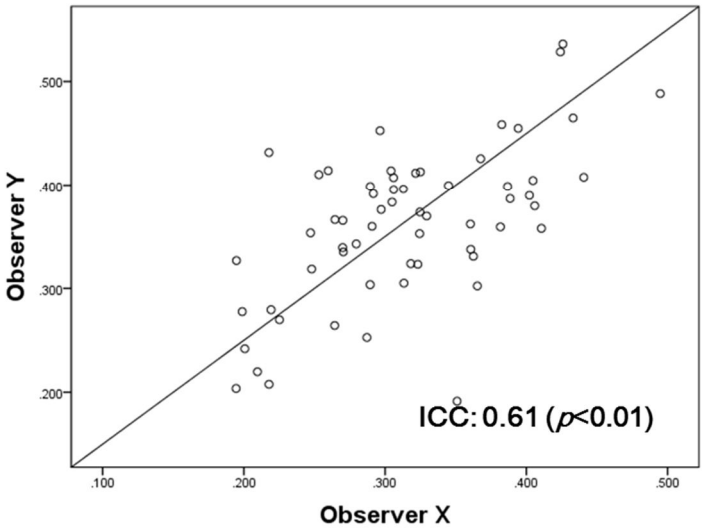

TA ratio in CCT between observer X and Y

Figure 8. Association of TD ratios measured by two observers (X, Y). In HRCT, ICC of TD ratio between two observers was 0.83 (p<0.01). In CCT, ICC of TA ratio between two observers was 0.61 (p<0.01). ICC in HRCT was calculated higher than CCT.

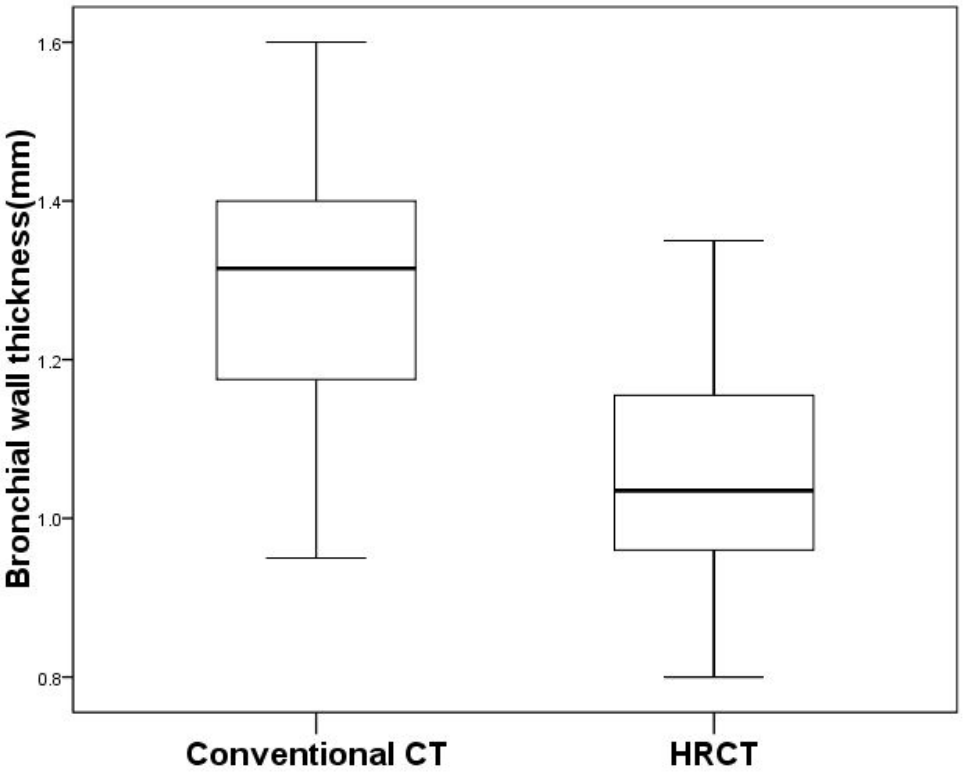

Figure 9. Comparison of bronchial wall thickness in CCT and HRCT. Bronchial wall thickness in CCT was measured higher than HRCT significantly ($p<0.01$).

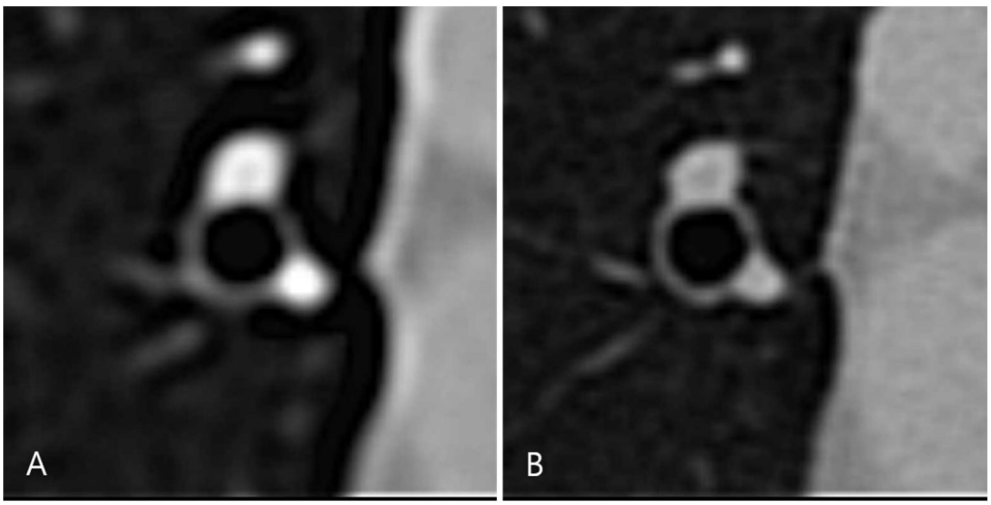

Figure 10. Comparison of CCT (A) and HRCT (B) at axial image of the same position. Irregular wall thickness was identified in CCT, hence relatively constant wall thickness in HRCT. The bronchial wall thickness was more exaggerated in CCT than HRCT and loss of circularity of adjacent vessel was also identified in CCT.

4. DISCUSSION

As hypothesized, CCT generated higher coefficient of variation (CV) than HRCT in BA ratio, TD ratio, WA%, and TA ratio. Higher CV indicated that the measuring values were more scattered. Due to its low resolution, CCT resulted in erratic measurements. Therefore, its data were more scattered than HRCT. When the average value of each of the four indices was compared, all indices except BA ratio were significantly different between HRCT and CCT.

To test the second hypothesis, ICC was analyzed in TD ratio, WA%, and TA ratio. These ICCs were analyzed with the three indices in HRCT and CCT separately. The value of ICC was used to determine which scan protocol had higher reproducibility. In TD ratio and WA% of HRCT, ICCs were slightly higher than those of CCT, suggesting that HRCT had higher reproducibility in measurements than CCT. In general, ICC value over 0.8 is considered as a reliable correlation. The ICC values of TD ratio and WA% were less than 0.8 in both scan protocols. In TA ratio, ICC in HRCT was higher than that of CCT. The ICC value of HRCT was 0.83, suggesting that the reproducibility of TA ratio in HRCT was reliable. Therefore, the TA ratio of HRCT was reliable with higher reproducibility than that of CCT.

With the same position of axial image, bronchial wall thickness was thicker in CCT than in HRCT. This difference in size could be due to difference in image processing algorithms. In the HRCT protocol with optimal settings, pixel size was expressed at least 0.25 mm. However, the pixel size was usually 1 mm in

CCT. With such difference in resolution, overestimation of bronchial wall could be made in CCT.

In human medicine, HRCT in pulmonary disease has been widely researched (Webb *et al.*, 1996). The optimal scan protocol in HRCT of lung was widely studied for best detailed bronchial structure and parenchyma (Mayo *et al.*, 1987; Webb *et al.*, 1984). In these studies, protocol that is most detailed and reducing noise was suggested with phantom model. In HRCT of lung, bronchial wall thickness is most accurate with window center between -250 and -700 Hounsfield unit (HU) and with window widths greater than 1,000 HU (Bankier *et al.*, 1996). For bronchial diameter in a canine excised lung model, the correlation between planimetry and HRCT is significantly coincident (McNamara *et al.*, 1992). However, comparison between the true diameter and that measured by HRCT in a feline model has not been reported. In this study, the true diameter was measured through necropsy to determine the accuracy of HRCT in measuring the bronchial wall thickness. However, the experimental animals used in this study were clinically healthy cats. They participated in this study voluntarily by their owners with minor dental procedures. Therefore, additional experiment such as necropsy was not possible, which was the limitation of this study. However, this results suggested that HRCT could be used as an accurate modality to determine the bronchial wall of animals.

In human medicine, HRCT has been compared to other modalities, such as plain radiograph, histopathologic examination, and CCT. In veterinary medicine, HRCT has been rarely used to diagnose pulmonary diseases. HRCT has been

reported to determine feline BA ratio and canine idiopathic pulmonary fibrosis (CIPF) (Johnson *et al*., 2005; Reid *et al*., 2012). Additional studies using HRCT to diagnose common diseases in veterinary medicine are needed in the future.

CCT has the limitation of low resolution and low delineation with relatively larger pixel size, making it difficult to identify circular bronchial wall. Consequentially, it can increase the error in the measurement. Therefore, accurate evaluation of bronchial wall thickness using CCT is difficult (Figure 10).

On the contrary, HRCT has to obtain maximal spatial resolution. Therefore, scan interval is increased and a small number of axial images are obtained. However, this scan protocol is for human patient. In this study, suitable axial images were not included into the HRCT series for some cats. Even with this limitation, delineated images of bronchus and lung from HRCT were more important for the evaluation of bronchial wall thickness in cats than those from CCT.

This study compared the values obtained from CCT and those obtained from HRCT in cats. The results of this study suggest that HRCT has various benefits in the evaluation of feline bronchial wall than CCT.

5. CONCLUSIONS

High resolution computed tomography presents more delineated images with more precise and highly reproducible measurement for bronchial wall thickness in clinically healthy cats than CCT. Therefore, HRCT is a useful modality in the assessment of bronchial wall in cats.

Chapter 2: Indices of bronchial wall and lumen in healthy cats using end expiration or inspiration ventilation technique with high resolution computed tomography

1. INTRODUCTION

In veterinary medicine, computed tomography (CT) has been established as one of the most common diagnostic modalities. CT seems to be superior in diagnosing diseases involving lung parenchyma and mediastinal structures. Diagnosis of bronchial disease with CT has been commonly used in human medicine. The bronchial lumen to pulmonary artery diameter ratio (BA ratio), one of criteria to quantify airway abnormalities, is widely used in human medicine (Kim *et al.*, 1995). In the past, bronchial disease in veterinary medicine was rarely dependent on laboratory examination or conventional radiographic examination. Instead, it was based on the diagnosis of exclusion. Recently, CT scan is used commonly in veterinary medicine. For example, BA ratios in healthy dogs and cats have been determined by CT scans (Cannon *et al.*, 2009; Reid *et al.*, 2012). In addition, CT scan has been used for quantitative analysis of bronchus for dogs with bronchiectasis (Cannon *et al.*, 2013).

In human medicine, CT has been used to assess bronchial wall thickness

in various pulmonary diseases. To assess bronchial wall thickness, various indices have been measured by CT examination, including TD ratio (wall thickness T divided by the total diameter of the bronchus D) and the ratio to compare the bronchial wall thickness to the adjacent pulmonary artery diameter (Boulet *et al.*, 1995; de Jong *et al.*, 2004).

The mean BA ratio in healthy cats has been reported to be 0.71 ± 0.05 (Reid *et al*., 2012). However, that study was performed in cats under general inhalational anesthesia using single breath-hold technique with airway pressure maintained at 14-15 cm of water. In clinical environment, it is not always possible for a CT scan to be performed under single breathe hold technique. In some clinical cases, induced apnea by hyperventilation technique is used in place of single breathe hold technique. Different ventilation techniques can cause differences in the diameter of bronchial lumen between inspiration and end expiration. Therefore, the application of normal BA ratio obtained during inspiration to studies using end expiration may be erroneous. The effect of ventilation technique on BA ratio in healthy dogs has been studied. It has been found that reference value obtained during positive–pressure inspiration is different from that obtained during end expiration (Makara *et al.*, 2013). TA ratio in dogs with bronchiectasis was studied recently using conventional CT in a retrospective manner (Szabo *et al*., 2015). However, the differences of BA ratio, TD ratio and TA ratio according to different ventilation techniques have not been evaluated in cats as yet.

Therefore, the aim of this study was to determine whether BA ratio, TD ratio and TA ratio of healthy cats using single breath hold technique with positive

pressure were different from those obtained with end expiration and manual hyperventilation with HRCT.

2. MATERIALS AND METHODS

2-1. Experimental animals

Sixteen client-owned cats, presented to the Irion Animal Hospital, Seoul, Korea, over a period of 6 month (November 2014-May 2015) were included in the study. The study population was consisted of clinically healthy client owned cats. All of these cats undergoing minor dental treatment and all of owners of these cats participated in this study voluntarily. The mean age of cats was 3.8 years (range 1-7 years) with a mean body weight of 4.0kg (range 2.8-6.0kg). Fifteen cats were Domestic short hair and 1 cat was Persian. Seven cats were castrated male and nine cats were spayed female. All cats were considered clinically healthy except minor dental disease such as periodontitis, by the owners at the time of the investigation and this observation was supported by findings on physical examination, complete blood count (CBC), serum chemistry and thoracic radiography. After CT scanning, microscopic examination via tracheal washing was performed and animals with suspected infectious condition were excluded. In addition, cats with abnormal CT findings were also excluded.

2-2. Animal preparation and anesthesia

The animals were fasted approximately 8 hours for general anesthesia. Twenty four gauge intravenous catheter were placed in cephalic vein for propofol (Provive®1%, Myungmoon Pharm. Co., Ltd., Seoul, Korea) and iohexol (Omnihexol®, Korea United Pharm. Inc., Seoul, Korea) injection. The antibiotic for minor dental treatment was administrated. A propofol was injected rapidly (6 mg/kg, IV) for induction. The tracheal tube was intubated and anesthesia was maintained with isoflurane (Ifran®, Hana Pharm. Co. Ltd., Seoul, Korea) and oxygen. Heart rate, respiratory rate, body temperature and end tidal carbon dioxide ($EtCo_2$) were monitored continuously during general anesthesia. Minor dental treatment was performed after CT examination in all cats.

2-3. CT examination

2-3-1. General CT scan

Study was performed with 4 channel CT scanner (Lightspeed Plus®, General Electric Medical System, CA, USA). The thoracic CT images of this study were obtained in sternal recumbency. The CT power injector (Mallinckrodt®, Liebel-Flarsheim, OH, USA) was used to control injection of contrast media. Contrast media were infused for 20 seconds and infused volume was 600 mgI/kg. All CT studies were performed using high resolution technique: 1.25 mm thick transverse images spaced 5 mm apart. CT images were acquired and reconstructed by using a bone algorithm. The scan protocols were 1 second, kV 120 and mAs 200.

2-3-2. Breathe hold technique

Two types of breathe hold techniques were performed to compare difference of two methods. All cats were scanned twice, each time with end expiration and positive pressure inspiration. First technique was performed during end expiration. The end expiration ventilation was inducing apnea using manually hyperventilation to maintain an end-tidal carbon dioxide between 25 and 30 mmHg. Second technique was single breathe hold technique, airway pressure maintained to the airway through an endotracheal tube. The positive pressure was maintained during the second CT scan and mean scan time was 20 seconds. Same CT scans were performed in different breathe hold technique in same animal in order named.

2-4. Image analyses

Analysis of DICOM CT images was performed using a commercially available viewing and analysis software (Spectra®, Infinitt Healthcare Co. Ltd., Seoul, Korea). All measurement were obtained on contrast enhanced transverse images, using moderately edge enhancing reconstruction algorithm at the lung window (window width = 1500 Hounsfield unit (HU), window level = -600 HU). All measurements were performed with image magnification of 1000% and by an author.

Bronchial lumen, entire bronchial diameter and adjacent arterial diameter were measured in four locations: left cranial, left caudal, right cranial and right caudal lung lobes. Right middle lung lobe was excluded because of bronchus of right middle lung lobe was visible parallel in transverse image. Therefore, bronchial lumen diameter could be obtained but exact bronchial wall thickness could not be obtained. The caudal part of left cranial lobe was also excluded because of lacking reproducibility and image quality.

A second segmental bronchus from the primary bronchus to each lobe was evaluated and the secondary bronchus that was best visualized, was measured. Pulmonary artery, bronchial lumen and whole bronchial diameter were measured entire hyperdense region associated with wall and artery. All measurements were tried to caliper bronchi or arteries those were most circular. However, if circular bronchus and artery were not identified, the oval representing bronchus and artery were measured in its smallest diameter to avoid any effect of obliquity in determining the exact diameter (Figure 11).

By measuring the overall bronchial diameter, bronchial lumen and adjacent artery, total three values were calculated. The bronchial lumen to artery ratio (BA ratio) was calculated, which is bronchial diameter divided by the diameter of the adjacent artery. Because of bronchial wall thickness is relatively small values than other values, measuring bronchial wall thickness directly was could be erroneous. Therefore, wall thickness (T) was derived indirectly from overall (D) and luminal (L) diameter of bronchus ($T = (D-L)/2$).Bronchial wall to

whole bronchial diameter ratio (TD ratio) was calculated by bronchial wall thickness (T) divided by diameter of adjacent whole bronchial diameter (D). Bronchial wall thickness to pulmonary artery ratio (TA ratio) was calculated by bronchial wall thickness (T) divided by diameter of adjacent pulmonary artery (A). All these measurements were acquired at end expiration and positive pressure inspiration separately.

2-5. Statistical analyses

Statistical analyses were selected and performed by the author. All calculations were performed using commercial software (SPSS 19®, SPSS Inc., Chicago, IL, USA). A paired sample t-test was used to compare difference between inspiration with positive pressure and end expiratory group. All results were reported as mean $\pm$ standard deviation. For all statistical analyses, a p value of less than 0.05 was considered significant.

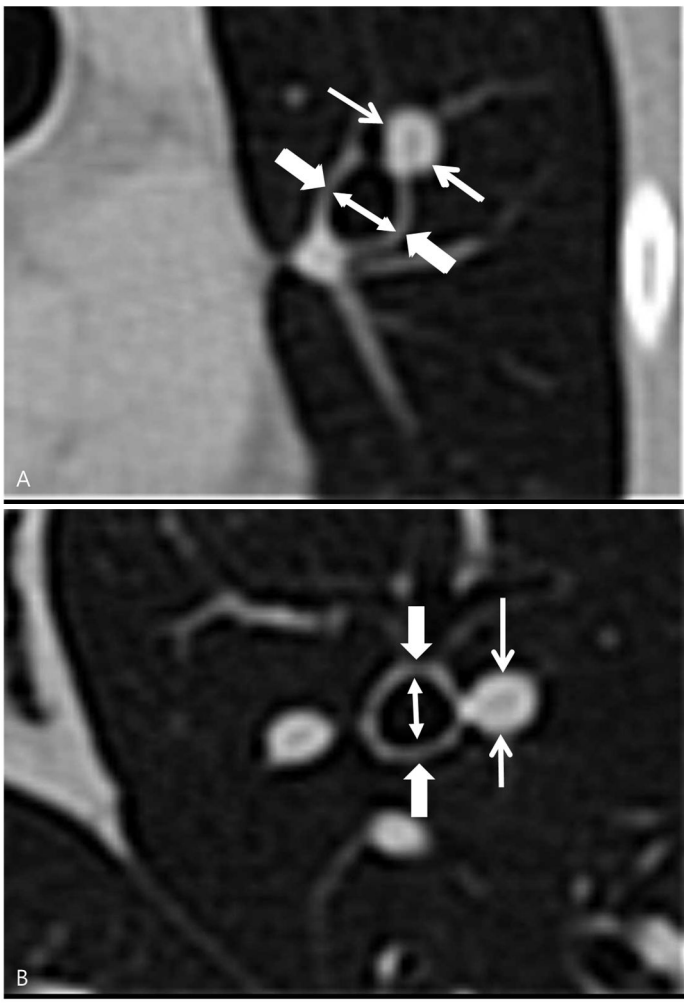

Figure 11. HRCT image of the cranial part of the left cranial lung lobe (A) and left caudal lung lobe. The internal diameter of the left cranial and caudal bronchial lumen and the diameter of the adjacent pulmonary artery in axial image were measured to determine the BA ratios. Thick arrows designate the entire diameter of bronchial lumens while thin arrows designate the adjacent pulmonary arteries. And double headed arrows designate the luminal diameter of bronchus.

3. RESULTS

With both ventilation techniques, transient apnea was produced. All scanning data were obtained without motion artifact. Total of 64 BA ratios, TD ratios and TA ratios were calculated from CT scans with positive pressure inspiration and end expiration. The mean BA ratio during positive pressure inspiration and end expiration were 0.87 ± 0.12 and 0.74 ± 0.11, and there were significant difference between them ($p<0.01$, Figure 12). The mean TD ratio during positive pressure inspiration and end expiration were 0.18 ± 0.02 and 0.21 ± 0.03 and were significantly different ($p<0.01$, Figure 13). The mean TA ratio during positive pressure inspiration and end expiration were 0.25 ± 0.05 and 0.26 ± 0.06 and were not significantly different (Figure 14). The mean of BA ratio, TD ratio and TA ratio was listed below (Table 4).

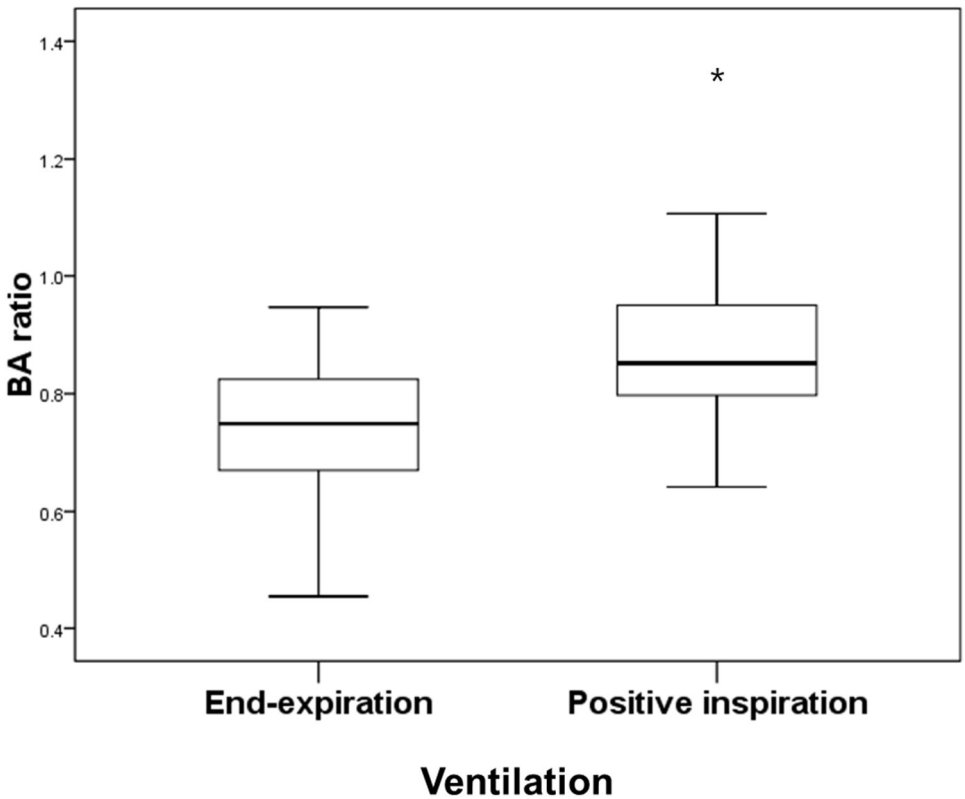

Figure 12. Comparison of BA ratio during end expiration and positive pressure inspiration. There was significant difference in BA ratio between images obtained during positive pressure inspiration and end expiration ($p<0.01$). * indicates significance ($p<0.01$).

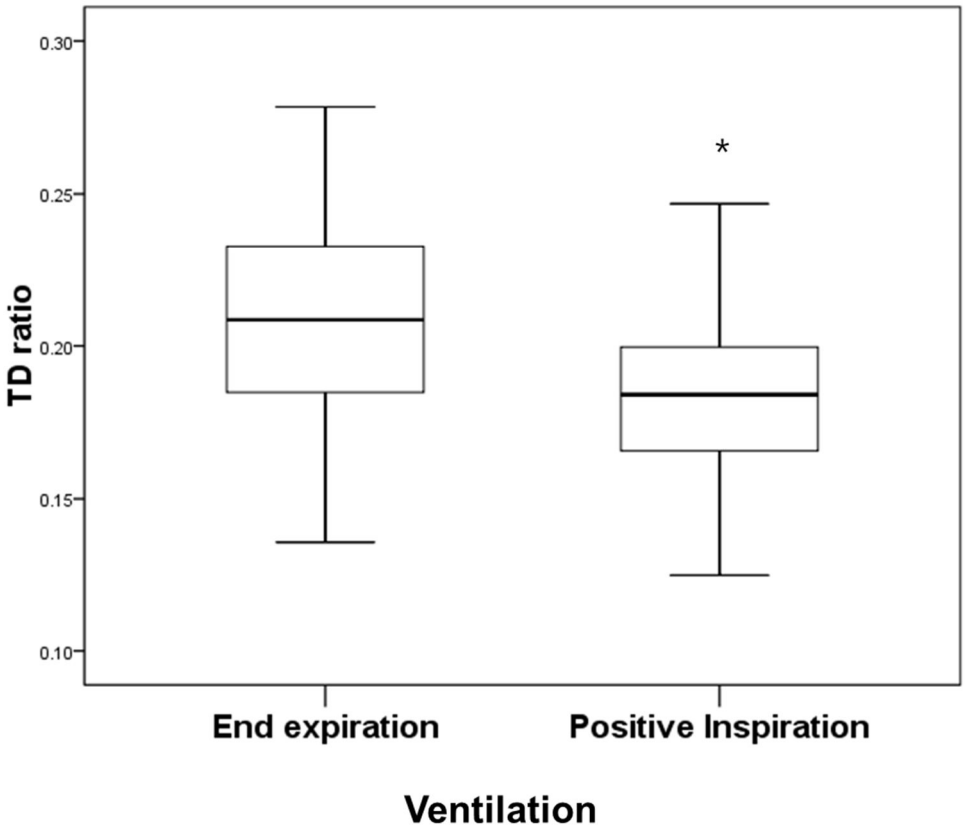

Figure 13. Comparison of TD ratio during end expiration and positive pressure inspiration. There was significant difference in TD ratio between images obtained during positive pressure inspiration and end expiration ($p<0.01$). * indicates significance ($p<0.01$).

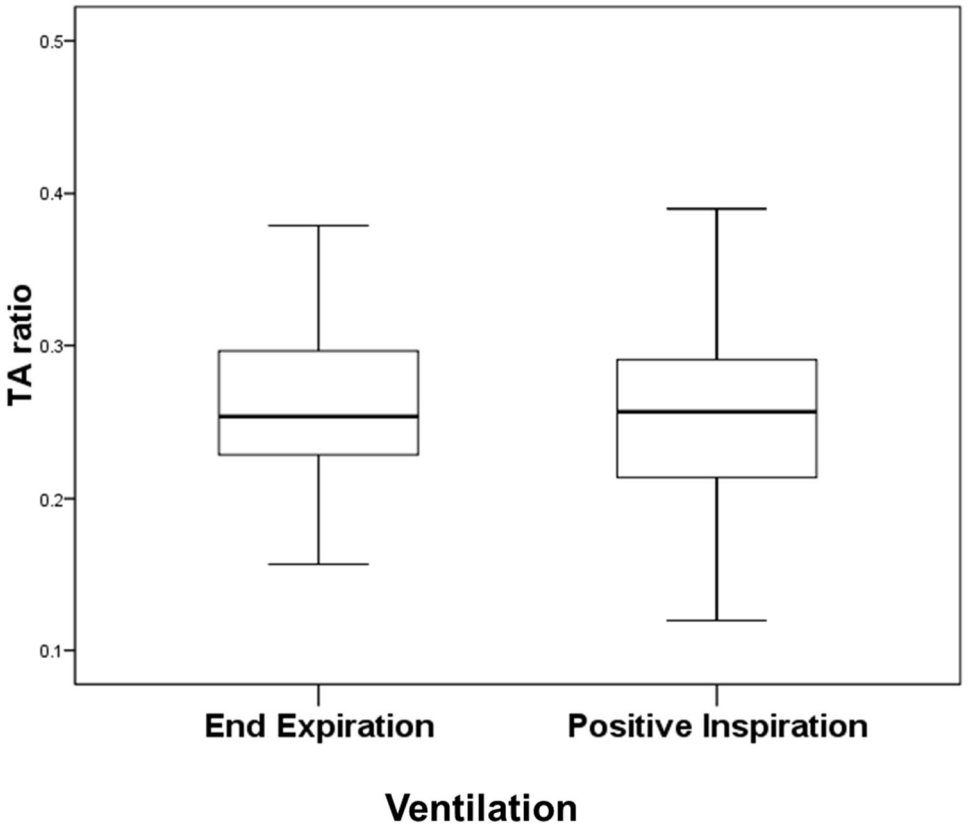

Figure 14. Comparison of TA ratio during end expiration and positive pressure inspiration. There was no significant difference in TA ratio between images obtained during end expiration and positive pressure inspiration.

Table 4. Comparison of BA ratio, TD ratio and TA ratio at end expiration and positive pressure inspiration (mean ± S.D.)

`	**End expiration**	**Positive pressure inspiration**
BA ratio	0.74 ± 0.11	0.87 ± 0.12 *
TD ratio	0.21 ± 0.03	0.18 ± 0.02 *
TA ratio	0.26 ± 0.06	0.25 ± 0.05

* indicates significance ($p<0.01$) (BA ratio = bronchial lumen to artery ratio, TD ratio = bronchial wall thickness to whole bronchial diameter, TA ratio = bronchial wall thickness to pulmonary artery ratio)

4. DISCUSSION

The mean of BA ratio and the mean of TD ratio in inspiration with positive pressure were significantly different in end expiration compared to positive inspiration. There were obvious changes in bronchial luminal diameter between inspiration and expiration. Pulmonary artery was considered as constant marker that was not changed with respiratory phase. In a study of dogs, diameter of pulmonary artery was not significantly different in ventilation (Makara *et al*., 2013). Therefore, significant difference was identified in BA ratio and TD ratio with alterd luminal size of bronchus. TA ratio was not significantly diffent between inspiration and expiration. These results mean that bronchial wall thickness was not chnaged according to respiration likewise diameter of pulmonary artery.

In the previous study about BA ratios in normal dogs and cats, bronchi and arteries were measured in all lung lobes including cranial part of left cranial lung lobe, caudal part of left cranial lung lobe, left caudal lung lobe, right cranial lung lobe, right middle lung lobe, and right caudal lung lobe (Cannon *et al*., 2009; Reid *et al*., 2012). In this study, HRCT was performed to obtain images of delineated bronchi and arteries. Because of the low number of total axial image, to increase spatial resolution HRCT spacing image at 5 mm interval, adequate images containing bronchus of the right middle lung lobe and the caudal part of the left cranial lung lobe were not obtained in several studies. In addition, the bronchus and artery of the right middle lung lobe were visualized longitudinally in axial images. This could introduce errors in measuring the exact bronchial luminal diameter and

arterial diameter. In human medicine evaluation, BA ratio in longitudinal orientation is not recommended (Hansell, 1998).

In veterinary medicine field, it may not be possible to make positive pressure inspiration by 15 cm water depending on the condition of patient and the region of interest. Therefore, normal range at the end expiration might be more useful for bronchial wall evaluations in CT scan taken at various conditions. Furthermore, TA ratio was not affected by inspiration and expiration. Therefore, TA ratio can be widely useful diagnostic tool in evaluating bronchial wall thickness in cats.

In a study on BA ratio depending on different ventilation techniques in dogs (Makara *et al*., 2013), significant difference in bronchial diameter between positive pressure inspiration and end expiration has been reported. In the same study, BA ratios obtained from larger airways are reported to be greater than those obtained from smaller airways (Makara *et al*., 2013). The difference in BA ratios between large bronchus and small bronchus might be meaningful in cats. However, even though HRCT was used to measure BA ratios of small bronchus, the low resolution and poor delineation of smaller bronchi and arteries such as lower than tertiary bronchus made it difficult to measure them. The difficulty in measuring small bronchial diameter was especially obvious for both cranial lung lobes rather than for caudal lung lobes. Such difficulty is caused by anatomical differences between dogs and cats (Done *et al*., 2009).

Computed tomography of the entire lung on end expiration has provided additional information about the difference between structure and function of lungs.

In human medicine, airway lumen measured at expiratory is more closely related to expiratory airflow measurements than to inspiratory CT (Arakawa *et al.*, 1998). In addition, changes at the airway luminal area between inspiration and expiration are strongly related to airflow limitation such as forced expiratory volume in one second (FEV1) (Matsuoka *et al.*, 2008). Airway responsiveness has been studied in healthy and allergen-sensitized cats with whole body plethysmography (Kirschvink *et al.*, 2007). Plethysmographic evaluation is not invasive. In addition, all values can be obtained without anesthesia or chemical restraint. However, plethysmography is not commonly used in the veterinary clinical field compared to CT by its complexity. Further study is needed to determine the relationship between plethysmographic evaluation and dynamic or expiratory CT examination to assess pulmonary function in veterinary medicine.

Asthma is relatively more common in cats than in dogs. Therefore, evaluation of airway limitation or airway responsiveness may play an important role in the diagnosis or the determination of the severity of feline asthma syndrome. In human medicine, dynamic HRCT with inspiration and expiration is particularly sensitive for the detection of diffuse lung diseases with small airway abnormalities such as bronchiectasis, bronchial asthma, and bronchiolitis obliterans (Nishino *et al.*, 2010). Therefore, the relationship between airway lumen measured at expiratory or inspiratory CT in cats and pulmonary function test needs to be studied in the future.

This is first report on BA ratio, TD ratio and TA ratio in healthy cats with different ventilation techniques. There were significant differences in BA ratio and

TD ratio measured with inspiration and positive pressure of 15 cm water and those measured with end expiration. However, TA ratio was not significantly different with different ventilation technique. These differences of BA ratio and TD ratio according to respiratory condition may apply to the evaluation of bronchial disease in cats with various anesthetic conditions in veterinary clinical practice. These results provide that TA ratio is not affected by inspiration or expiration in assessing bronchial wall thickness in cats.

5. CONCLUSIONS

In cats, BA ratio obtained under the condition of positive pressure inspiration was found to be higher than that obtained during end expiration. TD ratio in positive pressure inspiration was found to be lower than that in end expiration. However, TA ratio between inspiration and expiration was not different significantly. Results obtained by the two different ventilation techniques could be used to evaluate bronchial aspects such as BA ratio and TD ratio in clinical practice. TA ratio could be used to evaluate bronchial wall thickness regardless of inspiration or expiration.

Chapter 3: High resolution computed tomographic evaluation of bronchial wall thickness in healthy and clinically asthmatic cats

1. INTRODUCTION

Asthma is a common inflammatory disease of the air way characterized by variable and recurring symptoms, reversible airflow obstruction, and bronchospasm in human medicine (Brown *et al.*, 1984). Asthma is an excessive airway responsiveness to a variety of specific and nonspecific stimuli, including chronic pulmonary eosinophilia, elevated serum immunoglobulin E (Ig E), and excessive airway mucus production. The pathophysiological features of asthma are thought to be resulting from aberrant expansion of CD 4+ T cells producing type 2 cytokines interleukin-4 and interleukin-5. However, the exact role of these cytokines in asthma has not been demonstrated (Wills-Karp *et al.*, 1998). It has been reported that chronic inflammations of bronchial airway can cause changes to bronchial wall thickening histologically (National Heart Lung and Blood Institute, 2002). Acute symptoms of asthma usually arise from bronchospasm responsive to bronchodilator therapy. Acute and chronic inflammation not only can affect airway caliber and airflow, but also underlie bronchial hyper-responsiveness, enhancing the susceptibility to bronchospasm (National Heart Lung and Blood Institute, 2002).

In veterinary medicine, feline asthma syndrome (FAS) has been used to describe a respiratory condition in cat characterized by the combination of recurrent episode of paroxysm coughing, wheezing, and dyspnea that respond to glucocorticoid therapy (Corcoran *et al.*, 1995). Only a few detailed studies have reported the histopathologic changes in bronchus and lungs of FAS. Histopathologic finding of mucosal and submucosal edema with cellular infiltration, thickened basement membrane, smooth muscle hypertrophy, and airway plugging have been also reported (Moise *et al.*, 1981). Asthma has been experimentally induced in cats as an animal model for human asthma. Sensitization with house dust mite antigen or Bermuda grass antigen in cats has led to the production of allergen-specific Ig E, allergen-specific serum, bronchoalveloar lavage fluid (BALF) Ig G, and Immunoglobulin A (Ig A) to study airway hyper-reactivity, airway eosinophilia, and acute T helper 2 cytokine profiling in peripheral blood mononuclear cells and BALF cells with histologic evidence of airway remodeling (Reinero *et al.*, 2008). Based on that study, FAS is considered to be similar to allergic asthma in human in laboratory and histopathologic aspects.

Definite diagnosis of asthma in human can be confirmed with simple pulmonary function test to measure how much air and how quickly patients can blow out of their lungs with spirometry. Diagnosis of asthma in human can also be confirmed with methacholine challenge test and allergy test such as inhalation allergen test and intradermal skin test (Burrows *et al.*, 1989; Hargreave *et al.*, 1981; Peat *et al.*, 1987). Using bronchial provocation such as methacholine challenge test is limited because it depends on the compliance and cooperation of patients. It is

not readily applicable to cats (Corcoran *et al*., 1995). Lung function test has been used in cats with face mask and pneumotachygraphy using chest compression as for infant human patient (Bark *et al.*, 2007). Airway responsiveness and bronchial constriction have been used to study healthy cats with barometric whole-body plethysmography (Hoffman *et al.*, 1999). However, this experimental method has not been applied in the clinical field of veterinary medicine yet.

For several reasons, it has been impossible to diagnose asthma clearly in veterinary medicine without invasive biopsy or post-mortem examination. The diagnosis of FAS is typically based on changes on plain radiography and therapeutic response to glucocorticoid after excluding other known causes of respiratory distress, such as pneumonia, neoplasia, infectious bronchitis, and cardiac disease (Adamama-Moraitou *et al.*, 2004; Padrid, 2000).

In cats with FAS, conventional radiography had been a useful modality to exclude other diseases such as pulmonary edema. In cats with FAS, common radiographic signs in conventional radiography include bronchial patterns, unstructured interstitial lung patterns, lung hyperinflation, hyperlucency, aerophagia, and lung soft tissue opacities (Gadbois *et al.*, 2009). To increase the reliability of conventional radiography, inter- and intraobserver agreements have been performed in the same study (Gadbois *et al.,* 2009). However, quantitative radiographic assessment of bronchial wall thickness in feline patients has not been established yet.

In human medicine, computed tomography (CT) is a useful modality to assess the severity of asthma and diagnose the complications of asthma. To

delineate bronchial image in CT, high resolution computed tomography (HRCT) has been used in human medicine. In this study, chest radiography showed that the expected abnormalities of asthma was 37.8% in the asthmatics. However, HRCT revealed abnormalities of asthma was 71.9% of asthmatics (Paganin *et al.*, 1992). Measurement for internal size of bronchi using HRCT has been found to be highly reproducible (Seneterre *et al.*, 1994). When HRCT was used to assess airway wall thickness in chronic asthma, reproducibility was found to be high (Little *et al.*, 2002). However, the severity was not related to pulmonary function such as FEV1 (Little *et al.*, 2002). Wall area (WA) and WA ratio have been reported to be correlated with pulmonary function such as FEV1 and others (Niimi *et al.*, 2000). In addition, correlation between the severity of asthma and CT findings such as bronchiectasis and emphysema has been reported (Paganin *et al.*, 1996).

In veterinary medicine, HRCT has been used to assess bronchial wall and thoracic structures. HRCT has been used to determine the bronchial lumen to artery ratio (BA ratio) in cats (Reid *et al.*, 2012). Conventional CT has been used to determine the bronchial wall to adjacent arterial ratio in dogs with bronchiectasis in a retrospective manner (Szabo *et al.*, 2015). However, CT or HRCT has not been used to study FAS in veterinary medicine. The normal bronchial wall thickness or the indices of bronchial wall in cats has not been established yet.

Therefore, the objectives of this study were: 1) use HRCT to determine the bronchial wall thickness in healthy cats, and 2) identify bronchial wall changes between healthy cats and clinically diagnosed asthmatic cats.

2. MATERIALS AND METHODS

2.1 Experimental animals

2-1-1. Clinically healthy group (n = 16)

Sixteen client-owned cats, presented to the Irion Animal Hospital, Seoul, Korea, over a period of 6 month (November 2014-May 2015) were included in the study. The study population was consisted of clinically healthy client owned cats. All of these cats were undergoing minor dental treatment and all of owners of these cats were voluntary participated in this study. The mean age of cats was 3.8 years (range 1-7 years) with a mean body weight of 4.0 kg (range 2.8-6.0 kg). Fifteen cats were Domestic short hair and 1 cat was Persian cat. All cats were considered clinically healthy except minor dental disease such as periodontitis, by the owners at the time of the investigation and this observation was supported by findings on physical examination, CBC, serum chemistry and thorax radiography. After CT examination, microscopic examination via tracheal washing was performed and animal with suspected infectious condition was excluded and cats with abnormal CT findings were also excluded.

2.1-2. Clinically asthmatic group (n = 4)

The feline asthmatic patient group was selected from patients who have visited Irion animal hospital from 2014 to 2015, who showed clinical signs of wheezing and coughing, obvious bronchial and interstitial pattern on thoracic

radiograph and therapeutic response to glucocorticoid. The mean age of cats was 7.8 years old (range 5-11 years old) with a mean body weight of 5.2 kg (range 2.7-7.0 kg). Four cats were 2 Russian Blue cats, 1 Abyssinian cat and 1 Domestic short hair cat. Age, gender and body weight of asthmatic group was listed below (Table 5).

All cats in asthmatic group showed good response to glucocorticoid. Number 2 and 4 in asthmatic group were continuing glucocorticoid to control asthma. In conventional radiography, bronchial pattern in overall lung lobes was identified (4/4) and interstitial pattern of lung lobes was also identified in asthmatic group (4/4). Collapse and lobar atelectasis of right middle lung lobe was identified in one cat (1/4, Figure 15). All clinical signs, radiographic finding and medications were listed below (Table 6).

Table 5. Age, body weight, gender and breed of 4 cats in clinically asthmatic group

Number	Age	Body weight (kg)	Gender	Breeds
1	9 y	5.5	castrated male	Russian Blue
2	11 y	5.6	castrated male	Abyssinian
3	6 y	2.7	spayed female	Domestic short hair
4	5 y	7.0	castrated male	Russian Blue

Table 6. Clinical signs, Radiographic findings in conventional thoracic radiograph, medications in current asthmatic symptoms were listed in clinically asthmatic group

No	Clinical sign	Radiographic finding	Medication
1	Wheezing, cough	General interstitial density increased, bronchial pattern in both caudal lung lobe, right middle lung lobe lobar sign	Prednisolone
2	Wheezing, cough	General interstitial density increased, bronchial pattern in both caudal lung lobe	Prednisolone, theophylline
3	Intermittent cough, wheezing	Generally interstitial density increased, bronchial pattern in overall lung lobe	Prednisolone
4	Wheezing, cough, respiratory distress	Generally interstitial density increased, bronchial pattern in overall lung lobe	Prednisolone, zafirlukast

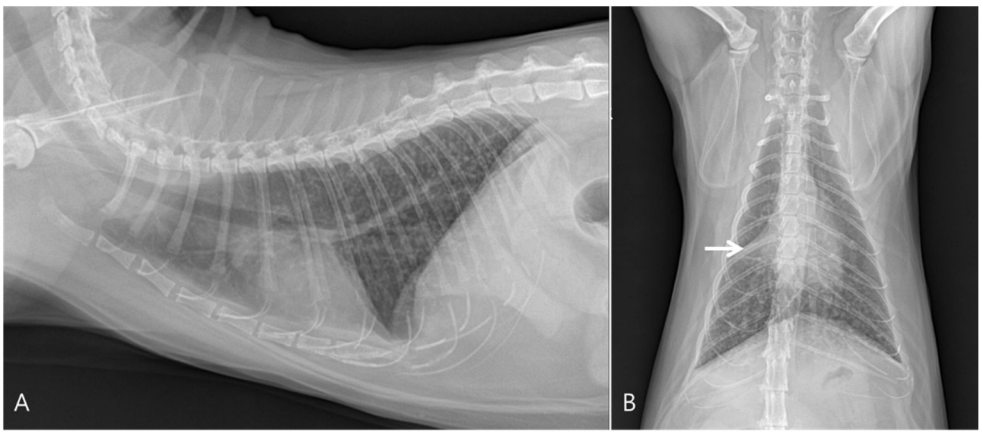

Figure 15. Lateral (A) and ventrodorsal (B) view of radiographies in asthmatic group (No.1). Diffuse interstitial density was increased in overall lung field and bronchial infiltration was identified in caudal lung field. Collapsed right middle lung lobe was identified (arrow). Left is cranial side of animal in lateral view(A) and right side of film was animals left side in ventrodorsal view (B) .

2-2. Animal preparation and anesthesia

The animals of both healthy group and asthmatic group were fasted approximately 8 hours for general anesthesia. Twenty four gauge intravenous catheter were placed in cephalic vein for propofol (Provive® 1%, Myungmoon Pharm. Co., Ltd., Seoul, Korea) and iohexol (Omnihexol®, Korea United Pharm. Inc., Seoul, Korea) injection. The antibiotic for minor dental treatment was administrated in healthy group. The oxygen was supplied for 30 minutes in asthmatic group with oxygen cage. The propofol was injected rapidly (6 mg/kg, IV) for induction. The tracheal tube was intubated and anesthesia was maintained with isoflurane (Ifran®, Hana Pharm. Co. Ltd., Seoul, Korea) and oxygen. Heart rate, respiratory rate, body temperature and end tidal carbon dioxide (EtCo2) were monitored continuously during anesthesia. Minor dental treatment was performed after CT examination in healthy group.

2-3. Scan protocols

Studies were performed with 4 channel CT scanner (Lightspeed Plus®, General Electric Medical System, CA, USA). The thoracic CT images of study were obtained in sternal recumbency. CT power injector (Mallinckrodt, Liebel-Flarsheim®, OH, USA) was used to control injection of contrast media. Contrast media was infused for 20 seconds and infused volume was 600 mgI/kg. Single

breathe hold technique was performed that airway pressure maintained at 15cm of water to the airway through an endotracheal tube. Positive pressure was maintained during the CT scan.

Computed tomography was performed using high resolution technique (HRCT): 1.25 mm thick transverse images spaced 5 mm apart. CT images were acquired and reconstructed using a bone algorithm. The scan protocols were 1 second, kV 120 and mAs 200.

2-4. Image analyses

Analysis of DICOM CT images was performed using a commercially viewing and analysis software (Spectra®, Infinitt Healthcare Co. Ltd., Seoul, Korea). All measurement were obtained on contrast enhanced transverse images, using moderately edge enhancing reconstruction algorithm at the lung window (window width = 1500 Hounsfield unit (HU), window level = -600 HU). All measurement was performed with image magnification of 1000%.

Bronchial lumen, entire bronchial diameter, and adjacent arterial diameter were measured in four locations: left cranial, left caudal, right cranial, and right caudal lung lobes. The right middle lung lobe was excluded because the bronchus of the right middle lung lobe was visible in transverse image. Therefore, the bronchial lumen diameter could be obtained. However, the exact bronchial wall thickness could not be obtained. The caudal part of the left cranial lobe was also

excluded due to the lack of reproducibility and image quality.

A second segmental bronchus from the primary bronchus to each lobe was evaluated. The second bronchus that could be best visualized was measured. Pulmonary artery, bronchial lumen, and whole bronchial diameter were measured for the entire hyper-dense region associated with wall and artery. All measurements were tried to caliper bronchi or arteries that were mostly circular. However, if circular bronchus and artery was not identified, oval bronchus and artery were measured for their smallest diameters to avoid any effect of obliquity in determining the exact diameter.

By measuring the overall bronchial diameter, bronchial lumen, and adjacent artery, a total of four values were calculated. The bronchial lumen to artery ratio (BA ratio) was calculated as the bronchial diameter divided by the diameter of the adjacent artery. Because the bronchial wall thickness had relatively small values than other values, directly measuring of bronchial wall thickness could be erroneous. Therefore, wall thickness (T) was derived indirectly from overall (D) and luminal (L) diameter of bronchus ($T = (D-L)/2$). Bronchial wall to whole bronchial diameter ratio (TD ratio) was calculated by bronchial wall thickness (T) divided by diameter of adjacent whole bronchial diameter (D). The third measurement was the percentage of total airway cross sectional area (WA%). It was calculated as the area of the lumen to that of overall bronchus. Bronchial wall thickness to pulmonary artery ratio (TA ratio) was calculated as bronchial wall thickness (T) divided by the diameter of adjacent pulmonary artery (A).

All these measurements were obtained for the healthy group and the

asthmatic group.

2-5. statistical analyses

Statistical analysis were selected and performed by the author (WSJ). All calculations were performed using non-commercial software (R, The R Foundation) and commercial software (SPSS 19®, SPSS Inc., Chicago, IL, USA). One way analysis of variation (ANOVA) was performed to identify difference between each lobe (left cranial, left caudal, right cranial and right caudal) in healthy group. A Welch two sample t- test was used to compare difference between male and female. Linear regression analysis was used to identify correlation with age and ratios. A Welch two sample t-test was used to compare difference between healthy group and clinically asthmatic group. Receiver operating characteristic curve was created and area under curve was calculated. Sensitivity, specificity, positive predictive value, and negative predictive value were calculated using the standard approaches at various cut-off ratios. All results were reported as mean $\pm$ standard deviation. For all statistical analyses, a p value of less than 0.05 was considered significant.

3. RESULTS

Sixty four bronchi and arteries were obtained from heathy 16 cats and 16 bronchi and arteries were obtained from 4 asthmatic cats. In obtained image, BA ratio, TD ratio, WA% and TA ratio of healthy group and asthmatic group were calculated.

Mean BA ratio of healthy group was 0.87 ± 0.12 and mean BA ratio of asthmatic group was 0.93 ± 0.21 and there was no significant difference between in healthy group and asthmatic group (p=0.24, Figure 16). Mean TD ratio of healthy group was 0.18 ± 0.02 and mean TD ratio of asthmatic group was 0.22 ± 0.02. TD ratios between healthy group and asthmatic group were significantly different (p<0.01, Figure 18). Mean WA% of healthy group was 59.62 ± 6.27% and mean BA ratio of asthmatic group was 68.98 ± 5.57%. WA% between healthy group and asthmatic group were significantly different (p<0.01, Figure 17). Mean TA ratio of healthy group was 0.25 ± 0.05 and mean TA ratio of asthmatic group was 0.37 ± 0.06. TA ratios between healthy group and asthmatic group were significantly different (p<0.01, Figure 18). These mean of 4 indices were list below (Table 7).

TD ratio, WA% , TA ratio between each lobes those were left cranial, left caudal , right cranial and right caudal, were not significant difference identified respectively (p=0.37, p= 0.36, p=0.11, Figure 18).

Statistical analysis was performed in four indices between male and female. There was no significant different in gender in TD ratio, WA% and TA

Ratio respectively. (p =0.82, p=0.83, p=0.47, Figure 19). Linear regression analysis was performed to found correlation of TD ratio, WA% and TA ratio with age in healthy group. TD ratio was not significantly correlated with age (R^2 = 0.048, p=0.083, Figure 20) and WA% was not significantly correlated with age (R^2 = 0.049, p=0.079, Figure 20). TA ratio was not significantly correlate with age (R^2 = 0.033, p=0.152, Figure 20).

Given these findings, a receiver operating characteristic curve (ROC) of TD ratio and TA ratio were created using the data from healthy group and asthmatic group (Figure 21). The area under curve (AUC) of TD ratio was 0.869 and AUC of TA ratio was 0.945.The both AUC of TD ratio and TA ratio were significantly different from 0.5 (p<0.01, Table 8). Cut-off ratio of 0.203 was best balanced with sensitivity 81.3% and specificity 81.3% in TD ratio. Cut-off ratio of 64.78% was best balanced with sensitivity 81.3% and specificity 81.3% in WA%. Cut-off ratio of 0.31 was best balanced with sensitivity 87.5% and specificity 92.2% in TA ratio (Table 9).

Additionally, in the images of clinically asthmatic cat, multiple hyperdense lines which was not related with vessel and bronchus were shown in pulmonary parenchyma (Figure 22).

Table 7. Comparison of four indices measured in healthy cats and clinically asthmatic cats (mean ± SD)

	Healthy group	**Asthmatic group**
	(n = 16)	(n = 4)
BA ratio	0.87 ± 0.12	0.93 ± 0.21
TD ratio	0.18 ± 0.02	0.22 ± 0.02*
WA(%)	59.62 ± 6.27	68.98 ± 5.57*
TA ratio	0.25 ± 0.05	0.37 ± 0.06*

* indicates significance ($p<0.01$). (BA ratio = bronchial lumen to artery ratio, TD ratio = bronchial wall thickness to whole bronchial diameter, WA% = percentage of bronchial wall area to whole bronchus area, TA ratio = bronchial wall thickness to pulmonary artery ratio)

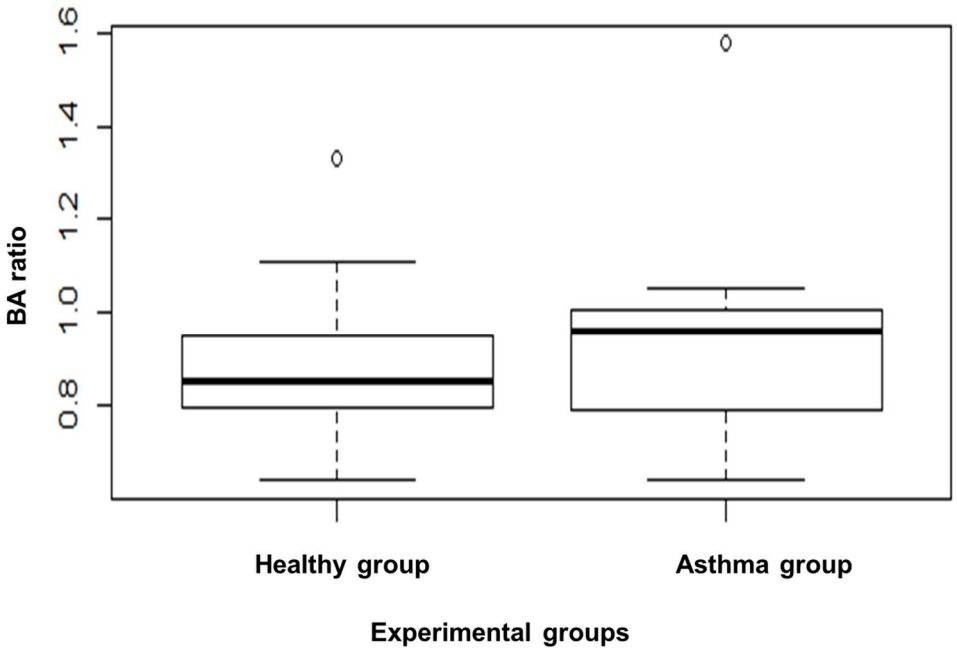

Figure 16. Comparison of BA ratio between healthy group and clinically asthmatic group. There was no significant difference between healthy group and asthmatic group.

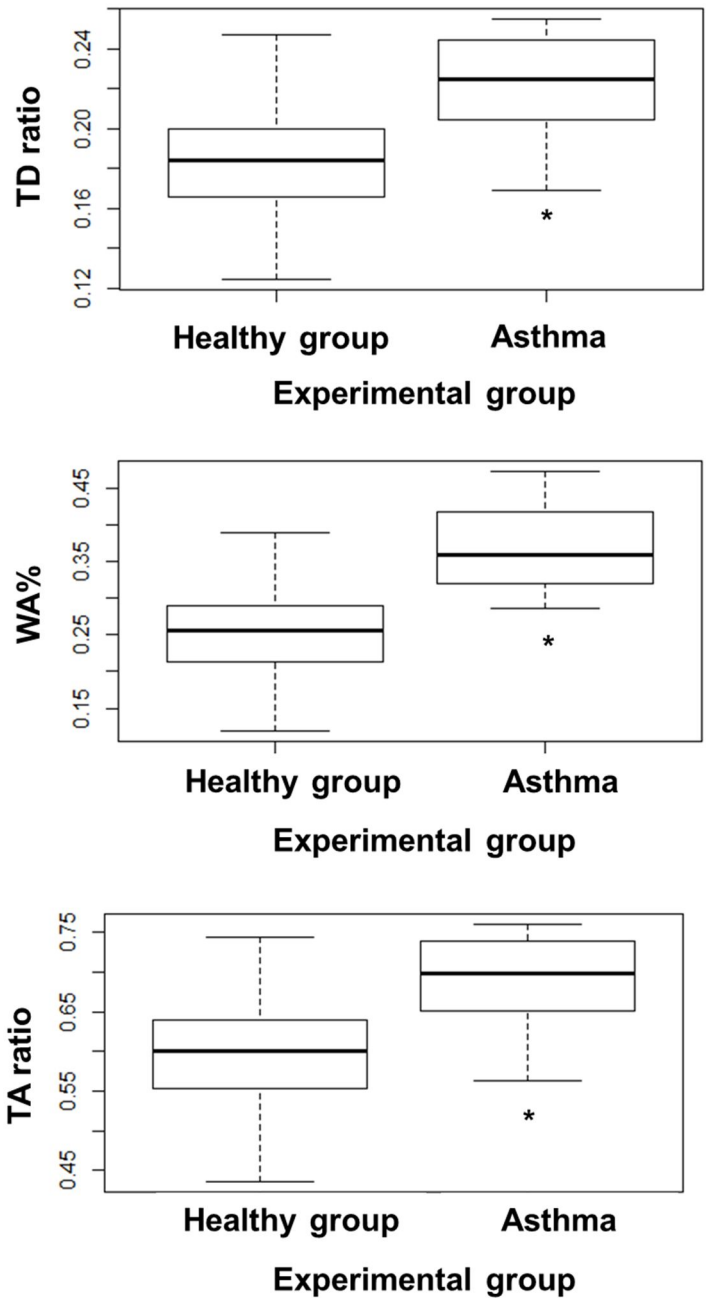

Figure 17. Comparison of TD ratio, WA% and TA ratio between healthy group and clinically asthmatic group. TD ratio, WA% and TA ratio were significantly different between two groups ($p<0.01$). * indicated significance ($p<0.01$)

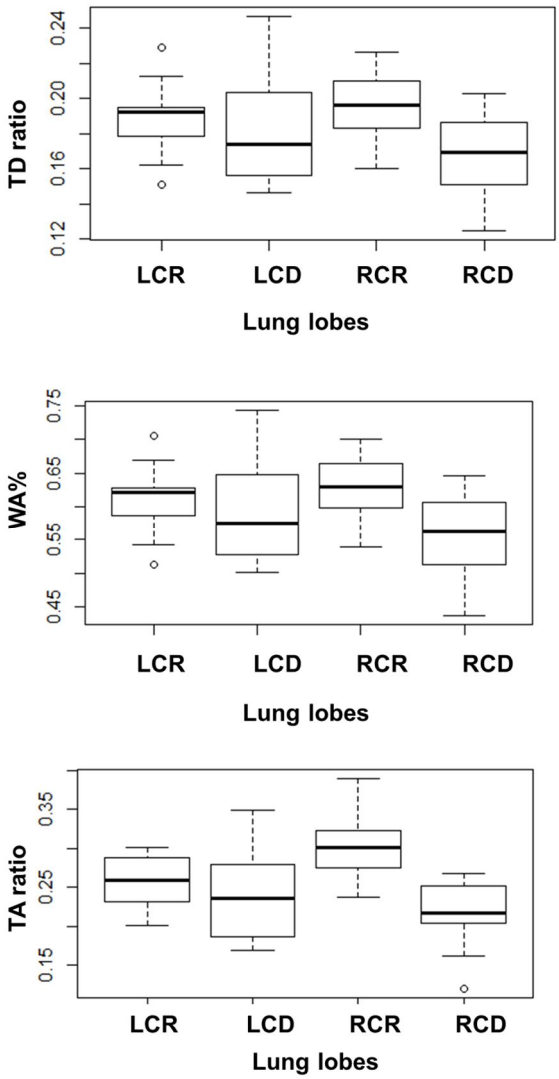

Figure 18. Comparison of TD ratio, WA% and TA ratio between each lung lobe (n = 16) in healthy group. TD ratio, WA% and TA ratio were not significantly different between each lobe; LCRCR= left cranial lung lobe, LCD = left caudal lung lobe, RCR= right cranial lung lobe, RCD= right caudal lung lobe.

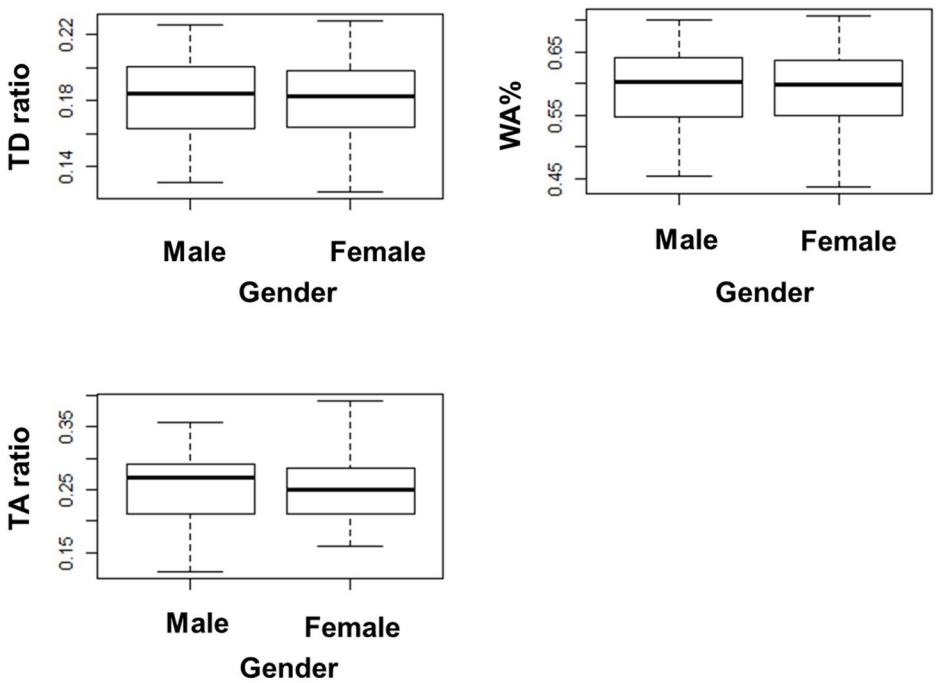

Figure 19. Comparison of BA ratio, TD ratio, WA% and TA ratio between male (n = 7) and female (n = 9) in healthy group. There was no significant difference between male and female.

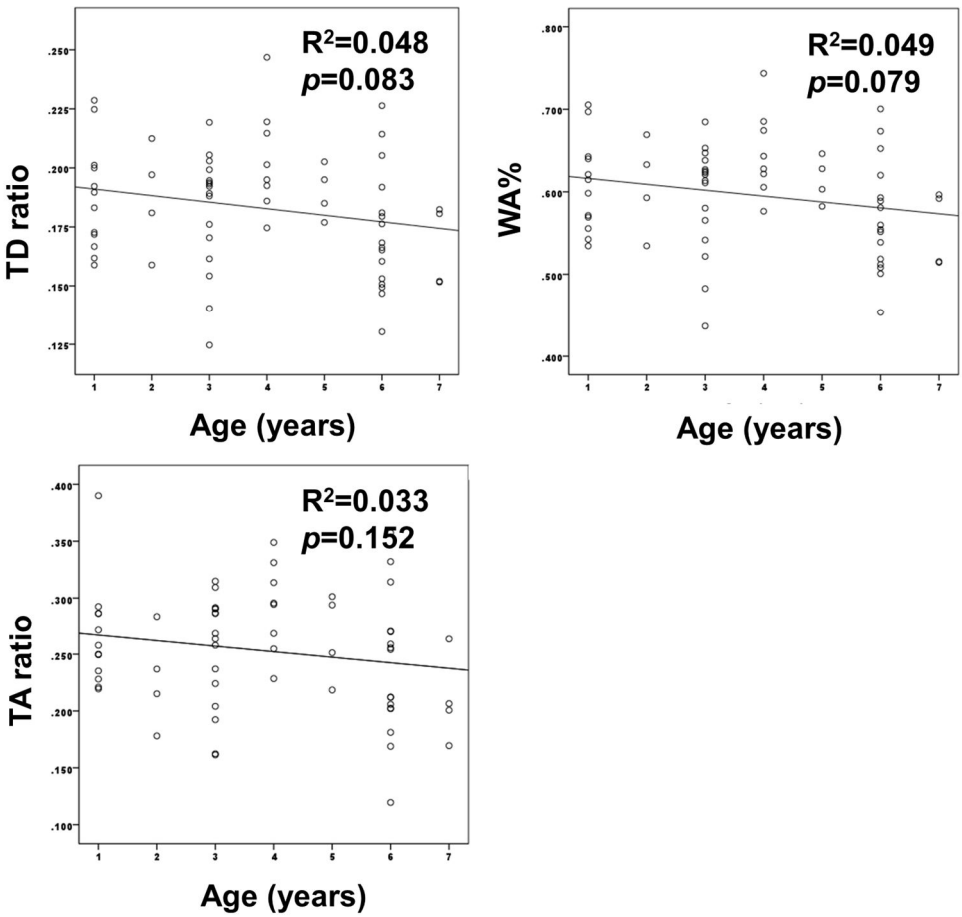

Figure 20. Linear regression analysis of TD ratio, WA% and TA ratio with age in healthy group. TD ratio was not significantly correlated with age (R^2 = 0.048, *p*=0.083) and WA% was also not significantly correlated with age also significantly different (R^2 = 0.049, *p*=0.079). TA ratio was not significantly correlated with age (R^2=0.033, *p*=0.152).

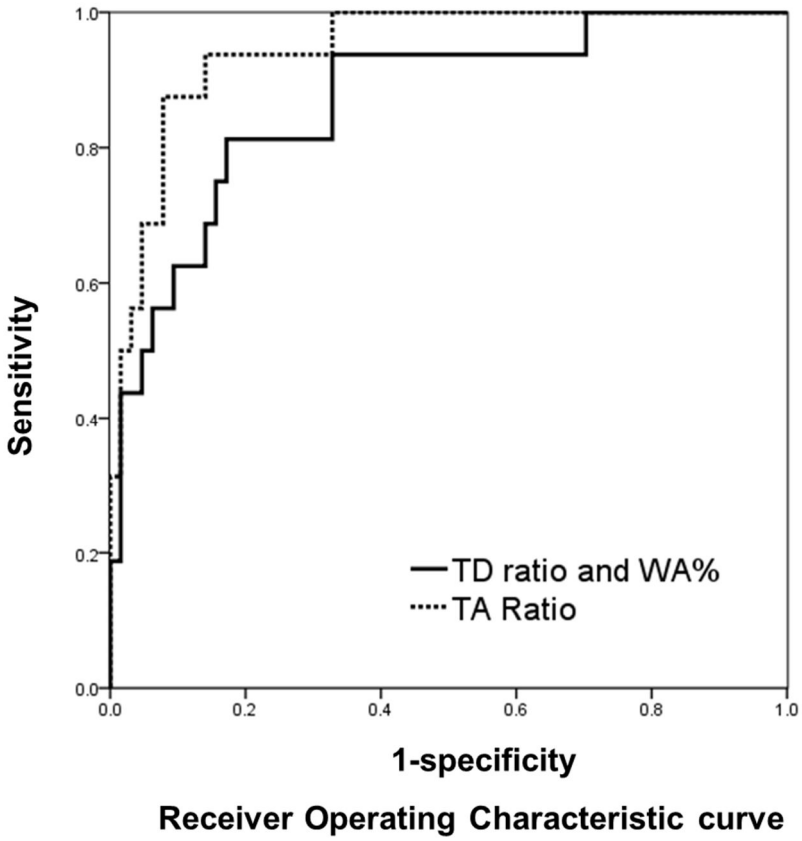

Figure 21. Receiver operating characteristic curve of the TD ratio, WA% and TA ratio in cats with asthma and healthy cats. Solid line represent TD ratio and WA% and dotted line represent TA ratio.

Table 8. The area under curve (AUC) of TD ratio, WA%, TA ratio. The AUC of each indices were significantly different from 0.5 ($p<0.01$)

	Area under curve(AUC)	***p*-value**
TD ratio`	0.869	$p<0.01$
WA%	0.869	$p<0.01$
TA ratio	0.945	$p<0.01$

Table 9. Result using various cut- off ratios to predict bronchial wall thickening in multiple indices

Cut-off ratio	TP	TN	FP	FN	Sens	Spec	PPV	NPV	Accuracy
TD ratio									
0.194	14	43	21	2	0.875	0.6729	0.4000	0.956	0.7125
0.203	13	52	12	3	0.812	0.8125	0.5200	0.945	0.8125
0.205	12	53	11	4	0.750	0.8281	0.5217	0.930	0.8125
WA%									
62.61	14	43	21	2	0.875	0.6719	0.4000	0.956	0.7125
64.78	13	52	12	3	0.812	0.8125	0.5200	0.945	0.8125
65.26	12	53	11	4	0.750	0.8281	0.5217	0.930	0.8125
TA ratio									
0.303	15	55	9	1	0.938	0.859	0.6250	0.9821	0.875
0.316	14	59	5	2	0.875	0.922	0.7364	0.9672	0.9125
0.331	11	60	4	5	0.688	0.938	0.7333	0.9230	0.8875

TP = true positive TN = true negative, FP = false positive, FN = false negative, Sens = sensitivity, Spec = specificity, PPV = positive predictive value, NPV = negative predictive value.

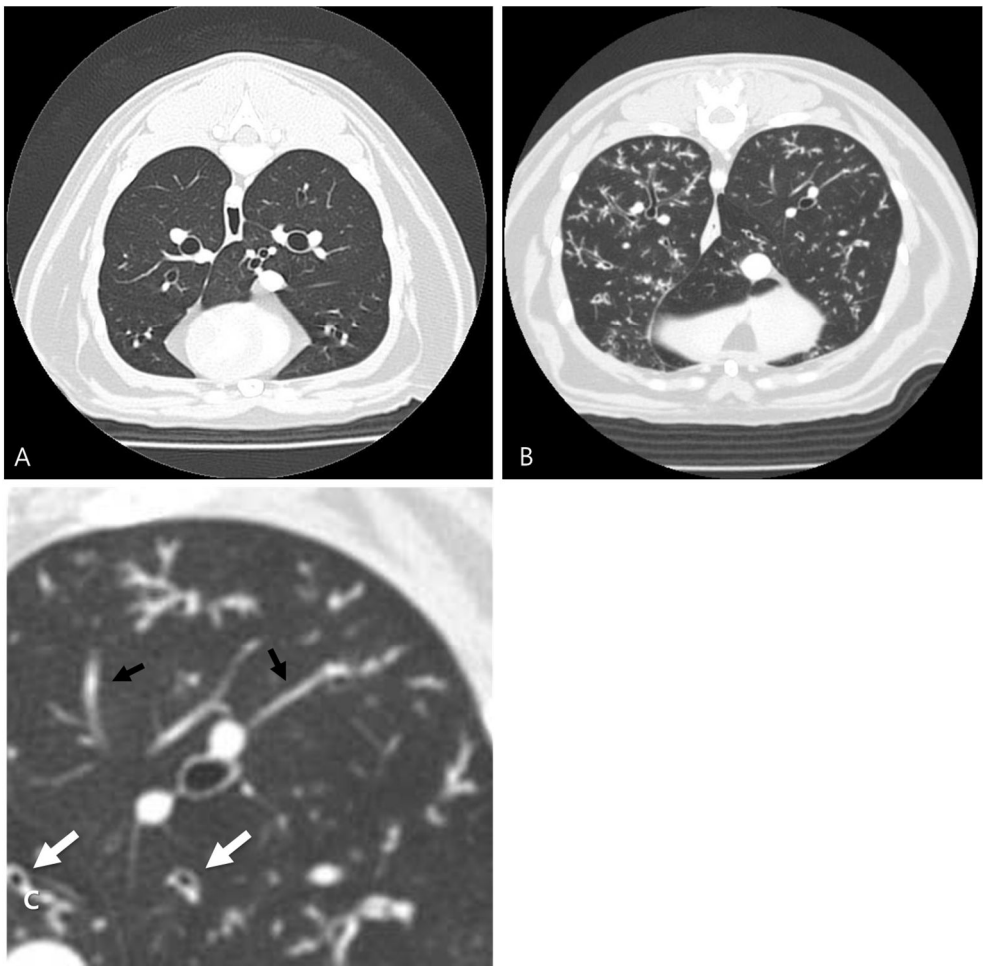

Figure 22. HRCT image of healthy cat (A), clinically asthmatic cat (B) and magnified image of asthmatic cat (C). Multiple hyperdense lines which was not related with vessel and bronchus were shown in pulmonary parenchyma (black arrow). Also thickened bronchial wall was identified in several bronchus (white arrow).

4.DISCUSSION

As hypothesized, the TD ratio, WA%, and TA ratio in cats with asthma were significantly greater than those in clinically normal cats. However, the BA ratio was not significantly different between the normal group and the asthmatic group. That is because if the whole diameters of bronchus in diseases such as asthma with thickened bronchial walls are the same, the luminal diameters will be smaller. If the BA ratio is not measured for lesions such as bronchiectasis, it is considered that BA ratio is not significantly different.

In normal cat group, no significant difference in TD ratio, WA%, or TA ratio of each lung lobe was identified. Therefore, the bronchial thickness of each lung lobe was not significantly different, allowing us to measure the bronchial wall in any lung lobe. Similarly, there were no significant differences in gender or age between the two groups.

The area under curve (AUC) of TD ratio and WA% had relatively high accuracy in predicting bronchial wall thickening in asthma patients, with a value of 0.869. The AUC of TA ratio was 0.945, which was greater than that of TD ratio and WA%. Therefore, TA ratio is a more accurate index to detect bronchial wall thickening in asthmatic patients than TD ratio or WA%. The TD ratio cut off value of 0.203 had the best sensitivity while the TD ratio cut off value of 0.303 had the best specificity. Therefore, to determine the bronchial wall thickening in cats with asthma, TA ratio and cut-off threshold of TD ratio could be used.

The golden standard to diagnose feline asthma has not been established

yet. This study was performed assuming that the cats who showed clinical signs of wheezing, coughing, interstitial pattern changes in plain thoracic radiograph, and reactiveness to glucocorticoid were asthma patients, which was the limitation in this study because the final diagnosis of asthma was not made first.

Several studies have evaluated the bronchial wall thickness in human medicine. Since bronchial wall thickness can change during airway generation, the ratios of bronchial and arterial dimensions was calculated rather than measuring their absolute values. One of the ratios was the TD ratio by dividing bronchial wall thickness with the whole diameter of bronchus. The percentage of wall area (WA%) has also been used in the quantification of bronchial wall thickness in human asthma patients (Niimi *et al*., 2000). In the case of bronchiectasis, simple measurement of bronchial wall thickness divided by bronchial luminal diameter could cause spurious underestimation of intrinsic bronchial wall thickening. Thus, to obtain an estimate of bronchial wall thickness, TA ratio was used in this study, which was the ratio of mean bronchial wall thickness divided by mean diameter of the accompanying pulmonary artery used previously (de Jong *et al*., 2004). As a result, the TA ratio was more accurate than TD ratio or WA%.

In this study, WA% was calculated by using simple geometrical equation. Therefore, the same statistical results were obtained from TD ratio and WA%. To avoid such same results, the area of the whole bronchial lumen and bronchial wall area were obtained by manually drawing in image. However, the bronchial image was too small to exactly draw a line. In addition, the latter method of wall area measurement may be greater in error. In human medicine, wall area (WA) and WA%

can be calculated automatically by assigning the region of interest (King *et al.*, 2000). Due to the lack of such calculation application in veterinary medicine, the availability of WA% cannot be promised.

There are a lot of studies about feline asthma syndrome (FAS). However, very few studies have been focused on the golden standard of FAS diagnosis in cats. Breathed flow and volume have been obtained for cats with face mask and pneumotachygraph using chest compression as for an infant human patient. Using this method, the maximum-forced expiratory flow at lung volume equivalent to functional residual capacity has been obtained. However, the voluntary lung function index such as FEV1 has not been obtained. In addition, such method cannot be easily applied to feline patients (Bark *et al.*, 2007). Airway responsiveness and bronchial constriction have also been studied in healthy cats with barometric whole-body plethysmography (Hoffman *et al.*, 1999), which could be used as a gold standard. However, barometric whole-body plethysmography cannot be applied routinely in veterinary clinical field. More research studies are needed to obtain more accurate results for the diagnosis of feline asthma using HRCT and barometric whole-body plethysmography together. Based on previous reports, this study and additional research with spirometry and provocation test will make it possible to diagnose feline asthma more accurately. Classifying specific cytokines and using cytokines as biomarker of asthma have been reported recently (Diamant *et al.*, 2010; Saude *et al.*, 2009), which could also aid the diagnosis of FAS.

In human medicine, many studies have reported the association between the severity of asthma and images of bronchial changes in HRCT. Forced expiratory volume in one second (FEV1) has been reported to be correlated with WA% (Niimi *et al*., 2000). TD ratio and WA% have been reported to be negatively correlated with carbon monoxide transfer coefficient (Little *et al*., 2002). In veterinary medicine, bronchial wall thickness ratio will be helpful to assess the severity of feline asthma because it is quantitative. However, indexing for the severity of asthma such as FEV1 in human medicine has not been established in veterinary medicine.

To measure the normal cat group, this study was proceeded in parallel during anesthesia for dental treatment due to minor dental problem such as gingivitis. Additional study with pathogen free group will be helpful for the evaluation of normal bronchial wall. Since the correlation between dental problem and bronchial disease has not been reported, it is difficult to exclude cats with dental problem from the healthy group.

The breed of cats used in this study was not diverse. Therefore, it was difficult to compare difference between breeds. Research studies are needed to determine the differences in normal ranges of bronchial wall for a variety of feline breeds. For example, in brachycephalic breed cat such as Persian cat, bronchial wall can be thicker than other breeds even though there is no clinical sign. Dogs with brachycephalic airway syndrome may contribute to the loss of small airway wall rigidity (De Lorenzi *et al.*, 2009). Based on this finding, the BA ratio in brachycephalic breed dog is found to be different from that in non-brachycephalic

dogs (Won *et al*., 2015). In Persian cat, brachycephalic syndrome including stenotic nares and elongated soft palate have been reported (Malik *et al.*, 2009). Therefore, research studies on feline brachycephalic breeds are needed in the future.

In this study, remarkable findings were observed in addition to thickening of bronchial wall and bronchodilation (Figure 22). In CT images of asthmatic cats, shadows of hyper-dense line not related to vessels or bronchial wall were observed frequently. This lesion is considered as sequellar line shadow indicating pulmonary fibrosis in human medicine. During assessment of lung recruitment, cylindrical or varicose bronchiectasis, sequellar line shadow, and emphysema are computed tomographic findings of asthmatic human patients (Paganin *et al*., 1996). Significant asthma assessment score (AAS) based on clinical signs and CT findings have been proven (Paganin *et al*., 1996). Scoring method for the evaluation of single axial image has been reported in human medicine (Naidich *et al.*, 1984). In veterinary medicine, evaluation of bronchus in plain radiograph has been reported (Gadbois *et al*., 2009). However, CT findings of FAS have not been reported. Besides quantitative study using HRCT, more researches are needed to evaluate the presence or absence of CT findings to determine the severity of asthma.

For the first time, this study reported the evaluation of bronchial wall thickness of normal cats and clinically asthmatic cats using HRCT. The results of this study suggest that quantification indices of bronchial wall thickness such as TD ratio and TA ratio could be used to diagnose feline asthma syndrome and other diseases involving bronchial wall thickening.

5. CONCLUSIONS

The purposes of this study were to evaluate the bronchial wall thickness using HRCT in healthy cats and to identify the difference in bronchial wall changes between healthy cats and clinically diagnosed asthmatic cats. To quantify bronchial wall thickness that changes during airway generation, TD ratio, WA%, and TA ratio were calculated from HRCT images. The results of this study revealed that the TD ratio, WA%, and TA ratio were significantly ($p<0.01$) different between healthy cats and clinically asthmatic cats. However, there was no significant difference in these ratios between lobes. In addition, there was no significant difference in this ratios according to gender or age. Based on these results, the ROC curve was calculated and the AUC of TA ratio was found to be 0.94, which was greater than that of the TD ratio or WA%. Therefore, TA ratio was considered as a more accurate index to detect bronchial wall thickening in asthmatic patients than TD ratio or WA%. TD ratio cut off of 0.203 had the best sensitivity and the TD ratio cut off ratio of 0.303 had the best specificity.

Taken all results together, HRCT is a useful modality to quantify bronchial wall thickness to diagnose diseases involving the thickening of bronchial wall, including feline asthma syndrome.

GENERAL CONCLUSION

In comparison of HRCT and CCT, HRCT presents more delineated images with more precise and highly reproducible measurement for bronchial wall thickness in clinically healthy cats than CCT. As a result, HRCT is suggest for useful modality in the assessment of bronchial wall in cats.

In comparison of different ventilation techniques, BA ratio obtained under the condition of positive pressure inspiration was found to be higher than that obtained during end expiration. TD ratio in positive pressure inspiration was found to be lower than that in end expiration. TA ratio between inspiration and expiration was not different significantly. Results obtained by the two different ventilation techniques could be used to evaluate bronchial aspects such as BA ratio and TD ratio in clinical practice. TA ratio could be used to evaluate bronchial wall thickness regardless of inspiration or expiration.

Comparison bronchial indices in healthy and asthmatic cats, TD ratio, WA%, and TA ratio were significantly ($p<0.01$) different between healthy cats and clinically asthmatic cats. However, there was no significant difference in these ratios between lobes. In addition, there was no significant difference in this ratios according to gender or age. Based on these results, the ROC curve was calculated and the AUC of TA ratio was found to be 0.94, which was greater than that of the TD ratio or WA%. Therefore, TA ratio was considered as a more accurate index to

detect bronchial wall thickening in asthmatic patients than TD ratio or WA%. TD ratio cut off of 0.203 had the best sensitivity and the TD ratio cut off ratio of 0.303 had the best specificity. As a result, TA ratio showed higher reproducibility, sensitivity and specificity among the four indices.

Taken all results together, HRCT is a useful modality to quantify bronchial wall thickness to diagnose diseases involving the thickening of bronchial wall, including feline asthma syndrome.

REFERENCES

Adamama-Moraitou K, Patsikas M, Koutinas A. Feline lower airway disease: a retrospective study of 22 naturally occurring cases from Greece. Journal of Feline Medicine & Surgery, 2004; 6: 227-233.

Arakawa H, Webb WR, Mccowin M, Katsou G, Lee K-N, Seitz RF. Inhomogeneous lung attenuation at thin-section CT: diagnostic value of expiratory scans. Radiology, 1998; 206: 89-94.

Bankier AA, Fleischmann D, Mallek R, Windisch A, Winkelbauer FW, Kontrus M, Havelec L, Herold CJ, Hübsch P. Bronchial wall thickness: appropriate window settings for thin-section CT and radiologic-anatomic correlation. Radiology, 1996; 199: 831-836.

Bark H, Epstein A, Bar-Yishay E, Putilov A, Godfrey S. Non-invasive forced expiratory flow–volume curves to measure lung function in cats. Respiratory Physiology & Neurobiology, 2007; 155: 49-54.

Boulet L, Bélanger M, Carrier G. Airway responsiveness and bronchial-wall thickness in asthma with or without fixed airflow obstruction. American Journal of Respiratory and Critical Care Medicine, 1995; 152: 865-871.

Brown PJ, Greville HW, Finucane KE. Asthma and irreversible airflow obstruction. Thorax, 1984; 39: 131-136.

Burrows B, Martinez FD, Halonen M, Barbee RA, Cline, MG. Association of asthma with serum IgE levels and skin-test reactivity to allergens. New England Journal of Medicine, 1989; 320: 271-277.

Cannon MS, Johnson LR, Pesavento PA, Kass PH, Wisner ER. Quantitative and qualitative computed tomographic characteristics of bronchiectasis in 12 dogs. Veterinary Radiology & Ultrasound, 2013; 54: 351-357.

Cannon MS, Wisner ER, Johnson LR, Kass PH. Computed tomography bronchial lumen to pulmonary artery diameter ratio in dogs without clinical pulmonary disease. Veterinary Radiology & Ultrasound, 2009; 50: 622-624.

Carroll N, Elliot J, Morton A, James A. The structure of large and small airways in nonfatal and fatal asthma. American Review of Respiratory Disease, 1993; 47: 405-410.

Corcoran B, Foster D, Fuentes VL. Feline asthma syndrome: a retrospective study of the clinical presentation in 29 cats. Journal of Small Animal Practice, 1995; 36: 481-488.

de Jong PA, Ottink MD, Robben SG, Lequin MH, Hop WC, Hendriks JJ, Paré PD, Tiddens HA. Pulmonary Disease Assessment in Cystic Fibrosis: Comparison of CT Scoring Systems and Value of Bronchial and Arterial Dimension Measurements 1. Radiology, 2004; 231: 434-439.

De Lorenzi D, Bertoncello D, Drigo M. Bronchial abnormalities found in a consecutive series of 40 brachycephalic dogs. Journal of the American Veterinary Medical Association, 2009; 235: 835-840.

Diamant Z, Boot J, Mantzouranis E, Flohr R, Sterk P, Van Wijk RG. Biomarkers in asthma and allergic rhinitis. Pulmonary Pharmacology & Therapeutics, 2010; 23: 468-481.

The throax In : Done SH, Goody PC, Evans SA, Stickland NC eds. *Color Atlas of Veterinary Anatomy*, *Volume 3, The Dog and Cat (Vol. 3)*.2nd ed. Elsevier Health Sciences, 2009, pp 195-251.

Gadbois J, d'Anjou M-A, Dunn M, Alexander K, Beauregard G, D'Astous J, De Carufel M, Breton L, Beauchamp G. Radiographic abnormalities in cats with feline bronchial disease and intra-and interobserver variability in radiographic interpretation: 40 cases (1999–2006). Journal of the American Veterinary Medical Association, 2009; 234: 367-375.

Hansell DM. Bronchiectasis. Radiologic Clinics of North America, 1998; 36: 107-128.

Hargreave FE, Ryan G, Thomson N, O'byrne P, Latimer K, Juniper E, Dolovich J. Bronchial responsiveness to histamine or methacholine in asthma: measurement and clinical significance. Journal of Allergy and Clinical Immunology, 1981; 68: 347-355.

Herold C, Brown R, Mitzner W, Links J, Hirshman C, Zerhouni E. Assessment of pulmonary airway reactivity with high-resolution CT. Radiology, 1991; 181: 369-374.

Hoffman A, Dhupa N, Cimetti L. Airway reactivity measured by barometric whole-body plethysmography in healthy cats. American Journal of Veterinary Research, 1999; 60: 1487-1492.

Johnson V, Corcoran B, Wotton P, Schwarz T, Sullivan M. Thoracic high-resolution computed tomographic findings in dogs with canine idiopathic pulmonary fibrosis. Journal of Small Animal Practice, 2005; 46: 381-388.

Kim SJ, Im J-G, Kim IO, Cho S-T, Cha S-H, Park KS, Kim DY. Normal bronchial and pulmonary arterial diameters measured by thin section CT. Journal of Computer Assisted Tomography, 1995; 19: 365-369.

King GG, Muller NL, Whittall KP, Xiang Q-S, Pare PD. An analysis algorithm for measuring airway lumen and wall areas from high-resolution computed tomographic data. American Journal of Respiratory and Critical Care Medicine, 2000; 161: 574-580.

Kirschvink N, Leemans J, Delvaux F, Snaps F, Clercx C, Gustin P. Non-invasive assessment of airway responsiveness in healthy and allergen-sensitised cats by use of barometric whole body plethysmography. The Veterinary Journal, 2007; 173: 343-352.

Little S, Sproule M, Cowan M, Macleod K, Robertson M, Love J, Chalmers G, McSharry C, Thomson N. High resolution computed tomographic assessment of airway wall thickness in chronic asthma: reproducibility and relationship with lung function and severity. Thorax, 2002; 57: 247-253.

Makara M, Dennler M, Schnyder M, Bektas R, Kircher P, Hall E, Glaus T. Effect of ventilation technique and airway diameter on bronchial lumen to pulmonary artery diameter ratios in clinically normal beagle dogs. Veterinary Radiology & Ultrasound, 2013; 54: 605-609.

Malik R, Sparkes A, Bessant C. Brachycephalia-a bastardisation of what makes cats special. Journal of Feline Medicine and Surgery, 2009; 11: 889-890.

Matsuoka S, Kurihara Y, Yagihashi K, Hoshino M, Nakajima Y. Airway Dimensions at Inspiratory and Expiratory Multisection CT in Chronic Obstructive Pulmonary Disease: Correlation with Airflow Limitation 1. Radiology, 2008; 248: 1042-1049.

Mayo JR, Webb W, Gould R, Stein M, Bass I, Gamsu G, Goldberg H. High-resolution CT of the lungs: an optimal approach. Radiology, 1987; 163: 507-510.

Mclean AN, Sproule MW, Cowan MD, Thomson NC. High resolution computed tomography in asthma. Thorax, 1998; 53: 308-314.

McNamara A, Muller N, Okazawa M, Arntorp J, Wiggs B, Pare P. Airway narrowing in excised canine lungs measured by high-resolution computed tomography. Journal of Applied Physiology, 1992; 73: 307-316.

Moise N, Spaulding G. Feline bronchial asthma: pathogenesis, pathophysiology, diagnostics and therapeutic considerations. Compendim of Continous Education of Practicing Veterianrian, 1981; 3: 1091.

National Heart Lung and Blood Institute, & National Institutes of health. Guidelines for the diagnosis and management of asthma: update on selected topics 2002. NIH publication, 02-5075,2002

Naidich DP, Zerhouni EA, Siegelman SS. Computed Tomography of the Thorax. J Thorac Imaging. 1985; 1(1):39-53.

Niimi A, Matsumoto H, Amitani R, Nakano Y, Mishima M, Minakuchi M, Nishimura K, Itoh H, Izumi T. Airway wall thickness in asthma assessed by computed tomography: relation to clinical indices. American Journal of Respiratory and Critical Care Medicine, 2000; 162: 1518-1523.

Nishino M, Washko GR, Hatabu H. Volumetric expiratory HRCT of the lung: clinical applications. Radiologic Clinics of North America, 2010;48: 177-183.

Padrid P. Feline asthma: diagnosis and treatment. Veterinary Clinics of North America: Small Animal Practice, 2000; 30: 1279-1293.

Paganin F, Seneterre E, Chanez P, Daures J, Bruel J, Michel F, Bousquet J. Computed tomography of the lungs in asthma: influence of disease severity and etiology. American Journal of Respiratory and Critical Care Medicine, 1996;153: 110-114.

Paganin F, Trussard V, Seneterre E, Chanez P, Giron J, Godard P, Sénac J, Michel F, Bousquet J. Chest radiography and high resolution computed tomography of the lungs in asthma. American Review of Respiratory Disease, 1992; 146: 1084-1087.

Peat J, Woolcock A, Cullen K. Rate of decline of lung function in subjects with asthma. European Journal of Respiratory Diseases, 1987; 70: 171-179.

Reid, LE, Ray Dillon A, Hathcock JT, Brown LA, Tillson M, Wooldridge AA. High-resolution computed tomography bronchial lumen to pulmonary artery diameter ratio in anesthetized ventilated cats with normal lungs. Veterinary Radiology & Ultrasound, 2012; 53: 34-37.

Reinero CR, Cohn LA, Delgado C, Spinka CM, Schooley EK, DeClue AE. Adjuvanted rush immunotherapy using CpG oligodeoxynucleotides in experimental feline allergic asthma. Veterinary Immunology and Immunopathology, 2008; 121: 241-250.

Saude EJ, Obiefuna IP, Somorjai RL, Ajamian F, Skappak C, Ahmad T, Dolenko BK, Sykes BD, Moqbel R, Adamko DJ. Metabolomic biomarkers in a model of asthma exacerbation: urine nuclear magnetic resonance. American Journal of Respiratory and Critical Care Medicine, 2009; 179: 25-34.

Seneterre E, Paganin F, Bruel J, Michel F, Bousquet J. Measurement of the internal size of bronchi using high resolution computed tomography (HRCT). European Respiratory Journal, 1994; 7: 596-600.

Szabo D, Sutherland-Smith J, Barton B, Rozanski EA, Taeymans O. Accuracy of computed tomography bronchial wall thickness to pulmonary artery diameter ratio for assessing bronchial wall thickening in dogs. Veterinary Radiology & Ultrasound, 2015; 56: 264-271.

Webb W, Müller N, Naidich D. HRCT findings of lung disease In: Webb, W, Müller, N, Naidich, D, eds. *High-resolution CT of the lung,* 2nd ed. Philadelphia: Lippincott-Raven, 1996, pp 41-108.

Webb WR, Gamsu G, Wall SD, Cann CE, Proctor E. CT of a bronchial phantom: factors affecting appearance and size measurements. Investigative Radiology, 1984;19: 394-398.

Wills-Karp M, Luyimbazi J, Xu X, Schofield B, Neben TY, Karp CL, Donaldson DD. Interleukin-13: central mediator of allergic asthma. Science, 1998; 282: 2258-2261.

Won S, Lee A, Choi J, Choi M, Yoon J. Computed tomographic bronchioarterial ratio in brachycephalic dogs without pulmonary disease. Journal of Veterinary Science, 2015; 16(2):221-4.

Young K, Aspestrand F, Kolbenstvedt A. High resolution CT and bronchography in the assessment of bronchiectasis. Acta Radiologica, 1991; 32: 439-441.

국문초록

정상 및 천식 고양이에서
고해상도 전산화 단층 촬영을 통한 기관지 벽 두께 평가

지도교수 : 윤 정 희

원 성 준

서울대학교 대학원

임상수의학 (수의방사선과학) 전공

고양이 천식 증후군은 기관지 과반응성에 의해서 천명음과 기침 등의 임상증상을 보이는 호흡기 질환이다. 이러한 기관지 반응성은 알러지 반응에 의해서 나타난다고 보고되었다. 고양이 천식 증후군은 사람의

천식 증후군과 유사하다고 보고 되었으며, 인의에서는 천식의 연구를 위하여 고양이를 동물 실험 모델로 사용하기도 한다. 사람에서의 천식의 진단은 메타콜린 부하 실험이나 폐기능 평가를 통하여 최종적으로 진단한다. 하지만 고양이에서는 자발적인 폐기능 검사는 불가능하다. 이에 수의학에서는 고양이 천식 증후군에 대한 확진 방법이 없었다. 인의에서는 천식의 병세의 정도나 치료 반응을 평가하기 위해서 고해상도 전산화 단층 촬영을 통한 기관지 벽의 지표들을 측정한 다양한 연구가 실시되었다. 하지만 고양이에서의 고해상도 전산화 단층 촬영을 통한 기관지 벽 평가는 아직까지 연구된 적이 없다. 본 연구의 목표는 고해상도 전산화 단층 촬영을 통하여 임상적으로 건강한 고양이와 임상적으로 천식으로 진단된 고양이에서 기관지 벽의 두께를 평가하는 것이다. 선행적으로 마취 중 환기 방식의 차이에 따라 기관지 벽과 내강의 변화 여부에 대해서 평가하며, 일반 전산화 단층 촬영에 비해 고해상도 전산화 단층 촬영의 우수함을 평가하고자 하였다.

건강한 16 마리의 고양이에서 전신 마취 하에 양압을 가한 흡기 상태와 호기말 무호흡 상태에서 기관지-혈관 비율, 벽-외경 비율, 벽-혈관 비율을 각각 측정하여 비교하였다. 고해상도 전산화 단층 촬영 기법의 유용성을 평가하기 위해서 동일 개체에서 고해상도 전산화 단층 촬영 기법과 통상적인 일반 전산화 단층 촬영 기법을 각각 실시하여, 두 영상을 비교 분석하였다. 고해상도 전산화 단층 촬영 기법과 일반 단층

촬영 기법의 비교에서는 각 촬영 기법으로 얻어진 영상에서 벽-외경 비율, 면적 분율, 벽-혈관 비율을 각각 측정하였고, 각 지수들에서 분산의 차이를 보기 위해 변동계수를 측정하였다. 두 검사자간의 신뢰도 평가를 위해 영상에서 벽-외경 비율, 면적 분율, 벽-혈관 비율에서 두 검사자간의 결과를 급내 상관 계수로 평가하였다. 마지막으로 동일 수준의 단면에서 기관지 벽을 직접 측정하여 비교하였다. 건강한 고양이와 천식 고양이의 기관지 벽을 평가함에 있어, 측정하는 부위나 기관지의 세대에 따라 그 절대치의 차이가 크므로, 기관지 벽과 기관지 총 외경의 비율, 총 외경 중 기관지 벽이 차지하는 비율, 기관지 벽을 인접한 혈관의 직경으로 나눈 비율을 측정하였다. 임상적으로 건강한 16 두의 고양이에서 64 개의 기관지와, 임상적으로 천식으로 진단된 4 두의 고양이에서 16 개의 기관지의 영상을 얻었고 각각의 영상에서 3 가지 지수를 측정하였다.

양압 흡기 상태에서의 기관지-혈관 비율은 0.87 ± 0.12 로 측정 되었고, 호기말 호흡 상태에서의 기관지-혈관 비율은 0.74 ±0.11 로 측정되었다. 두 환기 방식 차이에서 측정된 기관지-혈관 비율은 유의적인 차이가 있었다($p<0.01$). 기관지 벽-내강 비율은 각각 흡기와 호기에 0.18 ± 0.02 와 0.21 ± 0.03 로 나타났으며, 임상적으로 유의적인 차이가 있었다 ($p<0.01$). 하지만, 기관지 벽-혈관 비율은 흡기와 호기에 각각 0.25 ± 0.05 과 0.26 ± 0.06 로 관찰 되었으며 유의적인 차

이가 없었다.

벽-외경 비율, 면적 분율, 벽-혈관 비율 모두 고해상도 전산화 단층 촬영 기법에서 변동계수가 낮게 측정되었다. 벽-외경 비율, 면적 분율, 벽-혈관 비율 세 지수 모두에서 고해상도 전산화 단층 촬영이 일반 전산화 단층 촬영에 비해 더 높은 검사자간 신뢰도를 나타내었다. 동일 단면 영상에서 일반 단층 촬영기법과 고해상도 전산화 단층 촬영기법을 실시하여 수동으로 벽의 두께를 측정한 결과, 영상의 선예도 차이로 인해 고해상도 전산화 단층 촬영 영상에서 측정된 벽의 두께가 유의적으로 얇게 측정되었다.

임상적으로 건강한 16 마리 고양이에서 고해상도 전산화 단층 촬영 기법을 통하여 양압 흡기 상태에서 기관지 벽을 측정하였다. 얻어진 영상에서 벽-외경 비율, 면적 분율, 벽-혈관 비율은 0.18 ± 0.02, 59.62 ± 6.27 %, 0.25 ± 0.05 이었다. 동일한 조건으로 실시된 임상적인 천식으로 진단된 4마리 고양이에서도 동일 항목을 측정하였고, 벽-외경 비율, 면적 분율, 벽-혈관 비율은 0.22 ± 0.24, 68.98 ± 5.57 %, 0.37 ± 0.06 이었다. 임상적으로 천식이라 진단된 고양이에서, 세 지수는 정상적인 고양이에 비해서 유의적으로 높게 관찰되었다. 성별이나 나이, 폐엽 간의 유의적인 차이는 관찰되지 않았다.

본 연구를 통해 고양이 천식 증후군에서 고해상도 전산화 단층 촬영 기법을 통한 기관지 벽 평가는 유용한 방법임을 입증하였다. 또한,

기관지 벽을 의미하는 지표들 중에는 기관지벽-혈관 비율이 높은 재현성, 민감도, 특이도를 보였다. 임상적으로 진단된 천식 증후군이라는 제한점을 가지고는 있지만, 고양이에서 천식과 같이 기관지 벽의 비후를 동반하는 질환의 진단에 있어서 유용하다고 판단된다.

주요어: 고해상도 전산화단층촬영, 고양이, 기관지 벽 두께, 천식

학번 : 2011-30492