의학박사 학위논문

The Protective Effect of Systemic Steroid Administration in Hearing Preservation after Cochlear Implantation in Guinea Pigs

기니픽 동물 모델에서
전신적 스테로이드 투여의 와우 이식 후
청력 보존 효과에 대한 고찰

2017년 2월

서울대학교 대학원
의학과 이비인후과학 전공
나 윤 찬

A Thesis for a Doctoral Degree

기니픽 동물 모델에서 전신적 스테로이드 투여의 와우 이식 후 청력 보존 효과에 대한 고찰

The Protective Effect of Systemic Steroid Administration in Hearing Preservation after Cochlear Implantation in Guinea Pigs

February 2017

The Department of Otorhinolaryngology
-Head and Neck Surgery,
Seoul National University College of Medicine

Yoon Chan Rah

기니픽 동물 모델에서 전신적 스테로이드 투여의 와우 이식 후 청력 보존 효과에 대한 고찰

지도교수 이 준 호

이 논문을 나 윤 찬 의학박사 학위논문으로 제출함

2017년 1월

서울대학교 대학원

의학과 이비인후과학 전공

나 윤 찬

나 윤 찬의 박사학위논문을 인준함

2017년 1월

위원장	오 승 하	(인)
부위원장	이 준 호	(인)
위원	임 기 정	(인)
위원	박 철 기	(인)
위원	신 현 우	(인)

The Protective Effect of Systemic Steroid for the Hearing Preservation after Cochlear Implantation in Guinea Pigs

by
Yoon Chan Rah

A thesis submitted to the College of Medicine in partial fulfillment of the requirements for the Degree of Doctor of Philosophy in Medical Science (Otorhinolaryngology) at Seoul National University College of Medicine

January 2017

Approved by Thesis Committee:

Professor Seung-ha Oh Chairman
Professor Jun Ho Lee Vice chairman
Professor Gi Jung Im
Professor Chul-Kee Park
Professor Hyun-Woo Shin

Abstract

The Protective Effect of Systemic Steroid for the Hearing Preservation after Cochlear Implantation in Guinea Pigs

Yoon Chan Rah

Otorhinolaryngology, College of Medicine

The Graduate School

Seoul National University

Objectives: To determine the effectiveness of extended delivery of systemic steroids to preserve hearing in guinea pigs after cochlear implantation (CI).

Methods: Dexamethasone (4 mg/ml) was delivered parenterally via a mini-osmotic pump for either 3 or 7 days. The control group underwent CI without steroid infusion. A dummy CI electrode was inserted via a cochleostomy approach in 8-week-old guinea pigs. Auditory thresholds were assessed from tone burst auditory brainstem responses (2, 8, 16, 24, and 32 kHz) at 1 day prior to CI and 1, 4, and 12 weeks after implantation. Histologic evaluation of the cochleae was carried out.

Results: No differences were found in hearing thresholds among groups

before CI. Significant hearing preservation was achieved at 8, 16, 24, and 32 kHz only in the 7-day infusion group compared with the control group at 1 week after CI. The same trend was maintained at 4 weeks (16, 24 kHz) and 12 weeks (16, 24, and 32 kHz). Histologic review of the 7-day infusion group revealed less loose connective tissue deposition, less dense fibrosis in the scala tympani and the preservation of more spiral ganglion cells, compared with the control group.

Conclusion: Seven-day administration of systemic steroids was more effective in preserving residual hearing for 12 weeks after cochlear implantation (CI) than a 3-day delivery.

Key Words: Cochlear implant, Hearing loss, Steroid

Student Number: 2015-30582

CONTENTS

LIST OF TABLES AND FIGURES

Table

Figure

Introduction

The preservation of residual hearing after cochlear implantation (CI) is required to derive the audiological benefits of electro-acoustic stimulation (EAS) [1-4]. Electrode insertion can cause mechanical injuries to the basilar membrane and organ of Corti with subsequent activation of necrosis and apoptosis pathways [4-6]. Loss of perilymph, and trauma via a hydraulic pressure change could be another possible cause of intra-tympanic mechanical injuries associated with electrode insertion [4-6]. Soft surgical techniques (*i.e.*, a round window approach) or development of slim and short electrodes were tried and achieved successful preservation of residual hearing up to 85.7-96% and confirmed improvement in speech recognition especially under noise environment or in music perception [3-8]. However, hearing loss arising in cochlear regions apical to the tip of the inserted CI electrode, or delayed hearing loss after implantation, can result from metabolic causes, including the inflammatory responses to the surgical injury caused by electrode introduction [9].

Glucocorticoids have been prescribed for the treatment of various inner ear diseases, and especially to facilitate the restoration of hearing. One of its principal mechanisms of action is to inhibit the inflammatory

response [10]. Local delivery of glucocorticoids to the inner ear has been tried in various concentrations and delivery methods confirming significant preservation of hearing and spiral ganglion cell population [6, 11-12]. However, it has some significant limitations, for instance, diffusion through the round window membrane can fail due to micro-anatomical or physiologic factors [13]. Another limitation of local delivery is the ineffective preservation of low-frequency hearing in apical regions of the cochlea, which could result from a reduction in drug concentration from the base to the apex of the cochlea due to the concentration gradient and metabolism of the steroids [14, 15]. To overcome these limitations, a previous study used a guinea pig model to investigate pre-operative single injection of intravenous dexamethasone and achieved significant protection against hearing loss after cochlear implantation [16]. The present study evaluated the effect of the extended use of systemic steroid on hearing preservation after CI in guinea pigs, by analyzing correlations between the duration of steroid administration and long-term serial changes in auditory threshold. Intra-tympanic histologic changes were also assessed to investigate the underlying mechanisms.

Materials and Methods

Experimental animals and group allocation

A total of 21 female Hartley guinea pigs aged 8 weeks (350–450 mg) were divided into three groups: cochlear implantation without steroid infusion (control group; n = 5); steroid infusion subcutaneously for 3 days after cochlear implantation (3-day infusion group; n = 8); or 7 days (7-day infusion group; n = 8), commencing the night before implantation. The steroid was delivered parenterally by surgically inserted subcutaneous mini-osmotic pump. They were removed at either of 3 or 7 days after cochlear implantation according to the 3 day- or 7 day-steroid infusion group. The auditory threshold were measured preoperatively, at postoperative 1wk, 4wks, and 12wks. The pathologic evaluation of the cochlea was carried out at 12 wks after finishing planned experimental investigations. This study was approved by the Institutional Animal Care and Use Committee of Seoul National University Hospital (approval number: 12-0379-C1A1). The overall experimental schedules were described in Table 1.

Steroid infusion and cochlear implantation

Systemic steroid infusion was performed by inserting a dexamethasone-filled (4 mg/ml) mini-osmotic pump (Alzet model: 2ML1, Durect Corporation, Cupertino, CA, USA) into a subcutaneous pocket on the back of each guinea pig on a night prior to electrode insertion. The pump was filled with 2.0 mL of dexamethasone (4 mg/mL, after dilution with normal saline from dexamethasone sodium phosphate, 5 mg/ml, Huons, Seoul, Korea); the amount of steroid actually delivered was calculated by measuring the residual volume, following the manufacturer's protocol. The 7-day infusion group (6.4 mg) received almost double the dose of the 3-day group (3.2 mg), with similar daily doses per kilogram (2.32 mg/kg for 7-day infusion group; 2.59 mg/kg for 3-day infusion group) [10, 12]. Human equivalent dose was calculated using the formula based on the differences in the body surface area suggested by United States Food and Drug Administration [17]. Details regarding the human equivalent doses were described in Table 2.

For anesthesia, a mixture of 4 mg/kg ketamine (Ketamine HCl, 100 mg/2ml, Huons, Seoul, Korea) and 60 mg/kg xylazine (Rumpun™, 100 mg/ml, Bayer AG, Leverkusen, Germany) was injected intramuscularly. Local 1% lidocaine (Ilsung Pharmaceuticals, Seoul, Korea) was

injected subcutaneously to the surgical incision site prior to pump insertion and CI. The bulla was opened by drilling with a 2-mm-sized diamond burr, resulting in a wide exposure of the round window and the basal turn of the cochlea. The cochleostomy was carried out on the basal turn at 1 mm from the edge of the round window, with a 0.5-mm diamond burr. A dummy electrode (CI422 research electrode, Cochlear, Australia) was slowly introduced into the scala tympani to a depth of about 2.25 mm [6]. As soon as we felt resistance, we stopped advancement. A fascial plug was applied to prevent perilymph leakage.

Auditory threshold measurement

Auditory threshold was measured by the auditory brainstem response (ABR) using a Smart EP (Intelligent Hearing Systems, Miami, FL, USA) with the IHS high-frequency transducers (HFT9911–20–0035). A Blackmann-gated tone burst sounds lasting 5 ms (2.5 ms for rise and decay) at frequencies of 2, 8, 16, 24, and 32 kHz were presented directly to the ear canal in a sound-proof chamber. Recording subdermal needle electrodes were placed at the vertex, below the pinna of the left ear (reference), and below the contralateral ear (ground). Responses were recorded for 12 ms after stimulus onset and were amplified (200,000 X), band-pass filtered (100~3,000 Hz) and averaged

over 512 stimulus repetitions. The auditory thresholds were determined at the lowest sound level (dB) which exhibit a distinct ABR wave pattern during 5 dB decrements from 90 dB SPL by agreement of two independent researchers who were blinded to the study design and to the experimental group allocation. The average auditory thresholds of each group were measured and analyzed at each time point (preoperatively, 1, 4, and 12 weeks after CI).

Histology

At 12 weeks after CI, the animals were deeply anesthetized and cardiac perfusion was carried out with phosphate-buffered normal saline solution followed by 10% neutral buffered formalin (Sigma-Aldrich, St. Louise, MO, USA). Bilateral cochleae were harvested, decalcified in 4% ethylenediaminetetraacetic acid (EDTA, Sigma-Aldrich, St. Louise, MO, USA), embedded in paraffin and 5-μm sections were taken every 125 μm centered from mid-modiolar area. Then, they were mounted on the slides and stained with hematoxylin and eosin (H&E). They were examined with light microscopy (CX31, Olympus, Tokyo, Japan). The images containing the scala tympani, organ of Corti, and Rosenthal's canal with clear visualization of the hair cells were obtained and converted to JPEG files at the same

magnification. The degree of fibrosis and ossification were calculated by averaging 5-6 successive mid-modiolar sections as the relative area (%) occupied by the pathologic tissues compared with the area of the scala tympani using ImageJ software (National Institute of Health, Bethesda, MD, USA). The remaining inner and outer hair cells were also counted for each group. The density of spiral ganglion cells was measured by counting the clearly visible type I cell nuclei inside the Rosenthal's canal and divided by the measured canal area (mm^2) using Image J software. The hair cell numbers and spiral ganglion cell densities were also averaged across 5-6 successive mid-modiolar sections. All measurements were carried out by two histologists who were blinded to this study. Detailed description of the pathologic evaluation was described in Fig. 1. The pathologic evaluations were carried out at lower basal turn, lower mid turn, and lower apical turn as described in Fig. 2 and the results were compared between each groups.

Statistical analysis

The results are provided as the means (± standard deviation) or as percentages. The hearing thresholds of the three groups were compared using Kruskal–Wallis (K-W) test for each frequencies and the multiple pairwise comparison was carried out with the Bonferroni correction for

the auditory thresholds between the steroid-infusion groups and the control group. The threshold shift during first week [(1 week threshold) – (preoperative threshold)]

and between 1 and 12 weeks [(12 week threshold) – (1 week threshold)] were calculated and the threshold shifts of the three groups were compared with K-W test and the multiple pairwise comparison was also carried out with Bonferroni correction. Connective tissue depositions (%), ossifications (%), hair cell numbers (cells), and spiral ganglion cell density (cells/mm^2) of the three groups were compared using K-W test and the multiple pairwise comparison was also carried out with Bonferroni correction between the steroid-infusion groups and the control group. The differences in all pathologic variables were also compared among those from lower basal turn, lower mid turn, and lower apical turn using K-W test and the multiple pairwise comparison was also carried out with Bonferroni correction between each turns. We also analyzed the correlation between the histologic findings (the number of hair cells and spiral ganglion density) and the threshold shifts of anatomically corresponding hearing frequencies (24 kHz, 32 kHz and averaged 24 and 32 kHz thresholds shift). A *p*-value less than 0.05 was considered to indicate statistical significance. All analyses were performed using SPSS version 11.0 for Windows (IBM, New York, USA).

Results

Hearing changes

Prior to CI, the three groups exhibited no significant differences in auditory threshold over the entire frequencies. At 1 week after CI, auditory thresholds differed significantly among groups at 8, 16, 24, and 32 kHz (Table 3, Fig. 3). The 7-day infusion group exhibited a significantly better auditory threshold than the control group at the same frequencies. The significant differences in auditory thresholds were maintained at 4 weeks after CI at 16 and 24 kHz, and the 7-day infusion group had a significantly better auditory threshold compared with the control group at the same frequencies (Table 3, Fig. 3). Differences in auditory thresholds at 16, 24, and 32 kHz became more evident for all groups after 12 weeks postoperatively, and the 7-day infusion group had a significantly better auditory threshold at the same frequencies than that of the control group. Table 3 lists the details of the measured hearing thresholds and the detailed statistical results.

Significantly different average threshold shifts were found among groups during the first week after implantation compared with the preoperative auditory thresholds at 16 and 24 kHz (p=0.03 and p<0.01,

respectively, Fig. 4A). The 7-day infusion group exhibited significantly less threshold shift (19.50 ± 14.03 dB for 16 kHz; 14.50 ± 16.57 dB for 24 kHz) to that of the control group (42.50 ± 18.13 dB for 16 kHz; 43.13 ± 12.52 dB for 24 kHz) at the same frequencies (Fig. 4A). The 3-day infusion group exhibited intermediate threshold changes between control and the 7-day infusion groups (31.00 ± 18.07 dB for 16 kHz; 32.00 ± 20.90 dB for 24 kHz), however, the differences were not significant compared with the control group. Relatively small amount of auditory threshold changes were conformed during 1 and 12 week. For the threshold shift during 1 and 12 week, significant differences among groups were found at 16 and 32 kHz (p=0.031 and p=0.048, respectively, Fig. 4B). However, no significant differences were found between individual groups on multiple pairwise comparison (Fig. 4B).

Histologic changes

The occupied area (%) of loose connective tissue deposition, dense fibrosis, and ossification compared with the corresponding scala tympani area were analyzed. The number of hair cells, and spiral ganglion cell densities (per the area of the corresponding Rosenthal's canal, mm^2) were measured and analyzed. Representative histologic samples for each variables are shown in Fig. 5. In the analysis of the

lower basal turn and lower mid turn, significant differences were observed in loose connective tissue deposition (p = 0.036 and p = 0.048, respectively) among the groups. The control group had a relatively wider area of loose connective tissue deposition (46.9 ± 9.2%), compared with both steroid infusion groups (11.1 ± 2.6%, p = 0.017 for the 3-day infusion group; 11.3 ± 11.4%, p = 0.013 for the 7-day infusion group). The control group also had a relatively wider area of loose connective tissue deposition (31.8 ± 6.5%) than the 7-day infusion group (7.2 ± 2.0%, p = 0.031) in the lower mid turn. The apical turn had small areas of loose connective tissue deposition in all groups without significant significance. The control group (6.8 ± 2.3%) had a wider area of dense fibrosis compared with both steroid infusion groups (2.6 ± 0.8% for the 3-day infusion group, 0.8 ± 0.3% for the 7-day infusion group) in the lower basal turn, but this result was not statistically significant (p = 0.116). In the lower mid turn, those all group had small areas of dense fibrosis without significant differences and no definite dense fibrosis was observed in apical turn in all groups. Significant differences were observed in ossification among three groups (p = 0.011) in lower basal turn and the 3-day infusion group (12.4 ±1.1%) had a significantly wider area of ossification than the 7-day infusion group (0.4 ± 0.3%, p = 0.010). The control group had relatively wider area of ossification (8.9 ± 2.3%) than 3-day infusion

group (6.4 ± 1.3%) or 7-day infusion group (0.0 ± 0.0%) in mid turn, which failed show a significant statistical differences. The apical turn had no definite ossification in all groups. Details of histologic changes inside the scalar tympani were described in Fig. 6.

Spiral ganglion cell density differed among the groups (p = 0.011), with significantly more spiral ganglion populations in the 7-day infusion group (1624.9 ± 167.3 cells/mm^2) compared with the control group (695.0 ± 224.8 cells/mm^2, p = 0.046) in the lower basal turn. Analogous results were also confirmed for the mid turn (1421.5 ± 193.6 cells/mm^2 for 7-day infusion group, 643.1 ± 149.1 cells/mm^2 for control group; p = 0.048) and the apical turn (1573.2 ± 245.7 cells/mm^2 for 7-day infusion group, 589.2 ± 120.2 cells/mm^2 for control group; p = 0.038). The inner hair cell count did not reveal any statistically significant results, although the 7-day infusion group included almost double the number of hair cells compared with the control and 3-day infusion groups throughout all cochlear turns. Analogous results were confirmed for the investigation of the outer hair cell. Details for the changes of the inner ear structures were described in Fig. 7.

Significantly negative correlation was found between the spiral ganglion density and the averaged threshold shift of 24 and 32 kHz (ρ=-0.557, p=0.038). There was also borderline negative correlations between the spiral ganglion density and the 24 kHz (ρ=-0.491, p=0.075)

and 32 kHz (ρ=-0.500, p=0.069) threshold shifts. The hair cell numbers were also showed negative correlation with the threshold shifts and the number of inner hair cell and the 32 kHz threshold shifts showed borderline negative correlation (ρ=-0.474, p=0.087).

Discussion

Electrode insertion into the cochlea can cause direct damage to inner ear structures that come into contact with the electrodes. This induces an inflammatory response that may facilitate recovery [18], but an intense immune response can damage the cochlea, or the inserted electrode array can induce chronic inflammation with formation of fibrosis or ossification [19]. Glucocorticoid may reduce such responses by attenuating the effect of potent inflammatory mediators, up-regulating antioxidant enzyme activity, and reducing fibrosis formation [15, 20].

Some study investigated systemic infusion of glucocorticoid to preserve residual hearing after CI [15, 21, 22]. However, no studies have focused on whether hearing is preserved with extended use of a postoperative systemic steroid. In the present study, the hearing threshold of the 3-day infusion group was measured as intermediate between that of the control and 7-day infusion groups at 1 week after implantation. However, it worsened to the similar level of the control group, and differed significantly from that of the 7-day infusion group at 16, 24, and 32 kHz at 12 weeks after implantation. A study investigating the time course of murine inflammatory reaction revealed

that acute inflammatory response usually peaks at around 1 day after a wound and is down-regulated by 3 days [23]. After this time, the second phase of inflammatory response against a persistent injury or foreign body predominates: tissue is mainly infiltrated by immune effectors such as monocytes and lymphocytes. This peaks at around 7 days and subsides 10 days after a wound [23]. Next, the tissue repair process is mediated by fibrosis and angiogenesis, with key profibrotic cytokines, such as transforming growth factor (TGF) β [23, 24]. Both group commonly got glucocorticoid during initial 3 days which corresponds to the reported time interval of the acute inflammatory response. However, only 7-day infusion group got the glucocorticoid during the time periods of the second phase inflammatory response. The threshold shift of the 3-day infusion group (30.9 ± 17.4 dB) was almost similar with that of the control group (33.7 ± 17.9 dB) when averaged across whole frequencies during the first week, whereas the 7-day infusion group (21.8 ± 17.5 dB) exhibited significantly less threshold shift compared with them. This finding may suggest the importance of the protective role of glucocorticoid during the second phase of inflammation, which is known to be more destructive [25].

In the present study, the inserted depth of electrodes was about 2.25 mm; this location corresponds to 32 kHz, based on the equation suggested by Tsuji and Liberman [26]. Thus, threshold shifts in most

examined frequencies could be mainly resulted from metabolic causes rather than mechanical injury. The threshold shifts showed significantly negative correlation with spiral ganglion cell density, in accordance with the previous study [12] and the correlation was more obvious than those correlations with the number of hair cells. That might emphasize the importance of preserving the auditory nerve endings and the role of the glucocorticoid on that process, although cautions need to be exercised for a clear-cut conclusion due to the limited number of cases.

The amount of steroid infused to guinea pigs can be converted to a human equivalent dose (HED) using the formula for dose translation based on body surface area (BSA) suggested by the United States Food and Drug Administration [17]. The HED was 0.5 mg/kg/day for 7-day infusion group and 0.56 mg/kg/day for 3-day infusion group. The daily dose would correspond to 30 mg of dexamethasone (7-day infusion group) and 33.6 mg of dexamethasone (3-day infusion group) for a 60 kg adult human. These doses correspond to 200.1 mg of prednisolone (7-day infusion group) and 224.1 mg of prednisolone (3-day infusion group). Considering the current use of mega doses (500–1000 mg/day) for several disease such as optic neuritis, these amounts may be applicable to humans for hearing preservation as well [27].

The electrode insertion associated-histologic changes inside the scala tympani includes some characteristic findings than expected in a usual

inflammatory responses. First, the loose connective tissue deposition occupied the major tissue reaction. Similar findings were also reported in a previous study assessing the inflammatory tissue changes inside the scala tympani [6]. Those findings were associated with inflammation-derived tissue changes in a liquid-filled body cavity as reported in the previous studies that evaluated the changes inside the eye after inflammation [28]. Second, the neo-ossification was observed which was also found in the similar previous study [6]. It is well-known that severe intra-cochlear inflammation such as bacterial or viral meningitis could cause cochlear ossification [29, 30], which could support the intra-tympanic ossifications in this study. However, considering that the electrode insertion was carried out through cochleostomy, the possibility of the bone dust influx during the drilling or electrode introduction.

This study has several limitations. First, we could not measure plasma and cochlear concentration of steroid due to the need for animals to recover for extended periods of time following cessation of treatment. Instead, we measured the dose of steroid infused. Second, we could not determine the mechanism of steroid action in terms of hearing preservation, again because of the need to continue to monitor the hearing following the cessation of treatment. We obtained indirect evidence from histology. Third, these animals had normal hearing,

which differs from clinical cases involving humans with CI candidacy; thus, caution needs to be exercised extrapolating these findings to the hearing-impaired ear. We plan to extend this research using hearing-impaired animals with residual low frequency hearing. Fourth, we only evaluated the effect of electrode insertion. The influence of electrical stimulation between the electrodes and the adjacent cochlear structures need to be considered in the future.

Conclusion

Extended use of systemic glucocorticoid seems to be effective in long-term hearing preservation after CI, especially in the 7-day infusion group of guinea pigs with normal hearing. Based on the pathologic examination, the suspected mechanism is the suppression of inflammation and subsequent tissue changes.

References

[1] Kiefer J, Pok M, Adunka O, Stürzebecher E, Baumgartner W, Schmidt M, Tillein J, Ye Q, Gstoettner W. Combined electric and acoustic stimulation of the auditory system: results of a clinical study. Audiol Neurootol 2005;10(3):134-44.

[2] Talbot KN, Hartley DE. Combined electro-acoustic stimulation: a beneficial union? Clin Otolaryngol 2008;33:536-45.

[3] Gstoettner W, Kiefer J, Baumgartner WD, Pok S, Peters S, Adunka O. Hearing preservation in cochlear implantation for electric acoustic stimulation. Acta Otolaryngol 2004;124(4):348-52.

[4] Gantz BJ, Turner C, Gfeller KE, Lowder MW. Preservation of hearing in cochlear implant surgery: advantages of combined electrical and acoustical speech processing. Laryngoscope 2005;115(5):796-802.

[5] Eshraghi AA, Van de Water TR. Cochlear implantation trauma and noise-induced hearing loss: Apoptosis and therapeutic strategies. Anat Rec A Discov Mol Cell Evol Biol 2006;288(4):473-81.

[6] James DP, Eastwood H, Richardson RT, O'Leary SJ. Effects of round window dexamethasone on residual hearing in a Guinea

pig model of cochlear implantation. Audiol Neurootol 2008;13:86-96.

[7] Gantz BJ, Turner CW. Combining acoustic and electrical hearing. Laryngoscope 2003;113(10):1726-30.

[8] Lehnhardt E. Intracochlear placement of cochlear implant electrodes in soft surgery technique. HNO 1993;41:356-59.

[9] Adunka O, Roush P, Grose J, Macpherson C, Buchman CA. Monitoring of cochlear function during cochlear implantation. Laryngoscope 2006;116:1017-20.

[10] Crane RA, Camilon M, Nguyen S, Meyer TA. Steroids for treatment of sudden sensorineural hearing loss: A meta-analysis of randomized controlled trials. Laryngoscope 2015;125:209-17.

[11] Chang A, Eastwood H, Sly D, James D, Richardson R, O'Leary S. Factors influencing the efficacy of round window dexamethasone protection of residual hearing post-cochlear implant surgery. Hear Res 2009;255(1-2):67-72.

[12] Maini S, Lisnichuk H, Eastwood H, Pinder D, James D, Richardson RT, Chang A, Connolly T, Sly D, Kel G, O'Leary SJ. Targeted therapy of the inner ear. Audiol Neurootol 2009;14(6):402-10.

[13] Goycoolea MV, Lundman L. Round window membrane. Structure function and permeability: a review. Microsc Res Tech

1997;36:201-11.

[14] Plontke SK, Biegner T, Kammerer B, Delabar U, Salt AN. Dexamethasone concentration gradients along scala tympani after application to the round window membrane. Otol Neurotol 2008;29:401-6.

[15] Plontke SK, Glien A, Rahne T, Mäder K, Salt AN. Controlled release dexamethasone implants in the round window niche for salvage treatment of idiopathic sudden sensorineural hearing loss. Otol Neurotol. 2014;35:1168-71.

[16] Connolly TM, Eastwood H, Kel G, Lisnichuk H, Richardson R, O'Leary S. Pre-operative intravenous dexamethasone prevents auditory threshold shift in a guinea pig model of cochlear implantation. Audiol Neurootol 2011;16:137-44.

[17] Center for Drug Evaluation and Research, Center for Biologics Evaluation and Research. (2002) *Estimating the safe starting dose in clinical trials for therapeutics in adult healthy volunteers*, U.S. Food and Drug Administration, Rockville, Maryland, USA.

[18] Tornabene SV, Sato K, Pham L, Billings P, Keithley EM. Immune cell recruitment following acoustic trauma. Hearing research 2006;222:115-24.

[19] Choi CH, Oghalai JS. Predicting the effect of post-implant

cochlear fibrosis on residual hearing. Hear Res 2005;205:193-200.

[20] Tuor UI, Simone CS, Arellano R, Tanswell K, Post M. Glucocorticoid prevention of neonatal hypoxic-ischemic damage: role of hyperglycemia and antioxidant enzymes. Brain Res 1993;604:165-172.

[21] Lee J, Ismail H, Lee JH, Kel G, O'Leary J, Hampson A, et al. Effect of Both Local and Systemically Administered Dexamethasone on Long-Term Hearing and Tissue Response in a Guinea Pig Model of Cochlear Implantation. Audiol Neurotol 2013;18:392-405.

[22] Quesnel S, Nguyen Y, Elmaleh M, Grayeli AB, Ferrary E, Sterkers O, et al. Effects of systemic administration of methylprednisolone on residual hearing in an animal model of cochlear implantation. Acta Otolaryngol 2011;131:579-84.

[23] Stramer BM, Mori R, Martin P. The inflammation-fibrosis link? A Jekyll and Hyde role for blood cells during wound repair. J Invest Dermatol 2007;127:1009-17.

[24] Cowin AJ, Brosnan MP, Holmes TM, Ferguson MW. Endogenous inflammatory response to dermal wound healing in the fetal and adult mouse. Dev Dyn 1998;212:385-93.

[25] Khansari N, Shakiba Y, Mahmoudi M. Chronic inflammation

and oxydative stress as a major cause of age-related disease and cancer. Recent Pat Inflamm Allergy Drug Discov 2009;3(1):73-80.

[26] Tsuji J, Liberman MC. Intracellular labeling of auditory nerve fibers in guinea pig: central and peripheral projections. J Comp Neurol 1997;381:188-202.

[27] Gal RL, Vedula SS, Beck R. Corticosteroids for treating optic neuritis. Cochrane Database Rev 2015;14;8:CD001430. doi: 10.1002/14651858.CD001430.pub4. Review.

[28] Fibrosis and diseases of the eye. Martin Friedlander. J Clin Invest 2007;117(3):576-86.

[29] Cochlear ossification after meningitis. Axon PR, Temple RH, Saeed SR, Ramsden RT. Am J Otol 1998;19:19(6):724-9.

[30] Cochlear implantation after bacterial meningitis in children: outcomes in ossified and nonossified cochleas. Nichani J, Green K, Hans P, Bruce I, Henderson L, Ramsden R. Otol Neurotol 2011;32(5):784-9.

Table 1. Time course of experiments

Time	CI-1D	CI	CI+3D	CI+7D(1W)	CI+4W	CI+12W
Surgery	Pump insertion	CI	Pump removal (3D group)	Pump removal (7D group)		Sacrifice & Cochlear harvest
ABR	Baseline			1 W	4 W	12 W

CI: cochlear implantation, D: day(s), W: week(s), ABR: auditory brainstem response

Table 2. Actually infused dose of dexamethasone and corresponding human equivalent dose

Group	Total dose	Daily dose	Human daily dose* (Dexamethasone)	Human daily dose* (Prednisone)
7 Day	6.72 mg	0.96 mg (2.13 mg/kg)	0.46 mg/kg	3.04 mg/kg
3 Day	2.88 mg			

* Human equivalent dose was calculated using the formula based on the differences in the body surface area suggested by United States Food and Drug Administration

Table 3. Change of hearing thresholds

Time	Group	2k	*p**	8k	*p**	16k	*p**	24k	*p**	32k	*p**
Preop	Control	48.8	-	45.6	-	33.1	-	26.3	-	39.4	-
	3 day	41.5	-	36.0	-	30.5	-	25.0	--	30.5	-
	7 day	42.0	-	39.0	-	31.5	-	33.0	-	36.0	-
	K-W test	-	0.136		0.359	-	0.906	-	0.369	-	0.162
1 week	Control	70.0	-	78.1	-	75.6	-	69.3	-	68.7	-
	3 day	73.5	-	79.0	1.000	61.5	0.149	57.0	0.133	57.5	0.070
	7 day	67.0	-	62.0	**0.045**	51.0	**0.004**	47.5	**0.003**	52.5	**0.005**
	K-W test	-	0.682	-	**0.028**	-	**0.006**		**0.006**	-	**0.006**
4 week	Control	75.6	-	76.8	-	73.7	-	66.2	-	67.5	-
	3 day	77.5		76.5	-	68.0	1.000	61.5	1.000	62.0	-
	7 day	64.5	-	63.5	-	54.0	**0.039**	48.0	**0.008**	54.0	-
	K-W test	-	0.224	-	0.321	-	**0.030**	-	**0.009**	-	0.088
12 week	Control	78.7	-	80.0	-	73.7	-	70.6	-	70.6	-
	3 day	75.0	-	71.5	-	71.5	1.000	68.5	1.000	69.0	1.000
	7 day	67.0	-	69.5	-	52.0	**0.003**	53.5	**0.025**	50.0	**0.002**
	K-W test	-	0.092	-	0.228	-	**0.004**	-	**0.018**	-	**0.003**

* Results of Kruskal-Wallis test for all groups (marked with K-W test) or Post-hoc test using Bonferroni correction compared with control groups

Preop: preoperative, K-W test: Kruskal-Wallis test

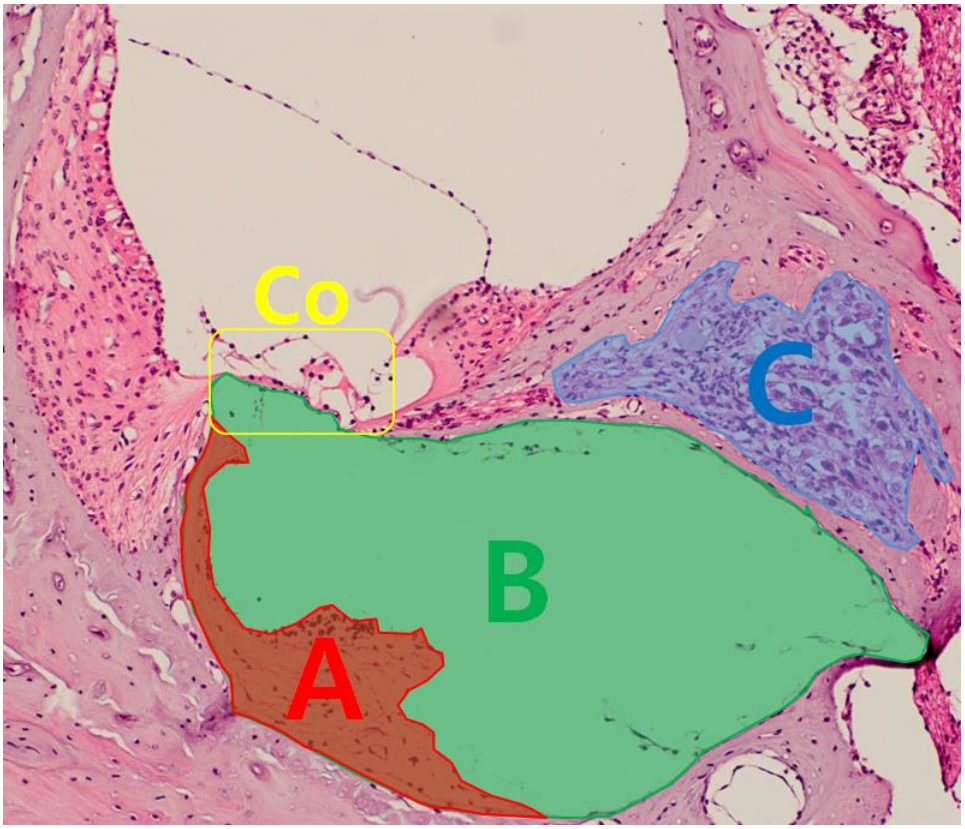

Figure 1. Comprehensive description of the pathologic evaluation. The degree of loose connective tissue deposition, dense fibrosis, or ossification was calculated as relative area (%) comparing to the corresponding whole scala tympani area. The pathologic tissue-occupied area (A) was divided by the whole scala tympani area (B). The spiral ganglion cell density was calculated by dividing the counted number of type I spiral ganglion cell nuclei by the measured area of Rosenthal's canal (mm^2, C). The number of inner and outer hair cells were directly counted at the organ of Corti (Co). All pathologic measurements were carried out by averaging 5-6 successive mid-

modiolar sections with ImageJ software (National Institute of Health, Bethesda, MD, USA).

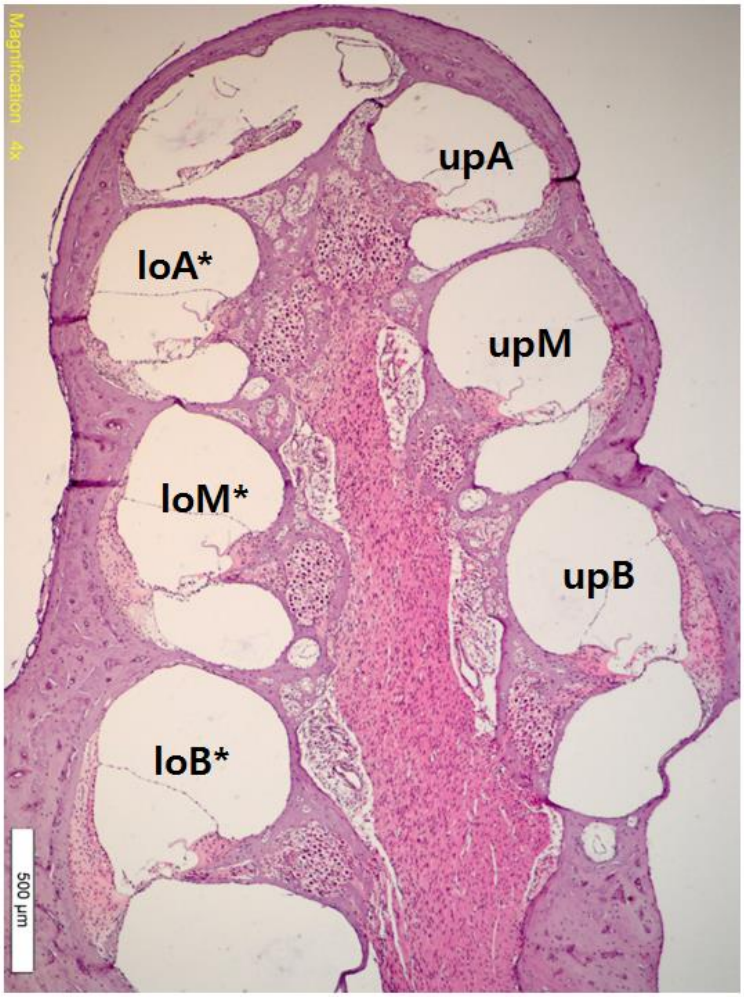

Figure 2. Representative image of cochlear turns of guinea pig where the pathologic assessment was carried out. Various pathologic evaluations were carried out in lower basal turn, lower mid turn, lower apical turn as marked with asterisk.

upA: upper apical turn, loA: lower apical turn, upM: upper mid turn, loM: lower mid turn, upB: upper basal turn, loB: lower basal turn

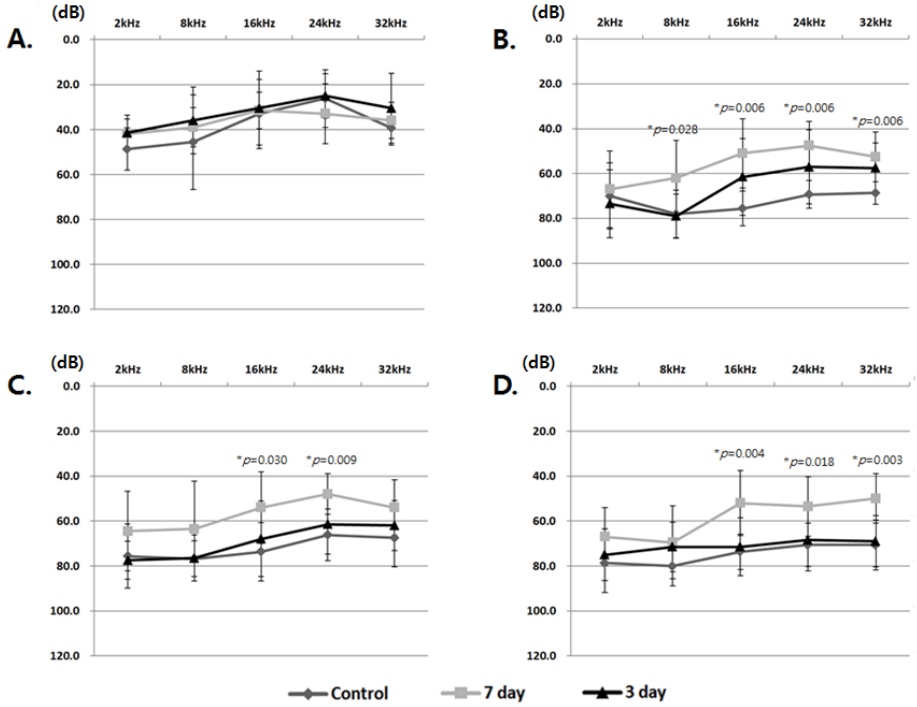

Figure 3. Change of auditory threshold according to groups. Initially, there was no significant difference in auditory thresholds (A). After implantation, significant differences were developed among hearing thresholds (at 8, 16, 24, 32 kHz) of each groups with significantly different auditory thresholds only between 7-day infusion and control group at 1 week after implantation (B). The same trends (at 16, 24 kHz) were maintained at 4 weeks after implantation (C). At 12 weeks after implantation, significant differences of auditory thresholds were observed at 16, 24, 32 kHz with significantly different thresholds only between 7-day infusion and control group (D).

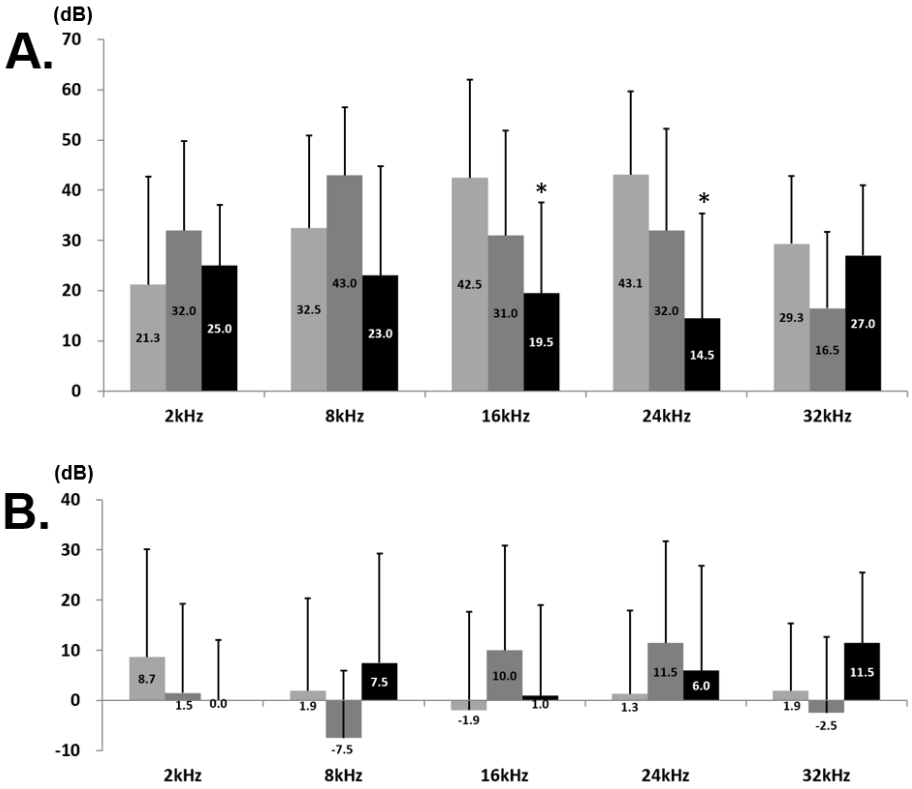

Figure 4. The average threshold shifts during the first week [(1 week threshold) – (preoperative threshold)] (A), and during 1 week and 12 weeks [(12 week threshold) – (1 week threshold)] (B) after cochlear implantation (CI). Most threshold shifts developed during the first week after CI with significant differences among groups for 16 kHz (p=0.03*, F=6.98, df=2) and 24 kHz (p<0.01*, F=9.45, df=2). The 7-day infusion group exhibited less threshold shift compared with the control group at 16 kHz (p=0.012) and 24 kHz (p=0.01). (A). Relatively small threshold shifts were observed between 1 week and 12 weeks after CI (B). The changes of 16 kHz (p=0.031*, F=6.97, df=2)

and 32 kHz (p=0.048*, F=6.06, df=2) were significantly different among groups, however, following multiple pairwise comparison revealed no significant differences between individual groups.

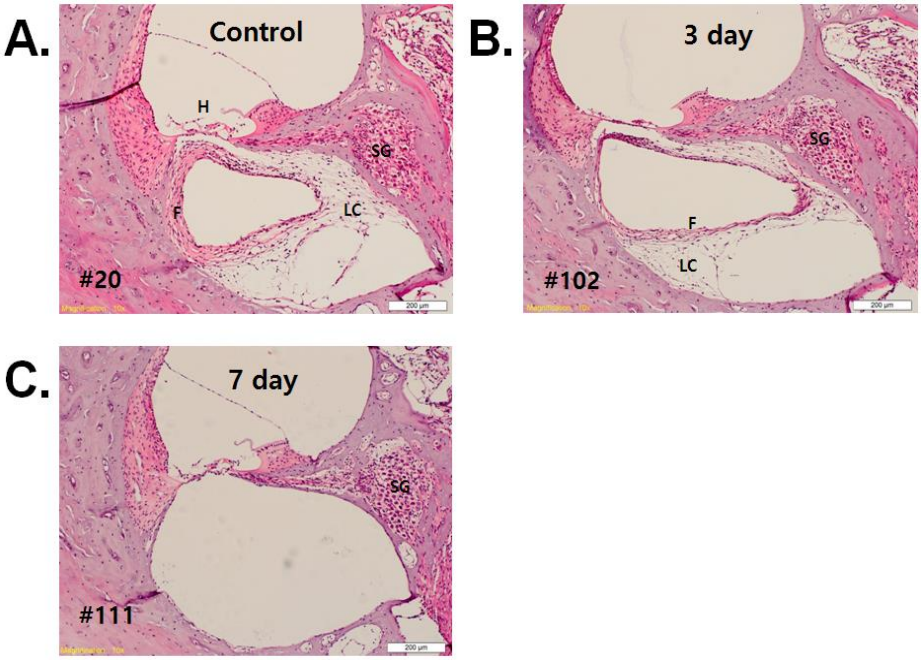

Figure 5. Representative samples of histologic changes of control group (A, case number 20), 3-day infusion group (B, case number 102), 7-day infusion group (C, case number 111). Most samples showed various degree of loose connective tissue deposition (LC), dense fibrosis (F), in scala tympani. Auditory hair cells (H) and spiral ganglion cells (SG) were also identified.

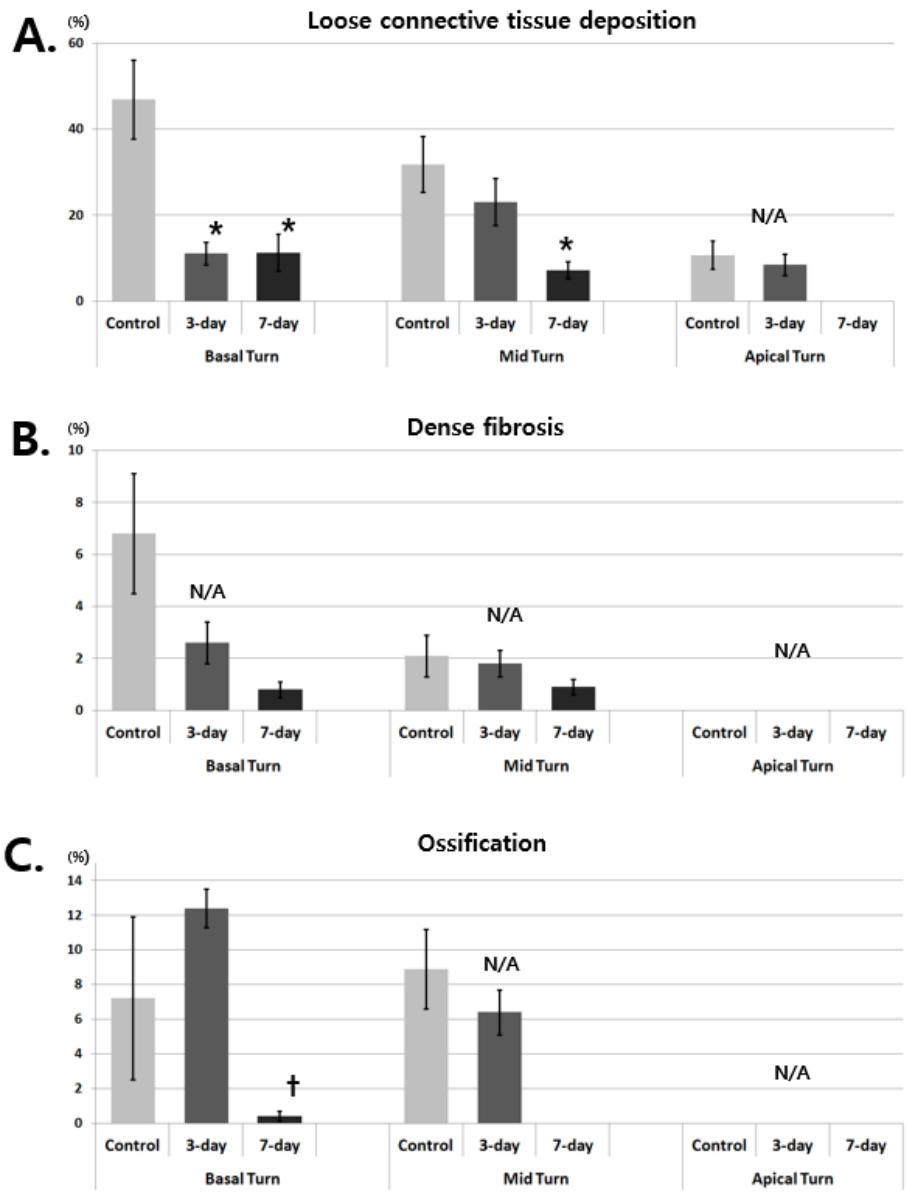

Figure 6. Quantitative analysis of histologic changes inside the scala tympani. Both steroid- infusion group had significantly narrower area of loose connective tissue deposition than control group in basal turn (p = 0.017 for 3-day infusion group, p = 0.036 for 7-day infusion group;

Bonferroni correction, A) and 7-day infusion group in mid turn (p = 0.045; Bonferroni correction, A). Both steroid-infusion group had narrower area occupied by dense fibrosis, however, those difference failed to show statistical significance (B). For ossification, a significant differences was found among three groups in the results of the basal turn (p = 0.011, χ^2=8.99, df=2, C). However, both steroid-infusion group failed to show significantly different ossification-occupied area compared with control group in the following multiple pairwise comparisons.

* Statistically significant differences compared with control group by Bonferroni correction

N/A: *Post hoc* analysis was not applicable due to the insignificance in the Kruskal-Wallis test among three groups.

† Statistically significant differences between 3-day and 7-day infusion group by the Bonferroni corrections

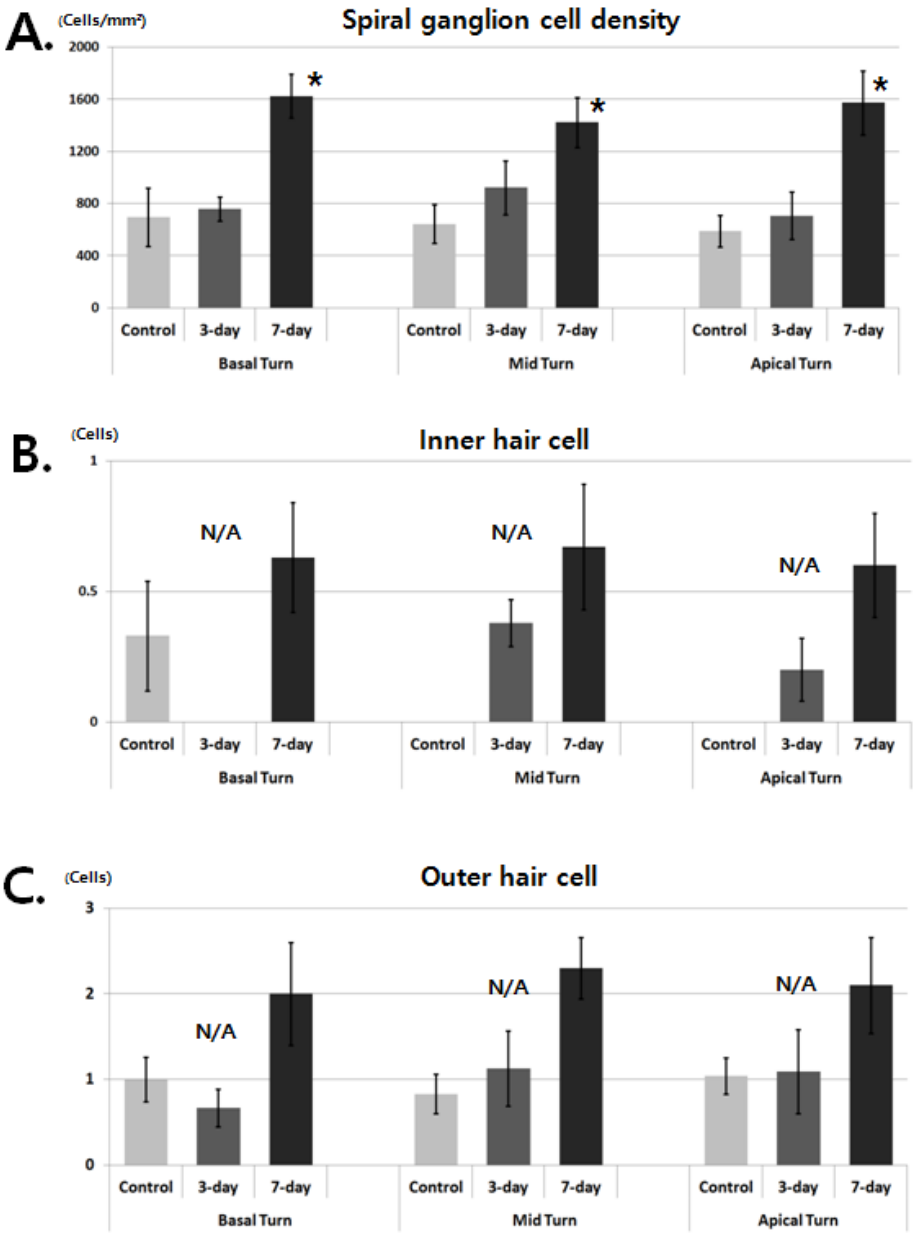

Figure 7. Quantitative analysis of the changes in the inner ear structures. Significantly more remaining spiral ganglion cells were confirmed in 7-day steroid infusion group compared with control group in the analysis of basal turn (p = 0.046), mid turn (p = 0.048), apical turn (p = 0.038)

(A). Auditory hair cells counts failed to show statistical significance in the analysis of inner hair cell (B) and out hair cell (C) in all three cochlear turns.

* Statistically significant differences compared with control group by Bonferroni correction

N/A: *Post hoc* analysis was not applicable due to the insignificance in the Kruskal-Wallis test among three groups.

국 문 초 록

연구목적: 장기간 전신 스테로이드 투여가 기니픽 동물 모델에서 와우이식 후 청력 보존에 미치는 효과에 대한 고찰

연구방법: 실험군에는 삼투압 펌프 이식을 통해 덱사메타손(Dexamethasone, 4 mg/ml)을 3일(3일 투여군) 혹은 7일(7일 투여군)간 투여하며, 대조군에는 투여하지 않는다. 실험용 인공와우전극을 8주령 기니픽의 와우에 와우 개창술을 통해 삽입한다. 청성뇌간유발청력역치검사를 실험 전날, 실험 후 1주, 4주, 12주에 2, 8, 16, 24, 32 kHZ에서 측정하여 비교 분석한다. 12주에 와우 병리 검사를 통해 와우 내의 조직 변화를 비교 분석한다.

연구결과: 와우이식 전에는 각 군간의 유의한 청력 차이는 관찰되지 않았다. 스테로이드 7일 투여군에서 대조군에 비해 8, 16, 24, 32 kHz에서 유의하게 적은 청력 역치 변화가 확인되었으며, 4주에는 16, 24 kHz에서, 12주에는 16, 24, 32 kHz에서 같은 결과가 확인되었다. 병리조직검사 상에서는 7일 투여군에서 대조군에 비해 유의하게 적은 고실계 내부의 섬유화 및 골화를 확인할 수 있었으며, 유의하게 많은 수의 나선신경절세포를 확인할 수 있었다.

결론: 와우 이식 후 12주까지 평가하였을 때에 전신 스테로이드 7일 투여는 대조군에 비해 유의하게 효과적인 청력보존 효과가 있음을 확인할 수 있었다.

주요어: 와우이식, 청력 감소, 스테로이드

학 번: 2015-30582