creative commons
COMMONS DEED

저작자표시-비영리-변경금지 2.0 대한민국

이용자는 아래의 조건을 따르는 경우에 한하여 자유롭게

- 이 저작물을 복제, 배포, 전송, 전시, 공연 및 방송할 수 있습니다.

다음과 같은 조건을 따라야 합니다:

저작자표시. 귀하는 원저작자를 표시하여야 합니다.

비영리. 귀하는 이 저작물을 영리 목적으로 이용할 수 없습니다.

변경금지. 귀하는 이 저작물을 개작, 변형 또는 가공할 수 없습니다.

- 귀하는, 이 저작물의 재이용이나 배포의 경우, 이 저작물에 적용된 이용허락조건을 명확하게 나타내어야 합니다.
- 저작권자로부터 별도의 허가를 받으면 이러한 조건들은 적용되지 않습니다.

저작권법에 따른 이용자의 권리는 위의 내용에 의하여 영향을 받지 않습니다.

이것은 이용허락규약(Legal Code)을 이해하기 쉽게 요약한 것입니다.

Disclaimer

dCollection

치의학박사 학위논문

Clinical outcome of intentional replantation of teeth: a retrospective study

의도적 재식술의 임상 결과에 대한 후향적 연구

2014년 2월

서울대학교 대학원

치의학과 치과보존학 전공

최 용 훈

Abstract

Clinical outcome of intentional replantation of teeth: a retrospective study

Yong-Hoon Choi, D.D.S., M.S.D.

Program in Conservative Dentistry

Department of Dentistry

Graduate School, Seoul National University

(Directed by Prof. Byeong-Hoon Cho, D.D.S., M.S.D., Ph.D.)

Objectives. The aims of this retrospective study were to evaluate the clinical outcomes of intentional replantation (IR) of teeth in terms of tooth survival and periradicular healing and to investigate their prognostic factors.

Methods. Two hundred and eighty-seven teeth treated by IR were analyzed retrospectively. Clinical outcomes between the cases with preoperative orthodontic extrusion for 2-3 week and those without extrusion were analyzed. The outcomes of IR were determined by clinical symptoms, tooth function, and radiographic evaluation. The probabilities of tooth survival and periradicular healing estimates were compared using Kaplan-Meier analysis. The contribution of a patient's age and sex, tooth

type and location, and preoperative orthodontic extrusion were investigated using the multivariate Cox proportional hazard model.

Results. The mean follow-up period was 25.4 ± 9.3 months. The overall success rate of IR was 89.5 % based on periradicular healing. However, the success rate of IR was 83.2% for the teeth extracted without extrusion and 94.4% for those extracted with extrusion. The overall tooth survival rate was 95.1%. The survival rates were 91.2% for the teeth extracted without extrusion and 98.1% for those extracted with extrusion. Among the variables tested, only the extraction technique with preoperative orthodontic extrusion significantly affected the survival rate (p =0.016). However, other prognostic variables, such as patient's age and sex, tooth type and location did not affect the survival of intentionally replanted teeth.

Significance. IR can be a viable treatment option for teeth with previously failed nonsurgical root canal treatment, regardless of a patient's age and sex, and tooth type and location. From this study, a preoperative orthodontic extrusion for 2-3 weeks before IR reduced root resorption and tooth fracture and would be recommended for successful IR.

Keywords: Extraction technique; Intentional replantation; orthodontic extrusion; Success estimate; Survival estimate

Student Number: 2010-30643

Contents

Abstract (in English)

Introduction ----------1

Materials and Methods ----------4

Results ----------13

Discussion ----------16

Conclusions ----------21

References ----------23

Tables and Figures ----------26

Abstract (in Korean) ----------32

Clinical outcome of intentional replantation of teeth: a retrospective study

Yong-Hoon Choi, D.D.S., M.S.D.
Program in Conservative Dentistry
Department of Dentistry
Graduate School, Seoul National University
(Directed by Prof. Byeong-Hoon Cho, D.D.S., M.S.D., Ph.D.)

Introduction

The intentional replantation (IR) procedure, which includes purposeful extraction, extra-oral periradicular surgery, and repositioning, has been used in dentistry for more than 250 years (1-3). Despite the lack of long term evidence, in the literature, IR has been considered as a fast, predictable, and reliable means of retaining a natural tooth that would otherwise be lost to extraction (1, 2, 4-9). Most studies have evaluated dental implants by using the survival rate of retained implants as an

outcome measure (10). However, most IR studies used clinical and radiographic evaluations to investigate the success rate of the procedure based on periradicular healing (2, 11). According to the periradicular healing, a clinical study of IR reported that 82% out of 192 teeth survived for 6-51 months (6). Another study reported 3 year success rate of 95% for 151 teeth (5). Bender and Rossman concluded in their 22 year study that IR reduced adverse outcomes and, therefore, it should not be regarded as a last resort, but as another treatment option, such a periradicular surgery (2).

There are several prognostic factors for IR. To prevent ankylosis or pathologic root resorption in traumatically avulsed and intentionally replanted teeth, scientists have extensively studied the importance of potential prognostic factors, such as, preserving a sound periodontal ligament (PDL) around the extracted root surface, preventing mechanical damage and chemical contamination, and careful extra-oral procedures (2, 4, 5, 7, 8, 12). A clinically successful IR technique should avoid any crushing or scraping contact with the root surface or socket (7, 8). Many authors have emphasized that careful extraction without fracturing the tooth is crucial for successful IR (1, 2, 5, 7, 8). The IR techniques usually involve using extraction forceps with a slow and firm luxating force by

holding the tooth above the cementoenamel junction (7, 8). However, most teeth requiring IR have weakened tooth structure due to previous root canal treatment or post and core treatment. Therefore, grasping the crown would increase the possibility of breakage (13). Extraction failure which is the most serious complication of IR procedure must be evaluated for outcome of this procedure. Because the most common indication for IR is for multi-rooted posterior teeth in which nonsurgical root canal treatment has failed and periradicular surgery is not feasible, extraction method of posterior teeth is important. In addition to the extraction technique, other factors that may affect the results of IR are extraction time, extra-oral time, a patient's age and sex, and the location and type of teeth (11).

Recently, improved atraumatic safe extraction (ASE) method for intentional replantation was suggested (14). It recommended preoperative orthodontic extrusion for 2-3 weeks before surgery to increase tooth mobility and volume of PDL, as a result, which could induce extraction more successful and reduce root resorption and ankylosis. Preoperative orthodontic extrusion for 2-3 weeks was recommended in the IR of the teeth that had a complicated root structure and high risk of fracture during extraction. The teeth that had received repeated nonsurgical root

canal treatments, and that had multiple relatively large and physically weak roots, or little coronal crown structure to grasp because of substantial decay or existing core restorations were indicated for the pre-operative orthodontic extrusion before extraction procedure.

This study evaluated whether the IR technique using orthodontic extrusion could improve the clinical outcome of the IR. For this purpose, the survival estimates (based on periradicular healing and functional success) and their prognostic factors of the 287 intentionally replanted teeth that survived until follow-up periods were retrospectively investigated.

Materials and Methods

This study was conducted after the approval from the institutional review board of the Seoul National University-Bundang Hospital (IRB no. B-1109/136-104). This was a retrospective cohort study that included 287 teeth from 285 patients who received IR from 2008 to 2011 at the Department of Conservative Dentistry of the Seoul National University-Bundang Hospital (Seoul, Korea). The mean age of the patients was 41.2

± 14.3 years, and the age range was 11–77 years. There were 121 men and 164 women. Most of the patients had no notable medical history, and they all were in relatively good health. Some patients who had high blood pressure or took aspirin daily were sent to their physicians for medical consultation before surgery. Inclusion criteria of this study was defined as those teeth 1) for which nonsurgical endodontic retreatment failed to alleviate symptoms, 2) in which the fractured instrument could not be removed or bypassed, 3) in which the calcified canal with persistent symptomatic apical periodontitis was not negotiated, 4) for which periradicular surgery was infeasible because anatomical structures (e.g., the inferior alveolar nerve, maxillary sinus, and dense cortical bone) limited accessibility and made it difficult to perform periradicular surgery, 5) for which excessive bone reduction was anticipated during periradicular surgery comparing the size of periapical lesion, and 6) for which previous periradicular surgery has failed. In addition to these criteria, only single tooth was included that had at least one neighboring sound tooth without pathologic mobility or dental implant. Teeth with healthy PDL, normal physiologic mobility and moderate periodontal pocket depths (i.e., < 5mm) were confirmed with radiographs and periodontal probing. Abutment teeth for fixed bridge or removable dentures were not

included because of fixation difficulties after surgery. Teeth with periodontal disease, horizontal and vertical cracks, and radiographic evidence of iatrogenic perforation were not included. Teeth with divergent root hampering safe extraction were also excluded.

Intentional replantation protocol

Patient preparation

One endodontist performed the IR procedures for all patients in this study. All patients provided the informed consent after the nature of the procedure and the possible risks and benefits had been explained. Teeth were extracted with pre-operative orthodontic extrusion or without extrusion. One hundred and sixty-two cases were orthodontically extruded for 2-3 weeks before surgery to increase mobility and the volume of PDL. One hundred and twenty-five were extracted without orthodontic extrusion.

For pain control, all patients received 400 mg of ibuprofen 30 minutes before the surgery. A prophylactic antibiotic (amoxicillin, 2.0g) was prescribed, if required. The patients were anesthetized with 2% lidocaine (with 1:80,000 epinephrine, Huons, Hwasung, South Korea) using

infiltration and block anesthesia techniques. Patients were instructed to rinse with 0.2% chlorhexidine gluconate before surgery for 1 minute. The surgical field was isolated in the same aseptic manner that is used for minor dental surgery. The operation time, including the extraction time and the extra-oral time, was recorded in seconds using a digital stopwatch.

Preoperative orthodontic extrusion

For preoperative orthodontic extrusion, a space for the orthodontic extrusion was created by removing the existing crown restoration and reducing the occlusal contacts. An orthodontic button was bonded to the tooth that was to undergo IR, and brackets were bonded to the adjacent anterior and posterior teeth. The orthodontic button was placed slightly gingivally, and an extrusive force of 50 g was applied for 2–3 weeks by ligation with a 0.014-inch round NiTi wire. In case of the most posterior tooth, 0.016 X 0.022 inch rectangular TMA wire was bended as an L-loop to generate extrusive force. Slight extrusion of 1–2 mm and increased mobility were obtained after extrusion. However, when orthodontic extrusion was not anticipated, existing full coverage restorations were not

removed. Provisional restorations and provisionally cemented permanent crowns were removed.

Extraction procedures

To avoid tooth fracture and minimize mechanical damage to the PDL, elevators were not used to luxate the tooth prior to extraction. Physics forcep (Golden Misch, Detroit, MI, USA) was used to prevent the beaks from sliding down into the sulcular region, which would injure the root surface and periodontal tissue. A slow and weak continuous force was applied bucco-lingually with care. While the beaks were placed at the cervical area of the lingual or palatal root surface above the cementoenamel junction, the buccal bumper was placed at the mucogingival junction on the buccal cortical bone (15). A steady, slow rotational force was applied by using only the wrist. The last stage of extraction in which the tooth was rotated or elevated was performed using a conventional dental forceps.

Extra-oral root-end treatment procedures

Patients were instructed to bite on moist gauze during the extra-oral procedures. The extracted tooth was gently rinsed with physiologic saline. Under a dental microscope (OPMI Pico, Carl Zeiss, Oberkochen, Germany), the extracted tooth was examined for any abnormalities such as fractures, cracks, and accessory canals. The tooth was held gently on the crown with physiologic saline-soaked gauze during the extra-oral procedure. A cylindrical high-speed diamond bur (Mani, Tokyo, Japan) was used to resect 2–3 mm of the root end. A 3-mm deep root-end cavity and an undercut were prepared using a # 330 high speed bur (Mani, Tokyo, Japan). The root-end cavity was dried with paper points and filled with white mineral trioxide aggregate (ProRoot MTA, Dentsply Tulsa, Tulsa, OK, USA).

Repositioning procedures

Periapical granulation tissue was cautiously removed from the periapical region using a surgical curette with caution to prevent from damaging the socket wall. Blood clots were removed by normal saline rinsing. The tooth was repositioned into the socket, and its location was evaluated. After inserting the tooth, the patient was instructed to bite on a rolled gauze to

push the tooth into the extraction socket and to prevent extrusion of the tooth from the extraction socket. Finger pressure was applied to adapt the buccolingual alveolar bone with the root surface of the tooth. Patients were instructed to bite on the rolled gauze for 2 hours and to maintain a soft diet for 10 days. When there was insufficient initial stability after repositioning or no opposing tooth to bite gauze, the repositioned teeth were splinted on the buccal surface with the adjacent teeth using a flexible orthodontic stainless steel round wire (Dentaflex 0.45mm, Dentaurum, Ispringen, Germany) and a nanofilled flowable resin composite (Filtek Supreme Ultra, 3M ESPE, St. Paul, MN, USA) for 10-14 days. Ibuprofen 600 mg every 8 hours were prescribed for 2 days.

Clinical and radiographic assessments

One week after surgery, all patients were recalled for a routine post-operative assessment and the sutures were removed if needed. For teeth splinted, resin wire splint was also removed after 10-14 days from splinting. Patients were then evaluated from 2 months after surgery, when the PDL was expected to heal.

Assessment was done according to the classification of the outcomes that was modified from the criteria previously described by Hayashi *et al.* (11). The outcomes were categorized as either 'Survival' or 'Failure'. These 2 categories were further subdivided into 'periradicular healing' and 'functional success' for the survival category and 'functional failure' and 'extraction failure' for the failure category. The criteria for each category were described in Table 1. Tooth fracture during extraction that had to be extracted was classified as 'extraction failure'. Root tip fractured less than 3 mm did not hamper the procedure and was not included in the 'extraction failure' category.

Intentionally replanted teeth were evaluated at each recall appointment in every 6 month interval. The outcome of IR was evaluated based on the clinical and radiographic examination. The examination was performed independently by two clinicians. Disagreements between the observers, were resolved by consensus. If a patient complained of pain, tenderness, or discomfort to percussion or bite test, if a swelling or fistula was present, or if a deep periodontal pocket was detected, this case was classified as 'functional failure'.

In the absence of clinical symptoms, the outcome was determined using digital intra-oral periapical radiographs (Heliodent; Sirona, Bensheim, Germany) Radiographic assessment was also performed independently by two endodontists. If there was a disagreement between the observers, it was resolved by consensus. Inflammatory root resorption and replacement root resorption were classified as 'functional failure'. Increased radiolucency or no evidence of bone regeneration after 6 months was classified as 'functional failure'. Teeth with minimal and arrested root resorption, but with normal lamina dura and PDL space and no definite clinical symptoms were included in the 'functional success'.

At 2-3 months after the surgery, if clinical symptoms and radiographic findings did not reveal any abnormality, a gold or porcelain-fused-to-gold crown was fabricated if needed. Further recall examinations were scheduled at 6-month intervals.

Statistical analyses

The Student's *t*-test was used to compare the extraction time between the two extraction methods with and without extrusion. The survival estimates were evaluated for each variable using the Kaplan-Meier

survival analysis repeatedly. The multivariate Cox proportional hazard model was used to compare the contribution of variables including patient's age and sex, tooth type and location, and extraction method to the survival estimates of IR treated teeth. The survival times were determined from the date of the IR to the final recall visit for censored cases in the 'periradicular healing' and 'functional success' subcategories and from the date of the IR to the date of diagnosis for the event cases in the 'functional failure' subcategory. Statistical analyses were performed by using PASW Statistics 18 software (SPSS, Inc., Chicago, IL, USA). The analyses were performed at a significance level of 0.05.

Results

The mean follow-up duration was 25.4 ± 9.3 months. The longest duration of recall was 53 months for teeth demonstrating a periradicular healing; the shortest duration was 7 months for teeth demonstrating functional failure and being ultimately extracted. The overall complete success (periradicular healing) rate was 89.5% and the overall survival rate including complete success and functional success was 95.1%. With respect to the use of orthodontic extrusion, success rate of the IR without

extrusion was 83.2% and that with orthodontic extrusion was 94.4%. The estimated survival time of the IR treated teeth were 4.13 ± 0.05 years (Tables 2 and 3; and Figure 1).

The extraction times of the two extraction techniques were not significantly different (Table 4). Extra-oral time was 11 min 25 sec ± 5 min 32 sec. Two teeth extracted without extrusion were failed during extraction and extracted completely. One was mandibular 1st molar and the other was mandibular 2nd molar. In 5 cases, root tip were fractured during extraction, but it did not hamper the next step because the length of fractured root tips were less than those of root resection. In cases of 24 teeth with long root or with thick cortical bones, extraction was performed with partial osteotomy.

Seven patients complained of occasional mild discomfort, rather than typical pain. Nine teeth had minimal arrested root resorption without clinical symptoms. These teeth could not be classified as a 'Failure' because the patients did not exhibit any other clinical symptoms leading to extraction during recall examinations. Because these 16 teeth apparently survived and recovered their function with normal periodontal tissue healing, except obscure discomfort, they were categorized as a

'functional success' and were included in the 'Survival' group (Tables 2 and 3).

Twelve patients could chew soft food, but they complained of a continuous dull pain and instability of the replanted teeth and 9 of them showed progressive root resorption or deep periodontal pocket. These teeth were classified as a 'functional failure' (Tables 2 and 3). From the teeth extracted without extrusion, nine teeth out of 19 root-resorbed teeth showed clinical symptoms. Among the teeth that were classified as a 'functional failure', one tooth extracted without orthodontic extrusion showed alveolar bone resorption and pathologic mobility. It was extracted eventually at 224 days after IR. However, the remaining 8 of the 9 functionally failed teeth survived, but showed root resorption with clinical symptoms (Table 3). Ten teeth that showed minimally arrested root resorption were included as a 'functional success'. Root resorption was mostly observed within 1 year of the surgery. For the variable of extraction technique, the survival rate of intentionally replanted teeth was 91.2% until 53 months for those extracted without extrusion and 98.1% until 33 months for those extracted with extrusion (Tables 3 and 4; Figure 1).

When the clinical outcomes of the two extraction techniques were compared using the Cox proportional hazard model, the extraction technique was the only variable that affected the survival estimates significantly (Table 5).Therefore, the results of Kaplan-Meire survival estimates were presented between the extraction techniques (Figure 1). The survival estimates of intentionally replanted teeth were not significantly affected by variables such as patient's sex and age, and tooth type and location (Cox proportional hazard model, Table 5). However, the survival estimates of the IR with orthodontic extrusion was significantly higher than that of the IR without extrusion (Cox proportional hazard model, $p = 0.016$, Table 5). The risk ratio of the IR performed with orthodontic extrusion was 0.22 compared to that of IR without extrusion.

Discussion

It is difficult to compare the outcome of this study directly with previous studies, because of variabilities in the follow-up periods, type of teeth, and evaluation criteria. In this study, the overall success rate (periradicular healing) of the IR was 89.5%. However, IR without extrusion and with orthodontic extrusion showed 83.2% and 94.4% of success rates,

respectively. It was comparable to the success rates of the previous studies. They reported an 80-95% of success rates and showed that IR was a highly reliable surgical endodontic treatment (2, 5, 6, 17). The sophisticated IR technique including orthodontic extrusion that was performed before the IR procedures was rarely investigated in previous studies. Even though there was no statistical difference in the extraction time between the two extraction techniques, the extraction technique affected the survival estimates of IR significantly, based on the Cox proportional hazard model ($p < 0.05$, Table 5). Statistically, the other evaluated prognostic factors including patient's age and sex, and tooth type and location did not affected the survival of intentionally replanted teeth.

Mechanical damage during the extraction is considered as a main reason of root resorption. The success of IR depended on a safe tooth extraction without root fracture and the proper management of a sound PDL (1, 2, 5-7). To prevent postoperative root resorption, preserving sound PDL during the procedure was the key factor. Hayashi introduced 'ortho-transplantation' as an alternative approach in autotransplantation of teeth (18). He suggested that performing preoperative orthodontic extrusion could increase PDL volume of donor tooth to prevent external

root resorption after transplantation to the recipient site. In our study, the same concept was adapted to the IR technique to prevent root resorption. Our study showed no root resorption was noted in patients who underwent extraction after orthodontic extrusion (Table 3). This difference may be attributed to increased PDL volume, and as a result, safe extraction (19). The increased mobility after orthodontic extrusion might also make extraction relatively easy in a short time, but there was no statistical difference in the extraction time irrespective of thepreoperative orthodontic extrusion. There were two complete extraction failures without extrusion, in contrast to no extraction failure after orthodontic extrusion. In this study, replanting a tooth after extraction required less than 15 minutes. This time is adequate for optimal PDL healing (16).

When buccal cortical bone was too hard and thick, additional surgical approach was done in 24 teeth to make a space for complete extraction. Osteotomy and autogenous bone grafting are common procedures in periodontal surgery and implant surgery. A few studies have been conducted on this approach to prevent root fracture and protect PDL during IR technique (13, 15, 20). In our clinical study, no extraction failure was recorded and no bone resorption and deep periodontal pocket were

found after IR of those teeth extracted with partial osteotomy. We did not use CBCT before extraction and could not figure out the bucco-lingual divergence of roots. In case of first molar, surgeon must consider the possibility of root divergency and it is recommended to take CBCT before surgery. Extraction with partial osteotomy may be a solution for extraction of multi-rooted molars and further long-term evaluation of stability is needed.

Within 1 year after the surgery, most functionally failed teeth were determined based on clinical symptoms and root resorption (Figure 1). This finding was in agreement with the findings of a previous report (22). One mandibular first molar showed rapidly progressive alveolar bone resorption and was extracted in 7 months after surgery. The reason of this failure was not clear, but it might be attributed to a fixation problem. It looked stable without resin wire splint just after surgery and the patient did not visit the clinic for routine check-ups until failure. Because most cases had sound surrounding alveolar bone, resin wire splinting was not necessary in all cases. However, those cases of the anterior teeth with thin labial cortical bone and the posterior teeth with mobility after repositioning must have been splinted for 10-14 days.

Before choosing a treatment option, it is necessary to compare the success rate of the IR to that of dental implants (10). To investigate the success rate of the IR procedure, clinical signs and symptoms and root resorption were evaluated clinically and radiographically in most studies (2, 11). However, most implant studies have reported only the survival rates as the outcome measure, and have shown 5 year survival rates of 92.2% - 100% for single implant restoration (23, 24). The survival rates reported in implant studies included the functional failure cases, in addition to the success cases reported in the IR studies and the functional success cases defined in this study. Even though the functional failure cases were not included in the survival rate of this study, the overall survival rate of IR including only the periradicular healing and the functional success categories was 95.1%. Based on the survival estimate, IR can be considered as a practical alternative to dental implants.

This study was a retrospective study on the clinical outcomes and the prognostic variables of IR. When root fracture was anticipated from preoperative radiographs, orthodontic extrusion was performed to prevent root fracture, especially in multi-rooted posterior teeth and severely curved anterior teeth. Little has been known about a reliable extraction method and the clinical outcome of the IR technique with respect to the

extraction methods. Considering safe extraction as the most critical procedure in IR, further studies on practical extraction methods and their clinical outcome will be needed. Retrograde filling material used in this study was MTA, the most widely used one for endodontic surgery. But the outcome of this study was comparable to that of an old study using amalgam as the retrograde filling material (2). The investigation about the effect of retrograde filling material on the success of IR will also be needed. In addition, because root resorption on the buccal or lingual side is difficult to locate on a radiograph, future studies on root resorption and ankylosis using adjunctive methods such as a periotest are also needed.

Conclusions

IR for those teeth that endodontically failed and periradicular surgery looked infeasible for was a reliable surgical treatment option with an excellent clinical survival rate (95.1%). According to the results of this study, extraction with preoperative orthodontic extrusion significantly affected the success and survival rates of IR. Preoperative extrusion for 2-3 weeks before extraction might prevent extraction failure and postoperative complications and could be recommended for successful IR.

Acknowledgments

This study was supported by grant no. 11-2011-003 from the Seoul National University Bundang Hospital Research Fund.

References

1. Guy SC, Goerig AC. Intentional replantation: technique and rationale. Quintessence Int 1984;15(6):595-603.

2. Bender IB, Rossman LE. Intentional replantation of endodontically treated teeth. Oral Surg Oral Med Oral Pathol 1993;76(5):623-630.

3. Kratchman S. Intentional replantation. Dent Clin North Am 1997;41(3):603-617.

4. Andreasen JO, Hjorting-Hansen E. Replantation of teeth. I. Radiographic and clinical study of 110 human teeth replanted after accidental loss. Acta Odontol Scand 1966;24(3):263-286.

5. Kingsbury BC, Jr., Wiesenbaugh JM, Jr. Intentional replantation of mandibular premolars and molars. J Am Dent Assoc 1971;83(5):1053-1057.

6. Koenig KH, Nguyen NT, Barkhordar RA. Intentional replantation: a report of 192 cases. Gen Dent 1988;36(4):327-331.

7. Niemczyk SP. Re-inventing intentional replantation: a modification of the technique. Pract Proced Aesthet Dent 2001;13(6):433-439.

8. Wolcott J, Rossman LE. Intentional replantation of endodontically treated teeth: an update. Compend Contin Educ Dent 2003;24(1):68-74.

9. Rouhani A, Javidi B, Habibi M, Jafarzadeh H. Intentional replantation: a procedure as a last resort. J Contemp Dent Pract 2011;12(6):486-492.

10. Iqbal MK, Kim S. A review of factors influencing treatment planning decisions of single-tooth implants versus preserving natural teeth with nonsurgical endodontic therapy. J Endod 2008;34(5):519-529.

11. Hayashi M, Kinomoto Y, Miura M, Sato I, Takeshige F, Ebisu S. Short-term evaluation of intentional replantation of vertically fractured roots

reconstructed with dentin-bonded resin. J Endod 2002;28(2):120-124.
12. Andersson L. Recommendations on prevention in guidelines from the International Association of Dental Traumatology. Dent Traumatol 2012;28(6):497.
13. Kany FM. Single-tooth osteotomy for intention replantation. J Endod 2002;28(5):408-410.
14. Choi YH, Bae JH, Kim YK. Atraumatic safe extraction for intentional replantation. J Korean Dent Assoc 2010;48(7):531-537.
15. Choi YH, Bae JH. Clinical evaluation of a new extraction method for intentional replantation. J Korean Acad Conserv Dent 2011;36(3):211-218.
16. Tsukiboshi M. Autotransplantation of teeth: requirements for predictable success. Dent Traumatol 2002;18(4):157-180.
17. Messkoub M. Intentional replantation: a successful alternative for hopeless teeth. Oral Surg Oral Med Oral Pathol 1991;71(6):743-747.
18. Hayashi H. Ortho-transplantation. Seoul: Narae Publishing, Co.; 2006. p8-15.
19. Han G, Huang S, Von den Hoff JW, Zeng X, Kuijpers-Jagtman AM. Root resorption after orthodontic intrusion and extrusion: an intraindividual study. Angle Orthod 2005;75(6):912-918.
20. Choi YH. Intentional replantation of the maxillary molar via partial osteotomy. Asian J Oral Maxillofac Surg 2011;23:73-76.
21. Trope M. Avulsion of permanent teeth: theory to practice. Dent Traumatol 2011;27(4):281-294.
22. Zuolo ML, Ferreira MO, Gutmann JL. Prognosis in periradicular surgery: a clinical prospective study. Int Endod J 2000;33(2):91-98.
23. Albrektsson T, Zarb G, Worthington P, Eriksson AR. The long-term efficacy of currently used dental implants: a review and proposed criteria

of success. Int J Oral Maxillofac Implants 1986;1(1):11-25.
24. Brocard D, Barthet P, Baysse E, Duffort JF, Eller P, Justumus P, et al. A multicenter report on 1,022 consecutively placed ITI implants: a 7-year longitudinal study. Int J Oral Maxillofac Implants 2000;15(5):691-700.

Tables and Figures

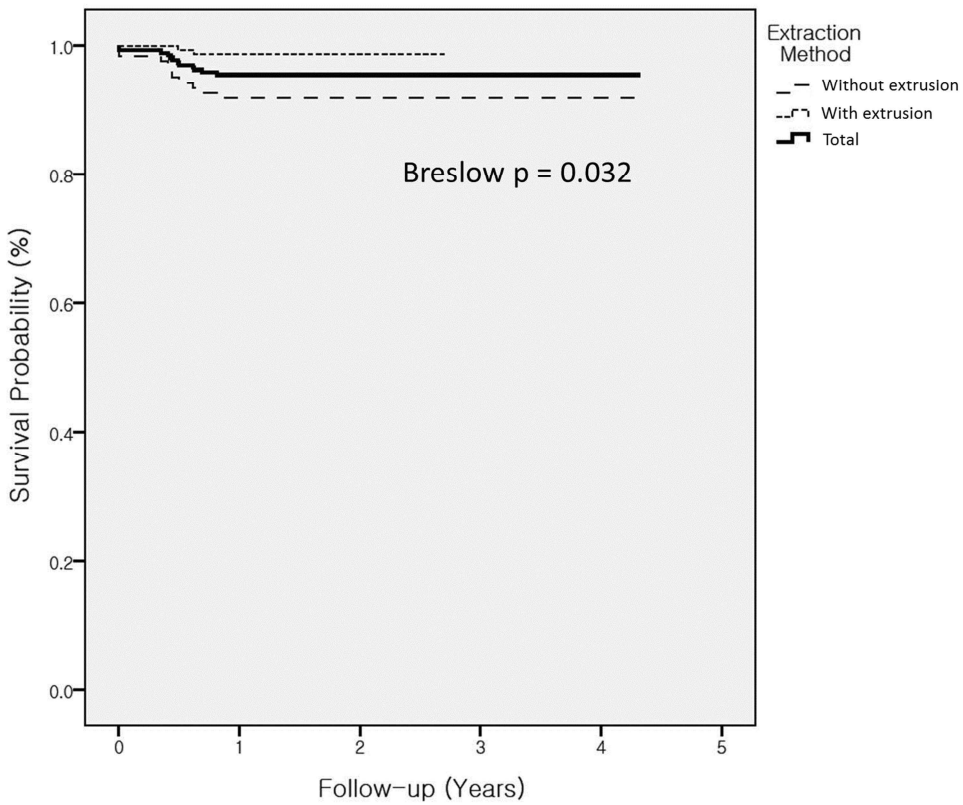

Figure 1. Kaplan-Meier survival estimate curves of intentionally replanted teeth according to the extraction techniques with or without preoperative orthodontic extrusion. The overall survival rate of intentionally replanted teeth was 95.1%. The estimated survival time was 4.13 ± 0.05 years. The survival rates were 91.2% until 53 months for the teeth extracted without extrusion and 98.1% until 33 months for those extracted with preoperative orthodontic extrusion. The difference in the survival estimates between the two extraction techniques with or without extrusion was statistically significant (p = 0.016).

Table 1. Criteria for deciding 'Survival' and 'Failure' as determined clinically or radiographically

	Subdivision	Description
Survival	Periradicular healing (Complete Success)	Absence of clinical symptoms Absence of a periradicular lesion Normal pocket depth (< 5mm) Regeneration of periodontal tissue Normal Physiologic mobility
	Functional Success	Normal pocket depth (<5mm) Normal Physiologic mobility Occasional minimal discomfort Minimal and arrested root resorption
Failure	Functional Failure	Periodontal pocket > 5 mm Pathologic tooth mobility Presence of clinical symptoms Persistent periradicular lesion or sinus tract Progressive root resorption
	Extraction Failure	Crown or root fracture during extraction

* For example, despite absence of any clinical symptom, the teeth demonstrating inflammatory resorption were classified as 'Functional Failure'.

Table 2. Clinical outcome of intentional replantation

	Survival		Failure	
	Periradicular healing (Complete Success, %)	Functional Success (%)	Functional Failure (%)	Extraction Failure (%)
Without Extrusion†	104 (83.2)	10 (8.0)	9 (7.2)	2 (1.6)
With Extrusion	153 (94.4)	6 (3.7)	3 (1.9)	0 (0.0)
Total	257 (89.5)	16 (5.6)	12 (4.2)	2 (0.7)

* Overall survival rate (Clinical success) was 95.1%. However, in case of the extraction without preoperative orthodontic extrusion, two teeth failed due to extraction failures and 1 tooth classified as functional failure was also extracted due to pain.

† With or without extrusion means extraction with or without preoperative orthodontic extrusion.

Table 3. Distribution of cases in 'Functional Success' and 'Functional Failure' according to the clinical symptoms and radiographic root resorption

	Without Extrusion†		With Extrusion	
	Functional Success	Functional Failure	Functional Success	Functional Failure
Root resorption	9	1		
Clinical symptoms			6	3
Both root resorption and clinical symptoms	1	8 (1 extracted)		
Total	10	9	6	3

* Minimal and arrested root resorption was categorized as 'Functional Success', and the sequelae were more frequent in the teeth extracted without extrusion (n = 10). No root resorption was observed in the teeth extracted with preoperative orthodontic extrusion.

† With or without extrusion means extraction with or without preoperative orthodontic extrusion.

Table 4. Average extraction time and number of teeth demonstrating extraction failure

	Extraction Time	Extraction Failure	n
Without extrusion†	3 min 22 sec ± 3 min 44 sec	2	125
With extrusion	4 min 40 sec ± 5 min 19 sec	0	162

* Extraction time was not significantly different between the two extraction techniques with or without extrusion (Student's *t*-test).

† With or without extrusion means extraction with or without preoperative orthodontic extrusion.

Table 5. Prognostic variables affecting the survival estimates of intentional replantation and their contribution according to the Cox proportional hazards model

	N	Survival rates		
		Wald	Odds ratio	*p*-value
Extraction tech		5.851		0.016*
Without extrusion†	125		4.483	
With extrusion	162		1.000	
Age (yrs)		2.208		0.900
10	17		1.441	0.998
20	43		3228.8	0.938
30	85		11724.5	0.928
40	59		7234.6	0.932
50	49		8561.5	0.931
60	27		3864.6	0.937
70	7		1.000	
Arch location		0.777		0.378
Maxilla	129		1.641	
Mandible	158		1.000	
Tooth group		0.605		0.437
Anterior	20		0.428	
Posterior	267		1.000	
Sex		0.025		0.874
Male	121		1.092	
Female	166		1.000	

* The risk ratio was statistically significant ($p < 0.05$).

† With or without extrusion means extraction with or without preoperative orthodontic extrusion.

Abbreviations: Extraction tech, Extraction techniques.

국문초록

의도적 재식술의 임상 결과에 대한 후향적 연구

최 용 훈

서울대학교 대학원 치의학과 치과보존학 전공

(지도교수 조 병 훈)

1. 목적

이 연구의 목적은 의도적 재식술로 치료한 치아의 임상적 성공률과 생존률을 후향적으로 연구하여 임상적 치료 결과에 미치는 요소들에 대해 평가하는 것이다.

2. 재료 및 방법

287 증례에 대해 후향적으로 연구하였으며, 술전 교정적 정출술을시행한 군과 시행하지 않은 군을 비교하였다. 또한 환자의 나이 및 성별, 치아 위치, 발치 소요 시간, 및 구강 외 시간의 영향에 대해서도 연구하였다. 생존에 대한

평가는 Kaplan-Meier 분석을 사용하였다. 환자의 나이, 성별, 치아의 위치, 발치 시간 및 방법 등 생존에 미치는 요인들은 Cox proportional hazard model 로 분석하였다.

3. 결과

의도적으로 재식한 치아의 성공률은 89.5% 였고, 생존율은 95.1% 였다. 평균 관찰 기간은 25.4 ± 9.3 개월이었다. 여러 요소들 중 발치전 교정적 정출술은 유의하게 생존률에 영향을 미쳤고 ($p < 0.05$), 다른 요소들은 유의한 영향을 미치지 않았다.

4. 결론

의도적 재식술은 통상적인 치료가 실패한 경우 자연치아를 살릴 수 있는 유용한 방법이다. 술전 2-3주간의 교정은 치근 흡수를 방지하며, 발치를 용이하게 하므로 성공적인 의도적 재식술을 위해 추천된다.

주요어 : 의도적 재식술, 교정적 정출, 발치 방법, 성공률, 생존률
학 번 : 2010-30643

감사의 글

먼저 본 논문을 작성하기까지 도움을 주신 모든 분께 감사의 마음을 전합니다.

아무것도 모르던 본과 4학년 시절 보존학의 길로 이끌어 주시고 또 어려운 환경 속에서 더 큰 곳에서 공부할 수 있도록 인도해 주신 김성교 교수님께 진심으로 감사 드립니다.

석사 과정부터 먼 거리에서의 통학으로 인하여 지도학생으로서 연구와 교육에 많이 부족하였으나 박사과정까지 잘 지도해주신 조병훈 교수님께 진심으로 감사 드립니다. 이번 박사 학위 논문을 위해 긴 시간 동안 세심하게 지도해 주셔서 지난 5년간의 임상 결과를 잘 정리할 수 있었습니다.

군을 제대하고 진로 문제로 곤란을 겪고 있을 때 흔쾌히 저를 받아들여 주신 분당서울대학교 병원 김영균, 배지현 교수님께 감사의 말씀을 전합니다. 특히 본 연구를 마음껏 할 수 있도록 진료 환경을 배려해 주시고 나아가 특허 출원 및 저서 집필 등 제가 감히 상상하지 못했던 세계로 인도해 주신 점 깊이 감사 드립니다. 학업과 진료를 병행하게 배려해 주신 윤필영 교수님께도 감사 드립니다.

논문 심사 과정에서 완성도를 높이기 위해 많은 시간을 할애하여 심사해 주시고 또 앞으로의 연구 방향까지 조언해 주신 백승호, 진보형 교수님, 조용히 격려해 주시고 응원해 주셨던 손호현 교수님께 감사 드립니다. 대학원 과정을 하는 동안 많은 이해와 배려로 도움을 주신 금기연 교수님 이하 보존과 교수님들과 의국원 여러분께도 진심으로 감사 드립니다.

박사 과정을 마치기 까지 여러 번 고비 때마다 격려와 지지를 통해 힘을 주신 사랑하는 부모님께 감사 드리고 어려운 여건 속에서도 묵묵히 지원해준 아내 강수진과 사랑하는 딸 민정이에게 고맙다는 말을 전합니다.

2014.2

저자 최용훈 씀