Abstract

Molar-incisor hypomineralization (MIH) is a term which describes the clinical feature of one to all the first permanent molars in hypomineralized state. On the other hand, Molar-incisor malformation (MIM) is a recently reported, novel dental phenotype, which is characterized by root malformation of the first permanent molars. This also may appear on the second deciduous molars as well as the maxillary permanent central incisors. The purpose of the present study was to investigate the clinical and radiological features of MIM. We retrospectively reviewed the radiographic data and medical history of 17 MIM patients who visited Seoul National University Dental Hospital from January 2001 to March 2015. The affected permanent first molars and deciduous molars showed short, slender underdeveloped roots and constricted pulp chamber. However, any abnormality in shape or color on the crown portion of the affected molars had not been recorded on dental chart. All the affected permanent incisors and canines exhibited dilacerated short roots. In some cases of incisors and canines, wedge-shaped defect on the cervical part of the crown was noted. Regarding the medical history of the patients, all the patients had been hospitalized because of several problems during neonatal period.

Due to the limitation of anatomical disability, MIM may cause early loss of the affected permanent teeth. Therefore, the early diagnosis on radiographs with appropriate treatment will lead to favorable prognosis for patients, especially on youth and adolescence.

.....

keywords : Molar-incisor malformation, MIM, Molar-incisor hypomineralization , MIH

Student Number : 2012-22221

Introduction

Molar-incisor hypomineralization (MIH) is a term which describes the clinical feature of one to all permanent first molars in hypomineralized state.[1-4] This hypomineralized condition is frequently associated with incisors as well. Affected teeth are fragile and susceptible to dental caries. Systemic complication or environmental factors affected during delivery or immediately after birth are presumed to be a cause of MIH. Many researches have been conducted on MIH and the prevalence is varied between 3.6-25%..[4]

Recently, Witt et al. defined a certain form of malformed root associated with an abnormally mineralized diaphragm on cervical portion of the tooth[5]. Lee et al. named this condition as molar-incisor malformation (MIM)[6]. MIM typically shows a short, narrow and sharp shape of underdeveloped root which mostly appears on permanent first molars. This also may appear on deciduous second molars as well as permanent maxillary central incisors.

MIM is similar to MIH in several aspects. Administration of various medications, congenital health problems, feeding difficulties, and neonatal infections were suggested as the cause of both types of anomalies. Also, both of them commonly occur on permanent central incisors and first molars. However, MIH manifests only on coronal portion of teeth and there has been no report on root involvement yet. Therefore, after tooth eruption, dentists can diagnose it with visual inspection. On the other hand, MIM can be diagnosed before eruption through radiographic examination since it manifests as malformation of root and pulp chamber. There have been only a few reports on MIM, until recently. The purpose of this study is to present the clinical and radiological features of MIM.

Materials and Methods

This retrospective study was approved by our institutional review board. We retrospectively reviewed the radiographic data and medical history of MIM patients who visited the Seoul National University Dental Hospital (SNUDH) from January 2001 to March 2015. We searched on Picture Archiving and Communications System (INFINITT PACS, INFINITT healthcare, Seoul, South Korea) with the following keywords of malformed, malformation, dysplastic, dysplasia, hypoplastic, or hypoplasia, combined with either tooth or root. All images had been interpreted by oral and maxillofacial radiologists. Among all the searched patients, we selectively included the patients with permanent or deciduous molars and/or incisors affected in all four quadrants of the jaw. The patients with dentin dysplasia, amelogenesis imperfecta, dentinogenesis imperfecta and regional odontodysplasia, which are generalized or segmental tooth malformation different from MIM, were excluded. The patients with a history of chemotherapy or radiation therapy were also excluded. Totally, 17 patients were identified as MIM. The radiological features were documented by a consensus of two experienced oral and maxillofacial radiologists. Both medical and dental chart review on those patients were performed and the clinical features were analyzed.

Result

Basically, all the 17 patients had MIM on the permanent first molars. The permanent upper central incisors were affected additionally on 5 patients and the permanent upper canines on 2 patients. Eight patients exhibited MIM on the deciduous molars. The affected permanent first molars and deciduous molars showed short, slender underdeveloped or undeveloped roots and constricted pulp chamber (Figure 1 to 5). However, any abnormality in shape or color on the crown portion of the affected molars was not recorded for intraoral examination on dental chart. All the affected permanent incisors and canines exhibited dilacerated short roots. In some cases of incisors and canines, wedge-shaped defect on the cervical part of the crown was noted (Figure 1A and 1B).

Regarding the medical history of the patients, all the patients had been hospitalized because of several problems during neonatal period (Table 1). Seven patients had a history of infection on the central nerve system, which were mostly meningitis. Four patients had undertaken a surgery due to cardiac or cerebral problems. One patient had had kidney transplantation and 5 patients had been cared in incubator due to premature birth with low body weight or dystocia.

For complication of the affected teeth, 8 patients showed periapical lesions of the affected teeth without any cause of infection, such as dental caries or crown fracture (Figure 3 and 5). Three out of the 8 patients only had periapical lesions, and the rest of them showed severe alveolar bone loss along with periapical lesions, forming endo-perio lesions (Figure 3A). A periapical cyst developed from an affected molar at 4 years of follow-up in one patient (Figure 3B). Furthermore, cellulitis of the left buccal cheek was caused by a periapical lesion of the affected permanent first molar in another patient (Figure 5).

The age of the patients at the time of their first visit to SNUDH was 3 to 14 years old with an average of 7.8 years. There were 10 male and 7 female patients. Twelve patients were referred from a local dental clinic

due to the malformation of the affected roots. Of the 12 patients referred, 6 patients presented without any symptoms while 6 patients showed pain and mobility on the affected molars. Especially, 1 patient showed a cellulitis of the left face caused by the spread of infection from the affected molar. The remaining 5 patients visited our hospital for other reasons, such as orthodontic treatment or extraction of mesiodens. The follow-up period of those patients were from 1 to 16 years with an average of 5 years.

Concerning the prognosis of the affected teeth, MIM affected molars in 8 patients were determined to be used carefully and followed-up under periodic recall check. Of the 8 patients, one patient has preserved the affected molars after successful endodontic treatment, while 7 patients had their molars extracted due to severe mobility and poor prognosis. After extraction, 6 patients underwent orthodontic treatment to replace the missing first molars with the permanent second molars, and one patient had a dental implant surgery. For those 6 patients with affected permanent incisors, three lost their incisors and the other three preserved the incisors after caries treatment. For those with incisors extracted, space maintainer was applied with a plan of dental implant surgery after the completion of alveolar bone growth.

Discussion

There are clinical criteria for diagnosing MIH. According to the current criteria of European Academy of Pediatric Dentistry (EAPD), the examination for MIH in epidemiological studies includes all permanent first molars and incisors.[9] However there are no consensus diagnostic criteria has been suggested for its radiologic feature. This is probably because it shows only slight defect on enamel which is not significantly detected on radiography. In contrast, MIM patients we found showed significant radiographic feature.

All 17 patients showed characteristic tooth appearance. Incisors and canines had dilacerated root and wedge-shaped defect on the cervical portion of the crown. Permanent and deciduous molars showed constricted pulp chamber without apparent malformation on the crown portion. Affected roots were short, slender, and narrow.

All the patients had a medical history of hospitalization during neonatal period because of infection on the central nervous system, surgery, premature birth, or dystocia. All of them, in common, had a medical history of intensive exposure to antibiotics. Alaluusua S. suggested that the use of antibiotics within 6-year after birth as a cause of MIH[10]. We think that intensive administration of antibiotics at critical period in tooth development may be the major cause of MIM.

The development of the second deciduous molars starts at around the same time as the permanent first molars and permanent incisors. If a risk factor occurs during overlapping period, root malformation could occur in both primary and permanent dentition. Because of the sequential development of the second deciduous molar and the first permanent molar, hypomineralization of deciduous molar can be used as a predictor for MIH.[11] Some MIH patients showed hypomineralized defects on the second deciduous molars as well as permanent canines, which was similar to our finding in MIM.[12]In the present study, seven patients showed MIM not only on the first permanent molars, but also on the

second deciduous molars. Therefore, root malformation of deciduous molars can be a predictor for MIM in young patients. Some patients in the present study only had radiographic records after their deciduous molars were fallen out. For those cases, we could not figure out if their deciduous molars had been affected by MIM.

Patient 7, 12, 16, 17 had been born in prematured state. Of them, patient 12, 16, 17 showed deciduous molars affected while patient 7 showed MIM only on the permanent molars. Patient 7 had prematurely been delivered at 32 week while patient 16, 12, 17 delivered at 27, 28, 29 weeks, respectively. This indicates that there might be a correlation between the timing of medication and MIM affected teeth. Harris el al. reported that the low birth-weight can have adverse effects on child' s tooth development including enamel defects and delayed eruption. However tooth malformation showed no significant correlation with low birth-weight.[13] In our country of South Korea, antibiotic medication is redundantly used for prematurely delivered baby, thus, antibiotic administration under incubator condition immediately after birth is suspected to be a strong causative factor for MIM.

MIM shows similar characteristics to those of MIH. Intensive usage of antibiotics in infancy may cause MIM while antibiotics are one of suspected etiologic factors for MIH as well. However, for both diseases, the exact critical period and the threshold level of irritant are not clearly defined. The effective level of irritant on the tooth forming cells, such as ameloblasts, odontoblasts and cementoblasts, is also unknown. MIM appears on molars and incisors, as it does in MIH. MIM and MIH may be a spectrum of a same disease. If a causative factor influences ameloblasts, odontoblasts and cementoblasts in different developmental stages with various intensities, the affected teeth can show diverse appearances from slight hypomineralization of the crown to severe root malformation.

. The different phenotypic appearance might be due to the difference in timing of the impact on tooth development and its intensity. Therefore, we suggest that the designation of ' medication related tooth

malformation’ should be considered for MIM and MIH altogether.

Dentists can simply diagnose MIH clinically, and there is no radiographic study on MIH. Thus, the possibility of MIH accompanied by MIM may exist. In contrast, MIM can only be diagnosed by radiographic examination since the affected teeth usually show a normal shape and color of the crown in visual inspection. Although the present study did not include visual inspection of the teeth affected by MIM, there was no record of abnormality of the crown indicating MIH in chart review. Futhermore, there might be a possibility of combined presentation of MIM and MIH, but it has not been reported in the previous literatures. Thus, we also need to consider MIM and MIH as a distinctive disease. Further studies are needed to elucidate the relationship between MIM and MIH.

MIH affected teeth are sensitive to dental caries. There have been many previous researches on the correlation between MIH and dental caries. Likewise, the teeth affected by MIM are frequently complicated with a periapical lesion even under a caries-free state of the tooth. Besides, as a result of underdevelopment of the roots and surrounding periodontal bone loss, the teeth affected by MIM may be lost early. After the full eruption of affected tooth, clinician should evaluate the state of tooth and predict the prognosis. Periodic follow-up check with radiographic examination are needed. Endodontic treatment can be performed for the teeth with questionable prognosis. Clinicians may extract the affected teeth when their mobility is severe because of the periodontal and periapical bone loss. Orthodontic treatment can be performed to close the empty space, from the early loss of the first permanent molars, using the second permanent molars. Dental implant prosthesis is another option for the early loss of the affected teeth. Because of periapical infection or structural deficiency itself, the MIM teeth are exposed to the possibility of early loss. Permanent canines and first permanent molars are important in masticatory movement. Permanent incisors are essential in esthetics. Losing those teeth in early childhood might influence both physical condition related to malnutrition and psychological development due to low self-confidence.

In conclusion, MIM may cause early loss of the affected permanent teeth, therefore early diagnosis with appropriate treatment will lead to favorable prognosis for patients, especially on youth and adolescence.

References

1) Weerheijm KL. Molar incisor hypomineralisation (MIH). Eur J Paediatr Dent. 2003 Sep;4(3):114-20.

2) Nishita Garg, Abhay Kumar Jain, SonaliSaha, Jaspal Singh. Essentiality of Early Diagnosis of Molar Incisor Hypomineralization in Children and Review of its Clinical Presentation, Etiology and Management. Int J ClinPediatr Dent. 2012 Sep-Dec; 5(3): 190-196.

3) Gotler M, Ratson T. [Molar incisor hypomineralization (MIH)--a literature review]. Refuat Hapeh Vehashinayim. 2010 Apr;27(2):10-8, 60.

4) Weerheijm KL. Molar incisor hypomineralization (MIH): clinical presentation, aetiology and management.Dent Update. 2004 Jan-Feb;31(1):9-12.

5) Witt CV, Hirt T, Rutz G, LuderHU.Root malformation associated with a cervical mineralized diaphragm--a distinct form of tooth abnormality? OralSurg Oral Med Oral Pathol Oral Radiol. 2014 Apr;117(4):e311-9. doi: 10.1016

6) Lee HS, Kim SH, Kim SO, Lee JH, Choi HJ, Jung HS, Song JS.A new type of dental anomaly: molar-incisor malformation (MIM).Oral Surg Oral Med Oral Pathol Oral Radiol. 2014 Jul;118(1):101-109.e3. doi: 10.1016

7) Jälevik B, Norén JG, Klingberg G, Barregård L. Etiologic factors influencing the prevalence of demarcated opacities in permanent first molars in a group of Swedish children. Eur J Oral Sci. 2001 Aug;109(4):230-4.

8) Seow WK. Clinical diagnosis of enamel defects: pitfalls and practical guidelines. Int Dent J. 1997 Jun;47(3):173-82.

9) Jälevik B. Prevalence and Diagnosis of Molar-Incisor-Hypomineralisation (MIH): A systematic review. Eur Arch Paediatr Dent. 2010 Apr;11(2):59-64.

10) Alaluusua S. Aetiology of Molar-Incisor Hypomineralisation: A systematic review. EurArch Paediatr Dent. 2010 Apr;11(2):53-8.

11) Elfrink ME, ten Cate JM, Jaddoe VW, Hofman A, Moll HA, Veerkamp JS. Deciduous molar hypomineralization and molar incisor hypomineralization. J Dent Res. 2012 Jun;91(6):551-5.

12) Weerheijm KL, Duggal M, Mejàre I, Papagiannoulis L, Koch G, Martens LC, Hallonsten AL. Judgement criteria for molar incisor hypomineralisation (MIH) in epidemiologic studies: a summary of the European meeting on MIH held in Athens, 2003. Eur J Paediatr Dent. 2003 Sep;4(3):110-3.

13) Harris EF, Barcroft BD, Haydar S, Haydar B. Delayed tooth formation in low birthweight African-American children. Pediatr Dent. 1993 Jan-Feb;15(1):30-5.

Table 1. Patients information

Patient No.	Age(y)/Sex	Affected tooth	Medical history	Radiographic features	Chief complaint	Clinical complication	Treatment and prognosis (period of follow up from the first visit to SNUDH)
1	7/M	6 1 | 1 6 6 | 6	Bacterial meningitis after birth	Upper central incisors: thin delacerated root, malformed crown Upper and lower bilateral permanent first molars: single short, narrow root formation, constriction of pulp chamber	Referred from local dentist for root malformation	Periapical lesion Early loss	Permanent central upper incisors, lower first molars: periodic recall check (4Y5M) Upper bilateral permanent first molars: extraction
2	7/M	6 1 | 1 6 6 | 6	Hospitalized due to Cerebral hemorrhage after birth	Upper central incisors: malformed crown Upper and lower bilateral permanent first molars: short, thin and narrow roots	Referred from local dentist for mesiodens		Periodic recall check (3Y2M)
3	8/M	6 1 | 1 6 6 | 6	Non-bacterial meningitis after birth, hospitalized due to bacterial meningitis 15 days after birth	Upper central incisors: thin delacerated root, malformed crown Upper and lower bilateral permanent first molars: undeveloped short root , constriction of pulp chamber	Orthodontic treatment	Early loss	Upper bilateral permanent first molars: extraction and space closure Lower bilateral permanent first molars: periodic recall check (5Y1M)
4	8/M	6 3 | 3 6 6 3 | 3 6	Viral encephalitis, asthma, osteogenesis imperfecta, mental retardation	Upper and lower bilateral canines: delacerated root Upper and lower bilateral permanent first molars: slightly affacted roots	Referred from local dentist for caries treatment		Periodic recall check (16Y8M)
5	12/M	6 | 6 6 | 6	Cranial surgery due to craniosynostosis 2 years after birth, proteinuria	Upper and lower bilateral permanent first molars: delacerated thin, short roots with periapical lesion, constriction of pulp chamber	Orthodontic treatment	Endo-perio lesion	Upper and lower bilateral permanent first molars: extraction and space closure (3Y2M)

6	7/F	6 / 6	6 / 6	Lipomeningomyelocele surgery after birth	Upper bilateral permanent first molars: slender roots, constriction of pulp chamber Lower bilateral permanent first molars: thin roots, mesial root dysplasia, constriction of pulp chamber	Orthodontic treatment	Early loss	Upper bilateral permanent first molars: periodic recall check (4Y1M) Lower bilateral permanent first molars: extraction
7	7/M	6 / 6	6 / 6	Early birth (32 weeks), encephalopathy, cerebral hemorrhage	Upper and lower bilateral permanent first molars: short, thin and narrow roots Periapical lesion under upper left permanent first molar	Referred from hospital for periapical abscess	Periapical lesion Cellulitis Early loss	Upper left permanent first molar: extraction The rest of permanent first molars: periodic recall check (9M)
8	7/F	6 / 6	6 / 6	Convulsion, brain capillary blockage after birth	Lower left permanent first molar: thin, delacerated distal root, constriction of pulp chamber Lower right permanent first molar: short, external resorpted distal root, constriction of pulp chamber Upper bilateral permanent first molar: root malformation	Tooth mobility and pain	Endo-perio lesion	Lower bilateral permanent first molars: root canal treatment (3Y2M)
9	9/M	6 / 6	6 / 6	kept in incubator due to distocia	All permanent first molars: short, thin underdeveloped roots Periapical lesion under both lower permanent first molar	Tooth pain on mastication	Endo-perio lesion Early loss	Upper right and both lower permanent first molars: implant prosthesis after extraction Upper left permanent first molars: periodic recall check (6Y11M)
10	14/F	6E / 6E	E6 / E6	Cardiac surgery 1week after birth due to total anomalous pulmonary venous	Upper bilateral permanent first molars: underdevelopment of roots Lower bilateral permanent first molars: slightly thin roots	Referred from hospital for periapical cyst	Periapical cyst	Bone graft after excision of periapical cyst under lower right premolar area (9Y4M)

				connection				
11	9/F	6E3 | 13E6 6E3 | 3E6		Meningitis after birth, epilepsy medication	Upper central incisors: thin root, twisted crown Upper and lower bilateral canines: lumpy, twisted crown Upper and lower bilateral permanent first molars: one or two short, narrow roots, diminished crown size	Referred from local dentist for tooth malformation	Endo-perio lesion Early loss	Upper central incisors: extraction, using of space maintainer Upper and lower bilateral permanent first molars: periodic recall check (3Y1M)
12	9/M	6E 1 | 1 E6 6E | E6		Early birth (28 weeks), genital operation after birth	Upper right central incisor: thin and delacerated root, twisted crown Upper and lower bilateral permanent first molars: one or two short, narrow roots, diminished crown size	Referred from local dentist for root malformation	Endo-perio lesion Early loss	Upper right central incisor, permanent first molars: extraction (3Y5M)
13	5/F	6ED | DE6 6ED | DE6		Bacterial meningitis after birth	Upper bilateral permanent first molars: undevelopment of root Lower bialteral permanent first molars: slight, narrow roots	Referred from local dentist for tooth malformation	Early loss of deciduous teeth	Periodic recall check (2Y11M)
14	7/M	6E | E6 6E | E6		Spinal meningitis after birth	Upper bilateral permanent first molars: slight dysplastic change of roots Lower bilateral permanent first molars: undevelopment of root	Referred from local dentist for root malformation		Periodic recall check (3Y)
15	5/M	6E | E6 6E | E6		Kidney transplantation due to chronic renal failure, Immunosuppressive drug Therapy	Upper and lower bilateral permanent first molars: thin, narrow, short roots	Tooth mobility		Periodic recall check (10Y)

16	8/F	6ED	DE6	Early birth (27 weeks)	Upper and lower bilateral primary first and second molars: underdevelopment of roots Upper and lower bilateral primary first molars: delacerated narrow roots	Referred from local dentist for root malformation		Periodic recall check (7M)
		6ED	DE6					
17	3/F	ED	DE	Early birth (29 weeks), chronic pulmonary disease, metaboilc syndrome about obesity	Upper and lower bilateral primary second molars, Lower bilateral primary first molars: underdevelopment of roots	Tooth pain	Periapical lesion	Periodic recall check (4Y)
		6ED	DE6					

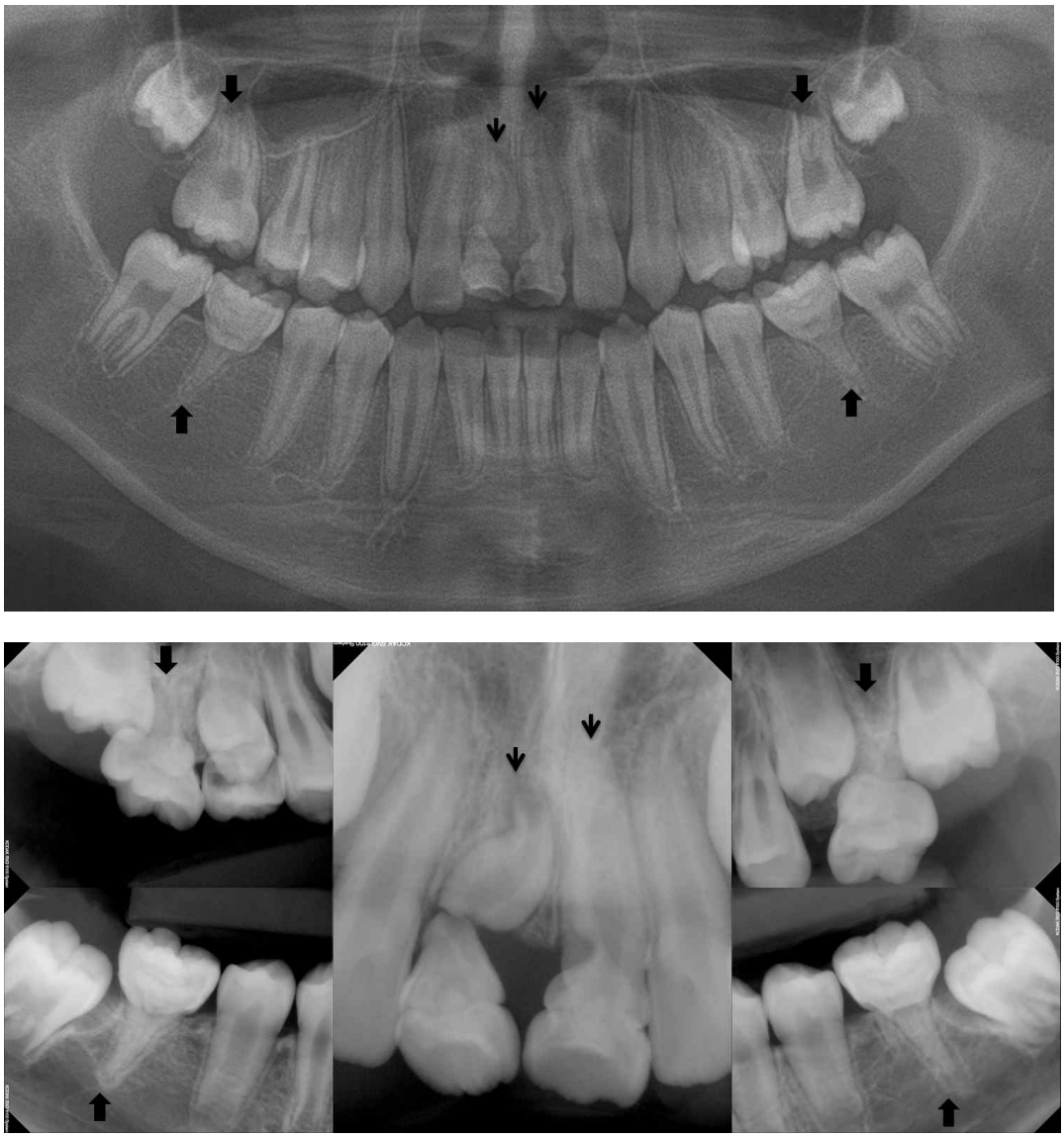

Figure 1.

Panoramic radiograph (A) of a 9-year-old boy and periapical radiographs (B-F) taken 2 years ago. A, Upper central incisors has a wedge-shaped defect on crown, and a severe defect on short, dilacerated root. Both lower first permanent molars show a normal crown contour, but only have a single short and slender root. Note the left first permanent molar showed another very small root. The pulp chambers of the lower first permanent molars seem to be constricted.

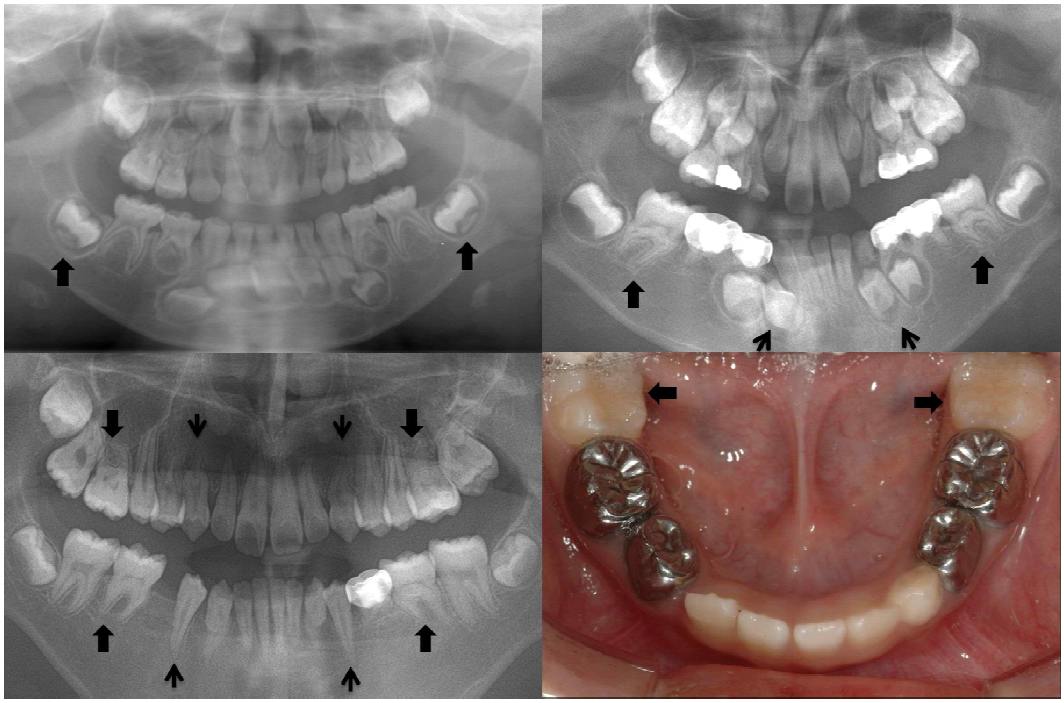

Figure 2.

Serial panoramic radiographs and clinical photograph of patient 4. A. Panoramic radiograph at 3-year-old.. The developing tooth germs of the lower permanent first molars show abnormal flat pulp chamber. There is no apparent pathologic change on the crown portion of the developing upper permanent first molars. B. Panoramic radiography obtained at 8 years old. Fully erupted lower permanent first molars exhibit constricted pulp chamber and short, slender roots. Note the root malformation of the lower permanent canines in developing state. C. Panoramic radiograph obtained at his age of 16 year-old. All four permanent canines show normal crown appearance with dilacerated, short roots. Note the short, slender roots and constricted pulp chamber of the upper permanent first molars, which were not revealed during their eruption stage on the previous radiographs. D. Clinical intraoral photograph of a lower dental arch taken at 8 years old showing normal crown form and alignment.

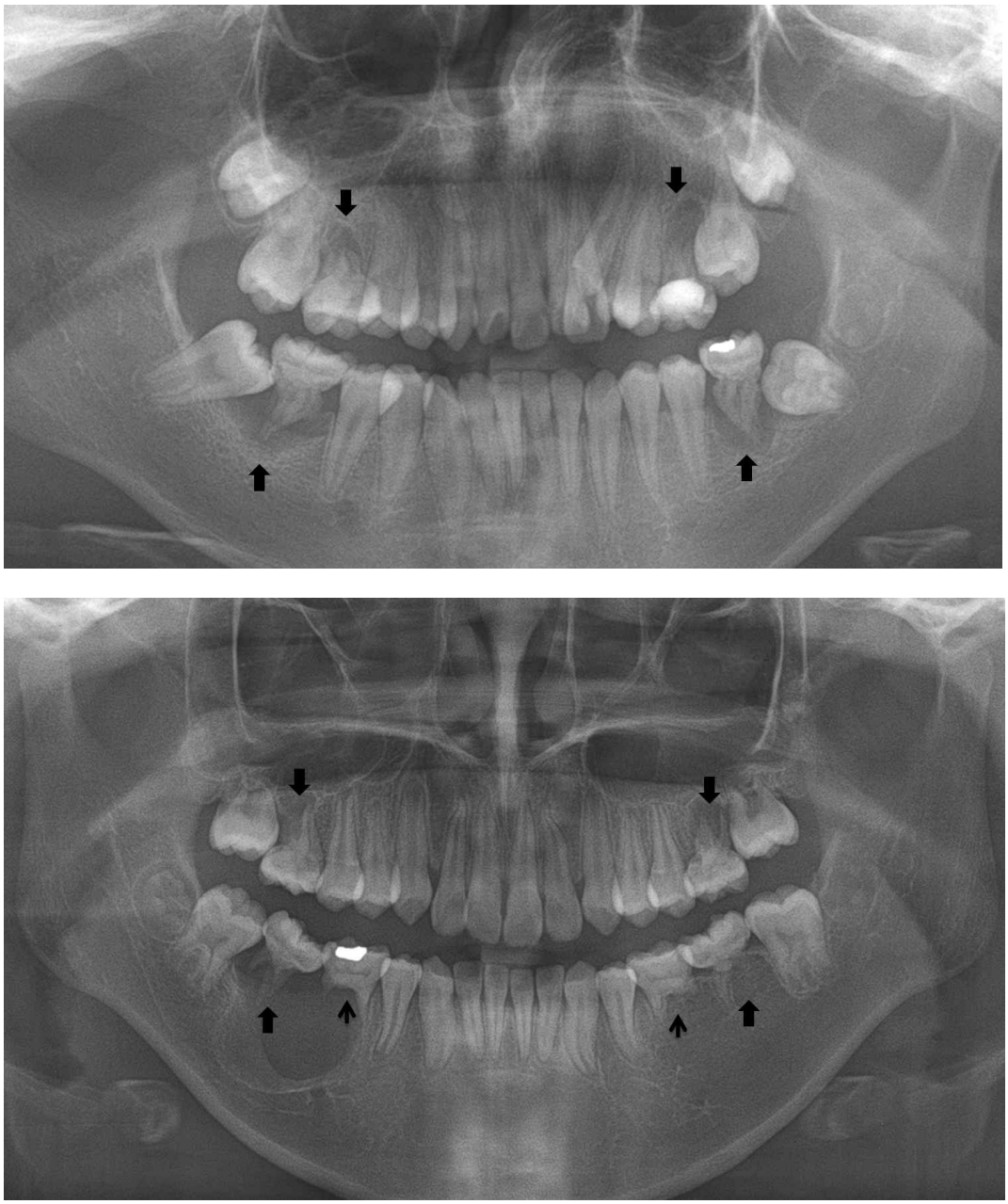

Figure 3.

A. Panoramic radiograph of a patient 5 at his age of 12-year-old. All permanent first molars exhibit converging, short, and slender roots. They have small crown and constricted pulp chamber as well. Note the periapical rarefaction around the root apices of all of them. B. Panoramic radiograph of a patient 10 at her age of 11-year-old. Note the periapical cyst of the right first permanent molar

involving the deciduous second molar as well. This periapical cyst was revealed on panoramic radiograph taken at 4 years of follow-up.

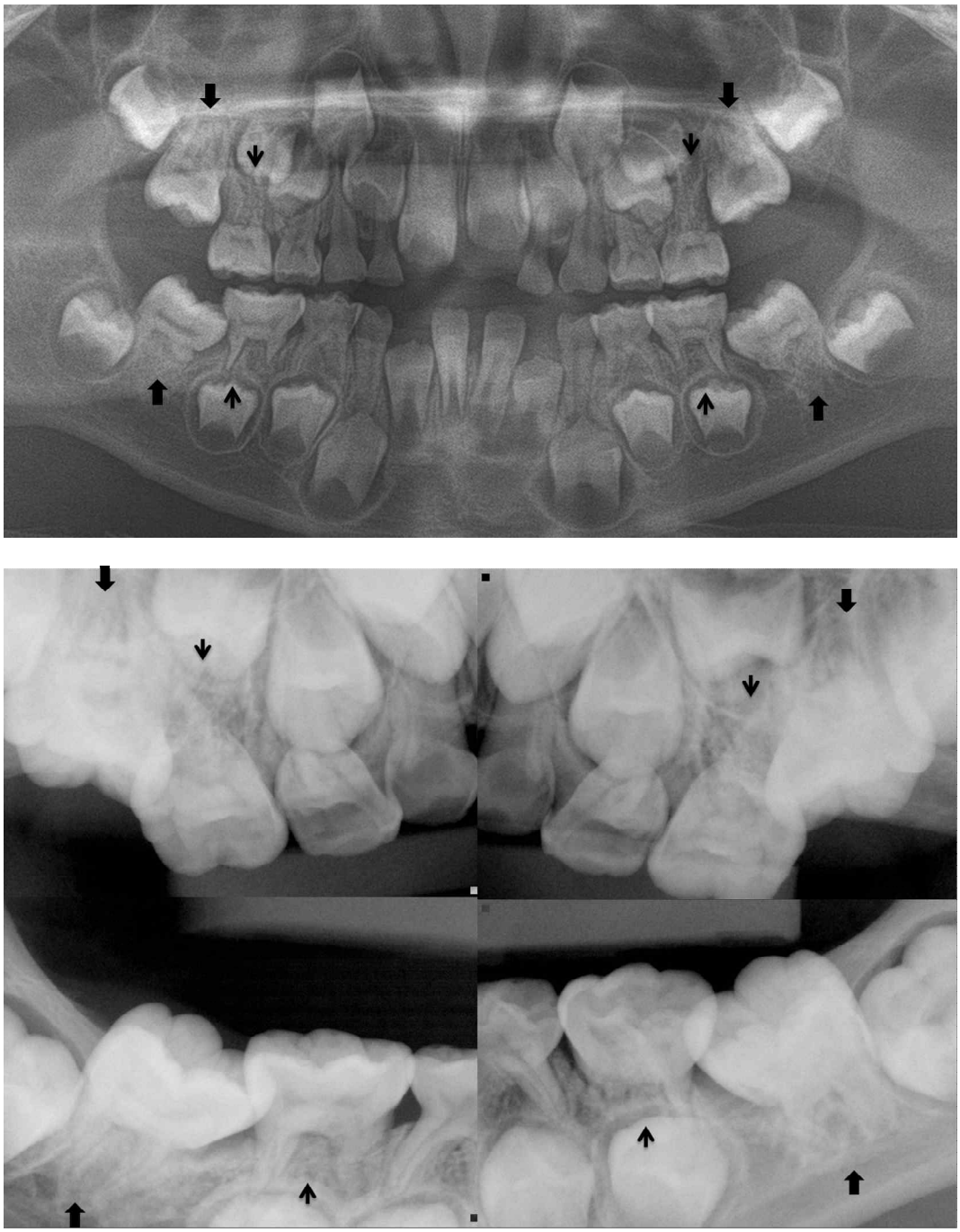

Figure 4.

Panoramic radiograph and intraoral periapical radiographs of a 7-year-old of patient 14. All permanent first molars exhibit normal crown contour yet

constricted pulp chamber and indistinct, underdeveloped roots. In addition, all deciduous second molars show short, slender, and underdeveloped roots.

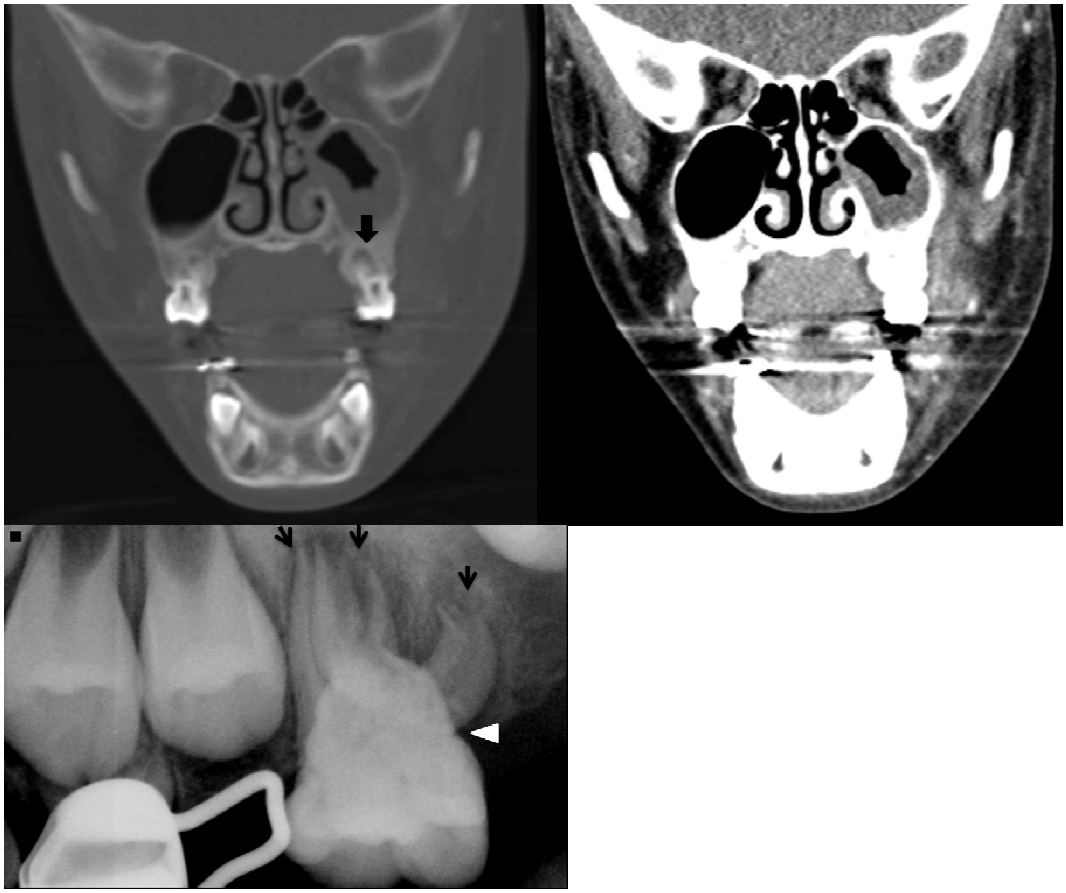

Figure 5.

Computed tomography image of a 7-year-old patient 7 in coronal view. Window width and level set for bone density (A) and set for soft tissue density (B). A, Periapical lesion is involving the palatal root of the upper left permanent first molar(arrow). The floor of the left maxillary sinus is affected and exhibiting mucosal thickening. B, Soft tissue adjacent to the tooth is found to be infected and diagnosed as cellulitis.

요약(국문초록)

17명의 환자정보를 통한 구치-절치 이형성증의 임상-방사선학적 특성

서울대학교 치의학대학원 치의학과

홍준기

구치-절치 저광화증은 1개 혹은 그 이상의 제1영구대구치의 저광화된 치관을 특징으로 가진다. 한편, 최근에 보고된 구치-절치 이형성증은 방사선사진 상에서 특징적으로 짧고 얇으며 뾰족한 모양의 저형성된 치근을 가지며, 대부분 제1영구대구치에서 발생한다. 또한 유구치와 영구 중절치, 견치에서도 발견된다.

이번 연구의 목적은 구치-절치 이형성증의 임상적, 방사선학적 특징을 조사하는 것이었다. 이를 위해 우리는 17명의 구치-절치 저형성증 환자들의 방사선학적 자료와 병력을 후향적으로 조사했다. 방사선학적 특징으로는 제1대구치와 유구치들의 치근이 짧고 가늘면서 저발육된 양상과 함께 치수강의 크기가 좁아진 소견을 보였다. 하지만, 치관부에서는 이상 소견의 징후에 대한 기록이 없었다. 영구절치와 견치에서도 만곡되면서 길이가 짧아진 치근의 소견이 관찰되었으며, 몇몇 증례에서는 치관에서도 치경부에 국한된 결손부가 관찰되었다. 환자들의 병력을 조사한 결과, 모든 환자들이 신생아 시기에 수술 등의 이유로 입원치료를 받은 적이 있는 것으로 나타났다.

구치-절치 이형성증 환자의 치아는 치근의 형태이상으로 인하여 일찍 치아를 상실할 가능성이 높다. 따라서 특히 어린 환자들의 경우 이 질환에 이환된 치아를 장기적으로 유지하기 위해서는 방사선사진을 이용한 조기 진단과 적절한 치료가 필요할 것으로 생각된다.

……

주요어 : 구치-절치 이형성증, 구치-절치 저광화증

학 번 : 2012-22221