



저작자표시-비영리-변경금지 2.0 대한민국

이용자는 아래의 조건을 따르는 경우에 한하여 자유롭게

- 이 저작물을 복제, 배포, 전송, 전시, 공연 및 방송할 수 있습니다.

다음과 같은 조건을 따라야 합니다:



저작자표시. 귀하는 원저작자를 표시하여야 합니다.



비영리. 귀하는 이 저작물을 영리 목적으로 이용할 수 없습니다.



변경금지. 귀하는 이 저작물을 개작, 변형 또는 가공할 수 없습니다.

- 귀하는, 이 저작물의 재이용이나 배포의 경우, 이 저작물에 적용된 이용허락조건을 명확하게 나타내어야 합니다.
- 저작권자로부터 별도의 허가를 받으면 이러한 조건들은 적용되지 않습니다.

저작권법에 따른 이용자의 권리는 위의 내용에 의하여 영향을 받지 않습니다.

이것은 [이용허락규약\(Legal Code\)](#)을 이해하기 쉽게 요약한 것입니다.

[Disclaimer](#)

Abstract

The relation between Frankfort plane, gnathologic plane and occlusal plane for application of articulator

Lee Sang Hyun
School of Dentistry
The Graduate School
Seoul National University

Introduction

Clinically articulators represent patient's occlusion for prosthodontic restoration, and for this purpose, records of reference planes are used to transfer information of static and functional jaw relationships to articulators. Frankfort horizontal plane and gnathologic plane are mainly used to set occlusal plane which is composed of information of heights of incisors and molars from these reference planes. Since occlusal plane in articulators sets the position of maxillary and mandibular casts, two casts mounted on articulator can represent position of two jaws in patient's skull and copy the real jaw movement.

In this study, relationship between these three reference planes(Frankfort plane, Gnathologic plane, Occlusal plane) was measured using lateral cephalogram of normal occlusions. And we discussed the method for application of the same occlusal plane in two articulators, using Frankfort plane or gnathologic plane for reference plane, which can lead fabrication of similar prosthesis.

Material and Method

62 males and 50 females were studied and their lateral cephalographs were used for our study. Subjects were dental students of Seoul National University from 2003 to 2007, and only students with normal occlusion were included after oral examination by residents in orthodontics. Radiographs of 3 males who had been examined twice in this period were excluded.

For radiographic analysis, lateral cephalogram was traced with lateral cephalography of 109 subjects. Analysis of angle between reference planes were achieved by V-ceph 5.5 (CyberMed, INC., Seoul, Korea) software, and IBM SPSS Statistics 23 (SPSS INC., Chicago, USA) was used for statistical analysis between results of male and female.

Result

①Angle between Frankfort plane and Occlusal plane: average value was 8.29 ± 3.62 degree, male 8.88 ± 3.09 degree, and female 7.63 ± 4.10 degree

②Angle between Frankfort plane and gnathologic plane: average value was 5.52 ± 3.62 degree, male 6.21 ± 2.53 degree, and female 4.84 ± 3.09 degree

③Angle between Gnathologic plane and Occlusal plane: average value was 2.77 ± 3.62 degree, male 2.67 ± 3.44 degree, and female 2.78 ± 3.98 degree

Conclusion

When prosthetically restoring with casts mounted on an articulator using Frankfort plane or gnathologic plane, the relationship between skull occlusal plane of patient can be the same in two articulator with using the angle between two reference planes. Also, there is no significant difference in men and women, the total average value can be applied in the same way.

Keyword : Frankfort plane, occlusal plane, gnathologic plane
Student Number : 2012-22186

I. Introduction	- 1 -
1) Subjects	- 3 -
2) Method for analysis	- 3 -
3) Angle for analysis.....	- 4 -
III. Results	- 7 -
IV. Discussion	- 8 -
V. Conclusion.....	- 10 -
References	- 11 -

I. Introduction

Several reference lines and planes for facial analysis are broadly used in dentistry, mainly in orthodontics and prosthodontics¹. Especially for prosthodontics, diagnosis and analysis of relationships between orofacial landmarks is important to determine references for positioning cast and occlusal plane, and for recording functional jaw movement, which are finally essential for fabricating accurate prosthesis².

Clinically articulators represent patient's occlusion for prosthodontic restoration, and for this purpose, records of reference planes are used to transfer information of static and functional jaw relationships to articulators. Frankfort horizontal plane and gnathologic plane are mainly used to set occlusal plane which is composed of information of heights of incisors and molars from these reference planes. Since occlusal plane in articulators sets the position of maxillary and mandibular casts, two casts mounted on articulator can represent position of two jaws in patient's skull and copy the real jaw movement³.

Frankfort plane(used same as Frankfort horizontal plane, FH plane) is virtual horizontal plane in skull, connecting the most inferior point of orbit and superior border of both ear pillars. It is known that Frankfort plane is almost parallel to horizontal plane when a person has a comfort posture, and that it is so stable that it has a less change with age increase, and highly reproducible as a reference plane, which are advantages for prosthodontic usage. With facebow, Frankfort plane is used for mounting a maxillary cast in articulator, and facebow transfer permits articulator to position the cast copying the relationship of two condyles and maxillary dentition of patient⁴.

Gnathologic plane needs the third reference point that is 43mm above from maxillary right central incisal edge. This virtual point and both orifices of

external acoustic meatus compose a gnathologic plane, which is reference plane for mounting a cast in a articulator as Frankfort plane is⁵.

Occlusal plane has two concepts, prosthodontic occlusal plane for dentition in denture and anatomic occlusal plane, and anatomic occlusal plane is a plane connecting mandibular incisor and distobuccal cusps of both second molars. Camper's plane, one of the prosthodontic occlusal plane, is a plane connecting ala of nose and superior border of external acoutinc meatus. It is called the prosthodontic occlusal plane due to being almost parallel to occlusal plane, and used to determine occlusal plane of wax rim in full denture fabrication. Gysi suggested Ala-tragus line, connecting the inferior border of ala of nose and the inferior border of external acoustic meatus, be more parallel to the anatomic occlusal plane^{6, 7}

Although researches for several reference lines and planes are actively in progress with advancement of devices and radiographic analysis is known as a goldstandard, clinicians rarely use radiographic diagnosis for prosthodontic restoration. Radiologic analysis can be used for prosthesis fabrication to improve the facial profile, and determine the vertical dimension of occlusion and even occlusal angle⁸.

In this study, relationship between these three reference planes(Frankfort plane, Gnathologic plane, Occlusal plane) was measured using lateral cephalogram of normal occlusions. And we discussed the method for application of the same occlusal plane in two articulators, using Frankfort plane or gnathologic plane for reference plane, which can lead fabrication of similar prosthesis.

II. Material and Method

1) Subjects

62 males and 50 females were studied and their lateral cephalographs were used for our study. Subjects were dental students of Seoul National University from 2003 to 2007, and only students with normal occlusion were included after oral examination by residents in orthodontics. Radiographs of 3 males who had been examined twice in this period were excluded.

2) Method for analysis

For radiographic analysis, lateral cephalogram was traced with lateral cephalography of 109 subjects. (Figure 1) To present the third point of gnathologic plane(43mm above the maxillary right central incisor), it was located vertically above 47.3mm from maxillary central incisor on lateral cephalogram considering the magnification ratio(110%), and marked with black triangle(◼). Also, orifice of external acoustic meatus and ear-rod(used in lateral cephalography) was marked on mid-point of two center of ear-rod with white triangle(◁), and these two points were connected to form gnathologic plane.-

Occlusal plane was drawn by connecting mid-point between maxillary central incisor edge and mandibular central incisor edge and occlusal point. After drawing three reference planes(Frankfort plane, gnathologic plane, occlusal plane), angles between theses planes were measured.

Analysis of angle between reference planes were achieved by V-ceph 5.5 (CyberMed, INC., Seoul, Korea) software, and IBM SPSS Statistics 23(SPSS INC., Chicago, USA) was used for statistical analysis between results of male and female.

3) Angle for analysis

- ① Angle between Frankfort plane and Occlusal plane
- ② Angle between Frankfort plane and gnathologic plane
- ③ Angle between Gnathologic plane and Occlusal plane

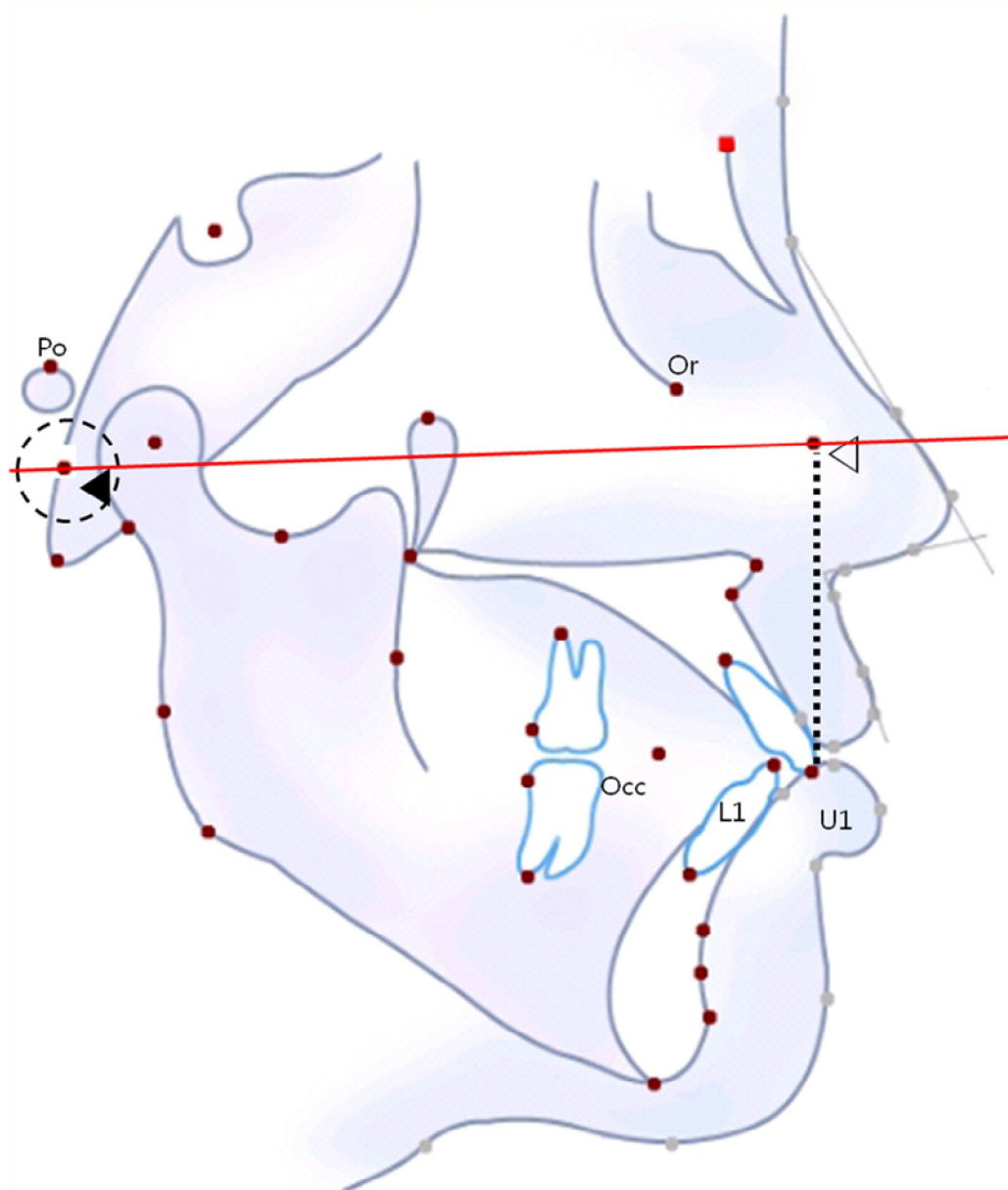


Figure 1 Scheme of reference points for radiographic analysis. Lateral cephalograms were completely traced and reference points for study were marked on cephalograms. Anterior reference point for gnathologic plane was marked vertically above 47.3mm from maxillary central incisor (\triangle), and posterior reference point, center of ear-rod was used(\blacktriangleleft) to form gnathologic plane. Po: Porion, Or: Orbitale, U1: Upper incisor, L1: Lower incisor, Occ: Occlusal point.)

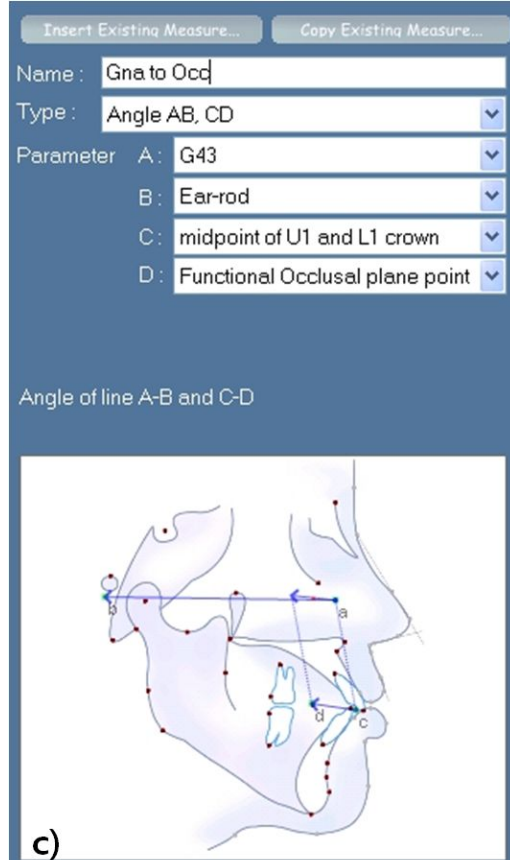
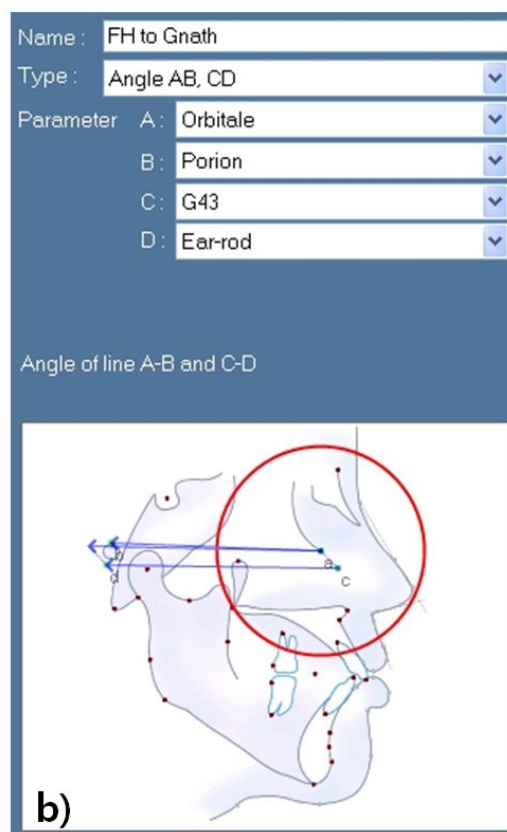
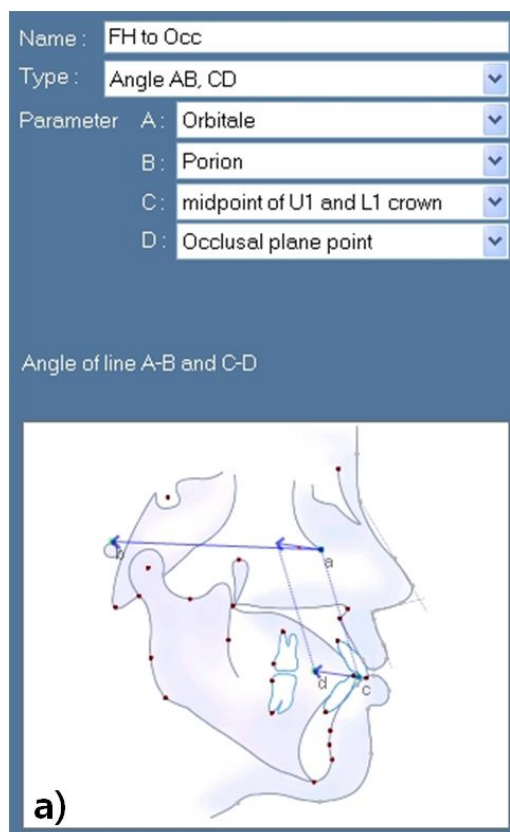


Figure 3 V-ceph(CyberMed, INC., Seoul, Korea) setting for analysis

a) Setting for angle between Frankfort plane and occlusal plane

b) Setting for angle between Frankfort plane and Gnathologic plane

c) Setting for angle between Gnathologic plane and occlusal plane

III. Results

Difference of male and female in angle between reference planes(Table I).

①Angle between Frankfort plane and Occlusal plane: average value was 8.29 ± 3.62 degree, male 8.88 ± 3.09 degree, and female 7.63 ± 4.10 degree

②Angle between Frankfort plane and gnathologic plane: average value was 5.52 ± 3.62 degree, male 6.21 ± 2.53 degree, and female 4.84 ± 3.09 degree

③Angle between Gnathologic plane and Occlusal plane: average value was 2.77 ± 3.62 degree, male 2.67 ± 3.44 degree, and female 2.78 ± 3.98 degree

	FH to Occlusal plane	FH to Gnathologic plane	Gnathologic to Occlusal plane
Total(n=109)	8.29 ± 3.62	5.52 ± 3.62	2.77 ± 3.62
Male(n=59)	8.88 ± 3.09	6.21 ± 2.53	2.67 ± 3.44
Female(n=50)	7.63 ± 4.10	4.84 ± 3.09	2.78 ± 3.98

Table I. Angle between Frankfort horizontal plane, Gnathologic plane and occlusal plane

IV. Discussion

Total 109 lateral cephalograms were used to analyze the angles between Frankfort plane, gnathologic plane, and occlusal plane.

According to Downs, the angle between Frankfort plane and occlusal plane has an average value of 9.3 degree⁹, whereas Goldsman suggested 8.6 degree as an average¹⁰, and probability index proposed average range of 8~12 degree¹¹. In our study, the average angle was 8.29 degree and similar to previous studies. The average value was 8.29 degree in men, and 7.63 degree in women, and because they had no significant difference according to t- test with 95% reliability, both were thought to be in a normal range.

The angle between Frankfort plane and gnathologic plane had an average value of 5.52 ± 3.62 degree, and there was significant difference between male(average 6.21 degree) and female(average 4.84 degree) subjects according to t-test with 95% reliability. However, there was no significant difference between male and female average of the angle between gnathologic plane and occlusal plane according to t-test with 95% reliability. Considering the angle between Frankfort plane and occlusal plane is sum of other two angles, it seems suspicious that the only one angle had difference between male and female average, and further study with more subjects can solve this uncertainty.

Camper's line(plane) is the most broadly used reference line for denture occlusion and called prosthetic occlusal plane. It is known to have difference of 2.1~6.1 degree with natural dentition and its occlusal plane¹², and this value is thought insignificant. Also, it is known that Camper's line has inclination of 12 degree to Frankfort plane². With these studies, the angle between Frankfort plane and prosthetic occlusal plane should be in 6~10 degree. Thus, the average angle between these two planes in our study(8.29 degree) seems to be in applicable range of prosthesis fabrication.

The gnathologic plane, proposed by Guichet, had inclination of average 5.52 degree to Frankfort. The posterior reference point of gnathologic plane can be porion, hinge axis¹³ or ear-rod like our study. However, these posterior reference points are thought to be not clinically significant, and one posterior reference point with consensus is needed for lateral cephalographic analysis of gnathologic plane.

Monteith proposed that occlusal plane angle(the angle between Frankfort plane and occlusal plane) can be calculated using PoNANS angle¹⁴, which was applied to make esthetic complete dentures for patients¹⁵. (Figure 3, 4) However, when using Frankfort plane as a reference plane for maxillary cast mounting, occlusal inclination can be too much for articulator to be in the range for manipulation or to handle with it^{16, 17}. For this reason, the reference plane can be replaced to gnathologic plane.

Substracting the angle value between Frankfort plane and gnathologic plane in our study can form occlusal angle for gnathologic plane, which can make the same relationship between skull base and occlusal plane in different articulator system using different reference plane. This means similar restorations can be made in different articulators. Also, total average value can be applicable due to insignificant difference between men and women.

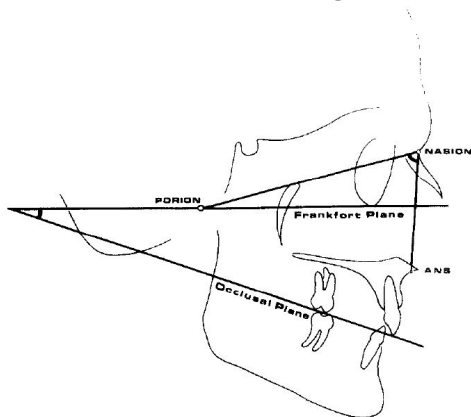


Figure 3. The formular for calculation of occlusal angle. $y = 77.3484 - 0.9098x$ (y: occlusal plane angle, x: PoNANS angle).

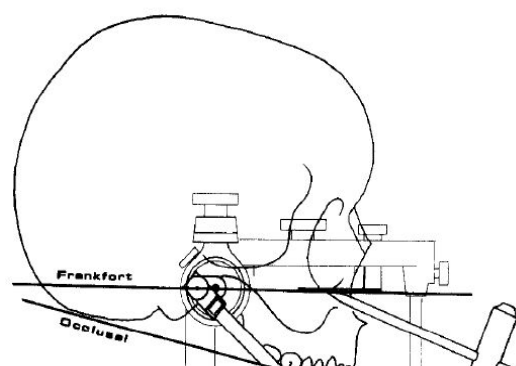


Figure 4. Location of Porion and hinge axis in semi-adjustable articulator can be accepted as equal, because Porion is a bony counterpart of external acoustic meatus (Monteith B. D. : J Prosthet Dent 54 : 81—87, 1985)

**(Monteith B. D. : J Prosthet Dent
54 : 81—87, 1985)**

V. Conclusion

When prosthetically restoring with casts mounted on an articulator using Frankfort plane or gnathologic plane, the relationship between skull occlusal plane of patient can be the same in two articulator with using the angle between two reference planes. It means functional restorations with similar form can be made in different articulators. Also, there is no significant difference in men and women, the total average value can be applied in the same way.

References

1. Downs WB. The role of cephalometrics in orthodontic case analysis and diagnosis. *American Journal of Orthodontics* 1952;38:162-182.
2. Olsson A, Posselt U. Relationship of various skull reference lines. *The Journal of Prosthetic Dentistry* 1961;11:1045-1049.
3. Ow RK, Djeng S, Ho C. The relationships of upper facial proportions and the plane of occlusion to anatomic reference planes. *The Journal of prosthetic dentistry* 1989;61:727-733.
4. Gonzalez JB, Kingery RH. Evaluation of planes of reference for orienting maxillary casts on articulators. *The Journal of the American Dental Association* 1968;76:329-336.
5. Wilkie ND. The anterior point of reference. *The Journal of prosthetic dentistry* 1979;41:488-496.
6. Ismail YH, Bowman JF. Position of the occlusal plane in natural and artificial teeth. *The Journal of prosthetic dentistry* 1968;20:407-411.
7. Van Niekerk F, Miller V, Bibby R. The ala-tragus line in complete denture prosthodontics. *The Journal of prosthetic dentistry* 1985;53:67-69.
8. Chaconas SJ, Gonidis D. A cephalometric technique for prosthodontic diagnosis and treatment planning. *The Journal of prosthetic dentistry* 1986;56:567-574.
9. Downs WB. Variations in facial relationships: their significance in treatment and prognosis. *American journal of orthodontics* 1948;34:812-840.
10. Goldsman S. The Variations In Skeletal And Denture Patterns In Excellent Adult Facial Types*. *The Angle Orthodontist* 1959;29:63-92.
11. Gramling JF. The probability index. *American Journal of Orthodontics and Dentofacial Orthopedics* 1995;107:165-171.
12. Quran FAA, Hazza'a A, Nahass NA. The position of the occlusal plane in natural and artificial dentitions as related to other craniofacial planes. *Journal of Prosthodontics* 2010;19:601-605.
13. 황희성, 이호용. Hanau 96-H, 교합기에 상악 모형 부착시. *대한치과의 사협회지: Vol* 1987;25.
14. Monteith BD. A cephalometric method to determine the angulation of the occlusal plane in edentulous patients. *The Journal of prosthetic dentistry* 1985;54:81-87.

15. Monteith BD. Evaluation of a cephalometric method of occlusal plane orientation for complete dentures. *The Journal of prosthetic dentistry* 1986;55:64–69.
16. Ash MM, Ramfjord SP. *An introduction to functional occlusion*: WB Saunders Company; 1982.
17. Bailey J, Nowlin T. Evaluation of the third point of reference for mounting maxillary casts on the Hanau articulator. *The Journal of prosthetic dentistry* 1984;51:199–201.

논문 초록

목적

보철치료 시, 환자의 악간 관계와 교합을 교합기에 재현하는 것은 필수적이다. 상, 하악의 정적, 동적 관계를 기록, 교합기에 옮기기 위해 인체의 두개 안면 영역에서 설정된 여러 평면 중의 하나를 기준면으로 사용하게 되는데, 그 중 대표적인 것이 Frankfort 평면과 gnathologic 평면이다. 이 기준면에 대해 구강 내 치아들의 절단면과 교합면이 형성한 교합평면(occlusal plane)을 교합기에 옮김으로써 환자의 두개에 대한 상악과 하악의 위치가 설정되어 교합기 상에서의 환자 치아 모형의 움직임이 실제 환자의 하악 운동을 나타낸다.

치의학의 영역에서 보철학과 교정학을 중심으로 여러 기준선, 기준면이 임상과 연구에 응용되고 있다. 특히 보철학에서는 악구강 기능의 진단과 보철물 제작에 두개안면부와 치아와의 위치관계의 파악이 교합 평면의 결정과 모형의 교합기 장착의 기준 또는 악운동측정을 위한 기준으로서 중요하다.

이 연구에서는 정상교합에서 세 가지 평면(Frankfort plane, Occlusal plane, Gnathologic plane)의 관계를 두부계측방사선사진을 활용하여 측정하고, Frankfort plane, 또는 gnathologic plane을 기준으로 사용하는 교합기 간 동일한 occlusal plane을 적용, 유사한 보철 수복물을 제작할 수 있는 방법을 탐색하였다.

방법

2003년부터 2007년에 걸쳐 20~39세 남성 59명, 여성 50명의 측방두부규격방사선 사진을 연구하였다. 이들은 서울대학교 치의학대학원 재학생이었으며 교정과 전문의에 의해 정상교합자로 분류되었다. 계측을 위해 측방계측 방사선사진만을 사용해 피험자들의 트레이싱을 완성했다. Gnathologic plane의 재현을 위해 측방두부규격 방사선 트레이싱 상에서 상악 우측 중절치에서 43 mm 상방의 점은. 또한 외이공 및 ear-rod가 위치하는 부위는 양쪽 ear-rod 중심의 중점을 이용해 표시하였고, 두 점을 이은 평면을 gnathologic plane으로 정하였다. 이 평면과 Frankfort plane, occlusal plane 사이 각의 측정과 분석에는 V-ceph 5.5 (CyberMed, INC., Seoul, Korea) software를 이용했다.

결과

① Frankfort plane과 교합평면 사이의 각: 전체 평균은 8.29 ± 3.62 이며, 남성은 8.88 ± 3.09 , 여성은 7.63 ± 4.10 로 나타났다.

② Frankfort plane과 gnathologic plane 사이의 각: 전체 평균은 5.52 ± 3.62 이며, 남성은 6.21 ± 2.53 , 여성은 4.84 ± 3.09 로 나타났다.

③ Gnathologic plane과 교합평면 사이의 각: 전체 평균은 2.77 ± 3.62 이며, 남성은 2.67 ± 3.44 , 여성은 2.78 ± 3.98 로 나타났다.

결론

Frankfort 평면과 gnathologic 평면 중 하나를 기준면으로 사용하는 교합기에 모형을 부착하여 수복진료를 할 때, 두 기준면 사이의 측정각을 사용하여 환자의 두개와 교합 평면이 동일한 관계에 있도록 하고, 유사한 형태의 기능적 수복물을 제작할 수 있다. 또한, 남성과 여성의 차이가 통계적으로 유의하지 않으므로, 두 기준면 사이의 각은 성별의 차이 없이 전체 평균을 적용할 수 있다.

주요어 : **Frankfort plane, occlusal plane, gnathologic plane**

학 번 : **2012-22186**