치의학석사 학위논문

Correlation analysis between tongue posture and hyoid bone position and cephalometric analysis variables in adult female patients

성인여성 환자에서 혀, 설골위치와 두부규격방사선 계측치들 간의 상관분석

2014년 2월

서울대학교 대학원
치의과학과 치과교정학 전공

정 석 기

치의학석사 학위논문

Correlation analysis between tongue posture and hyoid bone position and cephalometric analysis variables in adult female patients

지도교수 김 태 우

이 논문을 치의학석사 학위논문으로 제출함

2013 년 11 월

서울대학교 대학원

치의과학과 치과교정학 전공

정 석 기

정석기의 치의학석사 학위논문으로 인준함

2013 년 12 월

위 원 장 _____ (인)

부위원장 _____ (인)

위 원 _____ (인)

Abstract

Correlation analysis between tongue posture and hyoid bone position and cephalometric analysis variables in adult female patients

Seok Ki Jung, DDS

Department of Orthodontics, Graduate school, Seoul National University
(Directed by Professor **Tae-Woo Kim**, *DDS, MSD, PhD)*

Introduction: Despite of many previous studies, the relationships of long face and open bite to tongue and hyoid bond position are uncertain. The purpose of this study are to examine whether patients with long face and open bite have lower tongue and hyoid bone position or not, and to examine which cephalometric variables are closely correlated with tongue and hyoid bone position.

Methods: Two hundred twenty-seven Korean adult female patients aged over 18 years were evaluated. Lateral cephalograms of each subject were traced and several landmarks were digitized, then analysis was performed. Distance from the dorsum of tongue to palatal plane and distance from hyoidale to mandibular plane were used to represent tongue and hyoid bone position, respectively. The samples were divided into three groups for all three categories. First category is divided by the amount of overbite (open bite group, moderate overbite group and deep overbite group). Second category is divided by skeletal vertical pattern (high angle group, normal angle group and low angle group). Third category is divided by sagittal skeletal classification (Class I, Class II and Class III). ANOVA test was used to distinguish the differeneces among groups. Pearson's correlation test was used to detect correlation of cephalometric variables with tongue and hyoid bone position.

Results: In the comparison of overbite groups, there were no significant differences in tongue and hyoid bond position. However in the comparison of skeletal vertical pattern groups, tongue position of high angle group was lower than that of low angle group, and hyoid bond position of high angle group was lower than those of the other two groups. In the comparison of sagittal skeletal classification groups, there was no difference in tongue position, but hyoid bone position of Class II group was lower than that of the other two groups.

Correlation analysis showed that variables of anterior facial height, upper Incisor display, facial length are most closely correlated with tongue position and the variables of ramus height, posterior facial height, frankfort mandibular plane angle are most correlated with hyoid bone position.

Conclusions: This study suggests that long face with long anterior facial height tends to have lowerly positioned tongue, and long face with short posterior facial height tends to have lowerly positioned hyoid bone. Open bite only is not seemed to be correlated with tongue and hyoid position. Tongue and hyoid bone position are more related with vertical skeletal pattern than dental overbite pattern.

Key words : tongue position, hyoid bone position, open bite, long face
Student number : 2012-21827

Correlation analysis between tongue posture and hyoid bone position and cephalometric analysis variables in adult female patients

Seok Ki Jung, DDS

Department of Orthodontics, Graduate school, Seoul National University
(Directed by Professor **Tae-Woo Kim**, *DDS, MSD, PhD)*

성인여성 환자에서 혀, 설골위치와 두부규격방사선 계측치들 간의 상관분석

서울대학교 대학원 치의과학과 치과교정학 전공
(지도교수 : 김 태 우)

정 석 기

-Contents-

I. Introduction

The position of the tongue and hyoid bone in relation to the facial skeleton during growth and function has attracted considerable interest.

Lower tongue posture may affect several malocclusions such as widen lower arch, narrow upper arch, anterior open bite, clockwise rotation of mandible, long anterior facial height, posterior crossbite. Therefore observing tongue position and understanding relationship with facial morphology are important.

Hyoid bone position represents position of the tongue base. Compared with uncertain tongue position in the lateral headfilm, hyoid bone position is relatively definite. Therefore hyoid bone position is also valuable to substitute tongue position.

There are several articles to report relationship tongue and hyoid bond position to dentofacial skeletal pattern. Proffit reported that persons with low tongue posture are apt to have long face syndrome.[1] He said that the low tongue posture makes upper arch narrow, and also causes anterior open bite, due to differential eruption of anterior and posterior teeth. Tallgren and Solow reported that large hyo-mandibular distance is associated with a large mandibular inclination.[2]

On the contrary, there are several articles to report no differences of tongue and hyoid bond position according to facial pattern. Haralabakis et al reported that, however, there are no significant differences in the distance of hyoid bone position to mandibular plane between open bite patients and normal persons.[3] Subtelny and Sakuda also reported that no difference of hyoid bone position were found between open bite patients and normal occlusion groups.[4]

Despite of many previous articles[1-4], relationships of long face and open bite patients to tongue posture and hyoid bone position are uncertain. Therefore the purpose of this study is to examine whether patients of long face and open bite have lowerly positioned tongue and hyoid bone or not.

Additionally, we can find which parameter is most closely correlated with tongue and hyoid position through the correlation analysis between tongue posture and hyoid bone position and cephalometric variables.

II. Review of Literature

There have been many published articles about tongue and hyoid bone position.

Hwang et al reported that the hyoid bond showed significant inferoposterior movements, immediately after mandibular setback surgery.[5]

Karacay et al also reported that in the surgically corrected open bite case, the advancement of the mandible along with the correction of open bite affected not only the tongue posture and deglutitive movements, but also the breathing pattern of the patient.[6]

Fujiki et al reported that there were significant correlations between mandibular plane angle and ramus height, and movement of the front part of the dorsal tongue during deglutition in the patients with anterior open bite.[7]

Ozbek reported significant reduction of tongue-to-palate distance as well as hyoid bone-to-mandibular plane distance, after the application of rapid maxillary expansion.[8]

Wang Q et al reported that there was no statistically significant difference of the hyoid position following orthodontic treatment of Class I bimaxillary protrusion.[9]

Vieira et al reported that children with obstructive sleep apnea syndrome presented a significantly more anterior and inferior position of the hyoid bone than nasal breathers.[10]

Phoenix et al reported that the distance from hyoid to mandibular plane was longer in the rapid maxillary expansion group, and tongue length was unaffected.[11]

Bibby reported that the hyoid bone has a stable position and is independent of any posture alterations due to tongue-thrusting or mouth breathing.[12]

Opdebeeck et al examined 27 patients with a short face syndrome and nine patients with a long face syndrome. They found that hyoid bone was moving in concert with the mandible, the tongue, the pharynx, and the cervical spine in

both groups, and they stated that the reason behind this seems to be the need to maintain patency of the upper airway at the level of the base of the tongue.[13]

Andersen examined the vertical position of the hyoid bone in 34 patients with anterior open bite and 40 individuals with normal occlusion. He found that there was no statistically significant difference among the two groups.[14]

Adamidis investigated the hyoid bone position of two groups of patients exhibiting Class I and Class III malocclusions. He found a statistically significant difference in the position and inclination of the hyoid bone between the two groups. Class III patients showed a more anterior position of the hyoid bone and the bone showed a reverse inclination.[15]

Grant studied the position of the hyoid bone in Class I, II, and III malocclusion. He concluded that the hyoid bone position is constant in the three types of malocclusion.[16]

Graber[17], King[18] and Stepovich[19] stated that slight variations in head position in the cephalostat, the postural position of the spine, and the state of function all affect the position of the hyoid bone. They concluded that the hyoid bone has a highly variable position, not only from person to person but also from minute to minute in the same person.

Previous many papers have already studied the difference in position of the tongue and hyoid bone according to the dentofacial morphology. However, there were no studies that have enough sample size to clear relationship of tongue and hyoid bone position to dentofacial skeletal morphology.

III. Material and Methods

The sample consisted of 227 Korean adult female patients, aged over 18 years, who visted the Department of Orthodontics, Seoul National University Dental Hospital, Korea within a specific period of six months (Table 1). Patients with orthodontic treatment history and maxillofacial deformities were excluded.

Lateral cephalograms were taken for all samples as orthodontic records. All tracings were performed by a single investigator. To analyze measurement errors, all tracing were repeated twice, with interval of two weeks. The reference points were digitized with V-ceph (ver 5.3, Osstem Inc., Seoul, Korea). Twenty-eight landmarks (Figure 1) and 44 measurements (Figures 2 to 8) were used.

To determine the tongue position, the shortest distance from the dorsum of tongue to palatal plane (ANS-PNS) was selected. While the shortest distance from hyoidale to mandibular plane (Me-Go) was selected for the hyoid position (Figure 8).

The analysis were performed with three different criteria : overbite, skeletal vertical pattern and sagittal skeletal classification.

First category is the amount of overbite. Group 1 consisted of 68 subjects with anterior open bite (Overbite < 0mm), Group 2 consisted of 91 subjects with moderate overbite (Overbite 0 ~ 3mm), Group 3 consisted of 68 subjects with deep overbite (Overbite > 3mm).

Second category is skeletal vertical pattern. Group 1 consisted of 86 subjects with high angle (Björk Sum > 400°), Group 2 consisted of 73 subjects with normal angle (Björk Sum 395° ~ 400°), Group 3 consisted of 68 subjects with low angle (Björk Sum < 395°).

Third category is sagittal skeletal classification. Group 1 consisted of 81 subjects with skeletal Class I (ANB 1° ~ 5°), Groups 2 consisted of 68 subjects

with skeletal Class II (ANB > 5 ^{o}), Group 3 consisted of 78 subjects with skeletal Class III (ANB < 1 ^{o}) (Table 2).

The statistical analysis of the data was carried out in two stages. First, ANOVA test was used to detect possible significant differences among the groups. Tukey test was used for the post hoc test. Secondly, Pearson's correlation test was used to detect correlation of cephalometric analysis variables with tongue, hyoid position. P value less than 0.05 was considered statistically significant.

The intraclass correlation coefficient (ICC) was used to determine the reliability of the tracings and its values were scored as follows: ICC < 0.4, poor reliability; 0.4 < ICC < 0.75, moderate reliability; ICC > 0.75, excellent reliability.[20] The ICC values in the present study ranged from 0.97 to 0.99, demonstrating the excellent reliabilities (Table 3).

* Definition of cephalometric landmarks (Figure 1)

1. N : Nasion, the intersection of the frontal bone and two nasal bones
2. S : Sella, the center of the sella turcica
3. Or : Orbitale, the lowest point on the lower margin of the bony orbit
4. Po : Porion, the most superior point of the external auditory meatus
5. ANS : Anterior Nasal Spine, the tip of the anterior nasal spine
6. PNS : Posterior Nasal Spine, the tip of the posterior nasal spine
7. A point : Subspinale, the most posterior point on the anterior contour of the upper alveolar process
8. B point : Supramentale, the most posterior point on the anterior contour of the lower alveolar process
9. Pog : Pogonion, the most anterior point on the anterior contour of the symphysis
10. Gn : Gnathion, the most antero-inferior point on the anterior contour of the symphysis
11. Me : Menton, the lowest point of the symphysis

12. Go : Gonion, the most inferior, posterior and outward point on the mandible angle

13. Ar : Articulare, the intersection between the external contour of the cranial base and the dorsal contour of the condyle

14. U1 tip : upper incisor edge

15. U1 root : upper incisor root apex

16. L1 tip : lower incisor edge

17. L1 root : lower incisor root apex

18. middle point of U6 MBC and L6 MBC : middle point of upper first molar mesio-buccal cusp and lower first molar mesio-buccal cusp

19. Dorsum of tongue : the most superior point on the dorsum of tongue

20. H : Hyoidale, the most anterior, superior point on the hyoid bone

21. Pronasale : nose tip, the most anterior point of nose

22. Columella : the most anterior point on the columella

23. Subnasion : the point at junction of columella and upper lip

24. Labial superius : the point changed from concave line to convex line on the upper lip

25. Upper lip : the most anterior point on the upper lip

26. Stomion superius : the most inferior point on the upper lip

27. Lower lip : the most anterior point on the lower lip

28. Soft tissue pogonion : the most anterior point on the soft tissue chin

* Definition of the cephalometric measurements

- A-P relationship measurements (Figure 2)

1. SNA : Sella to Nasion to A point angle

2. SNB : Sella to Nasion to B point angle

3. ANB : A point to Nasion to B point angle

4. APDI : AB plane angle + facial plane angle + palatal plane angle

5. A to N-perp : the distance of A point to perpendicular line from nasion to FH

6. Pog to N-perp : the distance of Pog to perpendicular line from nasion to FH
7. Facial convexity : Nasion to A point to Pog angle
8. AB to MP : angle formed between AB plane and mandibular plane
9. ODI : AB to mandibular plane angle + palatal plane angle

- Vertical relationship measurements (Figure 3)

1. Björk sum : saddle angle + articular angle + gonial angle
2. FMA : FH to mandibular plane angle
3. CF : Combination factor, APDI + ODI
4. OP to MP : occlusal plane to mandibular plane angle
5. OP to FH : occlusal plane to FH angle
6. PPA : palatal plane angle, palatal plane to FH angle
7. AFH : anterior facial height, the distance from Nasion to Menton
8. PFH : posterior facial height, the distance from Sella to Gonion
9. FHR : facial height ratio, posteior to anterior facial height ratio

- Dental measurements (Figure 4)

1. OJ : overjet
2. OB : overbite
3. U1 to FH : angle formed between upper incisor axis and FH plane
4. U1 to SN : angle formed between upper incisor axis and SN plane
5. U1 to OP : angle formed between upper incisor axis and occlusal plane
6. IMPA : incisor mandibular plane angle
7. L1 to OP : angle formed between lower incisor axis and occlusal plane
8. IIA : interincisor angle
9. FMIA : angle formed between lower incisor axis and FH plane

- Soft tissue measurements (Figure 5)

1. UL to E line : upper lip to E line, the distance from upper lip to Ricketts esthetic line

2. LL to E line : lower ip to E line, the distance from lower lip to Ricketts esthetic line

3. NLA : nasolabial angle, columella to subnasion to labial superius angle

- Mandibular measurements (Figure 6)

1. MBL : mandibular body length, the distance from Menton to Gonion
2. Ramus height : the distance from Articular to Gonion
3. Body to ACB : mandibular body length to anterior cranial base(N-S) ratio
4. Gonial angle : Articulare to Gonion to Menton angle

- Other measurements (Figure 7)

1. Saddle angle : Nasion to Sella to Articulare angle
2. Articular angle : Sella to Articulare to Gonion angle
3. Y axis to SN : angle formed between S-Gn and S-N plane
4. Anterior cranial base : anterior cranial base, the distance from Sella to Nasion
5. Posterior cranial base : posterior cranial base, the distance from Sella to Articulare
6. Facial length : the distance from Sella to Gnathion
7. Facial depth : the distance from Nasion to Gonion
8. Upper incisor display : the distance exposed upper incisor down to stomion superius.

- Tongue and Hyoid measurements (Figure 8)

1. Tp to PP : the shortest distance from Dorsum of tongue to palatal plane
2. H to MP : the shortest distance from Hyoidale to mandibular plane

IV. Results

The results of cephalometric analysis are summarized in Tables 4 and 5 and Figures 9 and 10.

When tongue and hyoid bone positions were compared among open, moderate and deep overbite groups, there were no significant differences in both tongue and hyoid positions among the three groups.

However, when tongue and hyoid bone positions were compared among high angle, normal angle and low angle groups, there were significant differences of the tongue and hyoid position. Post-hoc test shows that there are differences of the tongue position between high angle and low angle groups. And it also shows that there are differences between high angle and normal angle groups, high angle and low angle groups in the hyoid position. Both tongue and hyoid position are lower in the high angle group.

When tongue and hyoid bone positions were compared among Class I, Class II and Class III groups, there were no significant differences in the tongue position, but there were significant differences in the hyoid position. Post-hoc test shows that there were difference between Class II and Class I groups, Class II and Class III groups in the hyoid position. Hyoid position are lower in Class II group.

Correlation analysis shows that variables of anterior facial height, upper Incisor display, facial length were significantly correlated with tongue position (correlation coefficient 0.324 ~ 0.371) and the variables of ramus height, posterior facial height, frankfort mandibular plane angle were significantly correlated with hyoid bone position (correlation coefficient 0.402 ~ 0.494).

V. Discussion

Generally, many open bite patients have long face and vice versa. Therefore it is thought that there may be a tendency to consider both characteristics are the same phenomena. However, as a result shows, both of two should be thought discriminately. Many articles have tried to show the different position of the tongue and hyoid bone between patients with open bite and normal occlusion.[2-4] However the present study shows that there were no differences of the tongue and hyoid bone position between patients with open bite and normal occlusion. On the contrary, there were significant difference of the tongue and hyoid bone position between patients with vertical growth pattern and normal growth pattern.

This is more clear when we divide samples into 9 groups by overbite and vertical pattern (Table 6, Figures 9-6, 10-6). High angle in open bite group (n = 33) occupied the biggest percentage in the open bite group (n = 68), but it's was about 50%, not all. Similarly, low angle in deep overbite group (n = 34) occupied the biggest portion in the deep overbite group (n = 68), but it is also about 50%, not all.

When carrying out analysis by each group, there was no significant difference in the tongue position. However there was significant difference in the hyoid bone position. Hyoid bone position is lower in patients with high angle, irrespective of overbite. However there is no significant difference of hyoid bone position among overbite groups (Table 6). This shows us that tongue and hyoid bond position, especially hyoid bone position may be related with vertical growth pattern, not overbite.

In some articles, it is reported that tongue position has a relationship with hyoid bone position. However in the present study, correlation coefficient between tongue position and hyoid bone position is only 0.169, and it is not high correlation. Instead, correlations between tongue position and anterior facial

height and between hyoid bone position and ramus height and posterior facial height were relatively high.

From the statistical results, we can conclude that tongue position tends to be low in the vertical growth pattern with long anterior facial height, and hyoid bone positon tends to be low in the vertical growth pattern with short ramus height and short posterior facial height.

It is note-worthy that skeletal Class II patient shows a lowerly positioned hyoid bone. Kim mentioned in his study that degenerative joint disease is related to the skeletal Class II open bite.[21] And other studies examined the relationship between degenerative joint disease and dentofacial morphology in women with anterior open bite. They found that facial morphology with TMJ ID is related to the skeletal Class II open bite tendency.[22,23] Ahn et al mentioned that Class II malocclusions with temporomandibular disorder patients tends to have a decreased posterior facial height, shortened ramus height, backward rotation and retruded mandible.[24] There are many temporomandibular disorder patients in the university hospital, it seems to have a effect on the results. Actually, high angle patients occupy high percentage in the Class II group (Figure 10-5).

This study was performed with enough sample size to show correlation and differences of each groups. Dentofacial skeletal morphology analysis may be useful to know patient's behavioral habits and soft tissue characteristics such as lower tongue posture. Careful observation and control of the lower tongue position is needed for stability of treatment and minimization of relapse.

Further investigation about the possibility of reducing relapse by the correction of lower tongue position will be needed.

VI. Conclusion

1. There were no significant difference of tongue and hyoid position between open bite group and other groups.
2. However, tongue and hyoid bone are lowerly positioned in the high angle group compared to normal and low angle groups.
3. Furthermore, hyoid bone position is low in the skeletal Class II group.
4. The most correlated cephalometric variables with tongue position are anterior facial height, upper incisor display and facial length.
5. The most correlated cephalometric variables with hyoid bone position are ramus height, posterior facial height and frankfort mandibular plane angle.
6. In summary, long face with long anterior facial height tends to have lowerly positioned tongue, and long face with short posterior facial height tends to have lowerly positioned hyoid bone. However, open bite only is not seemed to be correlated with tongue and hyoid position.

Table 1. Sample investigated

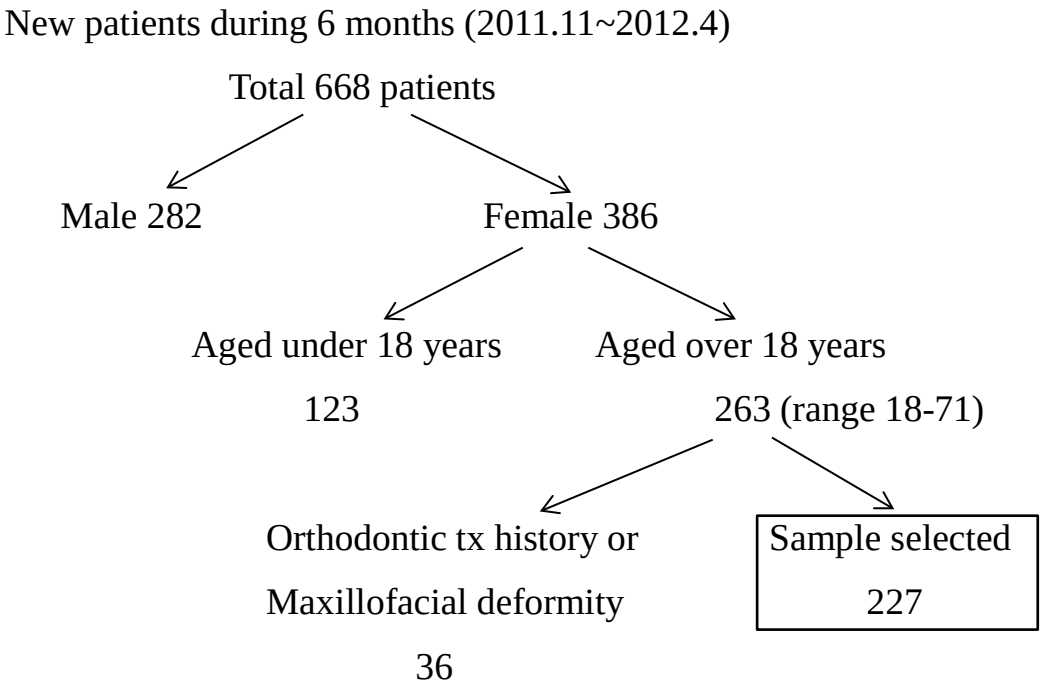

Table 2. Categorization and Grouping

Sample Size (Total)	227
Category 1	
open bite (OB < 0mm)	68
moderate overbite (OB 0 ~ 3mm)	91
deep overbite (OB > 3mm)	68
Category 2	
high angle (Björk Sum > 400)	86
normal angle (Björk Sum 395 ~ 400)	73
low angle (Björk Sum < 395)	68
Category 3	
Skeletal Class I (ANB 1 ~ 5)	81
Skeletal Class II (ANB > 5)	68
Skeletal Class III (ANB < 1)	78

Table 3. Intraclass correlation coefficient (ICC)

	ICC		ICC
Tp to PP	0.996	U1 to FH	0.992
H to MP	0.998	U1 to SN	0.992
SNA	0.993	U1 to OP	0.982
SNB	0.998	IMPA	0.994
ANB	0.997	L1 to OP	0.993
APDI	0.997	IIA	0.995
A to N-perp	0.988	FMIA	0.996
Pog to N-perp	0.997	UL to E line	0.996
Facial convexity	0.998	LL to E line	0.996
AB to MP	0.997	NLA	0.973
ODI	0.996	MBL	0.993
Björk Sum	0.998	Ramus height	0.995
FMA	0.997	Body to ACB	0.992
CF	0.992	Gonial angle	0.996
OP to MP	0.979	Saddle angle	0.991
OP to FH	0.983	Articular angle	0.992
PPA	0.987	Y axis to SN	0.998
AFH	0.998	Ant. cranial base	0.994
PFH	0.996	Post. cranial base	0.992
FHR	0.996	Facial length	0.998
OJ	0.996	Facial depth	0.998
OB	0.993	Upper incisor display	0.988

Table 4. Tongue and hyoid position comparison between each groups

	Open bite (n = 68)	Moderate over bite (n = 91)	Deep overbite (n = 68)	Significance
Tp to PP	8.28 ± 4.13	8.08 ± 3.53	7.50 ± 3.72	NS
H to MP	9.24 ± 5.41	9.70 ± 4.59	9.39 ± 5.16	NS

	High angle (n = 86)	Normal angle (n = 73)	Low angle (n = 68)	Significance
Tp to PP	8.85 ± 4.11	7.76 ± 3.31	7.08 ± 3.59	*
H to MP	11.97 ± 5.08	8.02 ± 4.14	7.86 ± 4.51	***

* (high angle > low angle), *** (high angle > normal angle, low angle)

	Class I (n = 81)	Class II (n = 68)	Class III (n = 78)	Significance
Tp to PP	7.80 ± 3.85	7.69 ± 3.44	8.38 ± 3.97	NS
H to MP	9.03 ± 5.24	11.08 ± 4.83	8.52 ± 4.61	**

** (Class II > Class I, Class III)

NS, Not significant, *P<.05, **P<.01, ***P<.001

Table 5. Correlation analysis between cephalometric variables and tongue, hyoid position (highest correlation top 3)

	Variables	Correlation coefficient	Significance
Tp to PP	AFH	0.371	***
	Upper incisor display	0.326	***
	Facial length	0.324	***
H to MP	Ramus height	-0.494	***
	PFH	-0.438	***
	FMA	0.402	***

NS, Not significant, *P<.05, **P<.01, ***P<.001

Table 6. Tongue and hyoid position comparison considering overbite and vertical pattern

Tp to PP	High angle	Normal angle	Low angle
Open bite	9.12 ± 4.81 (n = 33)	7.37 ± 2.92 (n = 23)	7.70 ± 3.89 (n = 12)
Moderate overbite	8.76 ± 3.39 (n = 37)	8.23 ± 3.69 (n = 32)	6.73 ± 3.31 (n = 22)
Deep overbite	8.51 ± 4.30 (n = 16)	7.41 ± 3.13 (n = 18)	7.08 ± 3.74 (n = 34)

H to MP	High angle	Normal angle	Low angle
Open bite	12.24 ± 4.77 (n = 33)	7.08 ± 3.90 (n = 23)	5.14 ± 5.19 (n = 12)
Moderate overbite	11.21 ± 4.85 (n = 37)	8.99 ± 4.15 (n = 32)	8.21 ± 4.18 (n = 22)
Deep overbite	13.19 ± 6.17 (n = 16)	7.51 ± 4.26 (n = 18)	8.61 ± 4.23 (n = 34)

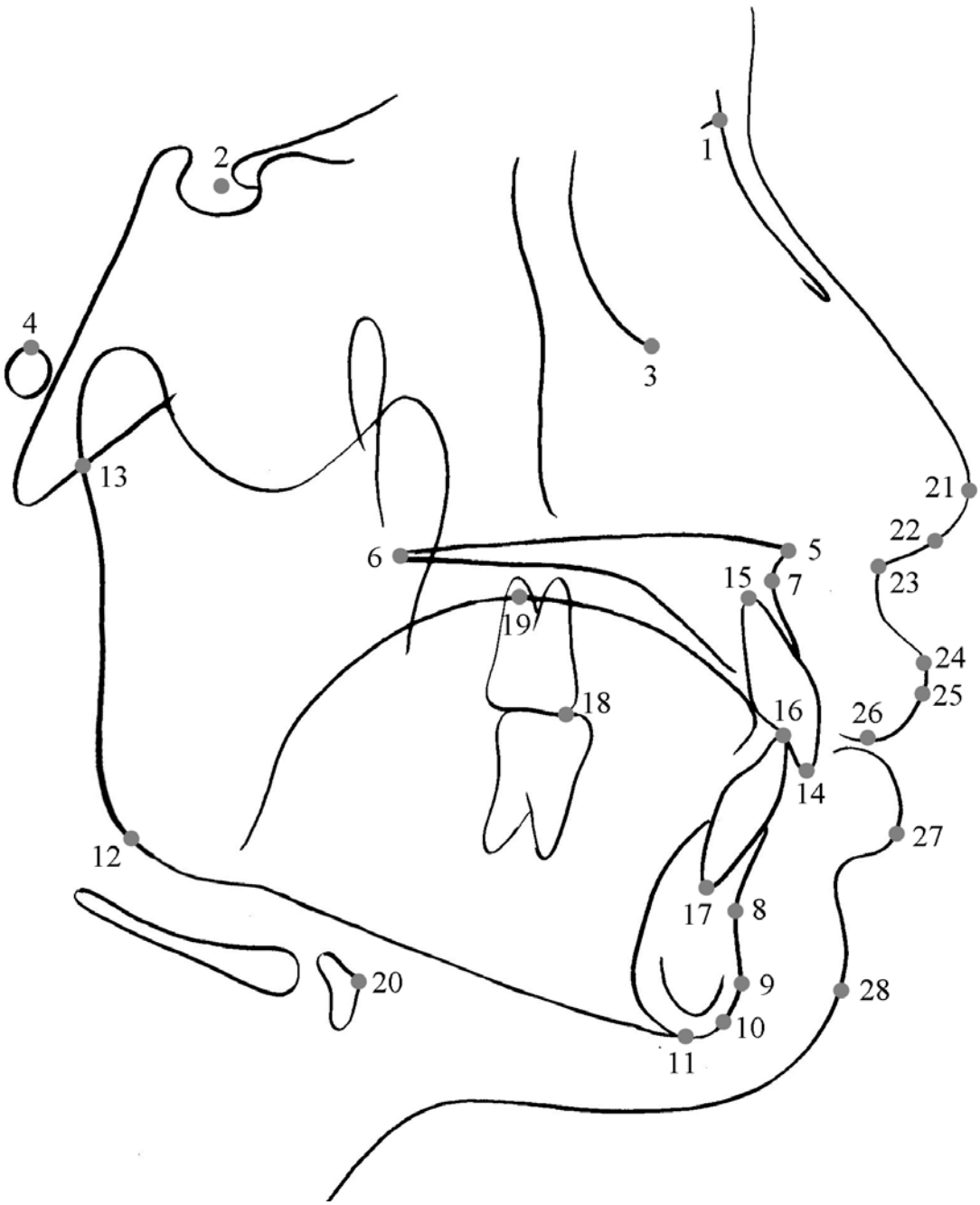

Figure 1. Landmarks used in this study

1) Nasion, 2) Sella, 3) Orbitale, 4) Porion, 5) ANS, 6) PNS, 7) A point, 8) B point, 9) Pogonion, 10) Gnathion, 11) Menton, 12) Gonion, 13) Articulare, 14) U1 tip, 15) U1 root, 16) L1 tip, 17) L1 root, 18) Middle point of U6 MBC and L6 MBC, 19) Dorsum of tongue, 20) Hyoidale, 21) Pronasale, 22) Columella, 23) Subnasion, 24) Labial superius, 25) Upper lip, 26) Stomion superius, 27) Lower lip, and 28) Soft tissue pogonion

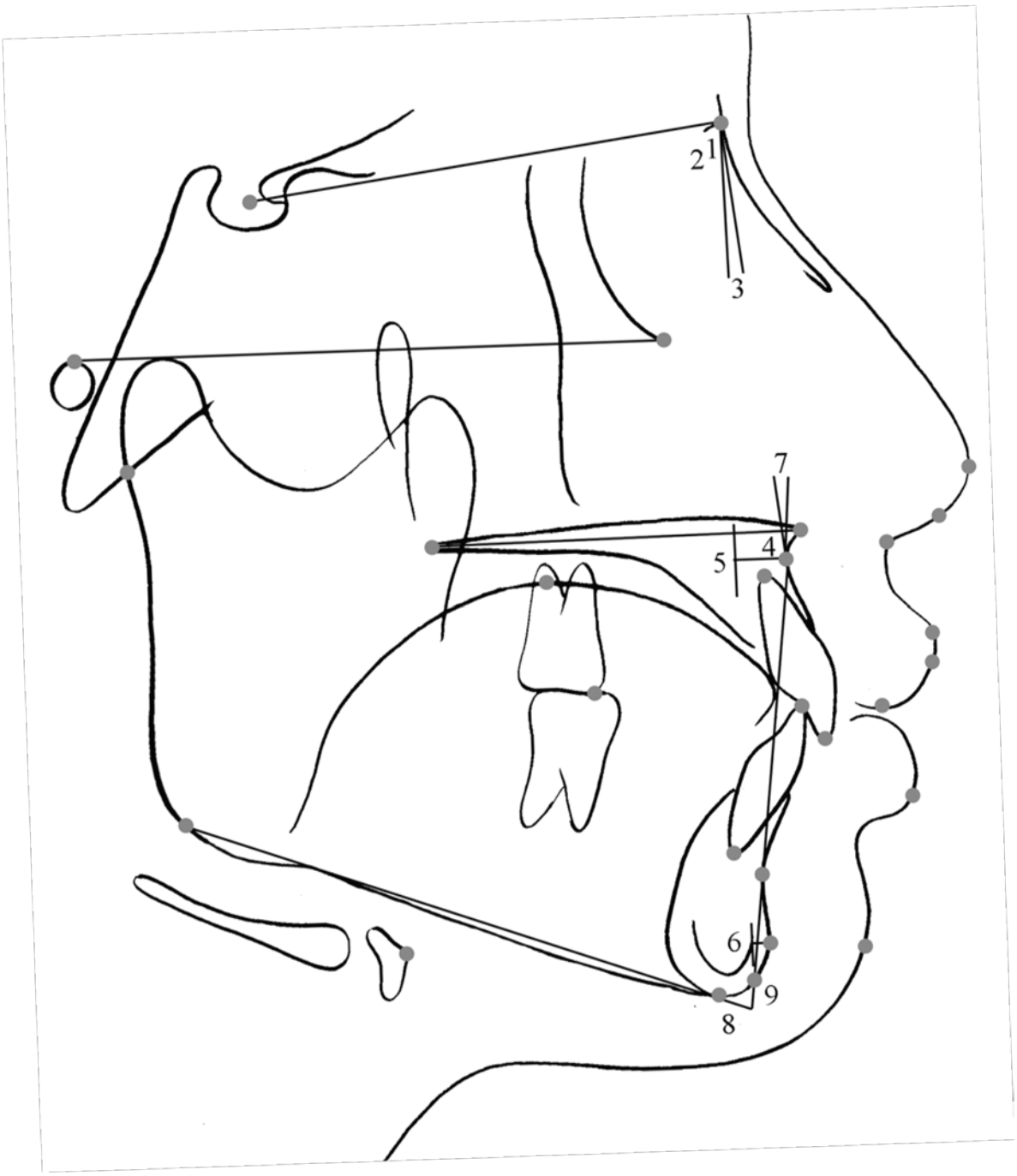

Figure 2. A-P relationship measurements used in this study

1) SNA, 2) SNB, 3) ANB, 4) APDI, 5) A to N-perp, 6) Pog to N-perp, 7) Facial convexity, 8) AB to MP, and 9) ODI

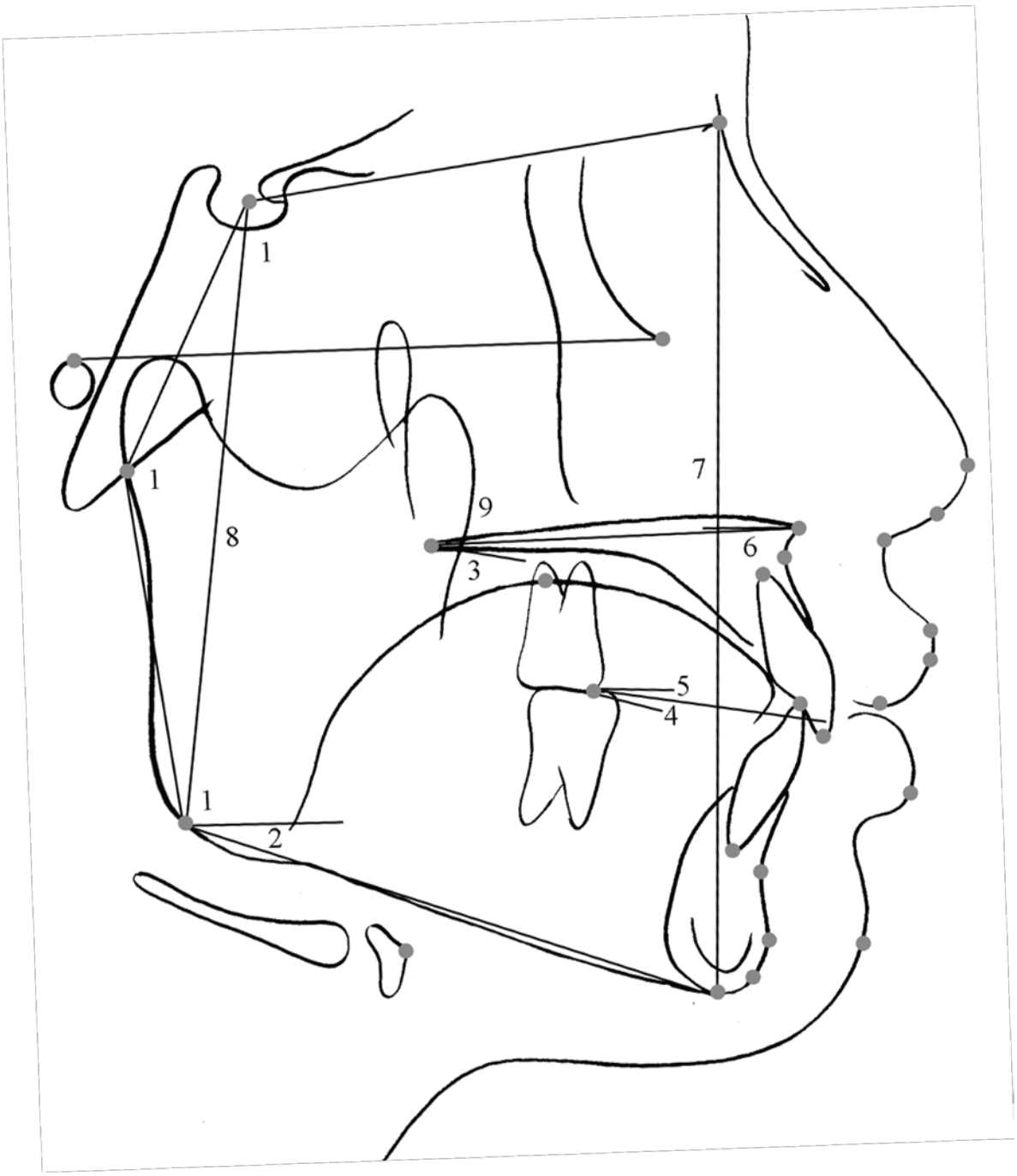

Figure 3. Vertical relationship measurements used in this study

1) Björk sum, 2) FMA, 3) CF (combination factor), 4) OP to MP, 5) OP to FH, 6) PPA (palatal plane angle), 7) AFH (anterior facial height), 8) PFH (posterior facial height), and 9) FHR (facial height ratio)

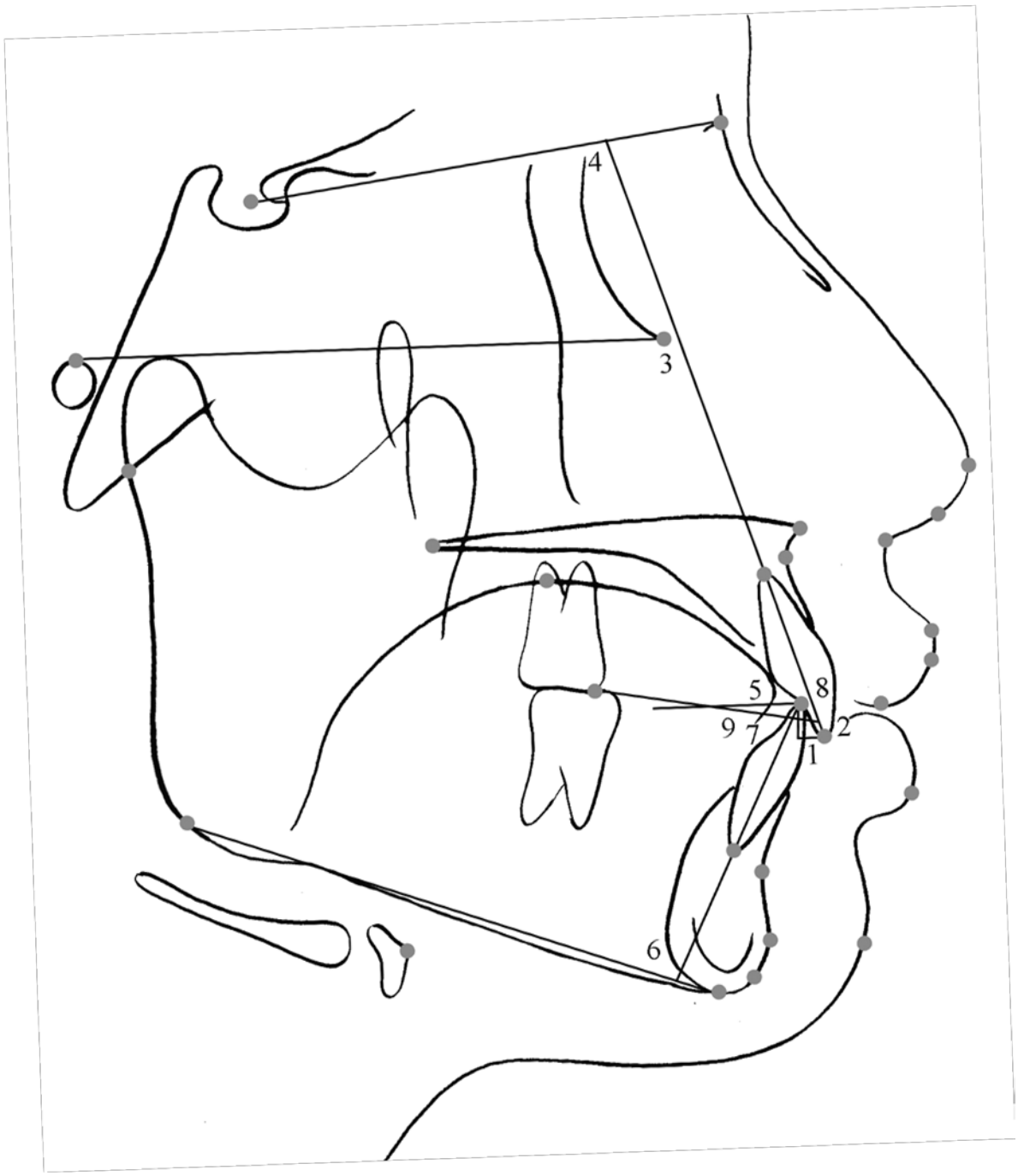

Figure 4. Dental measurements used in this study

1) OJ (overjet), 2) OB (overbite), 3) U1 to FH, 4) U1 to SN, 5) U1 to OP (occlusal plane), 6) IMPA, 7) L1 to OP, 8) IIA (interincisal angle), and 9) FMIA

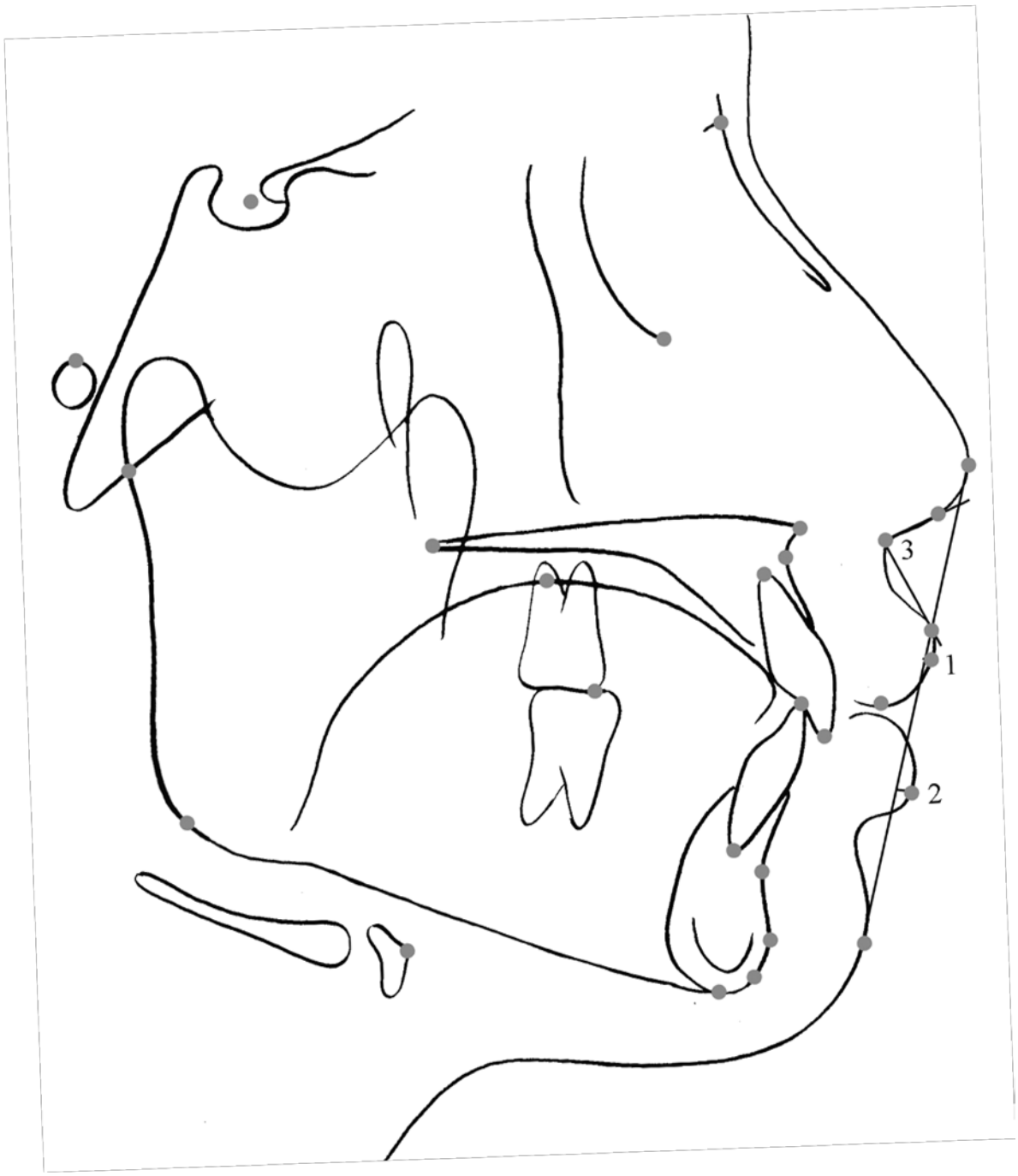

Figure 5. Soft tissue measurements used in this study

1) UL (upper lip) to E line, 2) LL (lower lip) to E line, and 3) NLA (nasolabial angle)

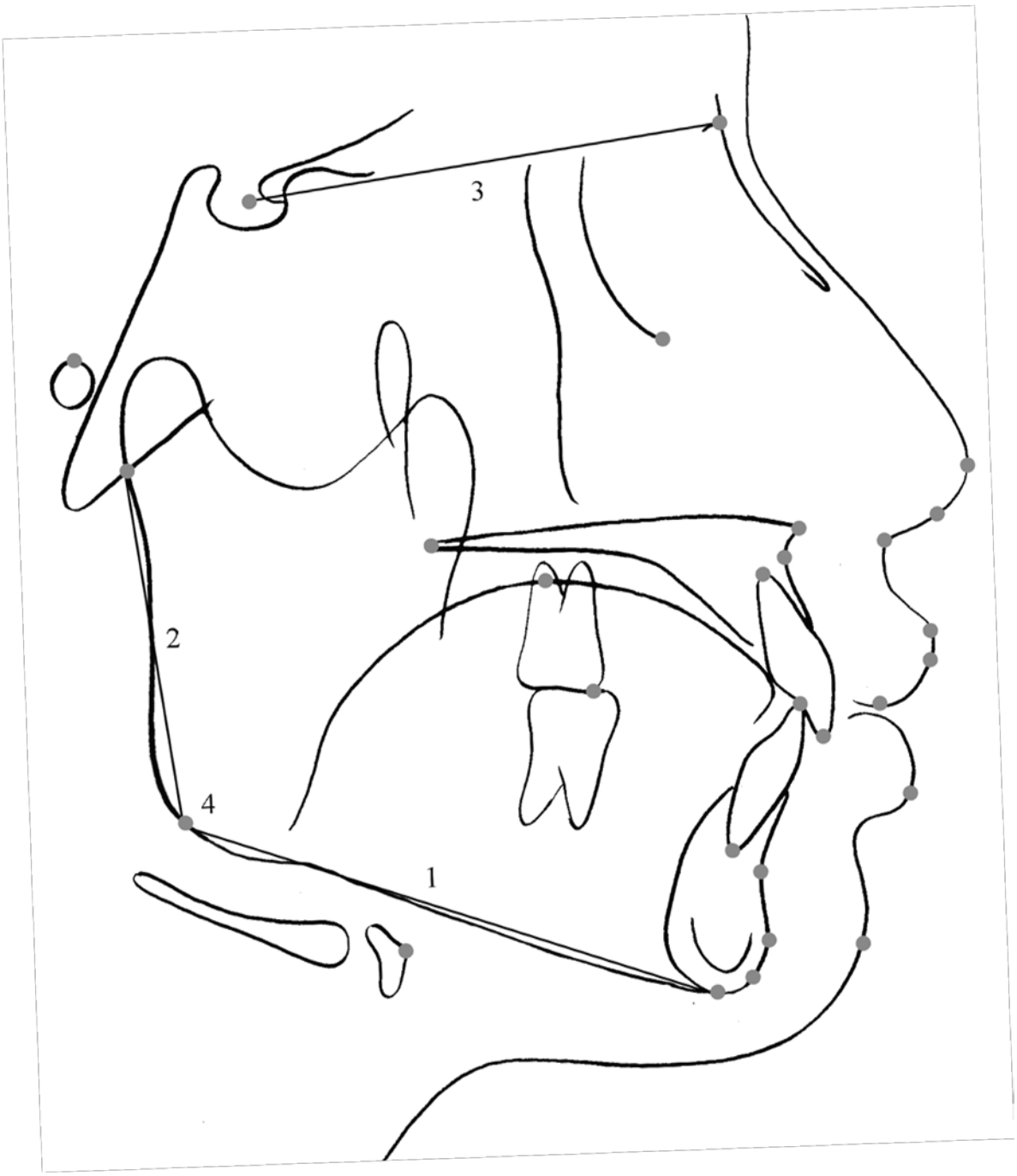

Figure 6. Mandibular measurements used in this study

1) MBL (mandibular body length), 2) Ramus height, 3) Body to ACB (anterior cranial base), and 4) Gonial angle



Figure 7. Other measurements used in this study

1) Saddle angle, 2) Articular angle, 3) Y axis to SN, 4) Anterior cranial base, 5) Posterior cranial base, 6) Facial length, 7) Facial depth, and 8) Upper Incisor Display

Figure 8. Tongue and hyoid measurements used in this study

1) Tp to PP and 2) H to MP

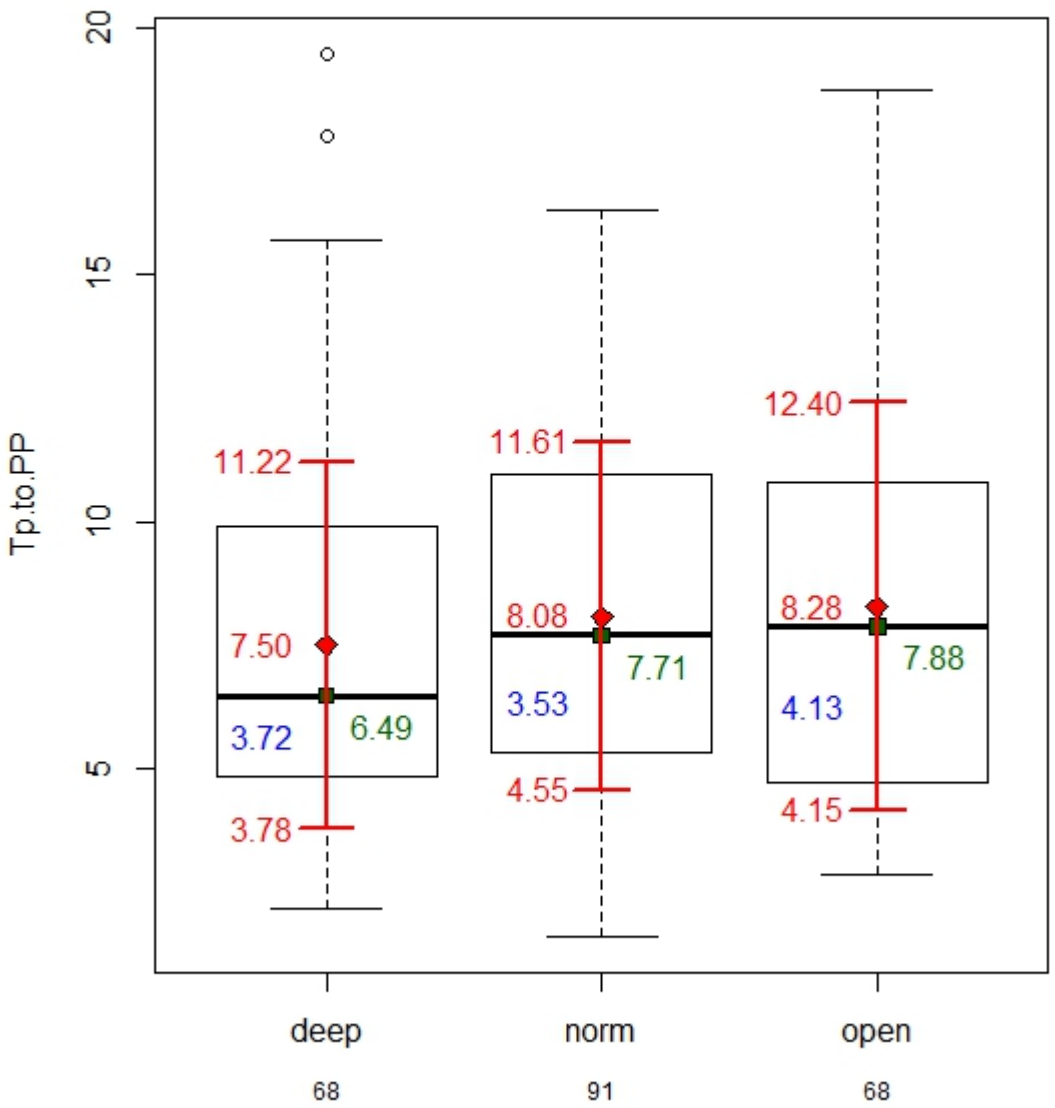

Figure 9-1. Tongue position comparison (Overbite)

* red dot : mean value, blue : standard deviation, green : median value
  red line : range of one standard deviation

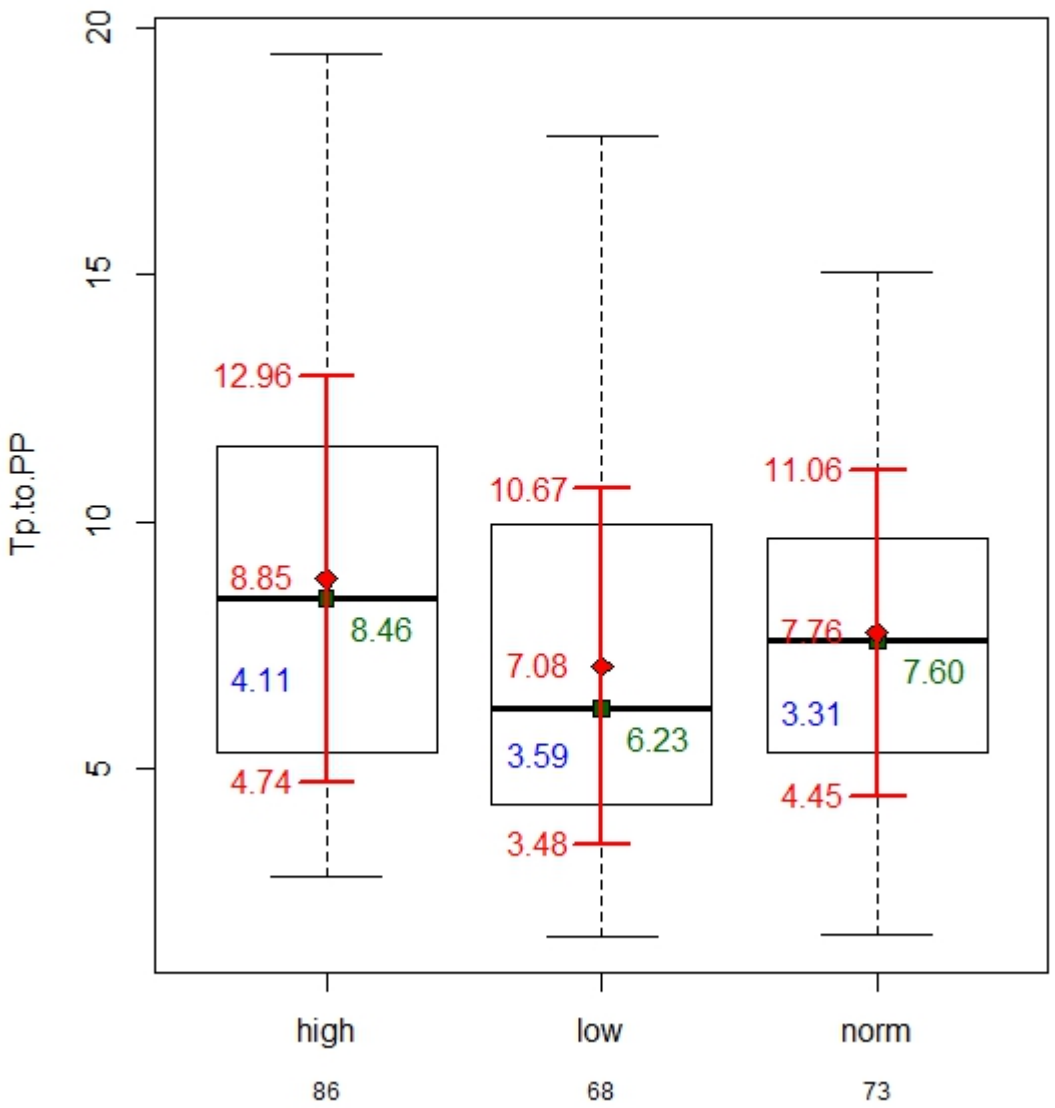

Figure 9-2. Tongue position comparison (Vertical pattern)

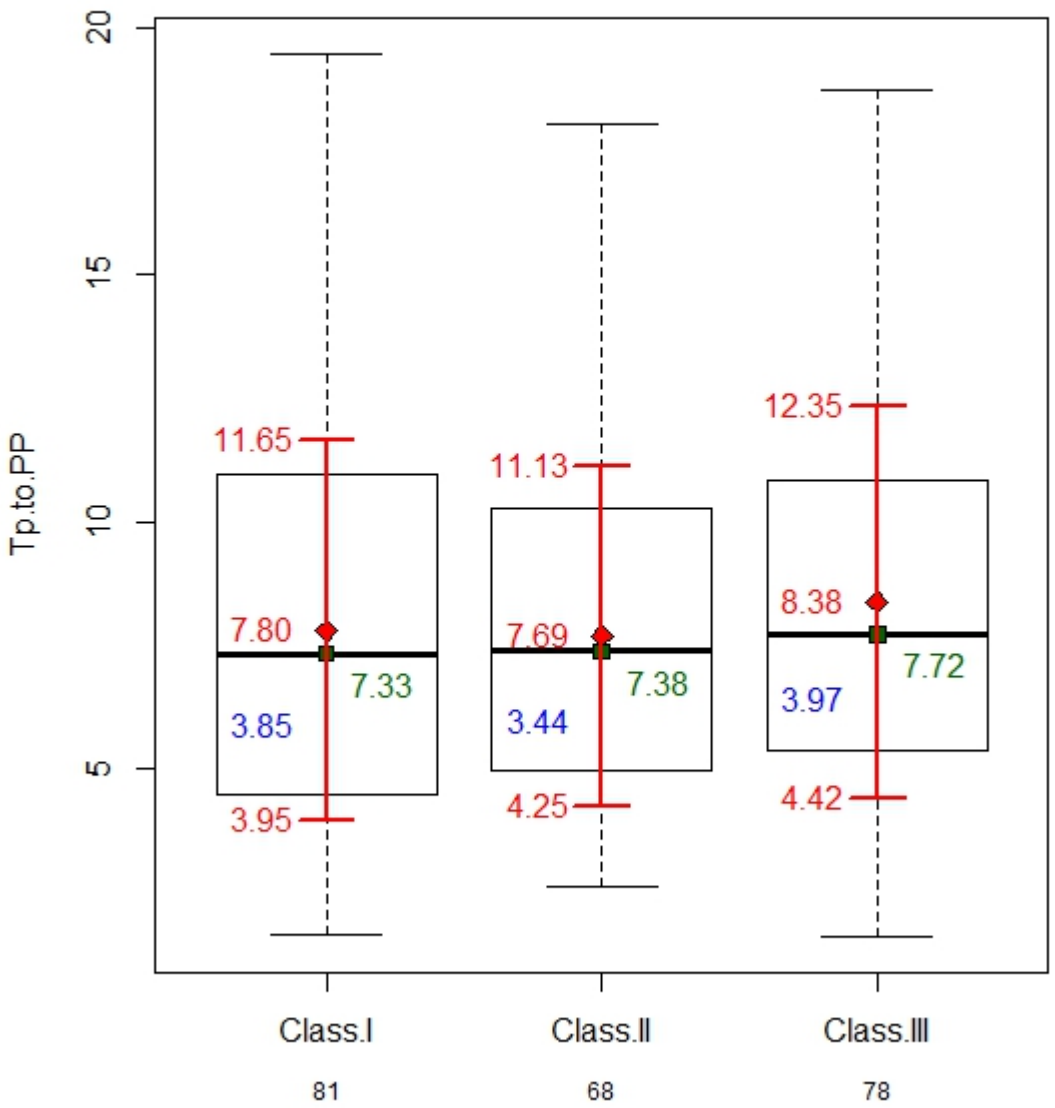

Figure 9-3. Tongue position comparison (Skeletal Classification)

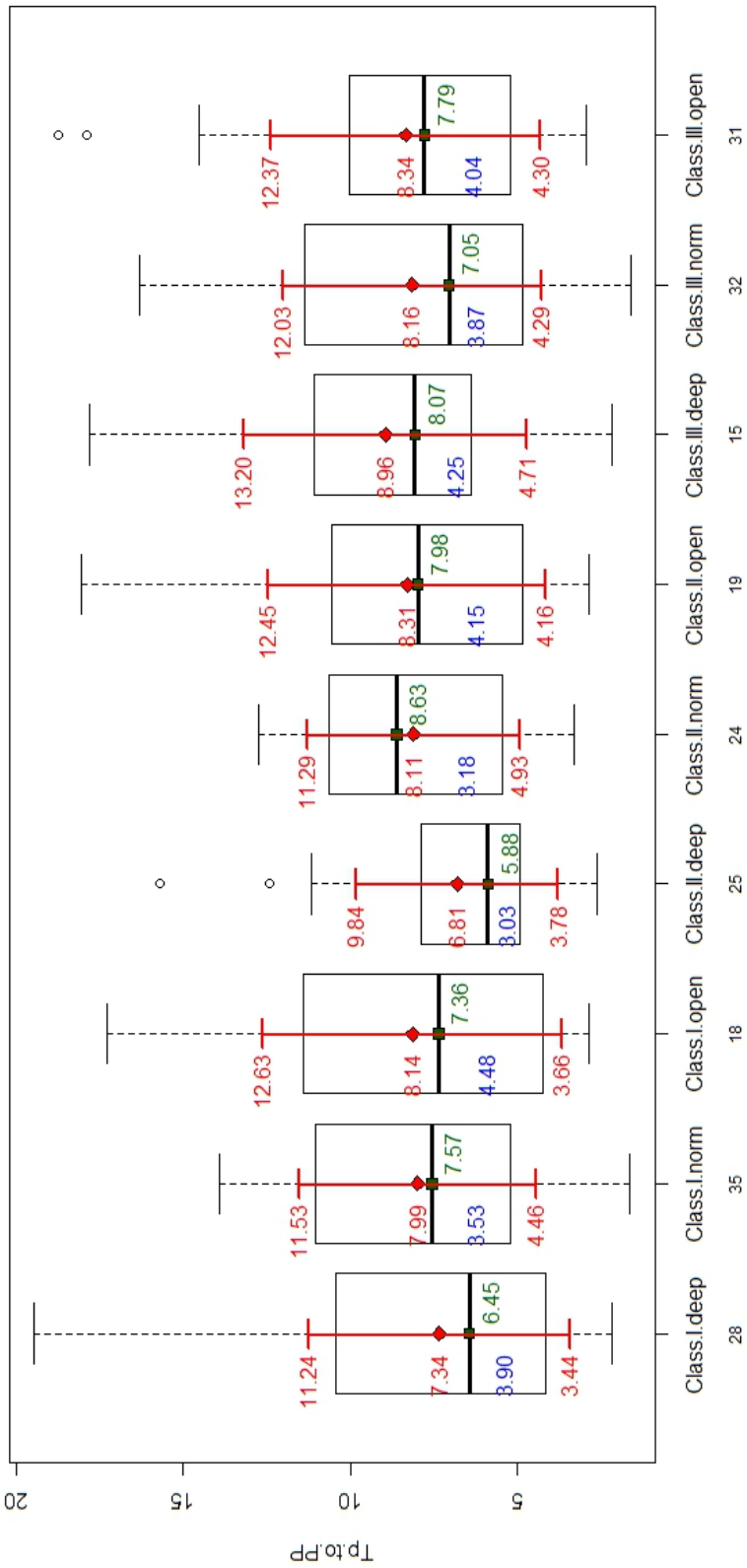

Figure 9-4. Tongue position comparison (Overbite and Skeletal Classification)

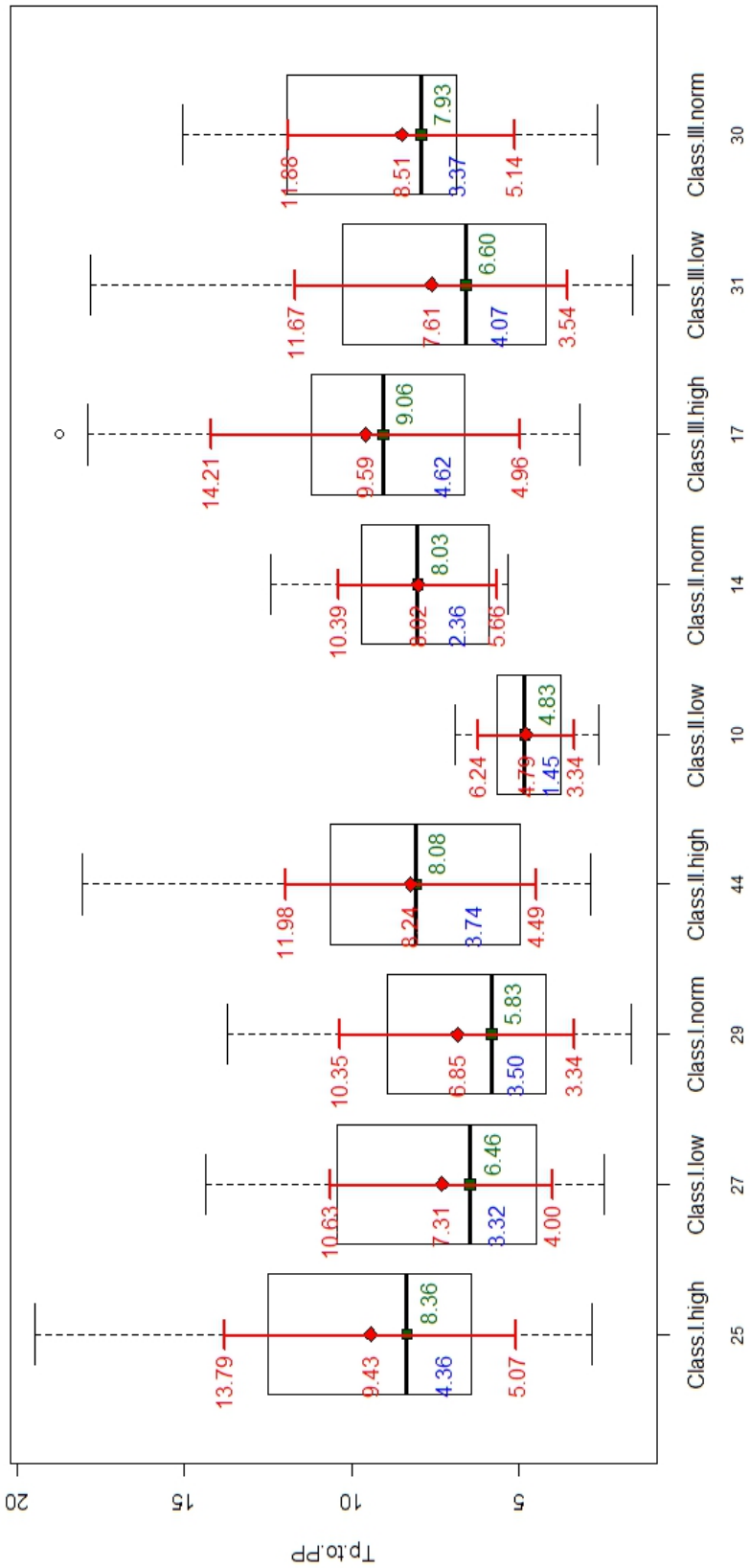

Figure 9-5. Tongue position comparison (Vertical and Skeletal Classification)

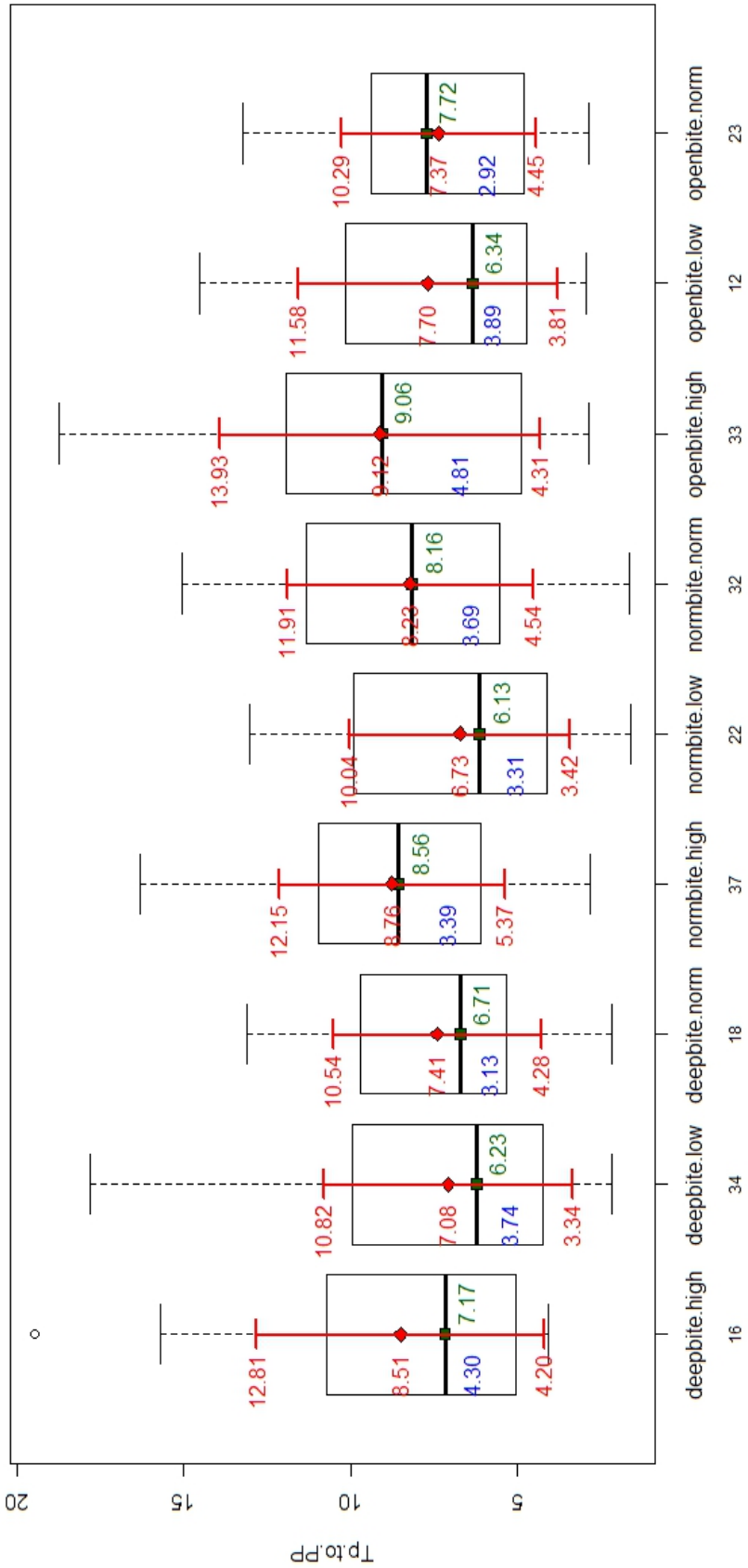

Figure 9-6. Tongue position comparison (Vertical and Overbite)

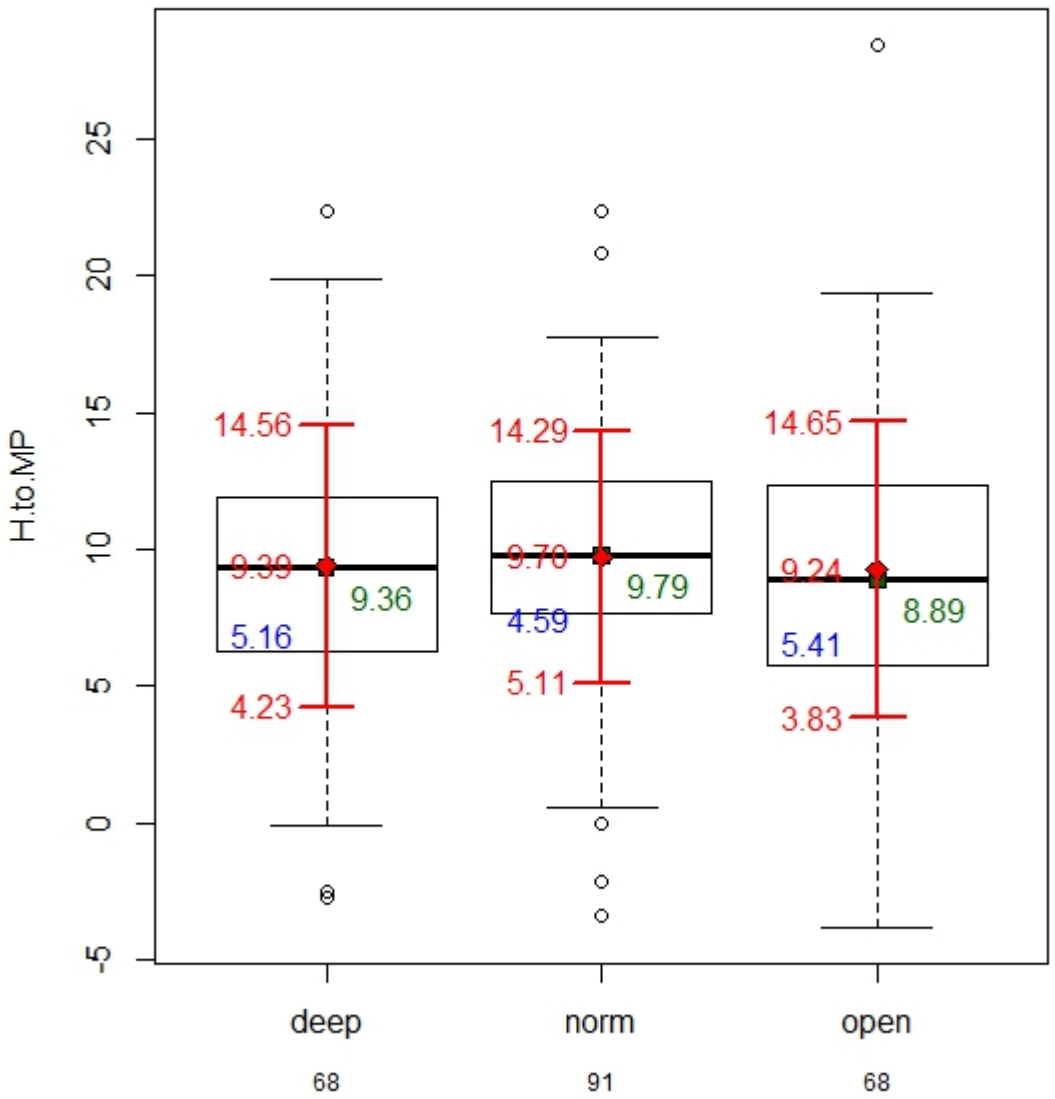

Figure 10-1. Hyoid position comparison (Overbite)

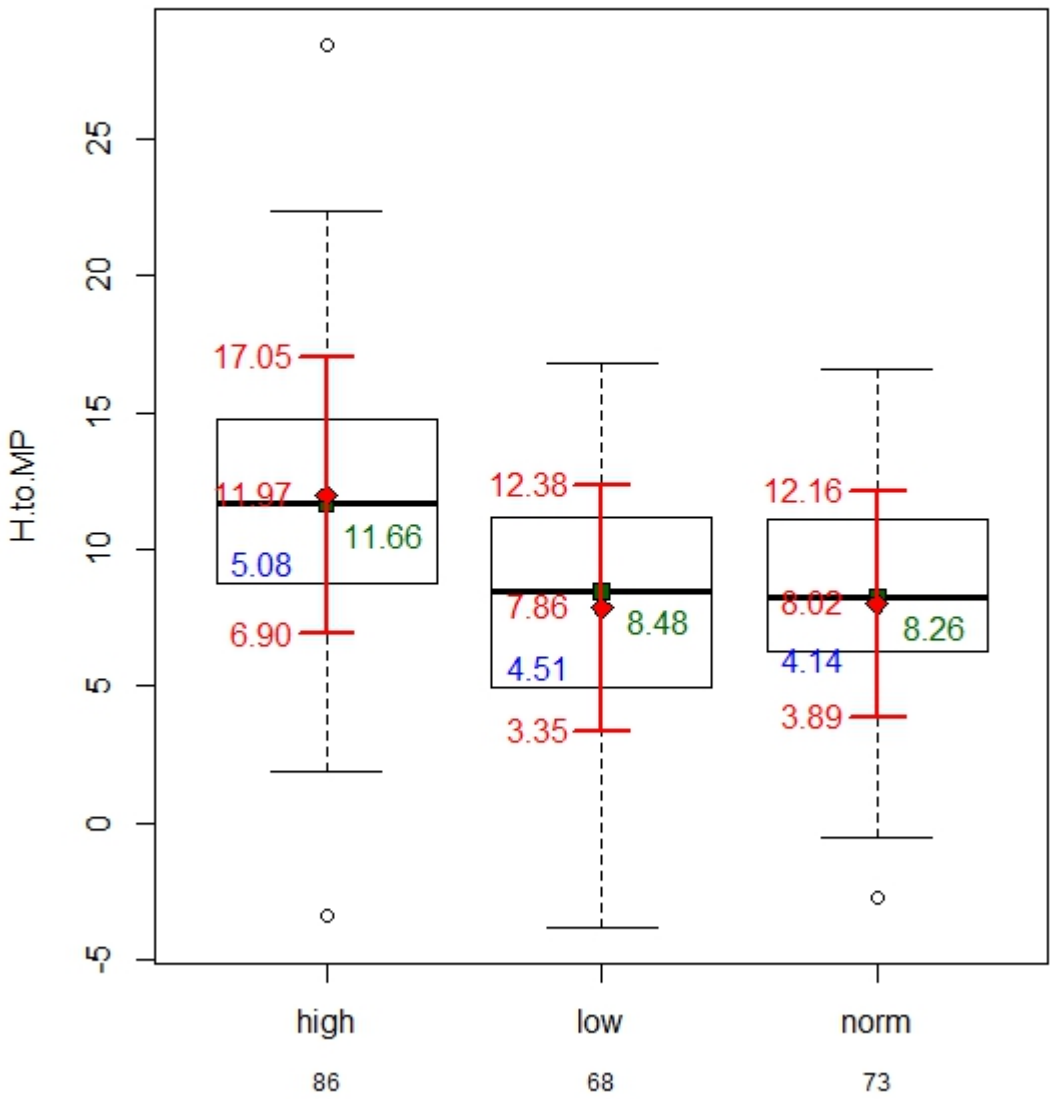

Figure 10-2. Hyoid position comparison (Vertical pattern)

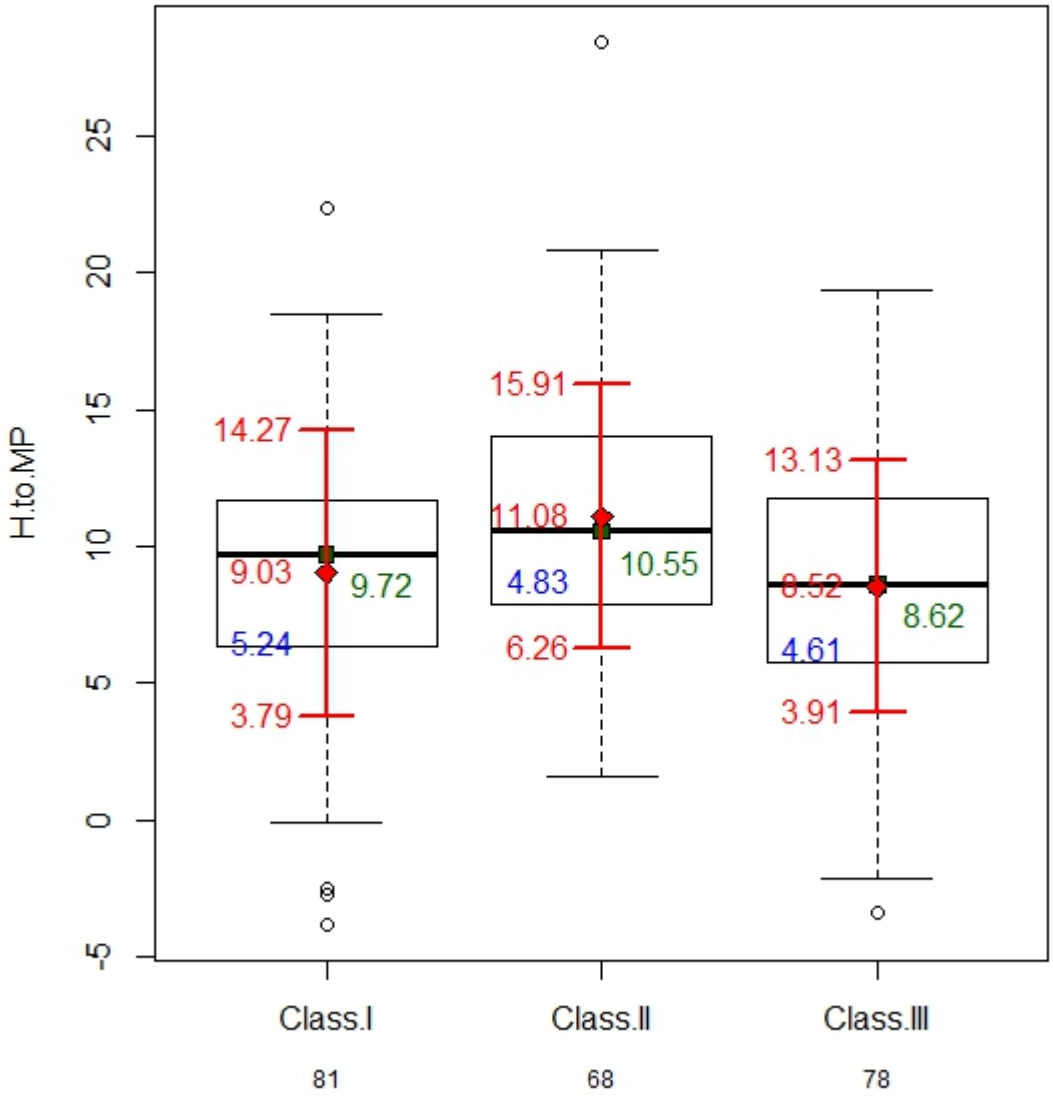

Figure 10-3. Hyoid position comparison (Skeletal Classification)

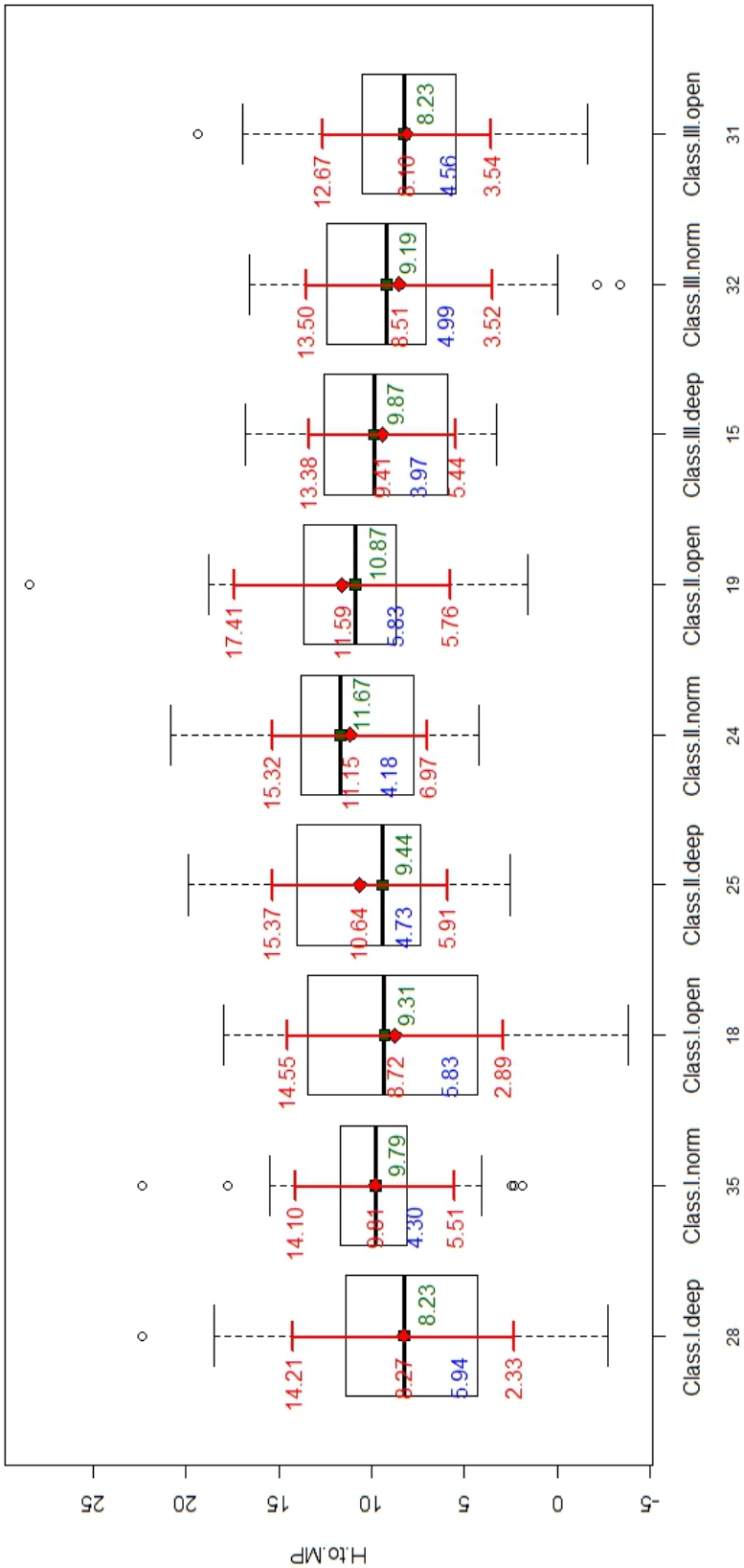

Figure 10-4. Hyoid position comparison (Overbite and Skeletal Classification)



Figure 10-5. Hyoid position comparison (Vertical and Skeletal Classification)

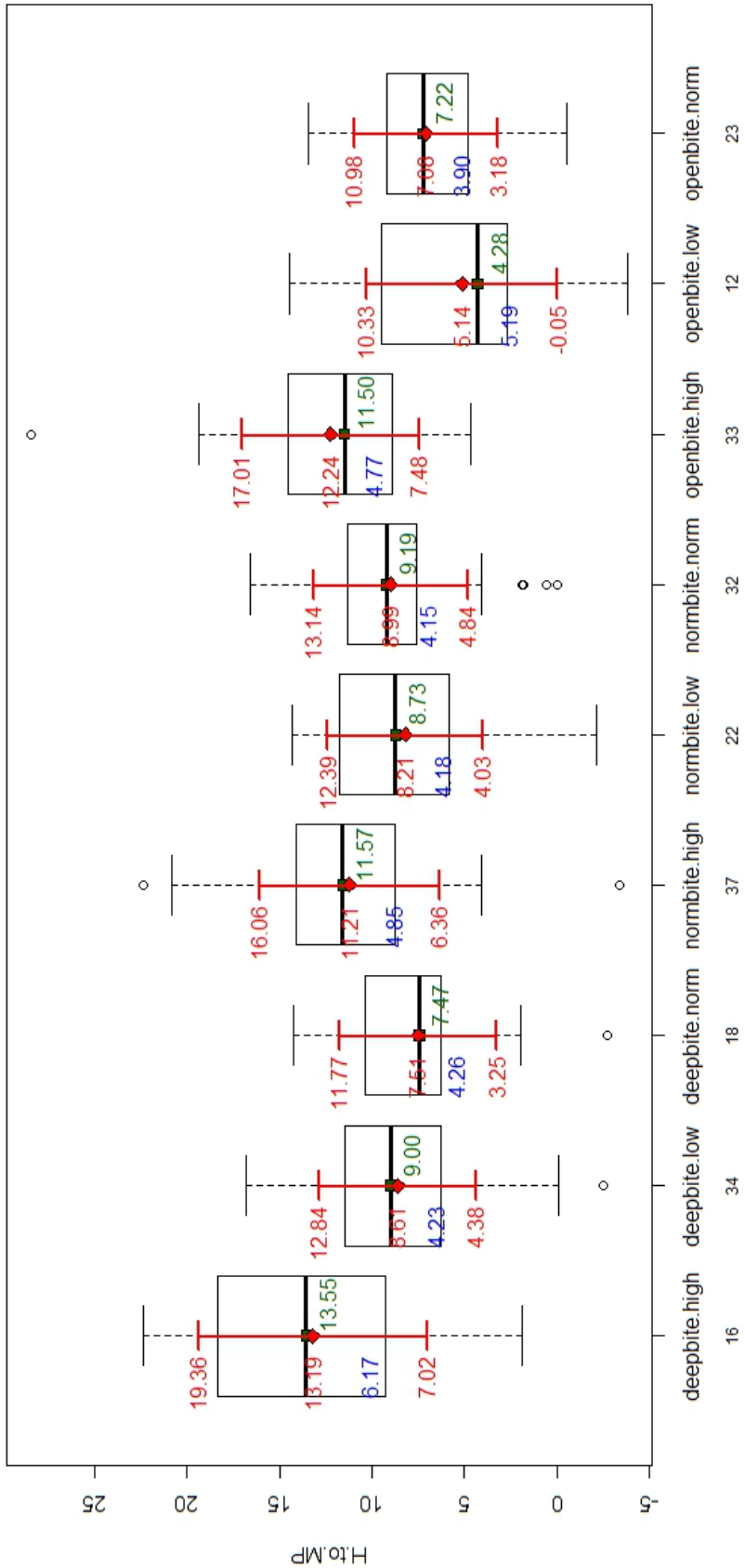

Figure 10-6. Hyoid position comparison (Vertical and Overbite)

VII. References

1. Proffit WR. Equilibrium theory revisited: factors influencing position of the teeth. Angle Orthod 1978;48:175-186.

2. Tallgren A, Solow B. Hyoid bone position, facial morphology and head posture in adults. Eur J Orthod 1987;9:1-8.

3. Haralabakis NB, Toutountzakis NM, Yiagtzis SC. The hyoid bone position in adult individuals with open bite and normal occlusion. Eur J Orthod 1993;15:265-271.

4. Subtelny JD, Sakuda M. Open-bite: Diagnosis and treatment. Am J Orthod 1964;50:337-358.

5. Hwang S, Chung CJ, Choi YJ, Huh JK, Kim KH. Changes of hyoid, tongue and pharyngeal airway after mandibular setback surgery by intraoral vertical ramus osteotomy. Angle Orthod 2010;80:302-308.

6. Karacay S, Akin E, Ortakoglu K, Bengi AO. Dynamic MRI evaluation of tongue posture and deglutitive movements in a surgically corrected open bite. Angle Orthod 2006;76:1057-1065.

7. Fujiki T, Inoue M, Miyawaki S, Nagasaki T, Tanimoto K, Takano-Yamamoto T. Relationship between maxillofacial morphology and deglutitive tongue movement in patients with anterior open bite. Am J Orthod Dentofacial Orthop 2004;125:160-167.

8. Ozbek MM, Memikoglu UT, Altug-Atac AT, Lowe AA. Stability of maxillary expansion and tongue posture. Angle Orthod 2009;79:214-220.

9. Wang Q, Jia P, Anderson NK, Wang L, Lin J. Changes of pharyngeal airway size and hyoid bone position following orthodontic treatment of Class I bimaxillary protrusion. Angle Orthod 2012;82:115-121.

10. Vieira BB, Itikawa CE, de Almeida LA, Sander HS, Fernandes RM, Anselmo-Lima WT et al. Cephalometric evaluation of facial pattern and hyoid bone position in children with obstructive sleep apnea syndrome. Int J Pediatr Otorhinolaryngol 2011;75:383-386.

11. Phoenix A, Valiathan M, Nelson S, Strohl KP, Hans M. Changes in hyoid bone position following rapid maxillary expansion in adolescents. Angle Orthod 2011;81:632-638.

12. Bibby RE. The hyoid bone position in mouth breathers and tongue-thrusters. Am J Orthod 1984;85:431-433.
13. Opdebeeck H, Bell WH, Eisenfeld J, Mishelevich D. Comparative study between the SFS and LFS rotation as a possible morphogenic mechanism. Am J Orthod 1978;74;509-521
14. Andersen WS, The relation of the tongue-thrust syndrome to maturation and other findings. Am J Orthod 1963;49;264-275
15. Adamidis IP, Spyropoulos MN. Hyoid bone position and orientation in Class I and Class III malocclusions. Am J Orthod Dentofacial Orthop 1992;101:308-312
16. Grant LE, A radiographic study of hyoid bone position in Angle's Class I, II and III malocclusions. Master's Thesis 1959(University of Kansas)
17. Graber LW. Hyoid changes following orthopedic treatment of mandibular prognathism. Angle Orthod 1978;48:33-38.
18. King EW. A roentgenographic study of pharyngeal growth. Angle Orthod. 1952;22:23.
19. Stepovich ML. A cephalometric positional study of the hyoid bone. Am J Orthod 1965;51:882-900
20. Chaves TC, de Andrade e Silva TS, Monteiro SA, Watanabe PC, Oliveira AS, Grossi DB. Craniocervical posture and hyoid bone position in children with mild and moderate asthma and mouth breathing. Int J Pediatr Otorhinolaryngol 2010;74:1021-1027.
21. Kim TW. Cephalometric appraisal of the open-bite cases with the degenerative joint disease of the temporomandibular joint. Korean J Orthod 1993;23;455-474
22. Byun ES, Ahn SJ, Kim TW. Relationship between internal derangement of the temporomandibular joint and dentofacial morphology in women with anterior open bite. Am J Orthod Dentofacial Orthop 2005;128:87-95
23. Kim TW. Cephalometric characteristics of open-bite cases with degenerative joint disease(DJD) of TMJ. Korean J Orthod 1995;25;665-674
24. Ahn SJ, Kim TW, Nahm DS. Cephalometric keys to internal derangement of temporomandibular joint in women with Class II malocclusions. Am J Orthod Dentofacial Orthop 2004;126:485-493.

국문초록

성인여성 환자에서 혀, 설골위치와 두부규격방사선 계측치들 간의 상관분석

서울대학교 대학원 치의과학과 치과교정학 전공
정 석 기

(지도교수 : 김 태 우)

1. 목적

많은 이전의 연구들에도 불구하고 장안모, 개방교합과 혀, 설골 위치와의 관계는 불분명한 것으로 보인다. 본 연구의 목적은 장안모, 개방교합을 가진 환자들이 낮은 혀와 설골 위치를 가지는지 여부를 알아보고자 하며, 여러 두부규격방사선 계측치들 중 혀, 설골위치와 상관도가 높은 변수가 무엇인지 찾고자 한다.

2. 방법

총 227명의 18세 이상의 성인 여성 환자들을 대상으로 실험을 진행하였다. 촬영된 두부규격방사선 사진을 토대로 수개의 기준점과 계측치들을 설정하였으며 특히 혀의 위치를 나타내기 위해서 혀의 배면에서부터 구개평면까지 가장 가까운 거리를 사용하였으며, 설골의 위치를 나타내기 위해서 설골점에서 하악평면까지의 가장 가까운 거리를 사용하였다. 표본은 3개의 범주로 각 3그룹으로 나누었다. 첫번째 범주는 피개교합을 토대로 나누었으며 개방교합군, 중간교합군, 심피개교합군으로 나누었다. 두번째 범주는 수직성장양상을 토대로 나누었으며 수직성장군, 정상성장군, 수평성장군으로 나누었다. 세번째 범주는 골격적 수평분류법을 토대로 나누었으며 1급, 2급, 3급으로 나누었다. 각 그룹간의 혀, 설골위치의 차이여부를 알아보기 위해 ANOVA test를 사용하여 조사하였다. 혀, 설골 위치와 두부규격방사선 계측치들간의 상관계수 조사를 위해 Pearson's correlation test가 실시되었다.

3. 결과

피개교합을 토대로 나눈 그룹간 비교에서는 혀, 설골위치의 통계적 유의미한 차이가 그룹간에 보이지 않았다. 그러나 수직성장양상을 토대로 나눈 그룹간 비교에서는 수직성장군에서의 혀의 위치가 수평성장군에서보다 유의미하게 낮게 나타났으며 수직성장군에서의 설골의 위치가 다른 두군에서보다 유의미하게 낮게 나타났다. 골격적 수평분류법을 토대로 나눈 그룹간 비교에서는 혀의 위치는 그룹간 차이가 없었으나 설골의 위치는 2급 부정교합에서 다른 두 그룹보다 낮게 나타났다. 상관계수 분석결과 혀의 위치와 밀접한 상관도를 보이는 계측치는 전안모고경, 상악중절치노출도, 안모길이로 나타났으며 설골의 위치와 밀접한 상관도를 보이는 계측치는 하악지길이, 후안모고경, 하악평면각으로 나타났다.

주요어 : 혀, 설골, 개방교합, 장안모.
학번 : 2012-21827