의학석사 학위논문

거대지 환아에서 골단유합술의 정량적인 추적결과

Quantitative results of epiphysiodesis in young children with macrodactyly

2015년 10월

서울대학교 대학원

의학과 석사과정

2005-22348

정 재 훈

Abstract

Background: Macrodactyly is a very rare congenital anomaly of single or multiple digits of the hands or feet involving bone and all soft tissue components. A treatment protocol has not been elucidated due to its rarity and variety of clinical manifestation. Moreover, there is a paucity of quantitative data regarding postoperative results in the long-term follow-up.

Methods: A retrospective chart review was performed for 13 patients with isolated macrodactyly who were treated with epiphysiodesis at our institution over a 15-year period. The relative size of macrodactyly was estimated by calculating the length and diameter of the involved digit compared with those of their normal counterpart on radiology. The relative size of each phalanx was measured preoperatively and postoperatively at 6 months, 1 year, 2 years, and in the long-term (7.63 years on average [range, 3.5–15 years]). The preoperative clinical feature of macrodactyly and the effect of epiphysiodesis on growth were investigated.

Results: Among 13 patients, there were 2 boys and 11 girls. Feet were more frequently involved (8 cases) than the hands (5 cases). The mean age at the first epiphysiodesis procedure was 4.23 years (range, 1–11 years). The mean follow-up period was 5.38 years (range, 1–16 years). Preoperatively, the relative size of the affected digit increased from the metacarpal/metatarsal bone to the distal phalanx in both length and diameter. Epiphysiodesis effectively regulated longitudinal growth from 6 months postoperatively to the long-term follow-up, but it did not control appositional growth. Compared with the preoperative state, the relative length of the operated phalanges decreased to 0.9267 at 6 months (p = 0.0476), 0.8916 at 1 year (p = 0.0048), 0.8688 at 2 years (p = 0.0018), and 0.8353 at the long-term follow-up (p = 0.0006).

Conclusions: Epiphysiodesis is an effective surgical method to control longitudinal growth of macrodactyly in young patients when growth potential remains. This information may

assist hand surgeons in determining the treatment plan and providing counseling to patients.

Key words: Macrodactyly, growth plate, bone development, long-term care, quantitative evaluation

Level of Evidence: Therapeutic Level I

Index

Introduction

Macrodactyly is a very rare congenital overgrowth disorder, accounting for 0.5–0.9% of all congenital hand abnormalities[1, 2]. Unlike secondary hypertrophy of the digits by a neoplastic lesion, macrodactyly is characterized by hyperplasia of all the elements of the affected digits. Macrodactyly should also be distinguished from tissue overgrowth associated with syndromic conditions such as the Proteus syndrome, Klippel-Trenaunay syndrome, or Sturge-Weber syndrome[3-6]. Therefore, although there has been confusion in nomenclature, true macrodactyly can be defined as isolated congenital overgrowth of the digit(s) involving all the elements unrelated to syndromic or neoplastic conditions[7].

Treatment for macrodactyly can be roughly categorized according to the patients' growth potential. In fully developed macrodactyly of older children or adults, the operation methods should be individualized according to their clinical state. They include soft tissue debulking, ostectomy, joint fusion, size-reducing procedures, or amputation. However, the rarity in incidence and variability in clinical features preclude a standard surgical protocol[8, 9].

However, in younger children with remnant growth capability, epiphysiodesis can be a good surgical option to control longitudinal growth. It is less invasive and technically easy to perform. Effective regulations of longitudinal growth in patients with macrodactyly by epiphysiodesis have been presented in previous articles[7, 10, 11]. However, the small-size clinical trials lack quantitative data, including long-term results.

In the present report, we discuss our clinical experiences of epiphysiodesis in younger children with macrodactyly. The preoperative state of macrodactyly and postoperative outcomes will be presented by quantitative analysis of the long-term follow-up. This information may assist hand surgeons in determining treatment plans and providing

counseling to patients or their guardians regarding the postoperative course.

Materials and methods

Between January 2000 and June 2015, 13 patients with macrodactyly underwent epiphysiodesis to control bone growth at our department. A single surgeon (K.S.T.) performed the operation on all the patients. The patients' medical records were reviewed for data, including sex, the affected site, age at operation, growth pattern (progressive versus static), treatment details, any complications, and the follow-up duration. This retrospective review was performed after obtaining approval from the institutional review board (IRB number: H-1507-103-689).

The preoperative state of the affected digits was investigated through gross physical examination and radiologic analysis. The length and diameter of the involved digit was measured on anteroposterior radiographs, and they were expressed as a relative ratio compared with their normal counterparts (fig. 1). First, we analyzed the preoperative length and diameter of each phalanx of the affected fingers or toes. After epiphysiodesis, we followed the patients' postoperative outcomes sequentially at 6 months, 1 year, and 2 years and at a long-term period, which on average, was 7.63 years (range, 3.5–15 years). Long-term results were acquired at the latest visit or just before any secondary surgery that could influence the outcome of primary epiphysiodesis. We also analyzed any differences in the postoperative results that may exist between the progressive and static type or between hands and feet. Progressive and static types were categorized based on their clinical manifestations and the rate of growth after birth [12, 13].

Our mean follow-up period of 5.38 years was measured from the date of epiphysiodesis to

that of the last follow-up or just before the secondary operation.

Surgical procedure

The phalanges to be treated were decided according to the severity in clinical manifestations. We tried to perform epiphysiodesis on at least 2 sites that were severely involved compared with normal counterpart. The least affected phalanges were spared to preserve as much range of motion as possible. A longitudinal incision was made on the dorsal side of the target epiphyseal plate. After subcutaneous dissection, the extensor tendon was retracted. The periosteum was elevated to expose the epiphysis under direct vision. The physis was ablated using an oscillating saw and osteotome. In some cases, electrocautery was also used. A Kirschner wire was inserted through the length of the phalanx to cross the epiphysis and joint. The periosteum was repaired with 4-0 Ethibond (Ethicon, Somerville, NJ, USA), and the skin was repaired with 5-0 Vicryl Rapide (Ethicon, Somerville, NJ, USA). Kirschner wires were removed around 6 weeks postoperatively when bone union was confirmed on radiographs. Concomitant soft tissue debulking was usually performed on the side of the digit that was more severely involved. The skin, abundant fibrofatty structure, and perineural tissue were stripped meticulously, paying attention not to injure the digital nerve itself.

Statistical analysis

Statistical analysis was performed using the SAS® program (version 9.2; SAS Institute Inc., Cary, NC, USA). A mixed-model method was adopted to assess the preoperative state of the involved digit between the phalanges, and it was used to investigate postoperative changes at five time points in terms of three independent variables: the treated phalanges (proximal

versus middle versus distal), growth types (progressive versus static), and affected area (hand versus foot). Hochberg's estimation was used for post-hoc analysis with an adjusted p-value. P-values <0.05 were considered statistically significant.

Source of Funding

There are no sources of funding to declare.

Results

Two male and 11 female patients were included in the present study. The mean age at the first epiphysiodesis procedure was 4.23 years (range, 1–11 years). Of 13 patients, there were 5 cases of hand involvement and 8 cases of foot involvement. The right side was affected in 7 and the left side was affected in 6, without any bilateral involvement. In 3 patients, >1 digit was involved. The lesions were distributed in the median nerve territory in all cases. A progressive growth pattern was found in 6 cases, and the other 7 cases showed a static growth pattern. Secondary epiphysiodesis was performed in 4 patients at 2.3 years (range, 1–7 years) after the first epiphysiodesis. Of 4 patients who underwent secondary procedure, 3 had the progressive type and 1 had the static type. There was no case of specific complications such as wound infection, dehiscence, and nonunion. The mean follow-up period was 5.38 years (range, 1–16 years). Detailed information about the clinical and surgical characteristics is summarized in Table 1.

Preoperative state of macrodactyly

The relative size of each phalanx in macrodactyly tended to increase from the proximal to the distal phalanx in both the length and diameter (fig. 2). The ratio of the length in the affected digits compared to their normal opposites was measured as follows: 1.08 ± 0.09 in the metacarpal/metatarsal (MC/T), 1.20 ± 0.14 in the proximal phalanx (PP), 1.38 ± 0.3 in the middle phalanx (MP), and 1.69 ± 0.49 in the distal phalanx (DP). Although we could not find any statistical significance between the PP and MC/T ($p = 0.0965$), the MP ($p = 0.0008$) and DP ($p < 0.0001$) showed a significantly increased value compared with the MC/T. Also, the distal phalanx was more severely involved than the PP ($p < 0.0001$) and MP ($p = 0.0073$). We also found a significant tendency in the relative length from the proximal to distal phalanx to increase ($p < 0.0001$).

The relative diameter of the affected digits measured with the same method was 1.12 ± 0.1 for the MC/T, 1.32 ± 0.17 for the PP, 1.22 ± 0.22 for the MP, and 1.53 ± 0.42 for the DP. We found that the PP ($p = 0.0065$) and DP ($p < 0.0001$) were more severely involved in the diameter compared with the MC/T, but there was no statistical difference between the MP and MC/T ($p = 0.1102$), or the MP and PP ($p = 0.2472$). The distal phalanx was more severely involved than the PP ($p < 0.0317$) and MP ($p = 0.0025$). There was also a significant tendency for the relative diameter from the proximal to distal phalanx to increase ($p < 0.0001$).

Postoperative outcome after epiphysiodesis

We found a significant decrease in the relative length when evaluating the postoperative results of epiphysiodesis ($p = 0.0023$) (fig. 3). Compared with the preoperative state, the relative length of the treated phalanx decreased postoperatively to 0.9267 at 6 months ($p = 0.0476$), 0.8916 at 1 year ($p = 0.0048$), 0.8688 at 2 years ($p = 0.0018$), and 0.8353 at the long-term follow-up ($p = 0.0006$). A difference was also found between 6 months and the long-

term follow-up (p = 0.0361), but we could not find any significant difference between the two time points after 1 year postoperatively.

The effects of independent variables on the length, DP, and progressive type showed an increased length throughout the follow-up period, although they showed a similar response to epiphysiodesis. Specifically, the postoperative outcome of the DP was 1.2657 compared with the PP (p < 0.0001), and that of the progressive type was 1.1348 compared with the static type (p = 0.0237) (fig. 4). However, we could not find any difference between the hand and feet (p = 0.8424).

Regarding the diameter, however, there was no evidence that epiphysiodesis effects appositional growth during the follow-up period (fig. 3). Compared with the preoperative state, the postoperative relative diameter was 1.0406 at 6 months (p = 0.2918), 1.1307 at 1 year (p = 0.0029), 1.0378 at 2 years (p = 0.4103), and 1.0680 at the long-term follow-up (p = 0.2831).

The effect of independent variables on the diameter showed that the DP increased to 1.1661 compared with the PP (p = 0.0007), but there was no difference between the progressive and static type (p = 0.1772), or between the hands and feet (p = 0.1141).

Case 1 (patient 4)

A 5-year-old girl visited our department for her huge left second finger. Epiphysiodesis was performed on the proximal and middle phalanxes using an oscillating saw and osteotome. After 2.5 years from the first operation, the epiphyseal plate of the distal phalanx was removed with the same method. Additional debulking surgery was performed on the volar side of the affected finger 5 years after the first operation. Longitudinal growth was

sufficiently regulated during the long-term follow-up, although an additional surgical procedure was required to reduce the diameter of the digits (fig. 5). There was no complication related with surgery. We could not find any impairment in joint movement or evidence of arthritis.

Case 2 (patient 11)

A 4-year-old female patient suffered from a large right second toe. Simultaneous epiphysiodesis was performed on her proximal, middle, and distal phalanxes. Longitudinal growth was controlled properly, but she felt discomfort when wearing shoes. When she became 7 years old, additional vertical osteotomy was performed on the fibular side of the phalanx, taking care not to injure the joints. During the long-term follow-up of 11 years, satisfactory results were obtained in both the functional and aesthetical aspects without significant complications (fig 6).

Discussion

Macrodactyly, an isolated congenital overgrowth of the hand or foot, is devastating for patients and a challenging condition for surgeons. The clinical features of affected digits encompass a wide range of phenotypes among individuals and have bizarre manifestation of enlargement and/or angulation unrelated to the anatomical unit. The etiology is not fully understood, but hypertrophied digital nerves are thought to be the leading cause of macrodactyly [14, 15]. Efforts have been made to classify macrodactyly according to its growth pattern. The progressive type shows a rapid growth rate, whereas the static type displays proportionate growth[12, 13]. Although this is an imperfect classification based on the clinical

observation without definite biological justification, this information can assist in assessing the patient's clinical course and determining the treatment strategy. The treatment plan is decided considering the severity and remnant growth potential of the affected digits. However, the rarity of incidence and variability in clinical features of macrodactyly preclude long-term quantitative data. Most studies are case reports that describe the best surgical methods specific for each individual's condition. In the present study, we performed epiphysiodesis in patients with macrodactyly and growth potential, and investigated postoperative growth in terms of the longitudinal and appositional growth. To the best of our knowledge, no other article has analyzed the effect of epiphysiodesis in macrodactyly with quantitative data in over a long-term follow-up.

Patients with true macrodactyly present with hyperplasia of all the tissue elements of the affected digits, including the phalanges, tendons, skin, subcutaneous fat, nerves, and vessels. Interestingly, we observed that phalanges became more severely affected when they were closer to the distal end. Hypertrophy of the distal phalanx was marked, but metacarpal involvement was not apparent. This is compatible with the observation in previous studies[7, 8, 12]. However, disagreement still exists in the involvement up to the metacarpal or metatarsal bone in cases of macrodactyly. Barsky reported no metacarpal involvement in his pioneering study[12]. Following clinical studies showed metacarpal involvement in most patients, although it did not appear marked on radiographic findings[7, 8, 16-18]. Our data also showed an increased ratio of the length (1.08 ± 0.09) and diameter (1.12 ± 0.1) of the metacarpal/metatarsal bone compared with its normal counterpart.

The successful regulation of longitudinal growth in the present study may be because disproportionate growth of the affected digit was slowed and a proportional relationship was anticipated compared with its normal counterpart. However, consensus on the effectiveness

of epiphysiodesis in macrodactyly has not yet been fully established. Ishida performed epiphysiodesis in 4 macrodactyly patients, and he prevented longitudinal overgrowth effectively without additional surgery[10]. Topoleski et al. presented satisfactory results of proximal phalangeal epiphysiodesis in regulating macrodactyly of the foot[11]. In contrast, Tsuge doubted that epiphyseal plate destruction alone is insufficient to control longitudinal growth[8]. Our data showed good results in each treated phalanx itself on radiography in both progressive and static type, but hypertrophy of all the soft tissue triggered by the digital nerve or compensatory growth of the MC/T can diminish the effect of epiphysiodesis[8, 11]. Detailed studies seem to be needed to elucidate contributing factors to the growth of macrodactyly.

As we anticipated, the diameter of the affected digit was not influenced by epiphyseal plate arrest. However, there was a significant increase in diameter at 1 year postoperatively (fig. 3). It is difficult to determine a proper reason for this, but Topoleski et al. also experienced widening of the metaphysis when performing epiphysiodesis in toe macrodactyly. They thought that it was due to iatrogenic periosteal stripping during open epiphysiodesis[11]. Hernandez et al. described similar results from an animal study, and they attributed it to decreased osteoclastic activity[19]. The detailed mechanism for this phenomenon should be investigated in a future study.

The distal phalanx showed a relatively bigger size in both the length and diameter compared with other phalanges. This tendency was maintained throughout the postoperative course, although no difference was found in the reaction to epiphysiodesis between the phalanges. Epiphyseal plate arrest seems to be insufficient, and the size-reducing procedure is required to correct distal phalangeal deformities, including arthrodesis, or downsizing the nail matrix[8, 12, 20].

Similarly, we found a significant increase in the length of the progressive type of

macrodactyly compared with that of the static type, although our data showed no statistical difference in the effect of epiphysiodesis between the progressive and static types during the postoperative course. This may explain why the progressive type accounted for 3 of 4 cases of secondary epiphysiodesis. Although the treatment principles are not different, most hand surgeons modify surgical plans according to the growth pattern of macrodactyly. Patients with the progressive type undergo operation earlier[20] and more frequently[7, 21], and they even undergo aggressive methods such as amputation[12, 20]. Kim et al reported a measureable foot size reduction and excellent functional results using ray amputation in foot macrodactyly[18].

This study has limitations in that the data were collected from a small number of patients in a retrospective manner. To evaluate the effect of epiphysiodesis, we selected data from patients with macrodactyly who underwent epiphysiodesis as a first step. Therefore, our data are subject to selection bias, as relatively less severe cases were included. In addition, the follow-up period was inevitably limited by the secondary operation, which could have directly influenced the growth of macrodactyly. Our mean follow-up period of 5.38 years was measured from the date of epiphysiodesis to that of the last follow-up or just before the secondary operation. No objective functional analysis was performed, but we have not experienced significant functional impairment through epiphysiodesis. The major strength of this study was that we performed quantitative analysis of the long-term follow-up. Size-reducing procedures are usually individualized according to the phenotypic variability, but epiphysiodesis does not differ much among individuals. Our observation clearly showed that epiphysiodesis effectively regulated longitudinal growth from 6 months postoperatively, and suggested that the probability of additional surgical procedure is increased in the distal phalanx or in the progressive type of macrodactyly.

In conclusion, epiphysiodesis is a promising, minimally invasive approach for regulating the

longitudinal growth of macrodactyly when growth potential remains. Objective functional analysis and contributing factors that can influence the growth of macrodactyly other than epiphysis should be investigated in the future in a large prospective study.

References

1. Leung PC, Chan KM, Cheng JC. Congenital anomalies of the upper limb among the Chinese population in Hong Kong. J Hand Surg Am 1982: 7: 563-5.

2. A. F. The Care of Congenital Hand Anomalies. In 2nd edition ed. St. Louis: Quality Medical 1994.

3. Biesecker LG, Happle R, Mulliken JB, et al. Proteus syndrome: diagnostic criteria, differential diagnosis, and patient evaluation. Am J Med Genet 1999: 84: 389-95.

4. Wiedemann HR, Burgio GR, Aldenhoff P, et al. The proteus syndrome. Partial gigantism of the hands and/or feet, nevi, hemihypertrophy, subcutaneous tumors, macrocephaly or other skull anomalies and possible accelerated growth and visceral affections. Eur J Pediatr 1983: 140: 5-12.

5. McGrory BJ, Amadio PC, Dobyns JH, Stickler GB, Unni KK. Anomalies of the fingers and toes associated with Klippel-Trenaunay syndrome. J Bone Joint Surg Am 1991: 73: 1537-46.

6. Greene AK, Taber SF, Ball KL, Padwa BL, Mulliken JB. Sturge-Weber syndrome: soft-tissue and skeletal overgrowth. J Craniofac Surg 2009: 20 Suppl 1: 617-21.

7. Cerrato F, Eberlin KR, Waters P, et al. Presentation and treatment of macrodactyly in children. J Hand Surg Am 2013: 38: 2112-23.

8. Tsuge K. Treatment of macrodactyly. J Hand Surg Am 1985: 10: 968-9.

9. VE W. Macrodactyly. 4th ed. New York: Churchill Livingstone, 2001.

10. Ishida O, Ikuta Y. Long-term results of surgical treatment for macrodactyly of the hand. Plast Reconstr Surg 1998: 102: 1586-90.

11. Topoleski TA, Ganel A, Grogan DP. Effect of proximal phalangeal epiphysiodesis in the treatment of macrodactyly. Foot Ankle Int 1997: 18: 500-3.

12. Barsky AJ. Macrodactyly. J Bone Joint Surg Am 1967: 49: 1255-66.

13. De Laurenzi V. [Macrodactyly of the middle finger]. G Med Mil 1962: 112: 401-5.

14. Murphey MD, Smith WS, Smith SE, Kransdorf MJ, Temple HT. From the archives of the AFIP. Imaging of musculoskeletal neurogenic tumors: radiologic-pathologic correlation. Radiographics 1999: 19: 1253-80.

15. L. M. The hand. In AH C, ed. Campbell's operative orthopaedics. 5th ed ed. St. Louis CV Mosby 1971: 282-89.

16. Dell PC. Macrodactyly. Hand Clin 1985: 1: 511-24.

17. Kalen V, Burwell DS, Omer GE. Macrodactyly of the hands and feet. J Pediatr Orthop 1988: 8: 311-5.

18. Kim J, Park JW, Hong SW, et al. Ray amputation for the treatment of foot macrodactyly in children. Bone Joint J 2015: 97-B: 1364-9.

19. Hernandez JA, Serrano S, Marinoso ML, et al. Bone growth and modeling changes induced by periosteal stripping in the rat. Clin Orthop Relat Res 1995: 211-9.

20. Gluck JS, Ezaki M. Surgical Treatment of Macrodactyly. J Hand Surg Am 2015: 40: 1461-8.

21. Hardwicke J, Khan MA, Richards H, Warner RM, Lester R. Macrodactyly - options and outcomes. J Hand Surg Eur Vol 2013: 38: 297-303.

Figure Legends

Figure 1. The length and diameter of each digit was measured on anteroposterior radiographs. (L: length, D: diameter)

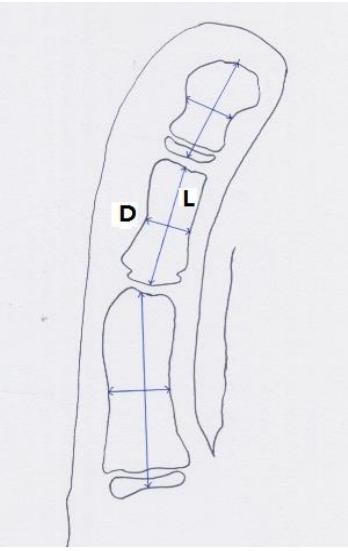

Figure 2. Preoperative state of macrodactyly calculated as the ratio of the length (left) and diameter (right) of the affected digits compared with their counterparts on the normal side. MC/T, metacarpal/metatarsal; PP, proximal phalanx; MP, middle phalanx; DP, distal phalanx.

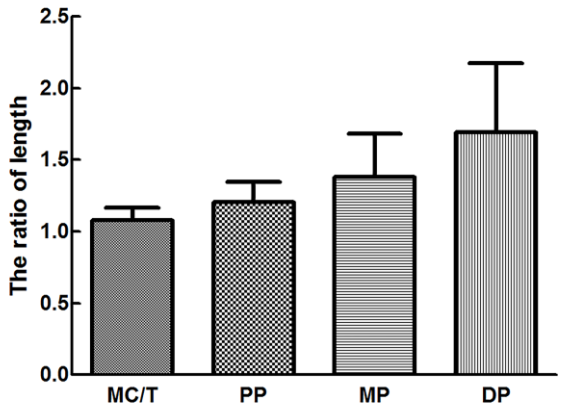

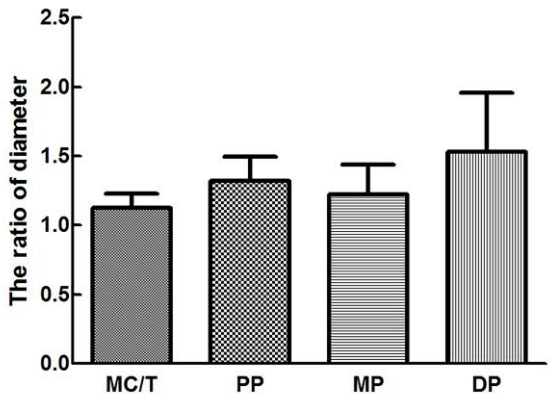

Figure 3. Graphs showing the serial change of the ratio of the length and diameter of affected digits compared with their normal counterparts for each digit. Preop, preoperatively; long-term, long-term follow-up.

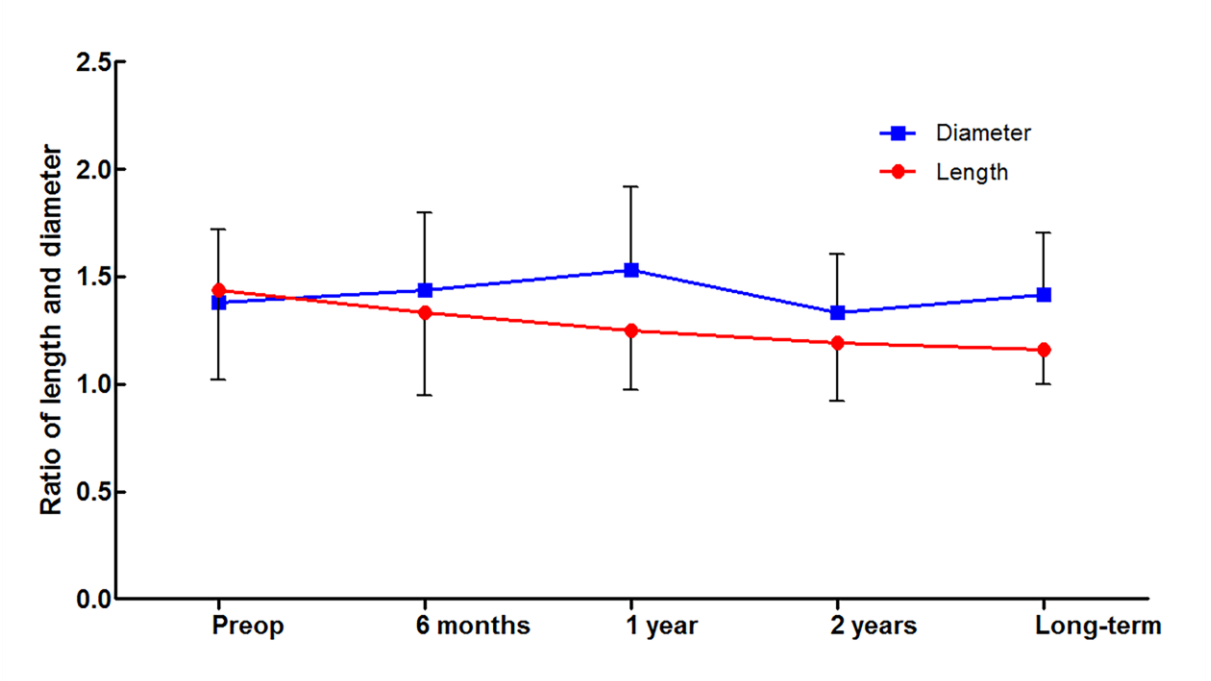

Figure 4. Graphs showing the serial change of the ratio of the length according to the clinical types of macrodactyly. There is a significant difference between the progressive and static type. Preop, preoperatively; long-term, long-term follow-up.

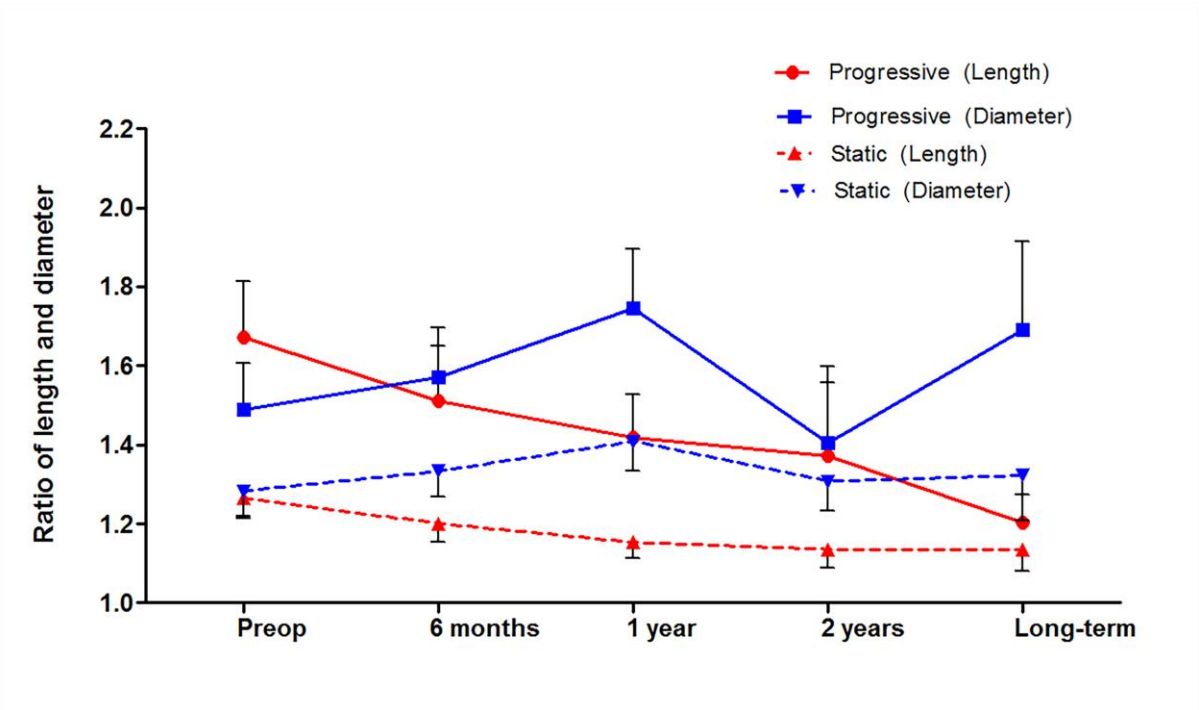

Figure 5. A 5-year-old female patient presented with macrodactyly of her left index finger. Preoperative (left upper) and 7-year postoperative (left lower) medical photographs showing good postoperative results. Radiologic images also showing good postoperative results (right lower) compared with preoperative state (right upper).

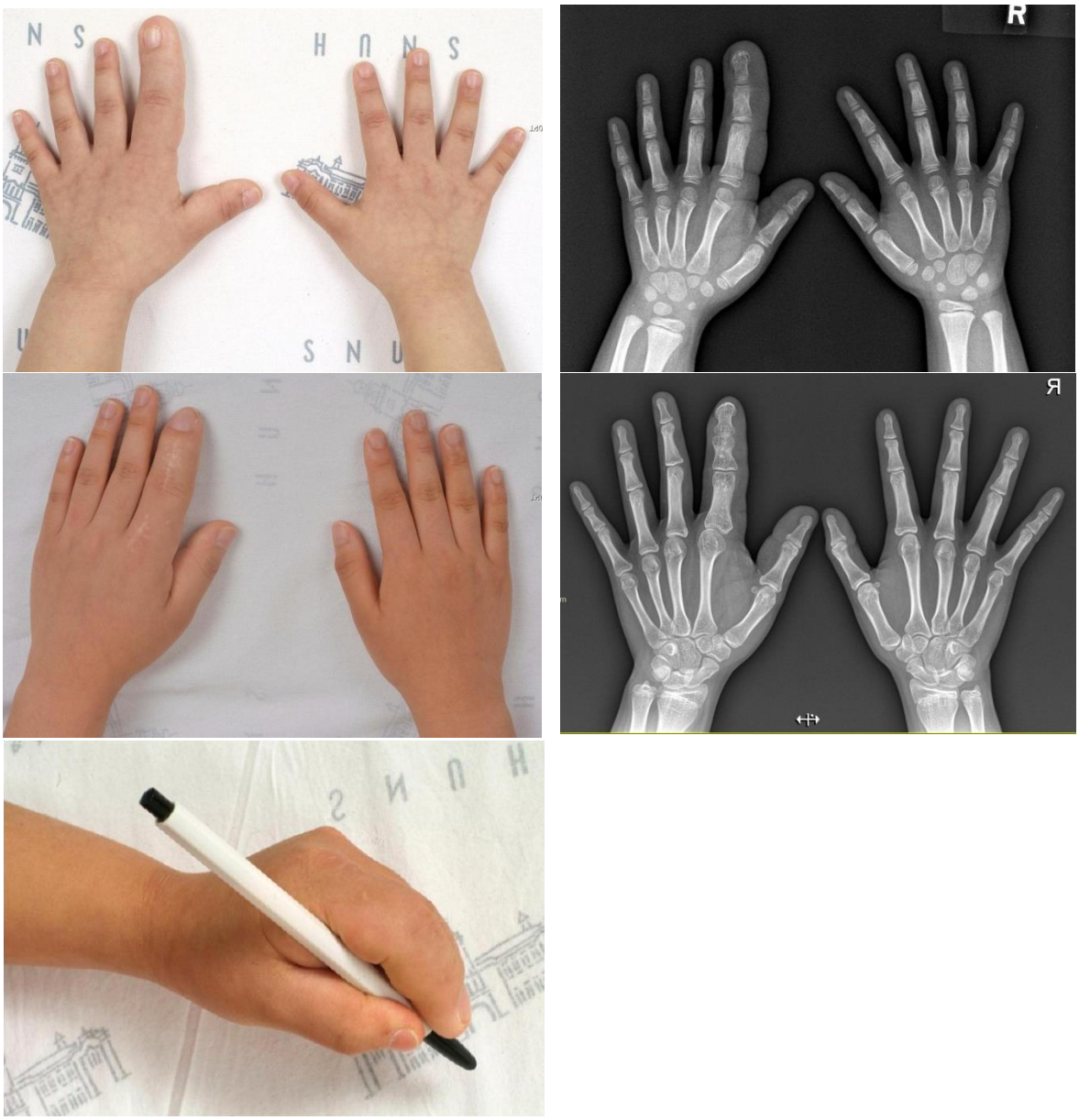

Figure 6. A 4-year-old female patient suffered from macrodactyly of her right second toe. Preoperative (left) and 11-year postoperative (right) radiologic images showing satisfactory postoperative results.

Table

Table 1. Detailed information of the patients with macrodactyly who underwent epiphysiodesis.

Patient number	**sex**	**Affected area**	**Affected site**	**Affected digits**	**Growth type**	**Number of op.**	**Epiphysiodesis, first**			**Epiphysiodesis, second**			**Follow-up period (years)**
							Digits	Age at op (years)	Accompanying operation	Digits	Age at op. (years)	Accompanying operation	
1	F	Foot	Right	2, 3	Pr	6	M(2,3)	1	Dbk, Ost (MT 2,3)	N/A	N/A	N/A	16
2	F	Foot	Left	2	St	1	P, M	5	N/A	N/A	N/A	N/A	1
3	F	Foot	Right	2	Pr	3	M, D	1	Dbk	N/A	N/A	N/A	11
4	F	Hand	Left	2	St	3	P, M	5	Dbk	D	7	Dbk	6
5	M	Foot	Left	3	Pr	2	P, M	1	Dbk, Ost (MT)	MT, D	6	Dbk	7
6	M	Hand	Left	2	St	1	M, D	6	Dbk	N/A	N/A	N/A	3
7	F	Hand	Left	1, 2	Pr	1	P, D(1)	6	Dbk, wOst (D 2)	N/A	N/A	N/A	1
8	F	Foot	Right	1, 2	Pr	3	P, D(1)	2	Dbk	MT(1)	3	Dbk, vOst (P, D 1)	4
9	F	Foot	Right	2	St	1	P, M	1	Dbk	N/A	N/A	N/A	2
10	F	Hand	Right	3	St	2	P, M, D	11	N/A	N/A	N/A	N/A	2
11	F	Foot	Right	2	St	2	P, M, D	4	N/A	N/A	N/A	N/A	11

12	F	Hand	Left	3	St	2	P, M, D	11	Dbk	N/A	N/A	N/A	5
13	F	Foot	Right	2	Pr	2	M, D	1	wOst(P, M)	P, M	2	Dbk, wOst (P)	1

Op.; operation, M; male, F; female, Pr.; progressive, St.; static, P: proximal phalanx, M: middle phalanx, D: distal phalanx, MT: metatarsal bone, Dbk: debulking, Ost: ostectomy, wOst: wedge ostectomy, vOst: vertical ostectomy, N/A: not applicable

국문초록

배경

거대지는 매우 드문 수부 및 족부의 선천성 기형으로, 골 조직 및 모든 연부조직이 침범된다. 아직까지 치료 프로토콜이 정립되어있지 않은데, 이는 거대지 자체가 매우 드물고 임상양상이 다양하게 나타나기 때문이다. 또한 수술 이후 장기 추적관찰 결과를 보여주는 정량적인 데이터 역시 거의 없는 실정이다.

재료 및 방법

최근 15년 동안 본원 성형외과에서 거대지를 주소로 내원하여 골단유합술을 시행받은 환자의 임상 데이터를 후향적으로 분석하였다. 거대지의 크기 변화를 확인하기 위해서 병변측 수지 및 족지의 길이와 직경을 X-ray 상에서 측정하여 반대측 정상 수지 및 족지의 크기에 대한 비율로 나타내었다. 이 상대적인 크기는 술 전, 수술 후 6개월, 1년, 2년, 그리고 장기추적 시기에 측정하여 거대지의 술 전 상태를 파악하고 수술 후 결과를 분석하였다.

결과

총 13명의 환자 중 2명이 남자, 11명이 여자였다. 발가락을 침범한 경우가 8례, 손가락을 침범한 경우가 5례였다. 처음 골단유합술을 시행한 연령은 평균 4.23 년 (범위, 1-11 년)으로 측정되었다. 평균 추적관찰 기간은 5.38년 (범위, 1-16년)이었다. 거대지의 수술 전 상태를 보면 길이와 직경 모두 반대 정상측에 비해 근위부에서 원위부로 갈 수록 심하게 이환된 것을 확인할 수 있었다. 골단 유합술을 시행한 이후에는 효과적으로 병변 부위의 길이 성장이 조절되는 것을 확인할 수 있었으나 넓이 성장에는 유의한 결과가 없었다. 수술 전과 비교하였을 때 골단 유합술을 받은 지골의 크기는 수술 후 6개월에 0.9267 (p = 0.0476), 술 후 1년에 0.8916 (p = 0.0048), 술 후 2년에 0.8688

(p = 0.0018), 그리고 장기 추적관찰에서 0.8353으로 (p = 0.0006)모두 통계적인 유의하게 성장이 저해됨을 확인할 수 있었다.

결론

골단유합술은 성장 잠재력이 남아있는 어린 거대지 환아에서 길이 성장을 조절할 수 있는 효과적인 수술 방법이다. 이번 연구를 통해 얻어진 정보는 수부외과의가 수술 방향을 설정하거나 환자에게 상담할 때 도움을 줄 수 있을 것이다.

Key words: 골단유합술, 거대지, 길이성장, 정량분석

의학석사 학위논문

거대지 환아에서 골단유합술의 정량적인 추적결과

Quantitative results of epiphysiodesis in young children with macrodactyly

2015년 10월

서울대학교 대학원

의학과 석사과정

2005-22348

정 재 훈

Abstract

Background: Macrodactyly is a very rare congenital anomaly of single or multiple digits of the hands or feet involving bone and all soft tissue components. A treatment protocol has not been elucidated due to its rarity and variety of clinical manifestation. Moreover, there is a paucity of quantitative data regarding postoperative results in the long-term follow-up.

Methods: A retrospective chart review was performed for 13 patients with isolated macrodactyly who were treated with epiphysiodesis at our institution over a 15-year period. The relative size of macrodactyly was estimated by calculating the length and diameter of the involved digit compared with those of their normal counterpart on radiology. The relative size of each phalanx was measured preoperatively and postoperatively at 6 months, 1 year, 2 years, and in the long-term (7.63 years on average [range, 3.5–15 years]). The preoperative clinical feature of macrodactyly and the effect of epiphysiodesis on growth were investigated.

Results: Among 13 patients, there were 2 boys and 11 girls. Feet were more frequently involved (8 cases) than the hands (5 cases). The mean age at the first epiphysiodesis procedure was 4.23 years (range, 1–11 years). The mean follow-up period was 5.38 years (range, 1–16 years). Preoperatively, the relative size of the affected digit increased from the metacarpal/metatarsal bone to the distal phalanx in both length and diameter. Epiphysiodesis effectively regulated longitudinal growth from 6 months postoperatively to the long-term follow-up, but it did not control appositional growth. Compared with the preoperative state, the relative length of the operated phalanges decreased to 0.9267 at 6 months (p = 0.0476), 0.8916 at 1 year (p = 0.0048), 0.8688 at 2 years (p = 0.0018), and 0.8353 at the long-term follow-up (p = 0.0006).

Conclusions: Epiphysiodesis is an effective surgical method to control longitudinal growth of macrodactyly in young patients when growth potential remains. This information may

assist hand surgeons in determining the treatment plan and providing counseling to patients.

Key words: Macrodactyly, growth plate, bone development, long-term care, quantitative evaluation

Level of Evidence: Therapeutic Level I

Index

Introduction

Macrodactyly is a very rare congenital overgrowth disorder, accounting for 0.5–0.9% of all congenital hand abnormalities[1, 2]. Unlike secondary hypertrophy of the digits by a neoplastic lesion, macrodactyly is characterized by hyperplasia of all the elements of the affected digits. Macrodactyly should also be distinguished from tissue overgrowth associated with syndromic conditions such as the Proteus syndrome, Klippel-Trenaunay syndrome, or Sturge-Weber syndrome[3-6]. Therefore, although there has been confusion in nomenclature, true macrodactyly can be defined as isolated congenital overgrowth of the digit(s) involving all the elements unrelated to syndromic or neoplastic conditions[7].

Treatment for macrodactyly can be roughly categorized according to the patients' growth potential. In fully developed macrodactyly of older children or adults, the operation methods should be individualized according to their clinical state. They include soft tissue debulking, ostectomy, joint fusion, size-reducing procedures, or amputation. However, the rarity in incidence and variability in clinical features preclude a standard surgical protocol[8, 9].

However, in younger children with remnant growth capability, epiphysiodesis can be a good surgical option to control longitudinal growth. It is less invasive and technically easy to perform. Effective regulations of longitudinal growth in patients with macrodactyly by epiphysiodesis have been presented in previous articles[7, 10, 11]. However, the small-size clinical trials lack quantitative data, including long-term results.

In the present report, we discuss our clinical experiences of epiphysiodesis in younger children with macrodactyly. The preoperative state of macrodactyly and postoperative outcomes will be presented by quantitative analysis of the long-term follow-up. This information may assist hand surgeons in determining treatment plans and providing

counseling to patients or their guardians regarding the postoperative course.

Materials and methods

Between January 2000 and June 2015, 13 patients with macrodactyly underwent epiphysiodesis to control bone growth at our department. A single surgeon (K.S.T.) performed the operation on all the patients. The patients' medical records were reviewed for data, including sex, the affected site, age at operation, growth pattern (progressive versus static), treatment details, any complications, and the follow-up duration. This retrospective review was performed after obtaining approval from the institutional review board (IRB number: H-1507-103-689).

The preoperative state of the affected digits was investigated through gross physical examination and radiologic analysis. The length and diameter of the involved digit was measured on anteroposterior radiographs, and they were expressed as a relative ratio compared with their normal counterparts (fig. 1). First, we analyzed the preoperative length and diameter of each phalanx of the affected fingers or toes. After epiphysiodesis, we followed the patients' postoperative outcomes sequentially at 6 months, 1 year, and 2 years and at a long-term period, which on average, was 7.63 years (range, 3.5–15 years). Long-term results were acquired at the latest visit or just before any secondary surgery that could influence the outcome of primary epiphysiodesis. We also analyzed any differences in the postoperative results that may exist between the progressive and static type or between hands and feet. Progressive and static types were categorized based on their clinical manifestations and the rate of growth after birth [12, 13].

Our mean follow-up period of 5.38 years was measured from the date of epiphysiodesis to

that of the last follow-up or just before the secondary operation.

Surgical procedure

The phalanges to be treated were decided according to the severity in clinical manifestations. We tried to perform epiphysiodesis on at least 2 sites that were severely involved compared with normal counterpart. The least affected phalanges were spared to preserve as much range of motion as possible. A longitudinal incision was made on the dorsal side of the target epiphyseal plate. After subcutaneous dissection, the extensor tendon was retracted. The periosteum was elevated to expose the epiphysis under direct vision. The physis was ablated using an oscillating saw and osteotome. In some cases, electrocautery was also used. A Kirschner wire was inserted through the length of the phalanx to cross the epiphysis and joint. The periosteum was repaired with 4-0 Ethibond (Ethicon, Somerville, NJ, USA), and the skin was repaired with 5-0 Vicryl Rapide (Ethicon, Somerville, NJ, USA). Kirschner wires were removed around 6 weeks postoperatively when bone union was confirmed on radiographs. Concomitant soft tissue debulking was usually performed on the side of the digit that was more severely involved. The skin, abundant fibrofatty structure, and perineural tissue were stripped meticulously, paying attention not to injure the digital nerve itself.

Statistical analysis

Statistical analysis was performed using the SAS® program (version 9.2; SAS Institute Inc., Cary, NC, USA). A mixed-model method was adopted to assess the preoperative state of the involved digit between the phalanges, and it was used to investigate postoperative changes at five time points in terms of three independent variables: the treated phalanges (proximal

versus middle versus distal), growth types (progressive versus static), and affected area (hand versus foot). Hochberg's estimation was used for post-hoc analysis with an adjusted p-value. P-values <0.05 were considered statistically significant.

Source of Funding

There are no sources of funding to declare.

Results

Two male and 11 female patients were included in the present study. The mean age at the first epiphysiodesis procedure was 4.23 years (range, 1–11 years). Of 13 patients, there were 5 cases of hand involvement and 8 cases of foot involvement. The right side was affected in 7 and the left side was affected in 6, without any bilateral involvement. In 3 patients, >1 digit was involved. The lesions were distributed in the median nerve territory in all cases. A progressive growth pattern was found in 6 cases, and the other 7 cases showed a static growth pattern. Secondary epiphysiodesis was performed in 4 patients at 2.3 years (range, 1–7 years) after the first epiphysiodesis. Of 4 patients who underwent secondary procedure, 3 had the progressive type and 1 had the static type. There was no case of specific complications such as wound infection, dehiscence, and nonunion. The mean follow-up period was 5.38 years (range, 1–16 years). Detailed information about the clinical and surgical characteristics is summarized in Table 1.

Preoperative state of macrodactyly

The relative size of each phalanx in macrodactyly tended to increase from the proximal to the distal phalanx in both the length and diameter (fig. 2). The ratio of the length in the affected digits compared to their normal opposites was measured as follows: 1.08 ± 0.09 in the metacarpal/metatarsal (MC/T), 1.20 ± 0.14 in the proximal phalanx (PP), 1.38 ± 0.3 in the middle phalanx (MP), and 1.69 ± 0.49 in the distal phalanx (DP). Although we could not find any statistical significance between the PP and MC/T ($p = 0.0965$), the MP ($p = 0.0008$) and DP ($p < 0.0001$) showed a significantly increased value compared with the MC/T. Also, the distal phalanx was more severely involved than the PP ($p < 0.0001$) and MP ($p = 0.0073$). We also found a significant tendency in the relative length from the proximal to distal phalanx to increase ($p < 0.0001$).

The relative diameter of the affected digits measured with the same method was 1.12 ± 0.1 for the MC/T, 1.32 ± 0.17 for the PP, 1.22 ± 0.22 for the MP, and 1.53 ± 0.42 for the DP. We found that the PP ($p = 0.0065$) and DP ($p < 0.0001$) were more severely involved in the diameter compared with the MC/T, but there was no statistical difference between the MP and MC/T ($p = 0.1102$), or the MP and PP ($p = 0.2472$). The distal phalanx was more severely involved than the PP ($p < 0.0317$) and MP ($p = 0.0025$). There was also a significant tendency for the relative diameter from the proximal to distal phalanx to increase ($p < 0.0001$).

Postoperative outcome after epiphysiodesis

We found a significant decrease in the relative length when evaluating the postoperative results of epiphysiodesis ($p = 0.0023$) (fig. 3). Compared with the preoperative state, the relative length of the treated phalanx decreased postoperatively to 0.9267 at 6 months ($p = 0.0476$), 0.8916 at 1 year ($p = 0.0048$), 0.8688 at 2 years ($p = 0.0018$), and 0.8353 at the long-term follow-up ($p = 0.0006$). A difference was also found between 6 months and the long-

term follow-up (p = 0.0361), but we could not find any significant difference between the two time points after 1 year postoperatively.

The effects of independent variables on the length, DP, and progressive type showed an increased length throughout the follow-up period, although they showed a similar response to epiphysiodesis. Specifically, the postoperative outcome of the DP was 1.2657 compared with the PP (p < 0.0001), and that of the progressive type was 1.1348 compared with the static type (p = 0.0237) (fig. 4). However, we could not find any difference between the hand and feet (p = 0.8424).

Regarding the diameter, however, there was no evidence that epiphysiodesis effects appositional growth during the follow-up period (fig. 3). Compared with the preoperative state, the postoperative relative diameter was 1.0406 at 6 months (p = 0.2918), 1.1307 at 1 year (p = 0.0029), 1.0378 at 2 years (p = 0.4103), and 1.0680 at the long-term follow-up (p = 0.2831).

The effect of independent variables on the diameter showed that the DP increased to 1.1661 compared with the PP (p = 0.0007), but there was no difference between the progressive and static type (p = 0.1772), or between the hands and feet (p = 0.1141).

Case 1 (patient 4)

A 5-year-old girl visited our department for her huge left second finger. Epiphysiodesis was performed on the proximal and middle phalanxes using an oscillating saw and osteotome. After 2.5 years from the first operation, the epiphyseal plate of the distal phalanx was removed with the same method. Additional debulking surgery was performed on the volar side of the affected finger 5 years after the first operation. Longitudinal growth was

sufficiently regulated during the long-term follow-up, although an additional surgical procedure was required to reduce the diameter of the digits (fig. 5). There was no complication related with surgery. We could not find any impairment in joint movement or evidence of arthritis.

Case 2 (patient 11)

A 4-year-old female patient suffered from a large right second toe. Simultaneous epiphysiodesis was performed on her proximal, middle, and distal phalanxes. Longitudinal growth was controlled properly, but she felt discomfort when wearing shoes. When she became 7 years old, additional vertical osteotomy was performed on the fibular side of the phalanx, taking care not to injure the joints. During the long-term follow-up of 11 years, satisfactory results were obtained in both the functional and aesthetical aspects without significant complications (fig 6).

Discussion

Macrodactyly, an isolated congenital overgrowth of the hand or foot, is devastating for patients and a challenging condition for surgeons. The clinical features of affected digits encompass a wide range of phenotypes among individuals and have bizarre manifestation of enlargement and/or angulation unrelated to the anatomical unit. The etiology is not fully understood, but hypertrophied digital nerves are thought to be the leading cause of macrodactyly [14, 15]. Efforts have been made to classify macrodactyly according to its growth pattern. The progressive type shows a rapid growth rate, whereas the static type displays proportionate growth[12, 13]. Although this is an imperfect classification based on the clinical

observation without definite biological justification, this information can assist in assessing the patient's clinical course and determining the treatment strategy. The treatment plan is decided considering the severity and remnant growth potential of the affected digits. However, the rarity of incidence and variability in clinical features of macrodactyly preclude long-term quantitative data. Most studies are case reports that describe the best surgical methods specific for each individual's condition. In the present study, we performed epiphysiodesis in patients with macrodactyly and growth potential, and investigated postoperative growth in terms of the longitudinal and appositional growth. To the best of our knowledge, no other article has analyzed the effect of epiphysiodesis in macrodactyly with quantitative data in over a long-term follow-up.

Patients with true macrodactyly present with hyperplasia of all the tissue elements of the affected digits, including the phalanges, tendons, skin, subcutaneous fat, nerves, and vessels. Interestingly, we observed that phalanges became more severely affected when they were closer to the distal end. Hypertrophy of the distal phalanx was marked, but metacarpal involvement was not apparent. This is compatible with the observation in previous studies[7, 8, 12]. However, disagreement still exists in the involvement up to the metacarpal or metatarsal bone in cases of macrodactyly. Barsky reported no metacarpal involvement in his pioneering study[12]. Following clinical studies showed metacarpal involvement in most patients, although it did not appear marked on radiographic findings[7, 8, 16-18]. Our data also showed an increased ratio of the length (1.08 ± 0.09) and diameter (1.12 ± 0.1) of the metacarpal/metatarsal bone compared with its normal counterpart.

The successful regulation of longitudinal growth in the present study may be because disproportionate growth of the affected digit was slowed and a proportional relationship was anticipated compared with its normal counterpart. However, consensus on the effectiveness

of epiphysiodesis in macrodactyly has not yet been fully established. Ishida performed epiphysiodesis in 4 macrodactyly patients, and he prevented longitudinal overgrowth effectively without additional surgery[10]. Topoleski et al. presented satisfactory results of proximal phalangeal epiphysiodesis in regulating macrodactyly of the foot[11]. In contrast, Tsuge doubted that epiphyseal plate destruction alone is insufficient to control longitudinal growth[8]. Our data showed good results in each treated phalanx itself on radiography in both progressive and static type, but hypertrophy of all the soft tissue triggered by the digital nerve or compensatory growth of the MC/T can diminish the effect of epiphysiodesis[8, 11]. Detailed studies seem to be needed to elucidate contributing factors to the growth of macrodactyly.

As we anticipated, the diameter of the affected digit was not influenced by epiphyseal plate arrest. However, there was a significant increase in diameter at 1 year postoperatively (fig. 3). It is difficult to determine a proper reason for this, but Topoleski et al. also experienced widening of the metaphysis when performing epiphysiodesis in toe macrodactyly. They thought that it was due to iatrogenic periosteal stripping during open epiphysiodesis[11]. Hernandez et al. described similar results from an animal study, and they attributed it to decreased osteoclastic activity[19]. The detailed mechanism for this phenomenon should be investigated in a future study.

The distal phalanx showed a relatively bigger size in both the length and diameter compared with other phalanges. This tendency was maintained throughout the postoperative course, although no difference was found in the reaction to epiphysiodesis between the phalanges. Epiphyseal plate arrest seems to be insufficient, and the size-reducing procedure is required to correct distal phalangeal deformities, including arthrodesis, or downsizing the nail matrix[8, 12, 20].

Similarly, we found a significant increase in the length of the progressive type of

macrodactyly compared with that of the static type, although our data showed no statistical difference in the effect of epiphysiodesis between the progressive and static types during the postoperative course. This may explain why the progressive type accounted for 3 of 4 cases of secondary epiphysiodesis. Although the treatment principles are not different, most hand surgeons modify surgical plans according to the growth pattern of macrodactyly. Patients with the progressive type undergo operation earlier[20] and more frequently[7, 21], and they even undergo aggressive methods such as amputation[12, 20]. Kim et al reported a measureable foot size reduction and excellent functional results using ray amputation in foot macrodactyly[18].

This study has limitations in that the data were collected from a small number of patients in a retrospective manner. To evaluate the effect of epiphysiodesis, we selected data from patients with macrodactyly who underwent epiphysiodesis as a first step. Therefore, our data are subject to selection bias, as relatively less severe cases were included. In addition, the follow-up period was inevitably limited by the secondary operation, which could have directly influenced the growth of macrodactyly. Our mean follow-up period of 5.38 years was measured from the date of epiphysiodesis to that of the last follow-up or just before the secondary operation. No objective functional analysis was performed, but we have not experienced significant functional impairment through epiphysiodesis. The major strength of this study was that we performed quantitative analysis of the long-term follow-up. Size-reducing procedures are usually individualized according to the phenotypic variability, but epiphysiodesis does not differ much among individuals. Our observation clearly showed that epiphysiodesis effectively regulated longitudinal growth from 6 months postoperatively, and suggested that the probability of additional surgical procedure is increased in the distal phalanx or in the progressive type of macrodactyly.

In conclusion, epiphysiodesis is a promising, minimally invasive approach for regulating the

longitudinal growth of macrodactyly when growth potential remains. Objective functional analysis and contributing factors that can influence the growth of macrodactyly other than epiphysis should be investigated in the future in a large prospective study.

References

1. Leung PC, Chan KM, Cheng JC. Congenital anomalies of the upper limb among the Chinese population in Hong Kong. J Hand Surg Am 1982: 7: 563-5.

2. A. F. The Care of Congenital Hand Anomalies. In 2nd edition ed. St. Louis: Quality Medical 1994.

3. Biesecker LG, Happle R, Mulliken JB, et al. Proteus syndrome: diagnostic criteria, differential diagnosis, and patient evaluation. Am J Med Genet 1999: 84: 389-95.

4. Wiedemann HR, Burgio GR, Aldenhoff P, et al. The proteus syndrome. Partial gigantism of the hands and/or feet, nevi, hemihypertrophy, subcutaneous tumors, macrocephaly or other skull anomalies and possible accelerated growth and visceral affections. Eur J Pediatr 1983: 140: 5-12.

5. McGrory BJ, Amadio PC, Dobyns JH, Stickler GB, Unni KK. Anomalies of the fingers and toes associated with Klippel-Trenaunay syndrome. J Bone Joint Surg Am 1991: 73: 1537-46.

6. Greene AK, Taber SF, Ball KL, Padwa BL, Mulliken JB. Sturge-Weber syndrome: soft-tissue and skeletal overgrowth. J Craniofac Surg 2009: 20 Suppl 1: 617-21.

7. Cerrato F, Eberlin KR, Waters P, et al. Presentation and treatment of macrodactyly in children. J Hand Surg Am 2013: 38: 2112-23.

8. Tsuge K. Treatment of macrodactyly. J Hand Surg Am 1985: 10: 968-9.

9. VE W. Macrodactyly. 4th ed. New York: Churchill Livingstone, 2001.

10. Ishida O, Ikuta Y. Long-term results of surgical treatment for macrodactyly of the hand. Plast Reconstr Surg 1998: 102: 1586-90.

11. Topoleski TA, Ganel A, Grogan DP. Effect of proximal phalangeal epiphysiodesis in the treatment of macrodactyly. Foot Ankle Int 1997: 18: 500-3.

12. Barsky AJ. Macrodactyly. J Bone Joint Surg Am 1967: 49: 1255-66.

13. De Laurenzi V. [Macrodactyly of the middle finger]. G Med Mil 1962: 112: 401-5.

14. Murphey MD, Smith WS, Smith SE, Kransdorf MJ, Temple HT. From the archives of the AFIP. Imaging of musculoskeletal neurogenic tumors: radiologic-pathologic correlation. Radiographics 1999: 19: 1253-80.

15. L. M. The hand. In AH C, ed. Campbell's operative orthopaedics. 5th ed ed. St. Louis CV Mosby 1971: 282-89.

16. Dell PC. Macrodactyly. Hand Clin 1985: 1: 511-24.

17. Kalen V, Burwell DS, Omer GE. Macrodactyly of the hands and feet. J Pediatr Orthop 1988: 8: 311-5.

18. Kim J, Park JW, Hong SW, et al. Ray amputation for the treatment of foot macrodactyly in children. Bone Joint J 2015: 97-B: 1364-9.

19. Hernandez JA, Serrano S, Marinoso ML, et al. Bone growth and modeling changes induced by periosteal stripping in the rat. Clin Orthop Relat Res 1995: 211-9.

20. Gluck JS, Ezaki M. Surgical Treatment of Macrodactyly. J Hand Surg Am 2015: 40: 1461-8.

21. Hardwicke J, Khan MA, Richards H, Warner RM, Lester R. Macrodactyly - options and outcomes. J Hand Surg Eur Vol 2013: 38: 297-303.

Figure Legends

Figure 1. The length and diameter of each digit was measured on anteroposterior radiographs. (L: length, D: diameter)

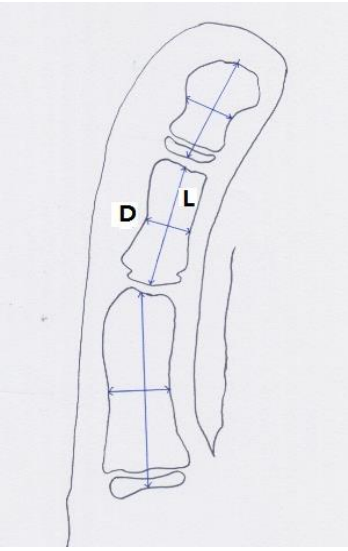

Figure 2. Preoperative state of macrodactyly calculated as the ratio of the length (left) and diameter (right) of the affected digits compared with their counterparts on the normal side. MC/T, metacarpal/metatarsal; PP, proximal phalanx; MP, middle phalanx; DP, distal phalanx.

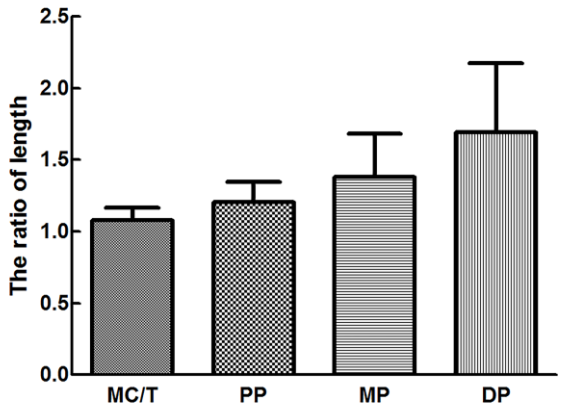

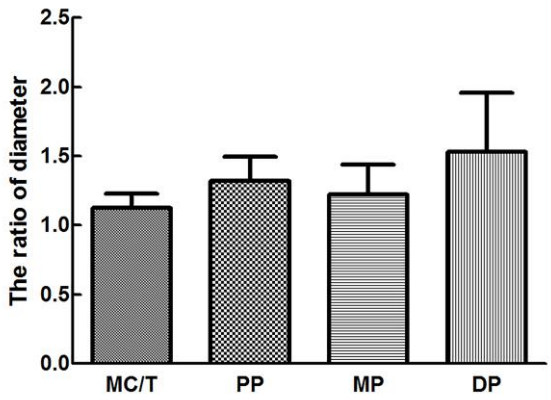

Figure 3. Graphs showing the serial change of the ratio of the length and diameter of affected digits compared with their normal counterparts for each digit. Preop, preoperatively; long-term, long-term follow-up.

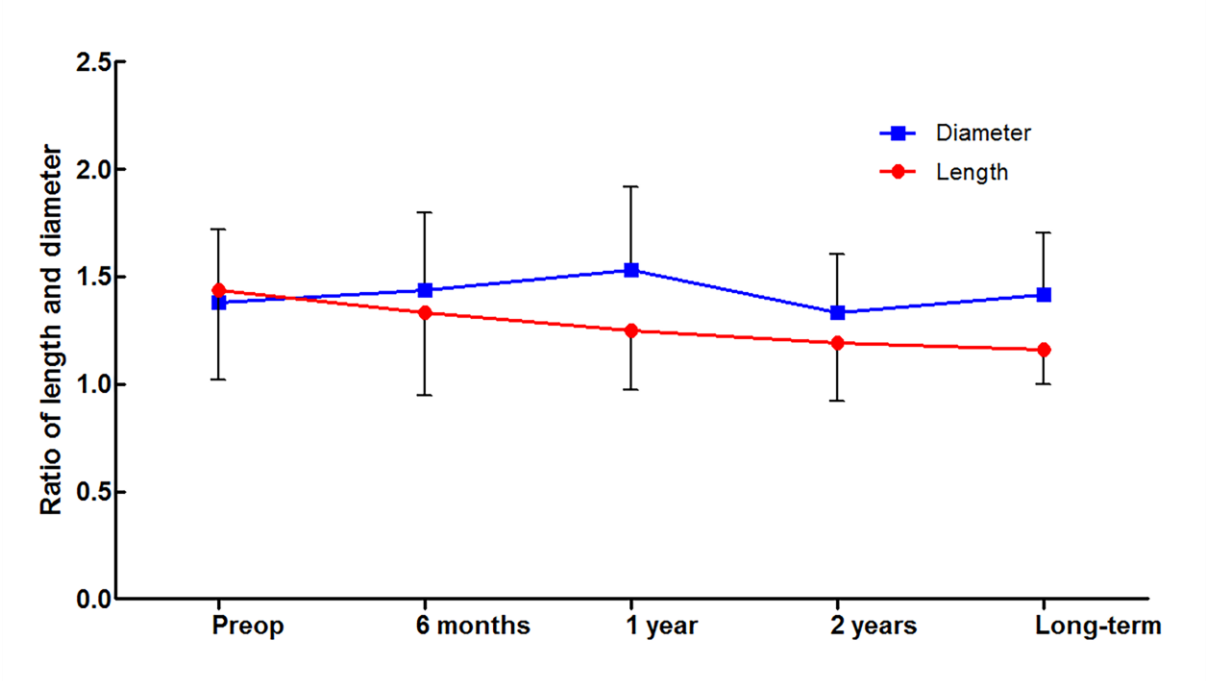

Figure 4. Graphs showing the serial change of the ratio of the length according to the clinical types of macrodactyly. There is a significant difference between the progressive and static type. Preop, preoperatively; long-term, long-term follow-up.

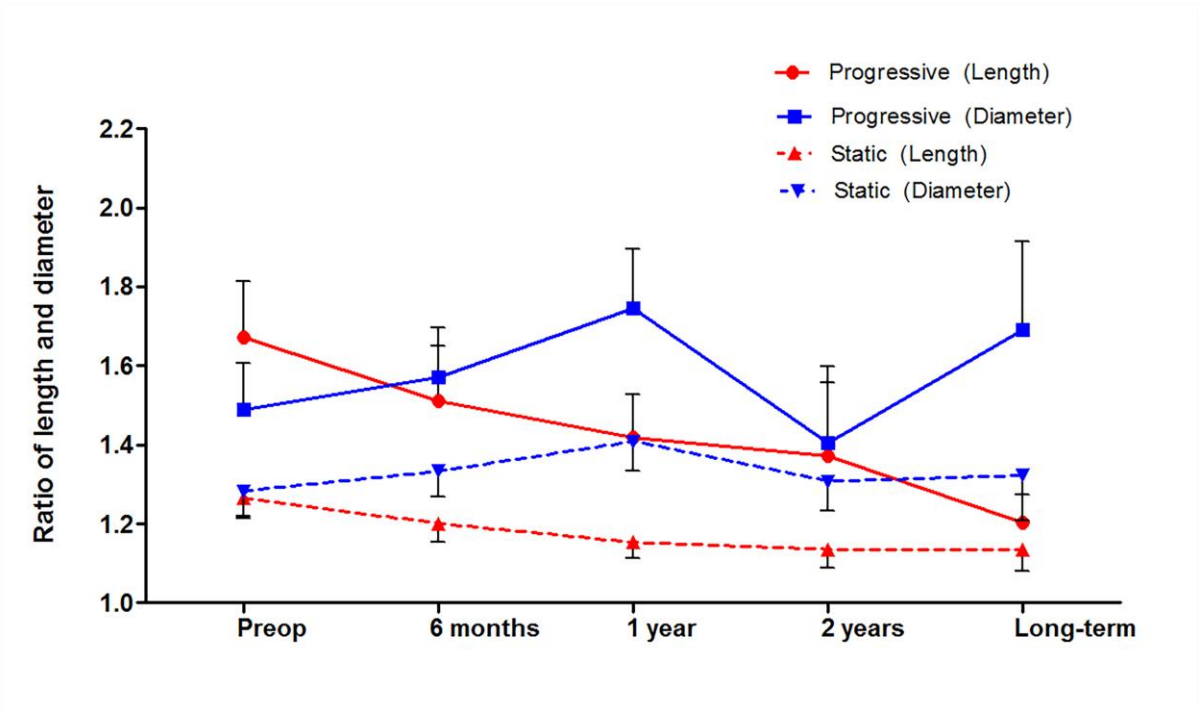

Figure 5. A 5-year-old female patient presented with macrodactyly of her left index finger. Preoperative (left upper) and 7-year postoperative (left lower) medical photographs showing good postoperative results. Radiologic images also showing good postoperative results (right lower) compared with preoperative state (right upper).

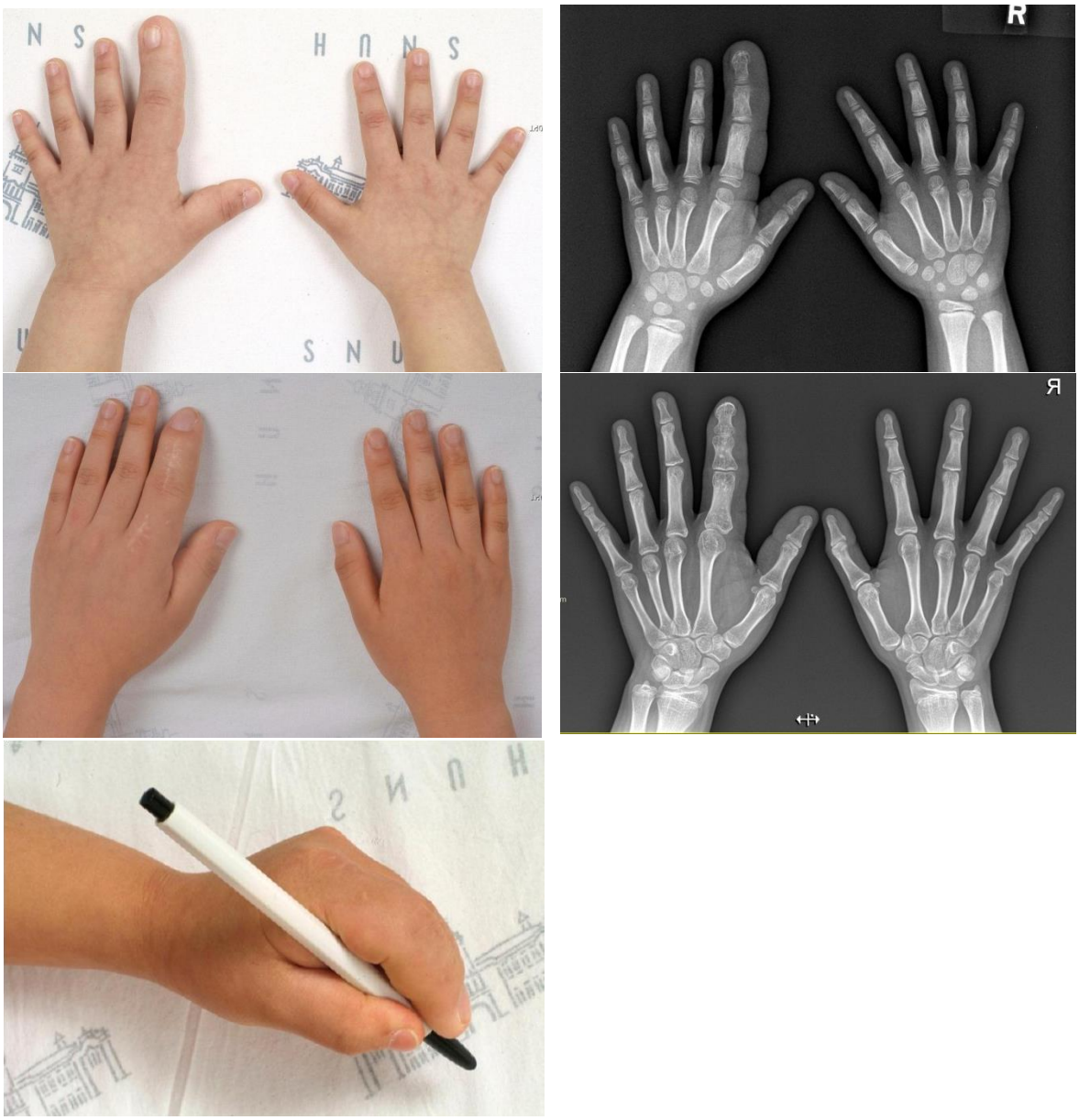

Figure 6. A 4-year-old female patient suffered from macrodactyly of her right second toe. Preoperative (left) and 11-year postoperative (right) radiologic images showing satisfactory postoperative results.

Table

Table 1. Detailed information of the patients with macrodactyly who underwent epiphysiodesis.

Patient number	**sex**	**Affected area**	**Affected site**	**Affected digits**	**Growth type**	**Number of op.**	**Epiphysiodesis, first**			**Epiphysiodesis, second**			**Follow-up period (years)**
							Digits	Age at op (years)	Accompanying operation	Digits	Age at op. (years)	Accompanying operation	
1	F	Foot	Right	2, 3	Pr	6	M(2,3)	1	Dbk, Ost (MT 2,3)	N/A	N/A	N/A	16
2	F	Foot	Left	2	St	1	P, M	5	N/A	N/A	N/A	N/A	1
3	F	Foot	Right	2	Pr	3	M, D	1	Dbk	N/A	N/A	N/A	11
4	F	Hand	Left	2	St	3	P, M	5	Dbk	D	7	Dbk	6
5	M	Foot	Left	3	Pr	2	P, M	1	Dbk, Ost (MT)	MT, D	6	Dbk	7
6	M	Hand	Left	2	St	1	M, D	6	Dbk	N/A	N/A	N/A	3
7	F	Hand	Left	1, 2	Pr	1	P, D(1)	6	Dbk, wOst (D 2)	N/A	N/A	N/A	1
8	F	Foot	Right	1, 2	Pr	3	P, D(1)	2	Dbk	MT(1)	3	Dbk, vOst (P, D 1)	4
9	F	Foot	Right	2	St	1	P, M	1	Dbk	N/A	N/A	N/A	2
10	F	Hand	Right	3	St	2	P, M, D	11	N/A	N/A	N/A	N/A	2
11	F	Foot	Right	2	St	2	P, M, D	4	N/A	N/A	N/A	N/A	11

12	F	Hand	Left	3	St	2	P, M, D	11	Dbk	N/A	N/A	N/A	5
13	F	Foot	Right	2	Pr	2	M, D	1	wOst(P, M)	P, M	2	Dbk, wOst (P)	1

Op.; operation, M; male, F; female, Pr.; progressive, St.; static, P: proximal phalanx, M: middle phalanx, D: distal phalanx, MT: metatarsal bone, Dbk: debulking, Ost: ostectomy, wOst: wedge ostectomy, vOst: vertical ostectomy, N/A: not applicable

국문초록

배경

거대지는 매우 드문 수부 및 족부의 선천성 기형으로, 골 조직 및 모든 연부조직이 침범된다. 아직까지 치료 프로토콜이 정립되어있지 않은데, 이는 거대지 자체가 매우 드물고 임상양상이 다양하게 나타나기 때문이다. 또한 수술 이후 장기 추적관찰 결과를 보여주는 정량적인 데이터 역시 거의 없는 실정이다.

재료 및 방법

최근 15년 동안 본원 성형외과에서 거대지를 주소로 내원하여 골단유합술을 시행받은 환자의 임상 데이터를 후향적으로 분석하였다. 거대지의 크기 변화를 확인하기 위해서 병변측 수지 및 족지의 길이와 직경을 X-ray 상에서 측정하여 반대측 정상 수지 및 족지의 크기에 대한 비율로 나타내었다. 이 상대적인 크기는 술 전, 수술 후 6개월, 1년, 2년, 그리고 장기추적 시기에 측정하여 거대지의 술 전 상태를 파악하고 수술 후 결과를 분석하였다.

결과

총 13명의 환자 중 2명이 남자, 11명이 여자였다. 발가락을 침범한 경우가 8례, 손가락을 침범한 경우가 5례였다. 처음 골단유합술을 시행한 연령은 평균 4.23 년 (범위, 1-11 년)으로 측정되었다. 평균 추적관찰 기간은 5.38년 (범위, 1-16년)이었다. 거대지의 수술 전 상태를 보면 길이와 직경 모두 반대 정상측에 비해 근위부에서 원위부로 갈 수록 심하게 이환된 것을 확인할 수 있었다. 골단 유합술을 시행한 이후에는 효과적으로 병변 부위의 길이 성장이 조절되는 것을 확인할 수 있었으나 넓이 성장에는 유의한 결과가 없었다. 수술 전과 비교하였을 때 골단 유합술을 받은 지골의 크기는 수술 후 6개월에 0.9267 (p = 0.0476), 술 후 1년에 0.8916 (p = 0.0048), 술 후 2년에 0.8688

(p = 0.0018), 그리고 장기 추적관찰에서 0.8353으로 (p = 0.0006)모두 통계적인 유의하게 성장이 저해됨을 확인할 수 있었다.

결론

골단유합술은 성장 잠재력이 남아있는 어린 거대지 환아에서 길이 성장을 조절할 수 있는 효과적인 수술 방법이다. 이번 연구를 통해 얻어진 정보는 수부외과의가 수술 방향을 설정하거나 환자에게 상담할 때 도움을 줄 수 있을 것이다.

Key words: 골단유합술, 거대지, 길이성장, 정량분석