의학석사 학위논문

Parathyroid Glands Preservation Using Indocyanine Green Fluorescence in Bilateral Axillo-Breast Approach Robotic Thyroidectomy

양측 겨드랑이-유방 접근법 로봇 갑상선 절제술에서 인도시아닌 그린의 형광을 이용한 부갑상선 보존 술식

2016년 2월

서울대학교 대학원

의학과 외과전공

정준우

의학석사 학위논문

Parathyroid Glands Preservation Using Indocyanine Green Fluorescence in Bilateral Axillo-Breast Approach Robotic Thyroidectomy

양측 겨드랑이-유방 접근법 로봇 갑상선 절제술에서 인도시아닌 그린의 형광을 이용한 부갑상선 보존 술식

2016년 2월

서울대학교 대학원

의학과 외과전공

정준우

Master of Science in Medicine

Parathyroid Glands Preservation Using Indocyanine Green Fluorescence in Bilateral Axillo-Breast Approach Robotic Thyroidectomy

양측 겨드랑이-유방 접근법 로봇 갑상선 절제술에서 인도시아닌 그린의 형광을 이용한 부갑상선 보존 술식

February 2016

The Department of Medicine (Surgery)

Seoul National University Graduate School

Joon Woo Chung

Parathyroid Glands Preservation Using Indocyanine Green Fluorescence in Bilateral Axillo-Breast Approach Robotic Thyroidectomy

지도교수 김수진

이 논문을 의학석사 학위논문으로 제출함

2015년 10월

서울대학교 대학원

의학과 외과학

정준우

정준우의 석사학위논문을 인준함

2016년 1월

위 원 장 이규언 (인)

부 위 원 장 김수진 (인)

위 원 천기정 (인)

Abstract

Parathyroid Glands Preservation Using Indocyanine Green Fluorescence in Bilateral Axillo-Breast Approach Robotic Thyroidectomy

Joon Woo Chung
Medicine, Surgery
The Graduate School
Seoul National University

Background: Bilateral Axillo-Breast Approach (BABA) robotic thyroidectomy (RoT) has shown favorable cosmetic and surgical outcomes since its introduction in 2008. With increasing use of BABA RoT, many trials have been made for effective identification and preservation of parathyroid glands and recurrent laryngeal nerves (RLNs). The aim of this study was to identify and preserve parathyroid glands using indocyanine green (ICG) fluorescence under near-infrared (NIR) light in BABA RoT.

Methods: A pilot study of 14 patients was designed to determine an optimal ICG dose. Seven different ICG doses (1 mg, 2.5 mg, 5 mg, 7.5 mg, 10 mg, 15 mg, 20 mg) were assessed for fluorescence patterns and optimal identification time of inferior parathyroid glands. Simultaneous intraoperative tissue parathyroid hormone (PTH) assays were done in 9 patients for biochemical confirmation of assumed parathyroid glands identified by ICG fluorescence. From September 2014 to August 2015, among patients who had undergone BABA RoT due to thyroid cancers, 22 patients were enrolled with informed consents. The patients were given 10 mg ICG intravenously after strap muscle dissection. By 'Firefly' system (NIR illuminator: 805 nm / filter: 825 nm) integrated to da Vinci Si robot system, ICG was excited and emitted green fluorescence. ICG fluorescence duration with optimal identification time of inferior parathyroid glands was estimated from time of its appearance and disappearance in parathyroid and thyroid respectively, with an attempt to find RLN at the same

time. Using propensity score matching, control group was set to compare surgical complications between two groups. Patient demographics and clinico-pathologic characteristics were analyzed together.

Results: In the pilot study, inferior parathyroid glands were effectively identified with 10 mg ICG at 3 minutes after injection. The results of intraoperative tissue PTH assays suggested successful parathyroid glands identification had been achieved in 9 patients. The mean time taken to visualize parathyroid and thyroid by ICG fluorescence was 203 ± 89 sec (range: 125-331 sec) and 207 ± 112 sec (range: 130-356 sec) with mean fluorescence duration of 20.8 ± 6.0 min (range: 16.6-35.8 min) and 20.1 ± 7.3 min (range: 15.5-33.8 min) respectively. All 32 parathyroid glands of 22 patients were distinguished from thyroid by earlier enhancement, more focal and intense fluorescence pattern. RLNs didn't show ICG fluorescence in contrast to thyroid and parathyroid glands. In postoperative period mild transient hypoparathyroidism was reported in one patient, otherwise no RLN palsy occurred. ICG group showed significantly lower rates of transient hypoparathyroidism (4.5 % vs 50 %, $P < 0.001$) and incidental parathyroidectomy (0 % vs 38.6 %, $P < 0.001$) compared to control group.

Conclusions: The results of the present study suggest that parathyroid glands preservation using ICG fluorescence under NIR light may be feasible and safe in BABA RoT. RLNs were also easily detected and saved by means of its non-fluorescent property.

……

Keywords: Bilateral Axillo-Breast Approach (BABA), Robotic Thyroidectomy, Parathyroid Glands, Indocyanine Green (ICG) Fluorescence, Near-Infrared (NIR)

Student Number: 2013-23494

Contents

List of Tables

List of Figures

Introduction

Thyroid cancers have increased more rapidly than other endocrine malignancies in the last decade (1). It is occupying 32.2 % of females' cancers and 7.2 % males' ones (2). Total 44,007 patients (35,955 females and 8,052 males) newly diagnosed with thyroid cancer were reported in the annual report of cancer statistics in Korea in 2012 (2). Thyroid cancers consist of papillary thyroid carcinoma (PTC), follicular thyroid carcinoma, medullary thyroid carcinoma, anaplastic thyroid carcinoma and lymphoma. Of them, PTC is most common with its incidence rate reported to be over 90% in Korea showing excellent survival rate if diagnosed and treated properly.

Conventional operation for thyroid disease has been open thyroidectomy since Kocher performed it for treatment of goiter first in 1872. There have been many advances in open thyroid surgery such as aseptic technics, minimal blood loss contributing to lower morbidity and mortality related to operation. Regarding thyroid cancer, radical operations like total thyroidectomy and lobectomy have been adopted in many centers. Though there are still many debates on prophylactic central lymph node (CLN) dissection in PTC, CLN metastasis has been reported to be closely related to prognosis in several studies (3, 4). Therefore CLN dissection is preferred in patients diagnosed with CLN metastasis preoperatively or suspicious for it in ultrasound or computed tomography in these days (4-6). Total thyroidectomy and thyroid lobectomy with therapeutic CLN dissection have become standard operations in patients with PTC showing a strong tendency for lymphatic spread.

Recently many studies have introduced new technics in thyroid surgery using endoscopy and laparoscopy (7-9). Among them, Bilateral Axillo-Breast Approach (BABA) technic applied to endoscopic surgery of benign and malignant thyroid disease first by Youn et al. since 2004 has shown favorable outcomes in oncologic and aesthetic aspects (10-12). In 2008 they reported BABA Robotic Thyroidectomy (RoT) with application of BABA technic to da Vinci robot system (Intuitive Surgical Inc., Sunnyvale, CA) (12). Indications of BABA RoT include as follows: (i) low risk and well differentiated thyroid cancer (ii) Graves' disease (iii) benign thyroid nodule with size under 8cm. Patients with history of previous neck surgery, advanced stage cancer or distant metastasis were

excluded (9). The study which reviewed 1026 cases of BABA RoT published in 2013 has reported that this technic showed similar surgical completeness and rates of complications compared to open thyroidectomy (13).

Though thyroid malignancy has been known to be indolent with high overall survival and low recurrence rate, complications like hypoparathyroidism and recurrent laryngeal nerve (RLN) palsy could impair patients' quality of life seriously (14). While many studies of RLN preservation with intraoperative nerve monitoring (IONM) have been reported, there have been many debates on surgical methods preventing hypoparathyroidism (15). Permanent hypoparathyroidism has been reported in 1-5 % of patients after total thyroidectomy impairing quality of life in many patients (16). Incidence rates of transient hypoparathyroidism were reported up to 50 % of patients who had undergone total thyroidectomy in several studies, forcing them to suffer from many symptoms and take medications for calcium and vitamin D supplementation (17). The rates of incidental parathyroidectomy related to CLN dissection, especially inferior parathyroid glands, have been reported up to 17.7 % as CLN dissection cases increased (14). Major symptoms of hypoparathyroidism are mainly related to hypocalcemia, such as tingling sensation, nerve conduction disturbance, muscle spasm and respiratory distress in severe cases. Therefore there have been several studies focusing on methods for preservation of parathyroid glands (14). In the past surgeons focused on anatomical dissection using land marks such as inferior thyroidal artery and RLN for identification of parathyroid glands. However it seemed to largely depend on surgeon's experience. Subsequently several studies using various agents like toluidine blue O, methylene blue, indocyanine green and 99^{m}Technetium-methoxyisobutylisonitrile (99^{m}TC-MIBI) for detection of parathyroid glands have been reported.

Indocyanine green (ICG) has been used for liver excretory function test for a long time. In recent years ICG was widely used in various fields such as patency evaluation after vessel anastomosis, navigation for sentinel lymph nodes and extrahepatic cholangiography (18). Recently reported experiments using near-infrared (NIR) fluorescence has demonstrated its usefulness to aid surgical

navigation in animal models and made meaningful steps toward application to intraoperative imaging in human (19). Among them, recent animal model study using ICG under NIR for parathyroid glands preservation has been published where canine parathyroid glands with ICG uptake were excited by light between 780 and 800 nm in wavelength emitting fluorescence around 830 nm, visualized successfully under NIR camera (20). Furthermore 'Firefly' system (Novadaq Technologies Inc., Mississauga, ON, CAN) (NIR illuminator: 805 nm / filter: 825 nm) integrated to da Vinci Si robot system (Intuitive Surgical Inc., Sunnyvale, CA) was introduced and made it more easy to use ICG fluorescence in robot thyroidectomy than open thyroidectomy that needed cumbersome equipment with additional costs.

Up to now there had been few studies of parathyroid glands preservation using ICG fluorescence in thyroid surgery of human. The aim of the present study was to evaluate feasibility and safety of parathyroid glands preservation using ICG in thyroid cancer patients who underwent BABA RoT.

Patients and Methods

To determine optimal dose of ICG for this study, a pilot study was conducted including total 14 patients who underwent BABA RoT due to PTC in Seoul National University Bundang Hospital (SNUBH) between December 2013 and August 2014.

From September 2014 to August 2015, total 22 patients diagnosed with PTC who were candidates for BABA RoT in SNUBH were recruited for main study. All operations were performed by single endocrine surgeon. Informed consents were available in all patients before operation. The protocols of this study were approved by the institutional review boards of SNUBH (B-1309/217-001). The patients with medical history of severe cardiovascular and respiratory disease, chronic kidney disease, cerebrovascular infarction, uncontrollable hypertension and diabetes mellitus, and drug allergy were excluded. Also patients younger than 20 years or older than 70 years, pregnant were excluded. In the last 9 patients, intraoperative tissue parathyroid hormone (PTH) assays were performed to confirm parathyroid glands.

For comparison of surgical complications, control group was retrospectively constituted using propensity score matching (1:2) regarding age, sex, tumor size, operation type. The subjects of control group were 44 patients who had also undergone BABA RoT without ICG satisfying inclusion criteria of this study by the same surgeon in SNUBH between April 2013 and August 2014.

Operative procedures

Surgical technics for BABA RoT was described in previous relevant studies in detail (9, 13). Patients were placed in supine position with neck hyperextension using pillow under their shoulders, and skin drawing of flap boundary and important anatomic landmarks such as thyroid and cricoid cartilages, sternocleidomastoid muscles, clavicles was made by marking pen before injection of saline-diluted epinephrine solution (1:200,000) into subplatysmal layer in neck and subcutaneously in anterior chest using long spinal tapping syringe. This 'hydro-dissection' was performed to prevent flap bleeding and proceed to subsequent dissection. Total four skin incisions were made on superomedial margins of both areolar plates and both axillary folds. After meticulous dissection with subcutaneous tunneler, four trocars were placed on each port site (Figure 1). Working space for robotic surgery was maintained by insufflation of 5-6 mmHg CO_2.

Having da Vinci Si robot system docked to patient, operator moved to a console box and refined the flap margin before proceeding to main steps of operation. After strap muscles were divided to the extent that thyroid isthmus was visible after careful exposure of tracheal surface without laceration and penetration, operator divided isthmus using a harmonic scalpel. In previous study Isthmus division seemed to be helpful not only in secure ligation of superior thyroidal vessels through clear vision, also in easy manipulation of thyroid gland (9). After ligation of middle thyroidal vein, surgeon proceeded to dissection of thyroid gland in upward direction with ligation of inferior thyroidal vessels, preservation of RLNs, superior and inferior parathyroid glands. Ipsilateral CLN dissection in patients with suspicious lymph node metastasis was done following resection of thyroid lobe where thyroid cancer was located. The resected lobe and CLN were extracted through axillary port site using endo-pouch. Contralateral lobectomy was done in the same manner in case of total thyroidectomy. Operation was finished after irrigation, meticulous bleeding control, insertion of hemostatic materials and drain. Surgical brassiere with compressive gauze packing was applied for prevention of flap bleeding.

Figure 1 Skin flap for BABA robotic thyroidectomy

BABA, Bilateral Axillo-Breast Approach

v: thyroid cartilage, +: cricoid cartilage, u : sternal notch, black dotted line: midline

12mm trocar for camera on right breast, 8mm trocars on left breast and both axillae

ICG injection

After 25 mg powder type ICG was dissolved by 10 cc saline in bottle (Figure 2), 4 cc of ICG solution corresponding to 10 mg of ICG was pulled out from bottle using syringe, optimal dose determined in the pilot study. As seen in liver excretory function test, dose up to 30 mg, ICG is known to be safe for 60 kg adult with high median lethal dose (50-80 mg/kg). When carotid sheath was exposed and 'switching motion' (9) was applied following strap muscle dissection, ICG solution was administered through patient's intravenous line. It was very important to prevent bleedings from surrounding structures like strap muscles, thyroid capsule and CLN. If bleeding had occurred, it would be impossible to visualize parathyroid glands clearly due to ICG leakage from vessels staining operative field. Also the caution not to administer ICG fast was made because it could make visualization of parathyroid and thyroid too fast and strong to discriminate parathyroid from thyroid. An important property of ICG in this study is fluorescence under NIR wavelength (700-900 nm), therefore 'Firefly' system with 805 nm illuminator and 825 nm filter integrated to da Vinci Si robot system was used. Since NIR light is famous for deep penetration ability with a high signal-to-background ratio to make tissue seen more translucent, fluorescence of ICG under NIR is expected to produce good intraoperative image of well-vascularized structures with contrast to others (21). After Firefly system was turned on following ICG injection, elapsed times to fluorescence onset with durations in parathyroid and thyroid, also fluorescence pattern of RLN were estimated. For the confirmation of assumed parathyroid glands, intraoperative tissue PTH assay was done at the same time. By long spinal tapping needle, a surgeon tried to get a sample from assumed parathyroid gland on needle tip of syringe with 3 cc saline engaged using robot arms (Figure 3, 4C). Tissue fluid with saline was moved to the test bottle and sent to the laboratory. Clinical characteristics including patient demographics were also analyzed together.

Data and statistical analysis

Data were statistically analyzed by t-test and chi-square test using SPSS ver. 18.0 software (SPSS Inc., Chicago, IL, USA). *P* value <0.05 was considered to be statistically significant.

Figure 2 1 vial of ICG (25 mg) mixed with 10 cc of normal saline

Figure 3 Spinal tapping needle engaged with 3 cc of normal saline for tissue PTH assay

Results

Pilot study

In pilot study with 14 patients to determine optimal ICG dose, two patients were included in each group with seven different doses (1 mg, 2.5 mg, 5 mg, 7.5 mg, 10 mg, 15 mg, 20 mg) and patterns of fluorescence were assessed by operator. Better visualization intensity and identification time around 3 minutes after ICG injection for parathyroid glands were observed in group with 10 mg than others. No complication related to operation was reported.

PTH assay

Intraoperative tissue PTH assay performed for total 13 assumed parathyroid glands in the last 9 patients showed 100 % accuracy in biochemical confirmation of parathyroid glands (Table 1). For reference, tissue PTH assays of surrounding structures such as subcutaneous fat, sternocleidomastoid muscle and CLN were assessed together. However no PTH was detected in these samples

Main study

Clinical characteristics and fluorescence data of ICG are shown in Table 2. Total 22 patients (21 females, 1 male) underwent BABA RoT due to PTC. Among them, ten belonged to total thyroidectomy group, and the others to lobectomy. There was no case with conversion to open thyroidectomy. Mean age was 38.6 ± 7.8 years (range: 22-54 years) and body weight was 59.2 ± 9.6 kg (range: 39.2-76.8 kg) on average. Mean tumor size was 0.86 ± 0.43 cm (range: 0.3-1.8 cm). Proportion of patients with tumor size below 1 cm was about 86.3 %. Final pathology was reported to be PTC in all cases. Average operation time was 27.3 ± 6.6 min (range: 20.2-37.0 min) for lobectomy. Mean taken times to visualization of parathyroid and thyroid by ICG fluorescence were 203 ± 89 sec (range: 125-331 sec) and 207 ± 112 sec (range: 130-356 sec) respectively. Mean durations of ICG

fluorescence maintenance of parathyroid and thyroid were 20.8 ± 6.0 min (range: 16.6-35.8 min) and 20.1 ± 7.3 min (range: 15.5-33.8 min). About 4 seconds' interval between fluorescence onset time of each gland seemed to be enough to distinguish parathyroid from thyroid. 3 minutes taken to parathyroid visualization was not long compared to total operation time. Procedure associated with ICG injection needed around 5 minutes without significant delay of operation time. Total 32 parathyroid glands were targeted to identify by ICG fluorescence under NIR light, which were successfully visualized in all patients. Figure 4 consists of serial photographs of visualization of parathyroid gland by ICG fluorescence under NIR light. Around 7 minutes after ICG injection, RLNs were identified without ICG fluorescence in contrast to surrounding tissues with ICG uptake. When compared with control group using propensity score matching (1:2), ICG group showed significantly lower rates of transient hypoparathyroidism (4.5 % vs 50 %, $P < 0.001$) and incidental parathyroidectomy (0 % vs 38.6 %, $P < 0.001$). One transient hypoparathyroidism case with mild tingling sensation was reported in ICG group, which have subsided after two weeks on calcium supplementation. While there was no case with transient RLN palsy in ICG group, it was reported in 5 patients (11.4 %) in control group, but statistically not significant ($P = 0.160$). No patient with allergy or anaphylactic reaction related to ICG intravenous injection was reported.

Table 1. Results of intraoperative tissue PTH assay

Patient No.	*Sex*	*Age*	*Operation*	*Intraoperative tissue PTH (pg/ml)*
1	female	31	TT	RI: 49.2 / LI: 32.4
2	female	46	LL	LI: 30.5
3	male	46	TT	RI: 30.8 / LI: 31.3
4	female	46	LL	LI: 27.2
5	female	34	LL	LI: 29.6
6	female	30	TT	RI: 66.8 / LI: 30.3
7	female	22	TT	RI: 28.2
8	female	34	TT	RI: 28.6 / LI: 30.4
9	female	54	RL	RI: 32.1

PTH, parathyroid hormone (normal range: 15-65 pg/ml); *TT*, total thyroidectomy; *LL*, left lobectomy; *RL*, right lobectomy; *LI*, left inferior; *RI*, right inferior

Table 2. Clinical characteristics and ICG fluorescence data

Variables	*with ICG* (n=*22)*	*without ICG* (n=*44)*	*P* value
Patient demographics			
Gender (female : male)	21 : 1	41 : 3	1.000
Mean age, years (range)	38.6 ± 7.8 (22-54)	39.4 ± 8.0 (22-60)	0.694
Mean body weight, kg (range)	59.2 ± 9.6 (39.2-76.8)	57.6 ± 9.1 (47.2-71.0)	0.531
Operation types (n, %)			
Total thyroidectomy	10 (45.5)	20 45.5)	1.000
Thyroid lobectomy	12 (54.5)	24 (54.5)	1.000
Pathology			
Papillary thyroid carcinoma (n, %)	22 (100)	44 (100)	1.000
Tumor size, cm (range)	0.86 ± 0.43 (0.3-1.8)	0.86 ± 0.40 (0.2-2.1)	1.000
ICG injection			
Mean time to parathyroid visualization, sec (range)	203 ± 89 (125-331)	NA	NA
Mean time to thyroid visualization, sec (range)	207 ± 112 (130-356)	NA	NA
Mean duration of parathyroid fluorescence, min (range)	20.8 ± 6.0 (16.6-35.8)	NA	NA
Mean duration of thyroid fluorescence, min (range)	20.1 ± 7.3 (15.5-33.8)	NA	NA
Mean operation time for each lobectomy, min (range)	27.3 ± 6.6 (20.2-37.0)	NA	NA
Postoperative complications (n, %)			
Transient hypoparathyroidism	1 (4.5)	22 (50)	<0.001
Incidental parathyroidectomy	0 (0)	17 (38.6)	<0.001
Transient RLN palsy	0 (0)	5 (11.4)	0.160
Allergy to ICG	0 (0)	NA	NA

RLN, recurrent laryngeal nerve; *ICG*, indocyanine green; *NA*, not available

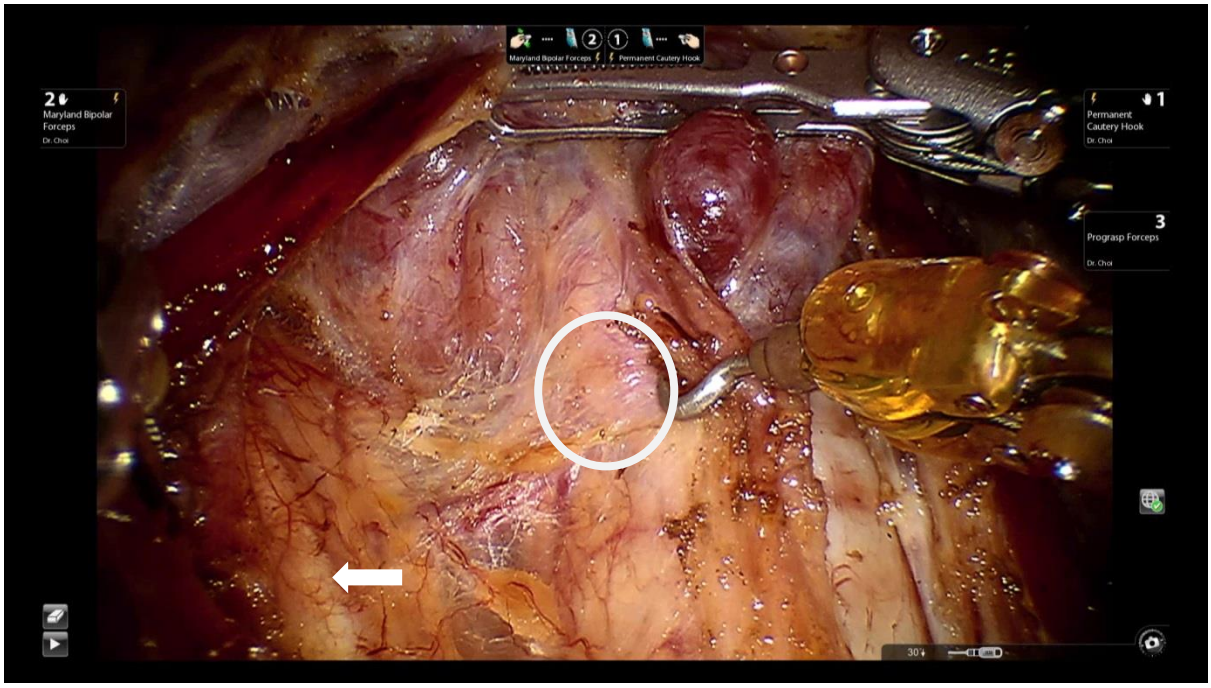

Figure 4 ICG fluorescence images of parathyroid and thyroid glands

(A) At the time assumed right inferior parathyroid gland (white circle) and carotid sheath (white arrow) were visible, ICG solution was administered intravenously

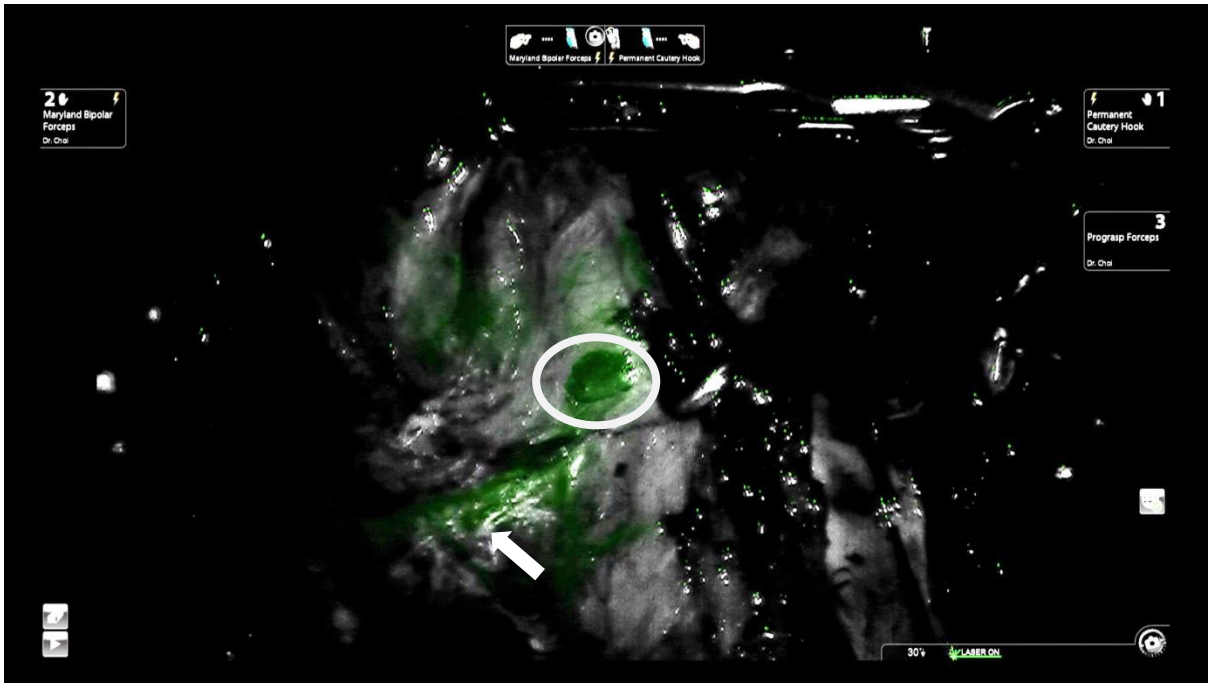

(B) Right inferior parathyroid gland (white circle) and inferior thyroidal artery (white arrow) were visualized by fluorescence at 3 minutes after ICG injection showing more focal and intense fluorescence than surrounding tissues

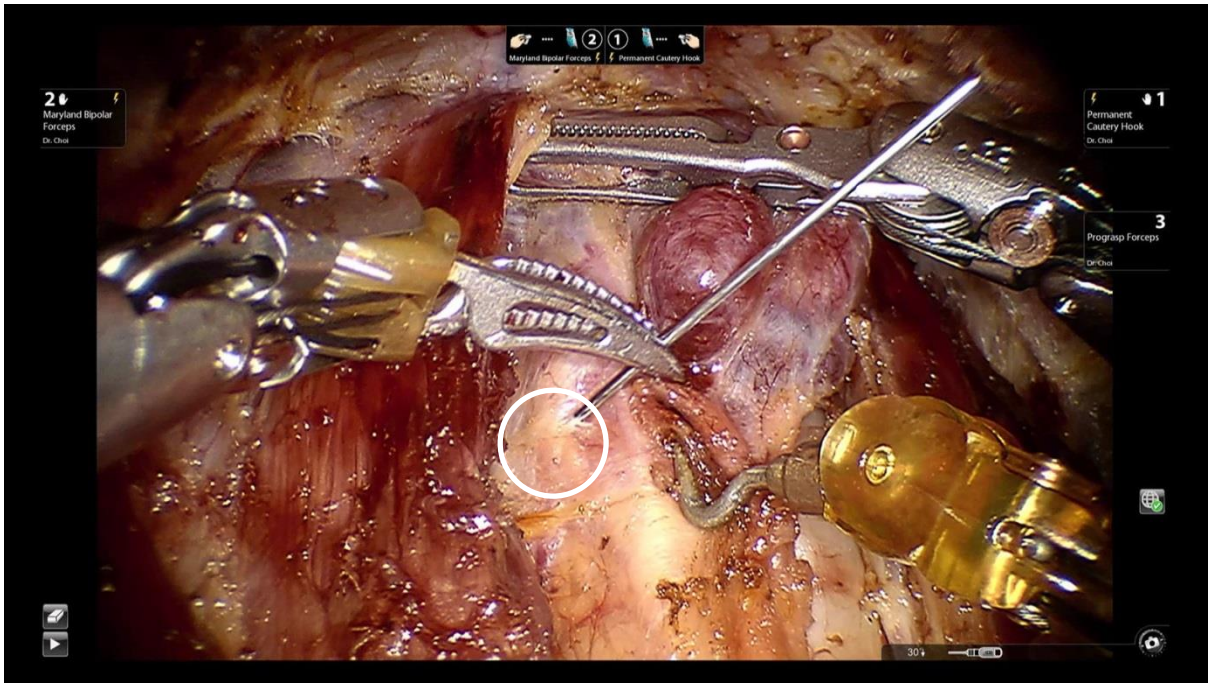

(C) Intraoperative tissue PTH assay of assumed parathyroid gland (white circle) was performed following parathyroid fluorescence detection in (B)

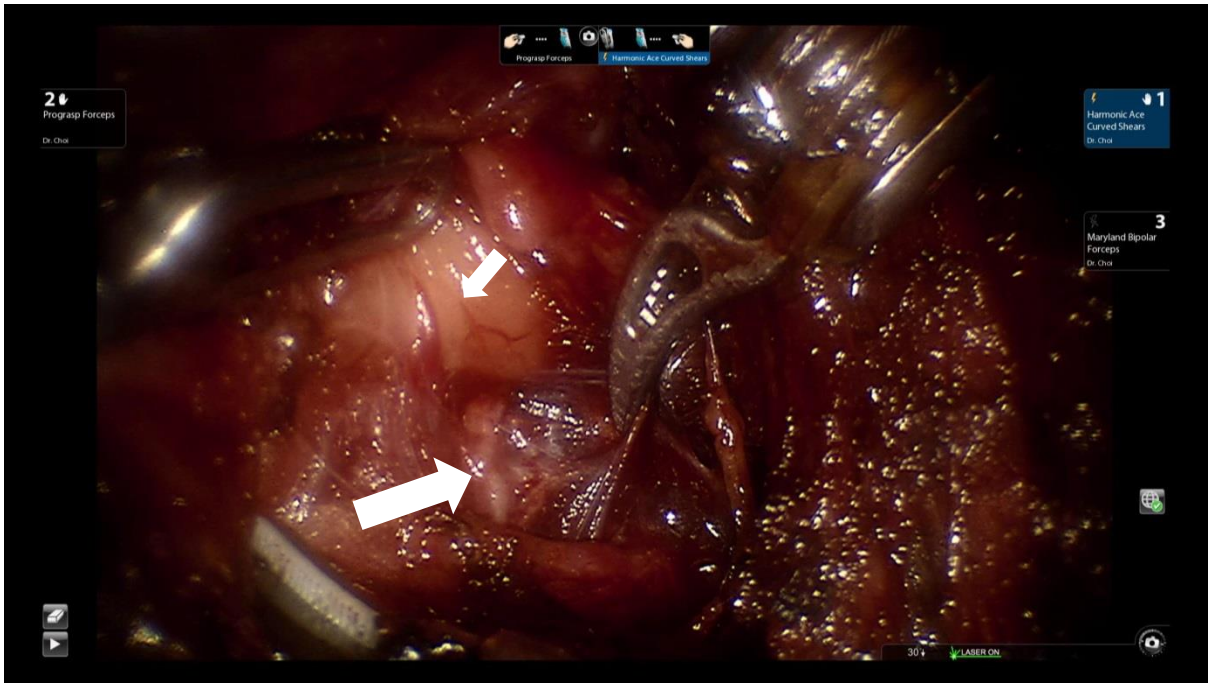

(D) Left RLN (large white arrow) was identified after inferior parathyroid gland preservation during left thyroid lobectomy (small white arrow)

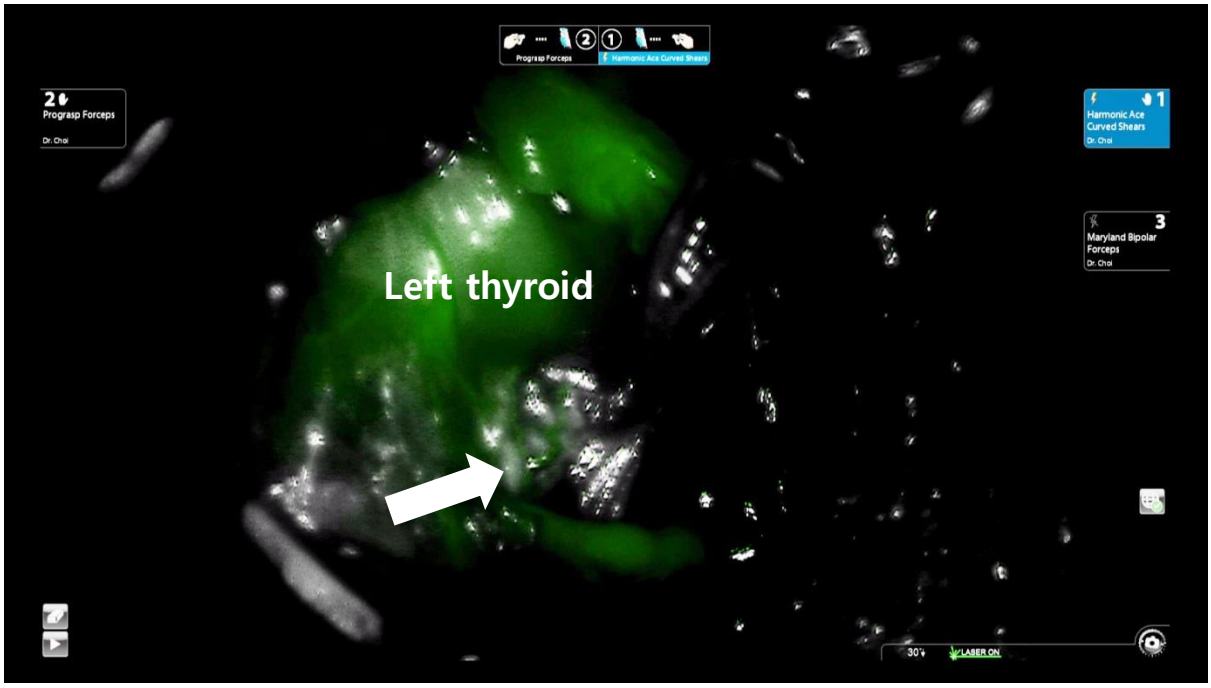

(E) Left RLN (white arrow) was seen non-fluorescently with ICG under NIR at 7 minutes after ICG injection when parathyroid and thyroid were already visualized by fluorescence

Discussion

Identification and preservation of inferior parathyroid glands by ICG fluorescence under NIR light was performed successfully and safely using 'Firefly' integrated to da Vinci Si robot system in this study. 10 mg of ICG, an assumed optimal dose determined from the pilot study, was seemed to be effective in identification of parathyroid glands. Estimated mean taken time to parathyroid visualization with fluorescence was 203 ± 89 sec after ICG injection which made a surgeon identify parathyroid glands by earlier than thyroid glands. By this technic, patients in study group showed significantly lower rates of transient hypoparathyroidism (4.5 % vs 50 %, $P < 0.001$) and incidental parathyroidectomy during operation than control group (0 % vs 38.6 %, $P < 0.001$) respectively with favorable clinical courses.

During last decade there have been many trials to attempt selective parathyroid glands identification using several agents like toluidine blue O, methylene blue, and 99^{m}TC-MIBI was introduced in the recent study (22, 23). Though toluidine blue had been used for intraoperative identification of parathyroid glands since 1966 as inorganic dye due to its property staining parathyroid glands specifically, it couldn't stain normal parathyroid well enough to be identified during thyroidectomy (24). Methylene blue has been popular dye used to aid in intraoperative parathyroid glands identification since 1971 (25). However it has been reported to have some limitations in recent systemic reviews such as relatively weak staining in normal parathyroid glands compared to abnormal ones, severe hypersensitivity and neurotoxic encephalopathy due to MAO inhibiting properties (26, 27). 99^{m}TC-MIBI is an emerging agent detected by radio-guided gamma probe. But increased chance of radiation exposure and relatively low detection rate of parathyroid glands around 50 % were reported (23).

ICG is the first fluorophore approved for clinical use by FDA with short half-life about 3-5 minutes and is excreted into bile (20, 28). ICG is mainly combined to plasma lipoprotein and distributed in vascular compartment making itself specific for vascularized structure (29). Besides these basic properties, ICG shows fluorescence enabling deep lying vessels or tissues to be well-visualized under

NIR light where tissue is becoming more translucent than visible wavelength (21). ICG fluorescence is known to be visible up to several millimeters in depth (20, 30). Short half-life of ICG made repeated use of dye possible for detection of parathyroid glands during operation. In this study, as mean duration of parathyroid fluorescence was around 20 minutes shorter than mean operation time for lobectomy around 27 minutes, clean operative fields of contralateral side without fluorescence could be seen after excision of lobes where cancer was located in total thyroidectomy cases. Subsequently contralateral lobectomy with second 10 mg ICG injection could be performed as effective as initial lobectomy with similar operation time. Total 20 mg ICG was used in patients who underwent total thyroidectomy without adverse effect related to dye as in lobectomy group. On the other hand short half-life of ICG has prevented enough contrast delivery to targets limiting intensity of fluorescence, therefore complimentary studies to overcome this have been reported recently (31, 32). Though ICG has not shown good discrimination between benign tissue and malignancy of parathyroid glands (20), it might not influence much the results because targets of fluorescence enhancement were mainly normal parathyroid glands in this study.

In recent study using animal model, authors repeated experiments several times for determining an optimal concentration using short half-life of ICG. Subsequently they suggested 18.75 ug/kg was the optimal concentration of ICG for identification of parathyroid glands in dogs, as peak intensity and onset time of fluorescence estimated by combined software were adequate at this level (20). Accordingly 18.75 ug/kg of ICG equal to about 1 mg of ICG in 60 kg patient was evaluated at first in a pilot study, but at this dose fluorescence onset time of parathyroid glands was over 15 minutes after ICG injection delaying main steps of operation and intensity of fluorescence was weak making parathyroid glands indistinguishable from thyroid and surrounding tissues. This might be attributable to more complex vessel anatomy, different cardiac function, blood circulation time of human, compared to dog. Therefore a pilot study for determination of the optimal dose in human comprised of seven small groups with different ICG doses (1 mg, 2.5 mg, 5 mg, 7.5 mg, 10 mg, 15 mg, 20 mg) was conducted, although two patients were included in each group and patterns of fluorescence were

subjectively assessed, it could be hypothesized that 10 mg was the optimal dose for average female whose weight is around 60 kg. At this level of ICG dose, ICG fluorescence of parathyroid glands was observed at 3 minutes after injection and earlier than that of thyroid glands by 4 seconds on average, distinguishable by our bare vision without significant delay in operation. Unlike animal model study and open surgery in human, there were no software program analyzing peak intensity and onset time of ICG fluorescence obtained from 'Firefly' accurately, therefore optimal dose was suggested rather than concentration. More objective data regarding ICG fluorescence will be reported when new analyzing tool is to be developed.

In thyroid cancer surgery, especially PTC, CLN dissection has become a routinely performed procedure for patients with proven or suspicious CLN metastasis in preoperative work-up because it has been reported to be closely related to surgical outcomes and prognosis (4, 5, 20). As CLN dissection grew popular, the rates of incidental parathyroidectomy during thyroid surgery have increased remarkably in these days. Incidence rates of transient and permanent hypoparathyroidism are reported up to 30-50 % and 1-5 % of total thyroidectomy cases respectively (13, 16). Inferior parathyroid gland is especially vulnerable to incidental parathyroidectomy during CLN dissection due to close anatomical proximity and various positions. As dissection from inferior to superior side had been preferred in BABA RoT, identification of inferior parathyroid glands with more various positions rather than superior glands was focused on in surgical fields. Anatomical variability of inferior parathyroid glands usually makes it more difficult to identify and preserve the parathyroid glands vulnerable to inadvertent injury during thyroid surgery and operation time can be also prolonged. Total 32 inferior parathyroid glands of 22 patients were successfully identified in all cases using ICG fluorescence under NIR light, of which 13 assumed parathyroid glands of 9 patients enrolled later were confirmed to be real parathyroid glands by intraoperative tissue PTH assays. It would be useful to help non-experienced surgeons to proceed to next steps in their operation with confidence. Also operation time may not be prolonged much in cases with difficulty in identifying parathyroid glands. Excellent rates of postoperative hypoparathyroidism can be also achieved by

synergistic effect between ICG fluorescence and experienced endocrine surgeon's judgment. It was notable that though more than half were lobectomy cases, there was only one transient hypoparathyroidism case reported in total thyroidectomy group with overall rate 4.5 % without incidental parathyroidectomy case who recovered at fist postoperative follow-up after two weeks' calcium supplementation. The rate of transient hypoparathyroidism in this study was significantly lower than 39.1 % previously reported in literature that reviewed numerous cases with BABA RoT (13). If operator gets more fluent in this method, dissection of superior parathyroid level can be also made prior to ICG injection, both parathyroid glands is to be visualized with fluorescence and saved simultaneously.

Since this study enrolled a relatively small group of 22 patients, statistical value would not be significant to apply this result to other cases. Regarding propensity score matching analysis this control group was recruited retrospectively after main study for comparison of surgical complications with ICG group, therefore data regarding ICG fluorescence and operation time of lobectomy were not available. Further prospective randomized controlled trials are needed to support this study. However, to the best of our knowledge, this might be the first clinical trial using ICG fluorescence imaging under NIR light for parathyroid glands preservation in human undergoing BABA RoT. The results of this study may be helpful in setting protocols for identification and preservation of parathyroid glands in BABA RoT.

Conclusions

Though there have been many trials using various methods to reduce rates of complications related to parathyroid injury during thyroid surgery, standard technics are still not established in this field. This study suggests IGC fluorescence imaging under NIR light for parathyroid glands preservation may be feasible and safe in BABA RoT.

References

1. Fallahi P, Giannini R, Miccoli P, Antonelli A, Basolo F. Molecular diagnostics of fine needle aspiration for the presurgical screening of thyroid nodules. Current genomics. 2014;15(3):171-7.

2. Korean Central Cancer Registry, Annual report of cancer statistics in Korea in 2012.

3. Lundgren CI, Hall P, Dickman PW, Zedenius J. Clinically significant prognostic factors for differentiated thyroid carcinoma: a population-based, nested case-control study. Cancer. 2006;106(3):524-31.

4. Monacelli M, Lucchini R, Polistena A, Triola R, Conti C, Avenia S, et al. Total thyroidectomy and central lymph node dissection. Experience of a referral centre for endocrine surgery. G Chir. 2014;35(5-6):117-21.

5. Shah JP. Cervical lymph node metastases--diagnostic, therapeutic, and prognostic implications. Oncology (Williston Park). 1990;4(10):61-9; discussion 72, 6.

6. Qubain SW, Nakano S, Baba M, Takao S, Aikou T. Distribution of lymph node micrometastasis in pN0 well-differentiated thyroid carcinoma. Surgery. 2002;131(3):249-56.

7. Jung JW, Choi JY, Lee KE, Park KW. Immunohistochemical and Molecular Markers Associated with Differentiated Thyroid Carcinoma. Journal of Korean Thyroid Association. 2015;8(1):50.

8. Chung YS, Choe JH, Kang KH, Kim SW, Chung KW, Park KS, et al. Endoscopic thyroidectomy for thyroid malignancies: comparison with conventional open thyroidectomy. World J Surg. 2007;31(12):2302-6; discussion 7-8.

9. Lee KE, Choi JY, Youn YK. Bilateral axillo-breast approach robotic thyroidectomy. Surgical laparoscopy, endoscopy & percutaneous techniques. 2011;21(4):230-6.

10. Choi JY, Lee KE, Chung KW, Kim SW, Choe JH, Koo do H, et al. Endoscopic thyroidectomy via bilateral axillo-breast approach (BABA): review of 512 cases in a single institute. Surg Endosc. 2012;26(4):948-55.

11. Lee KE, Koo do H, Im HJ, Park SK, Choi JY, Paeng JC, et al. Surgical completeness of bilateral axillo-breast approach robotic thyroidectomy: comparison with conventional open thyroidectomy after propensity score matching. Surgery. 2011;150(6):1266-74.

12. Lee KE, Rao J, Youn YK. Endoscopic thyroidectomy with the da Vinci robot system using the bilateral axillary breast approach (BABA) technique: our initial experience. Surgical laparoscopy, endoscopy & percutaneous techniques. 2009;19(3):e71-5.

13. Lee KE, Kim E, Koo do H, Choi JY, Kim KH, Youn YK. Robotic thyroidectomy by bilateral axillo-breast approach: review of 1,026 cases and surgical completeness. Surg Endosc. 2013;27(8):2955-62.

14. Sakorafas GH, Stafyla V, Bramis C, Kotsifopoulos N, Kolettis T, Kassaras G. Incidental parathyroidectomy during thyroid surgery: an underappreciated complication of thyroidectomy. World J Surg. 2005;29(12):1539-43.

15. Dionigi G, Lombardi D, Lombardi CP, Carcoforo P, Boniardi M, Innaro N, et al. Intraoperative neuromonitoring in thyroid surgery: a point prevalence survey on utilization, management, and

documentation in Italy. Updates in surgery. 2014;66(4):269-76.

16. McHenry CR, Speroff T, Wentworth D, Murphy T. Risk factors for postthyroidectomy hypocalcemia. Surgery. 1994;116(4):641-7; discussion 7-8.

17. Sasson AR, Pingpank JF, Jr., Wetherington RW, Hanlon AL, Ridge JA. Incidental parathyroidectomy during thyroid surgery does not cause transient symptomatic hypocalcemia. Arch Otolaryngol Head Neck Surg. 2001;127(3):304-8.

18. Marshall MV, Rasmussen JC, Tan IC, Aldrich MB, Adams KE, Wang X, et al. Near-Infrared Fluorescence Imaging in Humans with Indocyanine Green: A Review and Update. Open Surg Oncol J. 2010;2(2):12-25.

19. Chi C, Du Y, Ye J, Kou D, Qiu J, Wang J, et al. Intraoperative imaging-guided cancer surgery: from current fluorescence molecular imaging methods to future multi-modality imaging technology. Theranostics. 2014;4(11):1072-84.

20. Suh YJ, Choi JY, Chai YJ, Kwon H, Woo JW, Kim SJ, et al. Indocyanine green as a near-infrared fluorescent agent for identifying parathyroid glands during thyroid surgery in dogs. Surg Endosc. 2014.

21. Alander JT, Kaartinen I, Laakso A, Patila T, Spillmann T, Tuchin VV, et al. A review of indocyanine green fluorescent imaging in surgery. Int J Biomed Imaging. 2012;2012:940585.

22. Keaveny TV, FitzGerald P. Selective parathyroid staining. Lancet. 1968;2(7562):284.

23. Grubbs EG, Mittendorf EA, Perrier ND, Lee JE. Gamma probe identification of normal parathyroid glands during central neck surgery can facilitate parathyroid preservation. Am J Surg. 2008;196(6):931-5; discussion 5-6.

24. Zwas ST, Czerniak A, Boruchowsky S, Avigad I, Wolfstein I. Preoperative parathyroid localization by superimposed iodine-131 toluidine blue and technetium-99m pertechnetate imaging. J Nucl Med. 1987;28(3):298-307.

25. Dudley NE. Methylene blue for rapid identification of the parathyroids. Br Med J. 1971;3(5776):680-1.

26. Patel HP, Chadwick DR, Harrison BJ, Balasubramanian SP. Systematic review of intravenous methylene blue in parathyroid surgery. Br J Surg. 2012;99(10):1345-51.

27. Pollack G, Pollack A, Delfiner J, Fernandez J. Parathyroid surgery and methylene blue: a review with guidelines for safe intraoperative use. Laryngoscope. 2009;119(10):1941-6.

28. Shimizu S, Kamiike W, Hatanaka N, Yoshida Y, Tagawa K, Miyata M, et al. New method for measuring ICG Rmax with a clearance meter. World J Surg. 1995;19(1):113-8; discussion 8.

29. Lee Z, Moore B, Giusto L, Eun DD. Use of indocyanine green during robot-assisted ureteral reconstructions. Eur Urol. 2015;67(2):291-8.

30. Frangioni JV. In vivo near-infrared fluorescence imaging. Curr Opin Chem Biol. 2003;7(5):626-34

31. Holt D, Okusanya O, Judy R, Venegas O, Jiang J, DeJesus E, et al. Intraoperative near-infrared

imaging can distinguish cancer from normal tissue but not inflammation. PLoS One. 2014;9(7):e103342.

32. Hill TK, Abdulahad A, Kelkar SS, Marini FC, Long TE, Provenzale JM, et al. Indocyanine green-loaded nanoparticles for image-guided tumor surgery. Bioconjug Chem. 2015;26(2):294-303.

요약(국문초록)

배경: 양측 겨드랑이-유방 접근법 (바바) 로봇 갑상선 절제술은 2008년 도입된 후로 외과적인 면과 미용적인 면에서 양호한 성적을 보였다. 바바 로봇 수술 건수가 증가하면서 부갑상선과 되돌이 후두 신경을 효과적으로 찾아서 보존하기 위한 많은 시도가 있었다. 이에 본 연구에서는 바바 로봇 갑상선 절제술 환자에서 근적외선 하 인도시아닌 그린의 형광을 이용하여 부갑상선을 확인하고 보존하고자 하였다.

방법: 본 연구에 앞서 최적의 인도시아닌 그린 용량을 정하기 위하여 14명의 환자를 대상으로 예비 연구를 진행하였다. 각기 다른 인도시아닌 용량 (1 mg, 2.5 mg, 5 mg, 7.5 mg, 10 mg, 15 mg, 20 mg)을 주입한 7개군으로부터 형광의 양상과 최적의 하부 부갑상선 확인 시점을 평가하였다. 인도시아닌 그린 형광 하에서 부갑상선으로 추정되는 조직의 생화화적 확인을 위해 9명의 환자에서 수술 중 부갑상선 호르몬 검사를 시행하였다. 본 연구는 2014년 9월부터 2015년 8월까지 분당 서울대 병원에서 갑상선 암으로 진단되어 바바 로봇 갑상선 절제술을 받은 22명의 환자를 동의 하에 대상으로 하였다. 각 환자에게 10 mg의 인도시아닌 그린을 갑상선 피대근 박리 후 정맥을 통해 주입하였다. 다빈치 로봇에 장착된 근적외선 영역의 조명기 (805 nm)와 여과기 (825 nm)를 갖춘 'Firefly' 시스템에 의해 인도시아닌 그린이 자극되어 녹색의 형광을 발산하는 원리를 이용하였다. 부갑상선과 갑상선에 형광이 보이기 시작하는 시점과 사라지는 시점을 관찰하여 최적의 부갑상선 발견 가능 시간과 형광의 지속시간을 계산하였다. 동시에 되돌이 후두 신경의 형광 양상도 관찰하였다. 성향 점수 매칭 기법에 의하여 대조군을 설정하여 수술 합병증을 비교 분석하였다. 환자의 인구학적, 임상 및 병리적 특성도 같이 분석하였다.

결과: 예비 연구에서 10 mg 인도시아닌 그린 용량에서 부갑상선이 효과적으로 확인됨을 관찰하였고, 수술 중 부갑상선 호르몬 검사에서는 형광 하에서 부갑상선 추정

조직이 실제 부갑상선이었음을 9명 환자에서 전부 확인하였다. 부갑상선과 갑상선에서 형광이 나타나기까지 평균 경과시간은 각각 203 ± 89 초 (범위: 125-331 초), 207 ± 112 초 (범위: 130-356 초)가 걸렸으며, 형광지속시간은 각각 20.8 ± 6.0 분 (범위: 16.6-35.8 분), 20.1 ± 7.3 분 (범위: 15.5-33.8 분)이었다. 22명 환자에서 연구 대상이 된 총 32개의 부갑상선 전부가 갑상선보다 더 집중적이며 강한 조영 양상을 보였으며 일찍 조영 되었다. 되돌이 후두 신경은 인도시아닌 그린 형광을 보이지 않아 주변 조직과 대조적으로 관찰할 수 있었다. 수술 후 한 명의 환자에서 경도의 일시적 부갑상선 기능 저하증이 관찰되었고, 되돌이 후두 신경 마비는 없었다. 환자군은 대조군에 비해 유의하게 낮은 일시적 부갑상선 기능 저하 발생률 (4.5 % vs 50 %, $P < 0.001$) 과 비의도적 부갑상선 절제율 (0 % vs 38.6 %, $P < 0.001$)을 보였다.

결론: 본 연구 결과에 따르면 바바 로봇 갑상선 절제술 환자에서 인도시아닌 그린의 형광을 이용한 부갑상선 보존은 효과적이며 안전한 것으로 보인다. 되돌이 후두 신경은 형광을 보이지는 않으나 주변과 대비되어 관찰이 비교적 용이하였다. 향후 임상에서의 많은 활용과 성과를 기대한다.

……

주요어: 양측 겨드랑이-유방 접근법 (바바), 로봇 갑상선 절제술, 부갑상선, 인도시아닌 그린 형광, 근적외선

학 번: 2013-23494