수의학석사 학위논문

Detection of A Novel Cetacean Papillomavirus in a Common Dolphin in Jeju island, Republic of Korea

참돌고래에서의 해양포유류 파필로마바이러스 검출 및 특성분석

2020년 2월

서울대학교 대학원
수의학과 수의병인생물학 및 예방수의학 전공
한 세 진

Detection of A Novel Cetacean Papillomavirus in a Common Dolphin in Jeju Island, Republic of Korea

By

Se Jin Han

February, 2020

Veterinary Pathobiology and Preventive Medicine

Department of Veterinary Medicine

The Graduate School of Seoul National University

Detection of A Novel Cetacean Papillomavirus in a Common Dolphin in Jeju Island, Republic of Korea

By

Se Jin Han

Supervisor: Prof. Se Chang Park, D.V.M., Ph.D.

A dissertation submitted to the faculty of the Graduate School of Seoul National University in partial fulfillment of the requirements for the degree of Master in Veterinary Pathobiology and Preventive Medicine

February, 2020

Veterinary Pathobiology and Preventive Medicine

Department of Veterinary Medicine

The Graduate School of Seoul National University

Detection of A Novel Cetacean Papillomavirus in a Common Dolphin in Jeju Island, Republic of Korea

Se Jin Han
(Supervised by Professor Se Chang Park)
Department of Veterinary Pathobiology and Preventive Medicine
College of Veterinary Medicine
The Graduate School of Seoul National University

ABSTRACT

Papillomaviruses are oncogenic DNA viruses that infect epithelial and mucosal cells. To date more than 140 papillomaviruses with a proven capacity to infect humans and animals have been identified. Usually papillomaviruses form a balanced relationship with the host, such that the lesion does not progress to cause serious clinical problems. Notably however, cases of malignant transformation of benign tumors have been reported in several animal species, such as cattle, rabbits and dogs. In recent decades, papillomavirus has been detected in free-ranging marine mammals in the North

Sea of the Atlantic Ocean and the Southeast Pacific Ocean. Cetacean papillomavirus should be monitored constantly because it may affect the population dynamics of each host species by negatively affecting reproduction. Furthermore, the association of malignant transformation of papillomavirus infection in Atlantic bottlenose dolphin has been recently proposed. This report describes the case of a common dolphin that was found dead with proliferative skin lesions. Necropsy revealed enlarged mesenteric lymph node, left adrenal gland and left testis. Skin histopathology revealed typical characteristics of papilloma, incuding hyperkeratosis, koilocytosis, ballooning degeneration and inclusion bodies. In the testis and lymph node, multiple pleomorphic cells with abundant fibrous connective tissues were observed. Sequenced PCR products were closely related to *Omikronpapillomavirus* spp. isolated from the common bottlenose dolphin and Burmeister's porpoise. To our knowledge, this is the first report of oral and genital papillomatosis with concurrent metastatic neoplasia in common dolphin. The present study suggests that further investigations should focus on isolation of viruses and determination of their pathogenic potential. The distribution and emergence of papillomaviruses in Korean coastal common dolphin populations and the role of the virus as a possible cause of mortality should also be studied in the respect of conservation of marine ecosystem.

Keywords: Cetacean papillomavirus, Common dolphin (*Delphinus delphis*), Marine mammal infectious disease, Neoplasia

Student number: 2017-26024

CONTENTS

ABBREVIATIONS

BPV	*Bovine papillomavirus*
CfPV	*Canine familiaris papillomavirus*
DdPV	*Delphinus delphis papillomavirus*
DcPV	*Delphinus capensis papillomavirus*
HPV	*Human papillomavirus*
PCR	Polymerase Chain Reaction
PCV	*Porcine circovirus*
PsPV	*Phocoena spinipinnis papillomavirus*
PpPV	*Phocoena phocoena papillomavirus*
RhPV	*Rhesus papillomavirus*
TtPV	*Tursiops truncus papillomavirus*
TmPV	*Trichechus manatus papillomavirus*
ZcPV	*Zalophus californianus papillomavirus*

INTRODUCTION

Papillomaviruses are oncogenic DNA viruses that infect epithelial and mucosal cells. To date, more than 140 papillomaviruses with a proven capacity to infect humans and animals have been identified. The non-human papillomaviruses have been found in 54 different animal species, most of which are mammals but sometimes birds and reptiles [34]. In mammals, benign warts or papillomas on skin are the most common clinical signs of papilloma infection, but they can also occur in the mucous layers of the respiratory, digestive and genital organs [7]. Usually papillomaviruses form a balanced relationship with host, such that the lesion does not progress to cause serious clinical problems. Notably however, cases of malignant conversion of formerly benign tumor have been reported in humans [28], and several mammalian species, including cattle, rabbits and dogs [6][7][27][31]. Especially, animals with certain immunosuppressive factors, such as carcinogens or diseases, are more likely to show the transformation [7].

In last decades, papillomavirus-associated lesions in marine mammals have been discovered and reported [21][45]. Followed by a Van Bressem *et al.*'s (1999, 2007, 2009) reports in Burmeister's porpoise (*Phocoena spinipinnis*), dusky dolphin (*Lagenorhynchus obscurus*), and harbor porpoises (*Phocoena phocoena*), Bossart *et al.* (1996) studied the virus in Killer whale

(*Orcinus orca*), Rehtanz *et al*. (2006) detected the virus from Atlantic bottlenose dolphin (*Tursiops truncatus*), and Rivera *et al*. (2012) studied the virus in California sea lions (*Zalophus californianus*) [2][35][39][44] [46][47]. The viruses were identified by molecular approaches, immunohistochemistry, and electron microscopy. Most reported cases of papillomavirus in marine mammals have been limited to cutaneous and mucosal epithelium infections. Nevertheless, an association between malignant neoplasia and papilloma in Atlantic bottlenose dolphin was recently proposed [3]. The researchers implied that the viral infection may have a negative impact on population dynamics on the species, by negatively affecting reproduction and/or by increasing natural mortality [29].

Coastal odontocetes are a representative sentinel species and have been studied as indicators of ocean pollution around the world [4][14][20][29] [38][42]. The common dolphin (*Delphinus delphis*) is known as one of the most popular and representative odontocetes in Korean coastal water. Studies have been conducted to understand the role of these animals in ecosystem and investigate associations between ocean contamination and the concentration of heavy metals and persistent organic phosphates in the tissues of animals [1][19][23]. In contrast, research focused on diseases and epidemiology is insufficient.

The current study describes the case of a common dolphin found dead

on the coast of Jeju Island in the Republic of Korea, with papillomavirus-associated skin lesions. In addition, this study suggests that further investigations should focus on the isolation of viruses and determination of their pathogenic potential and capacity to cause mortality.

MATERIALS & METHHODS

Sample collection

Multiple cauliflower-like proliferative skin lesions were observed on a male common dolphin found dead on the northeast coast of Jeju Island in January 2019 (Fig. 1). Selected skin lesions around the genital, abdominal and oral regions were excised in appropriate size and fixed in 10% neutrally-buffered formalin immediately after the animal was found for histopathologic study. After skin sample collection, the animal was frozen at -20℃ for further post-mortem examinations.

During necropsy, tissue samples including typical skin lesions, multiple lymph nodes, liver, kidney, and testis were collected under sterile conditions and immediately stored at -80℃ for DNA and RNA extraction via standard molecular diagnostic protocols. Enlarged left testis and intra/retroperitoneal lymph nodes were collected and fixed in 10% neutrally-buffered formalin for histopathologic analysis even though the tissues had been frozen. Routine methods were used to embed the formalin-fixed samples in paraffin blocks. Paraffin-embedded sections were sliced at 5μm, mounted on glass slides, stained with hematoxylin and eosin and then examined with a light microscope. One set of unstained slides was sent to University Georgia, Athens to perform immunohistochemistry analysis.

Molecular analysis

Nucleic acid was extracted using the DNeasy Blood and Tissue Kit (Qiagen, Valencia, CA) in accordance with the manufacturer's instructions for animal tissue. DNA extraction preparations were stored at -20℃ prior to polymerase chain reaction (PCR) analysis. Considering the similarity between skin or genital lesions reported in other marine mammals, multiple PCR primers were selected. For detection of herpesvirus, poxvirus, papillomavirus and lobomycosis, PCR was conducted using previously established protocols [5][8][10][13][22][24][33][41][48]. PCR products were separated and visualized via electrophoresis in 1.5% agarose gels stained with StaySafe Nucleic Acid Gel Stain (Real Biotech Corporation, Taipei, Taiwan). Sequencing and cloning were performed by the Sequencing-Service Laboratory of Macrogen in Korea. Nucleotide and protein similarities were searched and analyzed via NCBI BLAST GenBank DNA database server. Sequence similarities were then investigated using ClustalW alignments comparing L1 gene sequences with corresponding gene sequences from previously characterized papillomaviruses. A phylogenetic tree was constructed by MEGA X using the Neighbor-joining method with other papillomavirus sequences. Missing data or gaps were completely deleted, and phylogeny was evaluated using 1,000 bootstrap replicates.

RESULTS

Macroscopic and microscopic pathology

The total body length of the animal (242.1) and well-worn teeth indicated that it had reached the age of sexual maturity [30]. Nineteen skin lesions were scattered over its body from snout to fluke. The most prominent ones were observed on left oral area and around anus. (Fig. 2). The size of the lesions was varied from small (1.2 x 1.3 cm) to large (24.5 x 22.0 cm). The maximum length dimension of affected skin was generally < 10 cm, but that of the genital lesions were greater than 24 cm. All skin lesions were sessile and had broad and diffused margins. The major lesions around the genital and oral areas exhibited firm verrucous morphology with a lot of fine fissures, and hemorrhaging, while most of the small lesions had little to no signs of bleeding and/or fissures. Histologically, the lesions were characterized by significant epithelial hyperplasia. Elongation and anastomosis of the rete pegs was observed in conjunction with fibrovascular connective tissues. Pyknotic nucleus and ballooning degeneration of keratocytes were also identified. A few basophilic intranuclear inclusion bodies were detected in the outer layers of the stratum spinosum (Fig. 3).

During necropsy abnormally enlarged organs in peritoneal cavity were identified, including left adrenal gland (6.6 x 4.8 cm) adhered to mesenteric

lymph node (24.7 x 22.7 x 16.1 cm), and left testis (37.6 x 11.6 cm). The outer surface of the organs was granulomatous (Fig. 4). Multiple gray to white nodules were detected on cut surfaces of left testis. Microscopically, the nodules were mostly composed of pleomorphic cells. The cells exhibited a diffuse and unorganized arrangement with anisokaryosis and anisocytosis (Fig. 5). On the other hand, right testicle exhibited an atrophic appearance grossly and measured 18.7 x 9.1 cm. Histolopathologically, the right testis exhibited regressive seminiferous tubules with a moderate to abundant amount of interstitial tissue composed of fibrocytes (Fig. 5).

The mesenteric lymph node was remarkably enlarged and even displaced the intestines. The mass adhered to the outer epithelium of the intestine and mesentery, suggesting that normal bowel movement had not been possible. On cut surfaces there was loss of normal architecture with evident angiogenesis. Multiple irregular firm gray to white nodules were observed with interspersed areas of hemorrhage, similar to the gross observations in the left testis. Histopathologically pleomorphic cells with abundant fibrous connective tissues were observed (Fig. 6). The left adrenal gland was attached to the lymph node such that it was hard to distinguish the normal anatomy of each organ. Immunohistochemically, all lesions were negative for bovine papillomavirus 1. Positive control tissues from Californian sea lions were included in those tests, to confirm the negative results in the study samples.

Molecular analysis

No herpesvirus, poxvirus or yeast DNA were obtained from all tissue samples, but papillomavirus was detected in skin samples using a pair of human papillomaviruses (HPV) PCR primers designed to amplify the L1 open reading frame. Full analysis of the primary PCR product revealed a 501-base pair nucleotide fragment of the papillomavirus L1 capsid protein gene and deposited into GenBank. (accession number MN536507). Following detection of the new virus, tentatively named *Delphinus capensis papillomavirus 1* (DcPV1). The sequences shared 70% nucleotide identity and 99% query coverage with *Tursiops truncatus papillomavirus* (TtPV) 9 isolated from an Indian River Lagoon bottlenose dolphin (*Tursiops truncatus*) (GenBank accession number MG905161.1). In multiple sequence alignment and phylogenetic tree analyses DcPV1 is in a clade of *Omikrnpapillomavirus* which includes TtPV5, TtPV6, TtPV9, *Phoconea phoconea papillomavirus 1* (PpPV1) and *Phocoena spinipinnis papillomavirus 1* (PsPV1) (GenBank accession numbers JN709470.1, JN709471.1, MG905161.1, GU117621.1 and AJ006302.1) (Fig. 7).

DISCUSSION

Histopathological characteristics of skin lesions

Benign tumors caused by papillomaviruses can be classified into several types: papillomas, viral plaques, and fibropapillomas, including sarcoids. One of the common clinical characteristic of cutaneous papilloma infection is an exophytic papuliferous benign mass. However, other papilloma can be observed with flat and plaque-like lesions which lack pronounced projections. Typically, papilloma can be defined by histopathology features such as diffuse epidermal hyperplasia (acanthosis), variable degrees of hyperkeratosis, ballooning degenerations, and degenerated keratinocytes (koilocytosis) [25]. In the present case, significant acanthosis and pyknotic nucleus of keratinocytes were observed. Ballooning degeneration and a few basophilic intranuclear inclusion bodies were also detected. Elongation and anastomosis of rete ridges was observed in conjunction with fibrovascular connective tissue.

Although immunohistochemistry results were negative, there have been some papillomavirus case studies of animals and humans in which immunohistochemistry result were negative for specific papillomavirus antibody [3][6][18]. According to previous studies, the lack of specific antibody cross reactivity or the fact that wildlife papillomaviruses have not yet been

studied as thoroughly as it has in HPV has also been pointed as one of the causes of the negative results. For example, in the bottlenose dolphin oral and genital tumor cases, genus-specific papillomavirus antigens were not identified immunohistochemically. However, papillomavirus had not been ruled out as an etiological agent based on its unique gross and histopathological findings [3]. In the present study, despite the lack of concordance, molecular confirmation via PCR together with the distinctive features of gross pathology and histopathology suggest that the skin lesions were caused by papillomavirus infection.

Differential diagnosis of abdominal neoplasm

There are several cases of malignant transformation of papillomavirus in human and animals like cattle, rabbits and dogs. In cattle, *Bovine papillomavirus 4* (BPV4) causes urinary bladder cancers and alimentary canal carcinoma when carcinogen is present as an environmental cofactor [6]. Cottontail rabbit papillomavirus is involved in the development of skin carcinoma in domestic rabbits [31]. In human, certain high-risk strains are known to be the principal cause of invasive and malignant cervical cancer [28]. Also, other strains of HPVs have been shown to be associated with anogenital carcinoma [43]. According to previous studies, the probability of such transformation is higher in immune-compromised individuals [7].

In the present study, DNA of papillomavirus was not detected in the peritoneal masses. It cannot be completely ruled out as one of the components of pathogenesis however, because it has been repeatedly demonstrated that there is a robust correlation between persistent papillomavirus-induced lesions and progression to cancer. The previous studies implied that the existence of virus is only necessary for the induction of lesion but may not continue for ongoing disease processes. For instance, the esophageal cancer in cattle which was caused by bovine papillomavirus 4 shows complete loss of viral genome in tumor [6][37]. Therefore, it may be that papillomavirus genetic traces disappeared after the virus functioned as a carcinogen, as can reportedly occur with other papillomaviruses [6][34]. Nevertheless, it is also difficult to refute the hypothesis that intraperitoneal neoplasia that was previously present may have compromise the animal's immune function and caused severe skin papillomatosis. Because of the nature of wildlife cases, it is not easy to clearly identify the causal relationships and determine which diseases or condition precede another.

Even though additional examination such as complete blood cell count and bone marrow examination could not be performed, based on characteristics of macroscopic and microscopic pathology the left testicular mass was diagnosed as a Sertoli cell tumor. Sertoli cell tumors typically develop as a unilateral solid mass and can cause dramatic enlargement of the affected testis.

Because Sertoli cells can produce anti-Mullerian hormones, the tumor can be endocrinologically active and inhibit testosterone production [25]. This may lead to clinical signs such as contralateral testicular atrophy.

Because the gross pathology of mesenteric lymph node and left testis were similar and histopathologic results were consistent, it can be assumed that the cause of both masses can come from same origin – even though it was not possible to clarify the primary cause. There have been few reports of neoplasia in marine mammals. Among described neoplastic cases in cetaceans, testicular neoplasms are very uncommon [9][16][26][32]. Moreover, metastasis of Sertoli cell tumor is rare and usually confined to local lymph nodes. Notably however, there is the potential for metastatic testicular neoplasia in cetaceans. Estep et al. (2005) described a case of Sertoli cell tumor in a spotted dolphin that extended to retroperitoneal lymph nodes and the adrenal gland [11]. This indicates that neoplastic Sertoli cells may successfully reach intratesticular blood vessels and spread into lymphatic vessels and surrounding lymph nodes and organs. Although the number of reported cases is small, Sertoli cell tumors could be considered potentially metastasizing tumors in the cetacean species.

Molecular analysis of the cetacean papillomavirus

The papillomavirus genome is a double-stranded circular DNA molecule up to 8,000 base pairs in length. Despite wide diversity in host species,

different papillomaviruses have surprisingly similar overall genomic organization. The genome encodes several early proteins (E1, E2, E4, E5, E6, and E7) and two late proteins (L1 and L2). L1 and L2, responsible for the formation of structural capsid proteins, are present in all papillomaviruses. Papillomaviruses have been classified based on the sequence identity of L1 capsid proteins. L1 protein makes up approximately 90% of the virion [18]. Early proteins play other roles, such as viral DNA replication. E5, E6, and E7 are known to be oncoprotein involved in cell transformation [7]. BPV1 is a prototype that shows typical papillomavirus genome composition, with L1, L2, E1, E2, E4, E5, E6, and E7 open reading frames.

The cases of papillomatosis in cetaceans have been reported several times, but only a limited number of papillomavirus genome sequences have been identified and characterized [36][37]. So far, cetacean papillomaviruses have been classified into two clades; *Omikronpapillomavirus* and *Upsilonpapillomavirus*. If the nucleotide sequence similarities of L1 protein differ by more than 60%, it indicated that each virus belongs to a different genus. Since the sequence isolated in the present case showed more than 70% nucleotide identity with *Omikronpapillomavirus*, it could be assumed that the virus belongs to the same genus [39].

Although the whole genome sequence of the DcPV1 could not be analyzed, the overall genome structure of PsPV1, which is phylogenetically

close, is elucidated. [17][43] It consists of L1, L2, E2, E4, E1, and E6. E6 is known as a major oncoprotein of HPV16, a high-risk group of human cervical cancer, and has been shown to be involved in tumor development in BPV1 and BPV4, as well. Thus, *Omikronpapilomavirus*, presumed to belong to DcPV1 is also likely to proceed oncogenesis.

Moreover, the evidence of recombination and positive selection was only identified in cetacean species [17][40]. Thus, it may worth studying in depth about papillomavirus evolution on cetacean papillomavirus species than other types. It would be interesting to study the genetic changes between the strains identified in Asian ocean and those found in the US and European seas [39].

Significance of monitoring papillomavirus-related diseases

There are many previous publications which emphasized marine mammals as the indicators of diverse anthropogenic stressors [12][14][15][20][49][50]. In Korea, studies on the accumulation of heavy metals and organic contaminants in the organs of cetacean have been regularly conducted. On the other hand, researches on how these environmental factors affect their health are insufficient. Previous researches have shown that the adverse impact of anthropogenic pollutants on general health of marine mammals have been increasing since the industrial revolution [28][48][49]. Although a clear

scientific connection between anthropogenic pollution and diseases incidence was not established, a number of case reports and articles suggested that more diseased animals were found from polluted waters [8][14][37][45][46]. As environmental pollution increases, viral diseases, which previously did not develop clinical symptoms, have become emerging infectious diseases which negatively affect the role of the animals as a top predator. Therefore, elucidation of its' virulence and pathogenicity, and constant monitoring of the incidence should be done. Several researches especially have noted that skin lesions of cetacean could be act as a good health indicator of ecosystem under severe pressure as a result of anthropogenic activities [29][47]. The present study reports the first viral disease of cetacean in the ocean of Korea. This suggests that research in conjunction with the view of viral epidemiology should be started in addition to the existing studies on pollutants accumulation in cetacean.

To our knowledge, this is the first report of oral and genital papillomatosis infection concurrent with metastatic neoplasia in a common dolphin. This present study raises the need for further investigation, which should focus on virus isolation and identification of its pathogenic potential. Since the virus may have negative impacts on population dynamics by interfering sexual behavior, the distribution and emergence of papillomaviruses in Korean coastal cetaceans and the role of the virus as a possible cause of

mortality should also be studied in the respect of marine ecosystem conservation.

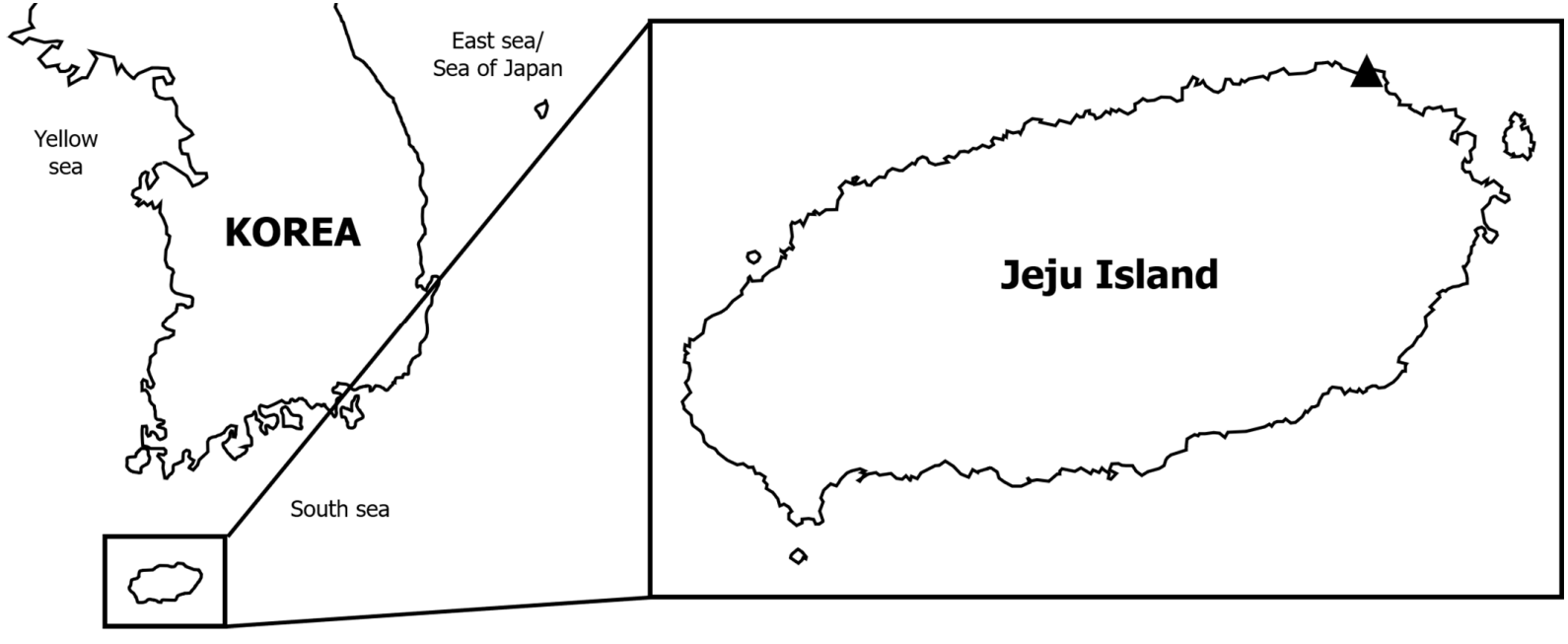

Figure 1. Geographic location of a common dolphin found dead in Korea.

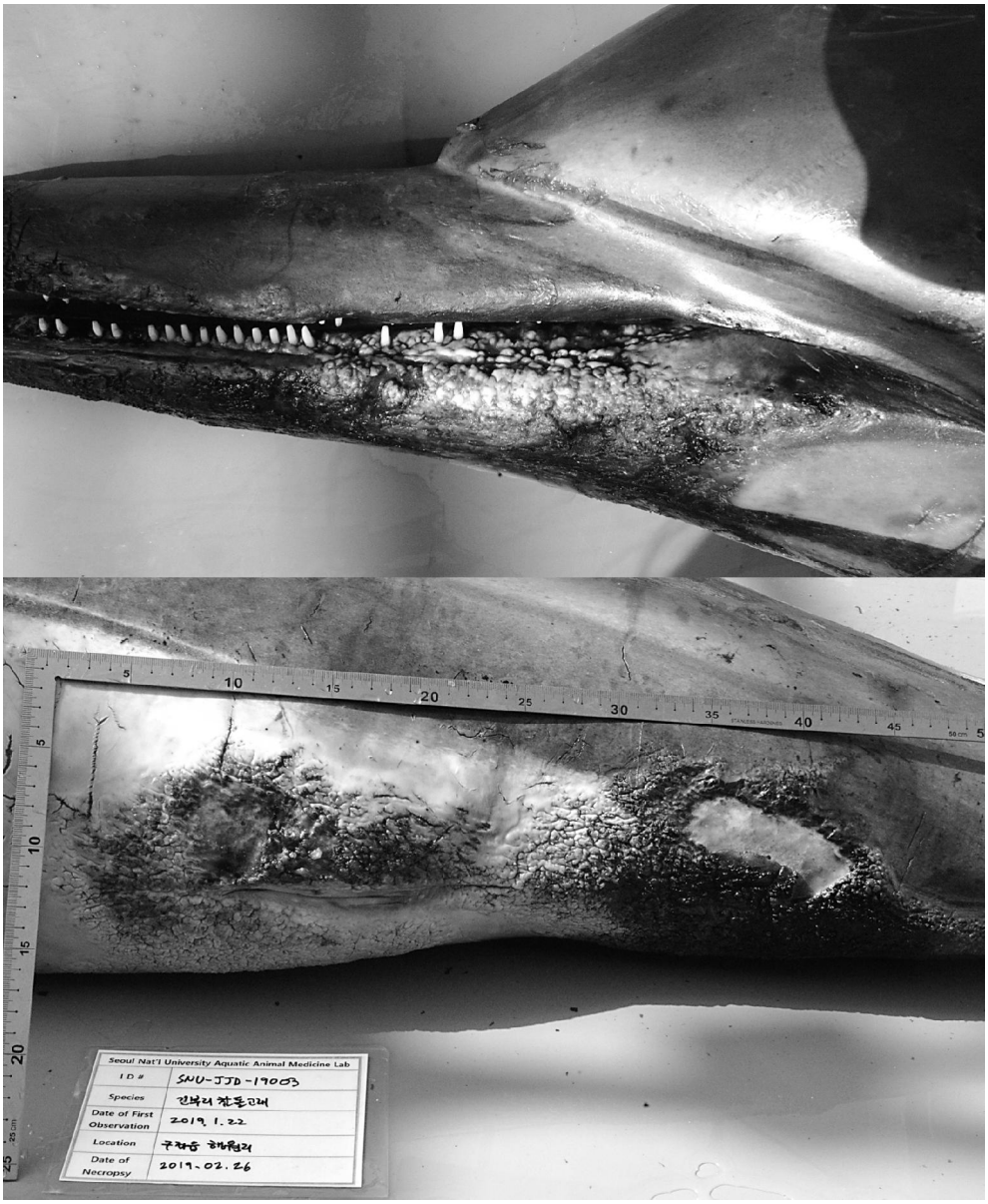

Figure 2. Gross pathology of the skin lesions in oral and genital areas.

Note the morphology of verrucous skin lesions with moderate to severe hemorrhage.

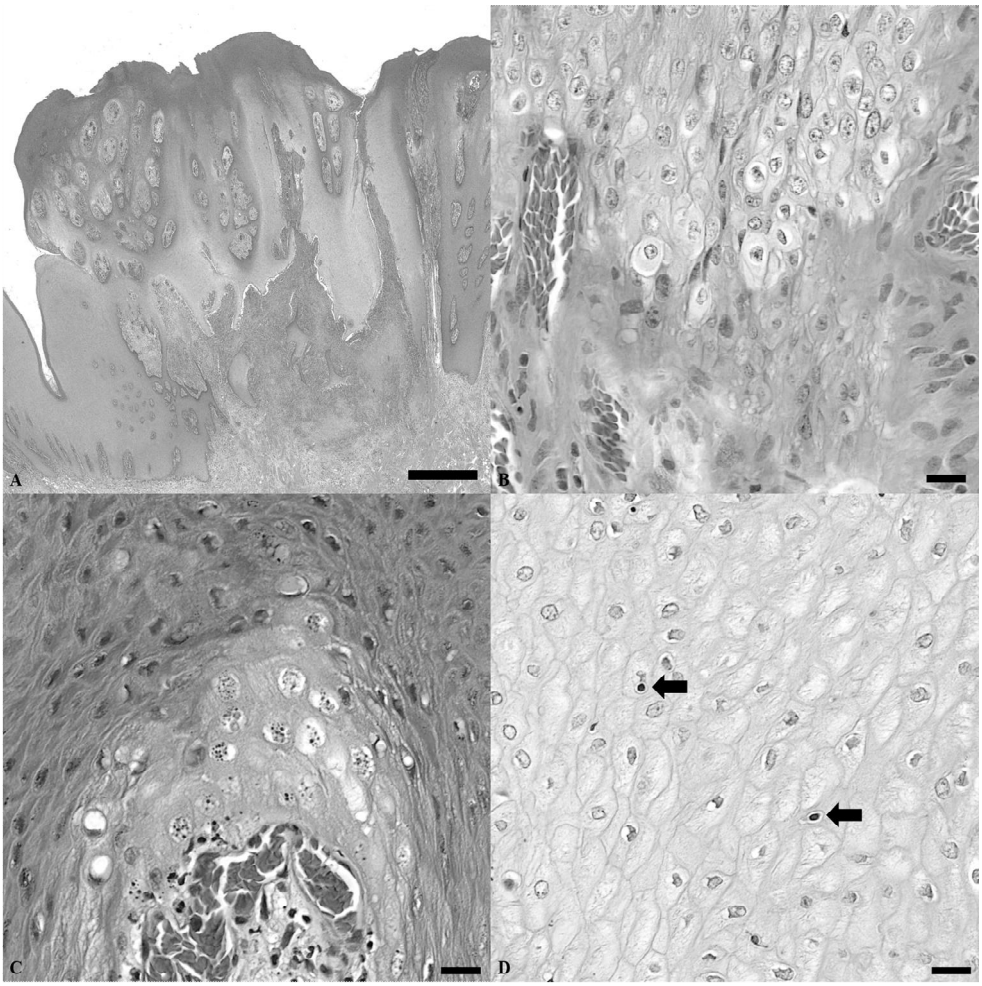

Figure 3. Histopathologic features of papillomatous skin lesions.

A. Elongation of rete ridges. Scale bar = 1000um. **B.** Multiple pyknotic nucleus were observed in conjunction with ballooning degeneration. Scale bar = 20um. **C.** Koilocytosis and ballooning degeneration. Scale bar = 20um. **D.** Inclusion bodies in stratum spinosum. Hematoxylin and eosin. Scale bar = 20um.

Figure 4. Gross morphology of abdominal masses.

A. Necropsy revealed enlarged mesenteric lymph node and left testis. **B.** Granulomatous appearance of enlarged mesenteric lymph node with attached adrenal gland. **C.** Cut surface of both testes. Note that multiple white to gray nodules on left testis.

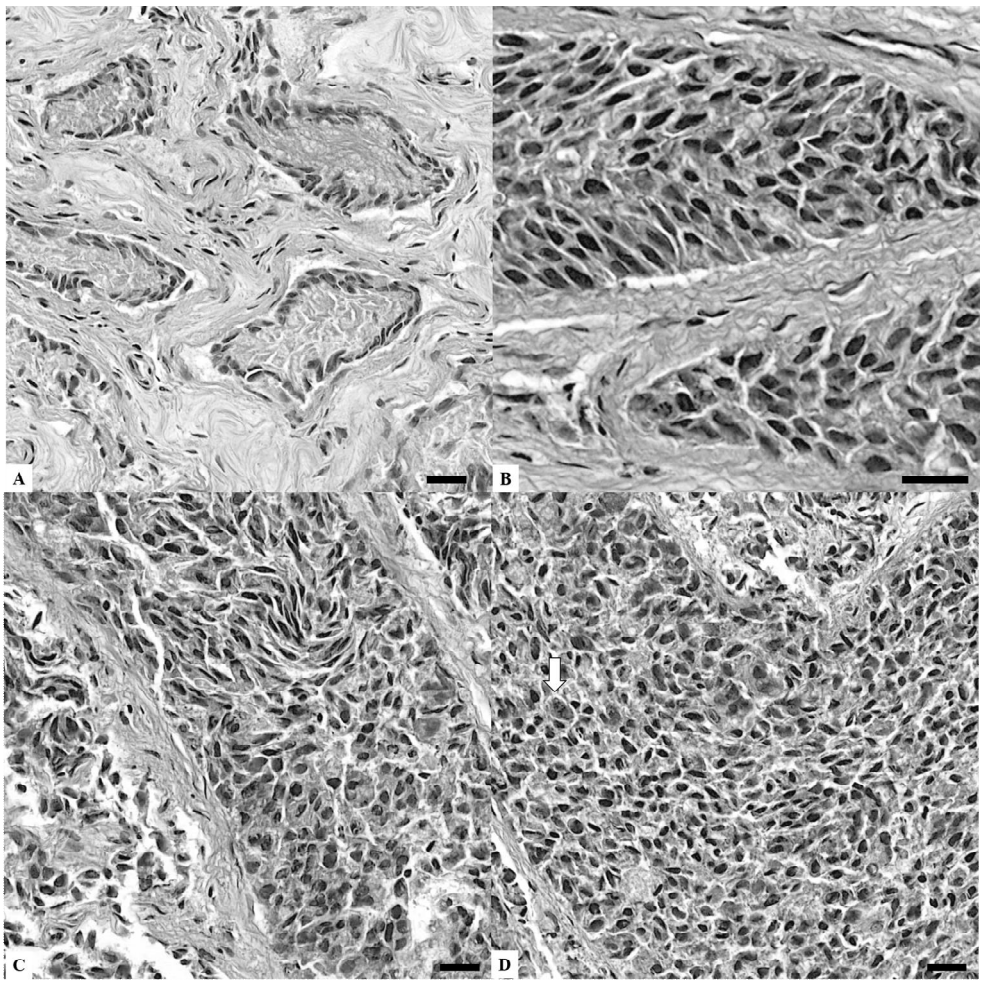

Figure 5. **Histopathologic characteristics of both testes.**

A: Right testis. B – D: Left testis. A. Right testis showed the features of regressive seminiferous tubules. Note that abundant amount of interstitial connective tissues composed of fibrocytes. Absence of spermatozoa and seminiferous tubules containing spermatogonia only. **B.** Sertoli cells with elongated to oval nuclei, and abundant eosinophilic cytoplasm. **C.** Note the number of pleomorphic cells in seminiferous tubule. **D.** Mitotic figure was detected in the seminiferous tubule.

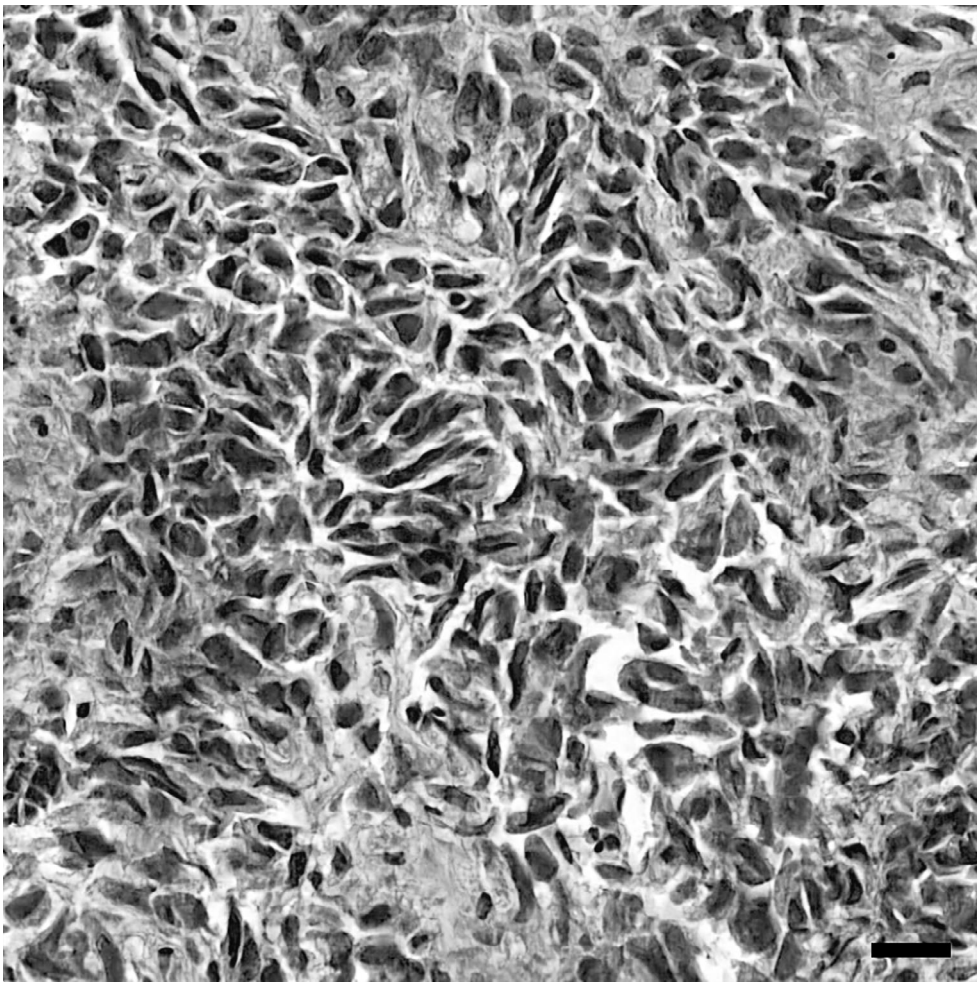

Figure 6. Microscopic features of mesenteric lymph node.

Pleomorphic cells with mild anisokaryosis. Hematoxylin and eosin.

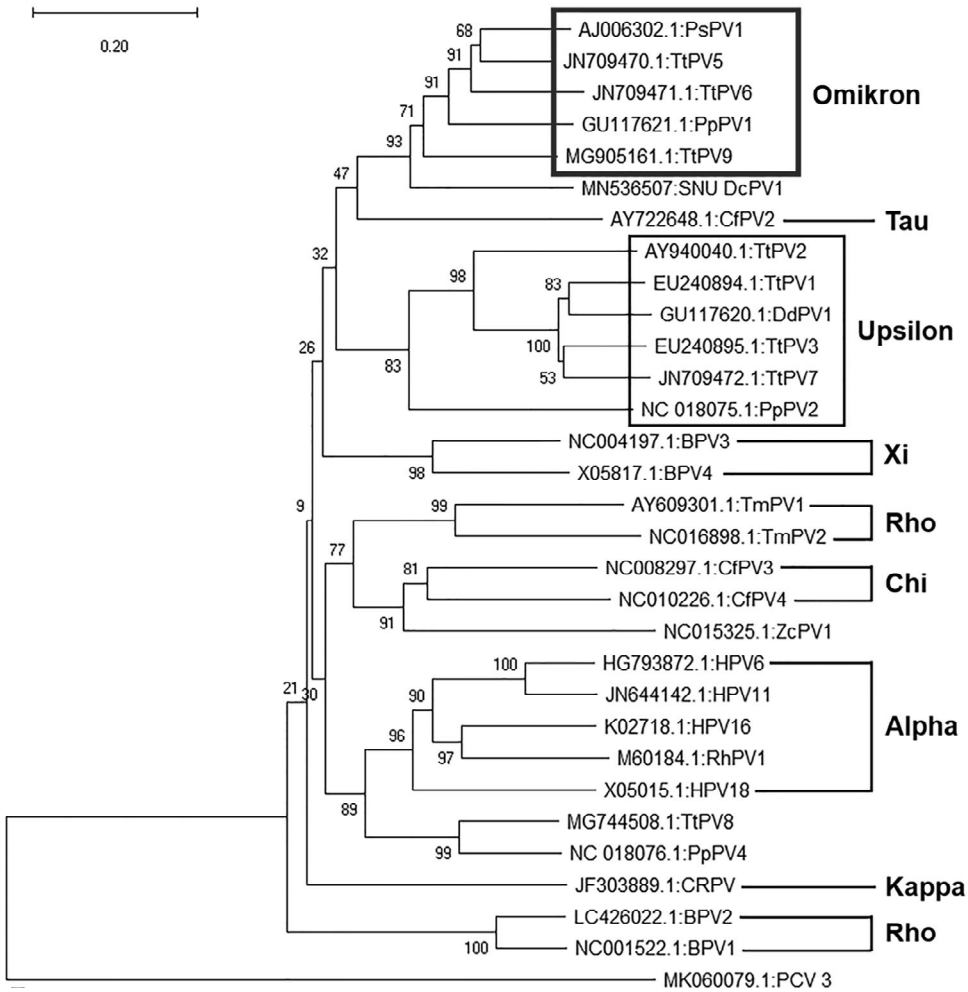

Figure 7. Neighbor-joining phylogram of L1 sequences of DcPV1 (indication for the sequence detected in this study) and other 29 selected sequences from papillomaviruses with one unrelated circovirus. At the branch nodes, values describe the confidence percentage out of 1,000 bootstrap replications. The papillomavirus types included PsPV1: *Phocoena spinipinnis papillomavirus* 1 AJ006302, TtPV5: *Tursiops truncates papillomavirus 5* JN709470.1, TtPV6: JN709471.1, PpPV1: *Phoconea phoconea papillomavirus 1* GU117621.1, TtPV9:

MG905161.1, CfPV2: *Canine familiaris papillomavirus 2* AY722648.1, TtPV2: AY940040.1, TtPV1: EU24894.1, DdPV1: *Delphinus delphis papillomavirus 1* GU117620.1, TtPV3: EU240895.1, TtPV7: JN709472.1, PpPV2: NC018075.1, BPV3: *Bovine papillomavirus 3* NC004197.1, BPV4: X05817.1, TmPV1: *Trichechus manatus papillomavirus 1* AY609301.1, TmPV2: NC016898.1, CfPV3: NC008297.1, CfPV4: NC010226.1, ZcPV1: *Zalophus californianus papillomavirus* 1 NC015325.1, HPV6: HG793872.1, HPV11: JN644142.1, HPV16: K02718.1, RhPV1: *Rhesus papillomavirus 1* M60184.1, HPV18: X05015.1, TtPV8: MG744508.1, PpPV4: NC018076.1, CRPV: *Cottontail Rabbit papillomavirus* JF303889.1, BPV2: LC426022.1, BPV1: NC001522.1, and PCV3: *Porcine circovirus 3* MK060079.1. Each name indicates host species.

REFERENCES

1. Ahn, S., Kim, H. W., Kim, S., Lee, Y. R., Park, K. J., Kim, D. N., & An, D. H. (2014). Diet of long-beaked common dolphin (*Delphinus capensis*) in the East Sea, Korea. *Animal Cells and Systems*, *18*(5), 340-350.
2. Bossart, G. D., Cray, C., Solorzano, J. L., Decker, S. J., Cornell, L. H., & Altman, N. H. (1996). Cutaneous papillomavirus-like papillomatosis in a killer whale (*Orcinus orca*). *Marine Mammal Science*, *12*(2), 274-281.
3. Bossart, G. D., Ghim, S. J., Rehtanz, M., & Goldstein, J. (2005). Orogenital neoplasia in Atlantic bottlenose dolphins (*Tursiops truncatus*). *Aquatic Mammals*, *31*(4), 473.
4. Bossart, G. D. (2011). Marine mammals as sentinel species for oceans and human health. *Veterinary Pathology*, *48*(3), 676-690.
5. Bracht, A. J., Brudek, R. L., Ewing, R. Y., Manire, C. A., Burek, K. A., Rosa, C., Beckmen, K.B., Maruniak, J.E. & Romero, C. H. (2006). Genetic identification of novel poxviruses of cetaceans and pinnipeds. *Archives of Virology*, *151*(3), 423-438.
6. Campo, M. S. (1997). Bovine papillomavirus and cancer. *The Veterinary Journal*, *154*(3), 175-188.
7. Campo, M. S. (2003). Papillomavirus and disease in humans and animals. *Veterinary and Comparative Oncology*, *1*(1), 3-14.

8. Cocumelli, C., Fichi, G., Marsili, L., Senese, M., Cardeti, G., Cersini, A., Ricci, E., Garibaldi, F., Scholl, F., Di Guardo, G. & Terracciano, G. (2018). Cetacean Poxvirus in two striped dolphins (*Stenella coeruleoalba*) stranded on the Tyrrhenian coast of Italy: Histopathological, ultrastructural, biomolecular and ecotoxicological findings. *Frontiers in Veterinary Science*, *5*, 219.
9. Diaz-Delgado, J., de los Monteros, A. E., Fernández-Maldonado, C., Arbelo, M., Quesada-Canales, O., Andrada, M., & Fernández, A. (2012). Mixed testicular neoplasia in a short beaked common dolphin *Delphinus delphis*. *Diseases of Aquatic Organisms*, *101*(3), 257-260.
10. Esperón, F., García-Párraga, D., Bellière, E. N., & Sánchez-Vizcaíno, J. M. (2012). Molecular diagnosis of lobomycosis-like disease in a bottlenose dolphin in captivity. *Medical Mycology*, *50*(1), 106-109.
11. Estep, J. S., Baumgartner, R. E., Townsend, F., Pabst, D. A., Mclellan, W. A., Friedlaender, A., Dunn, D.G. & Lipscomb, T. P. (2005). Malignant seminoma with metastasis, Sertoli cell tumor, and pheochromocytoma in a spotted dolphin (*Stenella frontalis*) and malignant seminoma with metastasis in a bottlenose dolphin (*Tursiops truncatus*). *Veterinary Pathology*, *42*(3), 357-359.
12. Flom, J. O., & Houk, E. J. (1979). Morphologic evidence of poxvirus in "tattoo" lesions from captive bottlenosed dolphins. *Journal of Wildlife Diseases*, *15*(4), 593-596.
13. Forslund, O., Antonsson, A., Nordin, P., Stenquist, B. O., & Hansson, B. G. (1999). A broad range of human papillomavirus types detected with a general

PCR method suitable for analysis of cutaneous tumours and normal skin. *Journal of General Virology*, *80*(9), 2437-2443.

14. Fury, C. A., & Reif, J. S. (2012). Incidence of poxvirus-like lesions in two estuarine dolphin populations in Australia: Links to flood events. *Science of the Total Environment*, *416*, 536-540.
15. Geraci, J. R., Hicks, B. D., & St Aubin, D. J. (1979). Dolphin pox: a skin disease of cetaceans. *Canadian Journal of Comparative Medicine*, *43*(4), 399.
16. Geraci, J. R., Palmer, N. C., & St. Aubin, D. J. (1987). Tumors in cetaceans: analysis and new findings. *Canadian Journal of Fisheries and Aquatic Sciences*, *44*(7), 1289-1300.
17. Gottschling, M., Bravo, I. G., Schulz, E., Bracho, M. A., Deaville, R., Jepson, P. D., Van Bressem, M.F., Stockfleth, E. & Nindl, I. (2011). Modular organizations of novel cetacean papillomaviruses. *Molecular Phylogenetics and Evolution*, *59*(1), 34-42.
18. Griffin, D. E., Howley, P. M., & Knipe, D. M. (2007). *Fields Virology* (Chapter 62. Papillomaviruses). Lippincott Williams & Wilkins.
19. Kim, S. G., Kim, S. S., Choi, H. G., & An, Y. R. (2011). Concentrations of trace metals in the tissues of long-beaked common dolphins (*Delphinus capensis*) in the East Sea, Korea. *Ocean Science Journal*, *46*(2), 55-62.
20. Kiszka, J., Van Bressem, M. F., & Pusineri, C. (2009). Lobomycosis-like disease and other skin conditions in Indo-Pacific bottlenose dolphins *Tursiops*

aduncus from the Indian Ocean. *Diseases of Aquatic Organisms*, *84*(2), 151-157.

21. Lambertsen, R. H., Kohn, B. A., Sundberg, J. P., & Buergelt, C. D. (1987). Genital papillomatosis in sperm whale bulls. *Journal of Wildlife Diseases*, *23*(3), 361-367.
22. Lecis, R., Tocchetti, M., Rotta, A., Naitana, S., Ganges, L., Pittau, M., & Alberti, A. (2014). First gammaherpesvirus detection in a free-living Mediterranean bottlenose dolphin. *Journal of Zoo and Wildlife Medicine*, *45*(4), 922-925.
23. Lee, S., Choi, S., Kim, J. H., Kim, H. W., & Sohn, H. (2018). Characteristics of the Cetacean Bycatch in Korean Coastal Waters from 2011 to 2017. *Korean Journal of Fisheries and Aquatic Sciences*, *51*(6), 704-713.
24. Li, Y., Meyer, H., Zhao, H., & Damon, I. K. (2010). GC content-based pan-pox universal PCR assays for poxvirus detection. *Journal of Clinical Microbiology*, *48*(1), 268-276.
25. Maxie, G. (2015). *Jubb, Kennedy & Palmer's Pathology of Domestic Animals*. (Volume 1. Chapter 6. Integumentary system., Volume 3. Chapter 5. Male genital system.) Elsevier Health Sciences.
26. Mawdesley-Thomas, L. E. (1975). Some aspects of neoplasia in marine animals. In *Advances in marine biology* (Vol. 12, pp. 151-231). Academic Press.

27. Munday, J. S., O'connor, K. I., & Smits, B. (2011). Development of multiple pigmented viral plaques and squamous cell carcinomas in a dog infected by a novel papillomavirus. *Veterinary Dermatology*, *22*(1), 104-110.

28. Muñoz, N., Bosch, F. X., De Sanjosé, S., Herrero, R., Castellsagué, X., Shah, K. V., Snijders, P.J. & Meijer, C. J. (2003). Epidemiologic classification of human papillomavirus types associated with cervical cancer. *New England Journal of Medicine*, *348*(6), 518-527.

29. Mouton, M., & Botha, A. (2012). *Cutaneous lesions in cetaceans: an indicator of ecosystem status* (pp. 123-150). InTech.

30. Murphy, S., Collet, A., & Rogan, E. (2005). Mating strategy in the male common dolphin (*Delphinus delphis*): what gonadal analysis tells us. *Journal of Mammalogy*, *86*(6), 1247-1258.

31. Nasseri, M., & Wettstein, F. O. (1984). Differences exist between viral transcripts in cottontail rabbit papillomavirus-induced benign and malignant tumors as well as non-virus-producing and virus-producing tumors. *Journal of Virology*, *51*(3), 706-712.

32. Newman, S. J., & Smith, S. A. (2006). Marine mammal neoplasia: a review. *Veterinary Pathology*, *43*(6), 865-880.

33. Rector, A., Van Doorslaer, K., Bertelsen, M., Barker, I. K., Olberg, R. A., Lemey, P., Sundberg, J.P. & Van Ranst, M. (2005). Isolation and cloning of the raccoon (*Procyon lotor*) papillomavirus type 1 by using degenerate

papillomavirus-specific primers. *Journal of General Virology*, *86*(7), 2029-2033.

34. Rector, A., & Van Ranst, M. (2013). Animal papillomaviruses. *Virology*, *445*(1-2), 213-223.
35. Rehtanz, M., Ghim, S. J., Rector, A., Van Ranst, M., Fair, P. A., Bossart, G. D., & Jenson, A. B. (2006). Isolation and characterization of the first American bottlenose dolphin papillomavirus: *Tursiops truncatus papillomavirus* type 2. *Journal of General Virology*, *87*(12), 3559-3565.
36. Rehtanz, M., Ghim, S. J., McFee, W., Doescher, B., Lacave, G., Fair, P. A., Reif, J.S., Bossart, G.D. & Jenson, A. B. (2010). Papillomavirus antibody prevalence in free-ranging and captive bottlenose dolphins (*Tursiops truncatus*). *Journal of Wildlife Diseases*, *46*(1), 136-145.
37. Rehtanz, M., Bossart, G. D., Fair, P. A., Reif, J. S., Ghim, S. J., & Jenson, A. B. (2012). Papillomaviruses and herpesviruses: Who is who in genital tumor development of free-ranging Atlantic bottlenose dolphins (*Tursiops truncatus*). *Veterinary Microbiology*, *160*(3-4), 297-304.
38. Reif, J. S., Mazzoil, M. S., McCulloch, S. D., Varela, R. A., Goldstein, J. D., Fair, P. A., & Bossart, G. D. (2006). Lobomycosis in Atlantic bottlenose dolphins from the Indian River lagoon, Florida. *Journal of the American Veterinary Medical Association*, *228*(1), 104-108.
39. Rivera, R., Robles-Sikisaka, R., Hoffman, E. M., Stacy, B. A., Jensen, E. D., Nollens, H. H., & Wellehan Jr, J. F. (2012). Characterization of a novel

papillomavirus species (ZcPV1) from two California sea lions (*Zalophus californianus*). *Veterinary Microbiology*, *155*(2-4), 257-266.

40. Robles-Sikisaka, R., Rivera, R., Nollens, H. H., Leger, J. S., Durden, W. N., Stolen, M., Burchell, J. & Wellehan Jr, J. F. (2012). Evidence of recombination and positive selection in cetacean papillomaviruses. *Virology*, *427*(2), 189-197.
41. Sierra, E., Díaz-Delgado, J., Arbelo, M., Andrada, M., Sacchini, S., & Fernández, A. (2015). Herpesvirus-associated genital lesions in a stranded striped dolphin (*Stenella coeruleoalba*) in the Canary Islands, Spain. *Journal of Wildlife Diseases*, *51*(3), 696-702.
42. Sohn, H., Park, K. J., An, Y. R., Choi, S. G., Kim, Z. G., Kim, H. W., An, D.H., Lee, Y.R. & Park, T. G. (2012). Distribution of whales and dolphins in Korean waters based on a sighting survey from 2000 to 2010. *Korean Journal of Fisheries and Aquatic Sciences*, *45*(5), 486-492.
43. Tornesello, M. L., Monaco, R., Nappi, O., Buonaguro, L., & Buonaguro, F. M. (2009). Detection of mucosal and cutaneous human papillomaviruses in oesophagitis, squamous cell carcinoma and adenocarcinoma of the oesophagus. *Journal of Clinical Virology*, *45*(1), 28-33.
44. Van Bressem, M. F., Cassonnet, P., Rector, A., Desaintes, C., Van Waerebeek, K., Alfaro-Shigueto, J., Van Ranst, M. & Orth, G. (2007). Genital warts in Burmeister's porpoises: characterization of *Phocoena spinipinnis papillomavirus* type 1 (PsPV-1) and evidence for a second, distantly related PsPV. *Journal of General Virology*, *88*(7), 1928-1933.

45. Van Bressem, M. F., Van Waerebeek, K., Piérard, G. E., & Desaintes, C. (1996). Genital and lingual warts in small cetaceans from coastal Peru. *Diseases of Aquatic Organisms*, *26*(1), 1-10.

46. Van Bressem, M. F., Van Waerebeek, K., & Raga, J. A. (1999). A review of virus infections of cetaceans and the potential impact of morbilliviruses, poxviruses and papillomaviruses on host population dynamics. *Diseases of Aquatic Organisms*, *38*(1), 53-65.

47. Van Bressem, M. F., Raga, J. A., Di Guardo, G., Jepson, P. D., Duignan, P. J., Siebert, U., Barrett, T., de Oliveira Santos, M.C., Moreno, I.B., Siciliano, S. & Aguilar, A. (2009). Emerging infectious diseases in cetaceans worldwide and the possible role of environmental stressors. *Diseases of Aquatic Organisms*, *86*(2), 143-157.

48. VanDevanter, D. R., Warrener, P., Bennett, L., Schultz, E. R., Coulter, S., Garber, R. L., & Rose, T. M. (1996). Detection and analysis of diverse herpesviral species by consensus primer PCR. *Journal of Clinical Microbiology*, *34*(7), 1666-1671.

49. Vos, J. G., Bossart, G., Fournier, M., & O'Shea, T. (Eds.). (2002). *Toxicology of Marine Mammals*. CRC Press.

50. Weijs, L., & Zaccaroni, A. (2016). Toxicology of marine mammals: new developments and opportunities. *Archives of Environmental Contamination and Toxicology*, *70*(1), 1-8.

국문 초록

참돌고래에서의 고래류 파필로마바이러스 검출 및 특성분석

한 세 진
서울대학교 대학원 수의학과
수의병인생물학 및 예방수의학 전공
(지도교수: 박 세 창)

파필로마바이러스는 DNA 바이러스로써, 상피와 점막층에 감염하여 종양을 발생시킬 수 있다. 현재까지 140여종 이상이 사람과 동물에 감염한다고 알려져 있으며 보통 피부 병변에 국한되고 파필로마나 사마귀 같은 양성 종양을 형성한다. 하지만 드물게 악성 종양으로 변이를 나타내기도 하는데, 동물에서는 소, 토끼 그리고 개에서 그러한 변이가 보고된 바 있다. 지난 20년간 10여종의 야생 고래류에서 파필로마바이러스가 확인되었으나 보고 지역은 대서양 북해와 태평양 남동해로 한정적이었다. 선행 연구에 따르면 해양포유류 파필로마바이러스 관련 질병의 임상

증상으로는 피부 및 점막 병변이 특징적이었지만 최근 만성 파필로마의 악성 변이 가능성이 대두되기도 했다. 본 연구에서는 한국의 제주도 해역에서 좌초하여 발견된 참돌고래의 증식성 피부병변에서 분리된 해양포유류 파필로마바이러스에 대한 연구 분석 결과를 보고한다. 피부병변 시료에서 PCR을 통해 얻어진 파필로마바이러스의 L1 gene이 검출되었으며, 이는 계통학적으로 Indian Liver Lagoon bottlenose dolphin에서 검출된 *Omikronpapillomavirus 1* 과 가장 유사한 것으로 확인되었다. 피부 병변의 조직병리학적 소견은 koilocytosis, ballooning degeneration, hyperkeratosis를 보였으며, 이는 파필로마바이러스 감염에 의해 나타날 수 있는 전형적인 소견이다. 좌측 고환 종괴에서는 핵대소부동과 세포대소부동이 보이는 다양한 형태의 Sertoli cell이 다수 관찰되었으며 장간막림프절 종괴에서도 비슷한 양상의 세포가 다수 관찰되었다. 본 연구는 아시아에서 최초로 해양포유류 파필로마바이러스를 분리하고 그 특성을 분석하였다는데 의의를 두고 있다. 또한 파필로마바이러스와 전이성 종양의 연계 가능성을 고찰하고자 하였다. 나아가 향후 한국 해역에 서식하는 해양포유류에서의 해당 바이러스의 분포

정도를 확인하고 잠재적인 병원성을 규명하는 등 추가 연구가 지속적으로 이루어져야 함을 제안한다.

핵심어: 해양포유류, 파필로마바이러스, 바이러스성 전염병, 참돌고래 (*Delphinus delphis*),

학번: 2017-26024

LIST OF ARTICLES

2019 Published

1. Saekil Yun, Jin Woo Jun, Sib Sankar Giri, Hyoun Joong Kim, Cheng Chi, Sang Geun, Kim, Sang Wha Kim, Jung Woo Kang, **Se Jin Han**, Jun Kwon, Woo Taek Oh, Se Chang Park*. Immunostimulation of *Cyprinus carpio* using phage lysate of Aeromonas hydrophila. *Fish and Shellfish Immunology*. 2019(86), 680-687.

2. Sang Wha Kim, **Se Jin Han**, Yonggab Kim, Jin Woo Jun, Sib Sankar Giri, Cheng Chi, Saekil Yun, Hyoun Joong Kim, Sang Guen Kim, Jeong Woo Kang, Jun Kwon, Woo Taek Oh, Jehyun Cha, Seunghee Han, Byeong Chun Lee, Taesung Park, Byung Yeop Kim, Se Chang Park*. Heavy metal accumulation in and food safety of shark meat from Jeju island, Republic of Korea. *PLOS ONE*, 14(3): e0212410.

3. Sib Sankar Giri, Jin Woo Jun, Saekil Yun, Hyoun Joong Kim, Sang Guen Kim, Jeong Woo Kang, Sang Wha Kim, **Se Jin Han**, Se Chang Park*. V. Sukumaran. Characterisation of Lactic Acid Bacteria Isolated from the Gut of *Cyprinus carpio* That May Be Effective Against Lead Toxicity. *Probiotics and Antimicrobial Proteins*. 11(1), 65-73.

4. Hyoun Joong Kim, Jin Woo Jun, Sib Sankar Giri, Saekil Yun, Sang Guen Kim, Sang Wha Kim, Jeong Woo Kang, **Se Jin Han**, Jun Kwon, Woo Taek Oh,

Hyung Bae Jeon, Cheng Chi, Dalsang Jeong, Se Chang Park*. Mass mortality in Korean bay scallop (*Argopecten irradians*) associated with *Ostreid Herpesvirus □1* μVar. *Transboundary and Emerging Diseases*. 2019 Apr 10

5. Sang Guen Kim, Jin Woo Jun, Sib Sankar Giri, Saekil Yun, Hyoun Joong Kim, Sang Wha Kim, Jeong Woo Kang, **Se Jin Han**, Dalsang Jeong, Se Chang Park*. Isolation and characterisation of pVa-21, a giant bacteriophage with anti-biofilm potential against *Vibrio alginolyticus*. *Scientific Reports*. 2019 Apr 18;9(1):6284.

6. Jin Woo Jun, Jeong Woo Kang, Sib Sankar Giri, SaekilYun, Hyoun Joong Kim, Sang Guen Kim, Sang Wha Kim, **Se Jin Han**, Jun Kwon, Woo Taek Oh, Dal sang Jeong, Se Chang Park*. Superiority of PLGA microparticle-encapsulated formalin-killed cell vaccine in protecting olive flounder against *Streptococcus parauberis*. *Aquaculture*. 509. 67-71.

7. Saekil Yun, Sib Sankar Giri, Hyoun Joong Kim, Sang Geun Kim, Sang Wha Kim, Jung Woo Kang, **Se Jin Han**, Jun Kwon, Woo Taek Oh, Cheng Chi, Jin Woo Jun, Se Chang Park*. Enhanced bath immersion vaccination through microbubble treatment in the cyprinid loach. *Fish and Shellfish Immunology.* 2019(91), 12-18.

8. Woo Taek Oh, Sib Sankar Giri, Saekil Yun, Hyoun Joong Kim, Sang Geun Kim, Sang Wha Kim, Jung Woo Kang, **Se Jin Han**, Jun Kwon, Jin Woo Jun, Se

Chang Park*. Emergence of Rickettsial Infection in Rainbow Trout (*Oncorhynchus mykiss*) Fry Displaying the Appearance of Red Mark Syndrome in Korea. *Microorganisms.* 29;7(9).

9. Woo Taek Oh, Jin Woo Jun, Sib Sankar Giri, SaekilYun, Hyoun Joong Kim, Sang Geun Kim, Sang Wha Kim, Jung Woo Kang, **Se Jin Han**, Jun Kwon, Ji Hyung Kim, THM Smits, Se Chang Park*. *Pseudomonas tructae* sp. nov., novel species isolated from rainbow trout kidney. *International journal of systematic and evolutionary microbiology*.

10. Woo Taek Oh, Jin Woo Jun, Sib Sankar Giri, SaekilYun, Hyoun Joong Kim, Sang Geun Kim, Sang Wha Kim, **Se Jin Han**, Jun Kwon, Se Chang Park*. *Staphylococcus xylosus* Infection in Rainbow Trout (*Oncorhynchus mykiss*) As a Primary Pathogenic Cause of Eye Protrusion and Mortality. *Microorganisms*. 29;7(9).

11. Woo Taek Oh, Sib Sankar Giri, SaekilYun, Hyoun Joong Kim, Sang Geun Kim, Sang Wha Kim, Jung Woo Kang, **Se Jin Han**, Jun Kwon, Jin Woo Jun, Se Chang Park*. *Janthinobacterium lividum* as An Emerging Pathogenic Bacterium Affecting Rainbow Trout (*Oncorhynchus mykiss*) Fisheries in Korea. *Pathogens*. 11;8(3).

12. Hyoun Joong Kim, Jin Woo Jun, Sib Sankar Giri, Cheng Chi, Saekil Yun, Sang Guen Kim, Sang Wha Kim, Jeong Woo Kang, **Se Jin Han**, Jun Kwon, Kw Hun

On, Woo Taek Oh, Se Chang Park*. Application of the bacteriophage pVco-14 to prevent *Vibrio coralliilyticus* infection in Pacific oyster (*Crassostrea gigas*) larvae. *Journal of invertebrate pathology.* 2019 Sep 11:107244.

13. Woo Taek Oh, Ji Hyung Kim, Jin Woo Jun, Sib Sankar Giri, SaekilYun, Hyoun Joong Kim, Sang Geun Kim, Sang Wha Kim, **Se Jin Han**, Jun Kwon, Se Chang Park*. Genetic Characterization and Pathological Analysis of a Novel Bacterial Pathogen, Pseudomonas tructae, in Rainbow Trout (*Oncorhynchus mykiss*). *Microorganisms*. 29;7(10).

14. Sang Wha Kim, **Se Jin Han**, Young Ran Lee, Byung Yeop Kim, Se Chang Park*. First report of a Risso's dolphin (*Grampus griseus*) stranded in Jeju Island, Republic of Korea: findings from necropsy, histopathology and microbiome analysis. *Veterinary Record Case Reports*. 2019, 7 :e000860.

15. Woo Taek Oh, Jin Woo Jun, Sib Sankar Giri, SaekilYun, Hyoun Joong Kim, Sang Geun Kim, Sang Wha Kim, **Se Jin Han**, Jun Kwon, Se Chang Park*. Genome and Phylogenetic Analysis of Infectious Hematopoietic Necrosis Virus Strain SNU1 Isolated in Korea. *Pathogens*. 8(4), 200.

16. Sang Guen Kim, Sib Sankar Giri, Saekil Yun, Hyoun Joong Kim, Sang Wha Kim, Jeong Woo Kang, **Se Jin Han**, Woo Taek Oh, Se Chang Park*. Genomic characterization of bacteriophage pEt-SU, a novel phiKZ-related virus infecting *Edwardsiella tarda*. *Archives of virology*. 2019 Oct 16.

17. Sib Sankar Giri, Jin Woo Jun, Saekil Yun, Hyoun Joong Kim, Sang Guen Kim, Sang Wha Kim, Jeong Woo Kang, **Se Jin Han**, Woo Taek Oh, Jun Kwon, Venkatachalam Sukumaran, Se Chang Park*. Effects of dietary heat-killed *Pseudomonas aeruginosa* strain VSG2 on immune functions, antioxidant efficacy, and disease resistance in *Cyprinus carpio*. *Aquaculture*. 514.

2018 Published

1. Hyoun Joong Kim, Jin Woo Jun, Sib Sankar Giri, Cheng Chi, Saekil Yun, Sang Guen Kim, Sang Wha Kim, Jeong Woo Kang, **Se Jin Han**, Se Chang Park* (2018). Complete genome sequence of bacteriophage pVco-5 that infects *Vibrio corallilyticus*, which causes bacillary necrosis in Pacific oyster (*Crassostrea gigas*) larvae. Genome Announcements. 6(2): e01143-17.

2. Sib Sankar Giri, Jin Woo Jun, Saekil Yun, Hyoun Joong Kim, Sang Guen Kim, Jeong Woo Kang, Sang Wha Kim, **Se Jin Han**, Se Chang Park*, and V. Sukumaran* (2018). Characterisation of Lactic Acid Bacteria Isolated from the Gut of *Cyprinus carpio* That May Be Effective Against Lead Toxicity. Probiotics and Antimicrobial Proteins. 10.1007/s12602-017-9367-6.

3. Sib Sankar Giri, Saekil Yun, Jin Woo Jun, Hyoun Joong Kim, Sang Guen Kim, Jeong Woo Kang, Sang Wha Kim, **Se Jin Han**, V. Sukumaran, Se Chang Park* (2018). Therapeutic Effect of Intestinal Autochthonous *Actobacillus reuteri* P16 Against Waterborne Lead Toxicity in *Cyprinus carpio*. Frontiers in Immunology. 10.3389/fimmu.2018.01824.

4. Jin Woo Jun, Sib Sankar Giri, Hyoun Joong Kim, Saekil Yun, Cheng Chi, Sang Guen Kim, Sang Wha Kim, Jeong Woo Kang, **Se Jin Han**, Jun Kwon, Woo Taek Oh, Dalsang Jeong, Se Chang Park* (2018). Identification and phylogenetic characterization of *Nybelinia surmenicola* (Cestoda: Trypanorhyncha) from squids (*Todarodes pacificus*) from East Sea, Republic of Korea. Journal of Preventive Veterinary Medicien. 42(3), 112-116.

LIST OF CONFERENCES

2019

1. Sib Sankar Giri, Saekil Yun, Hyoun Joong Kim, Sang Guen Kim, Sang Wha Kim, **Se Jin Han**, Woo Taek Oh, Jun Kwon, V. Sukumaran, Se Chang Park. Effects of dietary heat-killed *Pseudomonas aeruginosa* strain VSG2 on immune functions, antioxidant efficacy, and disease resistance of *Cyprinus carpio*. Marine Biotechnology Conference (MBC) 2019. Shizuoka, Japan, 2019.

2. Sang Wha Kim, Won Hee Hong, Jun Kwon, **Se Jin Han**, Byung Yeop Kim, Se Chang Park. First report of Ovaprim application in shark: Induction of oocyte development, ovulation, and semen release by Ovaprim injection in Banded houndshark (*Triakis scyllium*). Marine Biotechnology Conference (MBC) 2019. Shizuoka, Japan, 2019.

2018

1. **Se Jin Han**, Jin Woo Jun, Sib Sankar Giri, Seakil Yun, Hyoun Joong Kim, Sang Guen Kim, Sang Wha Kim, Jeong Woo Kang, Jun Kwon, Woo Taek Oh and Se Chang Park, Candida manassasensis infection in digestive tracts of Siberian sturgeon *Acipenser baerii* fingerlings. 3rd Aquaculture conference. Qingdao, China, 2018.

2. Hyoun Joong Kim, Jin Woo Jun, Sib Sankar Giri, Seakil Yun, Sang Guen Kim, Sang Wha Kim, Jeong Woo Kang, **Se Jin Han**, Jun Kwon, Woo Taek Oh and Se Chang Park, Application of Bacteriophages to Prevent Mass mortality Caused by *Vibrio coralliilyticus* in Pacific oyster (*Crassostrea gigas*) Larvae. 3rd Aquaculture conference. Qingdao, China, 2018.

3. Jeong Woo Kang, Jin Woo Jun, Sib Sankar Giri, Seakil Yun, Hyoun Joong Kim, Sang Guen Kim, Sang Wha Kim, **Se Jin Han**, Jun Kwon, Woo Taek Oh and Se Chang Park, Superiority of PLGA microparticle-encapsuled formalin-killed cell vaccine to conventional formalin-killed cell vaccine in protection against *Streptococcus parauberis* infection in olive flounder (*Paralichthys olivaceus*). 3rd Aquaculture conference. Qingdao, China, 2018.

4. Seakil Yun, Jin Woo Jun, Sib Sankar Giri, Hyoun Joong Kim, Sang Guen Kim, Sang Wha Kim, Jeong Woo Kang, **Se Jin Han**, Jun Kwon, Woo Taek Oh and Se Chang Park, Efficacy of Poly Lactic-co-glycolic Acid Microparticle Vaccine using Bacteriophage Lysates of Bacteria for Bacterial Infection in Fish. 3rd Aquaculture conference. Qingdao, China, 2018.

ACKNOWLEDGEMENTS

First and foremost, I would like to express deepest gratitude to Prof. Se Chang Park for the continuous support of my master's study and research, for his heart-warming advice, patience, motivation, and immense knowledge. His guidance helped me in all the time of research and writing of this thesis. I could not have imagined having a better advisor and mentor for my study.

Besides my advisor, I would like to thank the rest of my thesis committee: Prof. Byeong Chun Lee and Dr. Ji Hyung Kim for their encouragement, insightful comments and questions.

In addition, I am extremely grateful to Prof. Byung Yeop Kim, who kindly gave me priceless chances to do necropsy projects on stranded dolphins in Jeju Island. Thanks to him, this thesis could be completed.

I thank my fellow lab mates: Dr. Giri, Saekil Yun, Hyoun Joong Kim, Sang Guen Kim, Sang Wha Kim, Jeong Woo Kang, Woo Taek Oh and Sung Bin Lee for the stimulating discussions, and for all the fun we have had in the last two years. Especially, for Sang Wha, I would like to give my sincere thanks. She is a role model to me as a brave, brilliant and beautiful scientist. Also, thanks to Sang Guen for spending a lot of time answering my constant

questions and helping me a lot with experiments. I also thank mentors Dr. Won Hee Hong and Dr. Young-ran Lee for valuable advice for my career.

Last but not least, it's all thanks to sincere support from my family. They show unconditional love and patience and have always been there for me no matter where I am. Thank you so much for being so understanding and supportive.

This work was supported by the Ministry of Education, through the Brain Korea 21 Program for Veterinary Science, Seoul National University and the Research Institute for Veterinary Science, Seoul National University.