creative commons

COMMONS DEED

저작자표시-비영리-변경금지 2.0 대한민국

이용자는 아래의 조건을 따르는 경우에 한하여 자유롭게

- 이 저작물을 복제, 배포, 전송, 전시, 공연 및 방송할 수 있습니다.

다음과 같은 조건을 따라야 합니다:

저작자표시. 귀하는 원저작자를 표시하여야 합니다.

비영리. 귀하는 이 저작물을 영리 목적으로 이용할 수 없습니다.

변경금지. 귀하는 이 저작물을 개작, 변형 또는 가공할 수 없습니다.

- 귀하는, 이 저작물의 재이용이나 배포의 경우, 이 저작물에 적용된 이용허락조건을 명확하게 나타내어야 합니다.
- 저작권자로부터 별도의 허가를 받으면 이러한 조건들은 적용되지 않습니다.

저작권법에 따른 이용자의 권리는 위의 내용에 의하여 영향을 받지 않습니다.

이것은 이용허락규약(Legal Code)을 이해하기 쉽게 요약한 것입니다.

Disclaimer

dCollection

수의학 석사 학위논문

개에서 자기공명영상을 통한 요천추의 자세변화에 따른 척수원추 위치 이동의 평가

Locational Displacement of the Conus Medullaris by Dynamic Lumbosacral MRI in Dogs

2020년 2월

서울대학교 대학원
수의학과 임상수의학 (수의영상의학) 전공
남 지 혜

Locational Displacement of the Conus Medullaris by Dynamic Lumbosacral MRI in Dogs

지도교수 윤 정 희

이 논문을 수의학석사학위논문으로 제출함

2019 년 10 월

서울대학교 대학원

수의학과 임상수의학 (수의영상의학) 전공

남 지 혜

남지혜의 석사 학위논문을 인준함

2019 년 12 월

위 원 장 _____ 최 민 철 _____ (인)

부위원장 _____ 윤 정 희 _____ (인)

위 원 _____ 강 병 재 _____ (인)

Abstract

Locational Displacement of the Conus Medullaris by Dynamic Lumbosacral MRI in Dogs

Jihye Nam

Veterinary Clinical Sciences (Diagnostic Imaging)

Department of Veterinary Medicine

The Graduate School

Seoul National University

The purposes of the study were to identify and measure the displacement of the conus medullaris (CM) during positional changes of hindlimbs in normal dogs using MRI and further to establish the correlation between the displacement of the CM and lumbosacral angular change.

Nine healthy adult Beagles were examined in the study. MRI scans were performed with three different positions of the hindlimbs: neutral, flexion and extension, and the lumbosacral angle and the position of each CM were also measured using transverse T2-weighted sequence.

The CM was displaced caudally when hindlimbs position was changed from extension to flexion. There was a positive correlation between changes of lumbosacral angle and displacement of CM.

Nevertheless, the results may contribute to enhance the understanding of anatomical characteristics of the lumbosacral region and provide helpful information to scrutinize lumbosacral abnormalities and which previously had limitations using conventional MRI techniques without positional changes and evaluation after treatment.

.....

Keywords: lumbosacral, conus medullaris, MRI, lumbosacral angle, lumbosacral disease
Student number: 2018-29823

Contents

Introduction ····· 1

Materials and Methods ····· 3

1. Animals ····· 3
2. Anesthesia ····· 3
3. MRI examinations ····· 4
4. Image analysis ····· 5
5. Statistical analysis ····· 6

Results ····· 7

Discussion ····· 15

REFERENCES ····· 20

국문초록 ····· 24

Introduction

The lumbosacral region in dogs is a highly mobile functional unit due to its complex structural properties and large joint mobility.[1] For this reason, it is likely that degenerative disease will occur in this area if instability exists.[1,2] Because this region involves cauda equina that stretches out the hindlimbs and includes the spinal cord, confirmed diagnosis can be difficult when neurologic or orthopedic disorder occurs in combination.[3] These lumbosacral diseases which are also called cauda equina syndrome are a general term for a disease that occurs in the lumbosacral region in a broad sense including such as congenital deformity, degenerative and congenital lumbosacral stenosis, acute intervertebral disk extrusion, discospondylitis, traumatic fracture, luxation, inflammation, and neoplasia.[3,4]

The lumbosacral region consists of the conus medullaris (CM), from where the central spinal cord tapers near the tail to the tailing nerve root that branches out from the spinal cord, and is connected to a connective tissue known as the filum terminale after the CM.[1,3,5] In humans, the CM has a relatively consistent location, size, and shape.[6] However, in dogs, its size varies leading to different growth ranges of the vertebral column and widely varying anatomical locations.[7,8] Therefore, it is difficult to identify the normal location of the CM in the veterinary field, which makes diagnosis of lumbosacral diseases, such as tethered cord syndrome and congenital malformation

of filum terminale, challenging.[10,11] This syndrome can be diagnosed in humans based on the location of the CM, which is found more toward the end compared with normal.[10,12] The normal location of the CM region differs in dogs, and the diagnosis could be limited using conventional magnetic resonance imaging (MRI) techniques.[10] Several human studies identified the displacement of CM in the straight leg raise (SLR) test which induces posture change of hindlimbs related to pain response and confirmed limitation of the displacement of CM in case of lumbosacral disease, as in intervertebral disc disease.[13-18] The dynamic posture in MRI was considered as a useful method for assessing neuromechanical impairment in patients with sciatica from the nerve root.[13-18] One case report in veterinary medicine based on the aforementioned study of human medicine revealed limited mobility in tethered cord syndrome with postural change of hindlimbs.[10] However, in this case report, although there was no abnormality in the lumbosacral region of the comparison dog, disc herniation was present in the thoracolumbar region.[10]

The authors hypothesized that the range of the CM displacement has correlation with the range of the postural changes of hindlimbs in normal dogs. The aims of this study were to investigate the movement range of the CM according to changes in posture and the changes of lumbosacral angles when hind leg posture was altered from flexion to neutral and extension postures in order to identify possible correlations between changes of lumbosacral angle and the displacement of CM position.

Materials and Methods

1. Animals

Nine adult beagles were examined in this study. There were 8 male and 1 female dogs ranging from 21 to 42 months old (mean, 31.3; SD, ±10.1) and weighing 10.2 - 14.1 kg (mean, 12.4; SD, ±1.2). Each dog was healthy based on physical, neurologic, and laboratory data. There were neither clinical signs of lameness or back pain nor specific abnormalities in the spine and hindlimb on radiography. Animal care and experimental procedures were approved by the Institutional Animal Care and Use Committee of Seoul National University (SNU-190624-3).

2. Anesthesia

Food was withheld from the dogs for at least 12 hours before general anesthesia. Then, the dogs were sedated by premedication with acepromazine[a] (0.01 mg/kg, IV). Anesthesia was induced with alfaxalone[b] (2.0 mg/kg, IV), which was administered through a 24-gage catheter into a cephalic vein. The dogs were endotracheally intubated, and anesthesia was maintained with isoflurane[c] in 100% oxygen. During anesthesia and MRI, electrocardiography, pulse

oximetry, tidal carbon dioxide concentration ($EtCO_2$), minimum alveolar concentration, non-invasive blood pressure, and supply maintenance fluid therapy[d] (2.5 ml/kg/hr, IV) were monitored. Body temperature was measured every hour, and the general anesthesia took about 2 hours.

3. MRI examinations

The dogs were scanned with a 0.3-T permanent MR scanner[e] using the head coil. The scans were performed in transverse and sagittal planes of T2-weighted sequence for all dogs. MRI scans of the lumbar and lumbosacral regions were performed with the dog supported in dorsal recumbency. The variation postures were taken in the following three ways: neutral, flexion, and extension. Neutral position was obtained by flexing the pelvis and stifle without any fixing (i.e., frog-leg position); flexion position by pulling the hindlimbs cranially and restraining the ankle using elastic straps secured to the MRI table and the position was maintained with the hip joint flexed, the stifle joint extended and the hock joint flexed; and extension position by extending hindlimbs with restraining the feet to the MRI table. The T2-weighted sequence scan parameters were as follows: repetition time (TR) = 1729 ms, echo time (TE) = 116 ms, flip angle (FA) = 120°, number of acquisition (NSA) = 8, slice thickness = 3.0 mm, slice interval = 3.3 mm, field of view

(FOV) = 220 × 220 mm, matrix = 224 × 128, scan duration = 14 min, 48 seconds for sagittal plane, and repetition time (TR) = 1125 ms, echo time (TE) = 140 ms, flip angle (FA) = 90°, number of acquisition (NSA) = 6, slice thickness = 3.0 mm, slice interval = 3.5 mm, field of view (FOV) = 220 × 220 mm, matrix = 224 × 128, scan duration = 16 min, 47 seconds for transverse plane.

4. Image analysis

The lumbosacral angle and position of the CM were measured twice by two observers to obtain four data sets. All the MRI images were analyzed through the image analysis software[f]. Lumbosacral angle was the angle between two linear lines that crossed the center in parallel to each vertebral body to the 7th lumbar vertebra and the sacrum, and it was measured using the central point of the lumbosacral intervertebral space in median section of the sagittal plane of the T2-weighted sequence (Figure 1).

The termination of the CM was determined where spinal cord showed hypointense on a mid-sagittal T2-weighted image compared to the hyperintense cerebrospinal fluid. In several dogs with which CM was difficult to clearly distinguish, transverse plane images were analyzed.

To measure the extent of caudal movement of the CM, two axillary lines were drawn first. One line from the vertical center of cranial end plate to that of the caudal end plate of 7th lumbar vertebra, and

the other line perpendicular to the previous line starting from the tip of the CM. The distance was calculated from the cranial end plate of the 7th lumbar vertebra to the intersection point of the two lines (Figure 2).

5. Statistical analysis

Statistical analysis was performed by using a statistical software[g]. Intra-observer and inter-observer reproducibility were assessed for lumbosacral angle and position of the conus medullaris by using the intraclass correlation coefficient (ICC) and the value closed to 1 indicates excellent agreement. Spearman's rank correlation analysis and simple linear regression analysis were used to demonstrate the correlation between lumbosacral angle and variation in the position of the CM. P value of < 0.05 was considered as statistically significant.

Results

1. Lumbosacral angle

The lumbosacral angle for each posture was measured using the sagittal plane of T2-weighted sequences as the reference. The measured mean ± standard deviations (SD) for each posture was as follows: flexion, 180.6° ± 5.7° (range, 168.6° - 188.5°); neutral, 156.8° ± 5.6° (range, 145.8° - 166.7°); and extension, 148.3° ± 4.2° (range, 140.1° - 153.5°) (Table 1). The ICC level of the inter- and intra-observer for the two examiners was high (0.991 - 0.999). The average difference in the lumbosacral angle according to posture was 23.8° in neutral to flexion, 8.4° in neutral to extension, and 32.2° in flexion to extension (Figure 3).

2. Evaluation of change in locational CM according to position of hindlimbs

The location of the CM according to the posture of hindlimbs, as measured using the cranial 7th lumbar vertebra as the reference, was evaluated using the sagittal plane of T2-weighted sequence. The ICC level of the inter- and intra-observer for the two examiners was high (0.968 - 0.991). The mean values for displacement of CM according to positional change from the 7th lumbar to sacrum

direction were measured to be 9.09 ± 3.29 mm (range, 4.8 - 16.2 mm) for neutral to flexion, −2.5 ± 1.38 mm (range, −5.6 - (−0.4) mm) for neutral to extension, and 11.64 ± 3.89 mm (range, 5.50−18.80 mm) for extension to flexion (Figure 3).

Spearman's rank correlation analysis was used to assess angle changes according to change in the posture. The resulting correlation coefficient was 0.71 ($P < 0.05$), reflecting high correlation according to the correlation coefficient scale defined by Alfred.[19] This suggests that the increased lumbosacral angle during the change from extension to flexion and the extent of movement of the CM in the caudal direction are positively correlated.

Furthermore, the extent of CM movement demonstrated an average 0.39 ± 0.14 mm (range, 0.20 - 0.60 mm) in neutral to flexion, −0.32 ± 0.15 mm (range, 0.47 - 0.53 mm) in neutral to extension, and 0.37 ± 0.13 mm (range, 0.21 - 0.57 mm) in flexion to extension of distribution of movement for each one degree of angle moved (Table 2).

Simple linear regression analysis revealed an R^2 value of 0.795 and a regression coefficient of 0.343 ($P < 0.05$), reflecting a significant difference. This suggests a uniform linear distribution in movement according to changes in angle.

The values for dividing the changes in CM position according to position with the 7th lumbar vertebra length in each subject were as follows: 0.60 ± 0.19 (range, 0.31 - 0.85) for neutral to flexion; −0.16 ± 0.07 (range, −0.27 - (−0.04)) for neutral to extension; and 0.76 ± 0.23 (range, 0.59 - 1.06) for flexion to extension. Hence, postural change to

neutral flexion leads to approximately a 0.6-fold change in CM position compared with that in the 7th lumbar vertebra, on average, and approximately 0.76-fold in movement when posture changed from flexion to extension (Table 2).

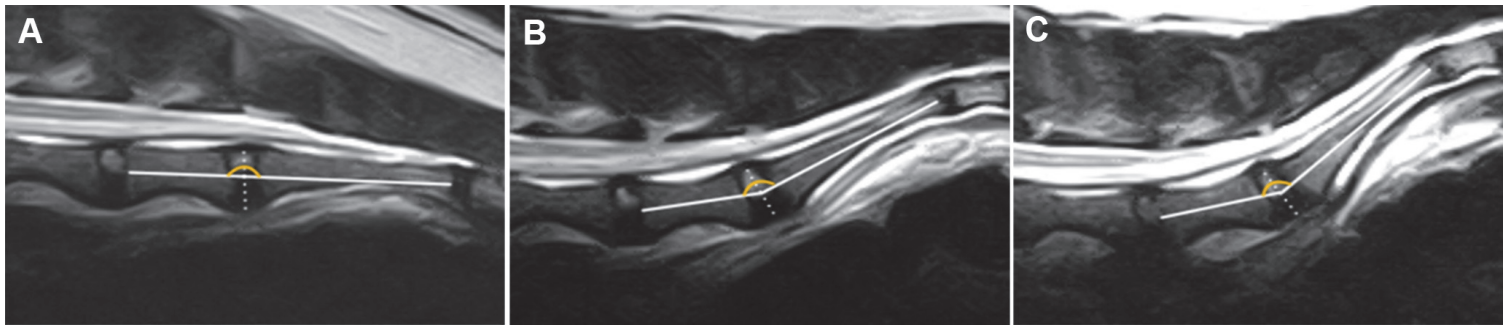

Figure 1. Lumbosacral angle was determined on T2-weighted sequence for each position: (A) flexion, (B) neutral, (C) extension. Angles measured between two lines drawn along the line across the 7th vertebra and sacrum from the base on intervertebral disc space.

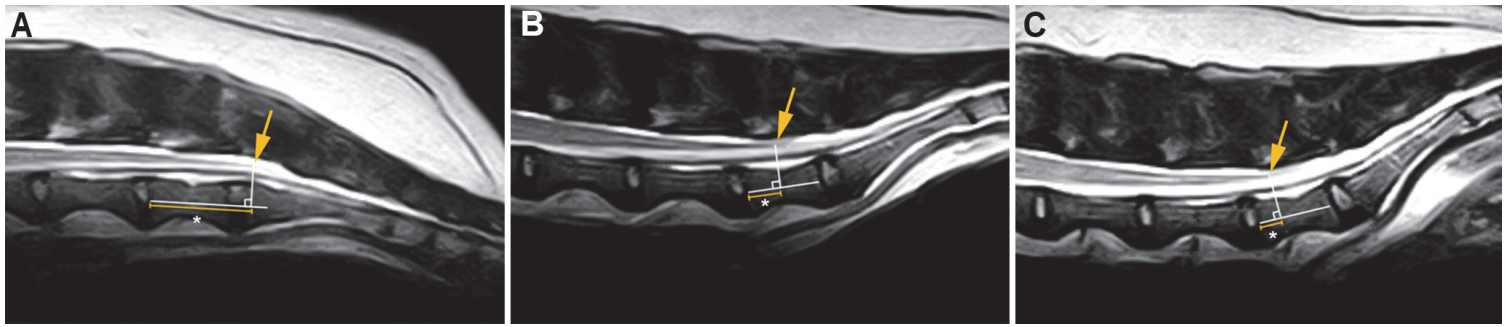

Figure 2. The displacements of the conus medullaris (arrow) were identified according to positional change (A) flexion, (B) neutral, and (C) extension. The location of the conus medullaris was calculated by measuring the line from the front of the central line of the 7th lumbar vertebra, a line perpendicular to the previous line drawn from the tip of the conus medullaris (asterisk). The conus medullaris was displaced caudally when the flexed hindlimbs were extended.

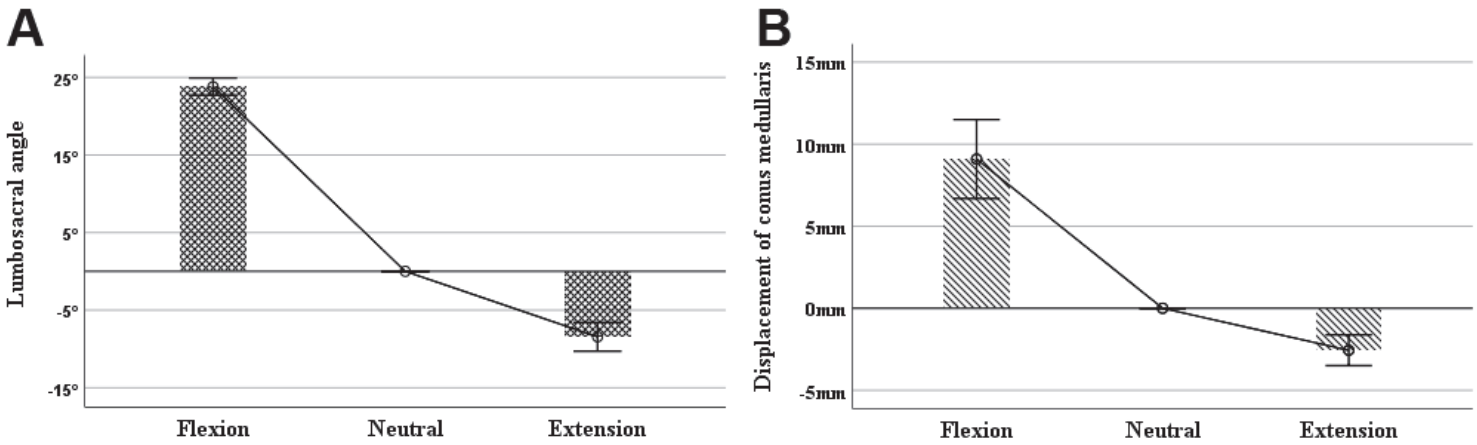

Figure 3. The average difference in lumbosacral angle (A) and displacement of CM (B) according to positional change of hindlimbs for flexion to neutral, neutral to extension, and flexion to extension. The two variations indicate a similar tendency.

Table 1. Mean ± SD values of lumbosacral angle for the hindlimb position of flexion, neutral, and extension as determined via MRI (mean ± SD)

	Hindlimbs position		
	Flexion	Neutral	Extension
LS angle(°)	180.6 ± 5.7	156.8 ± 5.6	148.3 ±4.2

Abbreviations: SD, standard deviation; LS angle, lumbosacral angle

Table 2. Calculated mean ± SD values for variation of lumbosacral angle and CM, the ratio of displacement of CM to lumbosacral angle, and the ratio of displacement of CM to 7th length according to changes in posture. (mean ± SD)

	Variable of hindlimbs position		
	Neutral to Flexion	Neutral to Extension	Extension to Flexion
CM: LS angle ratio	0.39 ± 0.1	0.32 ± 0.2	0.37 ± 0.1
CM: 7th vertebral length ratio	0.60 ± 0.2	-0.16 ± 0.1	0.76 ± 0.2

Abbreviations: SD, standard deviation; LS angle, lumnosacral angle; CM, conus medullaris

Discussion

In this study, changes in the location of the CM in the lumbosacral region of dogs in relation to positional changes of hindlimbs in flexion, neutral, and extension were evaluated. The results demonstrated a positive correlation between increased lumbosacral angle during positional change from extension to flexion and the distance moved by the CM in the caudal direction of the spinal cord. Furthermore, this distance relatively differed significantly among dogs with a maximum of 11.6 mm on average when posture was changed from extension to flexion, corresponding to 0.76-fold of the 7th lumbar vertebral length in each dog.

The SLR test, which was adopted from human medicine and similarly reflects postural changes in this study, is often used to diagnose muscle and spinal cord diseases in patients with low back pain.[13-15,18,20] The test is performed by placing the patient in a straight lying down position with hip joint in flexion while knee joint in extension and hock joint in flexion to verify whether sciatica (i.e., radiculopathy) is induced.[18,20] The mechanism is related to the sciatic nerve connected to the hindlimbs, which prevents its stretching by displacement of the connected lower lumbar and sacral nerve roots.[20] In fact, many studies using the SLR test demonstrated caudal displacement in the lower part of the lumbar and sacral nerve roots,

illustrating the "linear dependent" principle can also affect the CM, which is directly connected to the nerve root.[13-15,20] An MRI study related to this concept and conducted in humans demonstrated caudal displacement of the CM during the SLR test.[13-15]

In the case of our study, owing to the anatomical characteristics of the dogs, their hip joint was more flexible than that in humans and there was a lack of limitation in the applied postural changes that allowed wider-angle hip flexion because of the structure of the device employed. Because the neutral position in dogs involves a minor degree of hip and knee flexion, complete hip extension was included as one of the postures. Similar to studies in human medicine, there was a study on cadaver of dogs which proved the strain applied to the nerve root during the SLR test.[20] For this reason, the authors hypothesized that the pressure exerted on the spinal nerve and the extent of hip flexion are relatively uniform in linear correlation; thus, the lumbosacral angle during postural change was quantified to enable us to draw our conclusion. Therefore, the results of this study could provide quantitative data regarding the mechanical behavior of the lumbosacral region and enhance understanding of the neural structure, thus enabling the hypothesis that normal movement may not occur in the presence of factors that hinder normal mobility. Consequently, the results revealed an average of approximately 0.35 mm displacement of the CM per degree, demonstrating a relatively linear movement distribution according to degree change. However, the variation among dogs was significant, with a minimum of 0.22

mm and a maximum of 0.60 mm per degree, even considering the fact that the dogs were of same species and similar age and weight, which suggests that the calculated distance cannot be considered to be standard values in dogs.

According to a previous study about the position of CM, the location of the CM was distributed toward the front as the weight increased in the neutral position.[8] For dogs weighing 10 - 15 kg similar to those used in our study, CM was located in the front and middle area of the 7th lumbar vertebra in the neutral position.[8] This was observed in a similar position in our results. However, the weight of the dogs was not varied in our study; thus, further research that involves various species and different weights is needed to clarify whether variation in size of dog results in greater changes in CM location with changes in posture.

In fact, in radiculopathy (e.g., sciatica), the pain originates primarily from the pressure exerted on the nerve root, which reduces its gliding distance and causes severe tension, inducing decreased vascular flow, edema, and hypoxia.[20] This mechanism allows severe tension on the nerve root that affects not only nerve root movement but also the spinal cord.[13-15] Therefore, in the presence of nerve root pressure in lumbosacral disease, it could be hypothesized that changes in CM location may not occur with positional change of hindlimbs, as identified in this study. Because the degree of compression in the cauda equina did not correlate with the severity of clinical symptoms, such as pain and ataxia, additional diagnostic method is needed to

assess the diagnosis and prognosis of the disease when there is pain in the lumbosacral region.[22] For example, degenerative lumbosacral stenosis or lumbosacral disk herniation from disk material extrusion or protrusion can be approached with a similar mechanism, which would provide more information in the diagnosis of the disease which is confused between neurologic and orthopedic disorder through dynamic MRI.

Actually, previously published study in human medicine proved the reduction of CM displacement in the intervertebral disc disease patients and identified increasing CM movement in patients with improved clinical symptom, such as radiculopathy and low back pain.[16,17] Similarly, since there are limitations in assessing a dog's pain response unlike humans, the results of this study can also help in the evaluation after treatment. Not only that, as mentioned earlier, in previous case study in dogs, it used dynamic lumbosacral MRI to diagnose tethered cord syndrome in dogs. Because this congenital lesion is a fibrosis in the filum terminale connected to the CM that limited normal mobility, diagnosis was not possible using conventional MRI. However, this reported diagnosis was possible by identifying the lack of changes in CM location during postural changes.[10]

The authors could not find study results that address limited movement in lumbosacral diseases other than the tethered cord syndrome in veterinary medicine; as such, further studies in clinical diagnosis are needed. The experiments in this study evaluated the relatively smaller region of the caudal spinal cord, even with the fact

that the mid-sagittal images acquired may not be complete and not all species of dogs were represented given the small number of dogs from one species. Furthermore, variation was not induced for the angle of stifle, and thus, the maximum nerve stretch that can induce hip extension to the hind limb and CM movement range affected by stifle joint movement range was not evaluated.

To the authors' best knowledge, this is the first experimental study to identify displacement of CM by inducing postural changes in the hindlimbs of dogs. The research quantified the displaced range of the CM according to changes in the lumbosacral angle with changes in the hindlimb position. Due to limitations in sample size and variation of each dog, however, the results are limited to be used as representative values. Nevertheless, our findings will contribute to the enhancement of understanding of anatomical characteristics of the lumbosacral region and provide helpful information to scrutinize lumbosacral abnormalities which previously had limitations using conventional MRI techniques without postural changes.

REFERENCES

1. Tobias KM, Johnston SA: Lumbosacral spine, In: Adin CA, Nelson RW eds: Veterinary surgery small animal vol 1. St. Louis, MO, Elsevier Saunders, 2012;476-486

2. Jeryl C. Jones, Sarah E. Davies, Stephen R. Were et al. Effects of body position and clinical signs on L7-S1 intervertebral foraminal area and lumbosacral angle in dogs with lumbosacral disease as measured via computed tomography. *Am J Vet Res* 2008;80: 779-786

3. Simon J, Wheeler., lumbosacral disease. *Vet Clin North Am Small Anim Pract* 1992; 22: 937-950.

4. Ross H. Parmer, Jonathan N. Chambers, Canine lumbosacral disease. Part 1. Anatomy, pathophysiology, and clinical presentation. Pathophysiology and Clinical Presentation. The Compendium 61-79.

5. Fletcher TF. Spinal cord and meninges. In: Evans HE, de Lahunta A, editors. Miller's and Evans Anatomy of the Dog. 4th ed. St Louis, Missouri: Elsevier Saunders, 2013; 589 - 610.

6. Saifuddin A, Burnett SJ, White J., The variation of position of the conus medullaris in an adult population. A magnetic resonance imaging study. *Spine* 1998; 23:1452-1456.

7. Bergknut N, Meij B., Degenerative lumbosacral stenosis part 1 pathogenesis, clinical signs and diagnostics. European Journal of Companion Animal Practice. 2012;22(1):23 - 33.

8. Zohra Khan, Elizabeth Munro, Darren Shaw et al. Variation in the

position of the conus medullaris and dural sac in adult dogs, Vet Rec 2019;10.1136/vr.105279

9. Vermeulen, H A, On the conus medullaris of the domestic animals, In: KNAW, Proceedings, 18 I, 1915, Amsterdam, 1915; 780-792

10. De Decker, Vicky Watts, David M. Neilson, Dynamic lumbosacral magnetic resonance imaging in a dog with tethered cord syndrome with a tight filum terminale. *Front Vet Sci.* 2017;4: 134.

11. Sparks, Courtney R. Robertson et al., Morphometric analysis of spinal cord termination in Cavalier King Charles Spaniels, J Vet Intern Med, 2019:33(2):717-725

12. Yamada S., Won DJ, Pezeshkpour G et al., Pathophysiology of tethered cord syndrome and similar complex disorders., *J Neurosurg,* 2007;23(2): E6

13. Rade M, Ko¨ no¨ nen M, Vanninen R, et al. 2014 young investigator award winner: in vivo magnetic resonance imaging measurement of spinal cord displacement in the thoracolumbar region of asymp-tomatic subjects: Part 1: straight leg raise test. *Spine* 2014;39: 1288-1293.

14 Rade M, Ko¨ no¨ nen M, Vanninen R, et al. 2014 young inves-tigator award winner: In vivo magnetic resonance imaging measurement of spinal cord displacement in the thoracolumbar region of asymptomatic subjects: Part 2: comparison between unilateral and bilateral straight leg raise tests. *Spine* 2014;39: 1294-1300

15. Rade M, Shacklock M, Ko¨ no¨ nen M, et al. Part 3: developing methods of in vivo MRI measurement of spinal cord displacement in

the thoracolumbar region of asymptomatic subjects with uni- lateral and bilateral straight leg raise tests. *Spine* 2015;40: 935-941.

16. Rade M, Pesonen J, Kononen M, et al. Reduced spinal cord movement with the straight leg raise test in patients with lumbar intervertebral disc herniation. *Spine*, 2017;42:1117-1124.

17. Janne Pesonen, Marinko Rade, Mervi Ko¨no¨nen, Normalization of spinal cord displacement with the straight leg raise and resolution of sciatica in patients with lumbar intervertebral disc herniation A 1.5-year follow-up study, *Spine*, 2019;44:1064-1077.

18. Rebain R, Baxter GD, McDonough S, A systematic review of the passive straight leg raising test as a diagnostic aid for low back pain (1989 to 2000)., *Spine* 2002;27: E388 - E395.

19. Rovai, Alfred P., Jason D. Baker et al., Social science research design and statistics: A practitioner's guide to research methods and IBM SPSS. Watertree Press LLC, 2013:375

20. Kobayashi S, Suzuki Y, Asai T, Yoshizawa H. Changes in nerve root motion and intraradicular blood flow during intraoperative femoral nerve stretch test. Report of four cases. *J Neurosurg*. 2003;99: 298-305

21. Babbage CS, Coppieters MW, McGowan CM. Strain and excursion of the sciatic nerve in the dog: biomechanical considerations in the development of a clinical test for increased neural mechanosensitivity. *Vet J*. 2007;174: 330-336.

22. Mayhew, P.D., Kapatkin, A.S., Wortman, J.A. et al, Association of cauda equina compression on magnetic resonance images and clinical

signs in dogs with degenerative lumbosacral stenosis. *J Am Anim Hosp Assoc*. 2002;38: 555 - 562

국문 초록

개에서 자기공명영상을 통한 요천추의 자세변화에 따른 척수원추 위치 이동의 평가

남 지 혜

서울대학교 대학원

수의학과 임상수의학 (수의영상의학) 전공

본 연구에서는 정상 개에서 자기공명영상장치를 이용하여 후지 자세 변화에 따른 척수 원추 위치변화를 확인하고자 하였으며, 자세 이동 시 발생하는 요천추 사이의 각도 변화를 측정하여 각도 변화에 따른 척수 원주의 위치 변화의 상관관계를 알아보고자 하였다.

실험에는 총 9마리의 건강한 비글견이 사용되었으며, 자세 변화는 요천추의 굽힘, 중립, 폄 총 세 가지로 진행되었다. 각각의 자세에서 시상면

T2 강조영상을 통해 요천추사이 각도와 척수 원추의 위치를 확인하고 자세에 따른 변화 정도를 측정하였다.

그 결과, 후지의 폄자세에서 굽힘자세로 변화함에 따라 요천추사이의 각도는 증가하였고, 척추 원추는 꼬리쪽으로 이동하는 형태를 보였으며, 둘 사이에는 높은 상관관계($P<0.05$) 및 선형의 회귀분포를 만족하는 것으로 확인되었다.($P<0.05$)

척수 원추의 이동 정도는 개체별로 다소 차이를 보이는 것으로 확인되어 본 연구에서 측정한 척수 원추 이동의 평균값을 대푯값으로 사용하는 것에는 한계점이 존재하는 것으로 생각된다. 다만 본 결과를 통해 흉요추 영역에 대한 해부학적 이해도를 높이는데 도움이 될 수 있을 것이며, 이전 한 자세의 자기공명영상으로만 평가하였을 때 감별진단에 어려움이 있었던 요천추 영역의 질환들에 대한 평가 및 치료반응 평가에 있어서도 유용하게 적용할 수 있을 것으로 생각된다.

주요어: 요천추, 척수원추, 자기공명영상, 요천추사이 각도, 요천추질환
학번: 2018-29823