의학 석사 학위논문

Objective Measurement of HINTS (Head Impulse, Nystagmus, Test of Skew) in acute peripheral vestibulopathy

급성 말초 전정병증에서 HINTS (두부충동검사, 주시유발안진검사, 스큐편위검사) 검사의 객관적 측정

2020 년 2 월

서울대학교 대학원

의학과 이비인후과학 전공

이 동 한

급성 말초 전정병증에서 HINTS (두부충동검사, 주시유발안진검사, 스큐편위검사)검사의 객관적 측정

지도교수 구 자 원

이 논문을 의학석사 학위논문으로 제출함
2019년 10월

서울대학교 대학원
의학과 이비인후과학
이 동 한

이동한의 석사 학위 논문을 인준함
2020년 1월

위 원 장 김 태 우 _____ (인)

부 위 원 장 구 자 원 _____ (인)

위 원 박 민 현 _____ (인)

Objective Measurement of HINTS (Head Impulse, Nystagmus, Test of Skew) in acute peripheral vestibulopathy

by
Dong-Han Lee

A Thesis submitted to the Department of Otorhinolaryngology in partial fulfillment of the requirements for the Degree of Master of Science in Otorhinolaryngology at Seoul National University College of Medicine

January 2020

Approved by Thesis Committee

Professor	Tae-Woo Kim	Chairman
Professor	Ja-Won Koo	Vice chairman
Professor	Min Hyun Park	

ABSTRACT

Objective Measurement of HINTS (Head Impulse, Nystagmus, Test of Skew) in acute peripheral vestibulopathy

Dong-Han Lee
Department of Otorhinolaryngology
Seoul National University College of Medicine

OBJECTIVES: Quantitative parameters of HINTS (Head-Impulse, Nystagmus, Test-of-Skew) were developed and analyzed in patients with acute peripheral vestibulopathy.

MATERIAL & METHODS: HINTS was evaluated in 14 patients with spontaneous nystagmus who visited the dizziness clinic of Seoul National University Bundang Hospital between November 2017 and August 2018. Horizontal vestibulo-ocular reflex (VOR) gain was measured during head impulse test (HIT). To evaluate gaze evoked nystagmus (GEN), slow phase velocities (SPV) at different points of lateral gaze were measured and plotted, and the slope was calculated. Skew deviation was tested using polarizing lens to simulate alternate cover test, and the degree and latency of vertical deviation were measured.

RESULTS: Among 13 patients of peripheral vestibulopathy, 7 showed positive

result in HINTS evaluation (normal HIT: 4, direction changing GEN: 0, skew deviation: 3) and 3 showed lateropulsion, suggesting central lesion. One patient with cerebellopontine angle tumor may have both peripheral and central lesion and he showed positive HINTS finding (presence of direction changing GEN). The mean VOR gain of patients with abnormal HIT was 0.61 ± 0.29 and 1.09 ± 0.11 in lesional and contralesional sides, respectively, while that in patients with normal HIT was 1.09 ± 0.22 and 1.16 ± 0.12, respectively. The mean slope of horizontal SPV according to horizontal eye position was -0.02 ± 0.02. The mean value of vertical eyeball deviation of patients with positive skew deviation was 2.14 ± 1.18° with lesional side eye uncovered, and -1.97 ± 1.59° with contralesional side eye uncovered, and that in patients with negative skew deviation was -0.07 ± 0.31° and 0.20 ± 0.49°, respectively.

CONCLUSIONS: HINTS was objectively measured in acute vertigo patients with peripheral vestibulopahthy and 54% of patients showed positive finding in HINTS evaluation.

Keywords: dizziness, vertigo, head impulse test, nystagmus, skew deviation

Student Number: 2018-21327

CONTENTS

LIST OF FIGURES

LIST OF TABLES

LIST OF ABBREVIATIONS

AVS : acute vestibular syndrome

HINTS : Head-Impulse, Nystagmus, Test-of-Skew

HIT : head impulse test

VOR : vestibule-ocular reflex

vHIT : video head impulse test

GEN : gaze evoked nystagmus

SNUBH : Seoul National University Bundang Hospital

IRB : institutional review board

CT : computed tomography

MRI : magnetic resonance imaging

SPV : slow phase velocity

VNG : video nystagmography

APV : acute peripheral vestibulopathy

CP : canal paresis

DP : directional preponderance

P : participant

Dur : duration

SN : spontaneous nystagmus

EyeSeeCam VOR Gains: VOR gains of vHIT measured in the EyeSeeCam

(Interacoustics, Denmark) system

ICS Impulse VOR Gains: VOR gains of vHIT measured in the ICS Impulse

(Otometrics, Natus Medical, Denmark) system

VN : vestibular neuritis

MD : Meniere's disease

DB : down beating

UB : up beating

VS : vestibular schwannoma

INTRODUCTION

Acute vestibular syndrome (AVS) is caused by acute onset of unilateral vestibular insult in either peripheral or central vestibular system.[1] Differentiation between central and peripheral causes of AVS is necessary, because a misdiagnosed central lesion (e.g., stroke) could be fatal or have serious sequelae.[2-5] In 2009, Kattah and colleagues reported that if the HINTS (Head-Impulse, Nystagmus, Test-of-Skew) exam showed positive findings, i.e., presence of normal horizontal head impulse test (HIT), direction-changing nystagmus in eccentric gaze, or skew deviation in AVS patients with high risk of stroke, the stroke could be differentiated with 100% sensitivity and 96% specificity.[6] Thus, HINTS exam has been clinically used as a bed-side test to distinguish between the AVS causes.

HINTS tests assess eyeball movements. HIT assesses the peripheral vestibular system by measuring the vestibule-ocular reflex (VOR) of the semicircular canals. It is based on the detection of corrective saccades occurring during (covert saccade) or after (overt saccade) head movement, and covert saccade cannot be detected without special equipment. In 1988, Halmagyi and Curthoys first attempted to quantify HIT using scleral search-coil recordings.[7] Because this method required the subject to wear an uncomfortable contact lens and was time-consuming and expensive, it was unsuitable for routine diagnosis. Since the video head impulse test (vHIT) was first introduced at the Barany Society in 2004, its quantitative measurements have become more convenient and it has been widely used to evaluate the peripheral vestibular function degradation.[8-11] Although vHIT gain and

catch-up saccades have been analyzed quantitatively,[12] there is no widely accepted report about the quantitative evaluation of gaze evoked nystagmus (GEN) or skew deviation in patients with dizziness.

Here, we performed quantitative evaluation of HINTS in patients with dizziness mainly associated with peripheral lesions using one device.

PATIENTS AND METHODS

1. Study population

HINTS was quantitatively measured in 14 patients with spontaneous nystagmus who visited the dizziness clinic of Seoul National University Bundang Hospital (SNUBH) from November 2017 to August 2018. Vestibular examination including HINTS and brain imaging were performed if necessary, and the diagnoses were made considering the clinical course. The study protocol was approved by the institutional review board (IRB) of SNUBH, Seongnam-si, Korea (IRB number : B-2001/592-109).

2. Quantitative testing of HINTS

Quantitative evaluation of HINTS was conducted using a modified device of the vHIT test (EyeSeeCam, Interacoustics, Denmark), which consists of an iPad screen with a shading cylinder and a goggle with red and blue polarizing lenses (Figure 1-A). The goggle is connected to the laptop computer with an accompanying software (OtoAccess™ version 1.4, Interacoustics, Denmark) installed. The participant wears goggles and looks at the screen through the shading cylinder to perform the GEN and skew deviation tests.

a. Calibrating the eye position

Before the GEN and skew deviation tests are conducted, calibration is performed. The screen shows two dots of red and blue side-by-side, but the participant wearing red and blue polarizing lenses in each eye recognizes it as a single dot. While the participant is watching the dots displayed on the screen, the dots start from the center, move to the right, center, left, center, up, center, down, and center, and the high-speed camera mounted on the goggles recognizes the movement of the eyeball and calibrates the eye position (Figure 1-B).

b. Head Impulse Test

vHIT was tested using both EyeSeeCam and ICS impulse system. Both systems are similar, and they use goggles that contain a high-speed camera to record the eyeball movement, and an inertial measurement unit gyroscope to measure the head velocity.[13] Horizontal VOR gain on vHIT was measured and used for analysis.

c. Gaze Evoked Nystagmus

For the GEN test, the participant wears goggles and stares at the front screen through the shading cylinder. The dots on the screen start from the center, move 6° to the right, then 12° to the right, return to the center again, move 6° to the left, and then move 12° to the left. The dots stay at each point for 10 seconds, and the objective gazing position and eye movement are recorded by the camera throughout the test (Figure 1-C).

d. Test of Skew

In the skew test, the polarizing lenses play the most important role. Because the right eye wears a blue polarizing lens and the left eye wears a red polarizing lens, the right eye recognizes only the red dot and the left eye only the blue dot on the screen. When only the red dot is displayed in the center of the dark screen, the left eye loses the object to focus on, which is the same as covering the left eye (right eye uncovered). When the red dot on the screen changes to blue, the right eye loses the object to focus on, causing the same effect as covering the right eye (left eye uncovered) (Figure 1-D). Every 2 seconds, the red and blue dots are alternated, and the eye movements are recorded throughout the process. This method can simulate the alternate cover test for viewing the skew, and has the advantage of simultaneously recording eye movements. From the motion of the eyeball recorded over time, we can quantitatively analyze the degree and speed of the eyeball displacement, and the latency after which the displacement begins to occur.

3. Variables and Measures

Complete medical histories were recorded, including age, sex, diagnosis, side of vestibulopathy, onset, duration and character of dizziness. Physical examination results and bithermal caloric test results were also reviewed. Brain imaging data including computed tomography (CT) and magnetic resonance imaging (MRI) were reviewed to identify central lesions associated with dizziness. Gain and presence of overt or covert saccade were analyzed in the vHIT results. Slow phase velocity (SPV) of nystagmus of each gaze position and the slope of SPV according

to gaze position was obtained in the GEN test. The latency and degree of eyeball deviation were obtained in the alternate cover test using the polarizing lens method. Ocular lateropulsion is a tonic bias of the eyeball toward the lesion side when visual fixation is interrupted, and it has been reported in association with the lateral medullary (Wallenberg) syndrome.[14-16] We observed subtle lateropulsion in some patients during the alternate cover test and analyzed the latency and degree of deviation.

The abnormal criterion for vHIT gain was 0.8.[8,12,17] GEN test was defined as positive when the SPV of direction changing nystagmus was ≥ 0.5°/s at each gaze direction. Skew test was defined as positive when the vertical displacement of eye position ascended or descended by ≥ 1° in the alternate cover test. Similarly, lateropulsion was defined as positive when the eye position changed by ≥ 1° in the horizontal direction.

RESULTS

Patient characteristics

The clinical characteristics, diagnosis, laboratory data of 14 patients (6 [42.9%] males; median age, 49 years [range, 38-71 years]) with spontaneous nystagmus are summarized in Tables 1 and 2. Among the 14 patients, 7 (50.0%) were diagnosed with vestibular neuritis, 5 (35.7%) with Meniere's disease, 1 (7.1%) with acute vertigo (unspecified), and 1 (7.1%) with vestibular schwannoma. The median duration of dizziness in these patients was 15 days (range, 3-557 days).

Case 1 (P12, F/71) left vestibular neuritis

A 71-year-old female was diagnosed with left vestibular neuritis. On video nystagmography (VNG) examination, spontaneous right beating nystagmus was documented. Bithermal caloric tests revealed 75% of left side canal paresis. The VOR gains of vHIT were right 1.09 and left 0.10 in the EyeSeeCam system, and right 0.83 and left 0.27 in the ICS impulse system, showing that the left gain was much lower compared to the right. GEN test showed that there was right beating nystagmus (SPV: -1.09°/s) on the 14° right gaze, but it disappeared on the 13° left gaze (SPV: -0.12°/s) following Alexander's law. The slope of horizontal SPV according to horizontal eye position was -0.03. The skew deviaion was not clear on the alternate cover test. In the record, the eye elevated about 0.04 ± 0.33° when the right eye was uncovered, and it depressed about 0.00 ± 0.18° when the left eye was uncovered (Figure 4).

Case 2 (P06, M/40) right vestibular neuritis

A 40-year-old male was diagnosed with right vestibular neuritis. VNG examination revealed spontaneous left beating nystagmus. Bithermal caloric tests revealed 37% of right side canal paresis. The VOR gains of vHIT were right 0.87 and left 1.02 in the EyeSeeCam system, and right 0.88 and left 1.01 in the ICS impulse system, showing that the right gain was slightly lower compared to the left. GEN test showed that there was left beating nystagmus (SPV: 1.37°/s) on the 12° left gaze, but it disappeared on the 13° right gaze (SPV: 0.38°/s) following Alexander's law. The slope of horizontal SPV according to horizontal eye position was -0.04. The alternate cover test showed positive result for skew deviation. In the record, the eye elevated about 1.10 ± 0.95° when the right eye was uncovered, and it depressed about 1.28 ± 1.28° when the left eye was uncovered (Figure 5).

Case 3 (P07, M/44) right vestibular schwannoma

A 44-year-old male was diagnosed with right vestibular schwannoma. MRI images revealed 3.6-cm-sized vestibular schwannoma in the right cerebropontine angle. Patient's dizziness was attributed to both central and peripheral lesions, because the tumor involved both lesions. VNG examination revealed spontaneous left beating nystagmus. Bithermal caloric tests revealed 75% of right side canal paresis. The gains of vHIT were right 0.50 and left 1.02 in the EyeSeeCam system, and right 0.48 and left 0.87 in the ICS impulse

system, showing that the right side gain was lower compared to the left. GEN test showed that there was slight right beating nystagmus (SPV: -1.07°/s) on the 18° right gaze, and slight left beating nystagmus (SPV: 0.52°/s) on the 13° left gaze. The slope of horizontal SPV according to horizontal eye position was -0.05. The alternate cover test showed no definite skew deviation or lateropulsion (Figure 6).

Quantitative measurements of HINTS results

HINTS was quantitatively measured using the modified version of the existing vHIT system. The quantitative measurements involved (1) gain in vHIT, (2) SPV slope in GEN, and (3) latency and degree of skew and lateropulsion in the alternate cover test. The mean VOR gain of patients with abnormal HIT was 0.61 ± 0.29 (EyeSeeCam) and 0.55 ± 0.21 (ICS Impulse) on the lesional side, and 1.09 ± 0.11 (EyeSeeCam) and 0.90 ± 0.09 (ICS Impulse) on the contralesional side. The mean VOR gain of patients with normal HIT was 1.09 ± 0.22 (EyeSeeCam) and 0.95 ± 0.06 (ICS Impulse) on the lesional side, and 1.16 ± 0.12 (EyeSeeCam) and 0.94 ± 0.07 (ICS Impulse) on the contralesional side. The mean SPV in the GEN test was -0.27 ± 0.68°/s at 12° right gaze position, and 0.32 ± 0.59°/s at 12° left gaze position. The mean slope of horizontal SPV according to the horizontal eye position was -0.02 ± 0.02. The mean value of vertical eyeball deviation of patients with positive skew deviation was 2.14 ± 1.18° when the lesional side eye was uncovered and -1.97 ± 1.59° when the contralesional side eye was uncovered; whereas, in patients with negative skew deviation, it was -0.07 ± 0.31° when the lesional side eye was

uncovered and 0.20 ± 0.49° when the contralesional side eye was uncovered.

Summary of the objective measurements of HINTS

The quantitative HINTS evaluation results of 14 cases are summarized in Table 2. Of 14 patients with spontaneous nystagmus, 13 were associated with peripheral lesions, but 7 of them showed positive HINTS findings (normal HIT: 4, presence of direction changing GEN: 0, presence of skew: 3), and 3 showed lateropulsion. One patient had mixed peripheral and central lesion and showed positive HINTS finding (presence of direction changing GEN).

DISCUSSION

Most patients with AVS have acute peripheral vestibulopathy (APV), but some have stroke including the posterior circulation, therefore efforts have been made to distinguish them.[18] The pattern of nystagmus has been known to distinguish APV from pseudo-vestibular neuritis.[1] However, evidence of nystagmus pattern alone is not enough to distinguish between the cases.[19] Although clinicians have become increasingly reliant on brain MRI, it is not always available on time. Furthermore, it is known that MRI has 12% chances of false negativity for central lesion in the diagnosis of patients with AVS.[6] Since better and quick diagnostic tests are important to identify the central lesion, the clinical importance of HINTS has been emphasized and strengthened over the past decade.[20]

Normal findings of HIT in AVS have been known to strongly suggest central lesions.[21] Quantitative analysis of the test has been studied using various quantitative test tools.[7-11,13,17,22] Recent studies analyzed the vHIT gain and catch-up saccades quantitatively.[12] We performed vHIT with two different devices in the same patient and the results were generally consistent, indicating that the quantitative measurement tool of the HIT is fairly reproducible. As quantitative analysis of HIT has become more common and reliable, research is possible in varying test conditions including head velocities and accelerations.[23] However, there is no widely accepted report about the quantitative evaluation of GEN or skew deviation in patients with dizziness.

GEN occurs by the attempted maintenance of an eccentric eye position, and it

is caused by cerebellar and brainstem lesions, reflecting a deficiency of the neural integrator.[24] There have been a report that quantitatively measured GEN in 18 patients with acute balance problem without radiological neuropathology.[25] According to that study, the SPV of GEN ranged between 6 - 19°/s. However, that study recruited selective patients who showed GEN and mainly focused on analyzing optokinetic response, and none of them had spontaneous nystagmus in contrast to the participants in our study.

GEN elicited at extreme horizontal fields of gaze (end-point nystagmus) is usually physiologic; therefore, the examiner should be careful that the participant does not gaze in extreme directions when directing the eccentric gaze to induce GEN. Moreover, our observations showed that the SPV changed according to the gazing position. Therefore, for quantitative analysis, the stimulus should be presented under control. When measuring GEN with the equipment used here, it controlled the degree of eccentric gaze at a constant, which helped to maintain consistency of test conditions. We used 12° gaze conditions, and we need more data to determine whether this is the optimal condition for causing clear GEN. Since GEN with a low SPV, especially in elderly patients, is known to usually physiologic,[25] we need more data on the range of normal GEN. We mentioned only the slope of SPV according to the eye position in the GEN test, but the slope value itself does not mean that the GEN's direction has changed according to the gaze position. The direction change and intensity of GEN can be properly reflected by referring to the SPV values on the both right and left gaze.

Skew deviation is a vertical misalignment of the eyes caused by a

supranuclear lesion in the posterior fossa.[26-28] The vertical misalignment of eye is commonly detected by the alternate cover test, and it can be measured quantitatively with prismatic correction.[29] In this study, we were able to easily record and measure skew deviations or lateropulsion using only one device, without using additional eye occluder or prism bars with various refraction angles. There is limited information about the latency of eyeball deviation in the alternate cover test. Our data showed that there are about 0.3 - 0.4 seconds of latencies in skew deviation and lateropulsion. Currently, it is difficult to decipher the clinical meaning of this latency because there is limited data; hence, further data collection is needed in the future.

In this study, we first attempted a quantitative HINTS exam for dizziness patients with spontaneous nystagmus. Quantifying and recording the HINTS test were possible by using the modified version of the existing vHIT system. When conducting a GEN or alternate cover test without a recording device, the examiner could recognize the obvious eye movement and should make a judgment immediately. However, with the recorded eye movement data, we can detect subtle eye movements and make quantitatively reviewed decision for the results objectively.

Contrary to the previous study that insisted positive findings of HINTS exam could distinguish central causes of AVS,[6] our study on quantitative HINTS exam showed interesting results. Although HINTS was performed in patients with peripheral lesions, the positive rate of central findings was higher than expected. Our results suggest that there could be some cases of normal HIT (28.6%) and

skew deviation (21.4%) or lateropulsion (21.4%) in peripheral lesions. There are several reasons why our results are different from the conclusions of the previous report. First, the previous report was a conclusion drawn from patients with stroke risk factors; hence, this difference in the patient groups could have caused this difference. Our study provides information on how HINTS can appear in a more extended patients group. Second, objective measurement could detect more subtle eye movements, leading to this result.

Limitations

Comparing our quantitative data with HINTS exam without equipment would be important. Unfortunately, the HINTS examinations without equipment were not available for the 14 patients. Additionally, we performed HINTS exam only once in one patient, so the reproducibility of the test is still insufficient. We think that future data will be needed to see if quantitative tests are reproduced in repeated measurements.

Furthermore, the duration from the onset of dizziness to the time of HINTS exam was not equal among the patients. This indicates that some data could be indicative of the time when the symptoms reduced or disappeared, and this should be considered when interpreting the results. However, since we only selected patients with spontaneous nystagmus, our results reflected the data from patients with acute periods of symptoms.

Our study included patients with peripheral vestibulopathy and used the arbitrary criteria for each test, except vHIT gain. We need further quantitative

evaluation of HINTS in patients with central lesions, where each data may be more pronounced. Moreover, we did not have data from normal participants about the quantitative testing of HINTS. This quantitative analysis is necessary to establish the criteria for the range of normal and abnormal. Since the number of patients analyzed was small, it is necessary to conduct a planned study on a large number of patients with various causes of AVS in the future.

Despite these limitations, our study is meaningful because it was the first attempt to quantitatively measure the HINTS test. The quantitative measurement of HINTS can be conducted in a relatively short time by using simple equipment that needs minimal modification of an existing device.

CONCLUSION

The quantitative measurement of HINTS could be helpful in the clinical field encountering patients with dizziness by enabling visual reproduction of test results and diagnosis based on improved objectivity. Although positive findings of HINTS have been reported to suggest a central lesion, our findings suggested that there are some cases showing positive findings of HINTS in patients with acute vertigo associated with peripheral lesions.

REFERENCES

1. Hotson JR, Baloh RW. Acute vestibular syndrome. *The New England journal of medicine.* 1998;339(10):680-685.
2. Glass TA, Hennessey PM, Pazdera L, et al. Outcome at 30 days in the New England Medical Center Posterior Circulation Registry. *Archives of neurology.* 2002;59(3):369-376.
3. Edlow JA, Newman-Toker DE, Savitz SI. Diagnosis and initial management of cerebellar infarction. *The Lancet Neurology.* 2008;7(10):951-964.
4. Savitz SI, Caplan LR, Edlow JA. Pitfalls in the diagnosis of cerebellar infarction. *Academic emergency medicine.* 2007;14(1):63-68.
5. Kerber KA, Brown DL, Lisabeth LD, Smith MA, Morgenstern LB. Stroke among patients with dizziness, vertigo, and imbalance in the emergency department: a population-based study. *Stroke.* 2006;37(10):2484-2487.
6. Kattah JC, Talkad AV, Wang DZ, Hsieh YH, Newman-Toker DE. HINTS to diagnose stroke in the acute vestibular syndrome: three-step bedside oculomotor examination more sensitive than early MRI diffusion-weighted imaging. *Stroke.* 2009;40(11):3504-3510.
7. Halmagyi GM, Curthoys IS. A clinical sign of canal paresis. *Archives of neurology.* 1988;45(7):737-739.
8. Van Esch B, Nobel-Hoff G, Van Benthem P, Van Der Zaag-Loonen H, Bruintjes TD. Determining vestibular hypofunction: start with the video-head impulse test. *European Archives of Oto-Rhino-Laryngology.* 2016;273(11):3733-3739.
9. MacDougall HG, Weber KP, McGarvie LA, Halmagyi GM, Curthoys IS. The video head impulse test: diagnostic accuracy in peripheral vestibulopathy. *Neurology.* 2009;73(14):1134-1141.
10. Ulmer E, Chays A. [Curthoys and Halmagyi Head Impulse test: an analytical device]. *Annales d'oto-laryngologie et de chirurgie cervico faciale : bulletin de la Societe d'oto-laryngologie des hopitaux de Paris.* 2005;122(2):84-90.
11. MacDougall HG, McGarvie LA, Halmagyi GM, et al. A new saccadic indicator of peripheral vestibular function based on the video head

impulse test. *Neurology.* 2016;87(4):410-418.

12. Yang C, Lee J, Kang B, Lee H, Yoo M, Park H. Quantitative analysis of gains and catch-up saccades of video-head-impulse testing by age in normal subjects. *Clinical Otolaryngology.* 2016;41(5):532-538.
13. Cleworth TW, Carpenter MG, Honegger F, Allum JHJ. Differences in head impulse test results due to analysis techniques. *Journal of vestibular research : equilibrium & orientation.* 2017;27(2-3):163-172.
14. Crevits L, vander Eecken H. Ocular lateropulsion in Wallenberg's syndrome: a prospective clinical study. *Acta neurologica Scandinavica.* 1982;65(3):219-222.
15. Koter R, Regan S, Clark C, et al. Clinical Outcome Measures for Lateropulsion Poststroke: An Updated Systematic Review. *Journal of neurologic physical therapy : JNPT.* 2017;41(3):145-155.
16. Meyer KT, Baloh RW, Krohel GB, Hepler RS. Ocular lateropulsion: a sign of lateral medullary disease. *Archives of Ophthalmology.* 1980;98(9):1614-1616.
17. Weber KP, Aw ST, Todd MJ, McGarvie LA, Curthoys IS, Halmagyi GM. Head impulse test in unilateral vestibular loss: vestibulo-ocular reflex and catch-up saccades. *Neurology.* 2008;70(6):454-463.
18. Lee H, Cho Y-W. A case of isolated nodulus infarction presenting as a vestibular neuritis. *Journal of the neurological sciences.* 2004;221(1-2):117-119.
19. Lee H, Sohn S-I, Cho Y-W, et al. Cerebellar infarction presenting isolated vertigo: frequency and vascular topographical patterns. *Neurology.* 2006;67(7):1178-1183.
20. Kattah JC. Use of HINTS in the acute vestibular syndrome. An Overview. *Stroke and vascular neurology.* 2018;3(4):190-196.
21. Newman-Toker DE, Kattah JC, Alvernia JE, Wang DZ. Normal head impulse test differentiates acute cerebellar strokes from vestibular neuritis. *Neurology.* 2008;70(24 Pt 2):2378-2385.
22. Hougaard DD, Abrahamsen ER. Functional Testing of all Six Semicircular Canals with Video Head Impulse Test Systems. *Journal of visualized experiments : JoVE.* 2019(146).

23. Kim TS, Lim HW, Yang CJ, et al. Changes of video head impulse test results in lateral semicircular canal plane by different peak head velocities in patients with vestibular neuritis. *Acta oto-laryngologica.* 2018;138(9):785-789.
24. Buttner U, Grundei T. Gaze-evoked nystagmus and smooth pursuit deficits: their relationship studied in 52 patients. *Journal of neurology.* 1995;242(6):384-389.
25. Yetiser S, Ince D, Yetiser B. Optokinetic Analysis in Patients With Spontaneous Horizontal Gaze-Evoked Nystagmus Without Radiological Neuropathology. *Ear, nose, & throat journal.* 2019;98(7):420-424.
26. Brodsky MC, Donahue SP, Vaphiades M, Brandt T. Skew deviation revisited. *Survey of ophthalmology.* 2006;51(2):105-128.
27. Wong AM. Understanding skew deviation and a new clinical test to differentiate it from trochlear nerve palsy. *Journal of AAPOS : the official publication of the American Association for Pediatric Ophthalmology and Strabismus.* 2010;14(1):61-67.
28. Safran AB, Vibert D, Issoua D, Hausler R. Skew deviation after vestibular neuritis. *American journal of ophthalmology.* 1994;118(2):238-245.
29. Klaehn LD, Hatt SR, Leske DA, Holmes JM. Role of a Standardized Prism Under Cover Test in the Assessment of Dissociated Vertical Deviation. *Strabismus.* 2018;26(1):1-5.

Figure 1. Modified vHIT device and test methods.

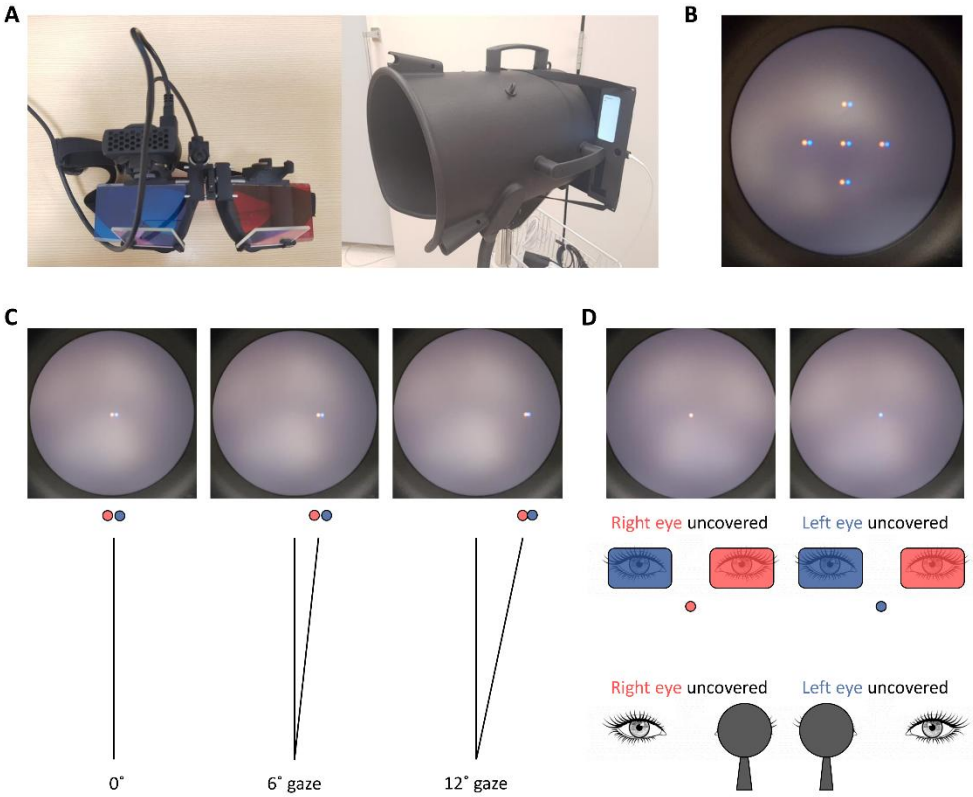

A. Polarizing goggles and iPad screen with a shading cylinder. **B.** Eye position calibration. **C.** Gazing positions in the GEN test. **D.** The polarizing goggle method to simulate the alternate cover test.

Figure 2. Example of result showing direction changing GEN

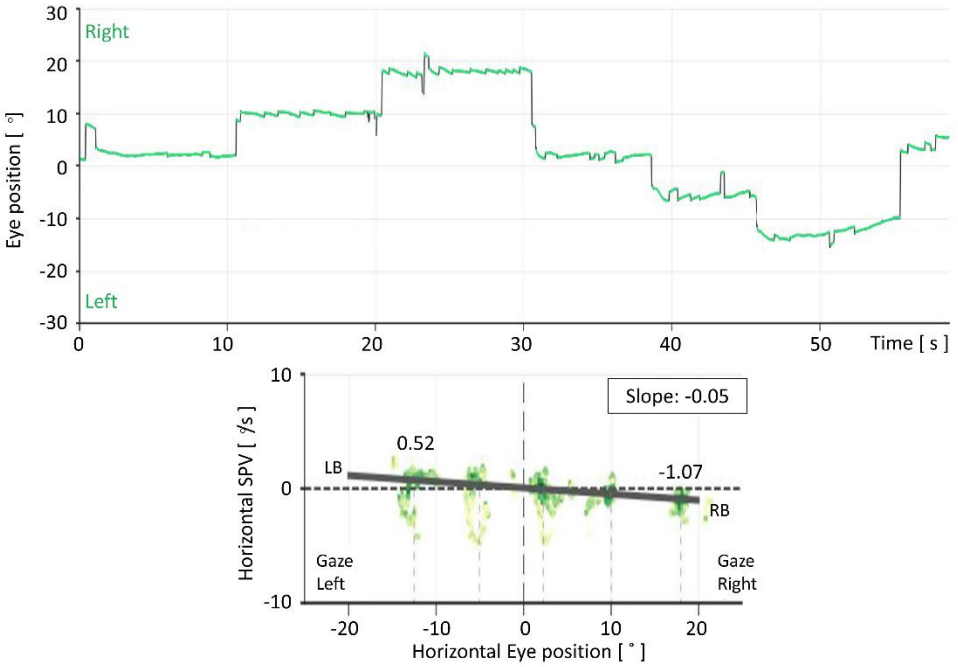

GEN test shows that there is slight right beating nystagmus (SPV: -1.07°/s) on the 18° right gaze position, and slight left beating nystagmus (SPV: 0.52°/s) on the 13° left gaze position. The slope of horizontal SPV according to horizontal eye position was -0.05.

Figure 3. Example of result showing skew deviation

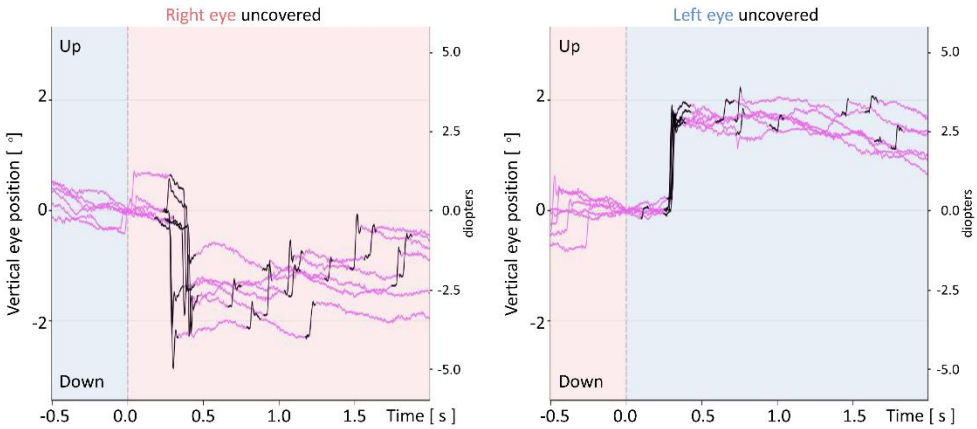

The alternate cover test shows that mean downward deviation is 0.84 ± 0.46° when the right eye was uncovered and mean upward deviation is 1.91 ± 0.38° when the left eye was uncovered.

Figure 4. Quantitative results of HINTS for patient with left vestibular neuritis

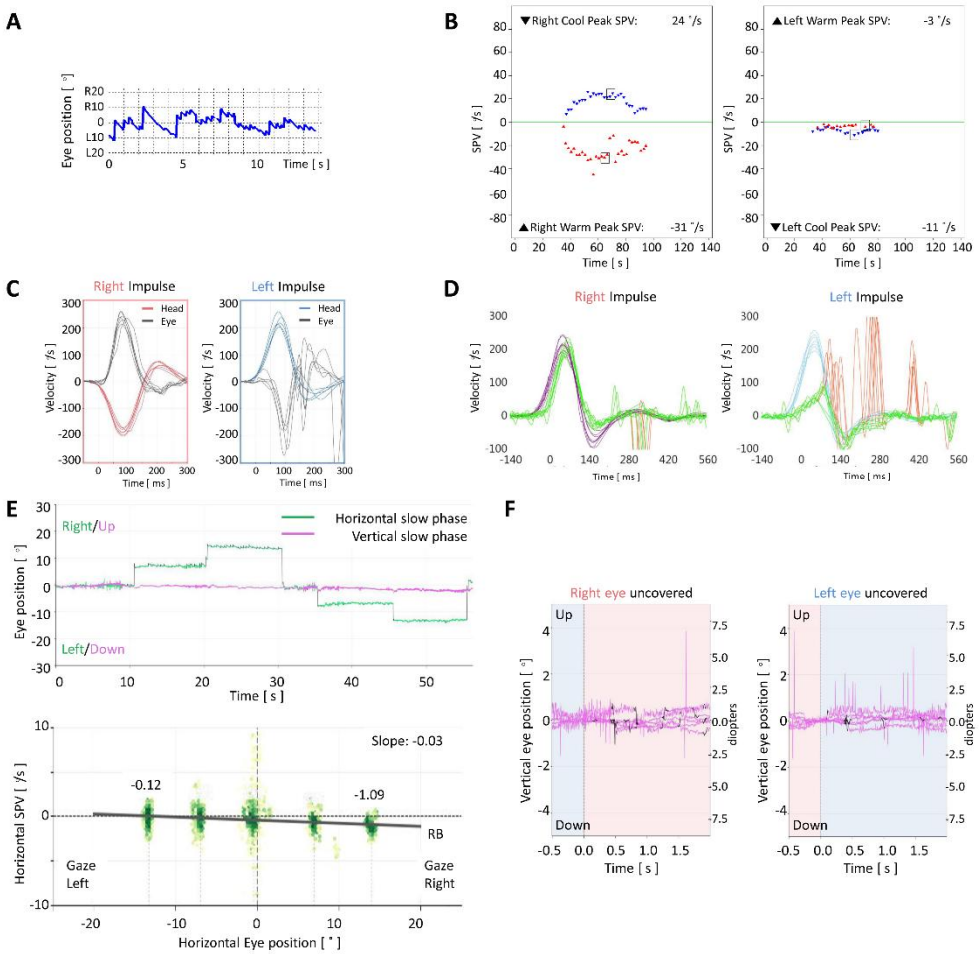

A. VNG shows spontaneous nystagmus with peak SPV: -9°/s at 2.7s. **B.** Caloric test reveals 75% canal paresis (CP) in the left ear and 33% directional preponderance (DP) to the right ear. **C.** vHIT result in the EyeSeeCam system shows VOR gains of right 1.09 and left 0.10. **D.** vHIT result in the ICS impulse system shows VOR gains of right 0.83 and left 0.27. **E.** GEN test shows right beating nystagmus (SPV: -1.09°/s) on the 14° right gaze, but it disappeared on the 13° left gaze (SPV: -0.12°/s). **F.** Skew deviation was not clear in the alternate cover test.

Figure 5. Quantitative results of HINTS for patient with right vestibular neuritis

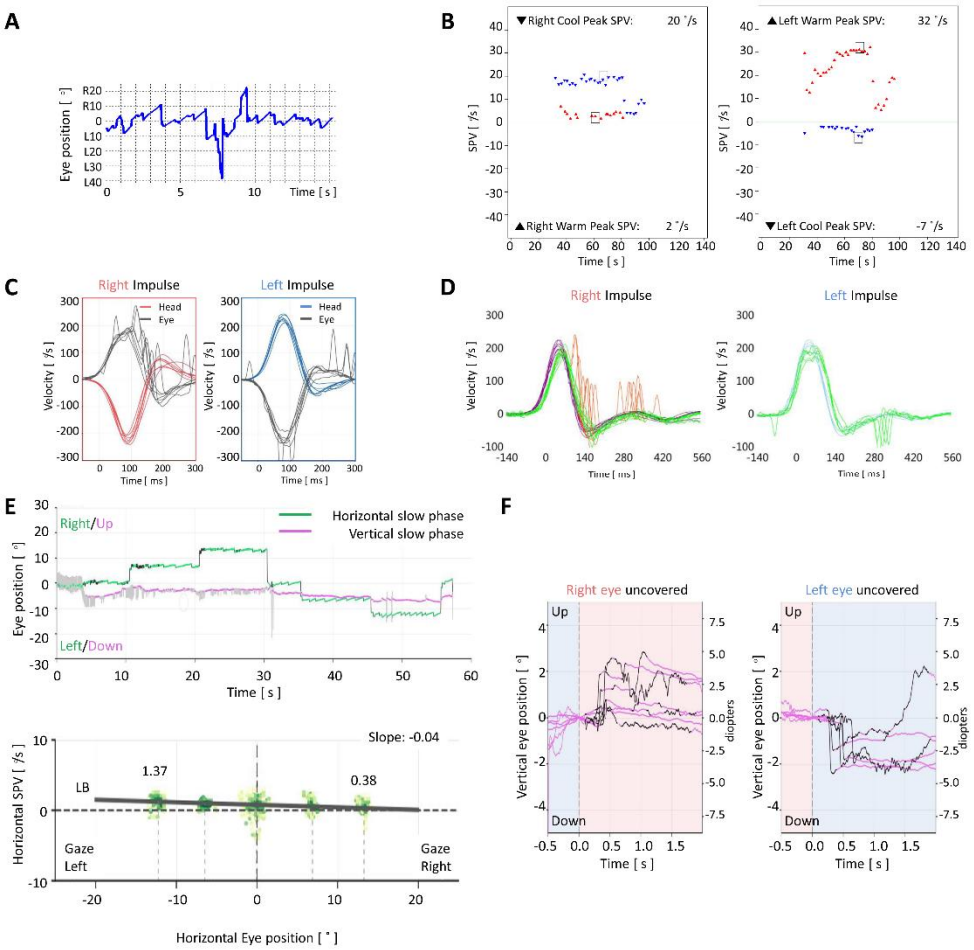

A. VNG shows spontaneous nystagmus with peak SPV: 9°/s at 6.3s. **B.** Caloric test reveals 37% CP in the right ear and 82% DP to the left ear. **C.** vHIT result in the EyeSeeCam system shows VOR gains of right 0.87 and left 1.02. **D.** vHIT result in the ICS impulse system shows VOR gains of right 0.88 and left 1.01. **E.** GEN test shows left beating nystagmus (SPV: 1.37°/s) on the 12° left gaze, but it disappeared on the 13° right gaze (SPV: 0.38 °/s). **F.** Skew deviation was observed in the alternate cover test. The eye elevated about 1.10 ± 0.95° when the right eye was uncovered, and it depressed about 1.28 ± 1.28° when the left eye was uncovered.

Figure 6. Quantitative results of HINTS for patient with right vestibular schwannoma

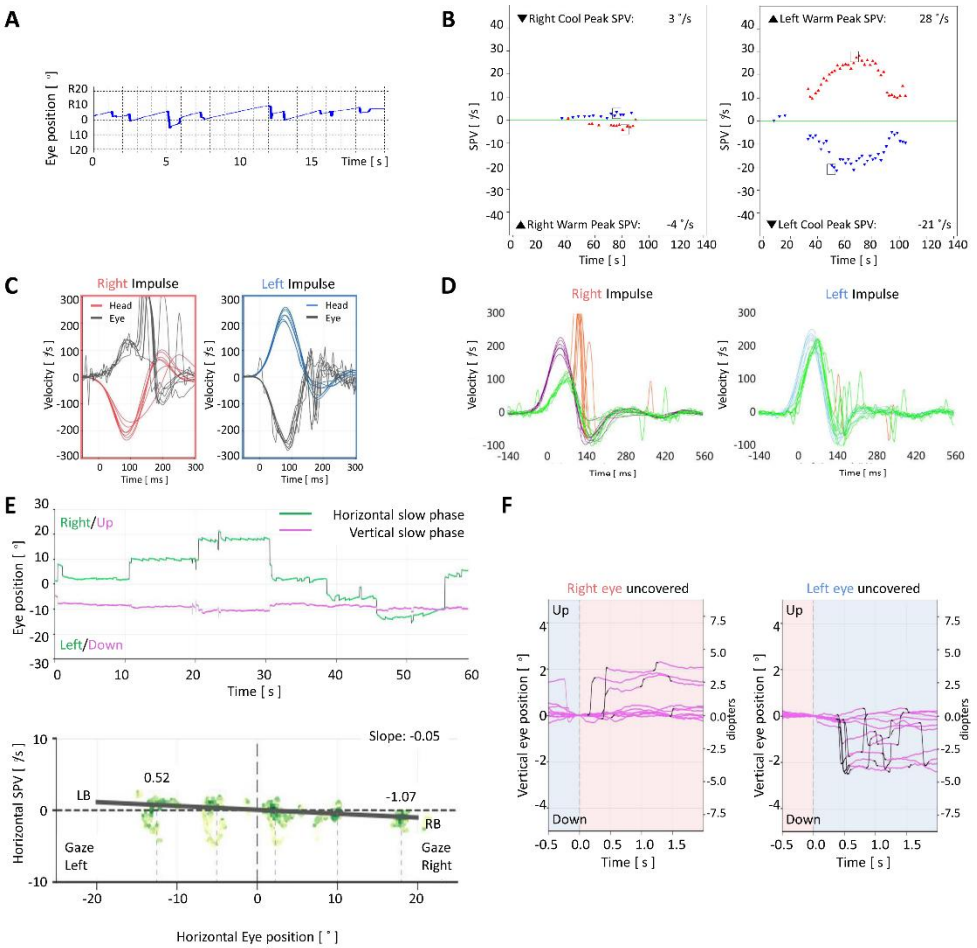

A. VNG shows spontaneous nystagmus with peak SPV: 2°/s at 17.9s. **B.** Caloric test reveals 75% CP in the right ear and 11% DP to the left ear. **C.** vHIT result in the EyeSeeCam system shows VOR gains of right 0.50 and left 1.02. **D.** vHIT result in the ICS impulse system shows VOR gains of right 0.48 and left 0.87. **E.** GEN test shows right beating nystagmus of SPV -1.07°/s on the 18° right gaze and left beating nystagmus of SPV 0.52°/s on the 13° left gaze. **F.** Skew deviation was not clear in the alternate cover test.

Table 1. HINTS results of 14 patients with spontaneous nystagmus.

P	Sex/ Age	Dur (d)	Diagnosis	SN [a] (°/s)	CP [b] (%)	EyeSeeCam VOR Gains		ICS Impulse VOR Gains		GEN (slope)	Vertical eye position [c] lesional uncover (med ± std °)	Vertical eye position [c] contralesional uncover (med ± std °)
						lesional	contralesional	lesional	contralesional			
P01	F/64	15	VN	-2	64	**0.80**	**1.19**	**0.63**	**0.94**	-0.03	-0.16 ± 0.45	0.52 ± 0.80
P02	F/42	15	MD, acute	8DB	53	N/A	N/A	0.95	0.99	-0.01	-0.24 ± 0.42	-0.63 ± 0.16
P03	M/38	10	Acute vertigo, unspecified [d]	5	12	1.31	1.30	0.98	0.92	-0.02	-0.19 ± 0.16	0.40 ± 0.49
P04	F/49	557	MD, recovery	-3	64	0.88	1.11	0.86	0.85	-0.01	-0.02 ± 0.14	-0.19 ± 0.25
P05	F/57	12	VN	3,3UB	100	**0.19**	**0.84**	**0.18**	**0.71**	-0.03	-0.45 ± 0.11	0.47 ± 0.45
P06	M/40	3	VN	9	37	**0.87**	**1.02**	**0.88**	**1.01**	-0.04	**1.10 ± 0.95**	**-1.28 ± 1.28**
P07	M/44	251	VS	2	75	**0.50**	**1.02**	**0.48**	**0.87**	**-0.05**	0.07 ± 0.83	-0.27 ± 0.86
P08	M/63	64	VN	5	40	**0.77**	**1.14**	**0.64**	**0.84**	0	**3.42 ± 0.39**	**-3.78 ± 1.30**
P10	M/45	20	MD	2	100	**0.79**	**1.17**	**0.69**	**0.98**	0	0.05 ± 1.42	0.06 ± 0.22
P11	F/49	154	MD	-1	4	1.08	1.08	1.00	1.01	-0.03	-0.42 ± 0.30	0.00 ± 0.12
P12	F/71	10	VN	9	75	**0.10**	**1.09**	**0.27**	**0.83**	-0.03	-0.00 ± 0.18	0.04 ± 0.33
P13	F/46	4	VN	9	56	**0.83**	**1.17**	**0.62**	**0.96**	-0.05	**1.91 ± 0.38**	**-0.84 ± 0.46**
P14	F/56	5	MD	1	59	**0.84**	**1.17**	**0.69**	**0.88**	-0.02	0.69 ± 0.26	1.05 ± 0.48
P15	M/61	195	VN	2	73	**0.37**	**1.13**	**0.40**	**0.94**	-0.01	-0.06 ± 0.33	0.73 ± 0.52

[a] positive value means spontaneous nystagmus to the contralesional side and negative means to the lesional side, respectively.

[b] canal paresis of lesional side.

[c] positive value means eyeball deviation to the upper direction and negative means to the lower direction, respectively.

[d] participant P03 was diagnosed with acute vertigo, unspecified, because caloric paresis and MRI finding were within normal limit and clinical course did not suggest any central cause.

** Underlined bold values indicate that the result of the test is abnormal.

HINTS: Head-Impulse, Nystagmus, Test-of-Skew, P: participant, Dur: duration, SN: spontaneous nystagmus, CP: canal paresis, EyeSeeCam VOR Gains: VOR gains of vHIT measured in the EyeSeeCam (Interacoustics, Denmark) system, ICS Impulse VOR Gains: VOR gains of vHIT measured in the ICS Impulse (Otometrics, Natus Medical, Denmark) system, VOR: vestibule-ocular reflex, GEN: gaze evoked nystagmus, VN: vestibular neuritis, MD: Meniere's disease, DB: down beating, UB: up beating, VS: vestibular schwannoma.

Table 2. Demographic and laboratory findings and positive rate of each component implicating central and peripheral signs in HINTS exam.

Age	51.8 ± 10.2	
Spontaneous Nystagmus		
Lesional side	3 / 14 (21.4%)	
Contralesional side	10 / 14 (71.4%)	
Other	1 / 14 (7.1%)	
Canal Paresis		
No	2 / 14 (14.3%)	
Lesional side		12 / 14 (85.7%)
Contralesional side	0	
	Sign of central lesion	Sign of peripheral lesion
HIT		
Nomal	4 / 14 (28.6%)	
Abnormal		10 / 14 (71.4%)
GEN		
Positive	1 / 14 (7.1%)	
Negative		13 / 14 (92.9%)
Skew deviation		
Positive	3 / 14 (21.4%)	
Negative		11 / 14 (78.6%)
Lateropulsion		
Positive	3 / 14 (21.4%)	
Negative		11 / 14 (78.6%)

HINTS: Head-Impulse, Nystagmus, Test-of-Skew, VOR: vestibule-ocular reflex, vHIT: video head impulse test, GEN: gaze evoked nystagmus

국 문 초 록

급성 말초 전정병증에서 HINTS (두부충동검사, 주시유발안진검사, 스큐편위검사)검사의 객관적 측정

서울대학교 의과대학
이비인후과학 전공 이 동 한

목적: 본 연구는 급성 말초 전정병증 환자에서 HINTS (두부충동검사, 주시유발안진검사, 스큐편위검사)의 정량적 파라미터를 개발하고 분석하였다.

방법: HINTS는 2017년 11월부터 2018년 8월까지 자발안진을 동반하며 분당 서울대학교 병원의 어지럼증 클리닉을 방문한 14명의 환자에서 분석되었다. 두부충동검사에서 수평 전정안구반사의 이득을 측정하였다. 주시유발안진을 평가하기 위해 각기 다른 지점 측방 주시시 발생하는 안진의 느린 성분 속도를 측정하고 플롯팅하여, 수평 주시위치의 변화에 따른 서상 안진 속도 변화의 기울기를 계산하였다. 편광렌즈를 사용한 교대눈가림검사 방법으로 스큐편위를 검사하였고, 안구의 수직편위 정도와 편위발생의 잠복기를 측정하였다.

결과: 13명의 말초 전정병증 환자들 중, 7명에서 HINTS 양성소견을 보였다. (두부충동검사상 정상 : 4명, 방향이 변하는 주시유발안진 : 0명,

스큐편위 : 3명) 그리고 3명에서 중추성 병변을 시사하는 측방편위 소견을 보였다. 한명의 소뇌교뇌각 종양 환자는 말초성 병변과 중추성 병변이 함께 관련되어 있었고 HINTS 양성 소견을 보였다. (방향이 변하는 주시유발 안진) 두부충동검사상 비정상을 보인 환자에서의 평균 전정안구반사 이득은 병변측과 병변반대측에서 각각 0.61 ± 0.29, 1.09 ± 0.11이었다. 반면, 두부충동검사가 정상인 환자의 평균 전정안구반사 이득은 각각 1.09 ± 0.22, 1.16 ± 0.12이었다. 눈의 주시위치에 따른 수평 서상안진속도의 평균 기울기는 −0.02 ± 0.02이었다. 스큐편위에서 양성을 보인 환자의 수직안구편위 평균값은 병변측 시야가 노출 되었을 때 2.14 ± 1.18 °, 병변반대측 시야가 노출 되었을 때 −1.97 ± 1.59 °였다. 스큐편위에서 음성을 보인 환자에서는 각각 −0.07 ± 0.31 °, 0.20 ± 0.49 °였다.

결론: HINTS는 말초 전정병증을 가진 급성 어지러움 환자에서 객관적으로 측정되었으며 54%의 환자가 HINTS 평가에서 양성 소견을 보였다.

주요어 : 어지럼증, 현훈, 두부충동검사, 안진, 스큐편위

학번 : 2018-21327

의학 석사 학위논문

Objective Measurement of HINTS (Head Impulse, Nystagmus, Test of Skew) in acute peripheral vestibulopathy

급성 말초 전정병증에서 HINTS (두부충동검사, 주시유발안진검사, 스큐편위검사) 검사의 객관적 측정

2020 년 2 월

서울대학교 대학원

의학과 이비인후과학 전공

이 동 한

급성 말초 전정병증에서 HINTS (두부충동검사, 주시유발안진검사, 스큐편위검사)검사의 객관적 측정

지도교수 구 자 원

이 논문을 의학석사 학위논문으로 제출함
2019년 10월

서울대학교 대학원
의학과 이비인후과학
이 동 한

이동한의 석사 학위 논문을 인준함
2020년 1월

위 원 장 김 태 우 _____(인)

부 위 원 장 구 자 원 _____(인)

위 원 박 민 현 _____(인)

Objective Measurement of HINTS (Head Impulse, Nystagmus, Test of Skew) in acute peripheral vestibulopathy

by
Dong-Han Lee

A Thesis submitted to the Department of Otorhinolaryngology in partial fulfillment of the requirements for the Degree of Master of Science in Otorhinolaryngology at Seoul National University College of Medicine

January 2020

Approved by Thesis Committee

Professor	Tae-Woo Kim	Chairman
Professor	Ja-Won Koo	Vice chairman
Professor	Min Hyun Park	

ABSTRACT

Objective Measurement of HINTS (Head Impulse, Nystagmus, Test of Skew) in acute peripheral vestibulopathy

Dong-Han Lee
Department of Otorhinolaryngology
Seoul National University College of Medicine

OBJECTIVES: Quantitative parameters of HINTS (Head-Impulse, Nystagmus, Test-of-Skew) were developed and analyzed in patients with acute peripheral vestibulopathy.

MATERIAL & METHODS: HINTS was evaluated in 14 patients with spontaneous nystagmus who visited the dizziness clinic of Seoul National University Bundang Hospital between November 2017 and August 2018. Horizontal vestibulo-ocular reflex (VOR) gain was measured during head impulse test (HIT). To evaluate gaze evoked nystagmus (GEN), slow phase velocities (SPV) at different points of lateral gaze were measured and plotted, and the slope was calculated. Skew deviation was tested using polarizing lens to simulate alternate cover test, and the degree and latency of vertical deviation were measured.

RESULTS: Among 13 patients of peripheral vestibulopathy, 7 showed positive

result in HINTS evaluation (normal HIT: 4, direction changing GEN: 0, skew deviation: 3) and 3 showed lateropulsion, suggesting central lesion. One patient with cerebellopontine angle tumor may have both peripheral and central lesion and he showed positive HINTS finding (presence of direction changing GEN). The mean VOR gain of patients with abnormal HIT was 0.61 ± 0.29 and 1.09 ± 0.11 in lesional and contralesional sides, respectively, while that in patients with normal HIT was 1.09 ± 0.22 and 1.16 ± 0.12, respectively. The mean slope of horizontal SPV according to horizontal eye position was -0.02 ± 0.02. The mean value of vertical eyeball deviation of patients with positive skew deviation was 2.14 ± 1.18° with lesional side eye uncovered, and -1.97 ± 1.59° with contralesional side eye uncovered, and that in patients with negative skew deviation was -0.07 ± 0.31° and 0.20 ± 0.49°, respectively.

CONCLUSIONS: HINTS was objectively measured in acute vertigo patients with peripheral vestibulopahthy and 54% of patients showed positive finding in HINTS evaluation.

Keywords: dizziness, vertigo, head impulse test, nystagmus, skew deviation

Student Number: 2018-21327

CONTENTS

LIST OF FIGURES

LIST OF TABLES

LIST OF ABBREVIATIONS

AVS : acute vestibular syndrome

HINTS : Head-Impulse, Nystagmus, Test-of-Skew

HIT : head impulse test

VOR : vestibule-ocular reflex

vHIT : video head impulse test

GEN : gaze evoked nystagmus

SNUBH : Seoul National University Bundang Hospital

IRB : institutional review board

CT : computed tomography

MRI : magnetic resonance imaging

SPV : slow phase velocity

VNG : video nystagmography

APV : acute peripheral vestibulopathy

CP : canal paresis

DP : directional preponderance

P : participant

Dur : duration

SN : spontaneous nystagmus

EyeSeeCam VOR Gains: VOR gains of vHIT measured in the EyeSeeCam

(Interacoustics, Denmark) system

ICS Impulse VOR Gains: VOR gains of vHIT measured in the ICS Impulse

(Otometrics, Natus Medical, Denmark) system

VN : vestibular neuritis

MD : Meniere's disease

DB : down beating

UB : up beating

VS : vestibular schwannoma

INTRODUCTION

Acute vestibular syndrome (AVS) is caused by acute onset of unilateral vestibular insult in either peripheral or central vestibular system.[1] Differentiation between central and peripheral causes of AVS is necessary, because a misdiagnosed central lesion (e.g., stroke) could be fatal or have serious sequelae.[2-5] In 2009, Kattah and colleagues reported that if the HINTS (Head-Impulse, Nystagmus, Test-of-Skew) exam showed positive findings, i.e., presence of normal horizontal head impulse test (HIT), direction-changing nystagmus in eccentric gaze, or skew deviation in AVS patients with high risk of stroke, the stroke could be differentiated with 100% sensitivity and 96% specificity.[6] Thus, HINTS exam has been clinically used as a bed-side test to distinguish between the AVS causes.

HINTS tests assess eyeball movements. HIT assesses the peripheral vestibular system by measuring the vestibule-ocular reflex (VOR) of the semicircular canals. It is based on the detection of corrective saccades occurring during (covert saccade) or after (overt saccade) head movement, and covert saccade cannot be detected without special equipment. In 1988, Halmagyi and Curthoys first attempted to quantify HIT using scleral search-coil recordings.[7] Because this method required the subject to wear an uncomfortable contact lens and was time-consuming and expensive, it was unsuitable for routine diagnosis. Since the video head impulse test (vHIT) was first introduced at the Barany Society in 2004, its quantitative measurements have become more convenient and it has been widely used to evaluate the peripheral vestibular function degradation.[8-11] Although vHIT gain and catch-up

saccades have been analyzed quantitatively,[12] there is no widely accepted report about the quantitative evaluation of gaze evoked nystagmus (GEN) or skew deviation in patients with dizziness.

Here, we performed quantitative evaluation of HINTS in patients with dizziness mainly associated with peripheral lesions using one device.

PATIENTS AND METHODS

1. Study population

HINTS was quantitatively measured in 14 patients with spontaneous nystagmus who visited the dizziness clinic of Seoul National University Bundang Hospital (SNUBH) from November 2017 to August 2018. Vestibular examination including HINTS and brain imaging were performed if necessary, and the diagnoses were made considering the clinical course. The study protocol was approved by the institutional review board (IRB) of SNUBH, Seongnam-si, Korea (IRB number : B-2001/592-109).

2. Quantitative testing of HINTS

Quantitative evaluation of HINTS was conducted using a modified device of the vHIT test (EyeSeeCam, Interacoustics, Denmark), which consists of an iPad screen with a shading cylinder and a goggle with red and blue polarizing lenses (Figure 1-A). The goggle is connected to the laptop computer with an accompanying software (OtoAccess™ version 1.4, Interacoustics, Denmark) installed. The participant wears goggles and looks at the screen through the shading cylinder to perform the GEN and skew deviation tests.

a. Calibrating the eye position

Before the GEN and skew deviation tests are conducted, calibration is performed. The screen shows two dots of red and blue side-by-side, but the participant wearing red and blue polarizing lenses in each eye recognizes it as a single dot. While the participant is watching the dots displayed on the screen, the dots start from the center, move to the right, center, left, center, up, center, down, and center, and the high-speed camera mounted on the goggles recognizes the movement of the eyeball and calibrates the eye position (Figure 1-B).

b. Head Impulse Test

vHIT was tested using both EyeSeeCam and ICS impulse system. Both systems are similar, and they use goggles that contain a high-speed camera to record the eyeball movement, and an inertial measurement unit gyroscope to measure the head velocity.[13] Horizontal VOR gain on vHIT was measured and used for analysis.

c. Gaze Evoked Nystagmus

For the GEN test, the participant wears goggles and stares at the front screen through the shading cylinder. The dots on the screen start from the center, move 6° to the right, then 12° to the right, return to the center again, move 6° to the left, and then move 12° to the left. The dots stay at each point for 10 seconds, and the objective gazing position and eye movement are recorded by the camera throughout the test (Figure 1-C).

d. Test of Skew

In the skew test, the polarizing lenses play the most important role. Because the right eye wears a blue polarizing lens and the left eye wears a red polarizing lens, the right eye recognizes only the red dot and the left eye only the blue dot on the screen. When only the red dot is displayed in the center of the dark screen, the left eye loses the object to focus on, which is the same as covering the left eye (right eye uncovered). When the red dot on the screen changes to blue, the right eye loses the object to focus on, causing the same effect as covering the right eye (left eye uncovered) (Figure 1-D). Every 2 seconds, the red and blue dots are alternated, and the eye movements are recorded throughout the process. This method can simulate the alternate cover test for viewing the skew, and has the advantage of simultaneously recording eye movements. From the motion of the eyeball recorded over time, we can quantitatively analyze the degree and speed of the eyeball displacement, and the latency after which the displacement begins to occur.

3. Variables and Measures

Complete medical histories were recorded, including age, sex, diagnosis, side of vestibulopathy, onset, duration and character of dizziness. Physical examination results and bithermal caloric test results were also reviewed. Brain imaging data including computed tomography (CT) and magnetic resonance imaging (MRI) were reviewed to identify central lesions associated with dizziness. Gain and presence of overt or covert saccade were analyzed in the vHIT results. Slow phase velocity (SPV) of nystagmus of each gaze position and the slope of SPV according to gaze position was obtained in the GEN test. The latency and degree of eyeball deviation were

obtained in the alternate cover test using the polarizing lens method. Ocular lateropulsion is a tonic bias of the eyeball toward the lesion side when visual fixation is interrupted, and it has been reported in association with the lateral medullary (Wallenberg) syndrome.[14-16] We observed subtle lateropulsion in some patients during the alternate cover test and analyzed the latency and degree of deviation.

The abnormal criterion for vHIT gain was 0.8.[8,12,17] GEN test was defined as positive when the SPV of direction changing nystagmus was ≥ 0.5°/s at each gaze direction. Skew test was defined as positive when the vertical displacement of eye position ascended or descended by ≥ 1° in the alternate cover test. Similarly, lateropulsion was defined as positive when the eye position changed by ≥ 1° in the horizontal direction.

RESULTS

Patient characteristics

The clinical characteristics, diagnosis, laboratory data of 14 patients (6 [42.9%] males; median age, 49 years [range, 38-71 years]) with spontaneous nystagmus are summarized in Tables 1 and 2. Among the 14 patients, 7 (50.0%) were diagnosed with vestibular neuritis, 5 (35.7%) with Meniere's disease, 1 (7.1%) with acute vertigo (unspecified), and 1 (7.1%) with vestibular schwannoma. The median duration of dizziness in these patients was 15 days (range, 3-557 days).

Case 1 (P12, F/71) left vestibular neuritis

A 71-year-old female was diagnosed with left vestibular neuritis. On video nystagmography (VNG) examination, spontaneous right beating nystagmus was documented. Bithermal caloric tests revealed 75% of left side canal paresis. The VOR gains of vHIT were right 1.09 and left 0.10 in the EyeSeeCam system, and right 0.83 and left 0.27 in the ICS impulse system, showing that the left gain was much lower compared to the right. GEN test showed that there was right beating nystagmus (SPV: -1.09°/s) on the 14° right gaze, but it disappeared on the 13° left gaze (SPV: -0.12°/s) following Alexander's law. The slope of horizontal SPV according to horizontal eye position was -0.03. The skew deviaion was not clear on the alternate cover test. In the record, the eye elevated about 0.04 ± 0.33° when the right eye was uncovered, and it depressed about 0.00 ± 0.18° when the left eye was uncovered (Figure 4).

Case 2 (P06, M/40) right vestibular neuritis

A 40-year-old male was diagnosed with right vestibular neuritis. VNG examination revealed spontaneous left beating nystagmus. Bithermal caloric tests revealed 37% of right side canal paresis. The VOR gains of vHIT were right 0.87 and left 1.02 in the EyeSeeCam system, and right 0.88 and left 1.01 in the ICS impulse system, showing that the right gain was slightly lower compared to the left. GEN test showed that there was left beating nystagmus (SPV: 1.37°/s) on the 12° left gaze, but it disappeared on the 13° right gaze (SPV: 0.38°/s) following Alexander's law. The slope of horizontal SPV according to horizontal eye position was -0.04. The alternate cover test showed positive result for skew deviation. In the record, the eye elevated about 1.10 ± 0.95° when the right eye was uncovered, and it depressed about 1.28 ± 1.28° when the left eye was uncovered (Figure 5).

Case 3 (P07, M/44) right vestibular schwannoma

A 44-year-old male was diagnosed with right vestibular schwannoma. MRI images revealed 3.6-cm-sized vestibular schwannoma in the right cerebropontine angle. Patient's dizziness was attributed to both central and peripheral lesions, because the tumor involved both lesions. VNG examination revealed spontaneous left beating nystagmus. Bithermal caloric tests revealed 75% of right side canal paresis. The gains of vHIT were right 0.50 and left 1.02 in the EyeSeeCam system, and right 0.48 and left 0.87 in the ICS impulse system, showing that the right side

gain was lower compared to the left. GEN test showed that there was slight right beating nystagmus (SPV: -1.07°/s) on the 18° right gaze, and slight left beating nystagmus (SPV: 0.52°/s) on the 13° left gaze. The slope of horizontal SPV according to horizontal eye position was -0.05. The alternate cover test showed no definite skew deviation or lateropulsion (Figure 6).

Quantitative measurements of HINTS results

HINTS was quantitatively measured using the modified version of the existing vHIT system. The quantitative measurements involved (1) gain in vHIT, (2) SPV slope in GEN, and (3) latency and degree of skew and lateropulsion in the alternate cover test. The mean VOR gain of patients with abnormal HIT was 0.61 ± 0.29 (EyeSeeCam) and 0.55 ± 0.21 (ICS Impulse) on the lesional side, and 1.09 ± 0.11 (EyeSeeCam) and 0.90 ± 0.09 (ICS Impulse) on the contralesional side. The mean VOR gain of patients with normal HIT was 1.09 ± 0.22 (EyeSeeCam) and 0.95 ± 0.06 (ICS Impulse) on the lesional side, and 1.16 ± 0.12 (EyeSeeCam) and 0.94 ± 0.07 (ICS Impulse) on the contralesional side. The mean SPV in the GEN test was -0.27 ± 0.68°/s at 12° right gaze position, and 0.32 ± 0.59°/s at 12° left gaze position. The mean slope of horizontal SPV according to the horizontal eye position was -0.02 ± 0.02. The mean value of vertical eyeball deviation of patients with positive skew deviation was 2.14 ± 1.18° when the lesional side eye was uncovered and -1.97 ± 1.59° when the contralesional side eye was uncovered; whereas, in patients with negative skew deviation, it was -0.07 ± 0.31° when the lesional side eye was uncovered and 0.20 ± 0.49° when the contralesional side eye was uncovered.

Summary of the objective measurements of HINTS

The quantitative HINTS evaluation results of 14 cases are summarized in Table 2. Of 14 patients with spontaneous nystagmus, 13 were associated with peripheral lesions, but 7 of them showed positive HINTS findings (normal HIT: 4, presence of direction changing GEN: 0, presence of skew: 3), and 3 showed lateropulsion. One patient had mixed peripheral and central lesion and showed positive HINTS finding (presence of direction changing GEN).

DISCUSSION

Most patients with AVS have acute peripheral vestibulopathy (APV), but some have stroke including the posterior circulation, therefore efforts have been made to distinguish them.[18] The pattern of nystagmus has been known to distinguish APV from pseudo-vestibular neuritis.[1] However, evidence of nystagmus pattern alone is not enough to distinguish between the cases.[19] Although clinicians have become increasingly reliant on brain MRI, it is not always available on time. Furthermore, it is known that MRI has 12% chances of false negativity for central lesion in the diagnosis of patients with AVS.[6] Since better and quick diagnostic tests are important to identify the central lesion, the clinical importance of HINTS has been emphasized and strengthened over the past decade.[20]

Normal findings of HIT in AVS have been known to strongly suggest central lesions.[21] Quantitative analysis of the test has been studied using various quantitative test tools.[7-11,13,17,22] Recent studies analyzed the vHIT gain and catch-up saccades quantitatively.[12] We performed vHIT with two different devices in the same patient and the results were generally consistent, indicating that the quantitative measurement tool of the HIT is fairly reproducible. As quantitative analysis of HIT has become more common and reliable, research is possible in varying test conditions including head velocities and accelerations.[23] However, there is no widely accepted report about the quantitative evaluation of GEN or skew deviation in patients with dizziness.

GEN occurs by the attempted maintenance of an eccentric eye position, and it

is caused by cerebellar and brainstem lesions, reflecting a deficiency of the neural integrator.[24] There have been a report that quantitatively measured GEN in 18 patients with acute balance problem without radiological neuropathology.[25] According to that study, the SPV of GEN ranged between 6 - 19°/s. However, that study recruited selective patients who showed GEN and mainly focused on analyzing optokinetic response, and none of them had spontaneous nystagmus in contrast to the participants in our study.

GEN elicited at extreme horizontal fields of gaze (end-point nystagmus) is usually physiologic; therefore, the examiner should be careful that the participant does not gaze in extreme directions when directing the eccentric gaze to induce GEN. Moreover, our observations showed that the SPV changed according to the gazing position. Therefore, for quantitative analysis, the stimulus should be presented under control. When measuring GEN with the equipment used here, it controlled the degree of eccentric gaze at a constant, which helped to maintain consistency of test conditions. We used 12° gaze conditions, and we need more data to determine whether this is the optimal condition for causing clear GEN. Since GEN with a low SPV, especially in elderly patients, is known to usually physiologic,[25] we need more data on the range of normal GEN. We mentioned only the slope of SPV according to the eye position in the GEN test, but the slope value itself does not mean that the GEN's direction has changed according to the gaze position. The direction change and intensity of GEN can be properly reflected by referring to the SPV values on the both right and left gaze.

Skew deviation is a vertical misalignment of the eyes caused by a supranuclear

lesion in the posterior fossa.[26-28] The vertical misalignment of eye is commonly detected by the alternate cover test, and it can be measured quantitatively with prismatic correction.[29] In this study, we were able to easily record and measure skew deviations or lateropulsion using only one device, without using additional eye occluder or prism bars with various refraction angles. There is limited information about the latency of eyeball deviation in the alternate cover test. Our data showed that there are about 0.3 - 0.4 seconds of latencies in skew deviation and lateropulsion. Currently, it is difficult to decipher the clinical meaning of this latency because there is limited data; hence, further data collection is needed in the future.

In this study, we first attempted a quantitative HINTS exam for dizziness patients with spontaneous nystagmus. Quantifying and recording the HINTS test were possible by using the modified version of the existing vHIT system. When conducting a GEN or alternate cover test without a recording device, the examiner could recognize the obvious eye movement and should make a judgment immediately. However, with the recorded eye movement data, we can detect subtle eye movements and make quantitatively reviewed decision for the results objectively.

Contrary to the previous study that insisted positive findings of HINTS exam could distinguish central causes of AVS,[6] our study on quantitative HINTS exam showed interesting results. Although HINTS was performed in patients with peripheral lesions, the positive rate of central findings was higher than expected. Our results suggest that there could be some cases of normal HIT (28.6%) and skew deviation (21.4%) or lateropulsion (21.4%) in peripheral lesions. There are several reasons why our results are different from the conclusions of the previous report.

First, the previous report was a conclusion drawn from patients with stroke risk factors; hence, this difference in the patient groups could have caused this difference. Our study provides information on how HINTS can appear in a more extended patients group. Second, objective measurement could detect more subtle eye movements, leading to this result.

Limitations

Comparing our quantitative data with HINTS exam without equipment would be important. Unfortunately, the HINTS examinations without equipment were not available for the 14 patients. Additionally, we performed HINTS exam only once in one patient, so the reproducibility of the test is still insufficient. We think that future data will be needed to see if quantitative tests are reproduced in repeated measurements.

Furthermore, the duration from the onset of dizziness to the time of HINTS exam was not equal among the patients. This indicates that some data could be indicative of the time when the symptoms reduced or disappeared, and this should be considered when interpreting the results. However, since we only selected patients with spontaneous nystagmus, our results reflected the data from patients with acute periods of symptoms.

Our study included patients with peripheral vestibulopathy and used the arbitrary criteria for each test, except vHIT gain. We need further quantitative evaluation of HINTS in patients with central lesions, where each data may be more pronounced. Moreover, we did not have data from normal participants about the

quantitative testing of HINTS. This quantitative analysis is necessary to establish the criteria for the range of normal and abnormal. Since the number of patients analyzed was small, it is necessary to conduct a planned study on a large number of patients with various causes of AVS in the future.

Despite these limitations, our study is meaningful because it was the first attempt to quantitatively measure the HINTS test. The quantitative measurement of HINTS can be conducted in a relatively short time by using simple equipment that needs minimal modification of an existing device.

CONCLUSION

The quantitative measurement of HINTS could be helpful in the clinical field encountering patients with dizziness by enabling visual reproduction of test results and diagnosis based on improved objectivity. Although positive findings of HINTS have been reported to suggest a central lesion, our findings suggested that there are some cases showing positive findings of HINTS in patients with acute vertigo associated with peripheral lesions.

REFERENCES

1. Hotson JR, Baloh RW. Acute vestibular syndrome. *The New England journal of medicine.* 1998;339(10):680-685.
2. Glass TA, Hennessey PM, Pazdera L, et al. Outcome at 30 days in the New England Medical Center Posterior Circulation Registry. *Archives of neurology.* 2002;59(3):369-376.
3. Edlow JA, Newman-Toker DE, Savitz SI. Diagnosis and initial management of cerebellar infarction. *The Lancet Neurology.* 2008;7(10):951-964.
4. Savitz SI, Caplan LR, Edlow JA. Pitfalls in the diagnosis of cerebellar infarction. *Academic emergency medicine.* 2007;14(1):63-68.
5. Kerber KA, Brown DL, Lisabeth LD, Smith MA, Morgenstern LB. Stroke among patients with dizziness, vertigo, and imbalance in the emergency department: a population-based study. *Stroke.* 2006;37(10):2484-2487.
6. Kattah JC, Talkad AV, Wang DZ, Hsieh YH, Newman-Toker DE. HINTS to diagnose stroke in the acute vestibular syndrome: three-step bedside oculomotor examination more sensitive than early MRI diffusion-weighted imaging. *Stroke.* 2009;40(11):3504-3510.
7. Halmagyi GM, Curthoys IS. A clinical sign of canal paresis. *Archives of neurology.* 1988;45(7):737-739.
8. Van Esch B, Nobel-Hoff G, Van Benthem P, Van Der Zaag-Loonen H, Bruintjes TD. Determining vestibular hypofunction: start with the video-head impulse test. *European Archives of Oto-Rhino-Laryngology.* 2016;273(11):3733-3739.
9. MacDougall HG, Weber KP, McGarvie LA, Halmagyi GM, Curthoys IS. The video head impulse test: diagnostic accuracy in peripheral vestibulopathy. *Neurology.* 2009;73(14):1134-1141.
10. Ulmer E, Chays A. [Curthoys and Halmagyi Head Impulse test: an analytical device]. *Annales d'oto-laryngologie et de chirurgie cervico faciale : bulletin de la Societe d'oto-laryngologie des hopitaux de Paris.* 2005;122(2):84-90.
11. MacDougall HG, McGarvie LA, Halmagyi GM, et al. A new saccadic indicator of peripheral vestibular function based on the video head impulse test. *Neurology.* 2016;87(4):410-418.

12. Yang C, Lee J, Kang B, Lee H, Yoo M, Park H. Quantitative analysis of gains and catch-up saccades of video-head-impulse testing by age in normal subjects. *Clinical Otolaryngology.* 2016;41(5):532-538.
13. Cleworth TW, Carpenter MG, Honegger F, Allum JHJ. Differences in head impulse test results due to analysis techniques. *Journal of vestibular research : equilibrium & orientation.* 2017;27(2-3):163-172.
14. Crevits L, vander Eecken H. Ocular lateropulsion in Wallenberg's syndrome: a prospective clinical study. *Acta neurologica Scandinavica.* 1982;65(3):219-222.
15. Koter R, Regan S, Clark C, et al. Clinical Outcome Measures for Lateropulsion Poststroke: An Updated Systematic Review. *Journal of neurologic physical therapy : JNPT.* 2017;41(3):145-155.
16. Meyer KT, Baloh RW, Krohel GB, Hepler RS. Ocular lateropulsion: a sign of lateral medullary disease. *Archives of Ophthalmology.* 1980;98(9):1614-1616.
17. Weber KP, Aw ST, Todd MJ, McGarvie LA, Curthoys IS, Halmagyi GM. Head impulse test in unilateral vestibular loss: vestibulo-ocular reflex and catch-up saccades. *Neurology.* 2008;70(6):454-463.
18. Lee H, Cho Y-W. A case of isolated nodulus infarction presenting as a vestibular neuritis. *Journal of the neurological sciences.* 2004;221(1-2):117-119.
19. Lee H, Sohn S-I, Cho Y-W, et al. Cerebellar infarction presenting isolated vertigo: frequency and vascular topographical patterns. *Neurology.* 2006;67(7):1178-1183.
20. Kattah JC. Use of HINTS in the acute vestibular syndrome. An Overview. *Stroke and vascular neurology.* 2018;3(4):190-196.
21. Newman-Toker DE, Kattah JC, Alvernia JE, Wang DZ. Normal head impulse test differentiates acute cerebellar strokes from vestibular neuritis. *Neurology.* 2008;70(24 Pt 2):2378-2385.
22. Hougaard DD, Abrahamsen ER. Functional Testing of all Six Semicircular Canals with Video Head Impulse Test Systems. *Journal of visualized experiments : JoVE.* 2019(146).
23. Kim TS, Lim HW, Yang CJ, et al. Changes of video head impulse test results

in lateral semicircular canal plane by different peak head velocities in patients with vestibular neuritis. *Acta oto-laryngologica.* 2018;138(9):785-789.

24. Buttner U, Grundei T. Gaze-evoked nystagmus and smooth pursuit deficits: their relationship studied in 52 patients. *Journal of neurology.* 1995;242(6):384-389.
25. Yetiser S, Ince D, Yetiser B. Optokinetic Analysis in Patients With Spontaneous Horizontal Gaze-Evoked Nystagmus Without Radiological Neuropathology. *Ear, nose, & throat journal.* 2019;98(7):420-424.
26. Brodsky MC, Donahue SP, Vaphiades M, Brandt T. Skew deviation revisited. *Survey of ophthalmology.* 2006;51(2):105-128.
27. Wong AM. Understanding skew deviation and a new clinical test to differentiate it from trochlear nerve palsy. *Journal of AAPOS : the official publication of the American Association for Pediatric Ophthalmology and Strabismus.* 2010;14(1):61-67.
28. Safran AB, Vibert D, Issoua D, Hausler R. Skew deviation after vestibular neuritis. *American journal of ophthalmology.* 1994;118(2):238-245.
29. Klaehn LD, Hatt SR, Leske DA, Holmes JM. Role of a Standardized Prism Under Cover Test in the Assessment of Dissociated Vertical Deviation. *Strabismus.* 2018;26(1):1-5.

Figure 1. Modified vHIT device and test methods.

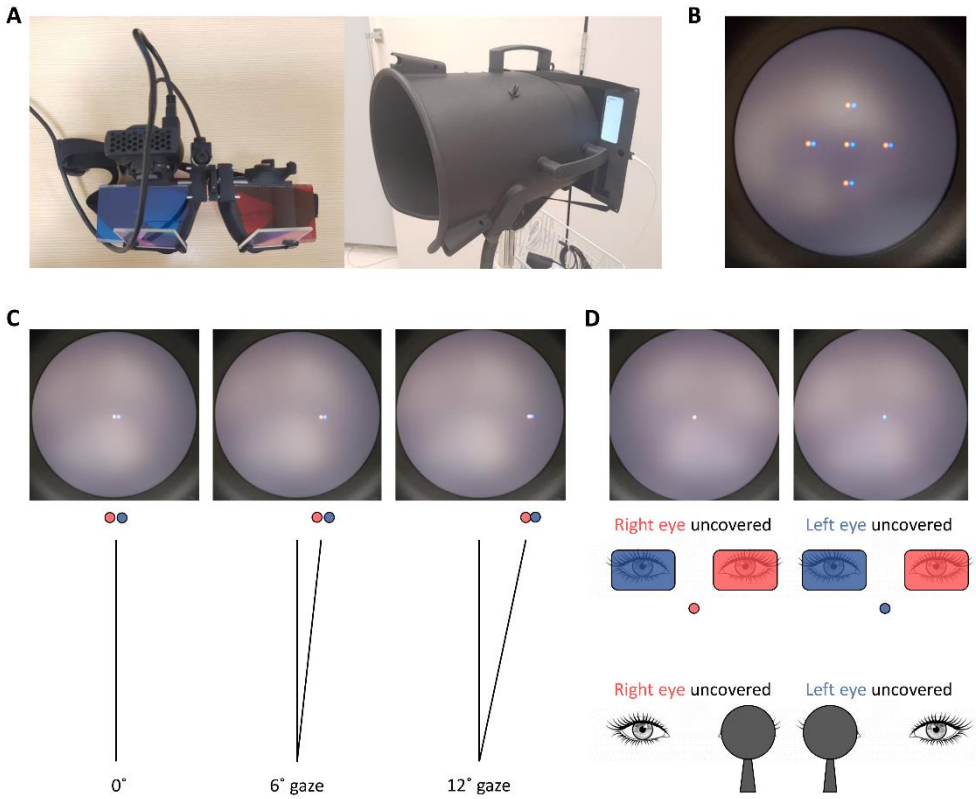

A. Polarizing goggles and iPad screen with a shading cylinder. **B.** Eye position calibration. **C.** Gazing positions in the GEN test. **D.** The polarizing goggle method to simulate the alternate cover test.

Figure 2. Example of result showing direction changing GEN

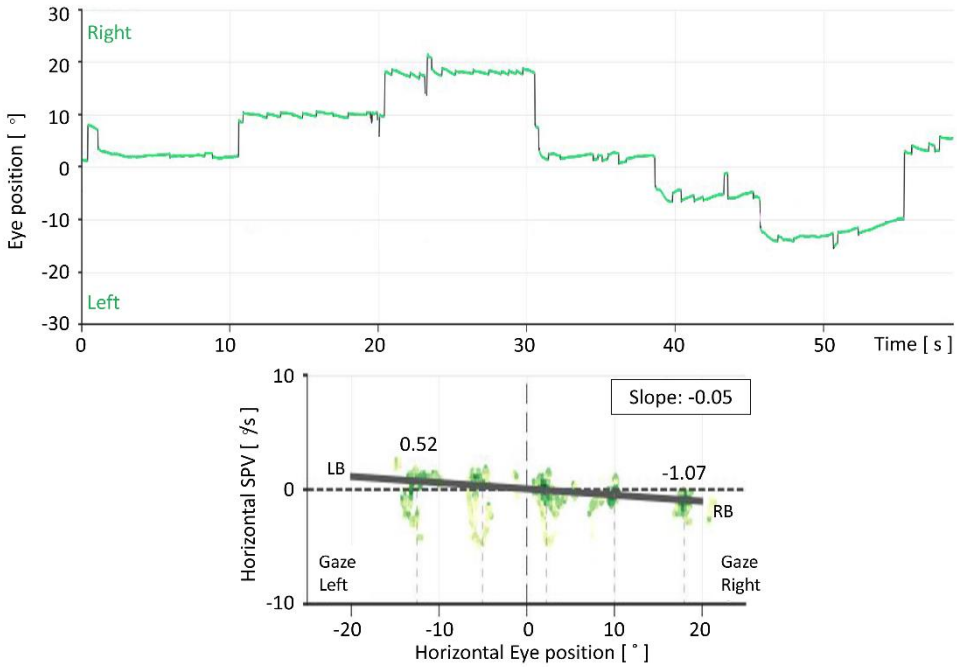

GEN test shows that there is slight right beating nystagmus (SPV: -1.07°/s) on the 18° right gaze position, and slight left beating nystagmus (SPV: 0.52°/s) on the 13° left gaze position. The slope of horizontal SPV according to horizontal eye position was -0.05.

Figure 3. Example of result showing skew deviation

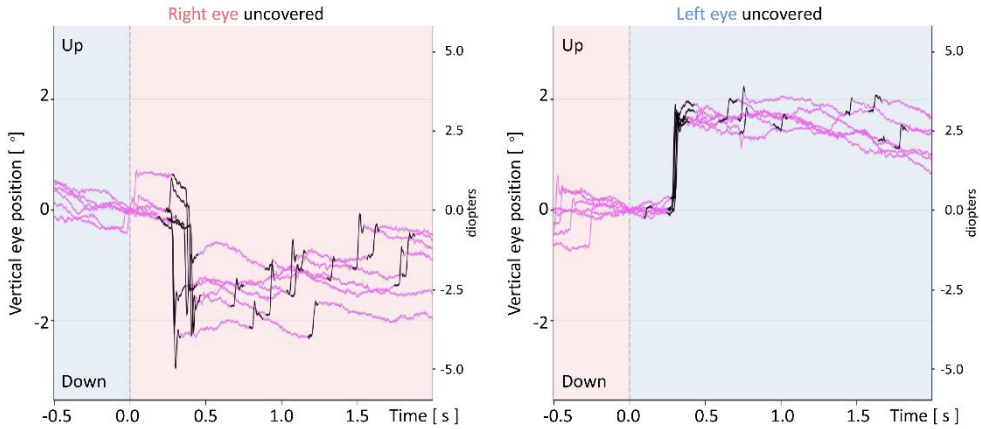

The alternate cover test shows that mean downward deviation is 0.84 ± 0.46° when the right eye was uncovered and mean upward deviation is 1.91 ± 0.38° when the left eye was uncovered.

Figure 4. Quantitative results of HINTS for patient with left vestibular neuritis

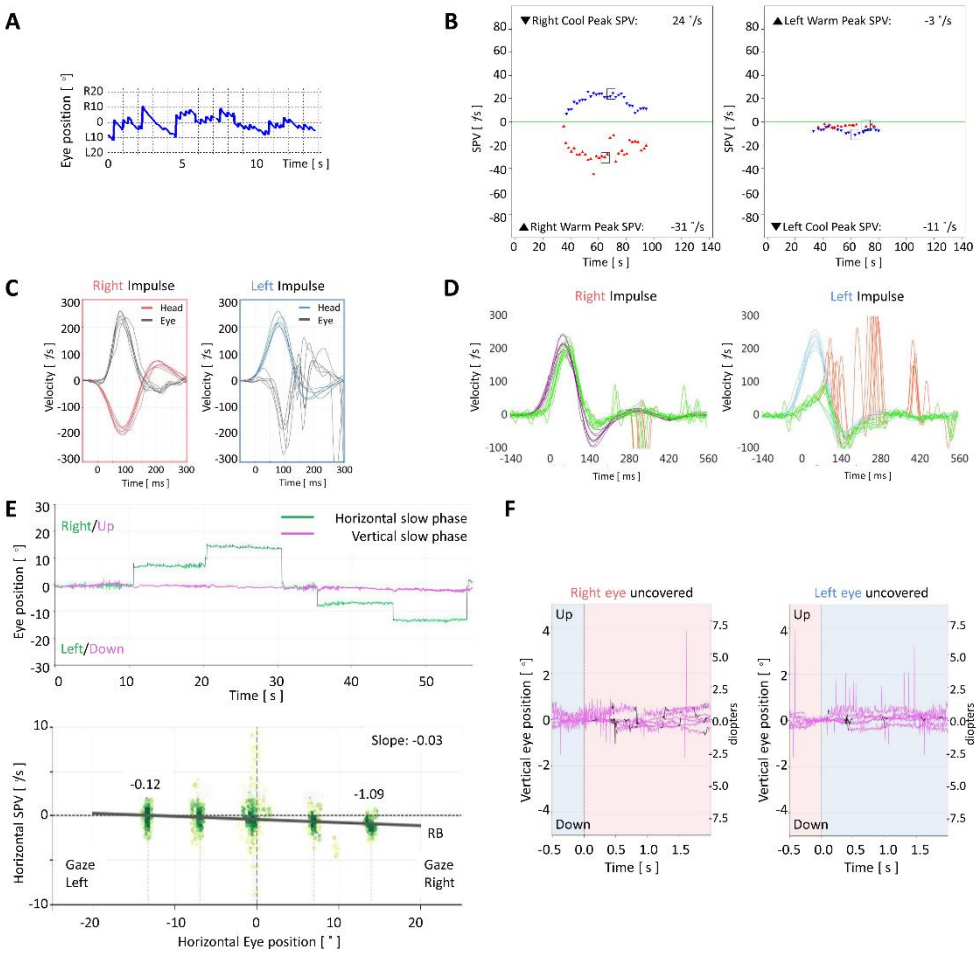

A. VNG shows spontaneous nystagmus with peak SPV: -9°/s at 2.7s. **B.** Caloric test reveals 75% canal paresis (CP) in the left ear and 33% directional preponderance (DP) to the right ear. **C.** vHIT result in the EyeSeeCam system shows VOR gains of right 1.09 and left 0.10. **D.** vHIT result in the ICS impulse system shows VOR gains of right 0.83 and left 0.27. **E.** GEN test shows right beating nystagmus (SPV: -1.09°/s) on the 14° right gaze, but it disappeared on the 13° left gaze (SPV: -0.12°/s). **F.** Skew deviation was not clear in the alternate cover test.

Figure 5. Quantitative results of HINTS for patient with right vestibular neuritis

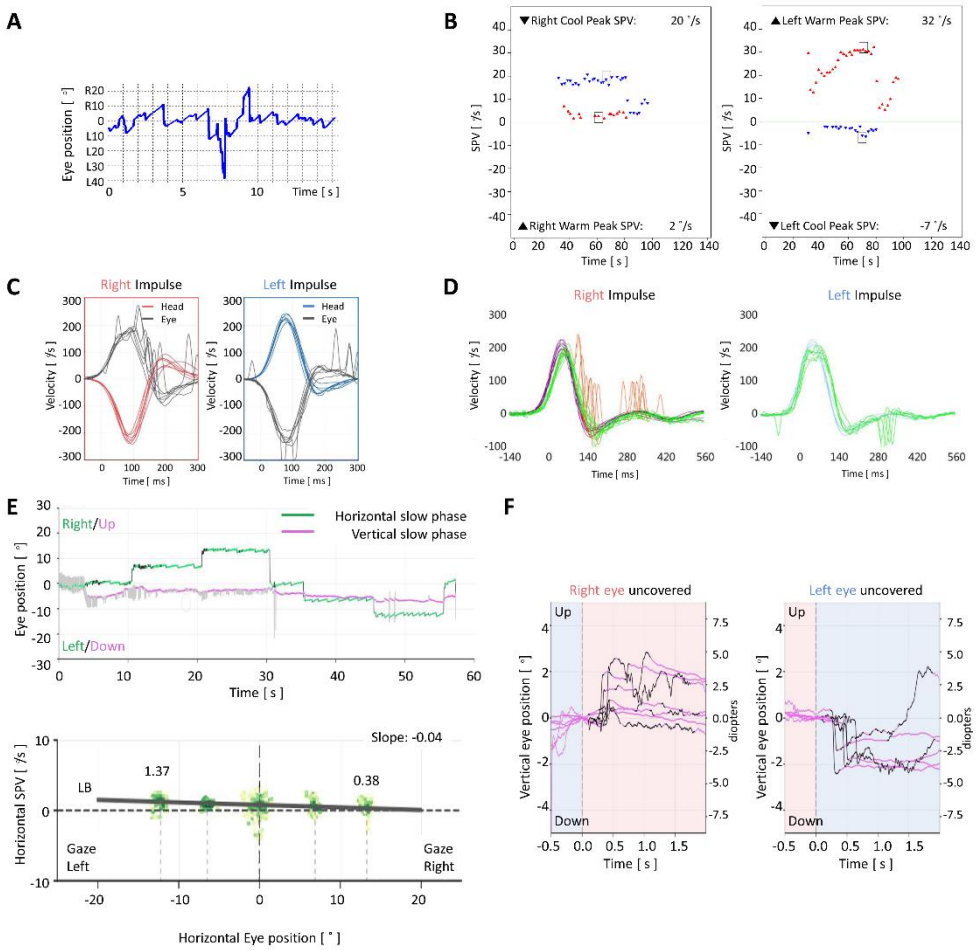

A. VNG shows spontaneous nystagmus with peak SPV: 9°/s at 6.3s. **B.** Caloric test reveals 37% CP in the right ear and 82% DP to the left ear. **C.** vHIT result in the EyeSeeCam system shows VOR gains of right 0.87 and left 1.02. **D.** vHIT result in the ICS impulse system shows VOR gains of right 0.88 and left 1.01. **E.** GEN test shows left beating nystagmus (SPV: 1.37°/s) on the 12° left gaze, but it disappeared on the 13° right gaze (SPV: 0.38 °/s). **F.** Skew deviation was observed in the alternate cover test. The eye elevated about 1.10 ± 0.95° when the right eye was uncovered, and it depressed about 1.28 ± 1.28° when the left eye was uncovered.

Figure 6. Quantitative results of HINTS for patient with right vestibular schwannoma

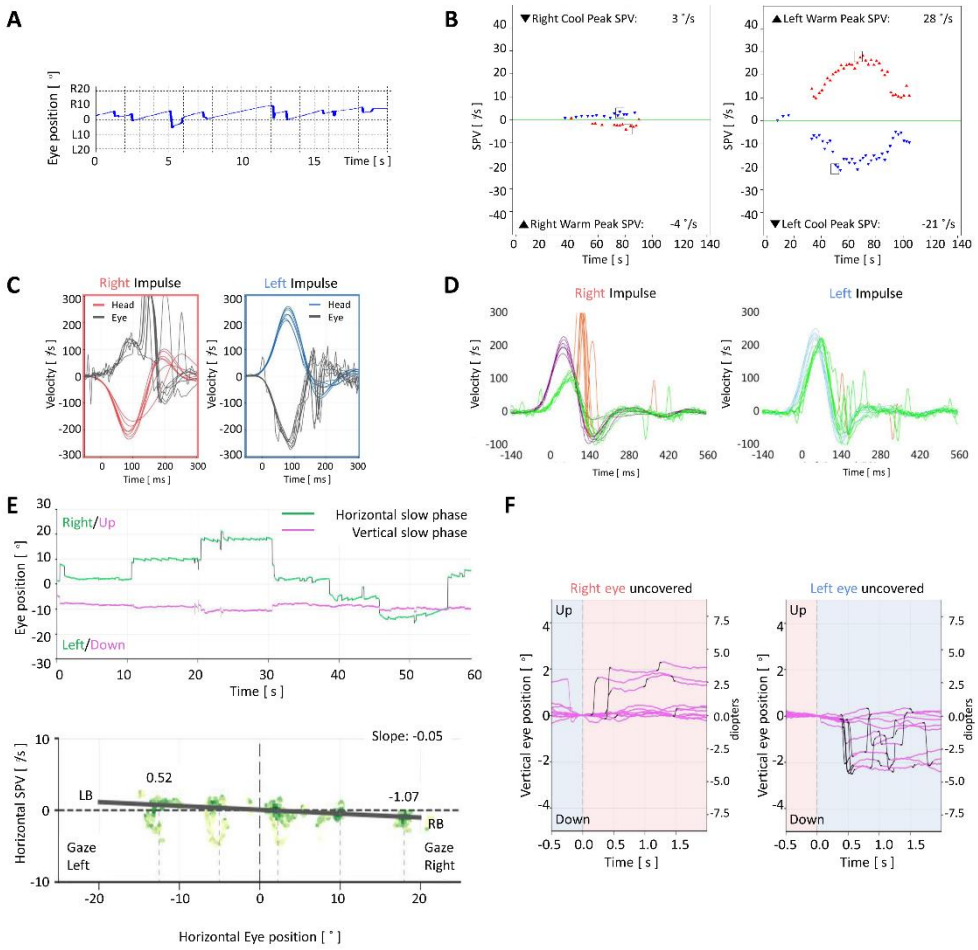

A. VNG shows spontaneous nystagmus with peak SPV: 2°/s at 17.9s. **B.** Caloric test reveals 75% CP in the right ear and 11% DP to the left ear. **C.** vHIT result in the EyeSeeCam system shows VOR gains of right 0.50 and left 1.02. **D.** vHIT result in the ICS impulse system shows VOR gains of right 0.48 and left 0.87. **E.** GEN test shows right beating nystagmus of SPV -1.07°/s on the 18° right gaze and left beating nystagmus of SPV 0.52°/s on the 13° left gaze. **F.** Skew deviation was not clear in the alternate cover test.

Table 1. HINTS results of 14 patients with spontaneous nystagmus.

P	Sex/ Age	Dur (d)	Diagnosis	SN [a] (°/s)	CP [b] (%)	EyeSeeCam VOR Gains		ICS Impulse VOR Gains		GEN (slope)	Vertical eye position [c] lesional uncover (med ± std °)	Vertical eye position [c] contralesional uncover (med ± std °)
						lesional	contralesional	lesional	contralesional			
P01	F/64	15	VN	-2	64	**0.80**	**1.19**	**0.63**	**0.94**	-0.03	-0.16 ± 0.45	0.52 ± 0.80
P02	F/42	15	MD, acute	8DB	53	N/A	N/A	0.95	0.99	-0.01	-0.24 ± 0.42	-0.63 ± 0.16
P03	M/38	10	Acute vertigo, unspecified [d]	5	12	1.31	1.30	0.98	0.92	-0.02	-0.19 ± 0.16	0.40 ± 0.49
P04	F/49	557	MD, recovery	-3	64	0.88	1.11	0.86	0.85	-0.01	-0.02 ± 0.14	-0.19 ± 0.25
P05	F/57	12	VN	3,3UB	100	**0.19**	**0.84**	**0.18**	**0.71**	-0.03	-0.45 ± 0.11	0.47 ± 0.45
P06	M/40	3	VN	9	37	**0.87**	**1.02**	**0.88**	**1.01**	-0.04	**1.10 ± 0.95**	**-1.28 ± 1.28**
P07	M/44	251	VS	2	75	**0.50**	**1.02**	**0.48**	**0.87**	**-0.05**	0.07 ± 0.83	-0.27 ± 0.86
P08	M/63	64	VN	5	40	**0.77**	**1.14**	**0.64**	**0.84**	0	**3.42 ± 0.39**	**-3.78 ± 1.30**
P10	M/45	20	MD	2	100	**0.79**	**1.17**	**0.69**	**0.98**	0	0.05 ± 1.42	0.06 ± 0.22
P11	F/49	154	MD	-1	4	1.08	1.08	1.00	1.01	-0.03	-0.42 ± 0.30	0.00 ± 0.12
P12	F/71	10	VN	9	75	**0.10**	**1.09**	**0.27**	**0.83**	-0.03	-0.00 ± 0.18	0.04 ± 0.33
P13	F/46	4	VN	9	56	**0.83**	**1.17**	**0.62**	**0.96**	-0.05	**1.91 ± 0.38**	**-0.84 ± 0.46**
P14	F/56	5	MD	1	59	**0.84**	**1.17**	**0.69**	**0.88**	-0.02	0.69 ± 0.26	1.05 ± 0.48
P15	M/61	195	VN	2	73	**0.37**	**1.13**	**0.40**	**0.94**	-0.01	-0.06 ± 0.33	0.73 ± 0.52

[a] positive value means spontaneous nystagmus to the contralesional side and negative means to the lesional side, respectively.

[b] canal paresis of lesional side.

[c] positive value means eyeball deviation to the upper direction and negative means to the lower direction, respectively.

[d] participant P03 was diagnosed with acute vertigo, unspecified, because caloric paresis and MRI finding were within normal limit and clinical course did not suggest any central cause.

** Underlined bold values indicate that the result of the test is abnormal.

HINTS: Head-Impulse, Nystagmus, Test-of-Skew, P: participant, Dur: duration, SN: spontaneous nystagmus, CP: canal paresis, EyeSeeCam VOR Gains: VOR gains of vHIT measured in the EyeSeeCam (Interacoustics, Denmark) system, ICS Impulse VOR Gains: VOR gains of vHIT measured in the ICS Impulse (Otometrics, Natus Medical, Denmark) system, VOR: vestibule-ocular reflex, GEN: gaze evoked nystagmus, VN: vestibular neuritis, MD: Meniere's disease, DB: down beating, UB: up beating, VS: vestibular schwannoma.

Table 2. Demographic and laboratory findings and positive rate of each component implicating central and peripheral signs in HINTS exam.

Age	51.8 ± 10.2	
Spontaneous Nystagmus		
Lesional side	3 / 14 (21.4%)	
Contralesional side	10 / 14 (71.4%)	
Other	1 / 14 (7.1%)	
Canal Paresis		
No	2 / 14 (14.3%)	
Lesional side		12 / 14 (85.7%)
Contralesional side	0	
	Sign of central lesion	Sign of peripheral lesion
HIT		
Nomal	4 / 14 (28.6%)	
Abnormal		10 / 14 (71.4%)
GEN		
Positive	1 / 14 (7.1%)	
Negative		13 / 14 (92.9%)
Skew deviation		
Positive	3 / 14 (21.4%)	
Negative		11 / 14 (78.6%)
Lateropulsion		
Positive	3 / 14 (21.4%)	
Negative		11 / 14 (78.6%)

HINTS: Head-Impulse, Nystagmus, Test-of-Skew, VOR: vestibule-ocular reflex, vHIT: video head impulse test, GEN: gaze evoked nystagmus

국 문 초 록

급성 말초 전정병증에서 HINTS (두부충동검사, 주시유발안진검사, 스큐편위검사)검사의 객관적 측정

서울대학교 의과대학
이비인후과학 전공 이 동 한

목적: 본 연구는 급성 말초 전정병증 환자에서 HINTS (두부충동검사, 주시유발안진검사, 스큐편위검사)의 정량적 파라미터를 개발하고 분석하였다.

방법: HINTS는 2017년 11월부터 2018년 8월까지 자발안진을 동반하며 분당 서울대학교 병원의 어지럼증 클리닉을 방문한 14명의 환자에서 분석되었다. 두부충동검사에서 수평 전정안구반사의 이득을 측정하였다. 주시유발안진을 평가하기 위해 각기 다른 지점 측방 주시시 발생하는 안진의 느린 성분 속도를 측정하고 플롯팅하여, 수평 주시위치의 변화에 따른 서상 안진 속도 변화의 기울기를 계산하였다. 편광렌즈를 사용한 교대눈가림검사 방법으로 스큐편위를 검사하였고, 안구의 수직편위 정도와 편위발생의 잠복기를 측정하였다.

결과: 13명의 말초 전정병증 환자들 중, 7명에서 HINTS 양성소견을 보였다. (두부충동검사상 정상 : 4명, 방향이 변하는 주시유발안진 : 0명,

스큐편위 : 3명) 그리고 3명에서 중추성 병변을 시사하는 측방편위 소견을 보였다. 한명의 소뇌교뇌각 종양 환자는 말초성 병변과 중추성 병변이 함께 관련되어 있었고 HINTS 양성 소견을 보였다. (방향이 변하는 주시유발 안진) 두부충동검사상 비정상을 보인 환자에서의 평균 전정안구반사 이득은 병변측과 병변반대측에서 각각 0.61 ± 0.29, 1.09 ± 0.11이었다. 반면, 두부충동검사가 정상인 환자의 평균 전정안구반사 이득은 각각 1.09 ± 0.22, 1.16 ± 0.12이었다. 눈의 주시위치에 따른 수평 서상안진속도의 평균 기울기는 −0.02 ± 0.02이었다. 스큐편위에서 양성을 보인 환자의 수직안구편위 평균값은 병변측 시야가 노출 되었을 때 2.14 ± 1.18 °, 병변반대측 시야가 노출 되었을 때 −1.97 ± 1.59 °였다. 스큐편위에서 음성을 보인 환자에서는 각각 −0.07 ± 0.31 °, 0.20 ± 0.49 °였다.

결론: HINTS는 말초 전정병증을 가진 급성 어지러움 환자에서 객관적으로 측정되었으며 54%의 환자가 HINTS 평가에서 양성 소견을 보였다.

주요어 : 어지럼증, 현훈, 두부충동검사, 안진, 스큐편위

학번 : 2018-21327