치의과학박사 학위논문

Effects of 4-Hexylresorcinol on the orthodontic tooth movement in ovariectomized rats

난소절제술을 시행한 쥐에서 4-Hexylresorcinol이 교정적 치아이동에 미치는 영향

2020년 8월

서울대학교 대학원

치의과학과 치과교정학 전공

최 광 효

-ABSTRACT-

Effects of 4-Hexylresorcinol on the orthodontic tooth movement in ovariectomized rats

Kwang-Hyo Choi, DDS, MSD

Department of Orthodontics, Graduate School, Seoul National University

*(Directed by Professor **Tae-Woo Kim**, DDS, MSD, PhD)*

Introduction: 4-Hexylresorcinol (4HR) has been shown to increase bone remodeling and may potentially facilitate tooth movement. This study investigated the effects of 4HR administration on (1) osteoblast-like cells and (2) tooth movement in ovariectomized rats.

Material and Methods: Saos-2 cells were treated with either 4HR or solvent (control). Protein expression levels were investigated 2, 8, and 24 hours after treatment. Thirty ovariectomized Sprague-Dawley rats were divided into two experimental groups (A and B) and one control group. After installation of 8 mm-NiTi coil spring between the lower incisor and

the first molar, groups A and B received subcutaneous weekly injections of 4HR (1.28 and 128 mg/kg). Micro-computerized tomography and histological analyses were performed after 2 weeks of tooth movement.

Results: The application of 4HR elevated expression of osteogenic markers in Saos-2 cells. Movement of the first molars was significantly greater in rats administered 4HR. Furthermore, the expression of bone morphogenic protein-2 (BMP-2), receptor activator of nuclear factor kappa-B ligand (RANKL), osteocalcin (OC), and tartrate-resistant acid phosphatase (TRACP) were increased after 4HR administration.

Conclusion: 4HR resulted in an increased expression of osteogenic markers in Saos-2 cells. The administration of 4HR in ovariectomized rats also resulted in accelerated orthodontic tooth movement and increases in the levels of both bone formation markers (OC and BMP-2) and bone resorption markers (TRACP and RANKL). The ability to accelerate tooth movement of 4HR showed the potential to shorten the period of orthodontic treatment without destructive bone change.

Keywords: animal model; bone morphogenic protein; 4-hexylresorcinol; nuclear factor kappa-B ligand; ovariectomy; tooth movement

Student Number: 2013-30657

Effects of 4-Hexylresorcinol on the orthodontic tooth movement in ovariectomized rats

Kwang-Hyo Choi, DDS, MSD

Department of Orthodontics, Graduate School, Seoul National University

(Directed by Professor Tae-Woo Kim, DDS, MSD, PhD)

-CONTENTS-

I. INTRODUCTION

Orthodontic treatment involves tooth movement, which requires the remodeling of the surrounding tissues. A number of studies have reported the physiological changes that occur in the alveolar bone during the application of orthodontic forces.[1-3] In order for tooth movement to occur without damaging the surrounding tissues, the alveolar bone is resorbed on the side towards which the tooth is being moved, and new bone formation occurs on the opposite side.[2,3] While tipping the balance towards bone resorption may accelerate tooth movement, this may also result in periodontal lesions.

Several trials have been conducted to investigate optimal methods to accelerate tooth movement. For example, studies have evaluated the effectiveness of increasing the amount of orthodontic force used,[3,4] as well as the use of vibration.[5] Surgical interventions such as corticotomy, micro-perforation, and piezocision have been assessed for their ability to induce accelerated bone remodeling.[6,7] Nevertheless, such procedures may damage the tooth root and cause discomfort and pain. The effects of hormones and drugs on tooth movement have also been investigated.[8,9] Parathyroid hormone has been reported to accelerate orthodontic tooth

movement by increasing osteoclastic activity.[8] However, the application of hormones may also disrupt the endocrine system and cause unexpected health problems.[10] Furthermore, the stimulation of bone resorption may result in delayed bone formation on the tension side, leading to periodontal problems.

4-Hexylresorcinol (4HR) is a kind of resorcinolic lipid and synthetics.[11] 4HR has been used in cosmetics and antiseptics without serious complications.[12] According to recent study, 4HR has been incorporated into bone graft for the inhibition of foreign body giant cell formation[13] and the nuclear factor kappa B pathway.[14] Multinucleated giant cell formation is a key feature for the development of osteoclast.[15] During osteoclastogenesis, the nuclear factor kappa B pathway is activated.[16] Accordingly, 4HR administration has been used for increasing bone formation.[17] 4HR increases angiogenesis vea a hypoxia-inducible factor (HIF)-independent pathway, but the detailed mechanism remains unclear.[18] In the recent report, 4HR increases the expression of transforming growth factor-β1 (TGF-β1).[19] TGF-β1 is also important in bone regeneration and remodeling.[20] Collectively, 4HR administration may accelerate orthodontic tooth movement without impairing bone formation.

To clarify 4HR induced bone formation in the orthodontic tooth movement, slow tooth movement is not a proper model. The ovariectomized animal model has an increased bone turnover rate; therefore, it has been widely used for the study of osteoporosis.[21,22] Bone turnover rate is closely associated with the speed of the orthodontic tooth movement.[23] The speed of bone formation is slower than that of bone resorption during the rapid orthodontic tooth movement.[24] For the evaluation of orthodontic tooth movement, accurate evaluation of root position is important. Recently, three-dimensional prediction method by computed tomography (CT) shows high accuracy of root position.[25] Accordingly, the ability of catch-up bone formation by 4HR will be demonstrated clearly in the rapid tooth movement model with CT evaluation. The ovariectomized animal model is optimal for studies investigating the effectiveness of treatments aimed at accelerating orthodontic tooth movement and accompanying complications.[24]

The objective of this study was to demonstrate the effects of 4HR administration (1) on osteoblast-like cells and (2) orthodontic tooth movement and the expression level of bone remodeling markers in an ovariectomized animal model.

II. REVIEW OF LITERATURE

1. 4-hexylresorcinol and its characteristics

1.1. 4-hexylresorcinol (4HR)

4-hexylresorcinol (4-Hexyl-1,3-benzenediol) is an alkylresorcinol with 6 methylenes in length at fourth position. 4HR contains of 18 hydrogen atoms, 12 carbon atoms and 2 oxygen atoms ($C_{12}H_{18}O_2$). It contains a total of 32 bonds. There are 14 non-H bonds, 6 multiple bonds, 5 rotatable bonds, 6 aromatic bonds, 1 six-membered rings and 2 aromatic hydroxyls. The molecular weight of 4HR is 194.27012 g/mol. The molecular structure of 4HR is given in Figure 1.

4HR have been included in the list of drugs in the World Health Organization (WHO) in 1999. 4HR is predominantly employed as the active ingredient in lotions, sprays, or lozenges indicated as a topical antiseptic to help prevent skin infection in minor cuts, scrapes, or burns, or as an antiseptic and local anesthetic for the relief of a sore throat and its associated pain. In addition, 4HR is used as an active ingredient in various commercial cosmetic skincare products as an anti-aging cream while other studies have looked into whether or not the compound could be used effectively as an anti-inflammatory agent or even as an anti-cancer therapy.

2-year toxicology and carcinogenesis studies of 4HR were conducted by US national toxicology program in 1988. 4HR was given to 50 rats and 50 mice of each sex, 5 days for week by dose of 0, 62.5 or 125 mg/kg. Under the conditions of these 2-year gavage studies, there was no evidence of carcinogenic activity of 4-hexylresorcinol for male or female rats given doses of 62.5 or 125 mg/kg.

1.2. 4HR inhibit foreign body giant cell formation

4HR inhibited diacylglycerol kinase (DAGK) in macrophage cells. DAGK is an important intracellular mediator of foreing body giant cell (FBGC) formation in macrophages. As a result of DAGK inhibition by 4HR, FBGC formation was significantly inhibited. 4HR-incorporating silk graft materials displayed significant reduction of granuloma formation and increases in the extent of new bone formation in a rabbit calvarial defect model.[13]

1.3. 4HR suppress the nuclear factor kappa B signaling pathway and increase new bone formation

Tumor necrosis factor-α (TNF-α) mediates inflammatory reactions and is mainly produced by macrophages. Increased levels of TNF-α expression influence the function of osteoblasts adjacent to the graft

material. TNF-α increases osteoclast activity but decreases osteoblast differentiation. Accordingly, suppression of TNF-α activity is important for new bone formation around the bone graft. TNF-α-induced osteoblast suppression is mediated by the nuclear factor kappa B (NF-κB) signaling pathway.[26] For these reasons, inhibiting the NF-κB signaling pathway is beneficial for bone regeneration. The application of 4HR suppressed the NF-κB signaling pathway in osteoblasts and 4HR-containing porcine bone particles promoted new bone formation in a rat calvarial defect model.[14]

Dental implant coated with 4HR showed better bone formation when contaminated. Because of the anti-septic activity and inhibition of NF-κB pathway. Both the bone formation value and the bone-to-implant contact value were significantly higher.[17]

2. Saos-2 cell for bone metabolism research

Saos-2 (Sarcoma osteogenic) is a cell line derived from the primary osteosarcoma of an 11-year-old Caucasian girl in 1973 by J Fogh and G Trempe.[27] The cell line is commonly used in bone metabolism research as a model for testing novel therapies. In 1987, Rodan et al. determined that

Saos-2 cells possess several osteoblastic features and could be useful as a permanent line of human osteoblast-like cells and as a source of bone-related molecules.[28]

Advantages for using Saos-2 cell line are that they have well-documented characterization data, the possibility to obtain large amounts of cells in short time, and the ability to deposit a mineralization-competent extracellular matrix which makes these cells a valuable model for studying events associated with the late osteoblastic differentiation stage in human cells.[29,30]

3. Ovariectomy increases bone turnover and lead to acceleration of the tooth movement

Ovariectomy results in an estrogen deficiency, which is associated with increased osteoclast cell differentiation and bone turnover.[21,22] Estrogen deficiency alters the production of osteoinductive proteins such as osteogenin and bone morphogenetic protein, which results in the disruption of bone matrix formation.[31] Since tooth movement is in bone metabolism, metabolic and hormonal changes owing to the ovariectomy affect tooth movement as well. Orthodontic tooth movement is significantly increased by ovariectomy.[24,25]

In addition, Wronski et al.[32] found that ovariectomy induced osteopenia and increased the indices of bone resorption and formation in the rat tibia at day 14 after ovariectomy, and the maximal increase in the bone resorption parameters in the femur occurred up to a few months postovariectomy.

4. Medication effects on the tooth movement

4.1 Parathyroid hormone (PTH)

PTH is secreted by the parathyroid glands and its main effect is an increase in the concentration of calcium in the blood; consequently, it stimulates bone resorption.

The effect of exogenous PTH on bone remodeling depends on the dose administered and the route of administration. Continuous administration of PTH mainly produces a catabolic effect, whereas the effects of intermittent administration are mainly anabolic.[33,34] Rapid bone formation on the tension side and resorption on the compression side of periodontal bone tissues inevitably lead to accelerated orthodontic tooth movement.

Some experimental research has demonstrated that PTH enhances orthodontic tooth movement,[8,35–38] Soma et al[35,36] reported that continuous administration of 10 mg PTH accelerated orthodontic tooth movement in rats, whereas intermittent administration of PTH did not. Li et al[37] reported that daily subcutaneous injection of 4 mg/100 g PTH accelerated orthodontic movement of the maxillary first molars in rats. Salazar et al[38] reported that subcutaneous administration of 30 mg/kg/d PTH was associated with a greater increase in the velocity of postsurgical orthodontic tooth movement by day 7 in ovariectomized rats than in nonovariectomized rats. Yao et al[8] reported that administration of PTH after orthognathic surgery accelerated remodeling of periodontal bone and promoted orthodontic tooth movement of the mandibular first molar after surgery in rabbits.

4.2 Estrogen

Estrogens are female sex hormones. For a long time, estrogen supplementation was used to overcome postmenopausal problems. However, it has become clear that this treatment increases the risk of breast cancer, strokes, and possibly other cardiac issues. This has led to the development of specific estrogen receptor modulators such as raloxifene, which has an estrogenic effect in bone, but reduces the risk for breast cancer.

Haruyama et al[39] reported that the rate of orthodontic tooth movement was inversely related to the estrogen serum level. Yamashiro et al[40] studied the effect of ovariectomy on buccal movement of rat molars. A significant increase in the rate of orthodontic tooth movement was established. Both studies suggest that estrogen supplementation might slow orthodontic tooth movement.

4.3 Simvastatin

Statins, such as simvastatin, lovastatin, and pravastatin, were primarily developed to inhibit cholesterol biosynthesis and reduce its plasma levels. Han et al[41] revealed that the systemic administration of simvastatin could minimize relapse through inhibiting the bone-resorbing activity of osteoclasts as well as stimulating bone formation. Mirhashemi et al[42] showed that the reduced tooth movement following treatment with statins in rats supported the osteogenic potential of this drug group along with its preventive effect on bone resorption. Alswarfeeri et al[43] reported that local administration of simvastatin diminished bone resorption processes associated with orthodontic tooth movement reducing the number of osteoclasts and the subsequent area of active bone resorption in rabbits.

III. MATERIAL AND METHODS

Part 1. Cellular experiments using Saos-2 cells

1. Saos-2 cell for bone metabolism research

Saos-2 (Sarcoma osteogenic) is a cell line derived from the primary osteosarcoma. Saos-2 cells possess several osteoblastic features and could be useful as a permanent line of human osteoblast-like cells and as a source of bone-related molecules. Advantages for using Saos-2 cell line are that they have well-documented characterization data, the ability to deposit a mineralization-competent extracellular matrix which makes these cells a valuable model for studying events associated with the late osteoblastic differentiation stage in human cells.

2. 4HR treatment on the Saos-2 cells and Western blot

Saos-2 cells (Korean Cell Line Bank No. 30085, Seoul, Korea) were suspended in RPMI 1640 supplemented with 10% fetal bovine serum (Euroclone, Milano, Italy), 50 U/mL of penicillin G, 50 μg/mL of streptomycin sulfate, 2 g/L sodium carbonate, and 0.11 g/L sodium

pyruvate. 4HR was purchased from Sigma-Aldrich (St. Louis, MO, USA).

Saos-2 cells were treated with 1, 10, and 100 μM of 4HR to analyze the protein expression level of TGF-β1, bone morphogenic protein-2 (BMP-2), BMP-4, alkaline phosphatase (AP), osteocalcin (OC), osteopontin (OP), type I collagen, and runt-related transcription factor 2 (RUNX2). The control consisted of Saos-2 cells treated by solvent only.

Proteins were collected 2, 8, and 24 hours after treatment. Collected proteins were mixed with a sodium dodecyl sulfate buffer and denatured by heating. Denatured proteins will be electrophoresed on 10% polyacrylamide gels. The gels were transferred to polyvinylidene difluoride membranes. After blocking, the membranes were probed with primary antibodies (dilution ratio = 1:500). Blots were imaged and quantified using a ChemiDoc XRS system (Bio-Rad Laboratories, Hercules, CA, USA).

3. Immunoprecipitation high-performance liquid chromatography (IP-HPLC) analyses of 4HR treated Saos-2 cells over time

The basic principle of IP-HPLC is similar to the enzyme-linked immunosorbent assay (ELISA). However, IP-HPLC uses protein A/G agarose beads in buffer solution and UV spectroscopy to determine protein

concentrations. In this study, 100 μg of protein from a Saos-2 cell culture were subjected to immunoprecipitation. Protein A/G agarose columns (Amicogen, Jinju, Korea) were separately pre-incubated with 1 μg of 96 different antisera.

Protein samples were mixed with 5 mL of binding buffer (150 mM NaCl, 10 mM Tris pH 7.4, 1 mM EDTA, 1 mM EGTA, 0.2 mM sodium vanadate, 0.2 mM PMSF, and 0.5% NP-40) and incubated in protein A/G agarose (Amicogen, Korea) columns on a rotating stirrer for 1 hour at 4° C. After washing columns with PBS (phosphate-buffered saline solution), target proteins were eluted using 150 μL of IgG elution buffer (Pierce, USA). Immunoprecipitated proteins were analyzed using an HPLC unit (1100 series, Agilent, USA) equipped with a reverse phase column and a micro-analytical detector system (SG Highteco, Korea). Elution was performed using 0.15 M NaCl/20 % acetonitrile solution at 0.4 mL/min for 30 min, and proteins were detected using an ultraviolet spectrometer at 280 nm. Control and experimental samples were run sequentially to allow comparisons. For IP-HPLC, whole protein peak areas (mAU*s) were calculated after subtracting negative control antibody peak areas, and square roots of protein peak areas were calculated to normalize concentrations. Protein percentages in total proteins in experimental and control groups were plotted. Results were analyzed using the chi-squared test.

The housekeeping proteins β-actin, α-tubulin, and glyceraldehyde 3-phosphate dehydrogenase (GAPDH) were used as internal controls. Expressional changes of housekeeping proteins were adjusted to <±5% using a proportional basal line algorithm. Protein expressional changes of ≤ ±5%, ±5-10%, ±10-20%, and ≥±20% change were defined as minimal, slight, meaningful, or marked, respectively.

Part 2. Animal experiments using ovariectomized rats

1. Preparation of ovariectomized rats

Six-weeks-old Crl:CD (Sprague-Dawley) specific pathogen-free (SPF)/ viral antibody free (VAF) outbred female rats (Orientbio Inc., Sungnam, Korea) were used in this study. Thirty rats (2-3 rats per cage) were housed and fed. All rats were acclimatized for 1 week prior to experimentation. Each rat was ovariectomized on both sides and rested for 2 weeks after the operation. Blood samples were obtained to monitor changes in estrogen levels. All procedures were performed in accordance with guidelines for laboratory animal care and were approved by Gangneung-Wonju National University for animal research (GWNU-2019-17).

2. Experimental groups and orthodontic appliance installation

Thirty rats were divided into 3 groups with 10 rats each. There were 2 experimental groups (low and high dosage group). The rats in the low dosage group received 1.28 mg/kg 4HR via subcutaneous injection in the abdominal region on day 0, 7, and 14 (Group A). The rats in the high dosage group received 128 mg/kg 4HR via subcutaneous injection on day 0, 7, and 14 (Group B). The rats in the control group received a solvent only (Control).

All rats received an orthodontic appliance consisting of an 8-mm nickel-titanium closed coil spring (Jinsung, Seoul, Korea) stretched between the right mandibular first molars and right mandibular incisors (Figure 2). The ring (connected to the spring) was inserted onto the incisor and fixed with light-cured resin. The other side of the spring was ligated to the first molar, with holes drilled lateral to the distal side of the molar at the gingival level, using a round bur. The spring was adjusted to provide a force of 120g, as measured with the use of force gauge (Tokyo-Seiki, Japan). The appliance was left in place without reactivation for 2 weeks to induce movement of the mandibular first molar.

The distance between the mesial surface of the first molar and the distal surface of the incisor was measured on day 0, 7, and 14 using wire under inhalation anesthesia. The distance between points marked on wire was measured with Vernier caliper. The amount of tooth movement was defined as the change in distance at each observation compared to day 0. Additionally, the final gap between the first and the second molars was also measured using a radiogram and software (SigmaScan Pro 5, SPSS Inc., Chicago, IL, USA).

3. Blood sample analysis

Two hours after the final injection on day 14, blood was sampled, and all rats were sacrificed. For the comparative purposes, sham operative animals (n=5) were included in the blood sample analysis and served as negative control. Blood osteocalcin (CAT#: E-EL-R1456), CTX (CAT#: E-EL-R0243), and tartrate-resistant acid phosphatase 5b (TRACP-5b) (CAT#: E-EL-R0628) measuring kits were purchased from Elabscience (Houston, TX, USA). For the ELISA or chemiluminescent immunoassay (CLIA) analysis, whole blood samples were centrifuged, and the plasma collected. The plasma was mixed with protein lysis buffer at a 1:1 volume ratio. These mixtures were used for ELISA analysis. The subsequent

procedure were conducted in accordance with the manufacturer' s protocol. A biopsy was obtained from the mandible, and micro-computerized tomography (mCT) and histological analyses were performed.

4. Micro-computerized tomography and histological analysis

The hemi-mandibles were sent to Genoss (Seoul, Korea) for the analysis of mCT. The prepared samples were loaded on SkyScan1173 (Bruker, Kontich, Belgium). The source voltage was 130 kV and image pixel size was 13.85 μm. In the cross-cut image, the root-to-bone ratio was measured at the distal surface of the distal root of the first molar. Three-dimensional reconstruction was done with the software provided by manufacturer.

Following mCT, the samples underwent decalcification with decalcifying solution-lite (Sigma Aldrich, St. Louis, MO, USA). After decalcification, the samples were embedded in paraffin and sectioned at a thickness of 10 μm. The specimens were stained with hematoxylin and eosin (HE). The antibodies for immunostaining were the same to western blot and IP-HPLC. After deparaffinization, trypsin treatment was performed for antigen retrieval, and an endogenous peroxidase block was carried out. After washing, a protein block was applied for 1 hour.

Antibodies for BMP-2 or receptor activator of nuclear factor kappa-B ligand (RANKL) were incubated in the humidified chambers at 4 °C for overnight. After washing, Envision (Dako, Glostrup, Denmark) was applied, and diaminobenzidine was used for colorization. Photos of the slides were taken without counterstaining.

5. Western blot for tissue samples

The opposite mandibles, that were not used for tooth movement, were placed into micro-test tubes, and stored in the deep freezer (n = 10 for each group). The tissues were vigorously homogenized in a tissue protein extraction reagent buffer with a protease inhibitor cocktail, and Western blot analysis was performed as described above. The expression level of each protein was measured using image analysis program. The expression level of β-actin was set as 1. The relative expression level of β-actin was calculated and compared.

Part 3. Statistical analysis

Proportional data (%) of the experimental and control groups were plotted into line graphs and star plots, and analyses were repeated 2 to 6 times until the standard deviations were < ±5%. Line graphs revealed the

similarities in expression patterns between the relevant proteins, and star plots revealed the differences in expression levels of the whole objective proteins. Results were analyzed using the chi−squared test. The expression of control housekeeping proteins (i.e., β−actin, α−tubulin, and GAPDH) were nonresponsive (≤5%) to 12, 24, and 48 hours of 4HR treatment.

The relative protein expression level in the western blot among groups was compared with ANOVA. Using the post hoc test, the difference between groups was analyzed. The significance level was set as 0.05.

IV. RESULTS

Part 1. Cellular experiments

1.1. Western blot: 4HR application increases osteogenic markers in Saos-2 cells

The application of 4HR to Saos-2 cells elevated the expression of osteogenic markers (Figure 3). The expression level of TGF-β1, bone morphogenic protein-2 (BMP-2), BMP-4, alkaline phosphatase (AP), osteocalcin (OC), osteopontin (OP), type I collagen, and runt-related transcription factor 2 (Runx2) were increased after 4HR administration. The increase in expression levels was dose (1–100 μM) and time-dependent (2–24h). OC and OP were particularly highly increased by 4HR administration.

1.2. IP-HPLC: Effects of 4HR on the expression of osteogenesis-related proteins in Saos-2 cells

4HR-treated Saos-2 cells showed slight increases in the expression of Ki-67 (19.8% at 24 hours) and proliferating cell nuclear antigen (7% at 8 hours) after 24 hours, compared to the non-treated control. This

indicated that the cellular proliferation of Saos-2 cells was relatively well-preserved during the 24 hours of 4HR treatment (Figure 4).

4HR-treated Saos-2 cells showed sequential dominant expression of osteogenesis-related proteins at 8, 16, and 24 hours. Proteins that were overexpressed at 8 hours included BMP-2 (19.2%), bone morphogenetic protein receptor-II (BMPR-II, 11.5%), TGF-β1 (28.8%), fibroblast growth factor-2 (FGF-2, 16.8%), and connective tissue growth factor (CTGF, 12.8%), which are relevant to the induction of bone formation. Proteins that were overexpressed at 16 hours included RANKL (26.1%), RUNX2 (23.1%), osterix (22.8%), aggrecan (17.7%), and calmodulin (CaM, 19.4%), which are relevant to osteoblast differentiation. Proteins overexpressed at 24 hours were BMP-3 (9%), osteoprotegerin (OPG, 11.1%), osteocalcin (9.1%), and osteopontin (24.6%), which are relevant to osteoid matrix deposition (Figure 4).

Furthermore, 4HR-treated Saos-2 cells showed marked downregulation of bone maturation-related proteins, including FGF-7 (20.6%), estrogen receptorβ(ERβ, 29.4%), BMP-4 (3%), osteonectin (28.2%), AP (20.6%), FGF-1 (24.9%), and transglutaminase-2 (TGase-2, 12.8%) at 8 and 16 hours. At 24 hours, there was an upregulation of

FGF−7 (5.4%), and slight downregulation of ERβ (3.4%), BMP−4 (7.9%), and AP (13.4%). A continuous marked downregulation of osteonectin (30.3%), FGF−1 (28.8%), and TGase−2 (18.2%) were also observed at 24 hours. These data suggested that 4HR−treated Saos−2 cells showed rare bone maturation after 24 hours of culture (Figure 4).

An examination of changes in global protein expression in osteogenesis−related proteins (n = 23) showed a sequential pattern of dominance during 24 hours of 4HR treatment versus the non−treated control (Figure 5). The proteins relevant to the induction of bone formation (BMP−2, BMPR−II, TGF−β1, FGF−2, and CTGF) were upregulated at 8 hours, and the proteins relevant to osteoblast differentiation (RANKL, RUNX2, osterix, aggrecan, and CaM) were upregulated at 16 hours. While the proteins relevant to osteoid matrix deposition (BMP−3, OPG, osteocalcin, and osteopontin) were upregulated at 24 hours, the proteins relevant to bone maturation (ERβ, BMP−4, osteonectin, ALP, FGF−1, and TGase−2) were still downregulated at 24 hours. These data suggested that 4HR efficiently induced bone formation in Saos−2 cells by sequential overexpression specific to the stages of osteogenesis.

Part 2. Animal experiments

2.1. Tooth movement assessment: Application of 4HR accelerates tooth movement

Control group received solvent only. Group A received low dosage of 4HR (1.28 mg/kg) and Group B high dosage of 4HR (128mg/kg). The distance of tooth movement at day 7 was 0.24 ± 0.84 mm, 0.92 ± 1.00 mm, and 0.89 ± 0.61 mm in the control, Group A, and Group B, respectively (Table 1). The differences between the groups were not statistically significant. At day 14, the distance of tooth movement was 1.98 ± 1.12 mm, 2.63 ± 0.68 mm, and 2.90 ± 0.42 mm in the control, Group A, and Group B, respectively. There was a significant difference among the groups (P =0.043), with the post hoc test showing the difference between the control group and Group B to be statistically significant (P =0.046).

These results were in accord to those in the radiogram (Figure 6). The gap between the first and the second molar measured in radiogram at day 14 was 0.22 ± 0.19 mm, 0.44 ± 0.23 mm, and 0.51 ± 0.21 mm in the control, Group A, and Group B, respectively. There was a significant difference among the groups (P =0.011). In post hoc test, the difference between the control group and Group B to be statistically significant (P =0.012) (Figure 6).

2.2. Alveolar bone height assessment on the tension side using mCT

The root-to-bone ratio (ratio of the distal root of the first molar to the interdental bone) was 0.65 ± 0.17, 0.64 ± 0.10, and 0.63 ± 0.15 in the control, Group A, and Group B, respectively (Figure 7). The differences between the groups were not statistically significant ($P > 0.05$).

2.3. Histologic analysis

In the hematoxylin and eosin stain (HE), the width of the periodontal ligament was narrower on the compression side than on the tension side (Figure 8). The expression of BMP-2 and RANKL were higher in Groups A and B compared to the control group. The expression of BMP-2 was higher on the tension side than on the compression side in Group A, while the expression of RANKL was higher on the compression side than on the tension side in Group A. A similar trend was observed in Group B. However, the expression level of RANKL was much higher than in Group A.

2.4. Western blot for tissue samples

In the Western blot analysis, the expression level of BMP-2 and RANKL were in accord to those of immunohistochemistry (Figure 9). In addition, the expression level of TGF-β1 and OC were also significantly

increased by 4HR administration compared to the control group (P <0.001). The relative expression level to β−actin for each protein is shown in the graph (Figure 9).

2.5. Plasma Level of Bone Turnover Markers

Rats in the negative control (NC) group did not receive an ovariectomy. Ovariectomy was associated with significant changes in bone turnover markers (Figure 10). The OC level was significantly different between groups (P <0.001). When compared to the NC group, the control group (P =0.004), Group A (P <0.001), and Group B (P =0.001) showed significantly higher levels of OC. Group A had a significantly higher level of OC than the control group (P =0.029).

Significant differences were observed between groups in terms of bone resorption markers, including c−terminal cross linking telopeptide (CTX; P =0.010) and TRACP−5p (P =0.002). The post hoc test showed the CTX level of Group B to be significantly lower than that of the control group (P =0.007). The TRACP−5p level was significantly higher in both Group A (P =0.003) and Group B (P =0.009), compared to the NC group.

V. DISCUSSION

In this study, 4HR application increased osteogenic markers such as TGF-β1, BMP-2, BMP-4, AP, OC, OP, type I collagen, and RUNX2 in Saos-2 cells. These findings were confirmed in both Western blot and immunoprecipitation high-performance liquid chromatography (IP-HPLC) analyses (Figure 3, 4 and 5).

The administration of 4HR to ovariectomized rats resulted in significantly greater degrees of tooth movement than in the untreated control (Table 1, Figure 6, $P < 0.05$). In spite of a greater amount of tooth movement, the bone level on the tension side was similar to that in the untreated control (Figure 7). In the histologic analysis, the administration of 4HR increased BMP-2 expression on the tension side of tooth movement and RANKL on the compression side (Figure 8). The administration of 4HR increased the blood levels of both OC and TRACP (Figure 9). 4HR administration was found to be beneficial for orthodontic tooth movement by accelerating both bone formation and resorption.

1. 4HR showed the ability to induce osteogenesis in Saos-2 cells, which appeared in a special order. Immediate bone formation can maintain the balance with bone resorption and support healthy tooth movement.

The osteogenesis-related proteins were expressed in a stage-specific manner in 4HR-treated Saos-2 cells, in accordance with the sequence of bone formation induction, osteoblast differentiation, osteoid matrix deposition, and bone maturation (Figure 4 and 5). At 8 hours after 4HR administration, overexpression of BMP-2, BMPR-II, TGF-β1, FGF-2, and CTGF was induced, which synergistically contributed to bone formation. Thereafter, the expression levels of these proteins decreased to the level of the non-treated control at 16 and 24 hours (Figure 5). At 16 hours, 4HR induced overexpression of RANKL (osteoclast differentiation factor),[44] RUNX2 (a key transcription factor associated with osteoblast differentiation),[45] osterix (a transcription factor for osteoblast differentiation),[46] aggrecan (a cartilage-specific proteoglycan core protein),[47] and calmodulin-dependent kinase II (a key regulator of osteoblast differentiation),[48] which co-operatively stimulated osteoblast differentiation. At 24 hours, 4HR induced overexpression of BMP-3 (a negative regulator for bone density),[49] OPG (a regulator for bone density),[50] osteocalcin (a calcium-binding protein),[51] and osteopontin (bone sialoprotein I),[52] which simultaneously regulated osteoid matrix deposition. These results corresponded with those of the Western blot (Figure 3).

For the orthodontic tooth movement, alveolar bone resorption and formation around the teeth must occur together. The speed of bone

formation is slower than that of bone resorption during the rapid orthodontic tooth movement.[24] While tipping the balance towards bone resorption may accelerate tooth movement, this may also result in periodontal lesions. Immediate activity of osteogenetic factors caused by 4HR can prevent the loss of overall periodontal support tissue by making it easy to generate alveolar bone with tooth movement.

2. Accelerated bone turnover and increased tooth movement through ovariectomy can clearly show the effect of 4HR in a short period of time.

Ovariectomy results in an estrogen deficiency, which is associated with increased osteoclast cell differentiation and bone turnover.[21,22] The activation of osteoclasts is a basic requirement for accelerated orthodontic tooth movement.[8,9] Orthodontic tooth movement is significantly increased by ovariectomy.[24,25] In this study, blood OC level and TRACP level was higher in all groups receiving an ovariectomy, compared to the NC group (Figure 9). It means that both bone resorption and bone formation was accelerated after ovariectomy.

All groups exhibited tooth movement after the application of the orthodontic appliance. Increased TRACP level in all groups receiving an ovariectomy, compared to the NC group. If the rate of bone formation is not equivalent to that of bone resorption, complications such as periodontal

lesions or root resorption may occur.[53,54] Thus, both bone resorption and bone formation are important for complication-free orthodontic tooth movement.[44]

In this study, the blood CTX level was not significantly increased by ovariectomy, and only the control group showed a higher average CTX value than the NC group (Figure 10). The blood CTX level is an indirect indicator of osteoclast activity.[55] It is increased when the balance between bone formation and resorption is tipped towards the latter.[55] As 4HR administration increased bone formation markers such as OC and BMP-2 (Figure 3, 9 and 10), the balance may have been tipped toward bone formation. The dosage-dependent change of serum markers was not prominent like tissue samples after 4HR administration (Figure 9 and 10). Serum reflects systemic changes and does not confine to bone activity. Consequently, the ratio between root length and bone height was similar to the control group, in spite of accelerated tooth movement (Figure 7).

3. The administration of 4HR increased BMP-2 expression on the tension side of tooth movement and RANKL on the compression side

In the histological analysis, increased expression of BMP-2 and RANKL were evident in Groups A and B (Figure 8). Notably, the expression of BMP-2 was more attenuated on the tension side compared

to the compression side (Figure 8). BMP−2 is associated with bone regeneration and is a member of the TGF−β family.[56] In cellular experiments, 4HR has been demonstrated to increase the TGF−β1 expression level.[19] As bone deposition is required on the tension side during orthodontic tooth movement, an increased expression of BMP−2 at this site may be attributed to its role in active bone formation. RANKL is a marker for osteoclasts.[44] The expression of RANKL was mainly observed on the compression side, as opposed to the tension side (Figure 8), indicating its role in active bone resorption. These findings corresponded to the results of the Western blot for tissue samples and blood sample analysis (Figure 9 and 10).

4. Limitations in this study and things to study more

Some limitations are acknowledged in this study. First, the rats were too young to show estrogen deficiency after ovariectomy. Compensatory estrogen secretion from the adrenal glands seemed to be much higher in all groups receiving an ovariectomy, compared to the NC group (Figure 11).[57] In spite of this limitation, both bone formation and resorption markers were elevated following the ovariectomy (Figure 10). In addition, serum OC levels were also higher in the ovariectomized rats compared to the NC group[58] (Figure 10). Thus, the original objective of the surgical procedure (to increase bone turnover rate) was achieved.

Second, the mechanism of osteoclast activation by 4HR administration was unclear. Increased levels of TRACP and RANKL, as well as rapid tooth movement, demonstrate the activation of osteoclasts, regardless of the surgical effects. As TGF-β1 is a master cytokine for bone metabolism, an increased expression of TGF-β1 may contribute to osteoclast activation. Furthermore, TRACP activity in pre-osteoclastic RAW264.7 cells is increased in the presence of TGF-β1,[59] and the expression of TGF-β1 is increased in RAW264.7 cells after 4HR administration.[19] However, this requires further clarification in a future study.

Third, the difference in dosage of 4HR between Groups A and B was greater than 100-fold. Additional studies are required to determine an optimal dosage within this range.

Fourth, the orthodontic force generated by closed coil spring is progressively reduced as its deactivation. Accordingly, some animals showed fully deactivated spring and further movement was impossible. This attenuated the difference according to the applied dosage.

Rat model has been widely used for the orthodontic movement because of similar characteristics with humans.[38] However, any animal study has inherent limitations.[60] Therefore, clinical application of 4HR for the orthodontic treatment should be careful.

5. Future clinical applicability of 4-hexylresorcinol in the orthodontic treatment

The effect of 4HR on tooth movement occurs not only by increasing the bone absorption on the compression side but also by increasing the bone formation on the tension side. There will be some advantages if 4HR can be safely utilized in the area of orthodontic treatment. First, acceleration of tooth movement can shorten the treatment period. Especially estrogen supplementation of middle-aged women in the postmenopausal period might slow the bone turnover and orthodontic tooth movement. Since 4HR does not show the side effect of estrogen hormone,[61] it can help for the orthodontic treatment. Second, 4HR can reduce periodontal problems in orthodontic treatment. For patients who already have poor periodontal support and low alveolar bone height, orthodontic treatment can be difficult or worsen the periodontal problem. In this case, 4HR administration can be of great help if it can support the formation of alveolar bone.

VI. CONCLUSION

In this study, the administration of 4HR resulted in an increased expression of osteogenic markers in Saos-2 cells. The administration of 4HR in ovariectomized rats also resulted in accelerated orthodontic tooth movement and increases in the levels of both bone formation markers (OC and BMP-2) and bone resorption markers (TRACP and RANKL). The ability to accelerate tooth movement of 4HR showed the potential to shorten the period of orthodontic treatment without destructive bone change.

VII. REFERENCES

1. Masella RS, Meister M. Current concepts in the biology of orthodontic tooth movement. Am J Orthod Dentofac Orthop. 2006;129:458-468.

2. Proffit WR. Fields HW, Larson B, Sarver DM. The biologic basis of orthodontic therapy. In Contemporary Orthodontics, 6th ed. Mosby: St Louis, IX, USA, 2018;296-325.

3. Kurol J, Owman-Moll P. Hyalinization and root resorption during early orthodontic tooth movement in adolescents. Angle Orthod. 1998;68:161-165.

4. Theodorou CI, Kuijpers-Jagtman AM, Bronkhorst EM. Optimal force magnitude for bodily orthodontic tooth movement with fixed appliance: A systematic review. Am J Orthod Dentofac Orthop. 2019;156:582-592.

5. Nishimura M, Chiba M, Ohashi T, Sato M, Shimizu Y, Igarashi K, Mitanig H. Periodontal tissue activation by vibration: Intermittent stimulation by resonance vibration accelerates experimental tooth movement in rats. Am J Orthod Dentofac Orthop. 2008;133:572-583.

6. Iino S, Sakoda S, Ito G, Nishimori T, Ikeda T, Miyawaki S. Acceleration of orthodontic tooth movement by alveolar corticotomy in the dog. Am J Orthod Dentofac Orthop. 2007;131:448.e1-e8.

7. Alfawal AMH, Hajeer MY, Ajaj MA, Hamadah O, Brad B. Effectiveness of minimally invasive surgical procedures in the acceleration of tooth movement: A systematic review and metaanalysis. Prog Orthod.

2016;17:33.e1-e12.

8. Li Y, Chen XY, Tang ZL, Tan JQ, Wang DX, Dong Q. Differences in accelerated tooth movement promoted by recombinant human parathyroid hormone after mandibular ramus osteotomy. Am J Orthod Dentofac Orthop. 2019;155:670-680.

9. Bartzela T, Türp, JC, Motschall E, Maltha JC. Medication effects on the rate of orthodontic tooth movement: A systematic literature review. Am J Orthod Dentofac Orthop. 2009;135:16-26.

10. Drăgănescu M, Carmocan C. Hormone therapy in breast cancer. Chirurgia 2017;112:413-417.

11. Kozubek A, Tyman JHP. Resorcinolic lipids, the natural non-isoprenoid phenolic amphiphiles and their biological activity. Chem Rev. 1999;99:1-25.

12. Farris P, Zeichner J, Berson D. Efficacy and tolerability of a skin brightening/anti-aging cosmeceutical containing retinol 0.5%, niacinamide, hexylresorcinol, and resveratrol. J Drugs Dermatol. 2016;15:863-868.

13. Kweon H, Kim SG, Choi JY. Inhibition of foreign body giant cell formation by 4- hexylresorcinol through suppression of diacylglycerol kinase delta gene expression. Biomaterials 2014;35:8576-8584.

14. Song JY, Kim SG, Park NR, Choi JY. Porcine bone incorporated with 4-hexylresorcinol increases new bone formation by suppression of the

nuclear factor kappa B signaling pathway. J Craniofac Surg. 2018;29:1983-1990.

15. Lee K, Seo I, Choi MH, Jeong D. Roles of mitogen-activated protein kinases in osteoclast biology. Int J Mol Sci. 2018;19:3004.e1-e20.

16. Sobacchi C, Menale C, Villa A. The RANKL-RANK axis: A bone to thymus round trip. Front Immunol. 2019;10:629.e1-e10.

17. Kim SG, Hahn BD, Park DS, Lee YC, Choi EJ, Chae WS, Baek DH, Choi JY. Aerosol deposition of hydroxyapatite and 4-hexylresorcinol coatings on titanium alloys for dental implants. J Oral Maxillofac Surg. 2011;69:e354-e363.

18. Jo YY, Kim DW, Choi JY, Kim SG. 4-Hexylresorcinol and silk sericin increase the expression of vascular endothelial growth factor via different pathways. Sci Rep. 2019;9:3448.e1-e11.

19. Kim MK, Yoon CS, Kim SG, Park YW, Lee SS, Lee SK. Effects of 4-hexylresorcinol on protein expressions in RAW 264.7 cells as determined by immunoprecipitation high performance liquid chromatography. Sci Rep. 2019;9:3379.e1-e15.

20. Qin Y, Tang S, Zhen G, Ding Q, Ding S, Cao X. Bone-targeted delivery of TGF-β type 1 receptor inhibitor rescues uncoupled bone remodeling in Camurati-Engelmann disease. Ann N Y Acad Sci. 2018;1433:29-40.

21. Bauss F, Wagner M, Hothorn LH. Total administered dose of ibandronate determines its effects on bone mass and architecture in

ovariectomized aged rats. J Rheumatol. 2002;29:990–998.

22. Yeh JK, Chen MM, Aloia JF. Ovariectomy−induced high turnover in cortical bone is dependent on pituitary hormone in rats. Bone 1996;18:443–450.

23. Iglesias−Linares A, Morford LA, Hartsfield JK Jr. Bone density and dental external apical root resorption. Curr Osteoporos Rep. 2016;14:292–309.

24. Sirisoontorn I, Hotokezaka H, Hashimoto M, Gonzales C, Luppanapornlarp S, Darendeliler MA, Yoshida N. Tooth movement and root resorption; the effect of ovariectomy on orthodontic force application in rats. Angle Orthod. 2011;81:570–577.

25. Staderini E, Guglielmi F, Cornelis MA, Cattaneo PM. Three−dimensional prediction of roots position through cone−beam computed tomography scans−digital model superimposition: A novel method. Orthod Craniofac Res. 2019;22:16–23.

26. Wang N, Zhou Z, Wu T, Liu W, Yin P, Pan C, Yu X. TNF−α−induced NF−κB activation upregulates microRNA−150−3p and inhibits osteogenesis of mesenchymal stem cells by targeting β−catenin. Open Biol. 2016;6:150258.e1−e10.

27. Fogh J, Fogh JM, Orfeo T. One hundred and twenty−seven cultured human tumor cell lines producing tumors in nude mice. J Natl Cancer Inst. 1977;59:221–226.

28. Rodan SB, Imai Y, Thiede MA, Wesolowski G, Thompson D, Bar−Shavit

Z, Shull S, Mann K, Rodan GA. Characterization of a human osteosarcoma cell line (Saos-2) with osteoblastic properties. Cancer Res. 1987;47:4961-4966.

29. McQuillan DJ, Richardson MD, Bateman JF. Matrix deposition by a calcifying human osteogenic sarcoma cell line (SAOS-2). Bone. 1995;16:415-426.

30. Gundle R, Beresford JN. The isolation and culture of cells from explants of human trabecular bone. Calcif Tissue Int. 1995;56(Suppl 1):S8-10.

31. Cesnjaj M, Stavljenic A, Vukicevic S. Decreased osteoinductive potential of bone matrix from ovariectomized rats. Acta Orthop Scand. 1991;62:471-475.

32. Wronski TJ, Cintro´n M, Doherty AL, Dann LM. Estrogen treatment prevents osteopenia and depresses bone turnover in ovariectomized rats. Endocrinology. 1988;123:681-686.

33. Uzawa T, Hori M, Ejiri S, Ozawa H. Comparison of the effects of intermittent and continuous administration of human parathyroid hormone (1-34) on rat bone. Bone. 1995;16:477-484.

34. Chen H, Frankenburg EP, Goldstein SA, McCauley LK. Combination of local and systemic parathyroid hormone enhances bone regeneration. Clin Orthop Relat Res. 2003;416:291-302.

35. Soma S, Iwamoto M, Higuchi Y, Kurisu K. Effects of continuous infusion of PTH on experimental tooth movement in rats. J Bone Miner Res.

1999;14:546-554.

36. Soma S, Matsumoto S, Higuchi Y, Takano-Yamamoto T, Yamashita K, Kurisu K, et al. Local and chronic application of PTH accelerates tooth movement in rats. J Dent Res. 2000;79:1717-1724.

37. Li F, Li G, Hu H, Liu R, Chen J, Zou S. Effect of parathyroid hormone on experimental tooth movement in rats. Am J Orthod Dentofacial Orthop. 2013;144:523-532.

38. Salazar M, Hernandes L, Ramos AL, Micheletti KR, Albino CC, Nakamura, Cuman RK. Effect of teriparatide on induced tooth displacement in ovariectomized rats: a histomorphometric analysis. Am J Orthod Dentofacial Orthop. 2011;139:e337-344.

39. Haruyama N, Igarashi K, Saeki S, Otsuka-Isoya M, Shinoda H, Mitani H. Estrous-cycle-dependent variation in orthodontic tooth movement. J Dent Res. 2002;81:406-410.

40. Yamashiro T, Takano-Yamamoto T. Influences of ovariectomy on experimental tooth movement in the rat. J Dent Res. 2001;80:1858-1861.

41. Han G, Chen Y, Hou J, Liu C, Chen C, Zhuang J, Meng W. Effects of simvastatin on relapse and remodeling of periodontal tissues after tooth movement in rats. Am J Orthod Dentofacial Orthop. 2010;138:550.e1-e7.

42. MirHashemi AH, Afshari M, Alaeddini M, Etemad-Moghadam S, Dehpour A, Sheikhzade S, Akhoundi MSA. Effect of atorvastatin on

orthodontic tooth movement in male Wistar rats. J Dent (Tehran). 2013;10:532-539.

43. AlSwafeeri H, ElKenany W, Mowafy M, Karam S. Effect of local administration of simvastatin on orthodontic tooth movement in rabbits. Am J Orthod Dentofacial Orhop. 2019;156:75-86.

44. Anesi A, Generali L, Sandoni L, Pozzi S, Grande A. From osteoclast differentiation to osteonecrosis of the jaw: Molecular and clinical insights. Int J Mol Sci. 2019;20:4925.e1-e18.

45. Bruderer M, Richards RG, Alini M, Stoddart MJ. Role and regulation of RUNX2 in osteogenesis. Eur Cell Mater. 2014;28:269–286.

46. Sinha KM, Zhou X. Genetic and molecular control of osterix in skeletal formation. J Cell Biochem. 2013;114:975–984.

47. Dodge GR, Diaz A, Sanz-Rodriguez C, Reginato AM, Jimenez SA. Effects of interferon-gamma and tumor necrosis factor alpha on the expression of the genes encoding aggrecan, biglycan, and decorin core proteins in cultured human chondrocytes. Arthritis Rheum. 1998;41:274–283.

48. Choi YH, Choi JH, Oh JW, Lee KY. Calmodulin-dependent kinase II regulates osteoblast differentiation through regulation of osterix. Biochem Biophys Res Commun. 2013;432:248–255.

49. Kokabu S, Rosen V. BMP3 expression by osteoblast lineage cells is regulated by canonical Wnt signaling. FEBS Open Biol. 2017;8:168–176.

50. Kenkre JS, Bassett J. The bone remodelling cycle. Ann Clin Biochem. 2018;55:308–327.

51. Mizokami A, Kawakubo-Yasukochi T, Hirata M. Osteocalcin and its endocrine functions. Biochem Pharmacol. 2017;132:1–8.

52. Singh A, Gill G, Kaur H, Amhmed M, Jakhu H. Role of osteopontin in bone remodeling and orthodontic tooth movement: A review. Prog Orthod. 2018;19:18.e1-e8.

53. Lee KM, Kim YI, Park SB, Son WS. Alveolar bone loss around lower incisors during surgical orthodontic treatment in mandibular prognathism. Angle Orthod. 2012;82:637–644.

54. Oz AZ, Ciger S. Health of periodontal tissues and resorption status after orthodontic treatment of impacted maxillary canines. Niger J Clin Pract. 2018;21:301–305.

55. Civitelli R, Armamento-Villareal R, Napoli N. Bone turnover markers: Understanding their value in clinical trials and clinical practice. Osteoporos Int. 2009;20:843–851.

56. Jung HM, Lee JE, Lee SJ, Lee JT, Kwon TY, Kwon TG. Development of an experimental model for radiation-induced inhibition of cranial bone regeneration. Maxillofac Plast Reconstr Surg. 2018;40:34.e1-e8.

57. Weisz J, Gunsalus P. Estrogen levels in immature female rats: True or spurious—Ovarian or adrenal? Endocrinology 1973;93:1057–1065.

58. Yoon KH, Cho DC, Yu SH, Kim KT, Jeon Y, Sung JK. The change of

bone metabolism in ovariectomized rats: Analyses of microCT scan and biochemical markers of bone turnover. J Korean Neurosurg Soc. 2012;51:323–327.

59. Ueta M, Takaoka K, Yamamura M, Maeda H, Tamaoka J, Nakano Y, Noguchi K, Kishimoto H. Effects of TGF-β1 on the migration and morphology of RAW264.7 cells in vitro. Mol. Med. Rep. 2019;20:4331–4339.

60. Farris EJ, Griffth JQ, Hafner JB. Breeding of the rat. In The rat in laboratory investigation, 2nd ed. Lippincott Company: Philadelphia, NY, USA, 1963;1–18.

61. Kang YJ, Oh JH, Seok H, Jo YY, Kim DW, Garagiola U, Choi JY, Kim SG. 4-Hexylresorcinol exhibits different characteristics to estrogen. Allp Sci. 2020;10:1737.e1-e11.

Table 1. Intergroup comparison of distance of tooth movement. (Change of the distance between the mandibular incisor and the mandibular first molar)

Group	Control	Group A (Low 4HR)	Group B (High 4HR)
Day 7	0.24 ± 0.84 mm	0.92 ± 1.00 mm	0.89 ± 0.61 mm
Day 14	1.98 ± 1.12 mm	2.63 ± 0.68 mm	2.90 ± 0.42 mm* (P = 0.046)

Control group received solvent only. Group A received low dosage of 4HR (1.28 mg/kg) and Group B high dosage of 4HR (128mg/kg).

There was a significant difference among the groups (P =0.043), with the post hoc test showing the difference between the control group and Group B to be statistically significant (P =0.046).

*P <0.05, comparison between the experimental groups and control group at each time point. The values are presented as mean ± SD.

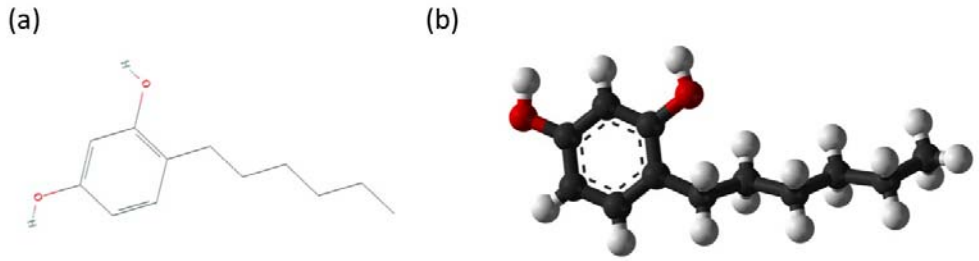

Figure 1. Molecular structure of 4-hexylresorcinol. 4HR contains of 18 hydrogen atoms, 12 carbon atoms and 2 oxygen atoms ($C_{12}H_{18}O_2$). (a) Chemical structure (b) 3D conformation

Figure 2. Application of 8mm nickel-titanium closed coil spring between the right mandibular first molars and incisor of the ovariectomized rats.

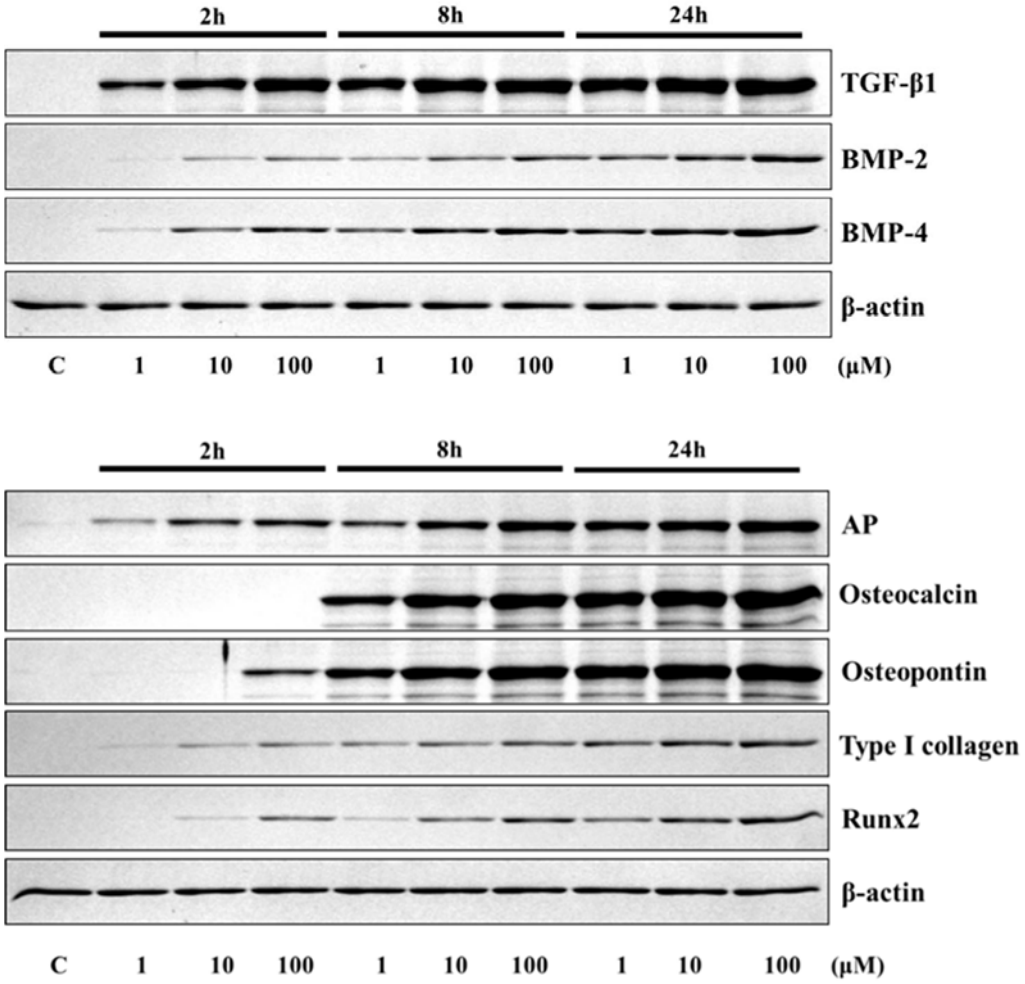

Figure 3. Western blot analysis of Saos-2 cells after 4HR administration. Expression of the osteogenic makers such as transforming growth factor-β1 (TGF-β1), bone morphogenic protein-2 (BMP-2), and BMP-4, alkaline phosphatase (AP), osteocalcin, osteopontin, type I collagen, and runt-related transcription factor 2 (RUNX2) was assessed. Expression levels were increased in proportion to 4HR concentration and time.

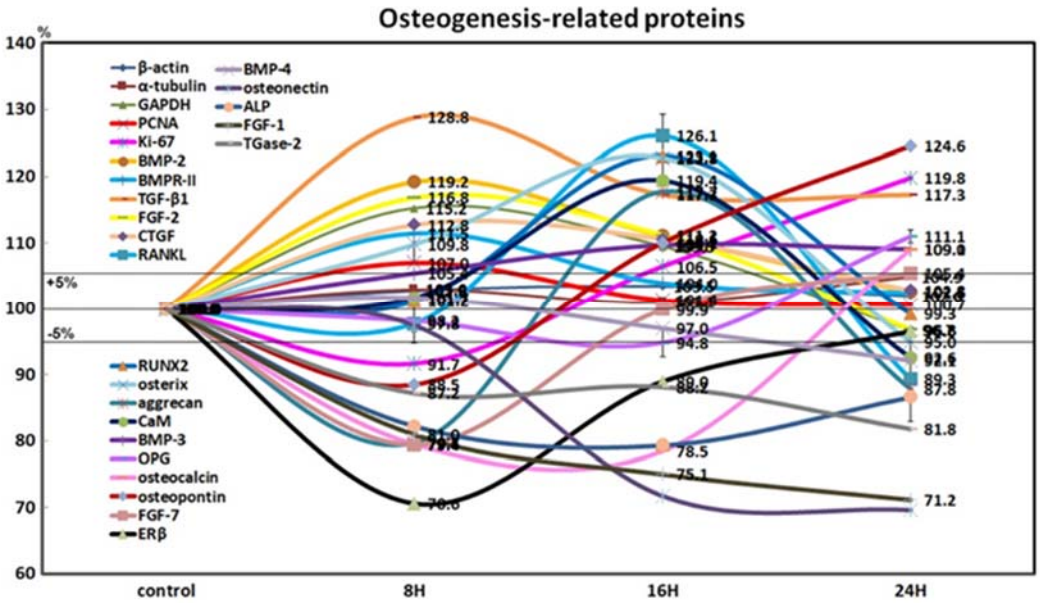

Figure 4. Expression of osteogenesis-related proteins (n = 21) in 4HR-treated Saos-2 cells, as determined by high-performance liquid chromatography. The line graph shows protein expression patterns on the same scale (%) versus culture time (8, 16, or 24 hours).

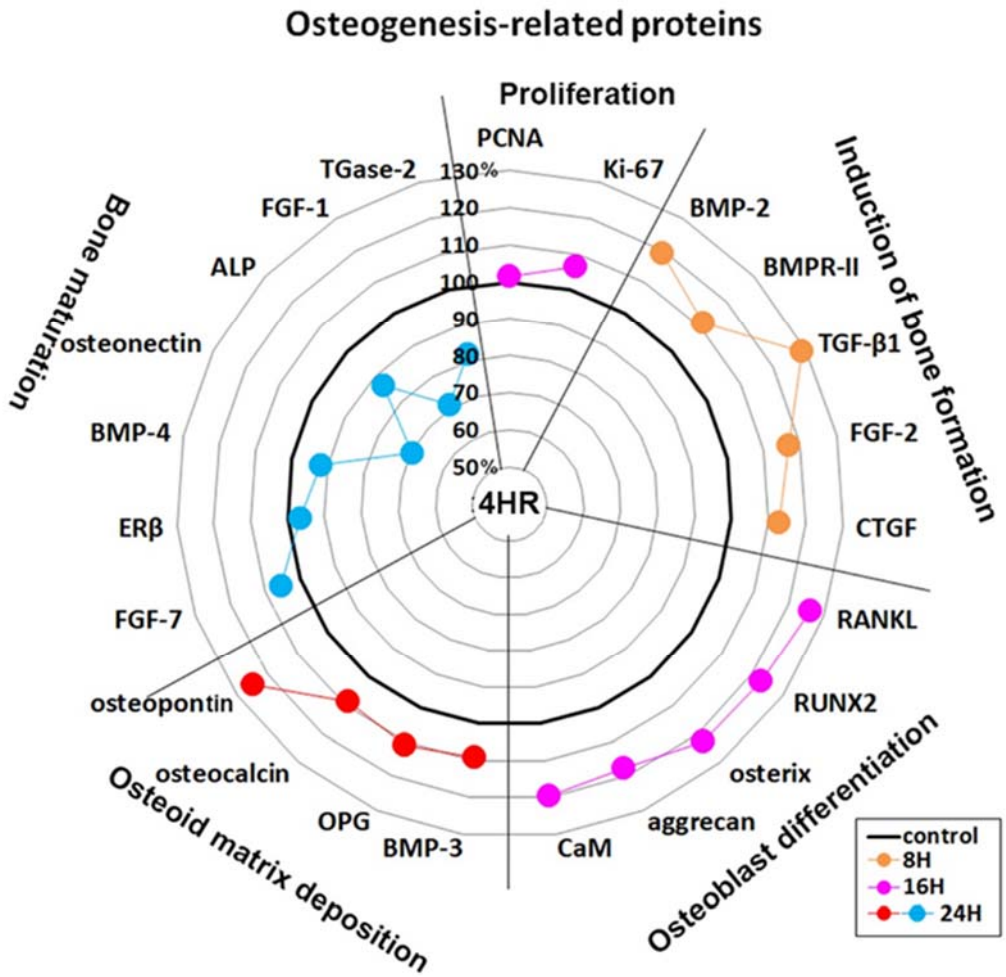

Figure 5. Star plot of global protein expression in Saos-2 cells treated with 4HR for 24 hours. The expression level (%) of osteogenesis-related proteins (n = 23) were sequentially dominant (in accordance with the four stages of osteogenesis) at 8 (orange dots), 16 (pink dots), and 24 hours (red and blue dots) after 4HR treatment compared to the non-treated control.

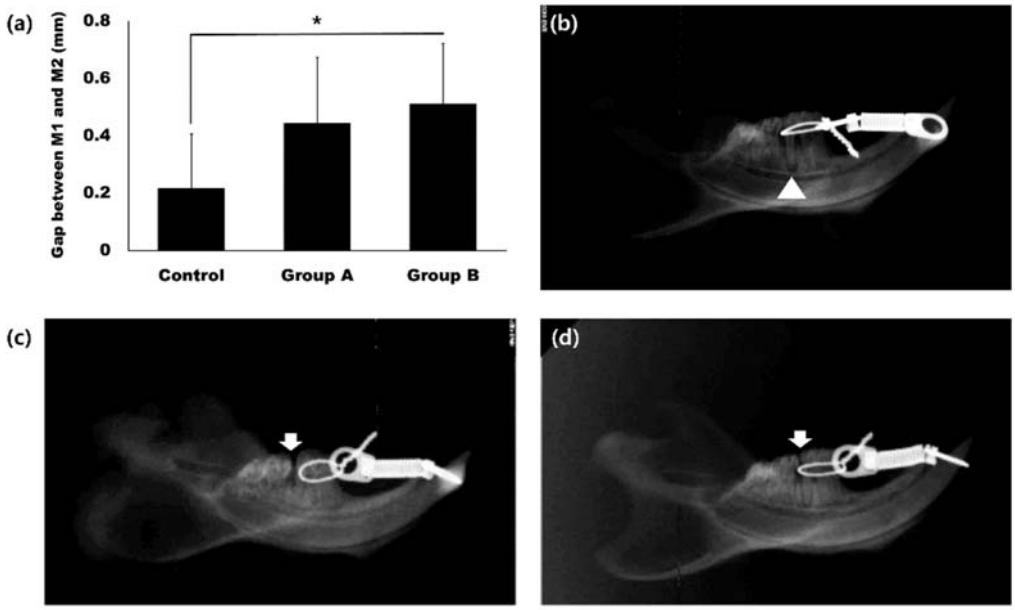

Figure 6. The gap between the first and the second molar measured in radiogram. Group A received low dosage of 4HR (1.28 mg/kg) and Group B high dosage of 4HR (128mg/kg). (a) There was a significant difference among the groups (P =0.011). In post hoc test, the difference between the control group and Group B to be statistically significant (P =0.012). (b) A radiogram at day 14, Control group, (c) A radiogram at day 14, Group A, (d) A radiogram at day 14, Group B,

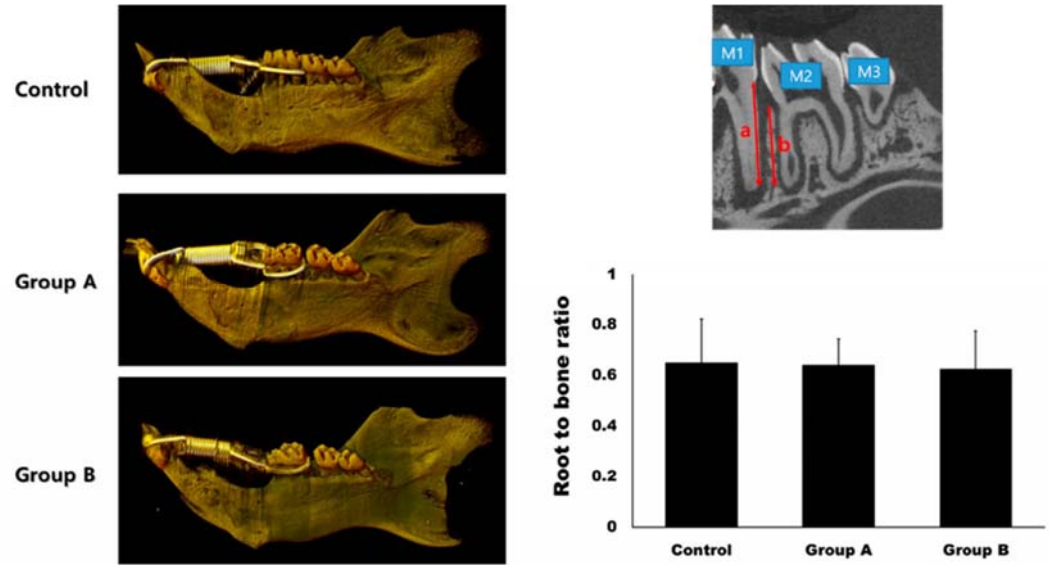

Figure 7. Micro-computerized tomogram. The gap between the first molar (M1) and the second molar (M2) was much wider in Group A and B compared to the control group. The root-to-bone ratio was measured at the distal surface of the distal root of M1. It was calculated as the ratio between the root length (a) and bone height (b). There was no significant difference in the root-to-bone ratio among the groups ($P > 0.05$).

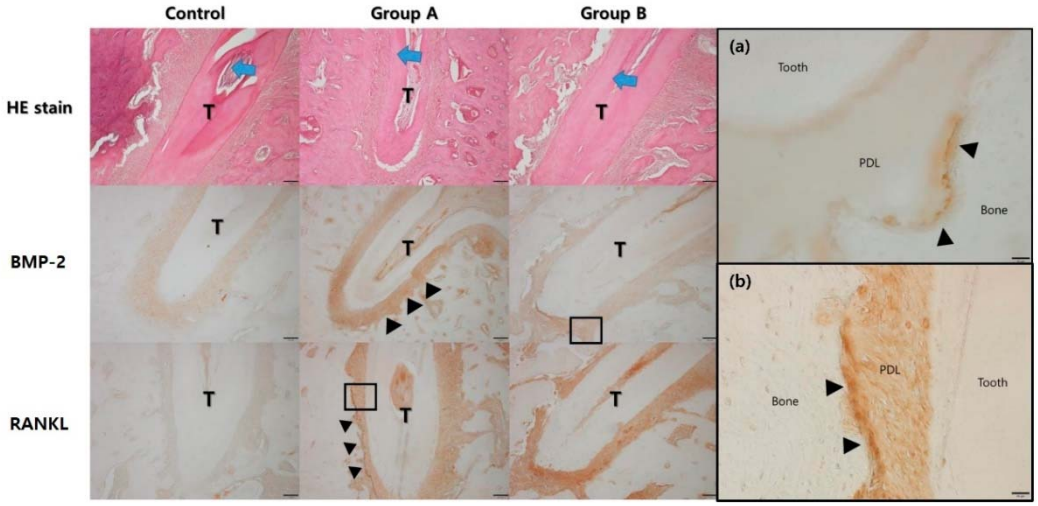

Figure 8. Histological analysis under the hematoxylin and eosin (HE) stain. The direction of tooth movement is indicated by the blue arrow at the central root of the first molar (T). The width of the periodontal ligament space was narrower on the compression side than on the tension side. The expression level of BMP-2 was higher in Group A and B compared to the control group on the tension side (arrow heads). The expression level of RANKL was also higher in Group A and B compared to the control group on the compression side (arrow heads). (a) High magnification views for BMP-2 of Group B showed the expression was mainly found in the cells lined on the tension side of the alveolar bone (arrow heads, original magnification x400) (PDL: periodontal ligament). (b) High magnification views for RANKL of Group A showed the expression was mainly found in the cells lined on the compression side of the alveolar bone (arrow heads, original magnification x400).

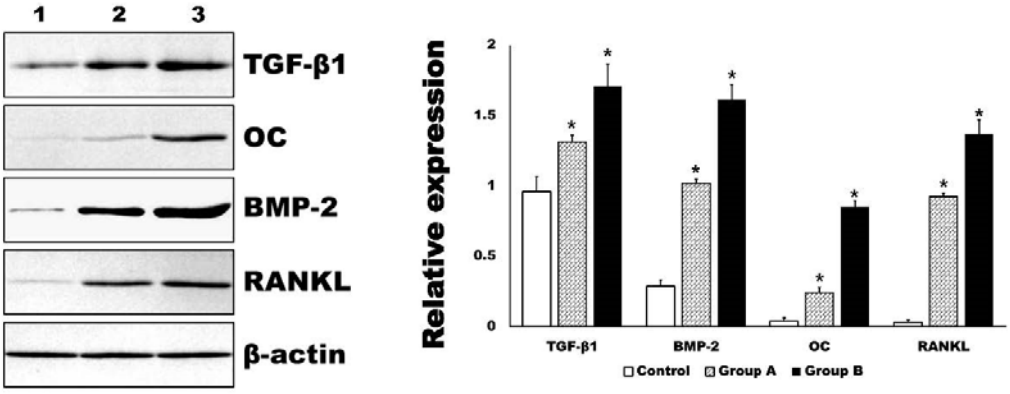

Figure 9. Western blot for tissue samples. The level of transforming growth factor-β1 (TGF-β1), osteocalcin (OC), bone morphogenic protein-2 (BMP-2), and receptor activator of nuclear factor kappa-B ligand (RANKL) were significantly increased in 4HR administered groups (Group A and B, *P <0.001) compared to the control group. The increasing of each marker was dependent on the applied dosage of 4HR (1: Control, 2: Group A, 3: Group B)

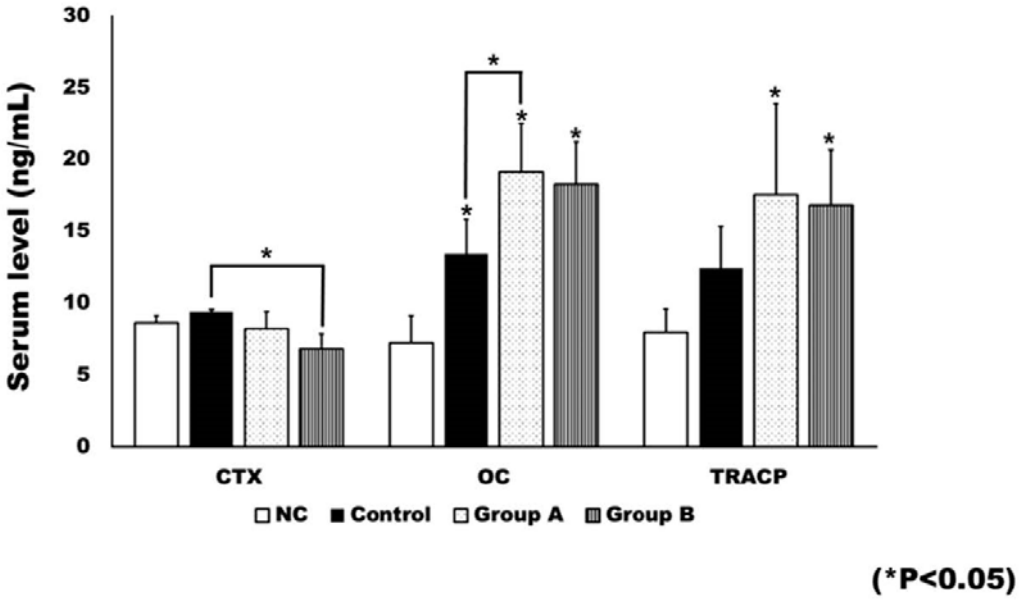

Figure 10. The plasma level of bone turnover markers.

The level of c-terminal cross linking telopeptide (CTX) was generally decreased after 4HR treatment. The CTX level in Group B was significantly lower than that of the control (* P =0.010).

The level of osteocalcin (OC) was significantly increased after ovariectomy (* P <0.05). When compared to the NC group, the control group (P =0.004), Group A (P <0.001), and Group B (P=0.001) showed significantly higher levels of OC. In addition, 4HR administration further increased the OC level. When compared to the control group, Group A showed a significantly higher OC level (*P =0.029).

The tartrate-resistant acid phosphatase (TRACP) level was also increased after ovariectomy. When compared to the NC group, Group A (P =0.003) and Group B (P =0.009) showed significantly increased TRACP levels.

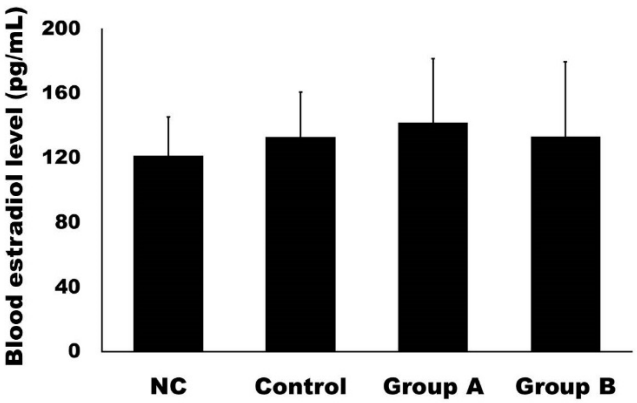

Figure 11. Blood estradiol level. The average value of blood estradiol was slightly increased after ovariectomy. However, the difference among groups was not statistically significant (P>0.05).

국문 초록

난소절제술을 시행한 쥐에서 4-Hexylresorcinol이 교정적 치아이동에 미치는 영향

최 광 효

서울대학교 대학원 치의과학과 치과교정학 전공

(지도교수: **김 태 우**)

목적: 4-Hexylresorcinol(4HR) 은 골개조를 증진시킨다는 것이 밝혀졌으며, 치아 이동을 촉진할 수 있는 가능성이 있다. 본 연구는 4HR이 (1) 조골세포에 미치는 영향 및 (2) 난소절제술을 시행한 쥐에서 치아이동에 미치는 영향을 평가하기 위해 시행되었다.

재료 및 방법: 총 30 마리의 Sprague-Dawley 쥐에서 난소절제술을 시행한 뒤에, 대조군, 저용량 4HR 투여군 (A군) 및 고용량 4HR 투여군 (B군)을 각각 10마리씩 설정하였다. A군과 B군에는 실험 0, 7 및 14일에 4HR을 복부에 피하주사(A군은 1.28 mg/kg, B군은 128 mg/kg)로 투여하였다. 쥐 하악에서 우측 절치와 제1대구치 사이에 NiTi-closed coil spring을 장착하여 치아이동을 위한 교정력을 부여하였다. 하악골 절편을 micro-computerized

tomography 및 조직학적 분석을 통하여 치아 주위의 골변화를 관찰하였다. 각 군에서 치아 이동량, 혈액 내 골대사 관련 인자의 발현을 검사하여 대조군과 비교하였다. 4HR이 조골세포에 미치는 생화학적 변화를 보기 위하여 4HR을 Saos-2 세포에 적용한 뒤 2, 8 및 24시간 후에 골대사와 연관된 단백질 발현을 웨스턴 블롯 및 면역침강반응 고성능 색층분석법 (IP-HPLC)을 이용하여 대조군과 비교하였다.

결과: 4HR을 투여한 군에서 대조군에 비하여 제1대구치의 이동량이 유의미한 증가를 보였다. 제1대구치 인장측에서 치조골의 높이는 대조군과 4HR 투여군에서 차이가 없었다. 조직학적 분석에서 4HR 투여군에서 대조군과 비교시 치아 이동의 압박측에서 BMP-2 (bone morphogenic protein-2)의 증가, 인장측에서 RANKL (receptor activator of nuclear factor kappa-B ligand)의 증가가 관찰되었다. 혈액분석에서는 4HR 투여군에서 osteopontin 및 TRAP (tartrate-resistant acid phosphatase) 증가가 관찰되었다. Saos-2 세포를 이용한 실험에서 4HR을 적용하였을 때 골형성에 관련된 인자들이 발현되었다.

결론: 난소절제술을 시행한 쥐에 4HR을 적용했을 때 교정적 치아 이동량이 증가하였으며, 골형성 및 골흡수에 관련된 표지자의 발현이 모두 증가하였다. 4HR을 사용하여 파괴적 골변화없이 교정적 치아이동을 가속화시킬 수 있는 가능성을 보였다.

주요어: 4-hexylresorcinol; ovariectomy; 동물 실험; 치아이동: 골형성 단백질; nuclear factor kappa-B ligand

학번: 2013-30657