의학석사 학위논문

Anatomical attributes of clinically relevant diagonal branches in patients with left anterior descending coronary artery bifurcation lesions

좌전하행 관상동맥 분지병변이 있는 환자에서 임상적으로 중요한 대각분지의 해부학적 속성에 관한 연구

2021년 8월

서울대학교 대학원

의학과 내과학 전공

전 원 경

Anatomical attributes of clinically relevant diagonal branches in patients with left anterior descending coronary artery bifurcation lesions

지도 교수 구 본 권

이 논문을 의학석사 학위논문으로 제출함
2021년 4월

서울대학교 대학원
의학과 내과학 전공
전 원 경

전원경의 의학석사 학위논문을 인준함
2021년 7월

위 원 장 _____ 장 은 화 _____

부위원장 _____ 구 본 권 _____

위 원 _____ 양 한 모 _____

Abstract

Anatomical attributes of clinically relevant diagonal branches in patients with left anterior descending coronary artery bifurcation lesions

Won Kyeong Jeon

Department of Internal Medicine

College of Medicine, Graduate School

Seoul National University

Backgrounds: Coronary bifurcation lesion is complex lesion subset with unique anatomical and physiological features. Previous studies failed to prove superiority of 2-stenting strategy over provisional stenting strategy. Therefore, in the determination of treatment strategy for bifurcation lesions, decision for which side branch to treat is important. This study was performed on the hypothesis that

evaluating myocardial territory of diagonal branches may assist efficient determination of clinically relevant branch in bifurcation lesion cases.

Aims: This study aimed to investigate the anatomical attributes determining myocardial territory of diagonal branches in patients with left anterior descending coronary artery bifurcation lesions and to develop prediction models for clinically relevant branches using myocardial perfusion imaging (MPI) and coronary CT angiography (CCTA).

Methods and results: The amount of ischemia and subtended myocardial mass of diagonal branches were quantified using MPI by percent ischemic myocardium (%ischemia) and CCTA by percent fractional myocardial mass (%FMM), respectively. In 49 patients with isolated diagonal branch disease, the mean %ischemia by MPI was 6.8±4.0%, whereas in patients with total occlusion or severe disease of all diagonal branches it was 8.4±3.3%. %ischemia was significantly smaller with the presence of non-diseased diagonal branches and dominant left circumflex artery (LCx). In the CCTA cohort (306 patients, 564 diagonal branches), mean %FMM was 5.9±4.4% and 86 branches (15.2%) had %FMM ≥10%. %FMM was different according to LCx dominance, number of branches, vessel size (≥2.5mm) and relative dominance between two diagonal branches. The diagnostic accuracy of prediction models for %FMM ≥10% based on logistic regression and decision tree was 0.92 (95% CI: 0.85-0.96) and 0.91 (95% CI: 0.84-0.96), respectively. There was no difference in the diagnostic performance of models with and without vessel size criterion.

Conclusions: LCx dominance, number of branches, vessel size, and dominance among diagonal branches determined the myocardial territory of diagonal branches. Clinical application of prediction models based on these anatomical attributes

would help to determine the clinically relevant diagonal branches in the cardiac catheterization laboratory.

Keyword : bifurcation, diagonal branch, ischemic burden, fractional myocardial mass, risk stratification

Student Number : 2015-21973

Table of Contents

Chapter 1. Introduction

Bifurcation lesions are one of the most challenging lesion subsets in the field of percutaneous coronary intervention (PCI). In general, clinicians determine which side branch deserves revascularization by integrating information including clinical setting, ease of access to branches, disease extent, plaque morphology, and anatomical relevance.

Despite recent advances in PCI techniques and stent technology, most randomized studies have failed to prove the superiority of a routine two-stent strategy compared with a provisional side branch intervention strategy [1]. A certain amount of ischemic burden is required to achieve the benefit of revascularization over medical treatment [2, 3]. Compared with main branches, side branches are smaller, more variable in anatomy, supplying less myocardium and less clinically relevant [4, 5]. Therefore, it is important to assess the myocardial mass at risk of side branches to determine the appropriate treatment strategy for bifurcation lesions. However, the method to identify the clinically relevant side branches associated with benefit from revascularization in the cardiac catheterization laboratory is not well defined.

This study was aimed to investigate anatomical attributes that determine ischemic burden and myocardial territory of diagonal branches, and to develop a prediction model for clinically relevant diagonal branches using myocardial perfusion imaging (MPI) and coronary computed tomography angiography (CCTA).

Chapter 2. Methods

STUDY POPULATION

Two different modalities, MPI and CCTA, were used to quantify the amount of ischemia and myocardial territory of a diagonal branch, respectively. For the MPI cohort, patients with severe jailed diagonal branch disease with available MPI within three months of invasive coronary angiography were selected from the Seoul National University Hospital Cardiac Catheterization and MPI database. Severe stenosis of a diagonal branch was defined as ≥90% angiographic stenosis or fractional flow reserve <0.75. Patients with >50% stenosis in the left anterior descending coronary artery (LAD) or left circumflex artery (LCx), or regional wall motion abnormality at the LAD territory were excluded (Figure 1). For the CCTA cohort, patients from a previous multicenter prospective registry were retrospectively reviewed for a post hoc analysis [4]. Patients with an available fractional myocardial mass (FMM) value of diagonal branches were included and those with diffuse diagonal branch disease were excluded from the analysis (Figure 1). The study protocol was approved by the institutional review board of each center.

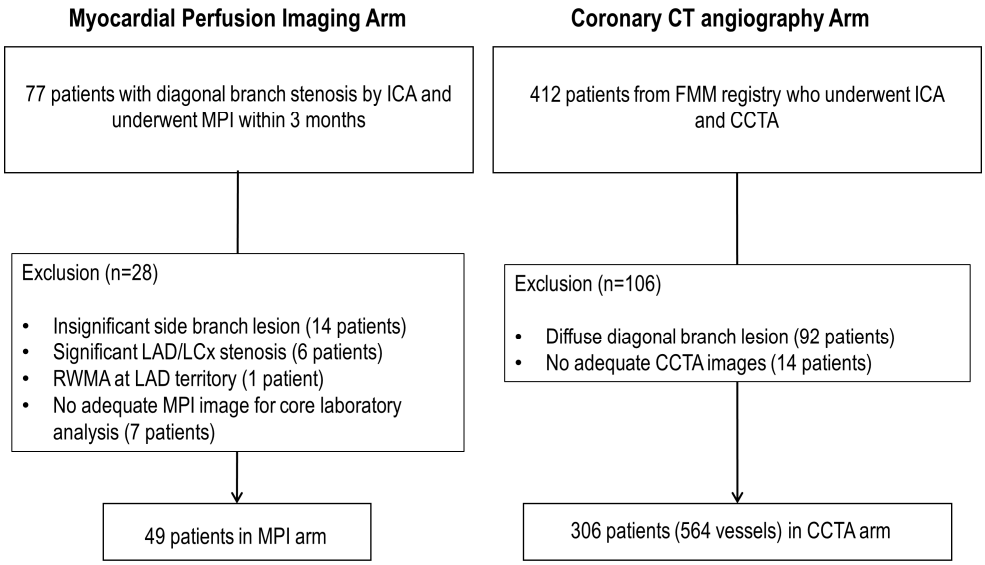

Figure 1. Flow chart illustrating the design of the study. ICA, invasive coronary angiography; MPI, myocardial perfusion imaging; LAD, left anterior descending coronary artery; LCx, left circumflex artery; RWMA, regional wall motion abnormality; FMM, fractional myocardial mass; CCTA, coronary CT angiography

MPI PROTOCOLS AND PARAMETERS

For the myocardial perfusion positron emission tomography (PET)/CT image acquisition, one-day stress and rest protocol was conducted using a BiographTM 40 TruePoint PET/CT (Siemens Medical Solutions, Knoxville, TN, USA). Rest images were acquired in 3D list-mode and stress images were acquired with adenosine infusion. Both images were acquired after administering 370 MBq of 13N-NH3. For the myocardial perfusion single photon emission CT (SPECT) image acquisition, the dual isotope protocol was conducted using 99mTc–sestamethoxyisobutylisonitrile and 201Tl for stress and rest images, respectively. All MPI images were screened and assessed by an independent MPI core laboratory at Seoul National University Hospital. Perfusion parameters were

evaluated automatically using Quantitative Perfusion SPECT (QPS; Cedars-Sinai Medical Center, Los Angeles, CA, USA). Myocardium was divided into 20 segments, and summed rest score (SRS), summed stress score (SSS), and summed difference score (SDS) were scored in each segment according to a five-grade system (0-4) for the assessment of perfusion status. SSS and SDS of diagonal segments were converted to percent of myocardial ischemia (%ischemia) of diagonal territory by dividing summed scores by 80 and multiplying by 100 (Figure 2, Figure 3) [2]. PET flow, coronary flow reserve and relative flow reserve were assessed as the ratio of stress myocardial blood flow (MBF) and resting MBF and as the ratio of stress MBF in diagonal myocardial territories to that of a reference vascular territory. [6, 7].

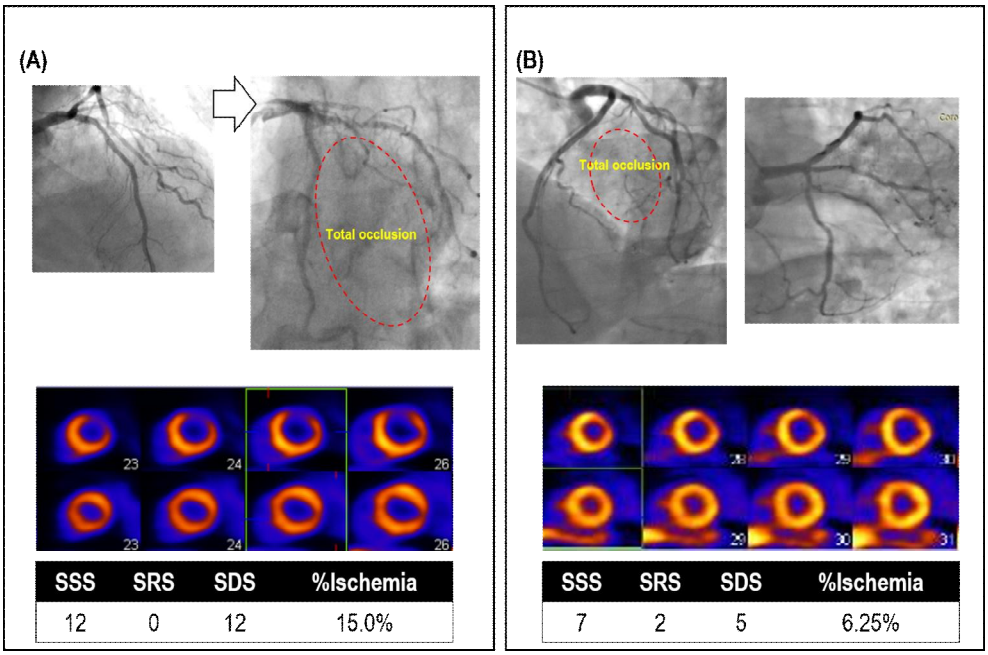

Figure 2. Myocardial ischemic territory caused by diagonal branch occlusion. A) Occlusion of a solitary diagonal branch caused %ischemia of 15%. B) However, %ischemia due to first diagonal branch occlusion was 6.25% in a case of

residual diagonal branch and large ramus intermedius. SDS: summed difference score; SRS, summed rest score; SSS, summed stress score

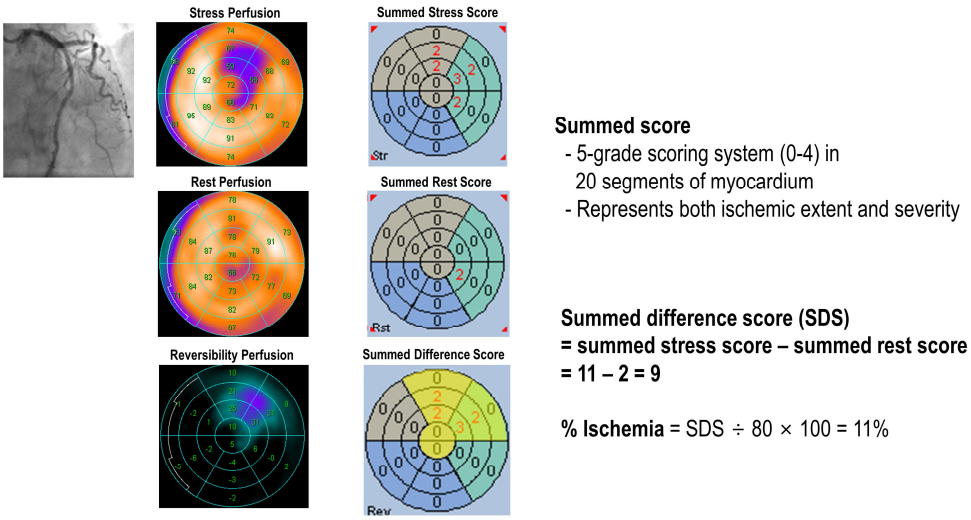

Figure 3. Calculation of percent ischemic territory by myocardial perfusion imaging. Myocardium was divided into 20 segments, and summed rest score (SRS), summed stress score (SSS), and summed difference score (SDS) were scored in every segment according to a 5-grade system (0-4) for the assessment of perfusion status. SSS and SDS of diagonal segments were converted to percent of myocardial ischemia of diagonal territory by dividing summed scores by 80 and multiplying by 100.

CORONARY CT ANGIOGRAPHY AND FRACTIONAL MYOCARDIAL MASS

CCTA was performed with at least 64-slice CT scanners (Aquilion ONETM or Aquilion 64 [Toshiba Medical Systems Corporation, Tochigi, Japan]; SOMATOM® Definition [Siemens Medical Solutions]; LightSpeed VCT [GE

Healthcare, Chicago, IL, USA]). Image data were reconstructed to a 3D coronary arterial tree model by a dedicated system (iNtuition; TeraRecon, Durham, NC, USA). CCTA analysis and FMM calculation were performed in an independent CCTA core laboratory at Samsung Medical Center. FMM of each diagonal branch was converted to percent FMM (%FMM) of diagonal branch by dividing each FMM by left ventricular myocardial mass. CCTA data were used to train and validate the prediction models for %FMM ≥10%.

DIAGONAL BRANCH SPECIFIC ANGIOGRAPHIC ATTRIBUTES

Coronary angiography was performed using standard techniques. Quantitative coronary angiography (QCA) was performed in an independent core laboratory with a validated software (CAAS 5.9; Pie Medical Imaging, Maastricht, the Netherlands). Angiographic attributes for diagonal branches >1.5 mm in diameter were visually defined as follows. Size was a binary attribute of vessel diameter ≥2.5 mm or <2.5 mm. Number was counted as one, two, and three or more diagonal branches. Dominance in patients with two diagonal branches (D1/2 dominance) was a binary attribute for one of two diagonal branches whose diameter was more than two times greater than its smaller counterpart. As part of the diagonal branch territory is shared with obtuse marginal branches, the total diagonal branch territory is influenced by the relative dominance of the LCx [8]. Therefore, the component of LCx dominance was defined as a left-dominant system or the presence of an obtuse marginal branch originating within the proximal 1/3 of the LCx and crossing the LAD at a right anterior oblique caudal view. The intermediate branch was classified as one of the obtuse marginal

branches. Clinically relevant diagonal branches were defined with %FMM ≥10% in this study. Two independent observers assessed the angiographic attributes in a blinded fashion. In cases with disagreement between observers, consensus was reached through discussion between the two observers.

STATISTICAL ANALYSIS

Continuous variables are presented as means with standard deviations. Categorical variables are presented as frequencies and percentages. Baseline characteristics, %ischemia and %FMM of the total diagonal territory are presented per patient. Per-vessel analysis was performed for the prediction of %FMM of an individual diagonal branch. The Student's t-test and chi-square test were used to compare continuous variables and categorical variables between groups, respectively. To train and validate models to predict %FMM ≥10%, the entire CCTA data set was split into training and validation sets (4:1). A binomial logistic regression model with tenfold cross-validation was used to train the prediction model. To build a decision tree model, the training and validation sets were used for recursive partitioning with tenfold cross-validation. Information gain was used to select attributes for higher nodes. The performance was compared in three different models: model 1 – size criterion only; model 2 – size, number, LCx dominance and D1/2 dominance; model 3 – number, D1/2 dominance and LCx dominance. The discrimination ability of a model was analyzed by comparing the area under the receiver operating characteristic (ROC) curve with a bootstrap method. The diagnostic performance of each model was assessed with sensitivity, specificity, positive predictive value, negative predictive value, and accuracy. All

probability values were two-sided, with $p<0.05$ considered statistically significant. All statistical analyses were conducted using R 3.4.3 (R Foundation for Statistical Computing, Vienna, Austria).

Chapter 3. Results

BASELINE CHARACTERISTICS

In the MPI cohort, 49 patients were included in the analysis after exclusion of 28 patients. Among 412 patients in the CCTA cohort, those with poor image quality and diffuse diagonal disease were excluded, resulting in 306 patients (564 diagonal branches) being included in this study (Figure 1). Baseline characteristics of patients in the MPI and CCTA cohorts are presented in Table 1.

ISCHAEMIC TERRITORY OF DIAGONAL BRANCHES

Among 49 patients assessed by MPI, 12 patients (24.5%) had %ischemia ≥10%. In 29 patients with severe disease in all diagonal branches, %ischemia was 8.4±3.3%, with 10 patients having %ischemia ≥10%. LCx dominance was present in 28 patients and their %ischemia was smaller than those without (5.6±3.8% vs 8.4±3.7%, p=0.012). Patients with non-diseased diagonal branches had lower %ischemia than those without LCx dominance (4.6±3.8% vs 8.4±3.3%, p=0.001). In 32 patients who underwent 13NH3-PET, mean hyperemic blood flow, coronary flow reserve, and relative flow ratio of ischemic diagonal territory were 1.66±0.35 g/mL/min, 1.83±0.57, and 0.66±0.10, respectively.

Table 1. Baseline Characteristics

	Myocardial perfusion imaging arm (n = 49)	Coronary CT angiography arm (n = 306)
Age, years	71.4 ± 7.4	63.6 ± 9.5
Male, n (%)	36 (73.5)	229 (74.8)
Body mass index, kg/m^2	24.7 ± 2.2	24.6 ± 2.7
Risk factors, n (%)		
Diabetes	23 (46.9)	118 (38.6)
Hypertension	32 (65.3)	194 (63.4)
Hypercholesterolemia	42 (85.7)	141 (46.1)
LVEF, %	61.0 ± 5.9	64.0 ± 6.8
Clinical diagnosis, n (%)		
Stable angina	49 (100.0)	248 (81.0)
Unstable angina	-	58 (19.0)
Diagonal branch territory	(n=49)	(n = 564)
Ischemia, %	6.8 ± 4.0	
%FMM, %		5.9 ± 4.4

CT, computed tomography; LVEF, left ventricular ejection fraction; FMM, fractional myocardial mass.

MYOCARDIAL TERRITORY ACCORDING TO ANATOMICAL ATTRIBUTES

Among 564 diagonal branches, 86 branches (15.2%) showed %FMM ≥10%. In patients with LCx dominance, the %FMM of total diagonal territory was smaller than in those without LCx dominance (8.9±3.1% vs 12.0±4.5%, $p<0.0001$) (Figure 3). For the total number of diagonal branches, a solitary diagonal branch had the highest %FMM (11.7%±5.1%) (Figure 4). Among the patients with three or more diagonal branches, only 1.2% showed %FMM ≥10% (Table 2). When there were two diagonal branches, the dominant branch had a greater chance of having %FMM ≥10% (Figure 4, Table 2).

DIAGNOSTIC PERFORMANCE OF PREDICTION MODELS BASED ON ANATOMICAL ATTRIBUTES

The models based on logistic regression were built to predict %FMM ≥10% with anatomical attributes of diagonal branches (Table 3). The model with the criterion of size ≥2.5 mm only had excellent negative predictive value. However, its positive predictive value was low (0.40). When the number of branches and dominance (LCx dominance and D1/2 dominance) were added (model 2), specificity and positive predictive value were improved with higher area under the curve (AUC) (0.96 vs 0.87, $p<0.001$). The diagnostic performance of models with and without size criterion (model 2 vs model 3) was not different (AUC 0.96 vs 0.92,$p=0.06$) (Table 3). To facilitate instant decision making at the time of evaluation, a decision tree model was developed to predict %FMM ≥10% (Figure 5). Its diagnostic performance is described in Table 4. The diagnostic performance

was similar, regardless of the vessel sizes assessed by QCA or by visual estimation. (Figure 6, Table 5)

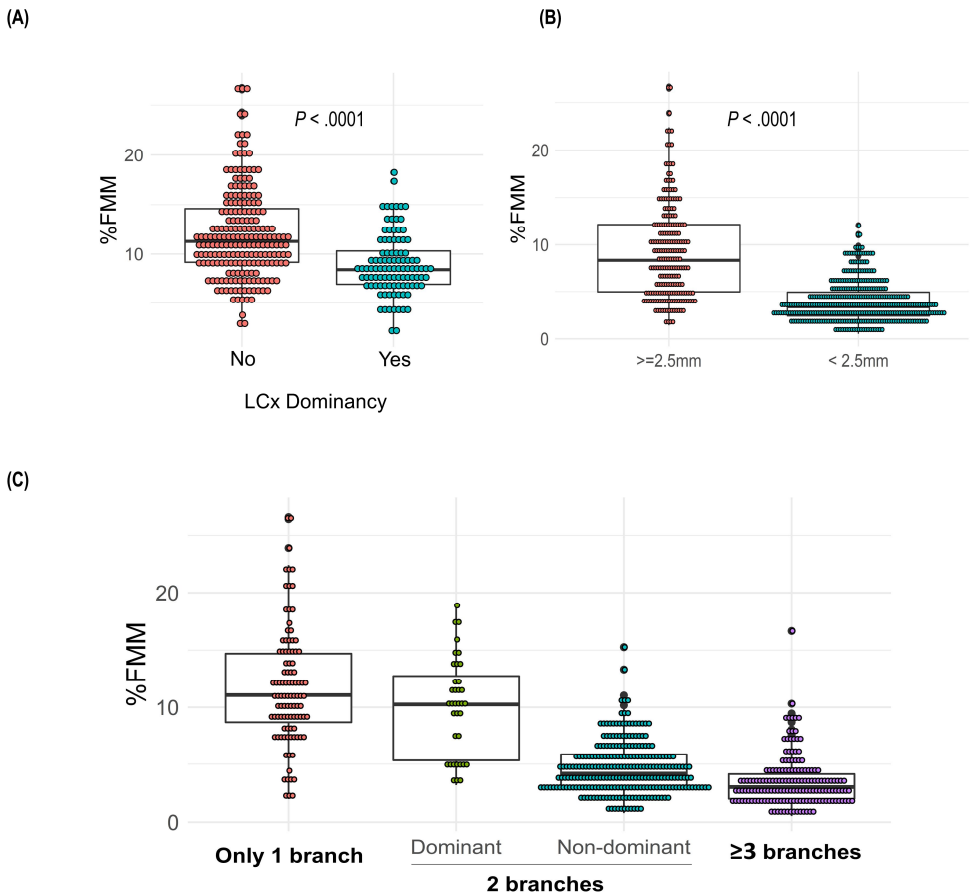

Figure 4. Diagonal branch territory according to dominance of left circumflex artery, vessel size and number of branches. Stacked dot plots represent the distribution of fractional myocardial mass (%FMM) of entire diagonal branches (A) and an individual diagonal branch (B). Branches are categorized into single diagonal branch, dominant and non-dominant branches of the two diagonal branches, and the branch of more than three diagonal branches (C). The overlaid box plot represents the median, first and third quartile of %FMM of the diagonal branch of each group.

Table 2. Angiographic Attribute of Diagonal Branches and %FMM

Attribute	Condition	%FMM < 10%	%FMM ≥ 10%	*P* value
Size	≥ 2.5mm	126 (60.3)	83 (39.7)	<0.0001
	< 2.5mm	352 (99.2)	3 (0.8)	
Number	1 branch	41 (41.0)	59 (59.0)	
	2 branches	273 (91.6)	25 (8.4)	<0.0001
	≥ 3 branches	164 (98.8)	2 (1.2)	
$D_{1/2}$ dominance	Yes	16 (44.4)	20 (55.6)	<0.0001
	No	257 (98.1)	5 (1.9)	
LCx dominance	Yes	166 (93.3)	12 (6.7)	0.0001
	No	312 (80.8)	74 (19.2)	

The numbers in the two subgroups are expressed in n (%). $D_{1/2}$ dominance denotes the presence of a dominant branch in case of 2 diagonal branches.

%FMM, percent fractional myocardial mass; LCx, Left circumflex artery.

Table 3. Diagnostic Performance of Logistic Regression Models for %FMM ≥ 10%.

Model	Parameters	Sp	Sn	NPV	PPV	AUC [95% CI]	Accuracy [95% CI]
Model 1	Size	0.74	1.00	1.00	0.40	0.87 [0.82-0.91]	0.85 [0.78-0.90]
Model 2	Size + Number + $D_{1/2}$ dominance + LCx dominance	0.93	0.94	0.99	0.70	0.96 [0.92-0.99]	0.92 [0.85-0.96]
Model 3	Number + $D_{1/2}$ dominance + LCx dominance	0.86	0.94	0.99	0.55	0.92 [0.87-0.97]	0.91 [0.83-0.95]

$D_{1/2}$ dominance denotes the presence of a dominant branch in case of 2 diagonal branches.

%FMM, percent fractional myocardial mass; Sp, specificity; Sn, sensitivity; NPV, negative predictive value; PPV, positive predictive value; AUC, area under curve; CI, confidence interval; LCx, left circumflex artery.

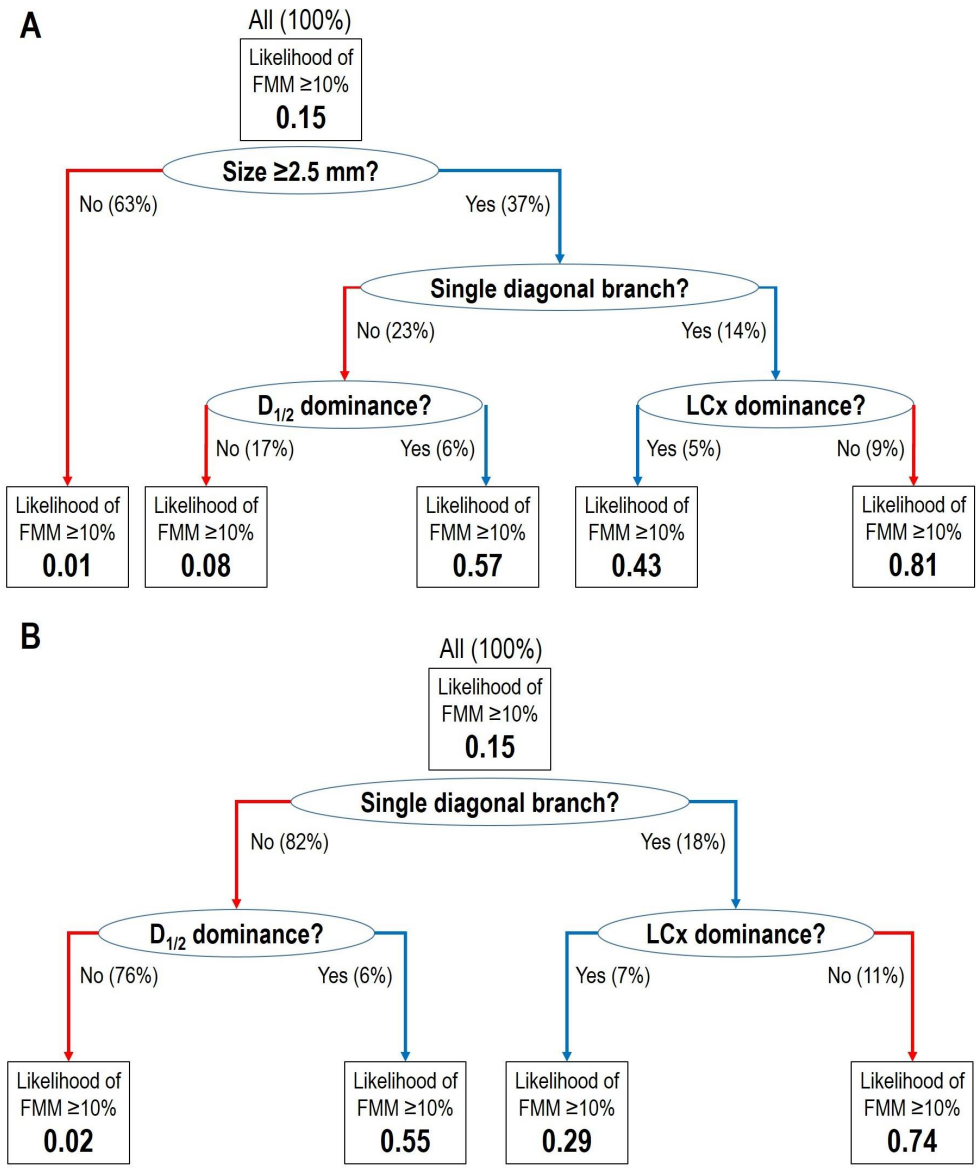

Figure 5. Decision trees to predict the likelihood of %FMM of a diagonal branch ≥10%. Each tree represents a decision algorithm for a case with (A) or without (B) information on the size of a diagonal branch. The top boxes are the root nodes containing the entire branches of the training set (100%). They are partitioned into one of two nodes by specific attribute in the next layer. FMM: fractional myocardial mass

Table 4. Diagnostic Performance of Decision Tree Models for %FMM ≥ 10%.

Parameters	Sp	Sn	NPV	PPV	AUC [95% CI]	Accuracy [95% CI]
Size + Number + $D_{1/2}$ dominance + LCx dominance	0.92	0.82	0.97	0.64	0.87 [0.77-0.97]	0.91 [0.84-0.96]
Number + $D_{1/2}$ dominance + LCx dominance	0.87	0.82	0.97	0.54	0.85 [0.75-0.95]	0.89 [0.82-0.94]

$D_{1/2}$ dominance denotes the presence of a dominant branch in case of 2 diagonal branches.

%FMM, percent fractional myocardial mass; Sp, specificity; Sn, sensitivity; NPV, negative predictive value; PPV, positive predictive value; AUC, area under curve; CI, confidence interval; LCx, left circumflex artery.

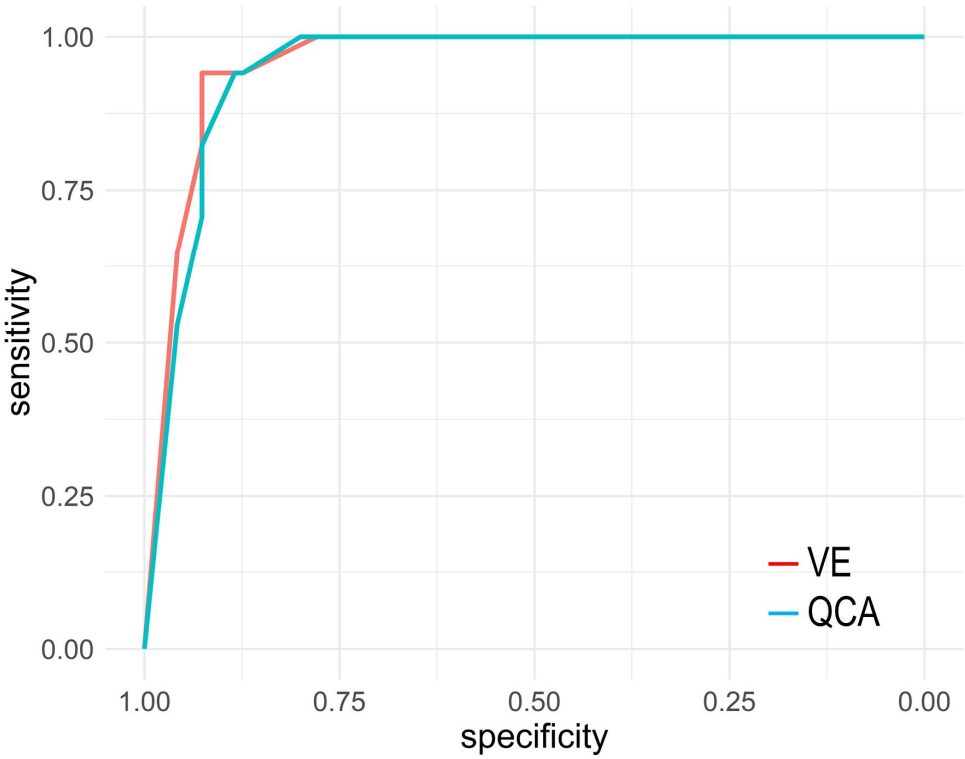

Figure 6. Comparison of diagnostic performance between models with vessel size by visual estimation and quantitative coronary angiography. The receiver operating characteristic (ROC) curves with the size attribute evaluated by visual estimation (VE) and quantitative coronary angiography (QCA) are shown. ROC curve represents the diagnostic performance of a logistic regression model to predict % fractional myocardial mass (%FMM) of a diagonal branch to be ≥10%.

Table 5. Diagnostic Performance of Predictive Models for %FMM ≥ 10%.

Models and Parameters	Sp	Sn	NPV	PPV	AUC [95% CI]	Accuracy [95% CI]
Logistic Regression						
Size (VE)	0.74	1.00	1.00	0.40	0.87 [0.83-0.91]	0.85 [0.78-0.90]
Size (QCA)	0.75	0.88	0.97	0.39	0.82 [0.72-0.91]	0.85 [0.77-0.91]
Size (VE) + Number + $D_{1/2}$ dominance + LCx dominance	0.93	0.94	0.99	0.70	0.96 [0.92-0.99]	0.92 [0.85-0.96]
Size (QCA) + Number + $D_{1/2}$ dominance + LCx dominance	0.88	0.94	0.99	0.59	0.95 [0.91-0.99]	0.89 [0.83-0.94]

Decision Tree						
Size (VE)+ Number + $D_{1/2}$ dominance + LCx dominance	0.92	0.82	0.97	0.64	0.87 [0.77-0.97]	0.91 [0.84-0.96]
Size (QCA) + Number + $D_{1/2}$ dominance + LCx dominance	0.92	0.71	0.92	0.60	0.82 [0.70-0.93]	0.88 [0.85-0.94]

Sp, specificity; Sn, sensitivity; NPV, negative predictive value; PPV, positive predictive value; AUC, area under curve; CI, confidence interval; VE, visual estimation; QCA, quantitative coronary angiography

Chapter 4. Discussion

This study was performed to assess the ischemic burden and myocardial territory of diagonal branches in patients with left anterior descending coronary artery bifurcation lesions using MPI and CCTA, and to develop models with anatomical attributes that can define the clinical relevance of diagonal branches. The major findings of this study were as follows. 1) The ischemic territory of diagonal branches was variable and most diagonal branches did not cause %ischemia >10%. The presence of non-diseased diagonal branches and LCx dominance were the anatomical attributes that determined the ischemic territory. 2) The anatomical attributes of myocardial territory assessed by CCTA were vessel size, number of branches and relative dominance. 3) Combining these anatomical attributes improved the diagnostic performance of a prediction model for clinically relevant diagonal branches compared with the model of vessel size only. 4) Vessel size information did not significantly improve the diagnostic performance of the prediction model. These results suggest that these concepts and prediction models could help clinicians to select the clinically relevant diagonal branches and determine the appropriate treatment strategy for LAD-diagonal bifurcation lesions. (Visual summary was shown in Figure 7)

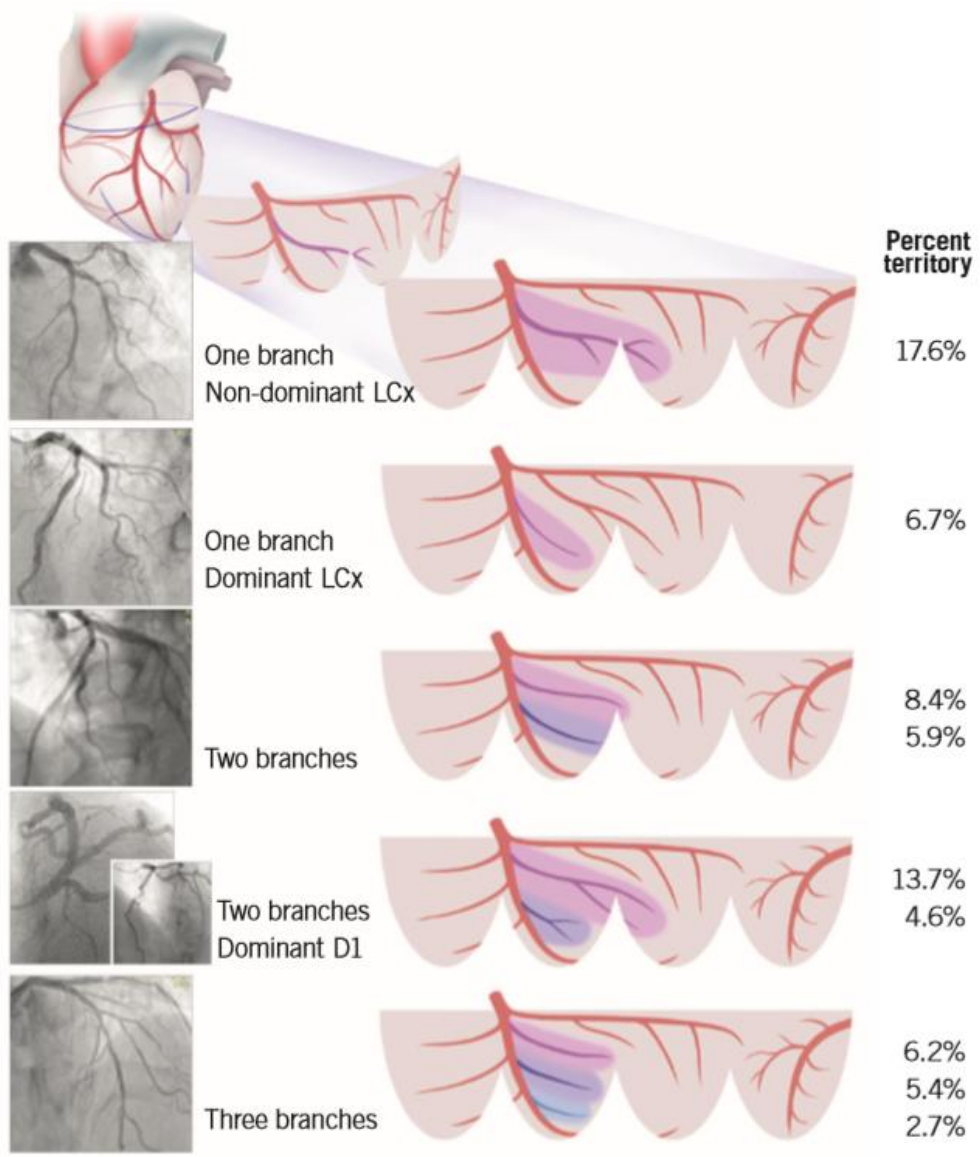

Figure 7. Visual summary. Myocardial territory of a diagonal branch is determined by LCx dominance, number of branches and dominance among branches.

CLINICAL RELEVANCE OF SIDE BRANCHES

The benefit of revascularization is dependent not only on the presence of ischemia but also on its extent. Revascularization for lesions that can cause ischemic burden

>10% of the left ventricle is regarded as having prognostic benefit compared with medical treatment [2, 3]. Compared with the main branches, side branches supply less myocardium and have less clinical and prognostic relevance [5, 8-10]. This can be one of the main reasons why routine side branch stent implantation could not show benefit over the provisional strategy [1], and FFR-guided revascularization for jailed side branches did not improve outcomes compared with angiography-guided intervention [11, 12]. In our study, %ischemia in patients with severe disease in all diagonal branches was only 8.4±3.3%, and 65.5% of them did not have %ischemia ≥10%. Therefore, assessment of the ischemic territory of a side branch should be one of the key steps in the process of selecting the appropriate treatment strategy for coronary bifurcation lesions.

ANATOMICAL DETERMINANTS OF MYOCARDIAL TERRITORY

Myocardial territory of a secondary branch is determined by the entire territory of a primary vessel and the partition of that specific branch among the secondary branches. The LAD generally supplies 40-45% of the left ventricle, and less than half of that territory is supplied by diagonal branches [4, 13, 14]. Diagonal branches mainly supply the anterior wall and part of the anterolateral wall, which is also supplied by branches from the LCx. Therefore, anatomical variations influence the myocardial territory of diagonal branches, and the number and territory of diagonal branches were reported to be smaller in cases with a dominant LCx or large obtuse marginal branch [8]. In this study, we defined LCx dominance as a left-dominant system or presence of an obtuse marginal branch originating within the proximal 1/3 of the LCx and crossing the LAD in a right anterior oblique

caudal view. It was used as one of the anatomical attributes that can influence total diagonal branch territory in anterior and anterolateral walls. Our study results showed that patients with LCx dominance had smaller %ischemia (5.6±3.8% vs 8.4±3.7%, p=0.012) and %FMM (8.9±3.1% vs 12.0±4.5%, p<0.0001) than those without LCx dominance. In addition, the presence of LCx dominance was the most important attribute in predicting the likelihood of %FMM ≥10% in patients with a single diagonal branch. It is natural that each branch's territory decreases according to the number of branches. When the association between the total number of diagonal branches and %FMM of an individual diagonal branch was assessed, the %FMM of a solitary diagonal branch was the highest (11.7±5.1%) followed by the two diagonal branches (5.3±3.1%). Among 166 branches of patients with ≥3 diagonal branches, only two branches showed %FMM ≥10%. In cases of two branches, relative dominance (D1/2 dominance) can determine the territory of that branch. In our study, the dominant branch had a greater %FMM (10.1±4.3% vs 4.6±2.3%) than the non-dominant branch.

CLINICALLY APPLICABLE PREDICTION MODELS

Recent studies showed that CCTA can be used to estimate the relative and absolute amount of myocardial territory of the specific vessel [4, 13-15]. However, these methodologies require ad hoc CCTA analysis and cannot be applied to patients without CCTA. In addition, this estimation can be inaccurate for branches with diffuse and severe disease which are potential targets for revascularization. In previous studies and during daily practice, vessel size has been the most commonly used anatomical attribute in order to estimate the myocardial territory or clinical

importance of a side branch [16, 17]. However, neither vessel size nor disease severity based on angiography had an influence on the outcomes according to the treatment strategy for bifurcation lesions [17, 18]. In addition, the limitations of QCA for bifurcation lesions [19] are well known. Therefore, a simple and practical approach that can incorporate anatomical attributes for the myocardial territory is needed. In our study, the diagnostic performance of predictive models was not different between the models with and without vessel size, and vessel diameter by QCA did not improve the diagnostic performance compared with visual assessment. When the dominance of the LCx and between two diagonals and the number of diagonal branches were used, the accuracy of a logistic regression model and a decision tree was 0.91 and 0.89, respectively. Therefore, these models can be used easily in daily practice regardless of the availability of vessel size data.

Limitations

This study has several limitations. First, the number of cases in the MPI arm was small. In addition, the burden of inducible ischemia assessed by MPI depends not only on vessel territory, but also on other factors such as stenosis severity, presence of non-viable myocardium, or inadequate hyperemia. Second, the clinical importance of side branches becomes greater in patients with left ventricular dysfunction or multivessel disease. Third, ischemic or infarction territory is smaller than myocardial territory at risk and %FMM may be larger than the ischemic territory of that vessel. In addition, it should be recognized that %FMM by CCTA is not an exact measurement but an estimation for the territory supplied by a diagonal branch. Fourth, this study could not include all variables that can be used to define myocardial territory, such as vessel length, lumen area and blood flow. In

this study, we selected simple angiographic attributes that can be used in daily practice from the results of previous studies and scientific reasoning. Finally, the prediction model was trained and validated in two different subgroups in the same study population. External validation could have increased the value of this model.

Conclusions

LCx dominance, number of branches, vessel size, and dominance among diagonal branches determine the myocardial territory of diagonal branches in patients with left anterior descending coronary artery bifurcation lesions. Clinical application of prediction models based on these anatomical attributes can help to determine the clinically relevant diagonal branches in the cardiac catheterization laboratory.

References

1. Lassen JF, Burzotta F, Banning AP, Lefèvre T, Darremont O, Hildick-Smith D, Chieffo A, Pan M, Holm NR, Louvard Y, Stankovic G. Percutaneous coronary intervention for the left main stem and other bifurcation lesions: 12th consensus document from the European Bifurcation Club. EuroIntervention. 2018;13:1540-53.

2. Hachamovitch R, Hayes SW, Friedman JD, Cohen I, Berman DS. Comparison of the short-term survival benefit associated with revascularization compared with medical therapy in patients with no prior coronary artery disease undergoing stress myocardial perfusion single photon emission computed tomography. Circulation. 2003;107:2900-7.

3. Neumann FJ, Sousa-Uva M, Ahlsson A, Alfonso F, Banning AP, Benedetto U, Byrne RA, Collet JP, Falk V, Head SJ, Jüni P, Kastrati A, Koller A, Kristensen SD, Niebauer J, Richter DJ, Seferovic PM, Sibbing D, Stefanini GG, Windecker S, Yadav R, Zembala MO; ESC Scientific Document Group. 2018 ESC/EACTS Guidelines on myocardial revascularization. Eur Heart J. 2019; 40:87-165.

4. Kim HY, Doh JH, Lim HS, Nam CW, Shin ES, Koo BK, Lee JM, Park TK, Yang JH, Song YB, Hahn JY, Choi SH, Gwon HC, Lee SH, Kim SM, Choe Y, Choi JH. Identification of Coronary Artery Side Branch Supplying Myocardial Mass That May Benefit From Revascularization. JACC Cardiovasc Interv. 2017;10:571-81.

5. Koo BK, Lee SP, Lee JH, Park KW, Suh JW, Cho YS, Chung WY, Doh JH, Nam CW, Yu CW, Lee BK, Vassilev D, Gil R, Lim HS, Tahk SJ, Kim HS. Assessment of clinical, electrocardiographic, and physiological relevance of diagonal branch in left anterior descending coronary artery bifurcation lesions. JACC Cardiovasc

Interv. 2012;5:1126-32.

6. Hwang D, Jeon KH, Lee JM, Park J, Kim CH, Tong Y, Zhang J, Bang JI, Suh M, Paeng JC, Na SH, Cheon GJ, Cook CM, Davies JE, Koo BK. Diagnostic Performance of Resting and Hyperemic Invasive Physiological Indices to Define Myocardial Ischemia: Validation With 13N-Ammonia Positron Emission Tomography. JACC Cardiovasc Interv. 2017;10:751-60.

7. Lee JM, Kim CH, Koo BK, Hwang D, Park J, Zhang J, Tong Y, Jeon KH, Bang JI, Suh M, Paeng JC, Cheon GJ, Na SH, Ahn JM, Park SJ, Kim HS. Integrated Myocardial Perfusion Imaging Diagnostics Improve Detection of Functionally Significant Coronary Artery Stenosis by 13N-ammonia Positron Emission Tomography. Circ Cardiovasc Imaging. 2016;9:e004768.

8. Cerci RJ, Arbab-Zadeh A, George RT, Miller JM, Vavere AL, Mehra V, Yoneyama K, Texter J, Foster C, Guo W, Cox C, Brinker J, Di Carli M, Lima JA. Aligning coronary anatomy and myocardial perfusion territories: an algorithm for the CORE320 multicenter study. Circ Cardiovasc Imaging. 2012; 5:587-95.

9. Iskandrian AS, Scherer H, Croll MN, Bemis CE, Segal BL, Kimbiris D, Wallner R. Exercise 201thallium myocardial scans in patients with disease limited to the secondary branches of the left coronary system. Clin Cardiol. 1979; 2:121-5.

10. Pereztol-Valdes O, Candell-Riera J, Oller-Martinez G, Aguade-Bruix S, Castell-Conesa J, Angel J, Soler-Soler J. Localización y cuantificación del área en riesgo mediante tomografía computarizada por emisión de fotones simples de perfusión miocárdica durante la oclusión arterial coronaria. [Localization and quantification of myocardium at risk by myocardial perfusion SPECT during coronary artery occlusion]. [Article in Spanish]. Rev Esp Cardiol. 2004; 57:635-43.

11. Koo BK, Park KW, Kang HJ, Cho YS, Chung WY, Youn TJ, Chae IH, Choi DJ,

Tahk SJ, Oh BH, Park YB, Kim HS. Physiological evaluation of the provisional side-branch intervention strategy for bifurcation lesions using fractional flow reserve. Eur Heart J. 2008;29:726-32.

12. Chen SL, Ye F, Zhang JJ, Xu T, Tian NL, Liu ZZ, Lin S, Shan SJ, Ge Z, You W, Liu YQ, Qian XS, Li F, Yang S, Kwan TW, Xu B, Stone GW. Randomized Comparison of FFR-Guided and Angiography-Guided Provisional Stenting of True Coronary Bifurcation Lesions: The DKCRUSH-VI Trial (Double Kissing Crush Versus Provisional Stenting Technique for Treatment of Coronary Bifurcation Lesions VI). JACC Cardiovasc Interv. 2015;8:536-46.

13. Sumitsuji S, Ide S, Siegrist PT, Salah Y, Yokoi K, Yoshida M, Awata M, Yamasaki K, Tachibana K, Kaneda H, Nanto S, Sakata Y. Reproducibility and clinical potential of myocardial mass at risk calculated by a novel software utilizing cardiac computed tomography information. Cardiovasc Interv Ther. 2016;31:218-25.

14. Kang SJ, Kim YH, Lee JG, Kang DY, Lee PH, Ahn JM, Park DW, Lee SW, Lee CW, Park SW, Park SJ, Koo HJ, Yun SC, Jung J, Kim N, Kweon J, Kang JW, Lim TH, Yang DH. Impact of Subtended Myocardial Mass Assessed by Coronary Computed Tomographic Angiography-Based Myocardial Segmentation. Am J Cardiol. 2019;123:757-63.

15. Ide S, Sumitsuji S, Yamaguchi O, Sakata Y. Cardiac computed tomography derived myocardial mass at risk using the Voronoi-based segmentation algorithm: A histological validation study. J Cardiovasc Comput Tomogr. 2017; 11:179-82.

16. Kassab GS, Bhatt DL, Lefèvre T, Louvard Y. Relation of angiographic side branch calibre to myocardial mass: a proof of concept myocardial infarct index. EuroIntervention. 2013;8:1461-3.

17. Hildick-Smith D, Behan MW, Lassen JF, Chieffo A, Lefèvre T, Stankovic G, Burzotta F, Pan M, Ferenc M, Bennett L, Hovasse T, Spence MJ, Oldroyd K, Brunel P, Carrie D, Baumbach A, Maeng M, Skipper N, Louvard Y. The EBC TWO Study (European Bifurcation Coronary TWO): A Randomized Comparison of Provisional T-Stenting Versus a Systematic 2 Stent Culotte Strategy in Large Caliber True Bifurcations. Circ Cardiovasc Interv. 2016; 9:e003643.

18. Behan MW, Holm NR, Curzen NP, Erglis A, Stables RH, de Belder AJ, Niemelä M, Cooter N, Chew DP, Steigen TK, Oldroyd KG, Jensen JS, Lassen JF, Thuesen L, Hildick-Smith D. Simple or complex stenting for bifurcation coronary lesions: a patient-level pooled-analysis of the Nordic Bifurcation Study and the British Bifurcation Coronary Study. Circ Cardiovasc Interv. 2011;4:57-64.

19. Shin DH, Koo BK, Waseda K, Park KW, Kim HS, Corral M, Lansky A, Honda Y, Fearon WF, Fitzgerald PJ. Discrepancy in the assessment of jailed side branch lesions by visual estimation and quantitative coronary angiographic analysis: comparison with fractional flow reserve. Catheter Cardiovasc Interv. 2011;78:720-6.

초 록

서론: 관상동맥 분지병변은 해부학적, 생리학적으로 복잡하고 독특한 특성을 지닌다. 기존 연구들에서 2-스텐트 치료가 잠정적 스텐트 치료에 비해 우월성을 보여주지 못하였다. 그러므로 분지병변의 치료전략을 결정할 때, 어느 분지를 치료할지 결정하는 것이 중요하다. 이 연구는 대각분지의 심근영역을 결정하는 해부학적 속성을 확인하고 심근관류영상과 관상동맥 조영 시티를 이용하여 임상적으로 중요한 분지 혈관을 예측하는 모델을 만들기 위해 시행되었다.

방법: 대각분지에서 심근허혈이 발생하는 영역과 그에 대응하는 심근질량의 크기를 심근관류영상을 통해 심근허혈분율(%ischemia), 그리고 관상동맥 조영 시티를 통해 심근질량분획분율(%FMM)으로 각각 계산하였다.

결과: 대각분지에만 병변을 가진 49명의 환자에서 평균 심근허혈분율은 6.8±4.0%였고, 모든 대각분지에 완전폐색 또는 중도의 병변이 있는 환자에서의 평균 심근허혈분율은 8.4±3.3%였다. 심근허혈분율 값은 병변이 없는 다른 대각분지와 우세자회선동맥이 있으면 유의하게 작았다. 관상동맥 조영시티 코호트(총 306명, 564개의 대각분지)에서 평균 심근질량분획분율은 5.9±4.4%였고 86개의 대각분지(15.2%)가 10% 이상의 심근질량분획분율을 보였다. 심근질량분획분율은 좌회선동맥 우세, 대각분지 개수, 혈관 직경(≥2.5mm), 대각분지가 두 개인 경우 상대적 우세 여부에 따라 달라졌다. 10% 이상의 심근질량분획분율을 예측하는 모델의 진단 정확도는 로지스틱 회귀에서는 0.92(95% 신뢰구간: 0.85-0.96)였고 의사결정트리에서는 0.91(95% 신뢰구간: 0.84-0.96)이었다. 혈관 직경의 기준 포함여부에 따른 각 모델의 진단 능력 차이는 없었다.

결론: 좌회선동맥 우세, 대각분지 개수, 혈관 직경, 그리고 대각분지들 사이의 상대적 우세 여부가 대각분지의 심근영역을 결정하였다. 이

해부학적 속성에 따른 예측 모델의 임상 적용은 심혈관조영실에서 임상적으로 중요한 대각분지를 결정하는데에 도움이 될 것이다.

주요어 : 분지, 대각분지, 심근허혈 부하, 심근질량분획, 위험 층화
학 번 : 2015-21973