수의학석사 학위논문

Comparison of the Measurement of the Iridocorneal Angle Using Ultrasound Biomicroscopy, Gonioscopy, and Spectral Domain Optical Coherence Tomography in Dogs

개에서 홍채각막각 측정에 대한 초음파생체현미경, 우각경 및 빛간섭단층촬영장치의 비교

2022 년 2 월

서울대학교 대학원

수의학과 임상수의학과

김 수 안

수의학석사 학위논문

Comparison of the Measurement of the Iridocorneal Angle Using Ultrasound Biomicroscopy, Gonioscopy, and Spectral Domain Optical Coherence Tomography in Dogs

개에서 홍채각막각 측정에 대한 초음파생체현미경, 우각경 및 빛간섭단층촬영장치의 비교

2022 년 2 월

서울대학교 대학원

수의학과 임상수의학과

김 수 안

Comparison of the Measurement of the Iridocorneal Angle Using Ultrasound Biomicroscopy, Gonioscopy, and Spectral Domain Optical Coherence Tomography in Dogs

개에서 홍채각막각 측정에 대한 초음파생체현미경,
우각경 및 빛간섭단층촬영장치의 비교

지도교수 서 강 문

이 논문을 수의학 석사 학위논문으로 제출함
2021년 10월

서울대학교 대학원
수의학과 임상수의학 전공
김 수 안

김수안의 석사 학위논문을 인준함
2022년 1월

위 원 장 _____ (인)
부 위 원 장 _____ (인)
위 원 _____ (인)

Abstract

Comparison of the Measurement of the Iridocorneal Angle using Ultrasound Biomicroscopy, Gonioscopy, and Spectral Domain Optical Coherence Tomography in Dogs

Su An Kim
Veterinary Clinical Sciences Major
Graduate School of Veterinary Medicine
Seoul National University

This study aimed to compare the iridocorneal angle (ICA) measurements of ultrasound biomicroscopy (UBM), spectral domain optical coherence tomography (SD-OCT), and gonioscopy and to demonstrate the inter-device agreement among the three methods to consider the diagnostic value of SD-OCT in the early detection of narrowing ICA.

A total of 29 eyes from 29 client-owned dogs with normal intraocular pressure (IOP) were scanned at the limbus using SD-OCT, UBM, and gonioscopy. ICA and angle opening distance (AOD) were measured from the obtained images of SD-OCT and UBM, and gonioscopy images were analyzed using the ICA grade and ZibWest angle index.

The mean ICA and AOD for SD-OCT and UBM were 28.87 ± 5.78º and 656.94 ± 201.37 μm and 29.00 ± 6.38º and 849.79 ± 257.12 μm, respectively. The mean difference in ICA between SD-OCT and UBM was 0.13º with a 95% limit of agreement (LoA) span of 15.1º, which showed positive agreement, whereas the mean difference in AOD between SD-OCT and UBM was 192.85 μm with a 95% LoA span of 912.21 μm, which showed negative agreement. The Pearson correlation

coefficient of the ICA of SD-OCT and ZibWest indices of gonioscopy was 0.574, indicating strong agreement, and the Pearson correlation coefficient of the UBM and gonioscopy was 0.43, indicating moderate agreement.

The inter-device agreements for ICA measurement of SD-OCT, UBM, and gonioscopy were good, such that SD-OCT could be considered an alternative option to screen the narrowing of the filtration angle in clinical settings due to its many benefits, such as the non-contact method and easy handling. Early detection of ICA narrowing may provide information on patients who need early therapeutic interventions.

Keywords: iridocorneal angle, spectral domain optical coherence tomography, gonioscopy, ultrasound biomicroscopy, glaucoma, dog

Student Number: 2020-28445

Table of Contents

Introduction

Gonioscopy is the gold standard for evaluating the iridocorneal angle (ICA) in both humans and animals (Park *et al*., 2011). It enables direct observation of the pectinate ligaments and visualization of the uveal trabecular region positioned caudally. Therefore, it is the most accurate diagnostic method for the anterior ciliary cleft. It also provides information on the presence of pectinate ligament abnormality (PLA) or the extent of pigmentation, which may go undetected with other examinations.

Other adjuvant methods, such as high-resolution ultrasound or ultrasound biomicroscopy (UBM), are required for further evaluation of the entire ciliary cleft. UBM is routinely used in clinical setting, where the most commonly used 50 MHz models have an axial resolution of 30 μm (Silverman, 2009). It provides broader information about the anterior ocular segment, such as the cornea, iris, anterior chamber depth, and ciliary cleft width.

Optical coherence tomography (OCT) is based on low-coherence interferometry that uses light rays close to infrared light to visualize intraocular structures. Its biggest advantage is the non-contact method, which can scan high-resolution images that are less than 10 μm (Leung *et al*., 2005). Moreover, the anterior chamber angle parameters can be quantified, allowing a more objective evaluation.

To the best of our knowledge, although several studies have analyzed the agreement of OCT with UBM or gonioscopy in humans (Dada *et al.,* 2007; Park *et al*., 2011; Porporato *et al*., 2020; Radhakrishnan *et al*., 2005; Rigi *et al*., 2016; Sakata *et al*., 2008; Tay *et al*., 2015) or rabbits (Li Puma *et al*., 2019), comparison of the ICA measurement of all three devices has not been reported in dogs. To better understand

the pathophysiology of aqueous humor outflow in canine glaucoma, it is important to visualize the outflow pathway using different methods and establish a comparative analysis of the angle parameters for normal eyes in various breeds. Therefore, this study aimed to demonstrate the inter-device agreement between gonioscopy, UBM, and SD-OCT and to consider the diagnostic value of SD-OCT in the early detection of narrowing ICAs.

Materials and Methods

1. Animals

Twenty-nine eyes of 29 client-owned dogs, that were appointed for ophthalmic recheck at the Veterinary Medical Teaching Hospital of Seoul National University, were investigated. All examinations were performed with the owners' consent. The criteria for selection of the study eyes were as follows: the opposite eyes of patients having a history of glaucoma or eyes suspected to be predisposed to primary glaucoma, such as those with congenital goniodysgenesis, or normal eyes. Routine ophthalmic examinations, including neuro-ophthalmic examinations, rebound tonometry (TONOVET®; Finland Oy, Helsinki, Finland), and slit-lamp biomicroscopy (SL-D7; Topcon Corp., Tokyo, Japan), were performed before scanning the anterior chamber of each dog. The exclusion criteria were as follows: corneal ulcer, severe corneal edema or pigmentation, peripheral anterior or posterior synechia, lens luxation, retinal detachment, or any recent ophthalmic surgery. The guidelines of the Institutional Animal Care and Use Committee of Seoul National University (SNU-211007-4) were followed for all procedures and animal care.

2. Imaging procedures

The anterior ocular chamber was examined using SD-OCT (iVue® 100; Optovue Inc., Fremont, CA, USA) and UBM (MD-320W; MEDA Co., Ltd., Tianjin, China). The opening of the ICA, including the pectinate ligaments, was examined using gonioscopy images (Genesis-D; Kowa, South Vermont, USA, Pan Retinal® 2.2; Volk, USA). Gonioscopy, UBM, and SD-OCT examinations were performed in the dark to minimize the effects of light. Measurements of all devices were performed consecutively. Neither sedatives nor systemic anesthetics were used for any of the procedures.

1) Spectral domain-optical coherence tomography

SD-OCT was set to a light source of 830-nm wavelength, a scan speed of 26,000 axial scans per second, a transverse resolution of 15 μm and an axial resolution of 5 μm (Ramos *et al*., 2009). The corneal adaptor module (cornea anterior module-low magnification) was used to visualize the anterior segment (Ramos *et al*., 2009), and an angle scan mode was set up to acquire the ICA images. The dogs were seated facing forward, and the head was slightly manipulated by the assistant so that the superior, inferior, nasal, and temporal limbus were well exposed each time to acquire ICA images of the respective quadrants. The scans were performed repetitively until the clearest images were obtained for each quadrant, with well-defined anatomical landmarks (sclerocorneal junction, iris, posterior cornea) and the least motion artifacts (Park *et al*., 2015).

2) Ultrasound biomicroscopy

UBM was performed in the superior to the temporal quadrants. Since it required a hand-held 50-mHz transducer that was linked to an eyecup, filled with distilled

water that came in contact with the ocular surface, examination of the other quadrants was difficult. One drop of 0.5% proparacaine hydrochloride (Alcaine®; Alcon, Fort Worth, Texas, USA) was instilled to the eye for examination. The upper eyelid was held open to expose the dorsal and temporal limbus, and the ultrasonic probe was placed perpendicular to the limbus. Minor pressure was applied in this process to avoid global distortion. The scans were repeated until a number of images with clear anatomical landmarks, including the corneoscleral limbus, iris, ICA, and anterior lens capsule, were acquired for both the dorsal and temporal views.

3) Gonioscopy

Gonioscopy was performed by manually opening the eyelids in a similar manner as during the UBM scanning, and the goniolens were placed along different locations so that the ICA openings of most of the angle were visualized. In other words, the scans were performed along the entire circumference, and at least three clear images obtained from different views were selected for analysis.

3. Image analyses

1) Iridocorneal angle parameters of ultrasound biomicroscopy (UBM) and spectral domain optical coherence tomography (SD-OCT)

The ICA and angle opening distance (AOD) of the UBM and SD-OCT images were evaluated. The ICA was measured as the angle between two lines that converged on the angle recess, one line extending from the posterior limbus, and the other extending from the plane of the peripheral iris root (Dulaurent *et al*., 2012; Park *et al*., 2015). The AOD was measured as the perpendicular distance (μm) between the posterior cornea at the corneoscleral junction and the iris surface. An external image processing software (ImageJ, NIH, Bethesda, MD) was used to measure these two parameters of the exported images acquired from SD-OCT and UBM (Fig. 1), to compare more accurately by eliminating the bias between the built-in software of the devices.

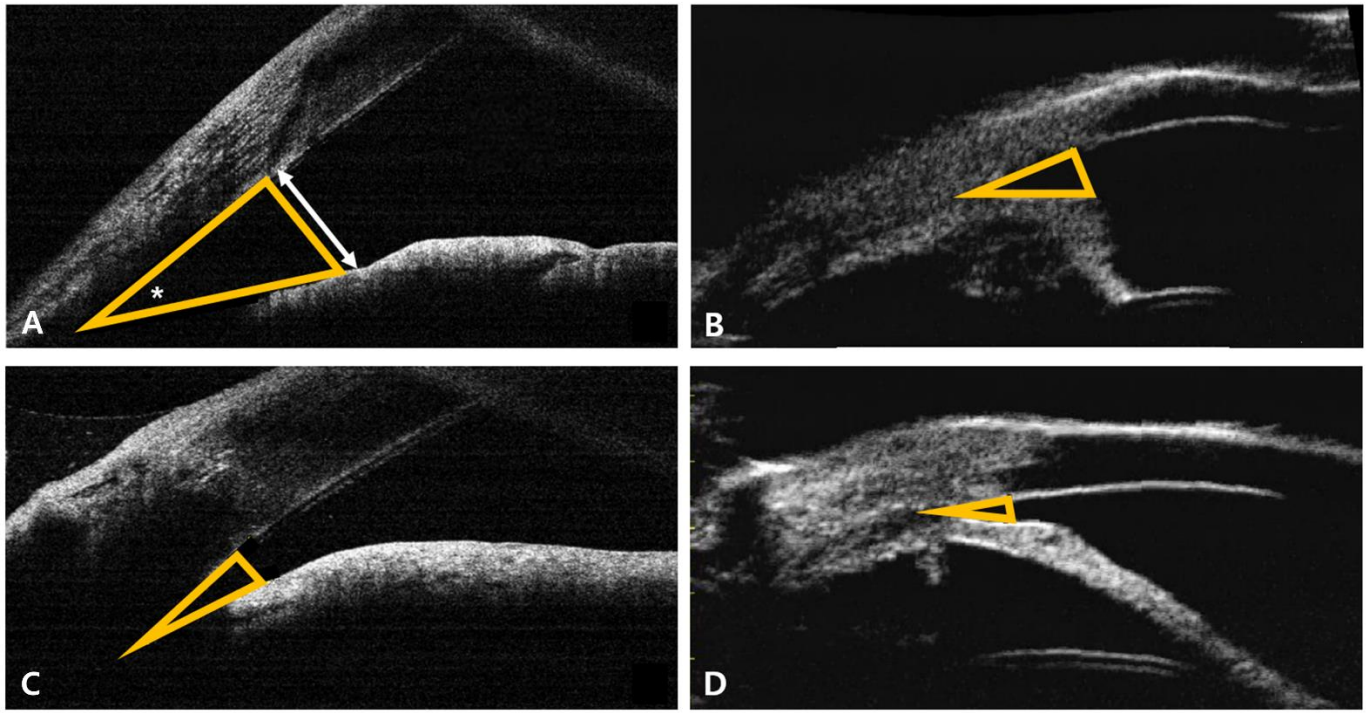

Fig. 1. Images of the iridocorneal angle of two dogs, scanned by spectral domain optical coherence tomography (SD-OCT) and ultrasound biomicroscopy (UBM). (A) The iridocorneal angle (ICA) and angle opening distance (AOD) parameters were measured using the ImageJ program. The (*) indicates the ICA and the double-headed arrow indicates the AOD. (A, B) SD-OCT and UBM images of an eye with open ICA. (C, D) SD-OCT and UBM images of an eye with narrow ICA. This dog had a history of glaucoma in the contralateral eye.

2) Gonioscopy

The gonioscopy images were analyzed using an external graphic software (Adobe Illustrator: Graphic Art, Adobe Inc., US). The ICA grades were analyzed according to previous studies (Dubin *et al*., 2017; Ekesten and Narfstrom, 1991; Miller and Bentley, 2015; Zibura *et al*., 2021), where the ratio of the width of the anterior opening of the ciliary cleft to the width from the origin of the pectinate ligaments to the posterior cornea was categorized into 5 grades: Grade 0, if the ratio was smaller than 0.15; grade 1, if the ratio was 0.15 − 0.30; grade 2, if the ratio was 0.30 − 0.45; grade 3, if the ratio was 0.45 − 0.55; and grade 4, if the ratio was larger than 0.55 (Zibura *et al*., 2021). The gonioscopic ICA parameters were further evaluated using the ZibWest index. Factors related to the degree of PLA, such as normal, fibrae latae, lamina, and occlusion, were assigned scores of 1.0, 0.75, 0.5, and 0.25, respectively (Zibura *et al*., 2021). The length of each factor was multiplied by their assigned scores, and the sum was divided by the total examined length, which was multiplied by the formerly calculated ICA grade (Zibura *et al*., 2021) (Fig. 2).

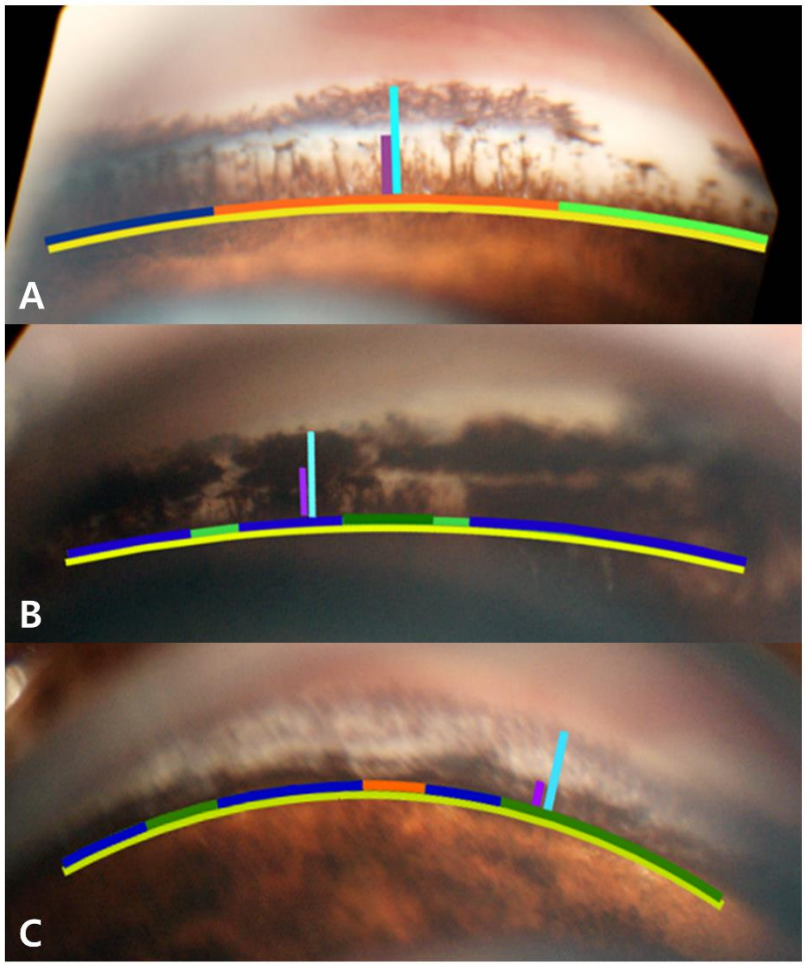

Fig. 2. Analysis of the filtration angles and the pectinate ligaments of three different dogs using the gonioscopic ZibWest index. The yellow line presents the portion of the iridocorneal angle (ICA) under analysis, the purple line presents the width of the area of pectinate ligaments, the sky blue line presents the distance from the origin of pectinate ligaments to the posterior cornea. The light green (normal), orange (fibrae latae), dark green (lamina), and blue (occlusion) lines express the extent of pectinate ligament abnormality. (A) An open ICA of grade 4 and ZibWest index of 2.841. (B) An open but highly pigmented ICA of grade 4 and ZibWest index of 1.514. (C) A narrow ICA of grade 2 and ZibWest index of 0.773.

4. Statistical analyses

The anterior chamber measurements (ICA and AOD) obtained using SD-OCT and UBM were expressed as the mean ± standard deviation (SD). Inter-device agreements of these measurements were assessed using the Bland–Altman plot by evaluating the mean differences and limit of agreement (LoA). LoA was calculated as the mean difference ± 1.96 SD (Doğan, 2018).

The ICA measurements made by SD-OCT, UBM, and gonioscopy were first tested using the Shapiro−Wilk test to confirm that their statistical distribution followed a normal distribution. The inter-device agreements of gonioscopy with UBM and SD-OCT were assessed using Pearson correlation analysis. The degree of correlation was evaluated as follows: high if the coefficient value lied between 0.5 and 1.0, moderate if the value lied between 0.30 and 0.49, and low if the value lied below 0.29 (Boslaugh and Watters, 2008). Statistical analyses were performed using the Statistical Package for the Social Sciences (SPSS) version 25 (SPSS Inc., Chicago, IL, USA). *P* value less than 0.05 was considered statistically significant.

Results

1. Animals

A total of 29 eyes of 29 client-owned dogs, of which 14 were male and 15 were female, were examined in this study. The mean age was 8.86 (range, 2 - 14) years. Ten dog breeds were included in the study population: 12 Shih Tzus, five Malteses, three Miniature Poodles, two Bichon Frises, two Cocker Spaniels, and one dog each of the following breeds: Cavalier King Charles Spaniel, Pomeranian, Boston Terrier, French Bulldog, and Chihuahua. All examined eyes were normotensive on rebound tonometry (Tonovet®; Icare Finland Oy, Helsinki, Finland). Of the 29 dogs, 18 (eight Shih Tzus, four Malteses, two Miniature Poodles, two Cocker Spaniels, one Boston Terrier, and one French Bulldog) had a history of glaucoma in the opposite eye. Prophylactic topical 0.5% betaxolol hydrochloride (Betoptic®; Alcon, Texas, US) or dorzolamide hydrochloride (Trusopt®; Santen Pharmaceutical, Co., LTD. Japan) was administered to the examined eye for varying durations. The remaining ten dogs had normal eyes without any history of glaucoma.

2. Agreement between SD-OCT and UBM

The mean ICA measurements were 28.87 ± 5.78º for SD-OCT (range, 18.51º − 38.92º) and 29.00 ± 6.38º for UBM (range, 18.68º − 40.77º), and the mean difference of ICA values between SD-OCT and UBM was -0.13º. The 95% LoA was -7.7º to 7.4º (Fig. 3A). This LoA span was sufficiently narrow for ICA to be considered a good agreement.

The mean AOD measurements were 656.94 ± 201.37 μm for SD-OCT (range, 295.01 − 1092.25 μm) and 849.79 ± 257.12 μm for UBM (range, 318.22 − 1780.14 μm), and the mean difference between the two devices was -192.85 μm. The 95% LoA span was -648.95 − 263.26 μm (Fig. 3B). The LoA span for AOD was interpreted as a poor agreement.

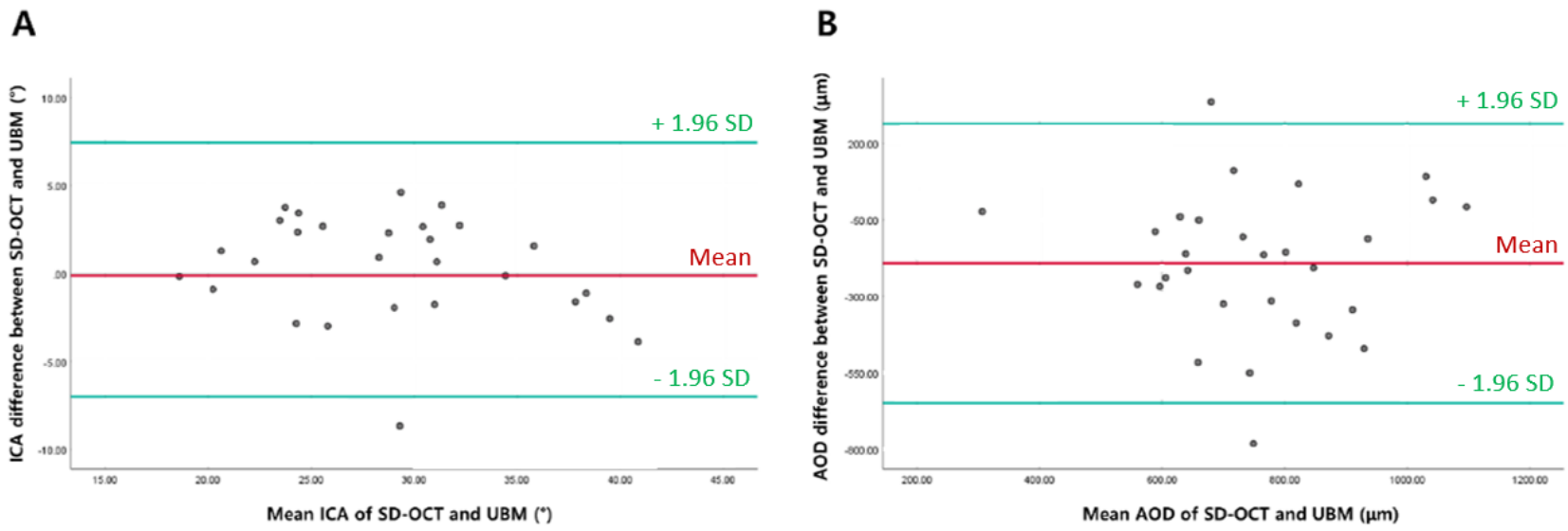

Fig. 3. Bland−Altman plots for the iridocorneal angle (ICA) and angle opening distance (AOD) measured by spectral domain optical coherence tomography (SD-OCT) and ultrasound biomicroscopy (UBM). The red lines indicate the mean difference, and the upper and lower green lines express the range of 95% limit of agreement (LoA). (A) The ICA shows an LoA span of 15.1º, with 3.45% (1/29) of the measurements out of the limits. (B) The AOD shows an LoA span of 912.21 µm, with 6.9% (2/29) of the measurements out of the limits.

3. Agreement between SD-OCT and gonioscopy

The ICA measurements of SD-OCT and the ZibWest scores acquired from gonioscopy examinations both followed a normal distribution according to the Shapiro−Wilk test. The Pearson correlation coefficient for the two measurements was 0.574. Since a Pearson correlation coefficient of 0.5 − 1.0 is considered a high degree of association (Boslaugh and Watters, 2008), the two parameters showed a strong agreement, and this result was statistically significant ($P = 0.001$, Fig. 4).

4. Agreement between UBM and gonioscopy

The ICA measurements of UBM also followed a normal distribution according to the Shapiro−Wilk test. The Pearson correlation coefficient of the ICA of UBM and the gonioscopic score was 0.43. Since a Pearson correlation coefficient of 0.30 − 0.49 is evaluated as moderate correlation (Boslaugh and Watters, 2008), the UBM and gonioscopic parameters showed a medium agreement, and this result was statistically significant ($P = 0.02$, Fig. 5).

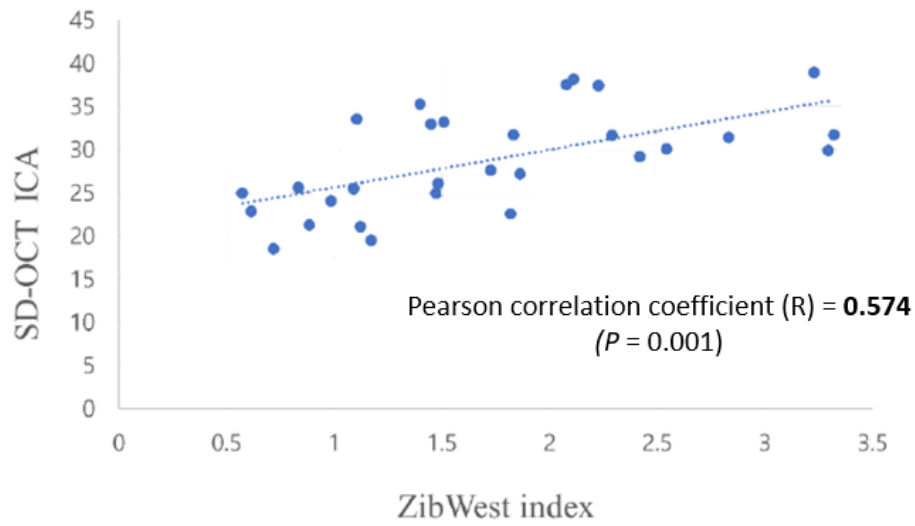

Fig. 4. The correlation between the ZibWest angle indices analyzed by gonioscopy and the iridocorneal angle measurements by spectral domain optical coherence tomography shows a positive linear relationship. Pearson correlation (R) was used for bivariant correlation analyses between the two parameters. *P* value less than 0.05 was considered to indicate statistical significance.

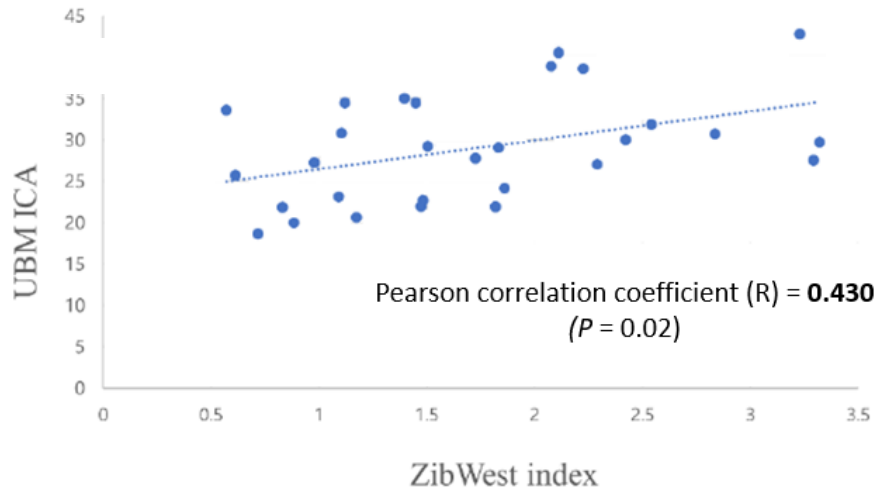

Fig. 5. The angle indices analyzed by gonioscopy and the iridocorneal angle measurements analyzed by ultrasound biomicroscopy show a positive linear relationship. Pearson correlation (R) was used for bivariant correlation analyses between the two parameters. *P* value less than 0.05 was considered to indicate statistical significance.

Discussion

This study found a significant correlation between the gonioscopic ZibWest angle indices and ICA calculated using SD-OCT and UBM. Many studies in humans have compared measurements of anterior chamber parameters using OCT, UBM, and gonioscopy (Dastiridou *et al*., 2015; Park *et al.*, 2011; Porporato *et al*., 2020; Qin *et al*., 2013; Radhakrishnan *et al.*, 2005; Ramos *et al*., 2009; Rigi *et al*., 2016; Sakata *et al*., 2008; Tay *et al*., 2015). There have been varying conclusions on the agreement of the three diagnostics; however, there is a consensus that OCT and gonioscopy cannot be used interchangeably because of the reference of different anatomical landmarks and the visualization of discrete parts of the ciliary cleft. Similar to humans, gonioscopy is considered the gold standard for evaluating the outflow of aqueous humor in small animals. In dogs, there has been a study comparing gonioscopy and UBM (Gibson *et al*., 1998), but there has not been a study comparing the degree of opening of the ICA measured by SD-OCT and gonioscopy. In this study, the ZibWest angle index was used to evaluate the relationship with the ICA measured by SD-OCT. This gonioscopy ICA morphology quantification scheme was used because of its inclusion of the extent of PLA (Zibura *et al*., 2021). Sensitive perception of minute changes in the outflow pathway anatomy is important for monitoring the progression of glaucoma. Therefore, this angle index may be helpful, as it implies not only the angle width or the presence of PLA but also its severity. This method also provides a continuous scale, different from former schemes that only classify the opening of the ICA into limited classes (Dubin *et al*., 2017).

In the present study, all images acquired using SD-OCT and UBM were well visualized. In previous studies, scans were usually focused on the temporal quadrant because of its relatively easy exposure minimization of manipulation of the eyelids (Dastiridou *et al*., 2015; Leung *et al*., 2008; Ma *et al*., 2016). However, in this study, it was important to gain scans of other quadrants as well, as the comparison with scans of gonioscopy, of which most of them visualized the iridocorneal opening of the majority of the circumference, was planned. Therefore, the average value of the angle parameter measurements for each quadrant was used in this study.

According to previous studies in humans, the evaluation of the agreement of AOD between various types of OCT using Bland－Altman plots and their LoA span showed poor to moderate agreement (Akil *et al*., 2017; Leung *et al*., 2008). For the evaluation of ICA using Bland－Altman plots or the Pearson correlation coefficient, OCT devices and UBM displayed good inter-device agreement (Dada *et al*.; 2007, Ma *et al*.; 2016). In this study, the 95% LoA span of AOD between SD-OCT and UBM was 912.21 μm, which was greater than the 0.53 mm, indicating poor agreement (Leung *et al*., 2008; Li Puma *et al*., 2019). In contrast, the 95% LoA span of the ICA between the two devices was 15.1º, which was narrower than that of a previous study that concluded good inter-device agreement with an LoA span of 18.5º (Ma *et al*., 2016). Therefore, the ICA measurements of SD-OCT and UBM showed good agreement.

The ICA grades of the participant dogs in this study were classified as grade 4, which could also be inferred from their normotensive IOP. Meanwhile, the mean ± SD of the ICA measured by SD-OCT was 29.00 ± 5.72º, which was significantly

narrower than the mean angle (42 ± 4°) of normal beagle dogs examined in a previous study using anterior segment OCT (Almazan *et al*., 2013). This may be due to the fact that the candidates for this study included dogs predisposed to developing glaucoma, as assumed by their morbidity history. In addition to the fact that the SD-OCT ICA values showed good agreement with the gonioscopic ZibWest indices, SD-OCT can serve as a helpful screening tool for diagnosing early glaucoma or distinguishing dogs that are likely to be affected by the disease.

In this study, nine dogs had ICA narrower than 25º on SD-OCT examinations. According to their gonioscopic ICA grade analyses, four, four, and one dogs had ICA grades 3, 2, and 1, respectively. Considering that there were a total of six dogs with ICA grade 3, five dogs with ICA grade 2, and one dog with ICA grade 1 in this study, the gonioscopic ICA grade itself can be considered a substantive predictive factor for the extent of opening of the ICA. In contrast, among the 11 dogs with severe PLA, four and seven had ICA grades 3 and 4, respectively. Three dogs with ICA grade 3 had narrow angles on SD-OCT, but the rest displayed wide open angles. Therefore, PLA observed on gonioscopy does not seem to affect the opening of the ciliary cleft as much as the ICA grade itself. This agrees with the previous understanding that unless there is extreme dysplasia of the pectinate ligaments, the resistance of the aqueous humor outflow does not seem to be sufficient (Plummer *et al*., 2021). This also corresponds to certain breeds where extensive PLA is commonly observed. Therefore, we can assume that the ICA grade should be taken into account more significantly than the morphology of the pectinate ligaments, such as occlusions or laminas in gonioscopy examination, when determining the potential risk of IOP elevation.

Primary angle closure glaucoma is the most common type of primary glaucoma in dogs, but there is still no definitive explanation for its pathogenesis (Plummer *et al*., 2021). Primary open angle glaucoma is known to involve tissue degeneration in the initially open filtration apparatus, but there is progressive closure of the angle with time. Not only does the outflow pathway require glaucoma for its narrowing, but aging can change the composition of the trabecular meshwork or reduce the zonular tension and eventually affect the outflow pathways (Plummer *et al*., 2021). For early diagnosis and prophylactic treatment of the predisposed eye, adopting SD-OCT as a screening device for the ICA may be necessary. As proven in this study, the ICA measurements between the UBM, gonioscopy, and SD-OCT were good; thus, the latter can be utilized as the diagnostic method of choice. SD-OCT also has the advantage of being a non-contact method, in that it is free of inflicting gravity or pressure on the globe that may affect the angle structures, which is especially useful when dealing with animal patients who may be uncooperative owing to discomfort. Moreover, SD-OCT can complement gonioscopy by differentiating a temporary appositional angle closure with genuine synechial closure (Plummer *et al.*, 2021).

The present study has some limitations. First, accidental indentation from gonioscopy may have affected the drainage angle, and the constriction of the pupils due to the illumination during the examination. Second, intraobserver and interobserver agreements were not evaluated in this study. However, good repeatability and reproducibility of OCT have been demonstrated in a previous study (Li *et al*., 2007), and gonioscopy in this study was performed by a single experienced ophthalmologist to minimize these errors. Another limitation was that the participants of this study were all normotensive patients; hence, the comparison of

the devices on glaucomatous patients could not be evaluated. Finally, the visualization of the entire ciliary cleft is not available on SD-OCT, different from UBM; thus, additional comparisons of important outflow structures other than the filtration angle itself could not be performed in this study. Narrow ICA allows the estimation of decreased perfusion at the proximal pathway and interference with the aqueous outflow, but it does not reflect the presence of impediment on the distal architectures. Therefore, further advancements in OCT to visualize the ciliary cleft are necessary.

Conclusion

Inter-device agreements for ICA were good between UBM and SD-OCT, and ICA measurements showed significant correlations between SD-OCT and gonioscopy. In conclusion, SD-OCT could be used as a meaningful screening diagnostic instrument to detect the narrowing of the ICA in canine glaucomatous patients in clinical practice.

References

Akil H, Dastiridou A, Marion K, Francis B, Chopra V. Repeatability, reproducibility, agreement characteristics of 2 SD-OCT devices for anterior chamber angle measurements. *Canadian Journal of Ophthalmology* 2017;52(2):166-170.

Almazan A, Tsai S, Miller PE, Lee SS, Vilupuru AS, Burke JA, Robinson MR. Iridocorneal angle measurements in mammalian species: normative data by optical coherence tomography. *Veterinary Ophthalmology* 2013;16(2):163-166.

Boslaugh S, Watters PA. Statistics in a Nutshell: A Desktop Quick Reference, ch. 7. Sebstopol, CA: O'Reilly Media. ISBN-13: 978-0596510497. 2008.

Dada T, Sihota R, Gadia R, Aggarwal A, Mandal S, Gupta V. Comparison of anterior segment optical coherence tomography and ultrasound biomicroscopy for assessment of the anterior segment. *Journal of Cataract & Refractive Surgery* 2007;33(5):837-840.

Dastiridou A, Marion KM, Niemeyer M, Francis BA, Sadda SR, Chopra V. Agreement in quantitative anterior chamber angle metrics between RTVue and Cirrus spectral domain optical coherence tomography. *Journal of Clinical & Experimental Ophthalmology* 2015;6(435):2.

Doğan NÖ. Bland-Altman analysis: A paradigm to understand correlation and agreement. *Turkish Journal of Emergency Medicine* 2018;18(4):139-141.

Dubin AJ, Bentley E, Buhr KA, Miller PE. Evaluation of potential risk factors for development of primary angle-closure glaucoma in Bouviers des Flandres. *Journal of the American Veterinary Medical Association* 2017;250(1):60-67.

Dulaurent T, Goulle F, Dulaurent A, Mentek M, Peiffer RL, Isard PF. Effect of mydriasis induced by topical instillations of 0.5% tropicamide on the anterior segment in normotensive dogs using ultrasound biomicroscopy. *Veterinary Ophthalmology* 2012;15:8-13.

Ekesten B, Narfstrom K. Correlation of morphologic features of the iridocorneal angle to intraocular pressure in Samoyeds. *American Journal of Veterinary Research* 1991;52(11):1875-1878.

Gibson TE, Roberts SM, Severin GA, Steyn PF, Wrigley RH. Comparison of gonioscopy and ultrasound biomicroscopy for evaluating the iridocorneal angle in dogs. *Journal of the American Veterinary Medical Association* 1998;213(5):635-638.

Leung CK, Chan WM, Yung WH, Ng ACK, Woo J, Tsang MK, Tse RKK. Comparison of macular and peripapillary measurements for the detection of glaucoma: an optical coherence tomography study. *Ophthalmology* 2005;112(3):391-400.

Leung CK, Li H, Weinreb RN, Liu J, Cheung CYL, Lai RYK, Pang CP, Lam DSC. Anterior chamber angle measurement with anterior segment optical coherence tomography: A comparison between slit lamp OCT and Visante OCT. *Investigative Ophthalmology & Visual Science* 2008;49(8):3469-3474.

Li H, Leung CK, Cheung CY, Wong L, Pang CP, Weinreb RN, Lam DSC. Repeatability and reproducibility of anterior chamber angle measurement with anterior segment optical coherence tomography. *British Journal of Ophthalmology* 2007;91(11):1490-1492.

Li Puma MC, Freeman KS, Cleymaet AM, Pederson SL, Crawford AC, Dinger SC, Li Puma LC, Johnston MS. Iridocorneal angle assessment of companion rabbits using gonioscopy, spectral-domain optical coherence tomography (Optovue iVue®), high-resolution ultrasound, and Pentacam® HR imaging. *Veterinary Ophthalmology* 2019;22(6):834-841.

Ma XY, Zhu D, Zou J, Zhang WJ, Cao YL. Comparison of ultrasound biomicroscopy and spectral-domain anterior segment optical coherence tomography in evaluation of anterior segment after laser peripheral iridotomy. *International Journal of Ophthalmology* 2016;9(3):417-423.

Miller PE, Bentley E. Clinical signs and diagnosis of the canine primary glaucomas. *Veterinary Clinics of North America. Small Animal Practice* 2015;45(6):1183-1212.

Park S, Kang S, Lee E, Kwak J, Park E, Lim J, Seo K. Ultrasound biomicroscopic study of the effects of topical latanoprost on the anterior segment and ciliary body thickness in dogs. *Veterinary Ophthalmology* 2015;19(6):498-503.

Park SB, Sung KR, Kang SY, Jo JW, Lee KS, Kook MS. Assessment of narrow angles by gonioscopy, Van Herick method and anterior segment optical coherence tomography. *Japanese Journal of Ophthalmology*

2011;55(4):343-350.

Plummer CE, Komaromy AM, Gelatt KN. The Canine Glaucomas. In: Gelatt KN, Ben-Shlomo G, Gilger BC, Hendrix DVH, Kern TJ, Plummer CE. *Veterinary Ophthalmology*. New Jersey: Wiley-Blackwell; 2021. p. 1173-1214

Porporato N, Baskaran M, Tun TA, Sultana R, Tan M, Quah JH, Allen JC, Perera S, Friedman DS, Cheng CY, Aung T. Understanding diagnostic disagreement in angle closure assessment between anterior segment optical coherence tomography and gonioscopy. *British Journal of Ophthalmology* 2020;104(6):795-799.

Qin B, Francis BA, Li Y, Tang M, Zhang X, Jiang C, Cleary C, Huang D. Anterior chamber angle measurements using Schwalbe's line with high resolution fourier-domain optical coherence tomography. *Journal of Glaucoma* 2013;22(9):684-8.

Radhakrishnan S, Goldsmith J, Huang D, Westphal V, Dueker DK, Rollins AM, Izatt JA, Smith SD. Comparison of optical coherence tomography and ultrasound biomicroscopy for detection of narrow anterior chamber angles. *Archives of Ophthalmology* 2005;123(8):1053-1059.

Ramos JL, Li Y, Huang D. Clinical and research applications of anterior segment optical coherence tomography - a review. *Clinical & Experimental Ophthalmology* 2009;37(1):81-89.

Rigi M, Bell NP, Lee DA, Baker LA, Chuang AZ, Nguyen D, Minnal VR, Feldman

RM, Blieden LS. Agreement between Gonioscopic Examination and Swept Source Fourier Domain Anterior Segment Optical Coherence Tomography Imaging. *Journal of Ophthalmology* 2016;1727039.

Sakata LM, Lavanya R, Friedman DS, Aung HT, Gao H, Kumar RS, Foster PJ, Aung T. Comparison of gonioscopy and anterior segment ocular coherence tomography in detecting angle closure in different quadrants of the anterior chamber angle. *Ophthalmology* 2008; 115(5), 769–774.

Silverman RH. High-resolution ultrasound imaging of the eye - a review. *Clinical & Experimental Ophthalmology* 2009;37(1):54-67.

Tay EL, Yong VK, Lim BA, Sia S, Wong EP, Yip LW. Agreement of angle closure assessments between gonioscopy, anterior segment optical coherence tomography and spectral domain optical coherence tomography. *International Journal of Ophthalmology* 2015;8(2):342-346.

Zibura AE, Robertson JB, Westermeyer HD. Gonioscopic iridocorneal angle morphology and incidence of postoperative ocular hypertension and glaucoma in dogs following cataract surgery. *Veterinary Ophthalmology* 2021;24 Suppl 1:50-62.

국문 초록

본 연구는 초음파생체현미경(UBM), 빛간섭단층촬영장치(SD-OCT), 그리고 우각경을 통하여 검사한 홍채각막각을 측정하고 검사법 사이의 상관성을 비교함으로써 상대적으로 사용하기 용이한 SD-OCT가 가지는 진단적 의의를 확인하기 위한 것이다.

2021년 서울대학교 동물병원에 내원한 개 29마리의 정상 안압 눈을 대상으로 진행하였다. 19마리는 반대쪽 눈에서 녹내장 진단받은 환자였으며 10마리는 정상 눈의 환자였다. UBM과 SD-OCT 장비를 이용하여 홍채각막각(ICA)과 개방각거리(AOD)를 측정하였고, 우각경을 이용하여 ICA 등급 및 기존 방식보다 더 정교한 평가가 가능한 ZibWest angle index를 계산하였다. 결과적으로 UBM과 SD-OCT를 통해 측정한 ICA는 우수한 상관성을 가지는 것을 확인하였으며, 반대로 AOD는 상관성이 매우 낮은 것을 확인하였다. SD-OCT와 UBM의 ICA 값과 우각경을 통해 계산한 ZibWest index를 비교하였을 때에는 유의적인 상관성을 확인하였다.

이상의 결과로부터 임상 환경에서 SD-OCT는 홍채각막각의 변화를 조기에 민감하게 판단할 수 있는 검사법으로 활용할 수 있을 것으로 예상되며, 이를 통해 환자에 따라 예방적 치료를 적절한 시기에 시작할 수 있도록 기여할 것으로 기대된다.

주요어: 홍채각막각, 빛간섭단층촬영장치, 우각경, 초음파생체현미경, 녹내장, 개

학　번: 2020-28445