치의과학석사 학위논문

Factors Affecting Bone Healing After Cyst Enucleation in Oral and Maxillofacial Region

구강악안면영역 낭종의 수술적 제거 후 악골치유 관련 인자 연구

2022년 2월

서울대학교 대학원

치의과학과 구강악안면외과학 전공

정 용 욱

Factors Affecting Bone Healing After Cyst Enucleation in Oral and Maxillofacial Region

지도 교수 서 병 무

이 논문을 치의과학석사 학위논문으로 제출함
2022년 2월

서울대학교 대학원
치의과학과 구강악안면외과학 전공
정 용 욱

정용욱의 치의과학석사 학위논문을 인준함
2022년 2월

위 원 장 명 훈 (인)

부위원장 서 병 무 (인)

위 원 박 주 영 (인)

Abstract

Purpose

This study investigated the results of cyst enucleation in the oral and maxillofacial region to examine the clinical characteristics of enucleation surgery and factors that affect bone healing after cyst removal. This study aimed to evaluate the necessity of bone graft in cystic defects of the maxillofacial region.

Patients and Methods

The patients who received cyst enucleation surgery under general anesthesia were followed up for over a year and retrospectively examined. Different surgical protocols were performed according to different periods. The criteria for assessing bone healing was categorized into either complete healing or incomplete healing. The degree of bone healing was assessed by the panoramic view taken at least 1 year after surgery regardless of the clinical features. Logistic regression test was performed to examine the factors that affect postoperative clinical results, such as infection, recurrence, and degree of bone healing after cyst enucleation.

Results

Among 316 patients, maxillofacial cysts were found in the posterior mandible with highest incidence rate of 43.6% with 138 cases and in the

anterior mandible with the lowest rate of 4.1% with 13 cases. The incidence rates of the cyst at different locations such as anterior maxilla, posterior maxilla, and mandibular ramus were 31% (n = 98), 13.6% (n = 43), and 7.5% (n = 24), respectively.

The mean value of the largest diameter of cysts was 22 mm in computed tomography (CT) images. Preoperative infections were observed in 83 cases (26.2%). Postoperative complications included 50 cases of postoperative infections (15.8%), 48 paresthesias (15.1%), 31 recurrences (15.1%), and 4 pathologic fractures (1.2%). Complete bone healing was observed in 238 cases (75.3%) and incomplete bone healing was observed in 78 cases (24.6%). Logistic regression analysis revealed that age was a factor affecting bone healing; younger patients showed higher rate of complete bone healing than older patients. The posterior maxilla showed the poorest degree of bone healing among different maxillomandibular locations. Xenogeneic bone graft was associated with complete bone healing, and autogenous bone graft was associated with incomplete bone healing. Incomplete bone healing was also associated with larger cysts but did not show significance.

Conclusions

Bone grafting after maxillomandibular cyst enucleation has a positive influence on bone healing and thus can be performed by surgeons if necessary. However, bone grafting should be considered carefully because postoperative complications such as infections still exist.

Keywords: Cyst, Complications, Xenogeneic bone graft, Bone healing

Student Number 2019-25919

Table of Contents

Chapter 1. Introduction

1.1. Study background

Cysts that occur in the oral and maxillofacial region have relatively higher morbidity than other oral and maxillofacial diseases.[1] Cysts in the oral and maxillofacial region can be categorized into odontogenic cysts and non-odontogenic cysts, with odontogenic cysts accounting for 90% of cases.[1] According to the 2017 revision of the World Health Organization (WHO) histological classification of odontogenic and maxillofacial bone tumors,[2] maxillofacial cysts are categorized into odontogenic cysts of inflammatory origin, odontogenic/non-odontogenic developmental cysts (Table 1). Studies on inflammatory odontogenic cysts have demonstrated clear pathogenesis. Pulp necrosis caused by dental caries irritates the periradicular tissues, which then causes the proliferation of epithelial cell rests of Malassez, thus forming a cyst. However, in the case of developmental cysts, the clinical causes and pathogenesis are yet to be concretely determined.[3]

Incidences of subtypes of maxillomandibular cysts differ in various references. According to previous retrospective studies, the most common cyst that developed in the oral and maxillofacial region was radicular cyst with an incidence rate of 52.3%–54.5%, followed by dentigerous cyst (17.9%–20.6%), and odontogenic keratocyst (OKC) (9.8%–11.7%).[1,4,5]

Radicular cysts are caused by chronic inflammation of the periapical

lesion and have fewer differences in morbidity by gender and age. Radicular cysts tend to occur more frequently in the maxilla than in the mandible.[6] In dentigerous cysts, younger patients tend to have higher incidence rates with overwhelmingly high occurrences in the mandibular third molar area.[7] OKCs have unique characteristics compared with other developmental cysts. Most developmental cysts display overlapping histopathological features[3]; however, OKCs have pathognomonic features of a uniform stratified squamous epithelial lining without rete ridges. OKC was classified as a tumor in the WHO classification (2005) because of their aggressive clinical manifestation and high recurrence rate. However, in the 2017 revision, the WHO odontogenic cyst classification revised keratocystic odontogenic tumor as OKC because of insufficient evidence.[8] Given its high recurrence, OKCs require a wider resection during surgical excision and closer observation than that of other cysts. With such characteristics that make it uniquely different from other cysts, OKCs need a clinical approach different from that of other odontogenic cysts.

Cysts have different characteristics according to diagnosis, and this could affect bone healing after surgery. The incidence, growth pattern, and recurrence rate of cysts differ depending on pathologic diagnosis. The diagnosis and cyst size affect the surgical method. Cyst enucleation is the most frequently used surgical method. However, when the cyst invades major anatomical structures, secondary surgery performed after decompression and marsupialization may be used for cyst removal. Furthermore, if the cyst is

widespread enough to cause cortical perforation, radical resection may be performed. If the recurrence rate is high, a wider range of bone removal considering safety margin is required. It can increase the bone defect size and lead to losing the bone wall, which could affect poor bone healing. Cyst size may affect bone healing after surgery; however, the average size according to cystic diagnosis has not been studied yet. This study investigated sex, age, diagnosis, lesion location, cyst size, preoperative infection, postoperative infection after bone graft, recurrence, and bone healing, which are the factors that potentially affect bone healing.

Previous studies have observed spontaneous bone healing after the enucleation of intrabony cysts.[9,10] Bone grafting is performed to enhance bone healing and increase bone formation. However, controversies exist on the results of bone grafting.[11] One study claimed that bone grafting facilitates bone healing, and others argued that the presence of grafting materials interferes and delays the initial bone healing process.[9] A previous study argued that bone grafting is necessary when the lesion is larger than the critical size[12]; however, other studies have claimed that bone grafting increases the rate of complications, such as postoperative infections.[13] These controversies remind us that bone grafting requires careful consideration.

1.2. Purpose of the study

This study examined retrospectively the results of patients who underwent cyst enucleation for the treatment of intrabony cysts in the oral and

maxillofacial region. The purpose of this study was to examine the factors that affect bone healing after cyst enucleation. The factors that affect bone healing, cyst diagnosis, lesion location, size, and complications were evaluated.

Chapter 2. Patients and Methods

2.1. Inclusion criteria

All patients underwent cyst enucleation under general anesthesia by a single surgeon from January 1, 2012, to December 31, 2019, at the Department of Oral and Maxillofacial Surgery at Seoul National University Dental Hospital (Seoul, Korea). This study retrospectively reviewed the medical records, preoperative panorama, computed tomography (CT) images, and postoperative panorama taken at least 1 year after surgery of patients who had followed up appointments for over a year after cyst enucleation.

This study followed the Institutional Review Board guidelines of Seoul National University Dental Hospital and received the board's approval (IRB No. ERI21043).

2.2. Exclusion criteria

To investigate the final degree of bone healing, patients who had followed up appointments in less than a year and patients who did not present for follow-ups were excluded from the study.

2.3. Predictor variables

This study regarded independent variables as explanatory variables, as they could not be manipulated by the researcher nor were they statistically

independent. Explanatory variables included sex, age, diagnosis, lesion location, cyst size, preoperative infection, and bone grafts. The anatomical locations of the lesions were the anterior maxilla, posterior maxilla, anterior mandible, posterior mandible, and mandibular ramus. When the cyst encroached into two anatomical locations, only the location where the cyst had originally occurred was counted. However, in the mandibular ramus, if the lesion in the posterior mandible had encroached into the ramus, the location was counted as the ramus. Lesion size was measured by the greatest diameter of the cyst obtained from preoperative CT. Preoperative infection was determined by reviewing medical records to identify whether the patient had received an incision and drainage procedure or prescribed antibiotics. Bone grafts were categorized into no bone grafts, xenografts (Bio-Oss®, Geistlich Sons Ltd, Wolhusen, Switzerland), and autogenous grafts (iliac bone graft).

2.4. Outcome variables

Response variables included postoperative infection, recurrence, and bone healing. Bone healing was considered to have occurred when the healed bone displayed homogenous density and if that density appeared similar to that of the surrounding bone or showed more radiopacity. The degree of bone healing was evaluated into two categories of complete healing and incomplete healing. Bone healing was considered complete if the postoperative panorama was taken at least 1 year after surgery showed no visible atrophies and no

radiolucency on the healing bone (Figure 1). Bone healing was regarded as incomplete if the panoramic view showed signs of bone atrophy and/or radiolucency (Figure 2). To infer the normal bone structure before the cyst had occurred, the unaffected area was also observed.

Logistic regression was performed to analyze the data and investigate the influence of explanatory variables on postoperative infection, recurrence, and bone healing. Kruskal–Wallis rank-sum test and Wilcoxon rank-sum test were performed to investigate the relationship between cyst size and response variables. All statistical analyses were performed using Language R (Vienna, Austria).[14] Results were considered significant if p-values were less than 0.05.

2.5. Surgical protocol

Surgeries were divided and performed in two phases. From 2012 to 2015, after cyst enucleation, performing bone grafts was decided by considering the defect size and clinical situation. If bone grafting is expected, autogenous bone grafts were decided for cases where the defect size was large. For cases where the size was moderate, xenogeneic bone grafting was performed.

In all cases where xenogeneic bone grafting was performed, Bio-Oss® (Geistlich Pharma AG, Wolhusen, Switzerland) was used; occasionally, Bio-gide® (Geistlich Pharma AG, Wolhusen, Switzerland) and Tisseel® (Baxter, Deerfield, IL) were also used. Autogenous bone grafting was performed by using the trapdoor method on the anterior iliac spine to extract

the particulate marrow cancellous bone (PMCB), which was then grafted onto the bone defect area. In cases with preoperative infection, primary closure was performed instead of bone grafting.

From 2016 to 2019, bone grafting was not performed if the residual bone wall was intact after cyst enucleation. However, in cases with insufficient soft tissue support after cyst enucleation, bone grafting was performed to facilitate the healing of bony defects.

Chapter 3. Results

3.1. Demographic data

The total number of patients who had followed up appointments for over a year from 2012 to 2019 was 316, including 204 men and 112 women. Their mean age during the first medical examinations was 40 ± 17 years. The average number of follow-up visits was 8 ± 4.3 and lasted for 121 ± 80.5 weeks on average. Eleven patients had diabetes, and seven patients were treated for osteoporosis. Marsupialization was performed in 33 cases (10.4%) and preoperative infection was observed in 83 cases (26.2%).

The mean greatest diameter of the cysts was 22 ± 10 mm. Dentigerous cysts were the most frequently diagnosed cysts with 137 (43.3%) cases, followed by periapical cysts with 67 (21.2%) cases, OKC with 63 (19.9%) cases, nasopalatine duct cysts with 34 (10.7%) cases, and postoperative maxillary cysts (POMC) with 7 (2.2%) cases. Other cysts were four cases of glandular odontogenic cysts (1.2%), one traumatic bone cyst (0.3%), one lateral radicular cyst (0.3%), one inflamed cyst (0.3%), and one residual cyst (0.3%) (Table 2).

Moreover, 138 cases of cysts occurred in the posterior mandible (43.6%), which specifically were 90 dentigerous cysts, 26 periapical cysts, 18 OKCs, and 4 others. In the anterior maxilla, 98 cysts were recorded (31.0%), which included 34 nasopalatine duct cysts, 27 periapical cysts, 27 dentigerous cysts, and 10 others. There were 43 cysts in the posterior maxilla, which

included 18 OKCs, 11 dentigerous cysts, 7 POMCs, 6 periapical cysts, and 1 inflamed cyst. In the mandibular ramus, 24 cysts occurred (7.5%), including 15 OKCs, 8 dentigerous cysts, and 1 glandular odontogenic cyst. The smallest number of cysts occurred in the anterior mandible (4.1%) with 8 periapical cysts and 5 others (Figure 3).

Bone healing was observed in all 316 patients regardless of whether bone grafts were performed or not. Bone grafts were opted against in 232 (73.4%) cases, and in cases where bone grafting was performed, xenogeneic bone grafting was conducted in 71 (22.4%) cases and autogenous bone grafting using the iliac bone graft was performed on 13 (4.1%) cases (Table 2).

The most common postoperative complication was postoperative infection (n = 50, 15.8%), followed by paresthesia (n = 48, 15.1%), recurrences (n = 31, 9.8%), and pathological fractures (n = 4, 1.2%). In the four cases of pathological fractures, open reduction and internal fixation was not performed (Table 2).

3.2. Infection

Postoperative infection occurred in 50 cases (Table 2). Male patients had higher infection rates than female patients, which proved to be significant. Postoperative infection was significantly lower in the anterior maxilla than in the posterior mandible. Other anatomical lesions produced insignificant results. No infection occurred in the anterior mandible (Table 3).

Bone grafting showed significantly higher postoperative infection rates than when bone grafting was not performed. More specifically, autogenous bone grafts had higher postoperative infection rates and yielded significant results. Preoperative infection was associated with tendencies of postoperative infection, but this was not significant (Table 3).

3.3. Recurrence

Recurrences occurred in 31 patients, of which 22 cases were OKCs. In logistic regression analysis, OKC results proved to be significant (Table 4). Sex, age, and other cysts excluding OKCs did not yield significant results.

3.4. Bone healing

Complete bone healing was observed in 238 cases, in which bone grafting was performed in 167 cases, xenogeneic bone grafting in 65 cases, and autogenous bone grafting in 6 cases. Moreover, 78 cases showed incomplete bone healing, of which bone grafting was not performed in 65 cases, xenogeneic bone grafting in 6 cases, and autogenous bone grafting in 7 cases (Figure 4). The results about bone healing by lesion location were as follows: 1) in the posterior mandible, 113 cases of complete bone healing and 25 cases of incomplete healing occurred (n = 138); 2) in the anterior maxilla, 78 cases of complete bone healing and 20 cases of incomplete healing (n = 98); 3) in the posterior maxilla, 13 cases of complete healing and 30 cases of incomplete healing (n = 43); 4) in the mandibular ramus, 22 cases of complete

healing and 2 incomplete healing cases (n = 24); 5) in the anterior mandible, 12 cases of complete healing and a single case of incomplete healing (n = 13) (Figure 5.)

Age was associated with complete bone healing rates, as younger patients had higher rates of complete bone healing. Compared with the posterior mandible, the posterior maxilla was associated with higher rates of incomplete bone healing. Other locations did not yield significant results. Higher rates of complete bone healing were observed in cases of xenogeneic bone grafting. Autogenous bone grafting was associated with higher incomplete bone healing rates. Larger cysts tended to be associated with relatively higher incomplete bone healing rates, but results were not significant (Table 6).

Chapter 4. Discussion

In previous studies, radicular cysts had the highest incidence rate of 52.3%–54.5% [1,4,5]. However, the incidence of a radicular (periapical) cyst was second to that of dentigerous cyst (Table 2). Small radicular cysts that were enucleated under local anesthesia were not included in this study; thus, the difference in incidence could be attributed to the inclusion only of patients who were operated on under general anesthesia.

Various studies have attempted to collect objective data on bone healing after cyst enucleation in panoramic view. A study used a metal marker to standardize the panoramic view taken after cyst enucleation, which was then digitalized to measure the size of bone defects.[10] The degree of healing in terms of bone density was 3.6% in the maxilla (1 was examined by comparing the number of pixels in the lesions and the surrounding bone).[9,15] Another study used preoperative panoramic views where linear measurements drawn on the outer limits of the lesions were used for investigating postoperative bone healing.[16] Recently, studies have used digital imaging and communications in medicine (DICOM) files from three-dimensional CT to examine postoperative bone healing.[17,18]

In this study, bone healing was observed through the most recent panoramic view taken at least 1 year after surgery. Most of the defects were healed with serial changes until 1 year. However, changes were not significant after 1 year. Infrequently, especially in large cystic defects, continuous bony

healing had occurred even after 1 year up to 2 years. This result was similar to that of previous studies.[9,10]

This study evaluated bone healing into two categories. Bone healing was considered complete if a panoramic view was taken 1 year after surgery displayed no visible atrophies and no radiolucency on the healing bone. Bone healing was regarded as incomplete healing if atrophies and/or radiolucency were shown. The criteria were set on the basis that panoramic views were sufficient for evaluating bone healing. Contrary to preexisting studies, this study did not use pixels or linear measurements because of distortions in the panoramic view, making quantitative measurements difficult and because those methods would be prone to error from density and measuring ranges set by the researcher. In this study, the method used is convenient, as it does not require additional CT after surgery. Therefore, it is relatively easier to observe and evaluate bone healing, and it allows for collecting data from many patients. However, certain limitations exist. Overlapping of the anatomical structures and prolonged retention of grafted materials can make it difficult to evaluate bone healing. In this study, the average period of follow-up was 4 years; thus, a consistent bone pattern with no significant changes could be observed. Follow-ups using the panoramic view may make quantitative measurement difficult; however, it is still competent to use for the evaluation of the patient's bone healing.

Male patients had significantly higher rates of postoperative infection (Table 3). This result was different from those previous studies.[13,19] This result

implied that habitual factors of oral hygiene, smoking, and alcohol abuse are related to postoperative infection.

In this study, cases with bone grafts had significantly higher postoperative cases where bone grafts were opted against (Table 3). More specifically, autogenous bone grafts displayed significant results. Bio-Oss is commonly used as grafting material for bone defects in the oral and maxillofacial region because of their predictability, sustainability, accelerated new bone formation, and least infection rates.[20] In this study, postoperative infection rates for the 15 (4.7%) cases where Bio-Oss was used for grafts were similar to that of preexisting studies that also used Bio-Oss, where postoperative infection rates ranged from 1% to 5%.[21]

Although autogenous bone grafts have a disadvantage of donor site morbidity, many studies have asserted it as the gold standard because of its low infection rate and capabilities for osteogenesis, osteoinduction, and osteoconduction.[22-26] However, in this study, autogenous bone grafts were associated with higher infection rates (odds ratio= 11.60; $p < 0.001$). Other studies did not reveal any significant infections on patients with cleft lip and palate or iliac bone grafts after cyst enucleation.[27,28] However, the results of this study yielded significant results for higher infection rates when autogenous bone grafts were performed. As there were not enough cases of autogenous bone grafts (13 cases), this makes it difficult to investigate the relationship between autogenous bone grafts and infections. As iliac bone grafting is typically performed on patients with larger cysts, (average defect

size: no bone graft, 18mm; xenogeneic bone graft, 22 mm; autogenous bone graft, 38 mm), there are higher possibilities of wound dehiscence and infection caused by bacterial flora because of the relatively large size of the wound. Furthermore, larger cysts can delay the essential process of neovascularization,[29] increasing the risk for postoperative infection. Finally, contamination that occurs during autogenous bone harvesting can also be a relevant factor.[30]

Bone grafts are associated with the unfavorable condition in which grafting materials are prone to infection because of oral bacterial flora. If bacterial pathogens are attached to the grafting materials,[31] they create a biofilm with antibiotic resistance properties, thus increasing the possibility of bone grafting failures. Therefore, aseptic techniques are of the utmost importance when performing bone grafts. To prevent bacterial contamination, the prescription of antibiotics before bone grafts and antiseptic soaking can be considered.

OKCs had significantly higher rates of recurrences. Of the 31 recurrences, 22 cases were OKCs (Table 5). Higher recurrence rates of OKCs have already been dealt with by various studies[32-34] along with different attempts to lower the recurrence rates.[35,36] A study claimed that radical resection was the gold standard for lowering the recurrence rates of OKCs.[37] They also argued that the application of Carnoy's solution or cryotherapy should be the first-line treatment of OKCs. Another study proposed a surgical protocol for patients who had received surgical treatment for OKCs based on

their long-term follow-up appointments that lasted on average for 77.5 months.[38]

Radical resection remains the gold standard for the treatment of OKCs, as it is the most certain method for lowering recurrences; however, it may have substantial side effects because of large resections. Many methods are used for reducing the resection margins, and typical methods included use of Carnoy's solution, cryotherapy, and peripheral ostectomy.

Younger age was associated with complete bone healing, with significant results (Table 6). A study utilized the changes in pixel count in the panoramic view to examine the correlation between age and postoperative bone healing.[15] They discovered that changes in pixel count were most active in patients aged <20 years. Another study discovered a negative correlation between patient's age and bone healing, along with fewer complications in younger patients.[10] Patients were divided into three groups according to age: age <20 years, 20–50, and >50 years. Patients aged < 20 years had the highest degree and speed of bone healing, with a better rate in increasing the density of the recovered bone. Older age tends increase the risks of morbidities and mortality and lower bone regeneration potential. Factors such as changes in multiple cellular processes, reduction of the number of stem cells, and altered revascularization are thought to influence the changes in bone healing responses.[39-42]

In this study, most of the patients aged <20 years displayed complete bone healing. In a total of 55 patients aged <20 years, 48 (87%) experienced

complete bone healing. Specifically, in the 7 (12.7%) cases of incomplete bone healing, most cases were poor bone healing after cyst enucleation in the posterior maxilla. One patient who was diagnosed with a nasopalatine duct cyst went through cyst enucleation in the anterior maxilla, which resulted in bone healing but showed radiolucency in the middle of the healing bone. Bone healing was also observed in adults, but younger age is still being associated with better bone healing. In patients who are not yet fully grown, sufficient bone healing can be expected even with large cysts because of their high potential for bone regeneration.

No cases of postoperative infection were recorded in the anterior mandible, which also had the lowest incidence rates of cysts with only 13 cases (Figure 3). Of the 13 cases, 8 were periapical cysts, and complete bone healing was observed in 12 cases (Figure 5). According to the results of this study where pathologic diagnoses and size were compared, the average size of periapical cysts was smaller than that of other cysts (Figure 6). Therefore, the small sizes of bone defects can be related to fewer complications and favorable bone healing. These results suggested that the pathologic diagnoses of the cysts are sometimes related to the size of the cysts, which may influence postoperative bone healing.

The poorest bone healing was observed in the posterior maxilla (Table 6). The maxillary sinus involves cystic lesions, which also makes evaluating the degree of bone healing difficult. In some of the postoperative CT images taken for checking wound infection in the posterior maxilla, the absence of

the bone wall was detected, which may have caused atrophy in the healing bone and is considered as incomplete bone healing. Furthermore, if cyst enucleation was accompanied by tooth extraction, pneumatization of the maxillary sinus and resorption of the alveolar bone made complete bone healing difficult.[43] Finally, this study's criteria for evaluating bone healing could influence the results. This study considered bone healing complete only if all of the bone defects had healed. However, as this is impossible for cysts in the maxillary sinus, this study's criterion for evaluating bone healing could be one of the limitations of this study.

Logistic regression analysis of the influence of cyst size on bone healing revealed that larger cysts were associated with poor bone healing; however, the results were not significant (Table 6). Various studies have observed larger cysts and their tendency toward poor bone healing.[9-11] The degree of bone healing can be influenced by the size of the bone defect and residual bone wall. A sufficient amount of residual bone wall and intact periosteum would result in a better degree of bone healing.[11]

Xenogeneic bone grafts were associated with complete bone healing, and autogenous bone grafts were associated with incomplete bone healing (Table 6). Xenogeneic bone grafts fill the bone defects more readily than no bone graft cases, which partly explained why the xenogeneic bone is superior to others. In cases of autogenous bone grafts that resulted in incomplete bone healing, the surgical protocol for relatively larger cysts is thought to be one of the reasons for incomplete bone healing with insufficient grafting on the

defects (Figure 7).

Various studies have observed the effect of bone grafting after cyst enucleation. However, each study has different surgical protocols and graft materials, along with different criteria for evaluating the degree of postoperative bone healing. This makes a concrete conclusion difficult.[44,45] When xenogeneic bone grafts are performed after intrabony cyst enucleation, a complete bone healing tendency was observed significantly. However, the surgeon must exercise caution when deciding to perform bone grafts, as they tend to increase postoperative complications.

Before bone grafting, risk factors that could influence postoperative bone healing must be carefully considered. If the patient is a heavy smoker, alcohol abuser, or has poor oral hygiene, their prognosis is expectedly poor. Moreover, lesion location and size, diagnosis, and amount of residual bone wall must be considered. Anatomical locations of cysts have different rates of postoperative infection; thus, it is a factor to consider when deciding on bone grafting.

Apart from postoperative complications, patients who displayed incomplete bone healing did not have clinical symptoms or functional defects. Although aiming for complete bone healing after cyst enucleation is plausible for certain circumstances, bone grafts are not necessarily required for every case where incomplete bone healing is expected with no harmful results after surgery. If soft tissue support is expectedly insufficient, or there are specific plans such as implant installation, bone grafts could be considered while

considering the risk factors. Therefore, the surgeon must make patient-specific treatment plans when planning the surgery instead of following general surgical protocols.

Chapter 5. Conclusions

This study confirmed the positive effects of bone grafting on bone healing. However, the postoperative infection rate was higher in bone grafting cases. For bone grafting, the patient's age, systemic diseases, lesion size and location, and functional aspects should be carefully considered. Since incomplete bone healing does not necessarily mean clinical complication and malfunction after surgery, bone grafting may be unnecessary if there are no functional problems.

Tables

Table 1. Classification of odontogenic and maxillofacial cysts*

Odontogenic cysts of inflammatory origin
Radicular cysts
Inflammatory collateral cysts

Odontogenic developmental cysts
Dentigerous cyst
Odontogenic keratocyst
Lateral periodontal and botryoid odontogenic cyst
Gingival cyst
Glandular odontogenic cyst
Calcifying odontogenic cyst
Orthokeratinized odontogenic cyst

Non-odontogenic developmental cyst
Nasopalatine duct cyst

*(Modified from WHO 4th edition, 2017)

(Note: The diseases relevant to this study were included in this table.)

Table 2. Descriptive statistics of the study variables

Study variables	Descriptive statistics
Sample size	316
Man	204 (64.5%)
Age (year)	40 ± 17
Cyst size (mm)	22 ± 10
Marsupialization	33 (10.4%)
Number of follow-up visits	8 ± 4.3
Follow-up duration (weeks)	121 ± 80.5
Pathology	
Dentigerous cyst	137 (43.3%)
Periapical cyst	67 (21.2%)
Odontogenic keratocyst	63 (19.9%)
Nasopalatine duct cyst	34 (10.7%)
Postoperative maxillary cyst	7 (2.2%)
Glandular odontogenic cyst	4 (1.2%)
Traumatic bone cyst	1 (0.3%)
Lateral radicular cyst	1 (0.3%)
Inflamed cyst	1 (0.3%)
Residual cyst	1 (0.3%)
Preoperative infection	83 (26.2%)
Comorbidities	
Diabetes	11 (3.4%)
Osteoporosis	7 (2.2%)
Complications	
Postoperative infection	50 (15.8%)
Paresthesia	48 (15.1%)
Recurrence	31 (9.8%)
Pathologic fracture	4 (1.2%)
Bone graft method	
None	232 (73.4%)
Xenogeneic bone graft	71 (22.4%)
Autogenous bone graft	13 (4.1%)
Bone healing	
Complete	238 (75.3%)
Incomplete	78 (24.6%)

Table 3. Results of the logistic regression analysis on postoperative infection

Predictor variables (reference)	**Odds ratio**	**95% Confidence interval**	***p-value***
Sex (female)			
Male	3.38	1.46–8.93	0.008*
Age (1-year incremental)	1.00	0.98–1.02	0.812
Anatomic location (Posterior mandible)			
Anterior maxilla	0.30	0.12–0.67	0.005*
Posterior maxilla	0.13	0.01–0.70	0.057
Mandibular ramus	0.48	0.10–1.83	0.325
Bone graft method (No bone graft)			
Xenogeneic bone graft	2.88	1.24–6.70	0.013*
Autogenous bone graft	11.60	2.85–51.91	< 0.001*
Preoperative infection (no)			
Yes	0.39	0.14–0.96	0.056

* Results were considered significant if *p*-values were less than 0.05

Table 4. Results of the logistic regression analysis on recurrence

Predictor variables (reference)	**Odds ratio**	**95% Confidence interval**	***p-value***
Sex (female)			
Male	0.92	0.35–2.43	0.862
Age (1-year incremental)	1.00	0.97–1.02	0.781
Pathologic diagnosis (Dentigerous cyst)			
Odontogenic keratocyst	34.11	8.93–226.81	<0.001*
Nasopalatine duct cyst	2.01	0.09–21.73	0.574
Periapical cyst	0.99	0.05–10.63	0.993

* Results were considered significant if *p*-values were less than 0.05

Table 5. Distribution of recurrences based on pathologic diagnosis.

Diagnosis	Descriptive Statistics
Odontogenic keratocyst	22 (70.9%)
Postoperative maxillary cyst	4 (12.9%)
Dentigerous cyst	2 (6.4%)
Periapical cyst	1 (3.2%)
Nasopalatine duct cyst	1 (3.2%)
Glandular odontogenic cyst	1 (3.2%)

Table 6. Results of the logistic regression analysis on postoperative bone healing

Predictor variables (reference)	**Odds ratio**	**95% Confidence interval**	***p-value***
Sex (female)			
Male	1.01	0.51–1.99	0.968
Age (1-year incremental)	0.96	0.94–0.98	<0.001*
Anatomic location (Posterior mandible)			
Mandibular ramus	7.15	1.26–76.77	0.053
Anterior mandible	1.86	0.28–7.63	0.586
Anterior maxilla	0.50	0.23–1.09	0.081
Posterior maxilla	0.08	0.03–0.20	<0.001*
Bone graft method (No bone graft)			
Xenogeneic bone graft	6.69	2.53–20.64	<0.001*
Autogenous bone graft	0.15	0.02–0.81	0.037*
Cyst size (1-mm incremental)	0.97	0.93–1.00	0.062

* Results were considered significant if *p*-values were less than 0.05

Figure Legends

Figure 1. Complete bone healing cases

Preoperative (left column) and postoperative panoramic views (right column) of complete bony healing cases. (A) Cyst enucleation without bone grafting was performed on a 14-year-old female patient with odontogenic keratocyst followed up to 6 years. (B) Preoperative and 5-year follow-up panoramic views after cyst enucleation with xenogeneic bone grafting on a 42-year-old female patient with nasopalatine duct cyst.

Figure 2. Incomplete bone healing cases

Preoperative (left column) and postoperative panoramic views (right column) of incomplete bone healing cases. (A) The periapical cyst was enucleated, and a bone graft was not performed on a 43-year-old male patient. On the 13 months later postoperative panoramic view, the radiolucent center was observed in the surrounding healed bone. (B) Cyst enucleation and xenogeneic bone graft were performed on an 82-year-old female patient with a nasopalatine duct cyst, followed up to 2 years. In the postoperative panoramic view, a radiolucent region was seen between implant fixtures.

Figure 3. Anatomical location according to the diagnosis.

The incidence of cysts was the most common in the posterior mandibular region and the least in the anterior mandibular region.

Figure 4. Bone healing degree based on bone graft methods.

More complete bone healing was observed than incomplete bone healing. In the case of incomplete bone healing, the ratio of xenogeneic bone graft was low.

Figure 5. Bone healing according to the anatomical location.

Except for the posterior maxilla cases, the rate of complete bone healing was higher than that of incomplete bone healing.

Figure 6. Cyst size according to the pathologic diagnosis.

The average diameter of the odontogenic keratocyst was the largest. The average sizes of the periapical cyst and nasopalatine duct cyst were comparable.

Figure 7. Cyst size according to the bone graft method.

The cyst size of the patients who underwent autogenous bone graft was the largest.

Figures

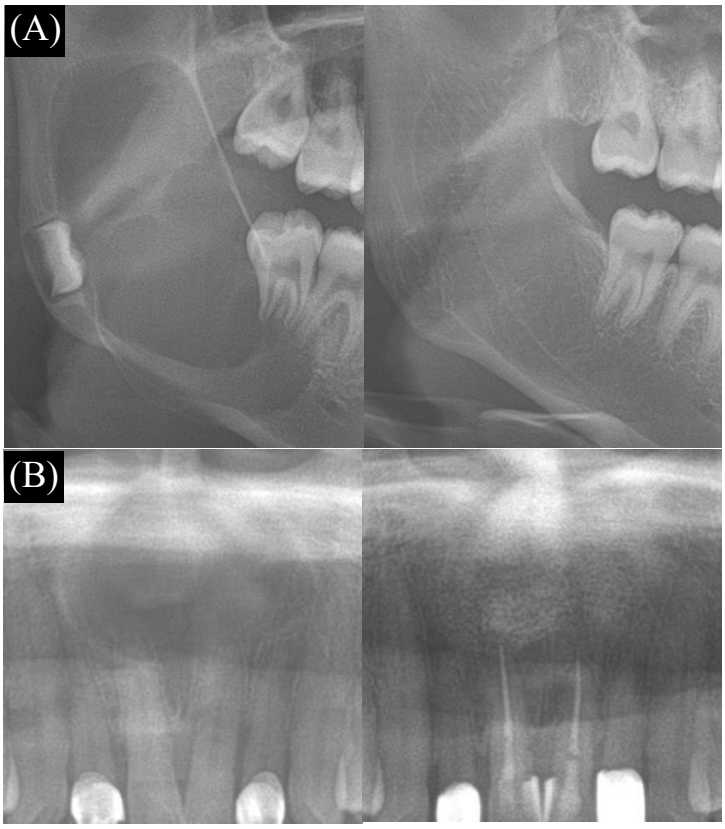

Figure 1. Complete bone healing cases.

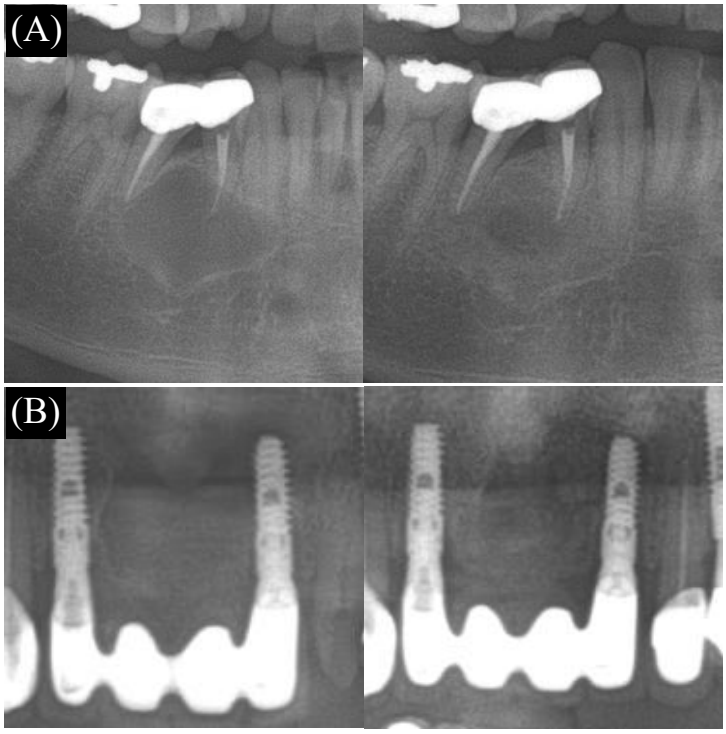

Figure 2. Incomplete bone healing cases

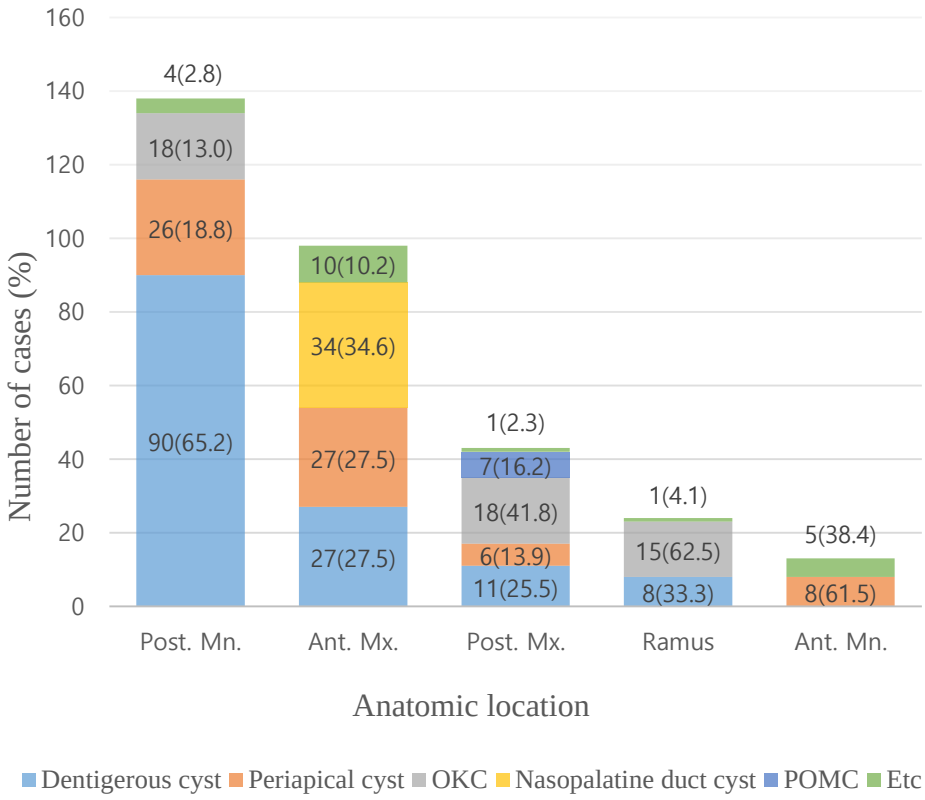

Figure 3. Anatomic location according to pathologic diagnosis
Post. Mn. : posterior mandible
Ant. Mx. : anterior maxilla
Post. Mx. : posterior maxilla
Ant. Mn. : anterior mandible

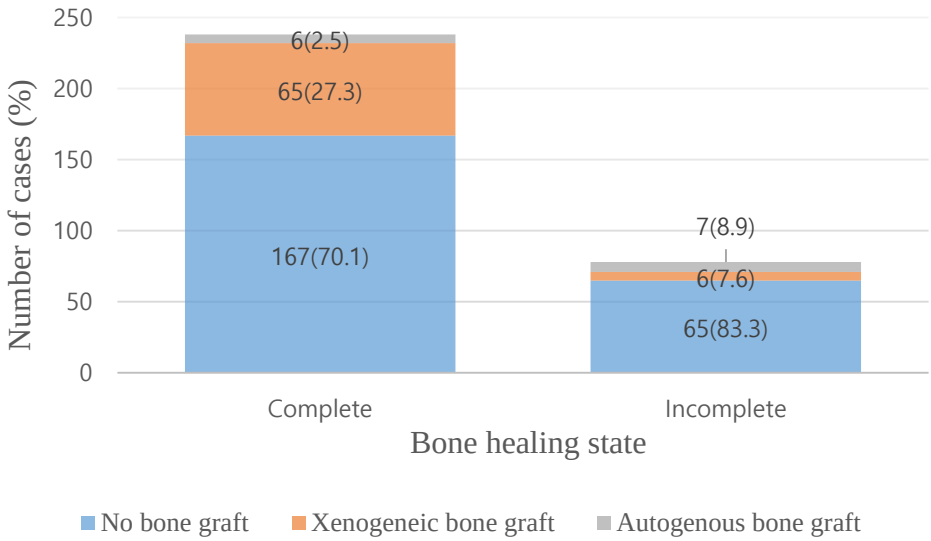

Figure 4. Bone healing degree based on bone graft methods

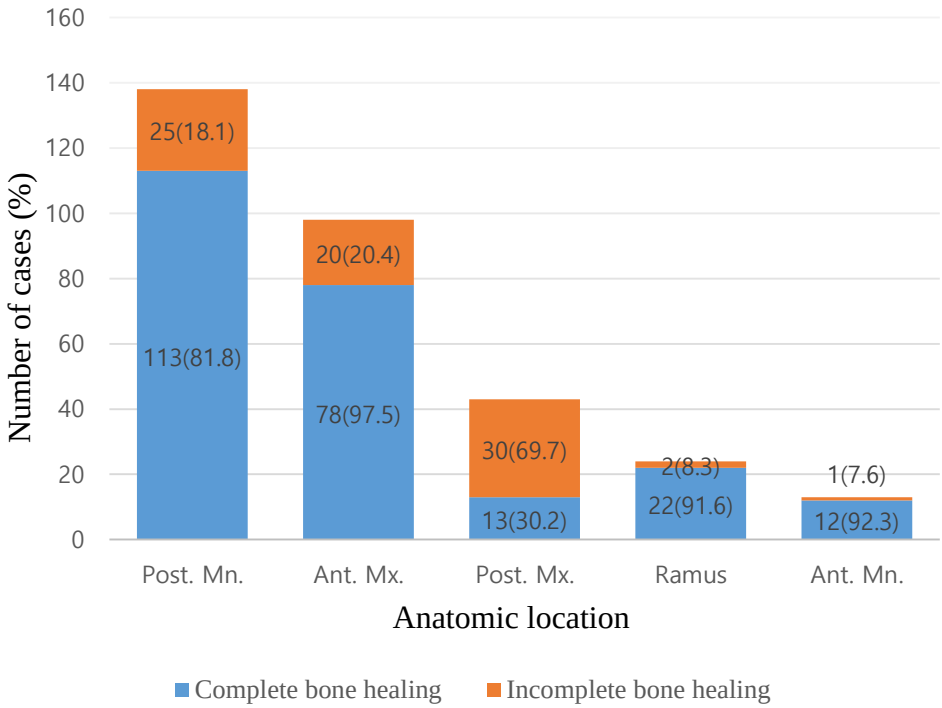

Figure 5. Bone healing according to anatomic location
Post. Mn. : posterior mandible
Ant. Mx. : anterior maxilla
Post. Mx. : posterior maxilla
Ant. Mn. : anterior mandible

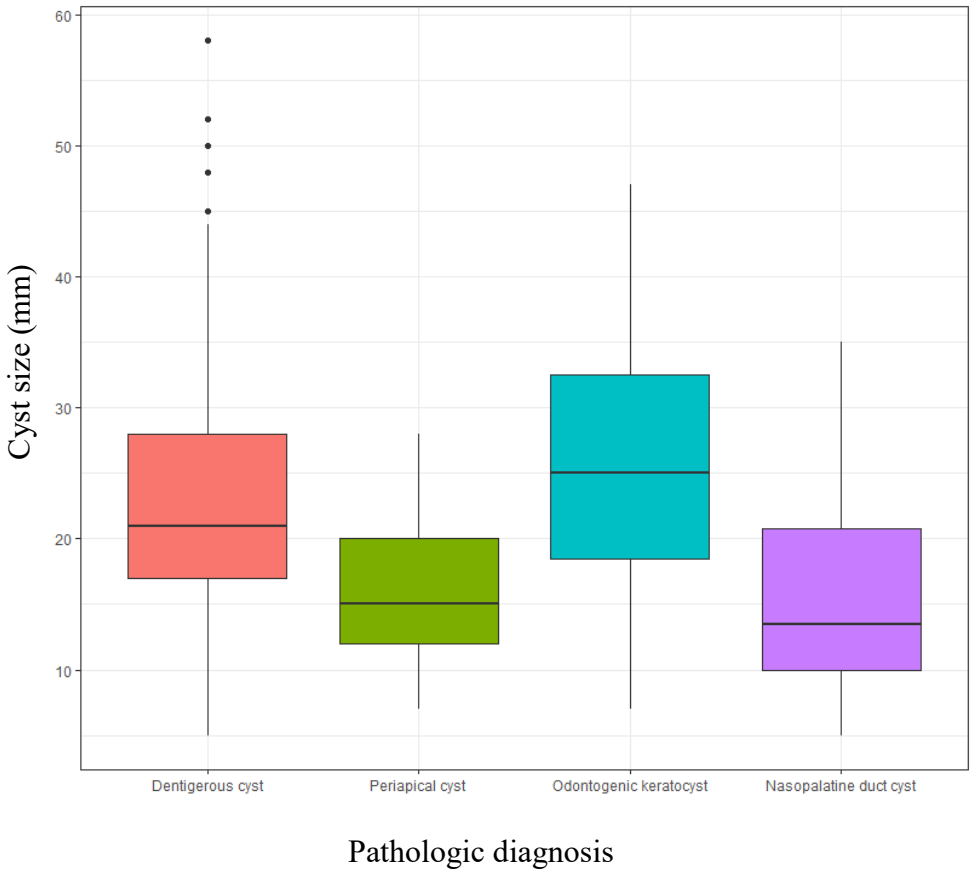

Figure 6. Cyst size according to pathologic diagnosis

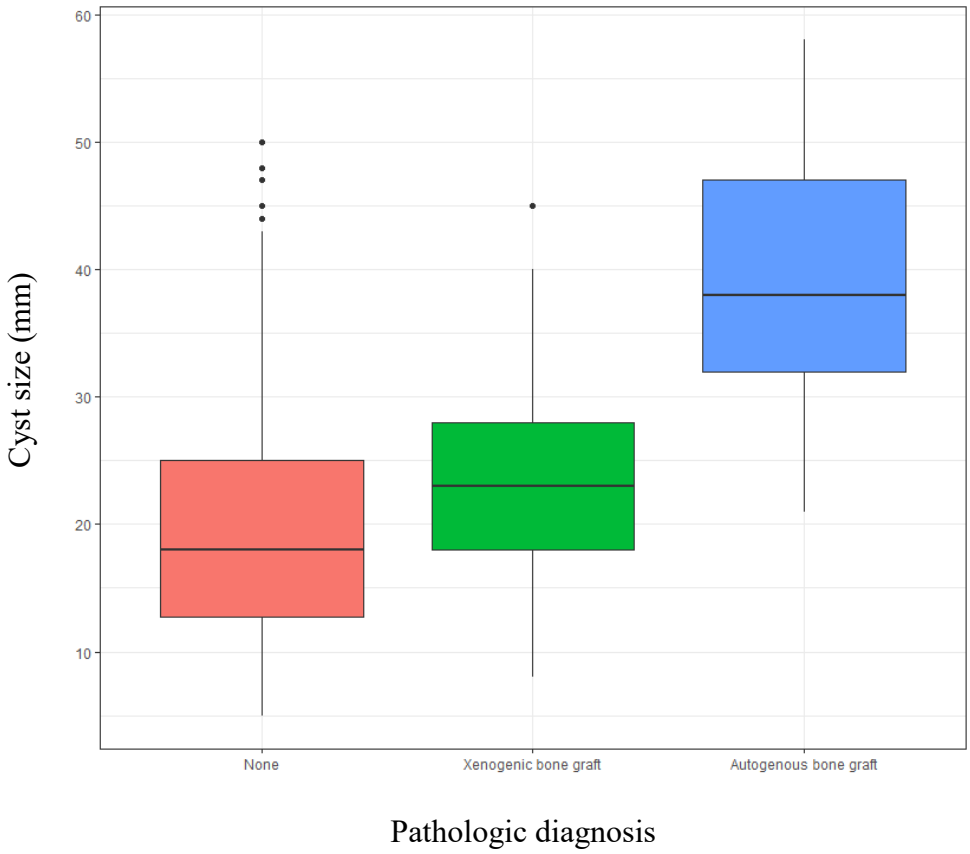

Figure 7. Cyst size according to bone graft method.

References

1. Jones A, Franklin C. An analysis of oral and maxillofacial pathology found in adults over a 30 year period. *J Oral Pathol Med* 2006;35:392-401.

2. El-Naggar, AK, Chan, JK, Grandis, JR. WHO classification of head and neck tumours, 2017.

3. Martin LH, Speight PM. Odontogenic cysts: an update. *Diagn Histopathol* 2017;23:260-265.

4. Jones A, Craig G, Franklin C. Range and demographics of odontogenic cysts diagnosed in a UK population over a 30 year period. *J Oral Pathol Med* 2006;35:500-507.

5. Johnson NR, Gannon OM, Savage NW, Batstone MD. Frequency of odontogenic cysts and tumors: a systematic review. *J Investig Clin Dent* 2014;5:9-14.

6. Latoo S, Shah AA, Jan SM, Qadir S, Ahmed I, Purra A, et al. Radicular cyst. *JK Science* 2009;11:187.

7. Zhang L, Yang R, Zhang L, Li W, MacDonald-Jankowski D, Poh C. Dentigerous cyst: a retrospective clinicopathological analysis of 2082 dentigerous cysts in British Columbia, Canada. *Int J Oral Maxillofac Surg* 2010;39:878-882.

8. Wright JM, Vered M. Update from the 4th edition of the World Health Organization classification of head and neck tumours: odontogenic and maxillofacial bone tumors. *Head Neck Pathol* 2017;11:68-77.

9. Chiapasco M, Rossi A, Motta JJ, Crescentini M. Spontaneous bone regeneration after enucleation of large mandibular cysts: a radiographic computed analysis of 27 consecutive cases. *J Oral Maxillofac Surg* 2000;58:942-948.

10. Hren NI, Miljavec M. Spontaneous bone healing of the large bone defects in the mandible. *Int J Oral Maxillofac Surg* 2008;37:1111-1116.

11. Nyimi BF, Yifang Z, Liu B. The Changing landscape in the treatment of cystic lesions of the jaws. *J Int Soc Prev Commun Dent* 2019;9:328.

12. Cha SK, Kim IK, Oh SS, Choi J-H, Oh N-S, Lim Y-I, et al. Clinical study of cyst in the jaw. *J Korea Assoc Oral Maxillofac Surg* 2001;27:167-173.

13. Lee H, Lee SJ, Seo BM. Investigation of postoperative complications of intrabony cystic lesions in the oral and maxillofacial region. *J Oral Maxillofac Surg* 2019;77:1823-1831.

14. Team. RDC. R: A language and environment for statistical computing. Vienna, Austria: *R Foundation for Statistical Computing* 2021.

15. Yim J-H, Lee J-H. Panoramic analysis about spontaneous bone regeneration after enucleation of jaw cyst. *J Korean Assoc Maxillofac Plast Reconstr Surg* 2009;31:229-236.

16. Rubio E, Mombrú C. Spontaneous bone healing after cysts enucleation without bone grafting materials: a randomized clinical study. *Craniomaxillofac Trauma Reconstr* 2015;8:14-22.

17. Vitale A, Battaglia S, Crimi S, Ricceri C, Cervino G, Cicciù M, et al. Spontaneous bone regeneration after enucleation of mandibular cysts:

retrospective analysis of the volumetric increase with a full-3D measurement protocol. *Appl Sci* 2021;11:4731.

18. Mayte B, Birte K, Rainer KM, Edward MR, Werner A, Anna S, et al. Retrospective 3D analysis of bone regeneration after cystectomy of odontogenic cysts. *J X-Ray Sci Technol* 2020:1-15.

19. Lim HK, Kim JW, Lee UL, Kim JW, Lee H. Risk factor analysis of graft failure with concomitant cyst enucleation of the jaw bone: a retrospective multicenter study. *J Oral Maxillofac Surg* 2017;75:1668-1678.

20. Shamsoddin E, Houshmand B, Golabgiran M. Biomaterial selection for bone augmentation in implant dentistry: a systematic review. *J Adv Pharm Technol Res* 2019;10:46.

21. Jensen T, Schou S, Stavropoulos A, Terheyden H, Holmstrup P. Maxillary sinus floor augmentation with Bio-Oss or Bio-Oss mixed with autogenous bone as graft: a systematic review. *Clin Oral Implants Res* 2012;23:263-273.

22. Myeroff C, Archdeacon M. Autogenous bone graft: donor sites and techniques. *J Bone Joint Surg* 2011;93:2227-2236.

23. Kao ST, Scott DD. A review of bone substitutes. *Oral Maxillofac Surg Clin North Am* 2007;19:513-521.

24. Dimitriou R, Mataliotakis GI, Angoules AG, Kanakaris NK, Giannoudis PV. Complications following autologous bone graft harvesting from the iliac crest and using the RIA: a systematic review. *Injury* 2011;42:S3-S15.

25. Schaaf H, Lendeckel S, Howaldt H-P, Streckbein P. Donor site morbidity after bone harvesting from the anterior iliac crest. *Oral Surg Oral Med Oral*

Pathol Oral Radiol Endod 2010;109:52-58.

26. Sakkas A, Wilde F, Heufelder M, Winter K, Schramm A. Autogenous bone grafts in oral implantology—is it still a "gold standard"? a consecutive review of 279 patients with 456 clinical procedures. *Int J Implant Dent* 2017;3:1-17.

27. Pradel W, Eckelt U, Lauer G. Bone regeneration after enucleation of mandibular cysts: comparing autogenous grafts from tissue-engineered bone and iliac bone. *Oral Surg Oral Med Oral Pathol Oral Radiol Endod* 2006;101:285-290.

28. Ferretti C, Muthray E, Rikhotso E, Reyneke J, Ripamonti U. Reconstruction of 56 mandibular defects with autologous compressed particulate corticocancellous bone grafts. *British J Oral Maxillofac Surg* 2016;54:322-326.

29. Griffin KS, Davis KM, McKinley TO, Anglen JO, Chu T-MG, Boerckel JD, et al. Evolution of bone grafting: bone grafts and tissue engineering strategies for vascularized bone regeneration. *Clin Rev Bone Miner Metab* 2015;13:232-244.

30. Manzano-Moreno FJ, Herrera-Briones FJ, Linares-Recatala M, Ocaña-Peinado FM, Reyes-Botella C, Vallecillo-Capilla MF. Bacterial contamination levels of autogenous bone particles collected by 3 different techniques for harvesting intraoral bone grafts. *J Oral Maxillofac Surg* 2015;73:424-429.

31. Nisyrios T, Karygianni L, Fretwurst T, Nelson K, Hellwig E, Schmelzeisen R, et al. High potential of bacterial adhesion on block bone

graft materials. *Materials* 2020;13:2102.

32. Forssell K, Forssell H, Kahnberg K-E. Recurrence of keratocysts: a long-term follow-up study. *Int J Oral Maxillofac Surg* 1988;17:25-28.

33. Myoung H, Hong SP, Hong SD, Lee JI, Lim CY, Choung PH, et al. Odontogenic keratocyst: review of 256 cases for recurrence and clinicopathologic parameters. *Oral Surg Oral Med Oral Pathol Oral Radiol Endod* 2001;91:328-333.

34. Chrcanovic BR, Gomez RS. Recurrence probability for keratocystic odontogenic tumors: an analysis of 6427 cases. *J Craniomaxillofac Surg* 2017;45:244-251.

35. Gosau M, Draenert FG, Müller S, Frerich B, Bürgers R, Reichert TE, et al. Two modifications in the treatment of keratocystic odontogenic tumors (KCOT) and the use of Carnoy's solution (CS)—a retrospective study lasting between 2 and 10 years. *Clin Oral Invest* 2010;14:27-34.

36. Titinchi F. Protocol for management of odontogenic keratocysts considering recurrence according to treatment methods. *J Korean Assoc Oral Maxillofac Surg* 2020;46:358-360.

37. Al-Moraissi EA, Dahan AA, Alwadeai MS, Oginni FO, Al-Jamali JM, Alkhutari AS, et al. What surgical treatment has the lowest recurrence rate following the management of keratocystic odontogenic tumor?: A large systematic review and meta-analysis. *J Craniomaxillofac Surg* 2017;45:131-144.

38. Mohanty S, Dabas J, Verma A, Gupta S, Urs A, Hemavathy S. Surgical

management of the odontogenic keratocyst: A 20-year experience. *Int J Oral Maxillofac Surg* 2021.

39. Borgiani E, Figge C, Kruck B, Willie BM, Duda GN, Checa S. Age-related changes in the mechanical regulation of bone healing are explained by altered cellular mechanoresponse. *J Bone Miner Res* 2019;34:1923-1937.

40. Lu C, Hansen E, Sapozhnikova A, Hu D, Miclau T, Marcucio RS. Effect of age on vascularization during fracture repair. *J Orthop Res* 2008;26:1384-1389.

41. Kasper G, Mao L, Geissler S, Draycheva A, Trippens J, Kühnisch J, et al. Insights into mesenchymal stem cell aging: involvement of antioxidant defense and actin cytoskeleton. *Stem Cells* 2009;27:1288-1297.

42. Checa S, Hesse B, Roschger P, Aido M, Duda GN, Raum K, et al. Skeletal maturation substantially affects elastic tissue properties in the endosteal and periosteal regions of loaded mice tibiae. *Acta Biomaterialia* 2015;21:154-164.

43. Chiapasco M, Zaniboni M, Rimondini L. Dental implants placed in grafted maxillary sinuses: a retrospective analysis of clinical outcome according to the initial clinical situation and a proposal of defect classification. *Clin Oral Implants Res* 2008;19:416-428.

44. Buchbender M, Neukam FW, Lutz R, Schmitt CM. Treatment of enucleated odontogenic jaw cysts: a systematic review. *Oral Surg Oral Med Oral Pathol Oral Radiol* 2018;125:399-406.

45. Ettl T, Gosau M, Sader R, Reichert TE. Jaw cysts–Filling or no filling after enucleation? A review. *J Craniomaxillofac Surg* 2012;40:485-493.

국문초록

구강악안면영역 낭종의 수술적 제거 후 악골치유 관련 인자에 관한 연구

정용욱
서울대학교 치의학대학원 구강악안면외과학 전공
(지도교수: 서병무)

1. 목 적

구강악안면영역의 골내 낭종 진단 하 낭종제거 수술을 받은 환자들을 대상으로 후향적 연구를 시행하여, 낭종 적출 후 골 회복에 영향을 줄 수 있는 요인들에 대하여 알아보고자 하였다.

2. 방 법

서울대학교 치과병원 구강악안면외과에서 2013년 1월 1일부터 2019년 12월 31일까지 구강악안면영역의 낭종 진단 후 낭종 적출술을 시행 받고, 1년 이상 외래 경과 관찰을 시행한 환자군에 대해 의무기록, 방사선 영상을 이용하여 후향적 연구를 시행하였다. 환자의 성별, 나이, 전신병력, 수술 후 외래 내원 기간 및 횟수, 병소의 진단명, 위치 및 크기, 술 전 감염 여부, 골이식의 시행 여부 및 종류, 조대술의 유무, 병소의 재발, 술 후 합병증 (병적골절, 감각 이상, 술 후 감염), 골 회복의 정도를 조사하였다. 술 후 골 회복의 정도는 수술 1년 후 파노라마 영상에서 결손부의 골 회복이 크기의 위축이 없고. 내부의 방사선투과성 영역이 없을 경우 완전한 치유 (Complete healing)로 나머지 경우에는 불완전한 치유 (Incomplete healing)로 평가하였다. 조사된 자료를 바탕으로 로지스틱 회귀분석 (Logistic regression test)을 시행하였다.

3. 결 과

총 316명의 환자 (남자: 204명, 여자: 112명)를 조사하였다. 환자의 평균 나이는 40세였으며, 평균 경과 관찰 횟수는 8회, 관찰 기간은 121주였다. 조직병리검사 결과 함치성낭종 137 (43.3%) 증례, 치근단낭 67 (21.2%) 증례, 치성각화낭 63 (19.9%) 증례, 비구개관낭 34 (10.7%) 증례, 술후상악낭 7 (2.2%) 증례, 그 외 8 (2.5%) 증례로 확인되었다. 하악 구치부의 낭종이 138 (43.6%) 증례로 발병률이 가장 높았으며, 하악 전치부에서 13 (4.1%) 증례로 발병률이 가장 낮았다. 상악 전치부, 상악 구치부, 하악지까지 낭종이 침범한 경우는 각각 98 (31.0%) 증례, 43 (13.6%) 증례, 24 (7.5%) 증례였다. CT에서 측정한 낭종의 평균 최대 직경은 22 mm였다. 합병증 발생으로는 술 후 감염 50 (15.8%) 증례, 병적 골절 4 (1.2%) 증례, 감각 이상 48 (15.1%) 증례가 있었다.

골 이식은 84 증례(이종골 이식 71 증례, 자가골 이식 13 증례)에서 시행되었다. 술 후 완전한 골 회복은 238 (75.3%) 증례에서 관찰되었고, 78 (24.6%) 증례의 경우 불완전한 골 회복을 보였다.

통계적으로 유의미성을 보인 결과는 다음과 같다. ($p-value < 0.05$) 술 후 감염은 남자의 경우가 유의미하게 더 높았으며 (odds ratio= 3.38; $p-value$= 0.008), 하악 구치부보다 상악 전방부가 적었다. (odds ratio= 0.30; $p-value$= 0.005). 골 이식을 시행하지 않은 경우가 술 후 감염이 가장 적었다. 자가골 이식 (odds ratio= 11.60; $p-value < 0.001$), 및 이종골 이식 시 (odds ratio= 2.88; $p-value = 0.013$) 감염률이 유의미하게 증가하였으며, 자가골 이식의 경우에서 더 많은 감염이 발생하였다. 환자군의 나이가 어릴수록 완전한 골 회복을 보인 경우가 많았다. (odds ratio= 0.96; $p-value < 0.001$). 하악 구치부와 비교했을 때, 상악 구치부의 불완전한 골 회복 양상이 관찰되었다. (odds ratio= 0.08; $p-value < 0.001$). 골 이식을 시행하지 않은 경우보다 이종골을 이식한 경우 완전한 골 회복 양상이 관찰되었으며 (odds ratio= 6.69; $p-value < 0.001$), 자가골 이식을 시행한 경우는 불완전한 골 회복을

보였다. (odds ratio= 0.15; *p−value*= 0.037).

Keyword: 낭종, 합병증, 골회복, 이종골이식
Student Number: 2019−25919