Circ J 2007; **71:** 1904–1911

Clinical Validity of Longitudinal Pre-Ejectional Myocardial Velocity for Identifying the Transmural Extent of Viable Myocardium

—— Early After Reperfusion of an Infarct-Related Coronary Artery ——

Hyung-Kwan Kim, MD*,†; Yong-Jin Kim, MD*,†; Sung-A Chang, MD*,†; Song-Yi Kim, MD*,†; Ho-Joon Jang, MD*,†; Whal Lee, MD**,†; Jin-Shik Park, MD*,†; Dae-Won Sohn, MD*,†; Byung-Hee Oh, MD*,†; Young-Bae Park, MD*,†; Yun-Shik Choi, MD*,†

Background Positive longitudinal pre-ejectional velocity (+PEVL) was recently reported to be a reliable index of myocardial recovery early after successful revascularization in myocardial infarction (MI); that is, it recognizes the transmural extent of viable myocardium. The applicability of PEVL in the real-world clinical setting for identifying the transmural extent of viable myocardium in reperfused recent MI was assessed.

Methods and Results Using tissue Doppler imaging, the resting basal and mid myocardial PEVLs were determined within 3 days after revascularization in 41 consecutive patients with recent MI. Infarct thickness was semi-quantified using delayed gadolinium-enhanced magnetic resonance imaging (MRI) at baseline and at 6-month follow up to differentiate transmural from nontransmural MI. The proportion of segments showing the presence of +PEVL was not significantly changed as infarct thickness increased (p=0.2), with 66.2% having +PEVL even in segments involving >75% transmural infarction. Moreover, +PEVL was found in a large fraction of segments with akinesia (70.4%). Specificity and negative predictive value of +PEVL for assessing infarct nontransmurality were disappointingly low (32.0% and 26.9%, respectively). All of these results were not altered when the 6-month follow-up MRI was done.

Conclusions +PEVL cannot be regarded as a reliable marker for predicting the transmural extent of viable myocardium in recent MI. (*Circ J* 2007; **71:** 1904–1911)

Key Words: Magnetic resonance imaging; Myocardial infarction; Pre-ejectional velocity; Tissue Doppler imaging

The early identification of viable myocardial extent after reperfusion therapy in patients with myocardial infarction (MI) is of substantial clinical value, in terms of patient management and predicting prognosis.[1–6] Because myocardial reperfusion after a reversible ischemic insult frequently results in a protracted contractile dysfunction, which is often described as 'myocardial stunning',[7,8] conventional wall motion assessment is limited in detecting viable myocardium with clinically acceptable confidence. Although dobutamine stress echocardiography, magnetic resonance imaging (MRI) or nuclear myocardial perfusion imaging has been traditionally used to assess myocardial viability, their applications are, in part, limited by their cost, availability, and variability.

Interestingly, 2 previous studies suggested that resting longitudinal pre-ejectional velocity (PEVL) measured at the apical echocardiographic views by tissue Doppler imaging (TDI) is a simple and accurate parameter that allows the prediction of contractile recovery after percutaneous coronary intervention (PCI) in patients with occluded coronary artery disease, implying the ability of PEVL to identify the extent of viable myocardium.[9,10] However, because a large number of patients with coronary artery disease comprise those with multi-vessel disease, not just a single-vessel disease, and wide spectrum of the left ventricular (LV) systolic function, this potential association between PEVL and myocardial viability requires confirmation before a general application of this attractive index can be made to a cohort of patients with multi-vessel coronary artery disease. Therefore, the purpose of this study was to apply this intriguing new TDI parameter to patients with recent MI who also had single- and multi-vessel coronary artery disease, and to assess its reliability in determining the transmural extent of viable myocardium, using delayed-enhanced MRI as a reference modality.

(Received May 21, 2007; revised manuscript received August 21, 2007; accepted August 23, 2007)

**Department of Internal Medicine, Cardiovascular Center, **Department of Diagnostic Radiology, †Seoul National University College of Medicine, Seoul National University Hospital, Seoul, Korea*

Part of this work was presented at the Annual Scientific Session of the American Heart Association, Chicago, IL, USA, November 12–15, 2006.

Part of this work was supported by a grant from the Korean Institute of Medicine, Seoul, Korea.

Mailing address: Yong-Jin Kim, MD, Division of Cardiology, Department of Internal Medicine, Seoul National University College of Medicine, 28 Yongon-dong, Chongno-gu, Seoul 110-744, Korea. E-mail: kimdamas@snu.ac.kr

Methods

Study Population

Forty-one consecutive patients who had experienced a first acute or subacute MI (age 55.6±11.6 years; range, 31–78 years) were prospectively recruited. All of them underwent successful PCI of an infarct-related coronary artery, and no significant coronary stenoses requiring an additional revascularization procedure remained after PCI in any patient. Acute MI was defined as typical ischemic chest pain lasting for at least 30 min in combination with either an elevation of cardiac-specific troponins or an electrocardiographic change of ST-segment elevation within 24 h from symptom onset and subacute MI, with a time gap between onset of symptoms and PCI performance from 24 h to <2 weeks. Patients with persistent severe heart failure (Killip class III or IV and/or LV ejection fraction (LVEF) <20%), uncontrolled myocardial ischemia or ventricular tachycardia, infarct-related arteries unsuitable for PCI, unsuccessful PCI, left bundle-branch block, atrial fibrillation, or more than mild valvular regurgitation were excluded. Whether or not patients enrolled in the present study had multi-vessel coronary artery disease was not in the consideration of the patient enrolment.

The study protocol was approved by the Institutional Review Board of the Seoul National University Hospital, and written informed consent was obtained from all participants before study enrollment.

Echocardiography

With the patient in a supine left lateral position, a comprehensive transthoracic echocardiography was performed within 72 h after PCI, using a commercially available echocardiographic machine (Vivid 7, GE Medical System, Horten, Norway). Routine standard echocardiographic examinations included LVEF by biplane modified Simpson's method and early (E) and late transmitral inflow velocities, and deceleration time of E velocity by pulsed-wave Doppler with the sample volume placed between the tips of mitral leaflets.

Three consecutive heart beats at the apical 4-, 2-, and 3-chamber images were digitally captured onto a magneto-optical disc in a cineloop format for later offline analysis of TDI data, using a customized dedicated software package (EchoPac vers. 5.0.1 for PC, GE Medical System, Horten, Norway). Gain and filter settings were carefully adjusted for better acquisition of myocardial tissue signals. Frame rates were at least above 120 frames/second, which allows for a temporal resolution of <9 ms, depending on the width and depth of the images obtained. A sample volume of 5× 5 mm was placed at the center of the basal and mid myocardial segments as parallel as possible to the motional vector of the myocardial segments being analyzed. All apical segments were discarded from the analyses due to the difficulty in aligning the Doppler beam with the longitudinal motion vector.

Motion of the anterior mitral leaflet was tracked throughout the cardiac cycle by the color M-mode TDI technique to determine cardiac time intervals, as described elsewhere.[11] Longitudinal systolic (SL') and early diastolic (EL') myocardial tissue velocities, as well as longitudinal peak velocity during the pre-ejectional period (PEVL), were obtained using a 16-segments model. When a biphasic PEVL pattern was encountered, the dominant one over the other, in terms of an absolute value, was chosen for subsequent analysis. Average values for PEVL were taken from 3 consecutive cardiac cycles in each patient. In addition, as a categorical term, a positive PEVL value (+PEVL) was considered an indicator of myocardial viability, whereas a negative PEVL value (–PEVL) was regarded as a nonviable marker, according to previous studies.[12,13] Sensitivity, specificity, positive and negative predictive values, and test accuracy of +PEVL for the prediction of nontransmural MI were subsequently assessed in reference to the baseline and 6-month follow-up cardiac MRIs.

Measurement of Infarct Thickness by Delayed Hyperenhanced Cardiac MRI

Cardiac MRI (Sonata 1.5T, Siemens, Erlangen, Germany) was performed after PCI using a phased-array coil wrapped around the chest. The acquisition time gap between echocardiography and cardiac MRI was fewer than 3 days. After localizing the heart, long axis and short axis cine images with a slice thickness of 8 mm and a gap of 2 mm were obtained throughout the entire LV using contiguous 2-dimensional steady-state precession sequences. After administering an intravenous bolus of gadodiamide (0.1 mmol/kg) at a rate of 5 ml/s using an infusion pump, delayed enhancement imaging was obtained with phase-sensitive inversion recovery sequence. Images were acquired during the patient's short breath-holding at end-expiration. Using ARGUS software (Siemens), infarct transmurality in the regions of interest was evaluated by an investigator blinded to the echocardiographic TDI results. For 31 patients (368 segments), cardiac MRI was repeated 6 months after the index MI and PCI by the same protocol. Quantification of the transmural extent of delayed enhancement was determined on a 5-grade scale basis using a 16-segments model as follows: 0 represents no hyperenhancement relative to the entire myocardial wall thickness; 1, 1–25% hyperenhancement; 2, 26–50% hyperenhancement; 3, 51–75% hyperenhancement; and 4, 76–100% hyperenhancement.[14] Regional wall motion score of an individual myocardium was also coded for each myocardium on a 3-grade scale basis: 1, normokinesia; 2, hypokinesia; and 3, akinesia. The analyses of cardiac MRIs were performed by one expert (WL), who was unaware of patient clinical and echocardiographic data.

Inter- and Intra-Observer Variabilities for PEVL Measurements

Inter- and intra-observer variabilities for PEVL measurements were determined by analyzing 60 segments in 5 randomly selected patients by 2 independent blinded observers, and these were further analyzed using least squares-fit linear regression analysis with SEE.

Statistical Analysis

All values are expressed as the mean ± SD or as a percentage. Proportion of the presence of +PEVL was compared using linear-by-linear association test in reference to each category of infarct thickness. Fisher's exact test was employed to evaluate differences in the failure rate of PEVL measurements according to the coronary circulation characteristics; that is, anterior (mid inferoseptal, basal to mid anterior, and basal to mid anteroseptal segments) or posterior (basal inferoseptal, basal to mid anterolateral, basal to mid inferior, and basal to mid inferolateral segments) circulation. Test accuracy and the positive and negative predictive values of color-coded TDI-derived +PEVL for differentiating transmural from nontransmural infarction in a given myocar-

Table 1 Clinical Characteristics and Conventional Echocardiographic Parameters of the Study Patients

	Study patients (n=41)
Clinical characteristics	
Demographics	
Age (years)	*55.6±11.6*
Male gender (%)	*34 (82.9%)*
BMI (kg/m²)	*24.2±2.8*
Risk factors	
Diabetes mellitus	*10 (24.4%)*
Hypertension	*13 (31.7%)*
*Smoking**	*27 (65.9%)*
Dyslipidemia	*8 (19.5%)*
Infarct-related artery	
LAD:LCX:RCA	*22:4:15*
STEMI:NSTEMI	*32:9*
Disease severity	
1-:2-:3-vessel disease	*21:13:7*
Medical treatments	
Aspirin or clopidogrel	*41 (100%)*
β-blocker	*26 (63.4%)*
ACEI or ARB	*36 (87.8%)*
Statin	*37 (90.2%)*
Conventional echocardiographic parameters	
LV systolic function	
LVESV (ml)	*62.4±30.5 (range, 29.1–214.2)*
LVEDV (ml)	*126.8±33.9 (range, 67.8–272.1)*
LVEF (%)	*52.2±9.3 (range, 21.3–66.4)*
LV diastolic function	
E (m/s)	*0.66±0.19*
A (m/s)	*0.63±0.18*
E/A ratio	*1.14±0.47*
DT (m/s)	*186.5±49.0*

**'Smoking' means active smokers as well as those ex-smokers who stopped smoking <1 year before enrollment.*
BMI, body mass index; LAD, left anterior descending coronary artery; LCX, left circumflex coronary artery; RCA, right coronary artery; (N)STEMI, (Non) ST-elevation myocardial infarction; ACEI, angiotensin-converting enzyme inhibitors; ARB, angiotensin receptor blockers; LV, left ventricle; LVESV (LVEDV), left ventricular end-systolic (end-diastolic) volume; E, early mitral inflow velocity; A, late mitral inflow velocity; DT, deceleration time of mitral E velocity.

dium were calculated using the following equations:

Test accuracy=(True positive+True negative)/Total number of tests performed;
Positive predictive value=True positive/(True positive+False positive); and
Negative predictive value=True negative/(True negative+False negative).

All statistical analyses were performed using SPSS version 13.0 (SPSS Inc, Chicago, IL, USA), and a p value of <0.05 was considered statistically significant.

Results

Clinical characteristics and conventional echocardiographic parameters are described in Table 1. Overall, a total of 464 myocardial segments were analyzed for S_L', E_L' and PEV_L measurements. Among these, 17 myocardial segments (3.7%) were considered unfeasible for reliable assessments of PEV_L, and S_L' and E_L' values were not procurable in 16 myocardial segments (3.67%). The number of myocardial segments subtended by anterior circulation from the left anterior descending coronary artery was 192 (41.4%), whereas the number of those supplied by posterior circulation from the left circumflex coronary artery and/or right

Table 2 Relationship Between S_L' or E_L' and the Infarct Thickness Estimated by the Baseline and 6-Month Follow-up Cardiac MRI

	Baseline MRI-determined infarct thickness							*6-Month follow-up MRI-determined infarct thickness*						
	0%	*1–25%*	*26–50%*	*51–75%*	*76–100%*	*Total*	*p value*	*0%*	*1–25%*	*26–50%*	*51–75%*	*76–100%*	*Total*	*p value*
S_L' (m/s)	*4.3±1.8*	*3.3±2.2*	*3.2±1.3*	*3.9±1.2*	*4.2±1.5*	*4.2±1.8*	*0.14*	*5.2±11.3*	*4.9±1.7*	*4.0±1.6*	*3.8±1.5*	*3.9±2.0*	*4.8±9.5*	*0.88*
E_L' (m/s)	*−4.6±2.4*	*−4.5±2.6*	*−3.5±1.7*	*−4.6±3.0*	*−4.8±2.1*	*−4.6±2.4*	*0.21*	*−4.6±2.5*	*−5.7±2.2*	*−4.7±2.5*	*−4.4±2.3*	*−4.1±2.5*	*−4.6±2.5*	*0.36*

S_L', longitudinal systolic myocardial velocity; E_L', early diastolic myocardial velocity; MRI, mgnetic resonance imaging.

coronary artery was 272 (58.6%). In terms of the failure of PEVL measurements, no significant differences were observed between segments from anterior and posterior circulation (9 segments (4.7%) vs 8 segments (2.9%), p=0.33).

Relation Between SL' or EL' Values and Cardiac MRI-Determined Infarct Thickness

As expected, SL' failed to differentiate transmural from nontransmural infarction (4.2±1.8 m/s vs 4.1±1.1 m/s with the baseline MRI as a reference standard, p=0.76; 3.8±1.7 m/s vs 5.0±10.4 m/s with the 6-month follow-up MRI as a reference standard, p=0.36). Moreover, SL' values stratified by the baseline MRI-based infarct thickness (0%, 1–25%, 26–50%, 51–75%, and 76–100% hyperenhancement) were 4.3±1.8 m/s, 3.3±2.2 m/s, 3.2±1.3 m/s, 3.9±1.2 m/s, and 4.2±1.5 m/s, respectively (p=0.14). The corresponding values in relation to the 6-month follow-up MRI were 5.2±11.2 m/s, 4.9±1.7 m/s, 4.0±1.6 m/s, 3.8±1.5 m/s, and 3.9±2.0 m/s, respectively (p=0.88) (Table 2), confirming that SL' is unhelpful for estimating the magnitude of infarct thickness. Indeed, all SL' values feasible for analysis displayed positive values regardless of the infarct transmurality.

With the baseline cardiac MRI as a reference, EL', similarly to SL', was unsuccessful for differentiating transmural from nontransmural MI (–4.3±2.4 m/s vs –4.7±2.5 m/s; p=0.23), indicative of its limited power for predicting myocardial viability in the setting of recent MI. This was also true for the relation between EL' and infarct thickness as determined by both the baseline and the 6-month follow-up cardiac MRIs (Table 2). All EL' values feasible for analysis displayed negative values irrespective of infarct thickness.

For further supporting evidence, we included only 114 segments with regional wall motion abnormalities on the baseline cardiac MRI, among which 5 segments were discarded because of failure to obtain a PEVL value. For this subgroup analyses, again, both SL' and EL' did not show any differences between segments with transmural and those with nontransmural infarction (3.9±1.8 m/s vs 3.4±1.7 m/s, p=0.14 for SL' and –4.5±2.3 m/s vs –4.4±1.7 m/s, p=0.84 for EL'), again upholding the concept that TDI-derived SL' and EL' are unhelpful for differentiating infarct transmurality.

Relation Between PEVL and Cardiac MRI-Determined Infarct Thickness

In Reference to the Baseline Cardiac MRI as a Reference Modality No statistically significant relationship was found between PEVL (treated as a continuous variable) and the different categories of MRI-determined infarct thickness (p=0.18). In addition, the proportion of myocardial segments with +PEVL in each category failed to show any meaningful trend as MRI-determined infarct thickness increased (p=0.2) (Table 3). Among 323 segments with delayed enhancement involving <25% of the myocardial wall, 241 segments (74.6%) clearly showed +PEVL, whereas 47 of 71 segments (66.2%) with >75% extent of infarction demonstrated +PEVL. Likewise, based on the subgroup analyses using 109 segments with regional wall motion abnormalities on the baseline cardiac MRI, there was no significant relationship between PEVL (as a continuous variable) and MRI-determined infarct thickness (p=0.11). The proportion of segments showing +PEVL was not significantly different throughout the categories stratified according to infarct thickness (p=0.35).

In Reference to the 6-Month Follow-up Cardiac MRI as

Table 3 Comparison of the Proportion of Segments With +PEVL According to Cardiac MRI-Determined Infarct Thickness

	Baseline MRI-determined infarct thickness							*6-Month follow-up MRI-determined infarct thickness*						
	0%	*1–25%*	*26–50%*	*51–75%*	*76–100%*	*Total*	*p value*	*0%*	*1–25%*	*26–50%*	*51–75%*	*76–100%*	*Total*	*p value*
+PEVL	*236*	*5*	*19*	*21*	*47*	*328*		*195*	*14*	*20*	*25*	*17*	*271*	
% within infarct thickness	*74.7%*	*71.4%*	*79.2%*	*72.4%*	*66.2%*			*78.0%*	*93.3%*	*74.1%*	*78.1%*	*56.7%*		
–PEVL	*80*	*2*	*5*	*8*	*24*	*119*	*0.2*	*55*	*1*	*7*	*7*	*13*	*83*	*0.15*
% within infarct thickness	*25.3%*	*28.6%*	*20.8%*	*27.6%*	*33.8%*			*22.0%*	*6.7%*	*25.9%*	*21.9%*	*43.3%*		
Total	*316*	*7*	*24*	*29*	*71*	*447*		*319*	*15*	*27*	*32*	*30*	*354*	

PEVL, longitudinal pre-ejectional velocity. Other abbreviation see in Table 2.

Table 4 Comparison of the Proportion of Segments With +PEVL According to Regional Myocardial Wall Motion Determined by Cardiac MRI

	Regional myocardial wall motion			*p value*
	Normal	*Hypokinesia*	*Akinesia*	
+PEVL	*251*	*18*	*59*	
% within PEVL category	*76.5%*	*5.5%*	*18.0%*	
% within regional wall motion	*74.3%*	*72.0%*	*70.2%*	*0.45*
–PEVL	*87*	*7*	*25*	
% within PEVL category	*73.1%*	*5.9%*	*21.0%*	
% within regional wall motion	*25.7%*	*28.0%*	*29.8%*	
Total	*338*	*25*	*84*	

Abbreviations see in Tables 2,3.

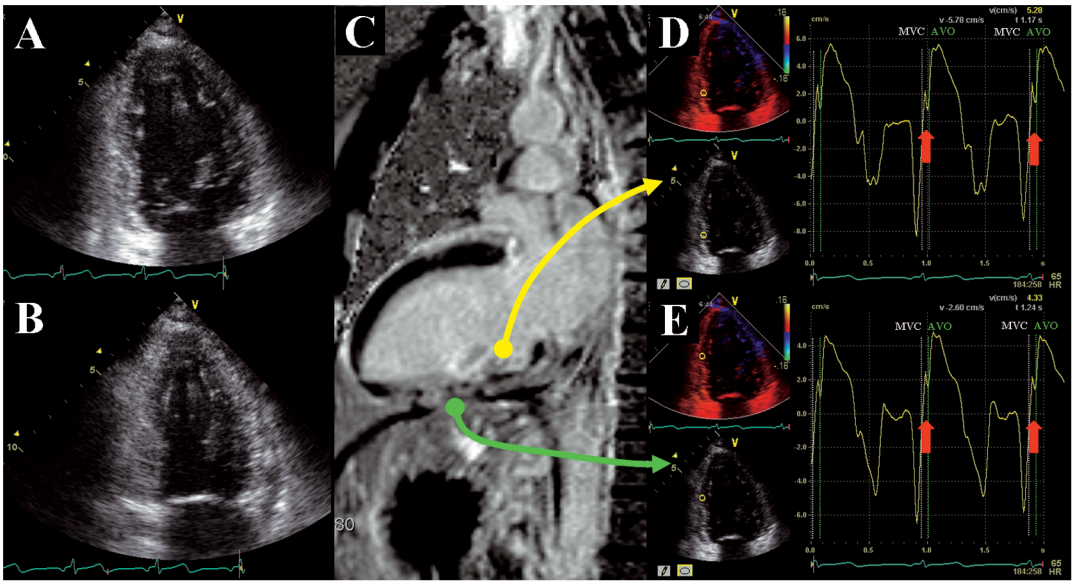

Fig 1. A representative example of a tissue Doppler imaging (TDI) tracing of a false positive result in a patient with myocardial infarction (MI). This patient experienced MI in the area of the right coronary artery 1 day before enrolling in the study, which is evident based on the akinetic basal and mid inferior myocardial segments in end-diastole (A) and end-systole (B). Even if cardiac magnetic resonance imaging with delayed gadolinium enhancement well displayed the transmural infarction of these myocardial segments without any expectation of myocardial functional recovery (C), positive longitudinal pre-ejectional velocity was definitely demonstrated by TDI analysis (D, E). In this patient, the left ventricular apex showed normal wall motion.

a Reference Modality Again, we found no significant trend between PEVL and the different categories of the 6-month follow-up MRI-determined infarct thickness (p=0.16). In terms of the proportion of segments with +PEVL in each category, no statistical significance could be demonstrated (p=0.15) (Table 3). Of 368 myocardial segments feasible for analysis on the 6-month follow-up MRI, 17 of 30 segments (56.7%) with delayed enhancement of >75% displayed +PEVL. In contrast, 265 segments showed <25% transmural necrosis, among which +PEVL was noted in 209 segments (78.9%).

Regional Wall Motion Assessed by Cardiac MRI and its Relation to the Presence of +PEVL

On the basis of the baseline cardiac MRI, +PEVL was found in a large proportion of segments with akinesia (70.2%), although the proportion of segments with +PEVL was highest for segments with normokinesia (74.3%). This was also true for analyses based on the 6-month follow-up MRI, with 71.7% of akinetic segments showing +PEVL. On the whole, most myocardial segments displayed +PEVL, irrespective of regional wall motion score (Table 4). A representative example of +PEVL in transmural MI; that is, a false positive result, is clearly illustrated in Fig 1, which shows +PEVL was manifested in the basal and mid inferior myocardial walls, in which transmural MI was documented by delayed-enhanced cardiac MRI.

Similar results were derived from analyses using 109 segments with regional wall motion abnormalities on the baseline cardiac MRI; that is, +PEVL was consistently found in most myocardial segments showing dysfunctional motion (18 of 25 segments (72.0%) for hypokinetic segments vs 59 of 84 segments (70.2%) for akinetic segments; p=0.99).

Ability of +PEVL to Differentiate Transmural From Nontransmural MI

In an attempt to simply examine the ability of +PEVL to differentiate transmural from nontransmural myocardial necrosis, all myocardial segments were assigned to either a nontransmural infarction group, involving only subendocar-

dial layers (ie, the extent of infarct thickness is <50%), or a transmural infarction group, in which the subendocardial layer and any degree of the epicardial layer were involved (ie, the extent of infarct thickness is ≥50%). Based on the baseline cardiac MRI, the sensitivity, specificity, positive and negative predictive values, and test accuracy of +PEVL were 74.9%, 32.0%, 79.3%, 26.9%, and 62.9%, respectively, for the prediction of the nontransmural infarction of a particular myocardial segment. The corresponding values for patients with single-vessel coronary artery disease were 70.8%, 26.9%, 72.0%, 25.7%, and 58.8%, respectively. The corresponding values obtained from the 6-month follow-up cardiac MRI are summarized in Table 5, and show no significant differences when compared with those derived from the baseline MRI.

When the same analyses were conducted using only 105 segments with regional wall motion abnormalities on the baseline cardiac MRI, the sensitivity, specificity, positive and negative predictive values, and test accuracy of +PEVL were 60.5%, 32.4%, 37.7%, 71.9%, and 47.7%, respectively, for the prediction of the nontransmural infarction of a particular myocardial segment. These results strongly advocate that the overall ability of +PEVL to predict nontransmural infarction is limited.

Intra- and Inter-Observer Variabilities for Measuring PEVL

Inter- and intra-observer variabilities for PEVL were determined by 2 independent blinded observers who analyzed 5 randomly selected patients. Two observers showed a correlation coefficient of r=0.92 (SEE=0.69). In terms of intra-observer variability, the correlation was found to be r=0.95 (SEE=0.55). The results concerning the presence or absence of +PEVL reported by 2 independent observers were consistent in 59 out of 60 segments (98.3%).

Table 5 Test Accuracy, Sensitivity, Specificity, and Positive and Negative Predictive Values for All Myocardial Segments

	Baseline MRI-based (n=464)	*6-Month follow-up MRI-based (n=368)*
Test accuracy	*62.9%*	*70.1%*
Sensitivity	*74.9%*	*78.4%*
Specificity	*32.0%*	*31.7%*
Positive predictive value	*79.3%*	*84.1%*
Negative predictive value	*26.9%*	*24.1%*

Abbreviation see in Table 2.

Discussion

TDI is a non-invasive, versatile echocardiographic technique capable of accurately measuring brief velocity changes in the myocardium with the help of its high temporal resolution,[15–17] which enables both radial pre-ejection velocity (PEVR) and PEVL to be easily measured. Normal myocardial velocity pattern during the pre-ejectional period has been described elsewhere.[8,19] A number of studies have addressed the diagnostic potential of TDI in the assessment of regional myocardial function.[15,19,20] However, most studies have focused on systolic and early diastolic myocardial velocities, and myocardial velocity during the pre-ejectional period has received less attention. Moreover, the utilization of SL' for determining the infarct transmurality of a particular myocardium at risk is known to be limited due to tethering and translational effects.[20,21]

Recently, Pislaru et al devised an intracardiac approach to apply PEVR (not PEVL) to the assessment of the extent of myocardial necrosis.[12] They demonstrated that a decrease in +PEVR correlates better than systolic myocardial velocity with the transmural extent of necrosis. A more recent animal experimental study suggested that PEVL is highly sensitive to changes in blood supply and that its use could make TDI a more powerful tool for quantifying regional myocardial function.[13] Even more recently, using a transthoracic approach, Penicka et al showed the usefulness of PEVL for predicting the recovery of contractile function during follow up in the setting of recent MI and a single-vessel coronary artery disease.[9] In their study, they hypothesized that the tethering effect might be restricted during the pre-ejectional period, which might provide PEVL with the ability to reflect myocardial viability with acceptable overall sensitivity, specificity and accuracy. Although smaller than those during the systolic or diastolic period, we believe that tethering effects during the pre-ejection period are unlikely to be negligible. As supporting evidence, a decrease in the longitudinal LV length before aortic valve opening was well demonstrated with high-speed cineventriculography.[22] Again, this is advocated by the fact that longitudinal pre-ejectional myocardial displacement can constitute 14% of the total longitudinal myocardial displacement, confirming the occurrence of a 'LV reshaping process' during the pre-ejectional period and, as such, the possibility of the generation of tethering force during this period.[23] This is especially true in a situation in which the reference point (ie, the position of the transducer) is located just above the apical myocardium (ie, echocardiographic apical views), toward which the rest of the myocardial segments move.

In the present study, for comprehensive assessment of the clinical validity of +PEVL value relative to the baseline, as well as the 6-month follow-up cardiac MRIs, we recruited patients with recent MI and single- as well as multi-vessel coronary artery diseases. Surprisingly, most myocardial segments with an infarct extent of >75% demonstrated +PEVL. According to an earlier study using cardiac MRI, which was applied to the infarcted human heart, the magnitude of segmental functional recovery gradually diminished with an increasing degree of transmural extent of necrosis, being completely absent in segments showing >75% transmural extent of delayed hyperenhancement.[14] Accordingly, +PEVL in the segments with delayed hyperenhancement involving >75% of myocardial thickness can be considered to be a false positive result in the context of myocardial viability. Based on the results of the present study, despite enthusiasm offered by resting PEVL of an individual myocardium for the prediction of myocardial viability or in the estimation of the transmural extent of myocardial necrosis in the setting of recent MI, the clinical value of resting PEVL is practically limited owing to its low specificity and low negative predictive value, regardless of the severity of coronary artery disease (ie, single-vessel vs multi-vessel disease). Our results are in accordance with those by Lyseggen et al, who reported that there is no consistent relation between +PEVL and regional myocardial contractility in an experimental model.[24] They also concluded that +PEVL is mostly load-dependent and does not reflect contractile dysfunction during ischemia.[24]

We believe that this practical limitation is partly attributable to the tethering effect caused by actively contracting the adjacent myocardium. This is clearly depicted in Fig 1,

in which akinetic movements in conjunction with transmural infarction in the basal and mid inferior walls strongly suggest the absence of viable myocardium. Even in this situation, a more apically oriented normokinetic apicoinferior wall has repercussions on the longitudinal movements of the basal and mid inferior walls, which generate +PEVL due to a tethering effect, despite the presence of transmural infarction in these segments.

Resting PEVR at the parasternal short axis view might be less influenced by the tethering effect if the reference point is located at the center of the LV cavity, as performed by Pislaru and colleagues,[12] and has a special advantage over the longitudinal approach currently used in a transthoracic fashion. Unfortunately, however, the current TDI technique using transthoracic echocardiography can provide myocardial velocities only from anteroseptal and inferolateral walls owing to its angle-dependency. Although intracardiac echocardiography enables comprehensive alignment of the Doppler beam with radial myocardial movements, it is less available in daily clinical patient care than transthoracic echocardiography. Furthermore, technical developments of Doppler echocardiography are expected for the sake of more easy acquisition of the resting PEVR with transthoracic approach.

The present study has some limitations that need to be addressed. First, the purported angle-dependency of the TDI technique is an inherent limitation and, thus, might affect the measurement of absolute PEVL values. However, we obtained not only the absolute value of PEVL, but also the presence or absence of +PEVL as a categorical variable. Second, the absolute PEVL values are largely dependent on the myocardial segments examined. The determination of PEVL by strain rate imaging may be a solution to overcoming the tethering effect and the variability of its value depending on the segments assessed, unlike its parent methodology, TDI. However, although strain rate imaging technique is theoretically a promising and interesting tool, especially thanks to its independence of tethering or translational effect, it is highly susceptible to signal noise and, as such, inter-observer correlation is not satisfactory,[25–27] which is an important pragmatic limitation that compromises the clinical acceptance of strain rate imaging technique. Third, the apical segments were omitted from the analyses, which could not be avoided because of the inherent limitation of TDI; that is, angle-dependency. Fourth, we used cardiac MRI-determined infarct thickness as a surrogate index for viability, not a contractile functional recovery with cineangiography in contrast to a previous study.[6] Although myocardial contractile recovery provides more direct evidence for the viability of a given myocardial segment, infarct transmurality assessed by delayed enhanced cardiac MRI is a more sensitive and objective marker for cardiac remodeling, delayed myocardial contractile recovery, and prognosis.[14] Thus, we do not believe that the results of the present study are likely to be altered by this methodological discrepancy.

In conclusion, despite the emerging interest in the preejectional phase and its corresponding myocardial velocity, in a real-world clinical setting encompassing patients with multi-vessel coronary artery disease, resting +PEVL has limited potential for identifying the transmural extent of viable myocardium in patients with reperfused recent MI. Whether or not resting +PEVR enables improved recognition of functional recovery or infarct transmurality of an individual myocardium in the human heart requires further study.

References

1. Braunwald E, Pfeffer MA. Ventricular enlargement and remodeling following acute myocardial infarction: Mechanisms and management. *Am J Cardiol* 1991; **68:** 1D–6D.
2. Bolognese L, Cerisano G, Buonamici P, Santini A, Santoro GM, Antoniucci D, et al. Influence of infarct-zone viability on left ventricular remodeling after acute myocardial infarction. *Circulation* 1997; **96:** 3353–3359.
3. Thanavaro S, Krone RJ, Kleiger RE, Province MA, Miller JP, deMello VR, et al. In-hospital prognosis of patients with first nontransmural and transmural infarctions. *Circulation* 1980; **61:** 29–33.
4. Tani S, Nagao K, Watanabe I, Kikushima K, Watanabe K, Anazawa T, et al. Increasingly well-preserved left ventricular function in hospital survivors with acute myocardial infarction: Effect of early and complete reperfusion strategy on left ventricular remodeling. *Circ J* 2007; **71:** 180–185.
5. Lee SH, Choi SH, Choi S, Jung JH, Lee N, Choi YJ, et al. Impact of chronotropic effect of cilostazol after acute myocardial infarction: Insights from change in left ventricular volume and function. *Circ J* 2007; **71:** 106–111.
6. Nagashima M, Itoh A, Otsuka M, Kasanuki H, Haze K. Reperfusion phenomenon is a strong predictor of left ventricular remodelling after acute myocardial infarction. *Circ J* 2005; **69:** 884–889.
7. Braunwald E, Kloner RA. The stunned myocardium: Prolonged, postischemic ventricular dysfunction. *Circulation* 1982; **66:** 1146–1149.
8. Heyndrickx GR, Millard RW, McRitchie RJ, Maroko PR, Vatner SF. Regional myocardial functional and electrophysiological alterations after brief coronary artery occlusion in conscious dogs. *J Clin Invest* 1975; **56:** 978–985.
9. Penicka M, Bartunek J, Wijns W, De Wolf I, Heyndrickx GR, De Raedt H, et al. Tissue Doppler imaging predicts recovery of left ventricular function after recanalization of an occluded coronary artery. *J Am Coll Cardiol* 2004; **43:** 85–91.
10. Penicka M, Tousek P, De Bruyne B, Wijns W, Lang O, Madaric J, et al. Myocardial positive pre-ejection velocity accurately detects presence of viable myocardium, predicts recovery of left ventricular function and bears a prognostic value after surgical revascularization. *Eur Heart J* 2007; **28:** 1366–1373.
11. Kjaergaard J, Hassager C, Oh JK, Kristensen JH, Berning J, Sogaard P. Measurement of cardiac time intervals by Doppler tissue M-mode imaging of the anterior mitral leaflet. *J Am Soc Echocardiogr* 2005; **18:** 1058–1065.
12. Pislaru C, Bruce CJ, Belohlavek M, Seward JB, Greenleaf JF. Intracardiac measurement of pre-ejection myocardial velocities estimates the transmural extent of viable myocardium early after reperfusion in acute myocardial infarction. *J Am Coll Cardiol* 2001; **38:** 1748–1756.
13. Edvardsen T, Urheim S, Skulstad H, Steine K, Ihlen H, Smiseth OA. Quantification of left ventricular systolic function by tissue Doppler echocardiography: Added value of measuring pre- and postejection velocities in ischemic myocardium. *Circulation* 2002; **105:** 2071–2077.
14. Kim RJ, Wu E, Rafael A, Chen EL, Parker MA, Simonetti O, et al. The use of contrast-enhanced magnetic resonance imaging to identify reversible myocardial dysfunction. *N Engl J Med* 2000; **343:** 1445–1453.
15. Sutherland GR, Stewart MJ, Groundstroem KW, Moran CM, Fleming A, Guell-Peris FJ, et al. Color Doppler myocardial imaging: A new technique for the assessment of myocardial function. *J Am Soc Echocardiogr* 1994; **7:** 441–458.
16. Bach DS, Armstrong WF, Donovan CL, Muller DW. Quantitative Doppler tissue imaging for assessment of regional myocardial velocities during transient ischemia and reperfusion. *Am Heart J* 1996; **132:** 721–725.
17. Sohn DW, Chai IH, Lee DJ, Kim HC, Kim HS, Oh BH, et al. Assessment of mitral annulus velocity by Doppler tissue imaging in the evaluation of left ventricular diastolic function. *J Am Coll Cardiol* 1997; **30:** 474–480.
18. Pellerin D, Berdeaux A, Cohen L, Giudicelli JF, Witchitz S, Veyrat C. Pre-ejectional left ventricular wall motions studied on conscious dogs using Doppler myocardial imaging: Relationships with indices of left ventricular function. *Ultrasound Med Biol* 1998; **24:** 1271–1283.
19. Garcia MJ, Rodriguez L, Ares M, Griffin BP, Klein AL, Stewart WJ, et al. Myocardial wall velocity assessment by pulsed Doppler tissue imaging: Characteristic findings in normal subjects. *Am Heart J* 1996; **132:** 648–656.
20. Wilkenshoff UM, Sovany A, Wigstrom L, Olstad B, Lindstrom L,

Engvall J, et al. Regional mean systolic myocardial velocity estimation by real-time color Doppler myocardial imaging: A new technique for quantifying regional systolic function. *J Am Soc Echocardiogr* 1998; **11:** 683–692.
21. Hatle L, Sutherland GR. Regional myocardial function--a new approach. *Eur Heart J* 2000; **21:** 1337–1357.
22. Karliner JS, Bouchard RJ, Gault JH. Dimensional changes of the human left ventricle prior to aortic valve opening: A cineangiographic study in patients with and without left heart disease. *Circulation* 1971; **44:** 312–322.
23. Lind B, Eriksson M, Roumina S, Nowak J, Brodin LA. Longitudinal isovolumic displacement of the left ventricular myocardium assessed by tissue velocity echocardiography in healthy individuals. *J Am Soc Echocardiogr* 2006; **19:** 255–265.
24. Lyseggen E, Rabben SI, Skulstad H, Urheim S, Risoe C, Smiseth OA. Myocardial acceleration during isovolumic contraction: Relationship to contractility. *Circulation* 2005; **111:** 1362–1369.
25. Hanekom L, Jenkins C, Jeffries L, Case C, Mundy J, Hawley C, et al. Incremental value of strain rate analysis as an adjunct to wall-motion scoring for assessment of myocardial viability by dobutamine echocardiography: A follow-up study after revascularization. *Circulation* 2005; **112:** 3892–3900.
26. Marwick TH. Measurement of strain and strain rate by echocardiography: Ready for prime time? *J Am Coll Cardiol* 2006; **47:** 1313–1327.
27. Cho GY, Chan J, Leano R, Strudwick M, Marwick TH. Comparison of two-dimensional speckle and tissue velocity based strain and validation with harmonic phase magnetic resonance imaging. *Am J Cardiol* 2006; **97:** 1661–1666.