수의학박사학위논문

Pathogenesis of African Swine Fever Occurring in Asia

아시아에서 발생하는 아프리카 돼지 열병의 병인론

2022년 8월

서울대학교 대학원

수의학과 수의병인생물학 및 예방수의학 전공

오 태 환

獸 醫 學 博 士 學 位 論 文

Pathogenesis of African Swine Fever Occurring in Asia

아시아에서 발생하는 아프리카 돼지 열병의 병인론

지도교수 채 찬 희 (D.V.M., Ph.D.)

이 논문을 수의학박사 학위논문으로 제출함
2022년 4월

서울대학교 대학원
수의학과 수의병인생물학 및 예방수의학전공
오 태 환

오 태 환의 수의학박사 학위논문을 인준함
2022년 6월

위 원 장 박 재 학 (인)

부위원장 채 찬 희 (인)

위 원 최 창 순 (인)

위 원 하 윤 철 (인)

위 원 강 익 재 (인)

Pathogenesis of African Swine Fever Occurring in Asia

By

Taehwan Oh, D.V.M.

A dissertation submitted in partial fulfillment of
the requirements for the degree of

DOCTOR OF PHILOSOPHY

Supervisor: Professor Chanhee Chae, D.V.M., Ph.D.

June 2022

Approved by

Park, Jae-Hak

Chae, Chanhee **Choi, Changsun**

Ha, Yooncheol **Kang, Ikjae**

Department of Veterinary Medicine
Graduate School of Seoul National University

Abstract

Pathogenesis of African Swine Fever Occurring in Asia

(Supervisor : Chanhee Chae, D.V.M., Ph.D.)

Taehwan Oh

Veterinary Pathobiology and Preventative Medicine (Pathology)
Department of Veterinary Medicine
Graduate School of Seoul National University

African swine fever virus (ASFV) is a large, icosahedral, enveloped, linear double strand DNA virus, causes hemorrhagic disease in domestic pigs and wild boars, and has been present in Asia since 2018. The objective of this dissertation was to reveal the pathogenesis of African swine fever (ASF) occurring in Asia through viral genetic characterization, pathological investigation of outbreak cases, and experimental reproduction of the disease.

In the first study, the genetic characterization of an ASFV isolate recently found in Vietnam was conducted to understand the genetic and epidemiologic characteristics of ASFV circulation within Asia. The wild-type virus was isolated using primary porcine kidney (PPK) cells, and successfully propagated to obtain a virus stock. Partial sequencing of viral major structural proteins p72, p54, and p30 categorized the new ASFV isolate as genotype II as it showed a high genetic homology with all isolates from other Asian countries. The partial sequences of these Asian isolates were also identical to those found in Georgia and Eastern Europe since 2007. These results revealed that ASF outbreaks in Asia were probably due to a single introduction of ASFV genotype II that spread slowly eastward, and without the introduction of additional virus genotypes.

In the second study, pathological investigations were conducted in recent successive Vietnamese ASF outbreaks to elucidate the pathogenesis of naturally occurring ASFV genotype II infection in Asia. Five major organs (lung, liver, kidney, spleen, and lymph nodes) were evaluated in necropsied pigs for splenomegaly, hemorrhagic lymph nodes and renal petechia being the most prominent gross lesions. Microscopic lesions based on tissue hemorrhage and lymphoid destruction were commonly observed in all necropsied pigs. ASFV antigen loads were determined by immunohistochemistry and were antigen positive for monocyte/macrophage lineage cells as well as for hepatocytes and tubular epithelial cells. Through this pathological study, it was confirmed that naturally occurring ASF in Asia was of an acute form where ASFV antigen distribution was widely spread in virus-infected pigs.

In the third study, twenty domestic pigs were orally inoculated with ASFV genotype II Asian isolates. A temporal pathology model was established by sacrificing 4 pigs

each at 1-, 3-, 5-, 7-, and 9-days post inoculation (dpi). Gross and microscopic lesions based on hemorrhage and lymphoid destruction were observed in five major organs (lung, liver, kidney, spleen, and lymph nodes) beginning at 3 dpi. Lesions were prominent at 5 dpi and reached peak severity at 9 dpi. ASFV antigen was observed from 3 dpi, mainly in the monocyte/macrophage lineage, but other cell types such as hepatocytes and tubular epithelial cells were antigen-positive at later stages of infection (7 dpi). These results demonstrated that ASFV circulating in Asia is highly virulent and sufficient in inducing the acute form of ASF via the oral route. It also provides evidence that the monocyte/macrophage lineage may play a major role in the acute ASF induction in early phase of viral infection.

Conclusively, this thesis suggested that ASF occurring in Asia is an acute clinical form of disease caused by genotype II ASFV, and that the monocyte/macrophage lineage plays a major role in the acute course of the disease. Through this study, an intergrated methodology was presented for the elucidation of the pathogenesis of ASF. Whole genome sequencing and comparative pathological studies of newly discovered virus isolates continue to be needed in case other ASFV genotypes enter Asia in the future.

Keywords: African swine fever virus; Pathogenesis; Genetic characterization; Pathological investigation; Antigen distribution

Student Number: 2018-22255

Table of Contents

LIST OF TABLES

PART II

PART III

LIST OF FIGURES

PART I

PART II

PART III

LIST OF ABBREVIATIONS

ASF	African swine fever
ASFV	African swine fever virus
CPE	Cytopathic effect
CSF	Classical swine fever
CSFV	Classical swine fever virus
CVR	Central variable region
DPI	Days post infection
FBS	Fetal bovine serum
FMDV	Foot-and-mouth disease virus
HAD	Hemadsorption reaction
IHC	Immunohistochemistry
IPT	Immunoperoxidase test
MGF	Multigene family
ORF	Open reading frames
PBS	Phosphate-buffered saline
PIM	Pulmonary intravascular macrophages
PPK	Primary porcine kidney
PRRS	Porcine reproductive and respiratory syndrome
PRRSV	Porcine reproductive and respiratory syndrome virus
RT-PCR	Real-time PCR
$TCID_{50}$	50% Tissue culture infective dose

GENERAL INTRODUCTION

African swine fever (ASF) is a contagious hemorrhagic disease that affects domestic pigs and wild boars. African swine fever virus (ASFV) is the causative agent of ASF and is a large, icosahedral, enveloped, linear double strand DNA virus (Salas and Andrés, 2013). ASFV was first described in 1921 in Kenya (Montgomery, 1921), and the virus was transmitted intercontinentally to Portugal in 1957 (Manso-Ribeiro et al., 1958). After half a century, ASF entered Georgia in 2007 (Rowlands et al., 2007), with the first outbreaks occurring in China in 2018 (Zhou et al., 2018). Currently, ASF has spread throughout Asia, including Vietnam, The Philippines, Mongolia, North Korea, South Korea, Indonesia, Myanmar, Laos, and Cambodia since 2019 (Mighell et al., 2021).

Genetic characterization of ASFV is a priority in the establishment of the heterogeneity and epidemiological links between the viruses in each ASF outbreak area (Misinzo et al., 2011). It means that possible routes and sources of ASFV can be identified through genotyping of the virus. A genotyping classification from partial sequencing of major structural protein p72 gene has been developed and widely used to define 24 ASFV genotypes from various regions (Achenbach et al., 2017; Quembo et al., 2017). Additional sequence assessments of structural proteins from the p30 and p54 genes have been used for epidemiological tracking with a higher resolution definition of virus relationships in regions where virus isolates are closely related to each other (Gallardo et al., 2009; Sanna, et al., 2017).

ASFV causes hemorrhagic disease such as Classical swine fever or erysipelas, showing no major clinical symptoms in wild boars, but various clinical symptoms in

domestic pigs. According to the course of clinical symptoms, the disease is classified into four types: peracute form, acute form, subacute form, and chronic form (Sánchez-Vizcaíno et al., 2019). Among them, acute ASF is the most typical form and occurs when the virus is exposed to naïve pigs, resulting in high fever, loss of appetite, and inactivity. The affected animals have extensive necrosis and hemorrhage of their lymphoid tissues, splenomegaly, erythema, and pulmonary edema. (Mebus et al., 1983).

It is well established that monocyte/macrophage cell lineage is a main target for ASFV (Gomez-Villamandos et al., 2013). Viral antigens can be detected in macrophages of the spleen, liver, and lung from 3 days post infection (dpi) in case of acute ASF (Fernandez et al., 1992). Cellular necrosis resulting in lymphoid destruction starts at 3 dpi and becomes apparent at 5 dpi. Thrombocytopenia which causes hemorrhages in multiple organs under experimental conditions is also observed at 3 dpi (Zakaryan et al., 2014). The pathogenesis of ASFV can be varied depending on the virulence of the virus strain, the route of infection, and the dose of infection.

This dissertation was designed to reveal the pathogenesis of ASF occurring in Asia. In Part I, genetic characterization of the ASFV strain isolated from a recent Vietnam outbreak was conducted to understand the genetic and epidemiologic characteristics of ASF in Asia. In Part II, pathologic investigations consisted of observed gross and microscopic lesions were conducted in successive ASF outbreak cases in Vietnam to elucidate the pathogenesis of naturally occurring ASFV infection in Asia. In Part III, a link between viral antigen distribution and tissue lesion development was confirmed by establishment of temporal pathology in pigs experimentally infected with Asian isolate of ASFV.

LITERATURE REVIEW

1. History

ASF, originally indigenous disease in wild African suids, was first described in 1921 in Kenya, when it transmitted to domestic pigs introduced from Europe (Montgomery, 1921). After its transcontinental transmission was reported in Portugal in 1957 (Manso-Ribeiro et al., 1958), ASF was consecutively found in Europe including Spain (1960), France (1964), Italy (1967), Sardinia (1978), Malta (1978), Belgium (1985), and the Netherlands (1986) (Arias and Sanchez-Vizcaino, 2002). The disease also affects Central, North, and South America, including Cuba (1971), the Dominican Republic (1978), Brazil (1978), and Haiti (1979). Subsequently ASF was eradicated from the western hemisphere with the exception of Portugal and Spain, where it became endemic for a period until 1995 (Bech-Nielsen et al., 1995; Arias et al., 2002). In 2007, ASF entered in Georgia (Rowlands et al., 2007), and spread to the Russian Federation (2007), Ukraine (2012) and Belarus (2013). The disease continued to spread to Asia through China in 2018 (Zhou et al., 2018), and has occurred sporadically in Vietnam, The Philippines, and South Korea since 2019 (Mighell et al., 2021). Currently, ASF outbreaks occur worldwide, and cause great damage to the pig industry and the economies of the affected countries.

2. Etiology

2-1 Classification

ASFV, the causing agent of ASF, is the only member of the family *Asfarviridae*, and is included in the genus *Asfivirus* (Dixon et al., 2005). ASFV is also the only known DNA arbovirus and is transmitted by soft ticks.

2-2 Virion Properties

The ASFV virion is enveloped and approximately 170 to 190 nm in diameter. The envelope contains hemagglutinin protein which is homologous to cellular CD2. The nucleocapsid core is surrounded by internal lipid layers and an icosahedral capsid. The capsid consists of four concentric layers and an external hexagonal membrane (Salas and Andrés, 2013). ASFV has 151 to 167 viral proteins depending on the isolate (Jia et al., 2017), and more than 50 structural proteins in virions, indicating that ASFV particles are complex. Many of structural proteins are highly antigenic, including the major capsid protein p72 and the membrane proteins p30 and p54. ASFV particles are sensitive to lipid solvents disrupting the envelope (Plowright and Parker, 1967). They are able to remain stable at a wide range of pH values (pH 4 – pH 10) but become inactive within minutes outside of the indicated range (EFSA, 2010). Virus particles found in serum or meat can remain infectious for months and even years at 4 °C. ASFV is thermolabile in that can be inactivated by heating at 60 °C for 30 minutes (Plowright and Parker, 1967) or 56 °C for 70 minutes (Mebus, 1988).

2-3 Genetic structure

ASFV is a linear double-stranded DNA virus. The viral genome of different isolates varies in length from 170 to 190 kb and encodes 151–167 open reading frames (ORF).

The Genome has covalently closed ends with inverted terminal repeats and hairpin loops. DNA consists of a conserved central region and two variable ends containing five multigene family (MGF) genes (Yañez et al., 1995). Gene Deletions and insertions occur within this MGF, generating antigenic variability which is associated with the degree of virulence and tick host range (Zsak et al., 2001; Burrage et al., 2004).

Since ASFV antigens do not sufficiently form neutralizing antibodies, a serotyping classification has not been developed. Instead, a genotyping classification with a partial sequence of structural protein from the p72 gene is used to define 24 ASFV genotypes (Achenbach et al. 2017; Quembo et al. 2017). ASFV isolates found in the Western Hemisphere before 2006 were identified as genotype I from West Africa, while a new genotype II from southeast Africa was found in the Caucasian region of Europe (EFSA, 2010). The sequence analysis of the central variable region (CVR) within the conserved central region is currently used for ASFV subtyping, which complements standard p72 genotyping (Phologane et al., 2005; Gallardo et al., 2014). Also, an additional sequence assessment of p30 and p54 genes have been used for virus tracking. 15 complete genome sequences found from different regions are available to-date, each with a different degree of virulence and host range (wild pigs, domestic pigs, and ticks) (De Villiers et al., 2010).

2-4 Virus Replication

Field isolates of ASFV replicate in porcine monocytes and macrophages. Replication occurs mainly in the cytoplasm, although the nucleus is needed at the early stage of viral DNA synthesis. Once the virions enter the endosomal pathway, transcription of early viral genes begins before the onset of DNA replication.

Intermediate and late genes are expressed following DNA replication. ASFV transcription follows temporal control which is relatively independent from the host cell (Rodriguez et al., 2013).

Several isolates can replicate in continuous cell lines including VERO, MS, CV-1, COS-1 and MA-104 after cell adaptation. These cell lines are currently used for ASFV research purposes, but there is a limitation in that they cause genetic and antigenic changes in the virus when subcultured for a long period of time (Sánchez-Vizcaíno et al., 2019). For these reasons, primary cells such as pulmonary alveolar macrophages are widely used for studying ASFV biology or diagnosis, but there are alternate problems with batch-to-batch consistency. This is one of the obstacles to the development of an ASFV vaccine.

3. Epidemiology

Although ASF has been eradicated in many countries, including Spain and Portugal, ASF has become endemic in some countries in Eastern Europe and continues to occur in Asia. Recently, the moderate virulent strains with low virulence have been found in endemic countries in Europe (Sehl et al., 2020). So far, two genetic variants have been identified, but it is necessary to monitor the emergence of new virus strains exhibiting unknown pattern of virulence. There are two conventional transmission patterns of ASF, one is the sylvatic cycle in wild boars and ticks, and the other is the epizootic and enzootic cycle in domestic swine.

3-1 Sylvatic Cycle

In southern and eastern Africa, ticks are biological vectors of ASFV. Indirect

transmission by biological vectors occurs in outdoor pig farms. The virus asymptomatically infects wild pigs (warthogs) and soft ticks (genus *Ornithodoros*) and is maintained in a sylvatic cycle (Maclachlan and Dubovi, 2010). ASFV replicates in the gut of ticks after the tick feeds on virus-infected pigs, and subsequently infects the reproductive system, causing transovarian transmission. The virus is also excreted in saliva or Malpighian excrement, causing trans-stadial transmission between the ticks. Young wild boars may become infected with the virus by eating the infected ticks can develop viremia. In contrast, older wild boars do not show viremia, but the virus can cause persistent infections in the lymphoid tissues.

3-2 Domestic Cycle

In Europe, ASFV is transmitted mainly via direct contact between infected and uninfected pigs (Sánchez-Vizcaíno et al., 2019). The primary introduction of ASFV into domestic pigs occurs through the bite of infected ticks or infected meat, or through contact with wild pigs (Maclachlan and Dubovi, 2010). Once the pigs are infected, the virus is excreted by oral fluid, feces, urine, and nasal discharge following the onset of clinical signs. The virus can be transmitted between pigs by direct contact, and within buildings by aerosol. Mechanical transmissions by worker and vehicles are possible and common, as the virus remains infectious in feces for several weeks. In recent years, there has been an increase in international transmission of ASFV reported in the process of importing and exporting uncooked pork.

4. Clinical signs

Wild boars usually do not show major clinical symptoms, whereas domestic pigs display a wide range of clinical symptoms. ASF is often confused with diseases such as classical swine fever (CSF) or erysipelas as they all cause hemorrhagic lesions. The incubation period is 5 to 15 days, and the clinical symptoms, mortality and morbidity vary depending on the virulence of the virus strain, the route of exposure, and the dose of exposure.

4-1 Peracute form

Peracute form of ASF is induced by a highly virulent strain and is characterized by high fever, cutaneous hyperemia, hyperpnea, loss of appetite, and inactivity. The affected animals die suddenly, 1–4 days after clinical signs appear, but lesions may not be present in the organs of infected animals. The peracute form is usually reported in early outbreaks of ASF-naïve regions (Sánchez-Vizcaíno et al., 2015).

4-2 Acute form

The acute form of ASF is induced by highly virulent or moderately virulent strains, and characterized by fever (40–42 °C), loss of appetite, inactivity, and leukopenia. The affected animals have extensive necrosis and hemorrhage of lymphoid tissue, splenomegaly, erythema, and pulmonary edema. (Mebus et al., 1983).

Splenomegaly and petechia in the kidney are characteristic lesions of acute ASF, and affected lymph nodes (mainly the renal and gastrohepatic) display extensive signs of hemorrhage. Cutaneous hyperemia is an obvious sign, in which erythema and cyanosis appear in the skin of extremities, ears, chest, abdomen, and the perineum.

Hemorrhagic discharge from the nasal cavity or anus may be observed. Severe respiratory changes with labored breathing are often observed in the last stage of the disease. The mortality rate is almost 100% at 7–9 days after the onset of clinical signs, with abortion as a possible first clinical sign in an outbreak. Acute ASF is the most common form observed when the disease causes an outbreak in ASF-naïve regions (Sánchez-Vizcaíno et al., 2015; Sánchez-Vizcaíno et al., 2019).

4-3 Subacute form

A subacute form of ASF is induced by moderately virulent strains. This form of the disease displays less severe clinical signs than the acute form, but hemorrhage and edema are sometimes more intense than the acute form (Gómez-Villamandos et al., 2013). Transitory thrombocytopenia and leukopenia are observed in the early and mid-stages of the disease (Gómez-Villamandos et al., 1997). Other symptoms include moderate to high fever, edema in several organs, hemorrhage and splenomegaly. The affected animals may die within 20 days, resulting in a 30 to 70% range of mortality rate. Subacute ASF can be observed in endemic areas, and surviving animals usually recover after 3-4 weeks, with intermittent viremia and anti-ASFV antibodies detected (Mur et al., 2016).

4-4 Chronic form

The chronic form of ASF is induced by a low virulent strain, reported in Spain, Portugal and recently Eastern Europe (Gallardo et al., 2018). Animals infected with this form of disease have no specific clinical signs, but some animals may excrete the virus for long periods of time resulting in the persistence of the disease in those

affected regions. These animals may show necrotic lesions of the skin, arthritis (fibrinous arthritis/periarthritis), and lameness, but remain void of vascular lesions. The problem with this form of the disease is that it causes chronic growth retardation.

5. Pathology

Pigs are initially infected with ASFV via the oronasal route, where the virus first replicates in the tonsils and regional lymph nodes then spreads rapidly through the lymph and blood into the body. Pigs suffering from ASF show a wide range of lesions in multiple organs depending on the virus virulence. Spleen enlargement, necrosis and hemorrhage in lymph nodes, petechia in kidneys, edema in the lung, and congestion in the liver are typical lesions associated with ASF. The lesions are based on lymphoid destruction and hemorrhage in the most clinical form of the disease, both of which have characteristic pathogenic mechanisms.

5-1 Pathogenesis of Lymphoid lesions

The main target of ASFV is of monocyte/macrophage lineage, and their ability to induce (or inhibit) the expression of pro-inflammatory cytokines and interferons; a critical factor in viral virulence (Maclachlan & Dubovi, 2010). The ASFV genome contain genes involved in the modulation of inflammation and host immune responses. The *A238L* gene encodes a protein that inhibits the activation of cellular transcription factor, and nuclear factor kB, while the 8DR gene induces T lymphocyte activation and mediation of hemadsorption by infected cells (Maclachlan & Dubovi, 2010). Also, there are genes involved in unprogrammed cell death in both inhibitory and inducing manners. In general, ASFV infection results in

severe leukopenia caused by apoptosis of lymphocytes and mononuclear cells, in which the massive destruction of lymphoid tissues including tonsil, thymus, spleen and lymph nodes is observed as disease progresses (Salguero, 2020). The upregulation of proinflammatory cytokines described as cytokine storm is a necessary mechanism for the extensive induction of apoptosis of lymphocytes (Salguero et al., 2005).

5-2 Pathogenesis of Vascular change

Hemorrhages, the typical lesion of the ASF, appear in multiple organs including kidney and visceral lymph nodes which lack fixed vascular macrophages. (Gomez-Villamandos et al., 2013). Importantly, hemorrhages may occur at earlier phase of the disease, while ASFV replicates in endothelial cells at only late phase (Gomez-Villamandos et al., 1995). This means that hemorrhage is not directly related with virus-induced cell damage. For this reason, a pathogenic mechanism has been proposed in that, after capillary endothelial cells activate phagocytosis, cell hypertrophy occurs, occludes the capillary lumen, and thus increases intravascular pressure (Gomez-Villamandos et al., 2013). The subsequent endothelial loss causes the exposure of the basal membrane where platelets can adhere resulting in the activation of the coagulation system and finally leading to disseminated intravascular coagulation (Gomez-Villamandos et al., 2013). The pathogenesis of the pulmonary edema is relevant with pulmonary intravascular macrophages (PIM), which secrete chemotactic proinflammatory cytokines such as IL-1α and TNF-α, thereafter, increasing the endothelial permeability. Increased permeability causes capillary fluid to leak into the alveolar and interalveolar space (Carrasco et al., 2002).

6. Diagnosis

Because the clinical signs and lesions of ASF are similar to those of erysipelas, salmonellosis, and especially CSF, a diagnosis cannot be made through observation or autopsy alone. There are various laboratory analyses available for ASFV diagnosis and samples including blood, oral fluid, lymphoid organs, kidney and lung are recommended for analysis (Arias and Sánchez-Vizcaíno, 2002).

6-1 Viral genome detection

Viral genome detection using either conventional or real-time PCR is currently the golden standard because of its high sensitivity and specificity. Most PCR methods are designed to ensure detection of almost all ASFV strains by targeting the highly conserved gene which encodes for a major viral structural protein, p72 (King et al., 2003). PCR methods have the advantage of being able to detect the virus even in the early phase of infection when animals do not show clinical symptoms. Multiplex PCR methods have been developed for differential diagnosis of ASF from similar clinical disease such as Classical swine fever virus (CSFV) (Agüero et al., 2004). Although multiplex PCR usually have lower sensitivity than single assays, it is useful for surveillance in ASF naïve regions and ASF/CSF co-circulation regions.

6-2 Virus isolation

Field strains of ASFV can be isolated in susceptible primary cell cultures of swine such as monocytes and macrophages obtained from blood or the lung. The infectious virus in the specimen replicates in cell culture and displays cytopathic effect (CPE)

and hemadsorption reaction (HAD) (Sánchez-Vizcaíno et al., 2019). Despite these useful tools, isolation of a wild-type virus from field specimens may provide irregular results and low effectiveness (Gallardo et al., 2015). Some field isolates do not display HAD, but rather CPE (Leitão et al., 2001; Boinas et al., 2004). Isolation of these non-HAD strains requires further confirmation using PCR to produce consistent results (Oura et al., 2013). Despite these limitations, virus isolation is essential in studying the biological characterization of ASFV strains.

6-3 Antigen detection

ASFV antigen detection has been conducted with direct, indirect and sandwich ELISAs, that have been developed both commercially as well as in-house. While in-house antigen ELISAs are not typically the preferred method, commercially developed antigen ELISA kits are available for the analysis of serum samples. They produce results rapidly and methods are easy to scale up, but have relatively low sensitivity (77.2%) when compared to the routine PCR recommended by OIE, even in high-tittered samples (Oura et al., 2013; Gallardo et al., 2015). Antigen ELISAs are therefore only recommended when combined with other serological tests.

6-4 Antibody detection

Serological antibody detection tests are commonly used for ASF diagnosis due to their relatively simple methodology and low cost involved as they require only a few devices and minor facilities. Diseased animals affected with ASFV have anti-ASFV antibodies for up to several months or even years after infection (Arias and Sánchez-Vizcaíno, 2002). Since there is currently no commercially available ASF vaccine, all

animals with positive serum antibody tests can be diagnosed as having a natural infection. Likewise, detection of ASFV-specific antibody is important in the evaluation of epidemiological situations in disease affected regions. Commercial ELISA kits from various manufacturers have been developed for the detection of ASF antibodies against most antigenic viral proteins including p30, p54, p72, and pp62. The ELISA test may exhibit lower sensitivity in detection during early stage of ASFV infection (7–12 days post infection), but it is reliable for the detection of antibodies during a fulminant course of infection (12-14 days post infection) (Gallardo et al., 2015). Although it is limited in its use of serum samples, antibody detection using ELISA methodology has still advantages for large-scale serological studies as it is a fast, easy, and economical method.

Positive ASFV test results from an ELISA could be confirmed by back-up methods such as an Indirect Immunoperoxidase test (IPT), recommended by the OIE (Gallardo et al., 2015). It requires the use of a fixed monolayer culture of VERO or an MS cell line infected with adapted-grown ASFV. Although there are some drawbacks such as results can be subjectively interpreted, the tests have a high sensitivity and specificity when performed by well trained staff. This method has an advantage in that any kind of specimen such as serum, excreted discharge, and body fluids can be used for accurate diagnosis.

7. Prevention

Since there is no commercially available vaccine for ASF, epidemic countries rely on active surveillance and culling as preventative measures. Eradication of ASFV has been achieved without vaccination in certain countries by having an effective

contingency plan in place. To prepare for ASF outbreak that is spreading around the world, a plan suitable for each country is needed.

7-1 Quarantine

Countries that are free of ASF have quarantine strategies in place that ban the importation of live pigs and pork products from infected countries (EFSA, 2010). In Asia and Europe, where recent ASF outbreaks occur sporadically, vehicles, people, and products related to the swine industry are monitored while taking a preemptive culling strategy around the outbreak area. Endemic countries such as Sardinia implement monitoring and control of live pig and pork product movement as a preventive measure, and extensive serological surveillance to detect carriers that are the source of ASFV. In endemic areas of Africa, control of natural hosts, such as wild African suids or soft ticks, is important in preventing the spread of ASF to domestic pigs (Sánchez-Vizcaíno et al., 2019).

7-2 Vaccination

Currently, a successful vaccine against ASFV is not developed or available. The first trial that used a live attenuated strain in 1963 in Portugal was unsuccessful (Manso-Ribeiro et al., 1963). Since then, some experimental vaccines based on attenuated ASFV strains have been developed but safety and efficacy issues remain unresolved (King et al., 2011; O'Donnell et al., 2016; Reis et al., 2016). An inactivated ASF vaccine is the fastest and easiest to make, but has low immunogenicity compared to live attenuated vaccine options. Inactivated vaccines have a major drawback in that it is impossible to induce a long-term T-cell immune

response. Subunit vaccines induce specific immunity by combining the expression of specific ASFV proteins. Viral epitope analysis is important, but effective subunit candidates are difficult to select as there are more than 167 ORFs of ASFV. Previous attempts of combining p30, p54, and p72 failed to induce neutralizing antibodies. Recombinant live vaccines have been developed by removing specific genes that related with virulence or a host immune response using CRISPR-Cas 9 or DNA homologous recombination. Also, live attenuated vaccines have been developed through unintentional genetic changes made during long subcultures. Chronic side effects accompanied by high fever have occurred from vaccination with some live strains, and catastrophic recombination may occur through recombination with wild type strains. In order to develop an effective ASF vaccine, there are many problems regarding not only efficacy, but also safety issues (Rock, 2017; Teklue et al., 2020).

8. References

Achenbach, J. E., Gallardo, C., Nieto-Pelegrín, E., Rivera-Arroyo, B., Degefa-Negi, T., Arias, M., ... & Sánchez-Vizcaíno, J. M. (2017). Identification of a new genotype of African swine fever virus in domestic pigs from Ethiopia. Transboundary and emerging diseases, 64(5), 1393-1404.

Agüero, M., Fernández, J., Romero, L. J., Zamora, M. J., Sánchez, C., Belák, S., ... & Sánchez-Vizcaíno, J. M. (2004). A highly sensitive and specific gel-based multiplex RT-PCR assay for the simultaneous and differential diagnosis of African swine fever and Classical swine fever in clinical samples. Veterinary research, 35(5), 551-563.

Arias, M., Sánchez-Vizcaíno, J. M., Morilla, A., Yoon, K. J., & Zimmerman, J. J. (2002). African swine fever. Trends in emerging viral infections of swine, 119-124.

Bech-Nielsen, S., Fernandez, J., Martinez-Pereda, F., Espinosa, J., Bonilla, Q. P., & Sanchez-Vizcaino, J. M. (1995). A case study of an outbreak of African swine fever in Spain. British veterinary journal, 151(2), 203-214.

Boinas, F. S., Hutchings, G. H., Dixon, L. K., & Wilkinson, P. J. (2004). Characterization of pathogenic and non-pathogenic African swine fever virus isolates from Ornithodoros erraticus inhabiting pig premises in Portugal. Journal of general virology, 85(8), 2177-2187.

Burrage, T. G., Lu, Z., Neilan, J. G., Rock, D. L., & Zsak, L. (2004). African swine fever virus multigene family 360 genes affect virus replication and generalization of infection in Ornithodoros porcinus ticks. Journal of virology, 78(5), 2445-2453.

Carrasco, L., Nunez, A., Salguero, F. J., San Segundo, F. D., Sanchez-Cordon, P., Gomez-Villamandos, J. C., & Sierra, M. A. (2002). African swine fever: Expression of interleukin-1 alpha and tumour necrosis factor-alpha by pulmonary intravascular macrophages. Journal of comparative pathology, 126(2-3), 194-201.

De Villiers, E. P., Gallardo, C., Arias, M., Da Silva, M., Upton, C., Martin, R., & Bishop, R. P. (2010). Phylogenomic analysis of 11 complete African swine fever virus genome sequences. Virology, 400(1), 128-136.

Dixon LK, Escribano JM, Martins C, et al. (2005). The Asfarviridae. In Fauquet CM, Mayo MA, Maniloff J, et al., eds. Virus Taxonomy: VIII Report of the International Committee for the Taxonomy of Viruses. London: Elsevier/Academic Press, pp. 135-143.

Donald, P. K. (2010). Asfarviridae and Iridoviridae. In Maclachlan NJ, & Dubovi EJ, eds. Fenner's veterinary virology (4th ed). Burlington, MA: Elsevier/Academic press, pp. 167-172.

European Food Safety Authority (EFSA). 2010. Scientific opinion on African swine fever. EFSA J 8:1-149.

Fernandez, A., Perez, J., Carrasco, L., Bautista, M. J., Sanchez-Vizcaino, J. M., & Sierra, M. A. (1992). Distribution of ASFV antigens in pig tissues experimentally infected with two different Spanish virus isolates. Journal of veterinary medicine, Series B, 39(1-10), 393-402.

Gallardo, C., Fernández-Pinero, J., Pelayo, V., Gazaev, I., Markowska-Daniel, I., Pridotkas, G., ... & Arias, M. (2014). Genetic variation among African swine fever genotype II viruses, eastern and central Europe. Emerging infectious diseases, 20(9), 1544.

Gallardo, C., Mwaengo, D. M., Macharia, J. M., Arias, M., Taracha, E. A., Soler, A., ... & Bishop, R. P. (2009). Enhanced discrimination of African swine fever virus

isolates through nucleotide sequencing of the p54, p72, and pB602L (CVR) genes. Virus genes, 38(1), 85-95.

Gallardo, C., Nieto, R., Soler, A., Pelayo, V., Fernández-Pinero, J., Markowska-Daniel, I., ... & Arias, M. (2015). Assessment of African swine fever diagnostic techniques as a response to the epidemic outbreaks in Eastern European Union countries: how to improve surveillance and control programs. Journal of clinical microbiology, 53(8), 2555-2565.

Gallardo, C., Nurmoja, I., Soler, A., Delicado, V., Simón, A., Martin, E., ... & Arias, M. (2018). Evolution in Europe of African swine fever genotype II viruses from highly to moderately virulent. Veterinary microbiology, 219, 70-79.

Gomez-Villamandos, J. C., Bautista, M. J., Carrasco, L., Caballero, M. J., Hervas, J., Villeda, C. J., ... & Sierra, M. A. (1997). African swine fever virus infection of bone marrow: lesions and pathogenesis. Veterinary pathology, 34(2), 97-107.

Gomez-Villamandos, J. C., Bautista, M. J., Sanchez-Cordon, P. J., & Carrasco, L. (2013). Pathology of African swine fever: the role of monocyte-macrophage. Virus research, 173(1), 140-149.

Gómez-Villamandos, J. C., Hervás, J., Méndez, A., Carrasco, L., Villeda, C. J., Wilkinson, P. J., & Sierra, M. A. (1995). Ultrastructural study of the renal tubular system in acute experimental African swine fever: virus replication in glomerular mesangial cells and in the collecting ducts. Archives of virology, 140(3), 581-589.

Jia, N., Ou, Y., Pejsak, Z., Zhang, Y., & Zhang, J. (2017). Roles of African swine fever virus structural proteins in viral infection. Journal of veterinary research, 61(2), 135.

King, D. P., Reid, S. M., Hutchings, G. H., Grierson, S. S., Wilkinson, P. J., Dixon, L. K., ... & Drew, T. W. (2003). Development of a TaqMan® PCR assay with internal amplification control for the detection of African swine fever virus. Journal of virological methods, 107(1), 53-61.

King, K., Chapman, D., Argilaguet, J. M., Fishbourne, E., Hutet, E., Cariolet, R., ... & Takamatsu, H. H. (2011). Protection of European domestic pigs from virulent African isolates of African swine fever virus by experimental immunisation. Vaccine, 29(28), 4593-4600.

Leitão, A., Cartaxeiro, C., Coelho, R., Cruz, B., Parkhouse, R. M. E., Portugal, F. C., ... & Martins, C. L. (2001). The non-haemadsorbing African swine fever virus isolate ASFV/NH/P68 provides a model for defining the protective anti-virus immune response. Journal of general virology, 82(3), 513-523.

Manso Ribeiro, J., Roza Azevedo, J. A., Teixeira, M. J. O., Braco Forte, M. C., Rod-rigues Ribeiro, A. M., Oliveira, F., ... & Dias Vigario, J. (1958). Peste Porcine provoquée par une souche différente (Souche L) de la souche classique. Bulletin - Office international des epizooties, 50, 516-534.

Manso-Ribeiro, J., Nunes-Petisca, J. L., Lopez-Frazao, F., & Sobral, M. (1963). Vaccination against ASF. Bulletin - Office international des epizooties, 60, 921-937.

Mebus, C. A. (1988). African swine fever. Advances in virus research, 35, 251-269.

Mebus, C. A., McVicar, J. W., & Dardiri, A. H. (1983). Comparison of the pathology of high and low virulence African swine fever virus infections. Comparison of the pathology of high and low virulence African swine fever virus infections., 183-194.

Mighell, E., & Ward, M. P. (2021). African swine fever spread across Asia, 2018–2019. Transboundary and emerging diseases, 68(5), 2722-2732.

Misinzo, G., Magambo, J., Masambu, J., Yongolo, M. G., Van Doorsselaere, J., & Nauwynck, H. J. (2011). Genetic characterization of African swine fever viruses from a 2008 outbreak in Tanzania. Transboundary and emerging diseases, 58(1), 86-92.

Montgomery, R. E. (1921). On a form of swine fever occurring in British East Africa (Kenya Colony). Journal of comparative pathology and therapeutics, 34, 159-191.

Mur, L., Atzeni, M., Martínez-López, B., Feliziani, F., Rolesu, S., & Sanchez-Vizcaino, J. M. (2016). Thirty-five-year presence of African swine fever in Sardinia: History, evolution and risk factors for disease maintenance. Transboundary and

emerging diseases, 63(2), 165-177.

O'Donnell, V., Risatti, G. R., Holinka, L. G., Krug, P. W., Carlson, J., Velazquez-Salinas, L., ... & Borca, M. V. (2017). Simultaneous deletion of the 9GL and UK genes from the African swine fever virus Georgia 2007 isolate offers increased safety and protection against homologous challenge. Journal of virology, 91(1), e01760-16.

Oura, C. A. L., Edwards, L., & Batten, C. A. (2013). Virological diagnosis of African swine fever—comparative study of available tests. Virus research, 173(1), 150-158.

Phologane, S. B., Bastos, A. D., & Penrith, M. L. (2005). Intra-and inter-genotypic size variation in the central variable region of the 9RL open reading frame of diverse African swine fever viruses. Virus genes, 31(3), 357-360.

Plowright, W., & Parker, J. (1967). The stability of African swine fever virus with particular reference to heat and pH inactivation. Archiv für die gesamte Virusforschung, 21(3), 383-402.

Quembo, C. J., Jori, F., Vosloo, W., & Heath, L. (2018). Genetic characterization of African swine fever virus isolates from soft ticks at the wildlife/domestic interface in Mozambique and identification of a novel genotype. Transboundary and emerging diseases, 65(2), 420-431.

Reis, A. L., Abrams, C. C., Goatley, L. C., Netherton, C., Chapman, D. G., Sanchez-

Cordon, P., & Dixon, L. K. (2016). Deletion of African swine fever virus interferon inhibitors from the genome of a virulent isolate reduces virulence in domestic pigs and induces a protective response. Vaccine, 34(39), 4698-4705.

Rock, D. L. (2017). Challenges for African swine fever vaccine development—"… perhaps the end of the beginning.". Veterinary microbiology, 206, 52-58.

Rodríguez, J. M., & Salas, M. L. (2013). African swine fever virus transcription. Virus research, 173(1), 15-28.

Rowlands, R. J., Michaud, V., Heath, L., Hutchings, G., Oura, C., Vosloo, W., ... & Dixon, L. K. (2008). African swine fever virus isolate, Georgia, 2007. Emerging infectious diseases, 14(12), 1870.

Salas, M. L., & Andrés, G. (2013). African swine fever virus morphogenesis. Virus research, 173(1), 29-41.

Salguero, F. J. (2020). Comparative pathology and pathogenesis of African swine fever infection in swine. Frontiers in veterinary science, 7, 282.

Salguero, F. J., Sanchez-Cordon, P. J., Nunez, A., de Marco, M. F., & Gomez-Villamandos, J. C. (2005). Proinflammatory cytokines induce lymphocyte apoptosis in acute African swine fever infection. Journal of comparative pathology, 132(4), 289-302.

Sánchez-Vizcaíno, J. M., Laddomada, A., & Arias, M. L. (2019). African swine fever virus. Diseases of swine, 443-452.

Sánchez-Vizcaíno, J. M., Mur, L., Gomez-Villamandos, J. C., & Carrasco, L. (2015). An update on the epidemiology and pathology of African swine fever. Journal of comparative pathology, 152(1), 9-21.

Sanna, G., Dei Giudici, S., Bacciu, D., Angioi, P. P., Giammarioli, M., De Mia, G. M., & Oggiano, A. (2017). Improved strategy for molecular characterization of African swine fever viruses from Sardinia, based on analysis of p30, CD2V and I73R/I329L variable regions. Transboundary and emerging diseases, 64(4), 1280-1286.

Sehl, J., Pikalo, J., Schäfer, A., Franzke, K., Pannhorst, K., Elnagar, A., ... & Breithaupt, A. (2020). Comparative pathology of domestic pigs and wild boar infected with the moderately virulent African swine fever virus strain “Estonia 2014”. Pathogens, 9(8), 662.

Teklue, T., Sun, Y., Abid, M., Luo, Y., & Qiu, H. J. (2020). Current status and evolving approaches to African swine fever vaccine development. Transboundary and emerging diseases, 67(2), 529-542.

Yanez, R. J., Rodríguez, J. M., Nogal, M. L., Yuste, L., Enríquez, C., Rodriguez, J. F., & Vinuela, E. (1995). Analysis of the complete nucleotide sequence of African swine fever virus. Virology, 208(1), 249-278.

Zakaryan, H., Karalova, E., Voskanyan, H., Ter-Pogossyan, Z., Nersisyan, N., Hakobyan, A., ... & Karalyan, Z. (2014). Evaluation of hemostaseological status of pigs experimentally infected with African swine fever virus. Veterinary microbiology, 174(1-2), 223-228.

Zsak, L., Lu, Z., Burrage, T. G., Neilan, J. G., Kutish, G. F., Moore, D. M., & Rock, D. L. (2001). African swine fever virus multigene family 360 and 530 genes are novel macrophage host range determinants. Journal of virology, 75(7), 3066-3076.

Zhou, X., Li, N., Luo, Y., Liu, Y. E., Miao, F., Chen, T., ... & Hu, R. (2018). Emergence of African swine fever in China, 2018. Transboundary and emerging diseases, 65(6), 1482-1484.

PART I. Genetic Characterization of an Asian Isolate of African Swine Fever Virus

ABSTRACT

African swine fever virus (ASFV) is a large, icosahedral, enveloped, linear double strand DNA virus, causes hemorrhagic disease in domestic pigs and wild boars, and has been present in Asia since 2018. Genetic characterization of ASFV is essential in establishing the heterogeneity and epidemiological links between the viruses in each ASF outbreak area. In this study, the genetic characterization of an ASFV isolate recently found in Vietnam was conducted to understand the genetic and epidemiologic characteristics of ASFV circulation within Asia. The wild-type virus was isolated using primary porcine kidney (PPK) cells, and successfully propagated to obtain a strain stock. Partial sequencing of viral major structural proteins p72, p54, and p30 categorized the new ASFV isolate as Genotype Ⅱ as it showed a high genetic homology with all isolates from other Asian countries. The partial sequences of these Asian isolates were also identical to those found in Georgia and Eastern Europe since 2007. These results revealed that ASF outbreaks in Asia were probably due to a single introduction of ASFV genotype Ⅱ that spread slowly eastward, and without the introduction of additional virus genotypes.

Keywords: African swine fever virus; Genetic characterization; Asian Isolate; Primary Porcine Kidney cells

INTRODUCTION

African Swine Fever Virus (ASFV), the causing agent of ASF, is a large, icosahedral, enveloped, linear double strand DNA virus. ASFV is the only member of the family Asfarviridae, found in the genus Asfivirus (Dixon et al., 2005). After ASFV was first described in 1921 in Kenya (Montgomery, 1921), its transcontinental transmission was reported in Portugal in 1957 (Manso-Ribeiro et al., 1958). In 2007, ASF entered in Georgia (Rowlands et al., 2007), and spread to China in 2018 (Zhou et al., 2018). Currently, ASF continues to occur throughout Asia including Vietnam, Philippines, Mongolia, North Korea, South Korea, Indonesia, Myanmar, Laos, and Cambodia (Mighell et al., 2021).

Genetic characterization of ASFV is a priority in the establishment of the heterogeneity and epidemiological links between the viruses in each ASF outbreak area (Misinzo et al., 2011). It means that possible routes and sources of ASFV can be identified through genotyping, thereby preventing further introductions of ASF. Because ASFV antigens do not form sufficient neutralizing antibodies, a genotyping classification rather than a serotyping classification has been developed. A genotyping classification from partial sequencing of major structural protein p72 gene has been developed and widely used to define 24 ASFV genotypes from various regions (Achenbach et al., 2017; Quembo et al., 2017). Additional sequence assessments of structural proteins from the p30 and p54 genes have been used for epidemiological tracking with a higher resolution definition of virus relationships in regions where virus isolates are closely related to each other (Sanna, et al., 2017; Gallardo et al., 2008).

In this study, the genetic characterization of the ASFV strain isolated from a recent Vietnam outbreak was conducted to understand the genetic and epidemiologic characteristics of ASFV, which is recently prevalent in Asia. As ASFV can undergo genetic and antigenic changes when extensively cultured in an existing continuous cell line (Sánchez-Vizcaíno et al., 2019), primary porcine kidney cells were selected for isolation of the wild-type virus to reduce these risks. Thereafter, partial sequencing against p72 genes as well as p30 and p54 genes of the virus isolates were performed.

MATERIALS AND METHODS

Preparation of primary porcine kidney cell culture

Crossbred pigs that were 21-28 days old were used to harvest primary porcine kidney cells with slight modifications from the referenced methodology (Takenouchi et al., 2014). The piglets were screened where they tested seronegative for PCV2, PRRSV and *M. hyopneumoniae* (Kim et al., 2003; Do et al., 2016; Dubosson et al., 2004). The tissue collection process was performed by anesthetizing the animals prior to euthanasia. The kidneys were then removed during necropsy. Post-necropsy, the tissues were further processed by removing the fibrous renal capsule from the kidneys. The renal cortex was then cut into small pieces (3–5 g each), and finely minced with scissors. The prepared tissues were transferred into 50 mL tubes containing a phosphate-buffered saline (PBS) solution (0.5 mg/mL) supplemented with dispase (250 U/ml, Falcon, Corning, NY, USA) and DNase I (13 U/ml, Worthington, Lakewood, NJ, USA). Tissues were then digested by a tube rotator containing collagenase (Wako, Tokyo, Japan) while incubating for 1h at 37 °C. Once digested, the material was filtered through a nylon mesh (pore size: 100mm), and re-suspended in growth medium composed of supplemented RPMI-1640 medium (Gibco, Grand Island, NY, USA) containing 10% heat- inactivated fetal bovine serum (Gibco), 0.005 mM 2-mercaptoethanol (Sigma-Aldrich, St. Louis, MO, USA), and 10 µg/mL bovine insulin (Sigma). The media also contained antibiotics as follows: 100U/ mL penicillin (Gibco), 100 mg/ mL streptomycin (Gibco), and 0.25 ug/ mL Amphotericin B (Gibco). The cell suspension was split into 20 x T-75 tissue culture flasks (Falcon) and cultured at 37 °C in a 5% CO_2 incubator for 2–3 weeks.

Full media changes occurred every 3–4 days throughout incubation. At the end of the incubation period, cells were harvested with a cell scraper and suspended in Cell Reservoir One with DMSO (Nacalai tesque, Kyoto, Japan) and immediately frozen in liquid nitrogen. This study was approved by Seoul National University Institutional Animal Care and Use Committee.

ASFV isolation using primary porcine kidney cells

After a stock of primary porcine kidney cells was established, ASFV was isolated from tissues of a pig suffering from acute ASF. A clinically suspected 10-week-old pig was selected from a farm with an ASF outbreak in Vietnam, and was confirmed through testing as positive exclusively for ASFV (King et al., 2003). Renal and gastrohepatic lymph nodes and spleen were collected from this pig post-euthanasia. Lymph nodes and spleen tissue homogenates were prepared for ASFV isolation as follows: Approximately 2% of the tissues were suspended into RPMI-1640 medium containing antibiotic-antimycotics (100 U of penicillin G per mL, 100 g of streptomycin sulfate per mL, and 0.025 g of amphotericin B per mL; Gibco, Invitrogen-Gibco, Carlsbad, CA, USA). The suspensions were then homogenized with a laboratory blender for 3 minutes, centrifuged at 1500 g for 5minutes, and sterilized through a 0.45 μm filter. The homogenates prepared in this manner was used as the inoculum for virus isolation. Once primary porcine kidney cells reached 80% confluency in T-25 tissue culture flasks, cells were dissociated with trypsin. Trypsin was then neutralized with, and cells were resuspended in 2mL RPMI-1640 medium containing 10% fetal bovine serum (FBS). The cell suspension was then mixed with 1mL aliquots of the inoculum (0.3 Multiplicity of Infection) described above. Three mL of infected cell aliquots was seeded into new T-25 flasks and placed

inside of a 37 °C, 5 % CO_2 incubator for 2 hours for adsorption onto cell layers. After two hours, flasks were fed with 5mL of RPMI-1640 medium and returned to the incubator for 48−72 hours. Post-incubation, three freeze-thaw cycles were performed on the infected flasks. Freshly cultured cells were infected by adding 1 mL of the cell lysate obtained from the previous 3x freeze/thawed flask. Several passages were performed in the same manner to propagate the virus stock.

Replication kinetics of ASFV isolated in primary kidney cells

Replication kinetics were determined for the ASFV isolates. The viral titration of culture supernatants was performed with real-time PCR (RT-PCR) and cytopathic effect (CPE)-based assays at in 1,3,5 and 7 days post infection (dpi). A titration of cell-free viral DNA was conducted by RT-PCR targeting p72 genes (King et al., 2003). Briefly, the forward and reverse primers, and probe were 5′-CTGCTCATGGTATCAATCTTATCGA-3′ and 5′-GATACCACAAGATC(AG)GCCGT-3′, and 5′-(FAM)-CCACGGGAGGAATACCAACCCAGTG-3′-(TAMRA), respectively. The RT-PCR conditions were 95 °C for 5 min, followed by 40 cycles of 95 °C for 15 s and 60 °C for 40 s. Genome copy numbers were calculated from Ct values obtained from RT-PCR using a standard curve constructed by 10-fold dilutions of quantified ASFV DNA. The results were expressed as Log10 genome copies/mL.

A titration of live-infectious virus was conducted by the CPE-based assay as previously described except for slight modifications (Hakobyan et al., 2018). Briefly, the titer was calculated by observing CPE on primary porcine kidney cells for the end-point of the 10-fold serial dilution. The results were expressed as log_{10}

$TCID_{50}$/mL according to the Reed and Muench method by tissue culture infective dose (TCID) (Reed and Muench, 1983).

Viral genome sequencing analysis

The sequencing of major structural proteins p72, p54, and p30 of the virus isolate was conducted as previously described (Bastos et al., 2003; Rowlands, et al., 2008; Gallardo et al., 2009). Genotyping primers which amplify the C-terminal region of the p72 gene were 5′-GGCACAAGTTCGGACATGT- 3′ and 5′-GTACTGTAACGCAGCACAG- 3′. The whole gene encoding the p54 protein was amplified using the primers 5′ -CGAAGTGCATGTAATAAACGTC-3′ and 5′ -TGTAATTTC ATTGCGCCACAAC-3′. The primer pairs used to amplify the CP204L (p30) gene were 5′-ATGAAAATGGAGGTCATCTTCAAAAC-3′ and 5′-AAGTTTAATGACCATGAGTCTTACC-3′. The obtained sequences of each of the three genes were deposited in the NCBI GenBank with the accession numbers of MW039157 (p72), MW039156 (p54) and MW039155 (p30) respectively. These sequences were further analyzed using BioEdit 7.2.5 with ClustalW for a comparison with other ASFV strains. To genotype the newly isolated strain, p72 sequences of all 24 genotype strains known to date were obtained from Genbank. In addition, p30 and p54 sequences of strains corresponding to the same genotype as the newly isolated strain were also obtained for further genetic characterization. Comparative genetic analysis was performed using BioEdit 7.2.5 with a sequence identity matrix, and the phylogenetic trees were constructed using the Neighbor-joining method with 1000 bootstrap values in Mega X software.

RESULTS

Replication kinetics of the ASFV isolate

ASFV DNA was not detected in infected cell culture supernatant at 1 dpi. Detection began in infected cell culture supernatant from 3 dpi, and the genomic copies of DNA continuously increased until 7 dpi. Infectious ASFV was also absent in infected cell culture supernatant at 1 dpi. The infectious virus was first detected in the infected cell culture supernatant from 3dpi and onward, with a continuously increasing titer until 7dpi (Figure 1).

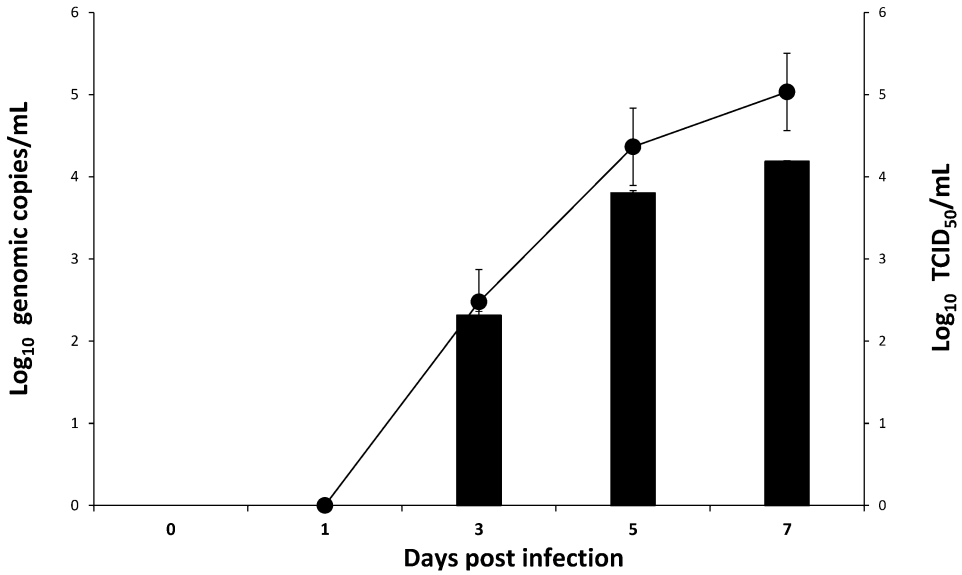

Figure 1. Replication kinetics of ASFV isolate in primary porcine kidney cells. RT-PCR results (bar) were expressed as $\log_{10}$ genomic copies/mL and CPE-based assay results (line) were expressed as $\log_{10}$ $TCID_{50}$/mL. Results of each time point represents the mean of three independent experiment of titration.

Phylogenetic analysis of the ASFV isolate

A phylogenetic analysis of the p72 partial sequence of the Vietnamese ASFV isolate categorized the isolate as part of genotype II with high homology. The p72 partial sequence of this isolate was 100% identical to the genotype II isolates from Georgia (2007), Armenia (2007), Russia (2012), Lithuania (2014), Poland (2014), China (2018), South Korea (2019), and Indonesia (2020) (Figure 2).

During phylogenetic analysis of the full p54 genome, the Vietnamese isolate was 100% identical with isolates from South Korea (2019), Mongolia (2019), Indonesia (2019), Timor-Letse (2019), Russia (2019), China (2018), Georgia (2007), Mozambique (2005), Madagascar (2003), but only 97.4% identical with the isolate from Zambia (2015) (Figure 3a).

During phylogenetic analysis of the partial genome of p30, the Vietnamese isolate was 100% identical with isolates from Timor-Letse (2019), China (2018), Russia (2012), Georgia (2007), and Mozambique (2002), but only 99.8% and 97.7% identical with isolates from Madagascar (1998) and Zambia (2002) respectively (Figure 3b).



Figure 2. Phylogenetic analysis with neighbor-joining method of major structural protein p72 partial sequence (MW039157) of a causative virus strain (●) from an ASF outbreak in Vietnam, 2019. The strains used in the analysis are represented by GenBank accession numbers/country of origin/collection date/genotype. Scale bar indicates nucleotide substitutions per site.

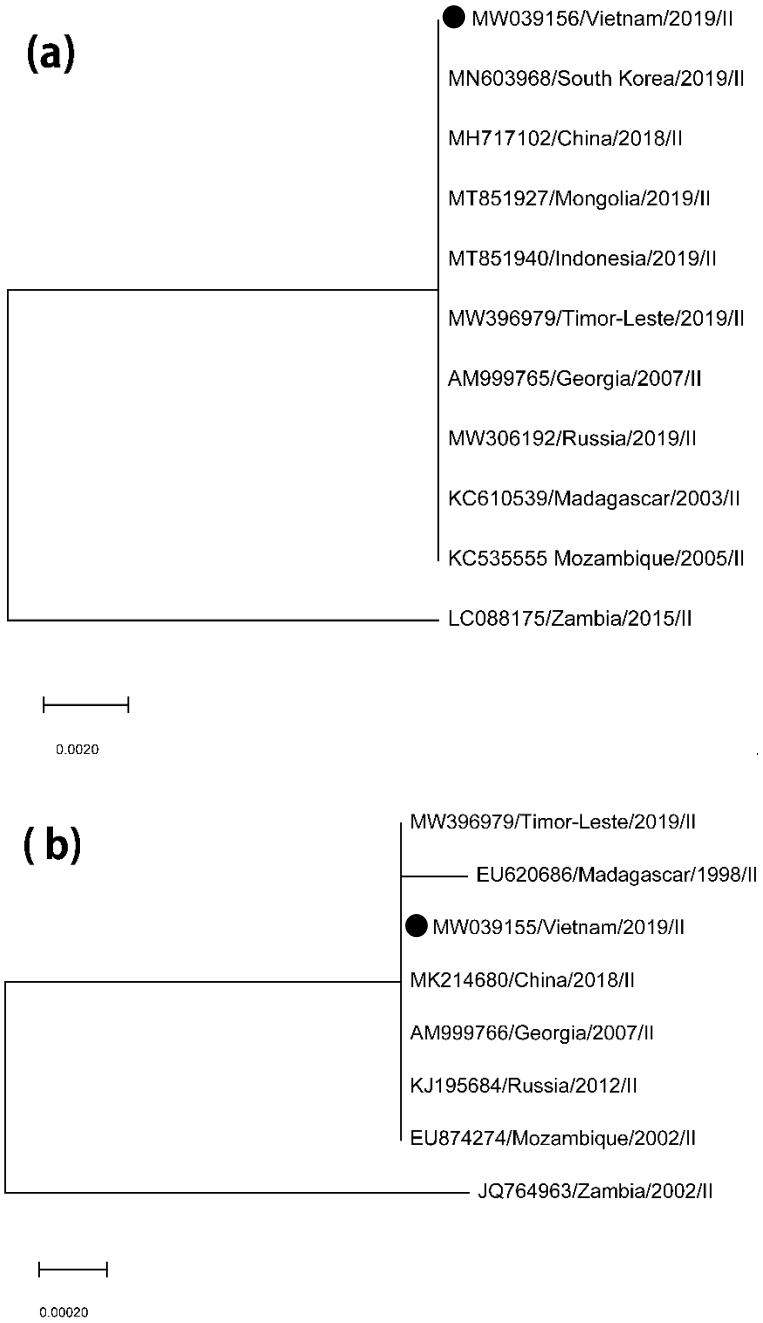

Figure 3. Phylogenetic analysis with neighbor-joining method of major structural protein p54 (MW039156; a) and p30 (MW039155; b) partial sequence of a causative virus strain (●) from an ASF outbreak in Vietnam, 2019. The strains used in the analysis are represented by GenBank accession numbers/country of origin/collection date/genotype. Scale bar indicates nucleotide substitutions per site.

DISCUSSION

The main finding in this study confirmed that the ASFV strain isolated from a recent outbreak in Vietnam belonged to Genotype II, the prevalent genotype found in Asia. Partial sequencing of the major structural proteins p72, p54, and p30 of the Vietnamese strain showed 100% identity with all strains found in other Asian countries including China, which was the first Asian country to be infected. Primary porcine kidney (PPK) cells were used to obtain a stock of the ASFV strain, resulting in the successful replication of the virus.

PPK cells were selected to establish a stable stock of virus strains for this study. Because ASFV mainly replicates in primary leukocyte lineage from pigs and can undergo genetic and antigenic changes when cultured for a long time in an existing continuous cell line, isolation of an ASFV strain is limited (Sánchez-Vizcaíno et al., 2019). Primary porcine kidney cells are one of the target cells of ASFV, and as they have the advantages of primary cells, many passages are allowed unlike monocytes and macrophages. (Oh et al., 2020). As a result of this study, PPK cells produced cell-free viral DNA and infectious viral progeny, leading to the successful isolation and establishment of new ASFV strains in Asia.

The major structural protein p72 viral gene (B646L) is highly conserved and is mainly targeted for sequencing in differential genotyping between virus strains isolated from different regions (Achenbach et al. 2017; Quembo et al. 2017). In this study, p72 genotyping confirmed that Vietnamese ASFV isolates belonged to Genotype II, together with other Asian isolates from China, Indonesia, and South Korea. Further phylogenetic analysis of p54 and p30 genes revealed that all Asian

strains had identical gene sequences to each other. Therefore, it can be concluded that the ASF outbreaks in Asia were probably due to a single introduction of the virus. In addition, the partial genes of these Asian isolates were 100% identical to those of the isolates found in Georgia and Eastern Europe since 2007, indicating that ASF spread slowly eastward without the introduction of additional genotypes. These isolates were most closely related to the isolate circulating in Mozambique but were distinguishable from the Zambian isolate in p54 and p30 gene analyses. These results are consistent with reports in 2007 that the source of the ASF outbreak in Georgia was from the eastern side of Southern Africa rather than from central or west Africa (Rowlands et al., 2007).

Several causes of ASFV transmission in Asia have been postulated including movement of infected pork or contaminated fomites, wild boar populations, and ineffective biosecurity methods. Long-distance ASF transmission between continents and countries is rare but possible through infected meat products, since ASFV can survive and remain infectious for long periods in the tissues of infected pigs. The first outbreak of ASF in Timor-Leste was more than 2,000 km from the last outbreak (Lu et al., 2020). The long-distance transport of pigs has traditionally been common in Asia, so it has been assumed that this was the main route of ASFV during the early epidemic phase (Mighell et al., 2021). ASF infection cases continue to be reported in wild boars to the OIE from China and Korea, another important risk factor of ASF transmission. In the later phase of the ASF epidemic, outbreaks have been reported at higher regional densities, suggesting that the virus was spread through direct contact with wild boars then transmitted between farms with poor biosecurity (Mighell et al., 2021).

In conclusion, an Asian strain of ASFV was successfully isolated and genetically

characterized from Vietnam. The isolate had high genetic homology with other isolates found in Asia and belonged to genotype II which was prevalent in eastern Europe. These results revealed that ASF outbreaks in Asia were probably due to a single introduction of the ASFV genotype II that spread slowly eastward and not from the introduction of additional virus genotypes. This study used partial-genome sequencing which is widely used for ASFV genetic characterization, but in the long term, whole-genome sequencing will be required to monitor the introduction of new virus genotypes into Asia.

REFERENCES

Achenbach, J. E., Gallardo, C., Nieto-Pelegrín, E., Rivera-Arroyo, B., Degefa-Negi, T., Arias, M., ... & Sánchez-Vizcaíno, J. M. (2017). Identification of a new genotype of African swine fever virus in domestic pigs from Ethiopia. Transboundary and emerging diseases, 64(5), 1393-1404.

Bastos, A. D., Penrith, M. L., Cruciere, C., Edrich, J. L., Hutchings, G., Roger, F., ... & Thomson, G. R. (2003). Genotyping field strains of African swine fever virus by partial p72 gene characterisation. Archives of virology, 148(4), 693-706.

Dixon LK, Escribano JM, Martins C, et al. (2005). The Asfarviridae. In Fauquet CM, Mayo MA, Maniloff J, et al., eds. Virus Taxonomy: VIII Report of the International Committee for the Taxonomy of Viruses. London: Elsevier/Academic Press, pp. 135-143.

Do, D. T., Park, C., Choi, K., Jeong, J., Nguyen, T. T., Le, D. T. H., ... & Chae, C. (2016). Nucleotide sequence analysis of Vietnamese highly pathogenic porcine reproductive and respiratory syndrome virus from 2013 to 2014 based on the NSP2 and ORF5 coding regions. Archives of virology, 161(3), 669-675.

Dubosson, C. R., Conzelmann, C., Miserez, R., Boerlin, P., Frey, J., Zimmermann, W., ... & Kuhnert, P. (2004). Development of two real-time PCR assays for the detection of *Mycoplasma hyopneumoniae* in clinical samples. Veterinary

microbiology, 102(1-2), 55-65.

Gallardo, C., Mwaengo, D. M., Macharia, J. M., Arias, M., Taracha, E. A., Soler, A., ... & Bishop, R. P. (2009). Enhanced discrimination of African swine fever virus isolates through nucleotide sequencing of the p54, p72, and pB602L (CVR) genes. Virus genes, 38(1), 85-95.

Hakobyan, A., Galindo, I., Nañez, A., Arabyan, E., Karalyan, Z., Chistov, A. A., ... & Zakaryan, H. (2018). Rigid amphipathic fusion inhibitors demonstrate antiviral activity against African swine fever virus. Journal of general virology, 99(1), 148-156.

Kim, J., Han, D. U., Choi, C., & Chae, C. (2003). Simultaneous detection and differentiation between porcine circovirus and porcine parvovirus in boar semen by multiplex seminested polymerase chain reaction. Journal of veterinary medical Science, 65(6), 741-744.

King, D. P., Reid, S. M., Hutchings, G. H., Grierson, S. S., Wilkinson, P. J., Dixon, L. K., ... & Drew, T. W. (2003). Development of a TaqMan® PCR assay with internal amplification control for the detection of African swine fever virus. Journal of virological methods, 107(1), 53-61.

Lu, G., Pan, J., & Zhang, G. (2020). African swine fever virus in Asia: its rapid spread and potential threat to unaffected countries. Journal of Infection, 80(3), 350-371.

Manso Ribeiro, J., Roza Azevedo, J. A., Teixeira, M. J. O., Braco Forte, M. C., Rod-rigues Ribeiro, A. M., Oliveira, F., ... & Dias Vigario, J. (1958). Peste Porcine provoquée par une souche différente (Souche L) de la souche classique. Bulletin - Office international des epizooties, 50, 516-534.

Mighell, E., & Ward, M. P. (2021). African swine fever spread across Asia, 2018–2019. Transboundary and emerging diseases, 68(5), 2722-2732.

Misinzo, G., Magambo, J., Masambu, J., Yongolo, M. G., Van Doorsselaere, J., & Nauwynck, H. J. (2011). Genetic characterization of African swine fever viruses from a 2008 outbreak in Tanzania. Transboundary and emerging diseases, 58(1), 86-92.

Montgomery, R. E. (1921). On a form of swine fever occurring in British East Africa (Kenya Colony). Journal of comparative pathology and therapeutics, 34, 159-191.

Oh, T., & Chae, C. (2020). First isolation and genetic characterization of porcine circovirus type 3 using primary porcine kidney cells. Veterinary microbiology, 241, 108576.

Quembo, C. J., Jori, F., Vosloo, W., & Heath, L. (2018). Genetic characterization of African swine fever virus isolates from soft ticks at the wildlife/domestic interface in Mozambique and identification of a novel genotype. Transboundary and emerging

diseases, 65(2), 420-431.

Reed, L. J., & Muench, H. (1938). A simple method of estimating fifty per cent endpoints. American journal of epidemiology, 27(3), 493-497.

Rowlands, R. J., Michaud, V., Heath, L., Hutchings, G., Oura, C., Vosloo, W., ... & Dixon, L. K. (2008). African swine fever virus isolate, Georgia, 2007. Emerging infectious diseases, 14(12), 1870.

Sánchez-Vizcaíno, J. M., Laddomada, A., & Arias, M. L. (2019). African swine fever virus. Diseases of swine, 443-452.

Sanna, G., Dei Giudici, S., Bacciu, D., Angioi, P. P., Giammarioli, M., De Mia, G. M., & Oggiano, A. (2017). Improved strategy for molecular characterization of African swine fever viruses from Sardinia, based on analysis of p30, CD2V and I73R/I329L variable regions. Transboundary and emerging diseases, 64(4), 1280-1286.

Takenouchi, T., Suzuki, S., Shinkai, H., Tsukimoto, M., Sato, M., Uenishi, H., & Kitani, H. (2014). Extracellular ATP does not induce P2X7 receptor-dependent responses in cultured renal-and liver-derived swine macrophages. Results in immunology, 4, 62-67.

Zhou, X., Li, N., Luo, Y., Liu, Y. E., Miao, F., Chen, T., ... & Hu, R. (2018). Emergence of African swine fever in China, 2018. Transboundary and emerging

diseases, 65(6), 1482-1484.

PART II. Pathology of Naturally Occurring African Swine Fever in Asia

ABSTRACT

African swine fever (ASF) is a contagious hemorrhagic disease found in domestic pigs and wild boars that is spreading continuously throughout Asia. Previous reports of clinical history and genetic characteristics have found that the occurrence of ASF in Asia was most likely due to a single introduction of the virus genotype II. In this study, pathological investigations were conducted in recent successive Vietnamese ASF outbreaks to elucidate the pathogenesis of naturally occurring ASFV genotype II infection in Asia. Five major organs (lung, liver, kidney, spleen, and lymph nodes) were evaluated in necropsied pigs for splenomegaly, hemorrhagic lymph nodes and renal petechia being the most prominent gross lesions. Microscopic lesions based on tissue hemorrhage and lymphoid destruction were commonly observed in all necropsied pigs. ASFV antigen loads were determined by immunohistochemistry and were antigen positive for monocyte/macrophage lineage cells as well as for hepatocytes and tubular epithelial cells. Through this pathological study, it was confirmed that naturally occurring ASF in Asia was of an acute form where ASFV antigen distribution was widely spread in virus-infected pigs. This study may facilitate the standardization of pathological investigations including the distribution of viral antigen in preparation for the diagnosis of various clinical forms during future pandemic or endemic scenarios in Asia.

Keywords: African swine fever; Pathogenesis; Histopathology; Immunohistochemistry; Asia

INTRODUCTION

African swine fever (ASF) is a contagious hemorrhagic disease that affects domestic pigs and wild boars. African swine fever virus (ASFV) is the causative agent of ASF and is a large, icosahedral, enveloped, linear double strand DNA virus (Salas and Andrés, 2013). ASFV was first described in 1921 in Kenya (Montgomery, 1921), and the virus was transmitted intercontinentally to Portugal in 1957 (Manso-Ribeiro et al., 1958). After half a century, ASF entered Georgia in 2007 (Rowlands et al., 2007), with the first outbreaks occurring in China in 2018 (Zhou et al., 2018). Currently, ASF has spread throughout Asia since 2019 to include Vietnam, The Philippines, Mongolia, North Korea, South Korea, Indonesia, Myanmar, Laos, and Cambodia (Mighell et al., 2021).

ASFV causes hemorrhagic disease such as CSF or erysipelas, showing no major clinical symptoms in wild boars, but various clinical symptoms in domestic pigs. The incubation period is 5 to 15 days, and the clinical symptoms, mortality and morbidity vary depending on the virulence of the virus strain, the route of exposure, and the dose of exposure. According to the course of clinical symptoms, the disease is classified into four types: peracute form, acute form, subacute form, and chronic form (Sánchez-Vizcaíno et al., 2019). Among them, acute ASF is the most typical form and occurs when the virus is exposed to naïve pigs, resulting in high fever, loss of appetite, and inactivity. The affected animals had extensive necrosis and hemorrhage of their lymphoid tissues, splenomegaly, erythema, and pulmonary edema. (Mebus et al., 1983).

The previous partial sequencing of viral major structural proteins p30, p54 and the

p72 genes revealed that the ASF outbreak in Asia was probably due to a single introduction of the virus genotype II from eastern Europe (Ge et al., 2018; Le et al., 2019; Kim et al., 2020). The Georgia 2007/1 isolate, which is currently referred to as the standard strain of ASFV genotype II circulating in Eastern Europe, is highly virulent and shows a high mortality rate in domestic pigs (Rowlands et al., 2007). In outbreak cases reported from Vietnam and Korea, pigs showed anorexia with high fever (> 40 °C) followed by sudden death (Le et al., 2019; Kim et al., 2020). These clinical symptoms were similar in the case of China, where all necropsied pigs had typical acute ASF lesions such as a marked enlargement of their spleens and diffuse hemorrhages in lymphoid organs (Ge et al., 2018).

In this study, pathologic investigations were conducted in successive ASF outbreak cases in Vietnam to elucidate the pathogenesis of naturally occurring ASFV genotype II infection in Asia. The pathological investigations consisted of observed gross and microscopic lesions in target organs. The viral antigen load was also evaluated in the tissues and blood by immunohistochemistry (IHC) and real time PCR (RT-PCR) respectively.

MATERIALS AND METHODS

Animal selection and sample collection

Animals for this study were selected from three ASF outbreak farms located in the Đồng Nai Province of Vietnam. Each farm was classified as farrow-to-finish unit and contained about 500, 200, and 180 sows, respectively. In all three farms, clinical symptoms including anorexia followed by sudden death began to appear from the sows in common, while redness and high fever were also found in the piglets. After positive results of ASF were obtained from serum and tissue samples tested according to the OIE recommendations, the local regulatory authority decided to cull all pigs. Prior to culling, a total of 6 growing pigs 10-16 weeks-old showing ASF-related clinical signs (high fever, recumbence, anorexia, and redness on the skin) were selected for necropsy, 2 each from 3 farms. Various tissue samples including lung, liver, kidney, spleen, lymph nodes were fixed in 10% neutral buffered formalin for histopathology. Blood samples were also collected for determining viremia of infected pigs. Although the mortality rate of disease differed depending on the farm and age, almost 100% of the animals with distinct clinical symptoms died, and an 80-90% mortality within one month of weaned and fattening pig infections were recorded. In the study period, porcine reproductive and respiratory syndrome virus (PRRSV), foot-and-mouth disease virus (FMDV), and classical swine fever virus (CSFV) were not detected in ASFV-infected pigs (Reid et al., 1999; Chung et al., 2002; Deng et al., 2005). This study was approved by Ministry of Agriculture and Rural Development (MARD) in Vietnam and conducted in compliance with the institutional rules for the care and use of laboratory animals.

Gross lesion observation

Morphometric analysis of gross lesions was conducted on five major organs including lung, liver, kidney, spleen, and lymph nodes (inguinal, gastrohepatic, renal) following, but with slight modifications to the standardized guidelines of pathological investigations in ASFV infections (Galindo-Cardiel et al., 2013). Evaluation of gross lesions were scored for characteristics of each of five organ lesions as follows: absent (-), mild (+), moderate (++) and severe (+++). Pulmonary gross lesions were scored based on the severity of edema, hemorrhage and consolidation. Hepatic gross lesions were scored for redness areas with color changes and hemorrhage with edema in the gall bladder. Renal gross lesions were scored for cortical and medullar hemorrhages. Splenic gross lesions were scored for congestion, necrosis (splenic infarction), and enlargement (splenomegaly). Lymph nodes were scored for congestion and enlargement.

Histopathology

Histopathologic lesions were scored in the same manner on a scale from - to +++. Pulmonary histopathologic lesions were scored based on the severity of edema, hemorrhage/congestion and inflammatory infiltrates. Hepatic histopathologic lesions were scored for hepatitis, angiectasia, and peribiliary edema. Renal lesions were scored for cortical and medullar hemorrhages, tubular necrosis, and interstitial inflammation. Splenic lesions were scored for lymphoid depletion, histiocytic necrosis, and hemorrhage/congestion. Lymph nodes were scored for lymphoid depletion, histiocytic necrosis and hemorrhage/congestion.

Immunohistochemistry

Immunohistochemistry (IHC) was conducted for the detection of ASFV antigen in the tissues from the disease-affected pigs. All tissue sections were deparaffinized in 60 °C overnight and treated with proteinase K in 20 min for antigen retrieval. After antigen retrieval, the sections were blocked with normal goat serum in 10 min and incubated with the rabbit polyclonal anti-ASFV p30 antibodies (Alpha Diagnostic Intl. Inc., San Antonio, Texas, USA) diluted in 1:1600 at 4 °C overnight. Alkaline phosphatase-conjugated polyclonal goat anti-rabbit immunoglobulins (DAKO, Glostrup, Denmark) diluted in 1:400 were treated as a secondary antibody for 1hour, and the color was developed with the alkaline phosphatase substrate kit (Vector Laboratories, Burlingame, CA, USA). From each IHC slides, the number of ASFV-antigen-positive cells/unit area (0.25 mm^2) was counted in randomly selected ten fields, and mean values were calculated. The ranked score was given as follows: - = no ASFV-antigen-positive cells, + = 1–10 positive cells, ++ = 11–30 positive cells, +++ = 31–100 positive cells, and ++++ = > 100 positive cells.

Quantification of ASFV DNA

Real time PCR (RT-PCR) was conducted for quantification of ASFV DNA in infected pigs. Briefly, viral DNA was extracted from serum samples using a nucleic acid extraction kit (DNeasy Blood & Tissue Kit, Qiagen, Hilden, Germany) following the manual of manufacturer. RT-PCR was performed targeting p72 genes as described previously (King et al., 2003). The forward and reverse primers, and probe were 5′-CTGCTCATGGTATCAATCTTATCGA-3′ and 5′-

GATACCACAAGATC(AG)GCCGT-3′, and 5′-(FAM)-CCACGGGAGGAATACCAACCCAGTG-3′-(TAMRA), respectively. RT-PCR conditions were 95 °C for 5 min, followed by 40 cycles of 95 °C for 15 s and 60 °C for 40 s. Genome copy numbers were calculated from Ct values using a standard curve constructed by 10-fold dilutions of quantified ASFV DNA. The results were expressed as Log_{10} genome copies/mL.

RESULTS

Gross lesion observation in pigs naturally infected with ASF

Gross lesions of pigs #1-6 were tabulated in table 1. There was moderate to severe hemorrhage and mild to moderate edema in the lungs of all pigs, but moderate consolidations were observed in 3/6 pigs (#2, #3, and #6) (Figure 1a). Moderate to severe intraparenchymal redness and hemorrhage in the gall bladder were observed in the livers of all pigs (Figure 1b). In the kidney, cortical and medullar hemorrhages differed in their levels of severity, ranging from mild to severe (Figure 1c). There were moderate to severe congestions and enlargement of the spleen (Splenomegaly) in all pigs. Spleen necrosis (splenic infarction) were observed in 5/6 pigs (#1, #2, #4, #5, and #6) with different levels of severity, from mild to severe, while one pig (#3) did not present necrotic lesions (Figure 1d). In 5/6 pigs (#2, #3, #4, #5, and #6), severe congestion and enlargement of lymph nodes were observed, while one pig (#1) show mild congestion and moderate enlargement (Figure 1e).

Table 1. Gross lesions of pigs naturally infected with ASF

Tissues	Lesions	Pig number					
		#1	#2	#3	#4	#5	#6
Lung	Edema	++	+	+	+	+	+
	Hemorrhage	+++	++	+++	++	++	+++
	Consolidation	-	++	++	-	+	++
Liver	Redness color change	+++	++	+++	+++	+++	+++
	Hemorrhage in gall bladder	+++	++	+++	+++	+++	+++
Kidney	Cortical hemorrhage	+	+++	++	+++	++	+++
	Medullar hemorrhage	+	+++	++	+++	++	+++
Spleen	Congestion	++	+++	++	+++	+++	+++
	Necrosis	+	+++	-	++	++	+
	Enlargement	++	+++	+++	++	+++	++
Lymph nodes	Congestion	+	+++	+++	+++	+++	+++
	Enlargement	++	+++	+++	+++	+++	+++

-: absent; +: mild; ++: moderate; +++: severe.

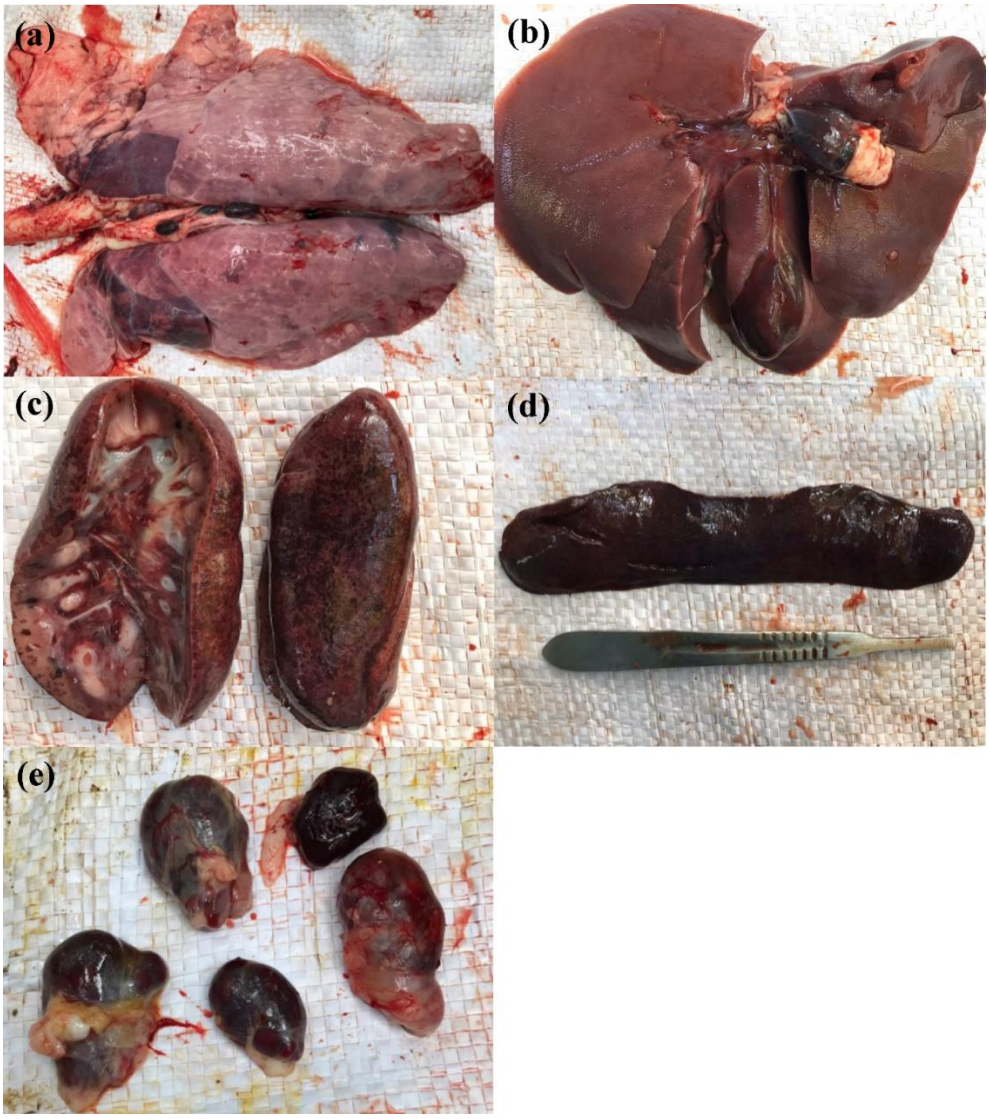

Figure 1. Gross lesions of pigs naturally infected with ASF. Congestion and consolidation in the cranial lobe of lung (a). Hemorrhage in gall bladder and bile duct with edema in vascular hilum (b). Diffuse renal darkness with cortical petechia and pelvic purpura (c). Diffuse darkness with congestion and splenic infarction (d). Congestion and enlargement of multiple lymph nodes (e).

Histopathology in pigs naturally infected with ASF

The histopathology of pigs #1-6 is tabulated in table 2. There were moderate to severe hemorrhage/congestion and inflammatory infiltrates in lungs of all pigs. Pulmonary edema was of mild to moderate severity (Figure 2a). Moderate to severe hepatitis, angiectasia, and peribiliary edema were observed in liver of all pigs (Figure 2b). Within the kidney, cortical and medullar hemorrhages with tubular necrosis were observed with different levels ranging from mild to severe in all pigs. Renal interstitial inflammation was mild in 5/6 pigs while one pig (#2) had moderate severity (Figure 2c). Mild to moderate hemorrhage/congestion and lymphoid depletion were present in the spleens of all pigs, while histiocytic necrosis was observed from mild to severe levels (Figure 2d). Within lymph nodes, moderate to severe lymphoid depletion and mild to moderate histiocytic necrosis were observed in all pigs. Hemorrhage/congestion were severe in all pigs except for one (#1) (Figure 2e).

Table 2. Histopathology in pigs naturally infected with ASF

Tissues	Lesions	Pig number					
		#1	#2	#3	#4	#5	#6
Lung	Edema	++	+	+	+	+	+
	Hemorrhage/congestion	+++	++	+++	++	++	++
	Inflammatory infiltrates	++	++	++	++	+++	++
Liver	Hepatitis	++	+++	++	+++	+++	++
	Angiectasia	+++	+++	+++	+++	+++	++
	Peribiliary edema	++	+++	++	+++	+++	++
Kidney	Cortical hemorrhage	+	+++	+	++	++	++
	Medullar hemorrhage	+	+++	+++	++	++	++
	Tubular necrosis	+	+++	++	++	+	++
	Interstitial inflammation	+	++	+	+	+	+
Spleen	Lymphoid depletion	+	++	+	++	+	+
	Histiocytic necrosis	+	+++	+	+++	++	++
	Hemorrhage/congestion	+	++	+	++	++	+
Lymph nodes	Lymphoid depletion	+++	++	++	+++	++	+++
	Histiocytic necrosis	++	++	+	+	+	+
	Hemorrhage/congestion	+	+++	+++	+++	+++	+++

-: absent; +: mild; ++: moderate; +++: severe.

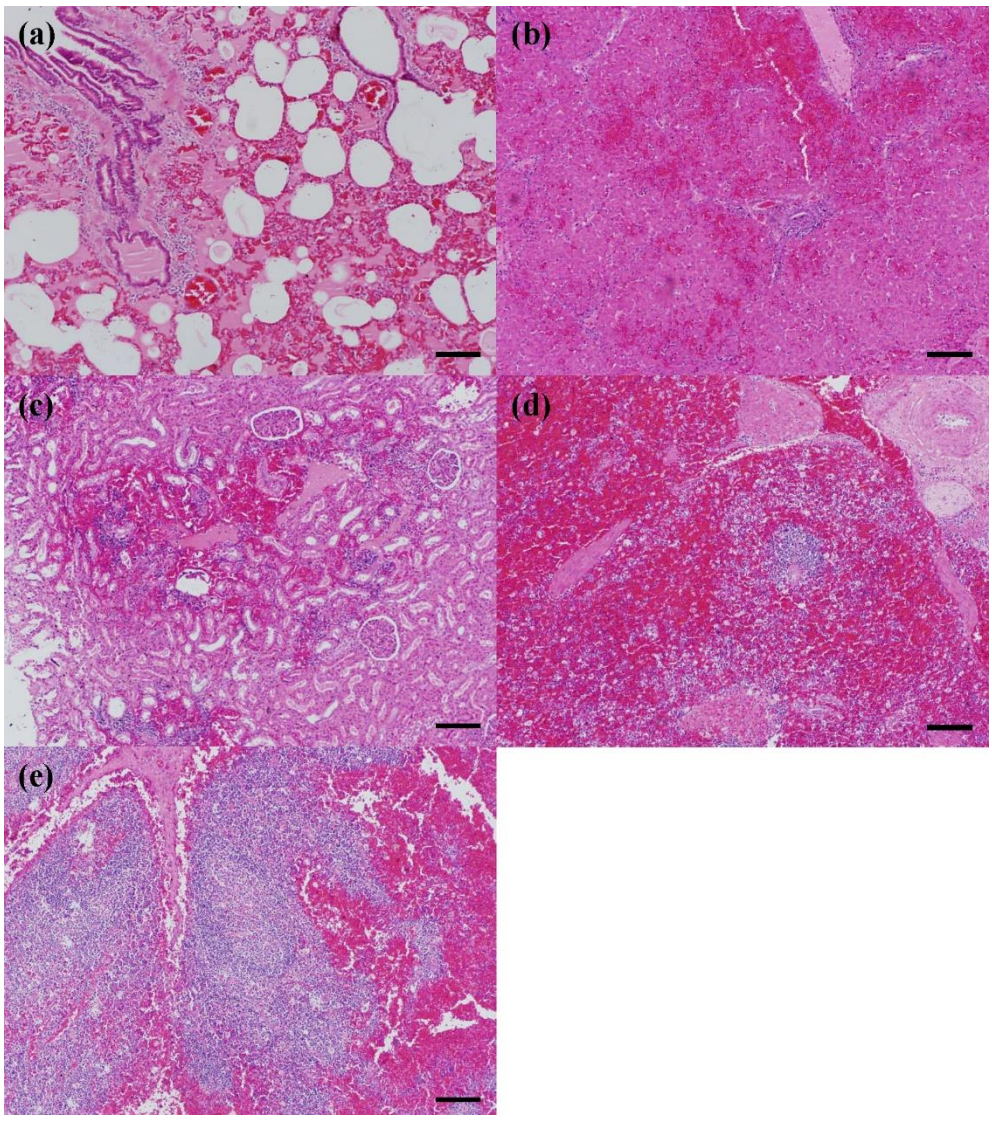

Figure 2. Histopathology in pigs naturally infected with ASF. Interstitial and intra-alveolar edema and hemorrhage in lung (a), Periportal inflammatory cell infiltration, diffuse sinusoidal dilation and peribiliary edema in liver (b), Multifocal hemorrhage and Interstitial inflammation and hyaline cast with tubular necrosis in kidney (c), Diffuse hemorrhage with lymphoid depletion in spleen (d), extensive hemorrhage around follicle with lymphoid depletion in germinal center of lymph nodes (e). Hematoxylin and eosin, bar 200 μm.

Antigen loads in tissues and blood of pigs naturally infected with ASF

ASFV antigen-positive cell types and viral loads as confirmed by IHC is tabulated in Table 3. In the lung, septal macrophages were commonly found to be antigen-positive in all pigs, while alveolar macrophages were found positive in only two pigs (#1 and #4) (Figure 3a). In the liver, many Kupffer cells and hepatocytes positive for the ASFV antigen were observed in all pigs (Figure 3b). In the kidney, an uncountable (>100) number of tubular epithelial cells were positive for ASFV antigen in all pigs, whereas mesangial cells or intravascular cells were immunolabeled in only two pigs (#1 and #5) (Figure 3c). Within the spleen, both red pulp and white pulp macrophages were ASFV-antigen positive in large numbers in all pigs (Figure 3d). In the lymph nodes, macrophages were found to be antigen-positive in all pigs, and the positive cells were found mostly in the follicles (Figure 3e). All pigs developed viremia in the resulting range of 1.98-3.07 Log_{10}genomic copies/mL. (Table 3).

Table 3. Viral antigen distribution in pigs naturally infected with ASF

Tissues	Cell type	Pig number					
		#1	#2	#3	#4	#5	#6
Lung	Septal macrophage	+++	+++	+++	++++	+++	+++
	Alveolar macrophage	+	-	-	+	-	-
Liver	Kupffer cell	+++	+++	+	++	+++	+++
	Hepatocyte	+++	+++	+	++	+++	+++
Kidney	Tubular epithelial cell	++++	++++	+++	++++	++++	++++
	Mesangial cell	+	-	-	-	+	-
	Intravascular macrophage	+	-	-	-	+	-
Spleen	Red pulp macrophage	+++	+++	+++	+++	+++	+++
	White pulp macrophage	+++	+++	+++	+++	+++	+++
Lymph node	Follicular macrophage	++	++	++	++	+++	++
	Extra follicular macrophage	+	+	+	+	++	+
Blood		2.74	3.06	2.37	3.07	2.17	1.98

-: no antigen positive cells; +: 1-10 positive cells; ++: 11-30 positive cells; +++: 31-100 positive cells; ++++: >100 positive cells, Viremia results were shown as Log_{10}genomic copies/mL.

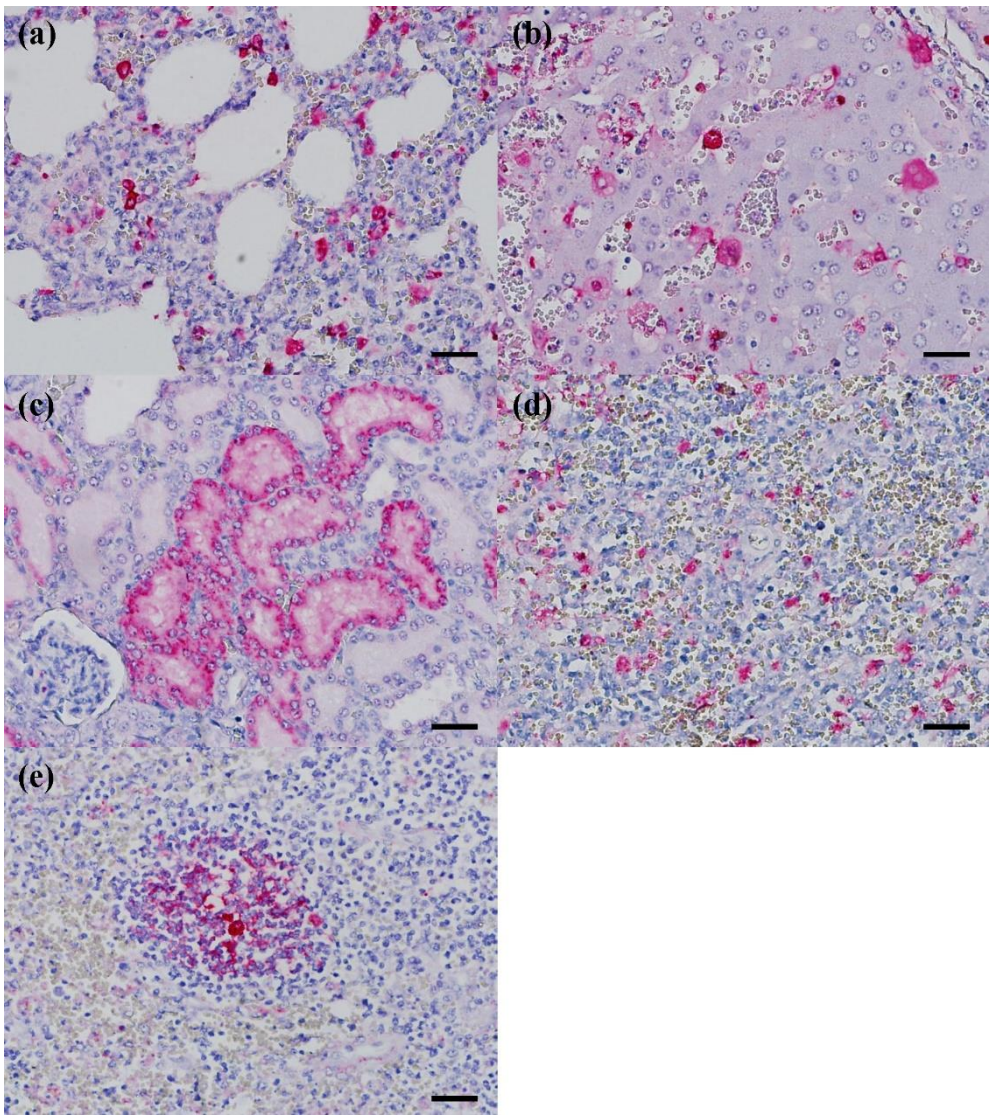

Figure 3. Immunohistochemistry in pigs naturally infected with ASF. Immuno-labelled septal macrophages and alveolar macrophages in lung (a), Immuno-labelled kupffer cells and hepatocytes in liver (b), Immuno-labelled tubular epithelial cells in kidney (c), Immuno-labelled resisting macrophages in spleen (d), immune-labelled follicular macrophages in lymph nodes (e). Hematoxylin counterstain, bar 50 μm.

DISCUSSION

In the present study, pathologic investigations were conducted in successive ASF outbreak cases in Vietnam. On outbreak farms, mortality rates of 80-90% have been recorded within one month from the time of disease onset to the culling of remaining pigs. The disease-affected pigs showed typical acute ASF lesions with splenomegaly, hemorrhagic lymph nodes and renal petechia being the most prominent gross lesions. Microscopic lesions based on tissue hemorrhage and lymphoid destruction were commonly observed in all necropsied pigs. IHC confirmed the wide range of antigen distribution in mononuclear cells, macrophages, hepatocytes and tubular epithelial cells. In Asia, including Vietnam, additional known pathogens cause hemorrhagic diseases, such as highly pathogenic-PRRS or CSF, but these were tested for and ruled out by RT-PCR method in this study.

In pulmonary pathology, diffuse hemorrhages were easily identified in the gross lesions of all infected pigs. Collapse and consolidation were observed in the lungs of some pigs, which may be attributed to a secondary bacterial infection due to immunosuppression induced by ASFV (Salguero et al., 2020). This is supported by the result that inflammatory infiltrates were frequently observed in the histopathology of the disease-affected pigs. ASFV replicates mainly in monocytes and macrophages (Sánchez-Vizcaíno et al., 2019), where antigen-positive septal macrophages were found in all pigs, whereas antigen-positive alveolar macrophages were found only in two pigs in this study. In previous experimental infection studies, viral antigens were not detected in the alveolar macrophages of infected pigs until 12 days-post-infection but were detected in septal macrophages and intravascular

macrophages at 3 days post infection. (Pérez et al., 1994; Oura et al., 1998). Therefore, it can be considered that alveolar macrophages did not significantly affect the pathogenesis of ASF.

Hepatic pathology results included redness areas with color changes in hepatic parenchyma and hemorrhage in gall bladders were evident in all necropsied animals. Diffuse necrotizing hemorrhages were observed in entire parenchyma in histopathology, and kupffer cells along with hepatocytes were immunolabelled in IHC. According to previous reports of natural infections, hemorrhage and necrosis were generally confined to zone 2 of hepatic parenchyma and immunolabelled hepatocytes were rare except in severe cases (Izzati et al., 2021). Thus, it can be concluded that the pigs examined in this study were in a significantly advanced course of ASF.

Through urinary pathology, renal petechiae in the cortex and purpura in medulla were commonly observed in all necropsied pigs. Tubular necrosis and interstitial inflammation along with multifocal hemorrhages were observed in histopathology. In IHC, antigen-positive mesangial cells and intravascular macrophages were found in only two pigs, whereas antigen-positive tubular epithelial cells were found with a high frequency in all animals. This may be attributed to either the virus replicating primarily in the monocyte/macrophage lineage infected tubular epithelial cells during the late phase of the disease (Pérez et al., 1994), or due to the high load of viral particles in urine that were reabsorbed into tubular epithelial cells (Izzati et al., 2021).

Within the lymphoid pathology, the severity of splenomegaly and lymph node enlargement varied among pigs, but hemorrhage/congestion were evident in all pigs. Lymphoid depletion and histiocytic necrosis were commonly observed in

histopathology of the spleens and lymph nodes, and these lesions were frequently accompanied by hemorrhage. In naturally occurring ASF, pigs are mainly infected with ASFV through the oronasal route, and the virus first replicates in regional lymph nodes before rapidly spreading through the lymph and blood into the body (Sánchez-Vizcaíno et al., 2019). Therefore, since lymphoid organs are the most susceptible organs to viral infection, lymphoid lesions would have been commonly observed in all pigs in the early to late stages of the disease.

In the present study, a pathological evaluation of five major organs revealed that the ASFV genotype II that is currently prevalent in Asia caused an acute form of ASF in Vietnam. The disease-affected pigs developed typical lesions of acute ASF based on lymphoid destruction and tissue hemorrhages and showed high levels of viral antigens in monocytes/macrophages lineage cells as well as in hepatocytes and tubular epithelial cells. This study may facilitate the standardization of pathological investigations including viral antigen distribution in preparation for diagnosis of various clinical forms for future pandemic or endemic scenarios in Asia. As this study focused solely on pigs that were clinically at the end stage of acute ASF, further studies on experimental infection are needed to confirm the course of disease in accordance with the infection time point and route of infection.

REFERENCES

Chung, H. K., Choi, C., Kim, J., & Chae, C. (2002). Detection and differentiation of North American and European genotypes of porcine reproductive and respiratory syndrome virus in formalin-fixed, paraffin-embedded tissues by multiplex reverse transcription-nested polymerase chain reaction. Journal of veterinary diagnostic investigation, 14(1), 56-60.

Deng, M. Y., Wang, H., Ward, G. B., Beckham, T. R., & McKenna, T. S. (2005). Comparison of six RNA extraction methods for the detection of classical swine fever virus by real-time and conventional reverse transcription–PCR. Journal of veterinary diagnostic investigation, 17(6), 574-578.

Dixon, L. K. (2008). African swine fever virus isolate, Georgia, 2007. Emerging infectious diseases, 14(12), 1870.

Galindo-Cardiel, I., Ballester, M., Solanes, D., Nofrarías, M., López-Soria, S., Argilaguet, J. M., ... & Segalés, J. (2013). Standardization of pathological investigations in the framework of experimental ASFV infections. Virus research, 173(1), 180-190.

Ge, S., Li, J., Fan, X., Liu, F., Li, L., Wang, Q., ... & Wang, Z. (2018). Molecular characterization of African swine fever virus, China, 2018. Emerging infectious diseases, 24(11), 2131.

Izzati, U. Z., Inanaga, M., Hoa, N. T., Nueangphuet, P., Myint, O., Truong, Q. L., ... & Yamaguchi, R. (2021). Pathological investigation and viral antigen distribution of emerging African swine fever in Vietnam. Transboundary and emerging diseases, 68(4), 2039-2050.

Kim, H. J., Cho, K. H., Lee, S. K., Kim, D. Y., Nah, J. J., Kim, H. J., ... & Kim, Y. J. (2020). Outbreak of African swine fever in South Korea, 2019. Transboundary and emerging diseases, 67(2), 473-475.

King, D. P., Reid, S. M., Hutchings, G. H., Grierson, S. S., Wilkinson, P. J., Dixon, L. K., ... & Drew, T. W. (2003). Development of a TaqMan® PCR assay with internal amplification control for the detection of African swine fever virus. Journal of virological methods, 107(1), 53-61.

Manso Ribeiro, J., Roza Azevedo, J. A., Teixeira, M. J. O., Braco Forte, M. C., Rod-rigues Ribeiro, A. M., Oliveira, F., ... & Dias Vigario, J. (1958). Peste Porcine provoquée par une souche différente (Souche L) de la souche classique. Bulletin - Office international des epizooties, 50, 516-534.

Mebus, C. A., McVicar, J. W., & Dardiri, A. H. (1983). Comparison of the pathology of high and low virulence African swine fever virus infections. Comparison of the pathology of high and low virulence African swine fever virus infections., 183-194.

Mighell, E., & Ward, M. P. (2021). African swine fever spread across Asia, 2018–2019. Transboundary and emerging diseases, 68(5), 2722-2732.

Montgomery, R. E. (1921). On a form of swine fever occurring in British East Africa (Kenya Colony). Journal of comparative pathology and therapeutics, 34, 159-191.

Oura, C. A. L., Powell, P. P., & Parkhouse, R. M. E. (1998). Detection of African swine fever virus in infected pig tissues by immunocytochemistry and in situ hybridisation. Journal of virological methods, 72(2), 205-217.

Pérez, J., Rodríguez, F., Fernández, A., Mulas, J. M. D. L., Gómez-Villamandos, J. C., & Sierra, M. A. (1994). Detection of African swine fever virus protein VP73 in tissues of experimentally and naturally infected pigs. Journal of veterinary diagnostic investigation, 6(3), 360-365.

Reid, S. M., Hutchings, G. H., Ferris, N. P., & De Clercq, K. (1999). Diagnosis of foot-and-mouth disease by RT-PCR: evaluation of primers for serotypic characterisation of viral RNA in clinical samples. Journal of virological methods, 83(1-2), 113-123.

Rowlands, R. J., Michaud, V., Heath, L., Hutchings, G., Oura, C., Vosloo, W., ... & Dixon, L. K. (2008). African swine fever virus isolate, Georgia, 2007. Emerging infectious diseases, 14(12), 1870.

Salas, M. L., & Andrés, G. (2013). African swine fever virus morphogenesis. Virus research, 173(1), 29-41.

Salguero, F. J. (2020). Comparative pathology and pathogenesis of African swine fever infection in swine. Frontiers in veterinary science, 7, 282.

Sánchez-Vizcaíno, J. M., Laddomada, A., & Arias, M. L. (2019). African swine fever virus. Diseases of swine, 443-452.

Van Phan Le, D. G. J., Yoon, S. W., Kwon, H. M., Trinh, T. B. N., Nguyen, T. L., Bui, T. T. N., ... & Song, D. (2019). Outbreak of African swine fever, Vietnam, 2019. Emerging infectious diseases, 25(7), 1433.

Zhou, X., Li, N., Luo, Y., Liu, Y. E., Miao, F., Chen, T., ... & Hu, R. (2018). Emergence of African swine fever in China, 2018. Transboundary and emerging diseases, 65(6), 1482-1484.

PART III. Pathology of Experimentally Induced African Swine Fever in Asia

ABSTRACT

African Swine Fever (ASF) is a contagious hemorrhagic disease that occurs in domestic pigs and wild boars and has spread throughout Asia since its introduction into China in 2018. As studies on the pathogenesis of ASF in Asia have been limited to field cases, the relationship between viral antigen distribution and clinical lesion development has not been elucidated. In this study, twenty domestic pigs were orally inoculated with ASFV genotype II Asian isolates. A temporal pathology model was established by sacrificing 4 pigs each at 1-, 3-, 5-, 7-, and 9-days post inoculation (dpi). Gross and microscopic lesions based on hemorrhage and lymphoid destruction were observed in five major organs (lung, liver, kidney, spleen, and lymph nodes) beginning at 3 dpi. Lesions were prominent at 5 dpi and reached peak severity at 9 dpi. ASFV antigen was observed from 3 dpi, mainly in the monocyte/macrophage lineage, but other cell types such as hepatocytes and tubular epithelial cells were antigen-positive at later stages of infection (7 dpi). These results demonstrated that ASFV circulating in Asia is highly virulent and sufficient in inducing the acute form of ASF via the oral route. It also provides evidence that the monocyte/macrophage lineage may play a major role in the acute ASF induction.

Keywords: African swine fever; pathogenesis; temporal pathology; antigen distribution

INTRODUCTION

African Swine Fever (ASF) is a contagious hemorrhagic disease in domestic pigs and wild boars. Although originally an indigenous disease in Africa, the first transcontinental spread of ASF occurred to Portugal in 1957, followed by Georgia in 2007 and China in 2018 (Montgomery, 1921; Rowlands et al., 2007; Zhou et al., 2018). African Swine Fever Virus (ASFV), the causative agent of ASF, is a large, icosahedral, enveloped, linear double strand DNA virus (Salas and Andrés, 2013). A genotyping classification of the partial sequence of the major structural protein p72 gene has been developed and widely used to define 24 ASFV genotypes from various regions (Achenbach et al. 2017; Quembo et al. 2017). It has been reported that the ASF outbreak in Asia was probably due to a single introduction of the virus genotype II, as it caused an acute form of ASF resulting in a high mortality rate in domestic pig populations (Le et al., 2019; Kim et al., 2020).

To determine the pathogenesis of ASFV circulating in an outbreak region, animals are experimentally infected with the virus isolates, in which the virulence, infection dose and route of isolate administration are key factors for the evolution of clinical course (Sánchez-Cordón et al., 2021). ASF is classified into four types according to the clinical course: peracute, acute, subacute, and the chronic form (Sánchez-Vizcaíno et al., 2019). It is well established that monocyte/macrophage cell lineage is a main target for ASFV (Gomez-Villamandos et al., 2013). Viral antigens can be detected in macrophages of the spleen, liver, and lung from 3 days post infection (dpi) in case of acute ASF (Fernandez et al., 1992). Cellular necrosis resulting in lymphoid destruction started at 3 dpi and became apparent at 5 dpi.

Thrombocytopenia which caused hemorrhages in multiple organs under experimental conditions was also observed at 3 dpi (Zakaryan et al., 2014).

Confirmation of a link between viral antigen distribution and tissue lesion development through experimental infection in animals is essential in understanding the pathogenesis of ASF. As there are not many studies on experimental ASF infection using strains isolated from Asia, the pathogenesis of the disease is based on what is known through field cases. The objective of the present study was to reveal the pathogenesis of ASF occurring in Asia through the establishment of temporal pathology in pigs experimentally infected with Asian isolates of ASFV.

MATERIALS AND METHODS

Animals

A total of twenty-four domestic pigs 10 weeks old and weighing 20 kg each were obtained from a commercial swine farm. The pigs had no presence of ASFV antigen or antibody as confirmed by PCR and ELISA respectively, according to the Office International des Epizooties recommendations (OIE, Paris, France). They were also confirmed negative for porcine reproductive and respiratory syndrome virus (PRRSV), foot-and-mouth disease virus (FMDV), and classical swine fever virus (CSFV) (Reid et al., 1999; Chung et al., 2002; Deng et al., 2005).

Virus

The Asian isolate of ASFV genotype II obtained from acute ASF specimens were used in this study. The virus was propagated in primary porcine kidney cells as described previously. Viral titer was determined by the Reed and Muench method for a tissue culture infective dose (Reed & Muench, 1938).

Experimental design

Twenty pigs were orally inoculated with 3 mL of 1×10^4 $TCID_{50}$/mL of the ASFV isolate, whereas the other four pigs were used as uninfected controls and received same dose of phosphate buffered saline (PBS). The pigs were housed in the same building and allowed access to commercial diets and water ad libitum. Four inoculated pigs were euthanized and submitted for necropsy at 1-, 3-, 5-, 7- and 9-days post inoculation (dpi) respectively, while the four uninfected controls were

sacrificed at the day of inoculation. Blood and tissue samples including lung, liver, kidney, spleen, and lymph nodes (inguinal, gastro-hepatic, renal) were taken for further analysis. This study was approved by the Animal Ethics Committee of the Vietnam National University of Agriculture.

Clinical signs observation

The pigs were monitored daily for clinical signs by the same personnel. Clinical signs were evaluated in eight criteria including pyrexia (>40.5 °C), anorexia, recumbence, skin hemorrhage/cyanosis, swelling, labored breathing or coughing, ocular discharge and digestive findings as previously described with slight modification (Gallardo et al., 2015).

Gross lesion observation

Morphometric analysis of gross lesions was conducted on five major organs including lung, liver, kidney, spleen, and lymph nodes (inguinal, gastrohepatic, renal) following, but with slight modifications to the standardized guidelines of pathological investigations in ASFV infections (Galindo-Cardiel et al., 2013). Evaluation of gross lesions were scored for characteristics of each of five organ lesions as follows: absent (-), mild (+), moderate (++) and severe (+++). Pulmonary gross lesions were scored based on the severity of edema, hemorrhage, and consolidation. Hepatic gross lesions were scored for redness areas with color changes and hemorrhage with edema in the gall bladder. Renal gross lesions were scored for cortical and medullar hemorrhages. Splenic gross lesions were scored for congestion, necrosis (splenic infarcts), and enlargement (splenomegaly). Lymph nodes were scored for congestion and enlargement.

Histopathology

Histopathologic lesions were scored in the same manner on a scale from absent (-) to severe (+++). Pulmonary histopathologic lesions were scored based on the severity of edema, hemorrhage/congestion and inflammatory infiltrates. Hepatic histopathologic lesions were scored for hepatitis, angiectasia, and peribiliary edema. Renal lesions were scored for cortical and medullar hemorrhages, tubular necrosis, and interstitial inflammation. Splenic lesions were scored for lymphoid depletion, histiocytic necrosis, and hemorrhage/congestion. The lesions of lymph nodes were scored for lymphoid depletion, histiocytic necrosis and hemorrhage/congestion.

Immunohistochemistry

Immunohistochemistry (IHC) was conducted for the detection of ASFV antigen in tissues from the disease-affected pigs. All tissue sections were deparaffinized in 60 °C overnight and treated with proteinase K in 20 min for antigen retrieval. After antigen retrieval, the sections were blocked with normal goat serum in 10 min and incubated with the rabbit polyclonal anti-ASFV p30 antibodies (Alpha Diagnostic Intl. Inc., San Antonio, Texas, USA) diluted in 1:1600 at 4 °C overnight. Alkaline phosphatase-conjugated polyclonal goat anti-rabbit immunoglobulins (DAKO, Glostrup, Denmark) diluted in 1:400 were treated as a secondary antibody for 1hour, and the color was developed with the alkaline phosphatase substate kit (Vector Laboratories, Burlingame, CA, USA). From each IHC slides, the number of ASFV-antigen-positive cells/unit area (0.25 mm^2) was counted in ten randomly selected fields, and mean values were calculated. The ranked score was given as follows: no ASFV-antigen-positive cells (-), 1–10 positive cells (+), 11–30 positive cells (++),

31–100 positive cells (+++), >100 positive cells (++++).

Quantification of ASFV DNA

Real time PCR (RT-PCR) was conducted for the quantification of ASFV DNA in infected pigs. Briefly, viral DNA were extracted from serum samples using a nucleic acid extraction kit (DNeasy Blood & Tissue Kit, Qiagen, Hilden, Germany) following the manual of manufacturer. RT-PCR was performed targeting p72 gene as described previously (King et al., 2003). The forward and reverse primers, and probe were 5′-CTGCTCATGGTATCAATCTTATCGA-3′ and 5′-GATACCACAAGATC(AG)GCCGT-3′, and 5′-(FAM)-CCACGGGAGGAATACCAACCCAGTG-3′-(TAMRA), respectively. RT-PCR conditions were 95 °C for 5 min, followed by 40 cycles of 95 °C for 15 s and 60 °C for 40 s. Genome copy numbers were calculated from Ct values using a standard curve constructed by 10-fold dilutions of quantified ASFV DNA. The results were expressed as Log_{10} genome copies/mL.

RESULTS

Clinical signs of pigs with experimentally induced ASF

Clinical signs observed throughout the study are tabulated in table 1. There were no specific clinical signs at 1dpi. From 3 dpi and onward, the inoculated pigs showed varying degrees of clinical signs. Pyrexia and skin hemorrhage were observed in four pigs, and ocular discharge were easily found in nine pigs. Joint swelling, labored breathing and diarrhea were occasionally observed in two pigs. At 5 dpi, most of clinical signs became evident; nine pigs developed pyrexia, anorexia, recumbence and skin hemorrhage (Figure 1). Joint swelling (four pigs) and labored breathing (six pigs) were also observed, while ocular discharge was found in all monitored pigs. Bloody diarrhea was found in two pigs. From 7 dpi, all pigs except one or two commonly showed multiple severe clinical signs, while the remaining four pigs reached a moribund stage by 9 dpi.

Table 1. Clinical signs of pigs with experimentally induced ASF

Clinical signs	Days post inoculation				
	1	3	5	7	9
Pyrexia (>40.5◦C)	0/20	4/16	9/12	7/8	4/4
Anorexia	0/20	0/16	9/12	6/8	3/4
Recumbence	0/20	0/16	9/12	6/8	3/4
Skin hemorrhage	0/20	4/16	9/12	6/8	4/4
Swelling	0/20	2/16	4/12	5/8	3/4
Labored breathing	0/20	2/16	6/12	7/8	3/4
Ocular discharge	0/20	9/16	12/12	8/8	4/4
Digestive findings	0/20	2/16	2/12	3/8	2/4

Number of Positive pigs/number of monitored pigs.



Figure 1. Clinical signs of pigs with experimentally induced ASF. The affected pigs showed diffuse redness on back (a) and petechial hemorrhage on limb (b) from 5 dpi.

Gross lesion observation in pigs with experimentally induced ASF

Gross lesions observed throughout the study are tabulated in table 2. All gross lesions in inoculated pigs were discernible from 3 dpi. In the lungs, there was mild edema, hemorrhage, and consolidation. Hemorrhage and consolidation developed to a moderate severity at 5 dpi, while edema developed to a moderate severity by 7 dpi (figure 2a). Within the livers, intraparenchymal redness was observed at 3 dpi and increased in severity from 5 dpi. Mild hemorrhages were observed in gall bladders at 5 dpi and increased in severity at 9 dpi (figure 2b). Hemorrhages were observed in the cortex and medulla of the kidney, which were mild at 5 dpi and moderate at 9 dpi (figure 2c). Congestion and enlargement in spleens began to appear at 3 dpi, which developed to moderate severity at 5 dpi and was considered severe by 7 dpi. Necrosis (splenic infarcts) were observed at 5 dpi and increased in severity until 9 dpi (figure 2d). Within the lymph nodes, congestion and enlargement were observed concurrently from 3 dpi and developed to moderate severity at 5 dpi and was considered severe by 9 dpi (figure 2e).

Table 2. Gross lesions of pigs with experimentally induced ASF

Tissues	Lesions	Days post inoculation				
		1	3	5	7	9
Lung	Edema	-	+	+	++	++
	Hemorrhage	-	+	++	++	++
	Consolidation	-	+	++	++	++
Liver	Redness color change	-	+	++	++	++
	Hemorrhage in gall bladder	-	-	+	+	++
Kidney	Cortical hemorrhage	-	-	+	+	++
	Medullar hemorrhage	-	-	+	+	++
Spleen	Congestion	-	+	++	+++	+++
	Necrosis	-	-	+	++	+++
	Enlargement	-	+	++	+++	+++
Lymph nodes	Congestion	-	+	++	++	+++
	Enlargement	-	+	++	++	+++

-: absent; +: mild; ++: moderate; +++: severe.

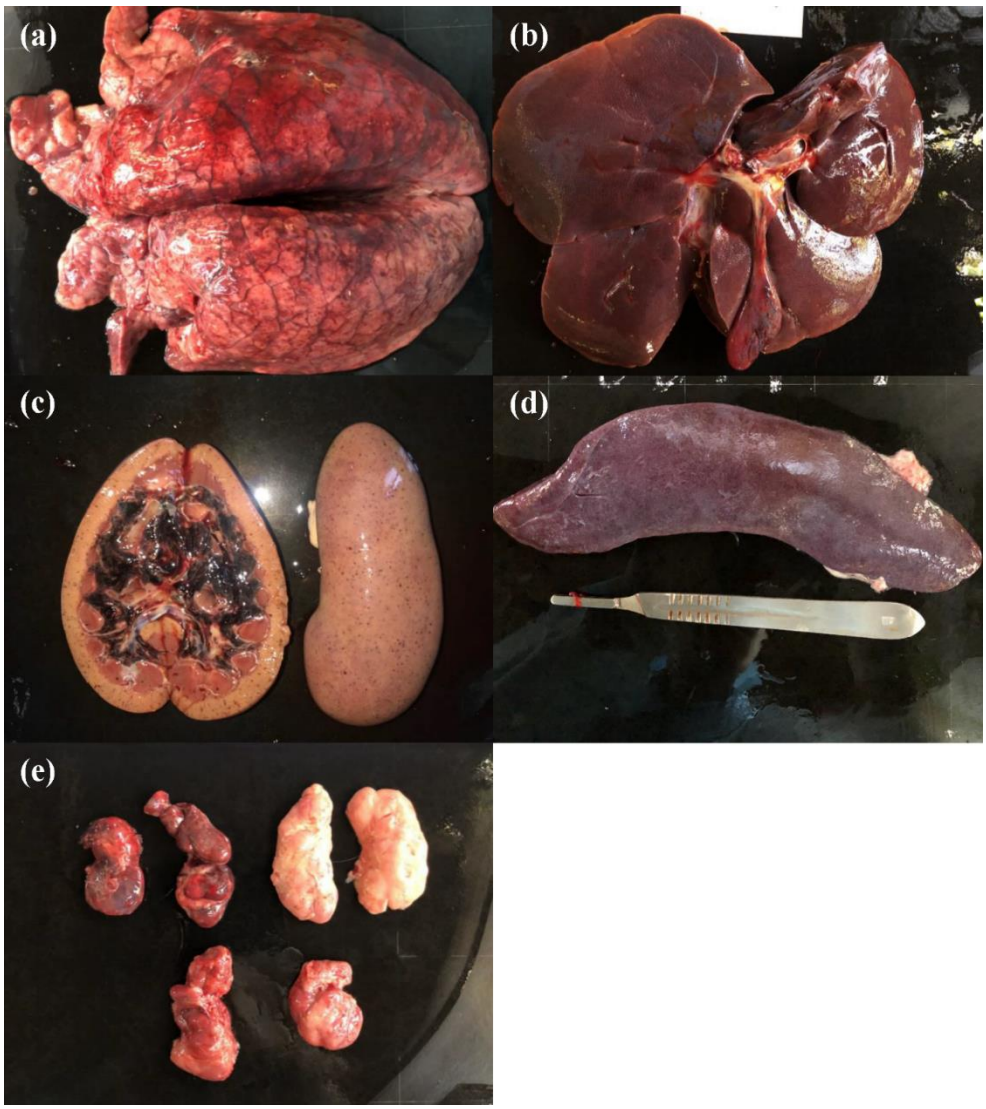

Figure 2. Gross lesions of pigs with experimentally induced ASF. Edema and hemorrhage with distension of interlobular walls in lung at 9 dpi (a). Redness color change in hepatic parenchyma and hemorrhage in gall bladder and common bile duct at 9 dpi (b). Cortical petechia and pelvic dilation with purpura at 9 dpi (c). Enlargement of spleen (splenomegaly) at 9 dpi (d). Congestion and enlargement of multiple lymph nodes at 9 dpi (e).

Histopathology in pigs with experimentally induced ASF

The results of histopathology are tabulated in table 3. A mild severity of edema and inflammatory infiltrates were observed in the lungs at 1 dpi and increased in severity at 5 dpi. Hemorrhage was observed from 3 dpi, and continued to develop until 9 dpi (figure 3a). Hepatitis was observed in livers from 1 dpi and increased in severity to moderate at 5 dpi followed by severe at 7 dpi. Sinusoidal angiectasia and peribiliary edema were observed from 3 dpi and developed until classified as severe at 9 dpi (figure 3b). Hemorrhages were observed concurrently in cortex and medulla of kidneys, which were mild in severity at 3 dpi, moderate at 5-7 dpi, and severe by 9 dpi. Tubular necrosis was observed from 3 dpi and became more intense by 9 dpi. Mild interstitial inflammation was observed from 5 dpi to 9 dpi (figure 3c). Lymphoid depletion and histiocytic necrosis in spleens were first observed at 1 dpi and increased in severity from 5 dpi and 7 dpi. Hemorrhage was observed with mild severity at 3 dpi and developed to moderate at 5 dpi followed by severe at 7 dpi (figure 3d). Lymphoid depletion and histiocytic necrosis were observed within lymph nodes from 1 dpi and increased in severity from 7 dpi and 5 dpi. Hemorrhage was mild at 3 dpi, moderate at 7 dpi, and severe by 9 dpi (figure 3e).

Table 3. Histopathology in pigs with experimentally induced ASF

Tissues	Lesions	Days post inoculation				
		1	3	5	7	9
Lung	Edema	+	+	++	++	++
	Hemorrhage/congestion	-	+	++	++	++
	Inflammatory infiltrates	+	+	++	++	++
Liver	Hepatitis	+	+	++	+++	+++
	Angiectasia	-	++	++	++	+++
	Peribiliary edema	-	+	++	++	+++
Kidney	Cortical hemorrhage	-	+	++	++	+++
	Medullar hemorrhage	-	+	++	++	+++
	Tubular necrosis	-	+	+	+	++
	Interstitial inflammation	-	-	+	+	+
Spleen	Lymphoid depletion	+	+	++	++	+++
	Histiocytic necrosis	+	+	+	++	+++
	Hemorrhage/congestion	-	+	++	+++	+++
Lymph nodes	Lymphoid depletion	+	+	+	++	+++
	Histiocytic necrosis	+	+	++	++	+++
	Hemorrhage/congestion	-	+	+	++	+++

-: absent; +: mild; ++: moderate; +++: severe.

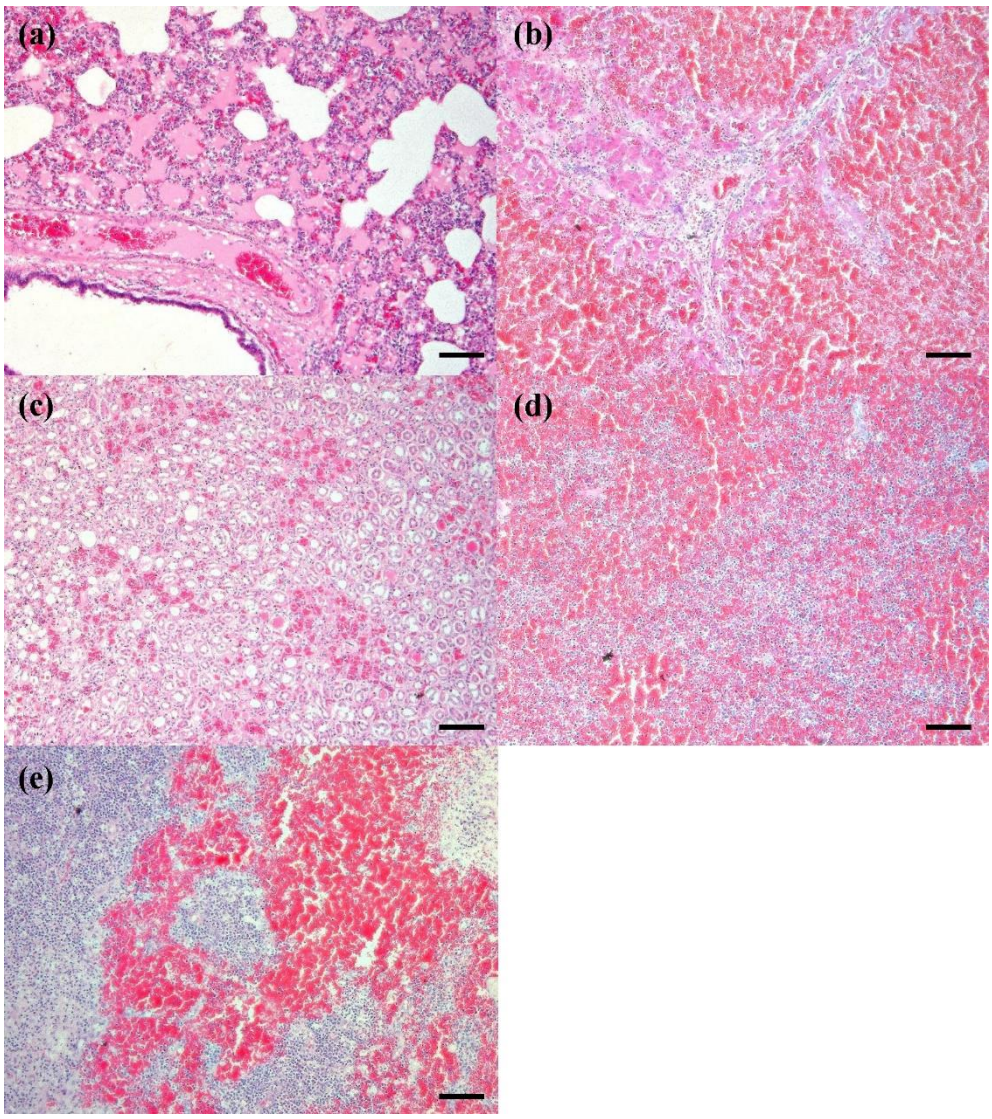

Figure 3. Histopathology in pigs with experimentally induced ASF. Interstitial and intra-alveolar edema and hemorrhage in lung at 9 dpi (a), diffuse congestion with sinusoidal dilation in liver at 9 dpi (b), Multifocal hemorrhage and hyaline cast with tubular necrosis in kidney at 9 dpi (c), intense diffuse red pulp congestion with decrease of white pulp at 9 dpi (d), diffuse hemorrhage with lymphoid depletion in lymph nodes at 9 dpi (e). Hematoxylin and eosin, bar 200 µm.

Antigen loads in tissues and blood of pigs with experimentally induced ASF

ASFV loads in tissues and blood were confirmed by IHC and RT-PCR, respectively, are tabulated in Table 4. ASFV antigens were first observed in the lungs at 3 dpi, mainly in septal macrophages. Viral antigens were found in alveolar macrophages at 5 dpi, but at lower levels than in septal macrophages (Figure 4a). Viral antigens were first observed in Kupffer cells of the liver from 3 dpi where and the antigen load continued to increase until 9 dpi. Hepatocytes were also ASFV-antigen positive at 7-9 dpi (Figure 4b). Within the kidney, tubular epithelial cells, mesangial cells, and intravascular cells were observed as positive for ASFV-antigen at 5 dpi. The antigen load in tubular epithelial cells increased rapidly from 7 dpi whereas other cell types did not (Figure 4c). ASFV antigens in the spleen were observed in macrophages of the red pulp and white pulp from 3 dpi where the antigen load increased at 7 dpi (Figure 4d). Within the lymph nodes, the viral antigens were observed mainly in macrophages of the follicle and extra-follicle from 3 dpi where the antigen load increased at 5 dpi and 9 dpi (Figure 4e). Viremia began to appear at 3 dpi and continue to increase until 9 dpi.

Table 4. Viral antigen distribution in pigs with experimentally induced ASF

Tissues	Cell type	Days post inoculation				
		1	3	5	7	9
Lung	Septal macrophage	-	++	++	++	+++
	Alveolar macrophage	-	-	+	+	++
Liver	Kupffer cell	-	+	++	++	+++
	Hepatocyte	-	-	-	+	+
Kidney	Tubular epithelial cell	-	-	+	+++	++++
	Mesangial cell	-	-	+	+	+
	Intravascular macrophage	-	-	+	+	+
Spleen	Red pulp macrophage	-	++	++	+++	+++
	White pulp macrophage	-	++	++	+++	+++
Lymph node	Follicular macrophage	-	+	++	++	+++
	Extra-follicular macrophage	-	+	++	++	++
Blood		0 ±0	2.51 ±0.16	3.82 ±0.62	4.12 ±0.11	4.62 ±0.15

-: no antigen positive cells; +: 1-10 positive cells; ++: 11-30 positive cells; +++: 31-100 positive cells; ++++: >100 positive cells, Viremia results were shown as Log_{10}genomic copies/mL (Mean value ± standard deviation).

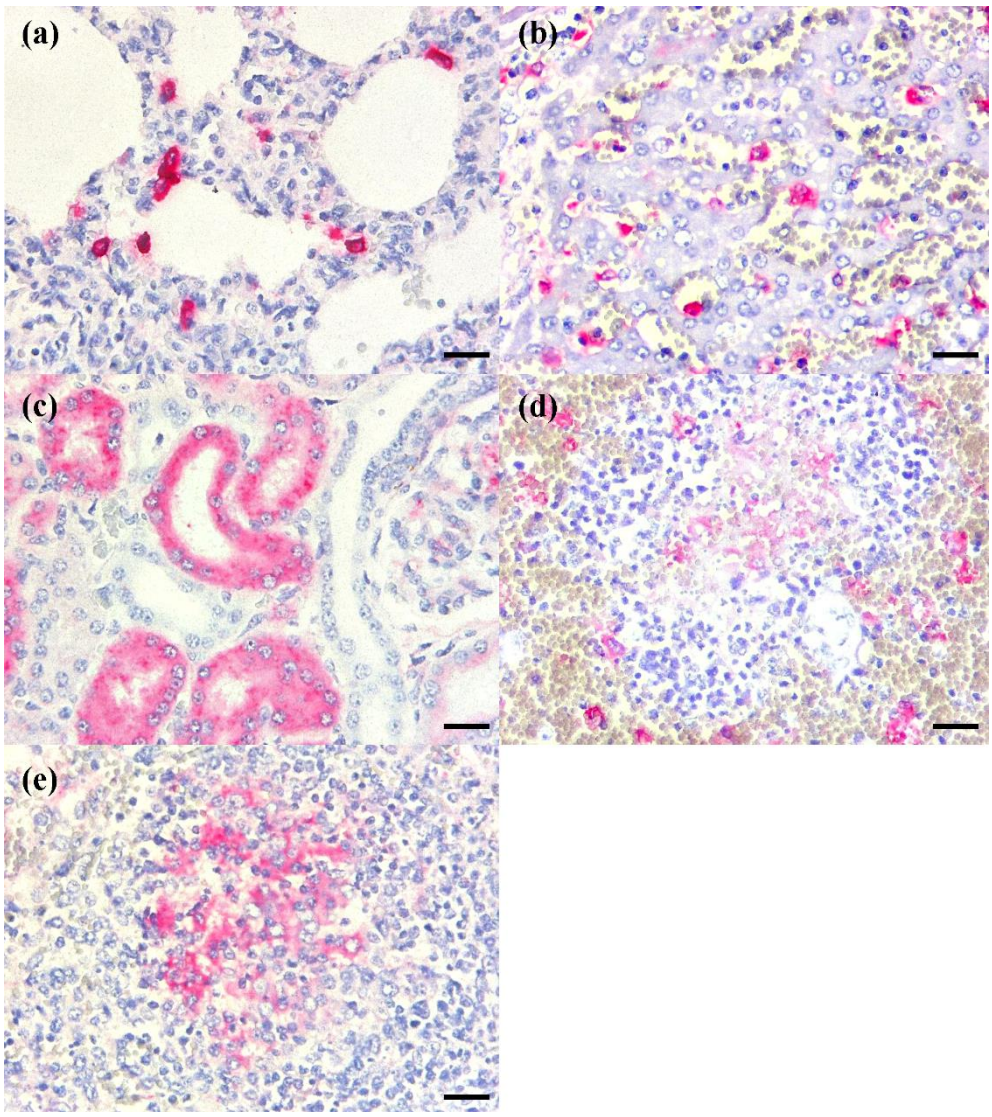

Figure 4. Immunohistochemistry in pigs with experimentally induced ASF. Immuno-labelled septal macrophages and alveolar macrophages in lung at 9 dpi (a), Immuno-labelled kupffer cells and hepatocytes in liver at 9 dpi (b), Immuno-labelled tubular epithelial cells and mesangial cell in kidney at 9 dpi (c), Immuno-labelled resisting macrophages in spleen at 9 dpi (d), immune-labelled follicular macrophages in lymph nodes at 9 dpi (e). Hematoxylin counterstain, bar 50 µm.

DISCUSSION

To elucidate the pathogenesis of ASF occurring in Asia, temporal pathology of ASF was established in domestic pigs experimentally infected with the Asian isolate of ASFV. Clinical signs of infected pigs including anorexia, recumbence, and skin hemorrhage were prominent from 5 dpi, and all pigs exhibiting these clinical signs had a high fever. Gross and microscopic lesions based on hemorrhage and lymphoid destruction were observed in five major organs (lung, liver, kidney, spleen, and lymph nodes) beginning at 3 dpi, were prominent at 5 dpi, and reached peak severity at 9 dpi. ASFV-antigen distribution was confirmed by IHC, where immunolabeling was observed from 3 dpi, mainly in the monocyte/macrophage lineage, although other cell types such as hepatocytes and tubular epithelial cells were immunolabeled at later stages of infection (7 dpi). Viremia first appeared at 3 dpi, and its titers increased rapidly at 5 dpi where they continued to increase until 9 dpi, like the pattern of clinical signs.

The temporal pathology in this experimental study revealed that acute ASF lesions, including hemorrhage and lymphoid destruction, began at an early stage of the disease (3 or 5 dpi). In this stage, ASFV antigens were mainly observed in monocytes and macrophages, not in vascular endothelial cells or lymphocytes. These results suggested that the acute ASF lesions were not directly associated with ASFV-induced cellular damage. It is further supported by the findings that ASFV replication in hepatocytes and tubular epithelium was observed at the late stage of infection (7-9 dpi), but hepatitis and tubular necrosis were observed from the early stage of infection (3-5 dpi). As the monocyte/macrophage cell lineage is the main target for

ASFV, its ability to induce a cytokine-mediated innate immune response is a critical factor in ASF pathogenesis (Maclachlan & Dubovi. 2010; Gomez-Villamandos et al., 2013). In this respect, it can be concluded that the acute ASF lesions observed in this study were induced by the immune response of macrophages, where ASFV mainly replicates during the early stages of infection.

It is well established that the clinical course of ASF depends on the virulence of the causative strain and the dose and route of infection. In this study, the animals were orally inoculated with $1x10^4$ $TCID_{50}$ of the ASFV genotype II Asian isolate. Oral or oro-nasal infection are the most common routes used in the field but are known to require a relatively high titer for infection as they show a lower efficacy than parenteral infection (McVicar, 1984). The virus-inoculated animals in this study developed typical acute ASF lesions including splenomegaly, renal petechia and hemorrhagic lymph nodes, which was like the results of previous experimental studies using ASFV genotype II European isolates (Pikalo et al., 2019). It is also partially in line with a previous study that oral inoculation with a low-dose of highly virulent genotype II virus was sufficient in infecting animals despite a delayed clinical course (Pietschmann et al., 2015). Therefore, it can be concluded that the ASFV genotype II Asian isolate is highly virulent and can cause acute ASF by the oral infection route.

Previously, it has been reported that there is very low genetic variability among the ASFV genotype II isolates found in Asia and Europe (Forth et al., 2019). However, it is not clear whether genetic variability in the virus isolates indicates a virulence range. A moderately virulent ASFV genotype II isolate was recently found in Estonia and the viral clearance was observed at 7 dpi in domestic pigs under experimental conditions (Sehl et al., 2020). The Asian isolate of ASFV genotype II used in this

study originated in Vietnam and has been shown to cause acute ASF in pigs, however, as in Europe, variants that cause different clinical forms of ASF may appear in the future in Asia as well.

In conclusion, temporal pathology of acute ASF was established in domestic pigs experimentally infected with the Asian isolate of ASFV. The developmental pattern of tissue lesions observed in temporal pathology confirmed that ASFV circulating in Asia was highly virulent and sufficient in inducing the acute form of ASF in animals via the oral route. Also, the antigen distribution of ASFV confirmed by IHC revealed that monocyte/macrophage cell lineage is the main target of the virus, and may play a major role in the acute ASF induction. Since only one Asian isolate was used in this study, further comparative experimental studies using isolates from other regions are needed to establish the pathogenesis of ASF in Asia.

REFERENCES

Achenbach, J. E., Gallardo, C., Nieto-Pelegrín, E., Rivera-Arroyo, B., Degefa-Negi, T., Arias, M., ... & Sánchez-Vizcaíno, J. M. (2017). Identification of a new genotype of African swine fever virus in domestic pigs from Ethiopia. Transboundary and emerging diseases, 64(5), 1393-1404.

Chung, H. K., Choi, C., Kim, J., & Chae, C. (2002). Detection and differentiation of North American and European genotypes of porcine reproductive and respiratory syndrome virus in formalin-fixed, paraffin-embedded tissues by multiplex reverse transcription-nested polymerase chain reaction. Journal of veterinary diagnostic investigation, 14(1), 56-60.

Deng, M. Y., Wang, H., Ward, G. B., Beckham, T. R., & McKenna, T. S. (2005). Comparison of six RNA extraction methods for the detection of classical swine fever virus by real-time and conventional reverse transcription–PCR. Journal of Veterinary Diagnostic Investigation, 17(6), 574-578.

Fernandez, A., Perez, J., Carrasco, L., Bautista, M. J., Sanchez-Vizcaino, J. M., & Sierra, M. A. (1992). Distribution of ASFV antigens in pig tissues experimentally infected with two different Spanish virus isolates. Journal of Veterinary Medicine, Series B, 39(1-10), 393-402.

Forth, J. H., Forth, L. F., King, J., Groza, O., Hübner, A., Olesen, A. S., ... & Beer,

M. (2019). A deep-sequencing workflow for the fast and efficient generation of high-quality African swine fever virus whole-genome sequences. Viruses, 11(9), 846.

Galindo-Cardiel, I., Ballester, M., Solanes, D., Nofrarías, M., López-Soria, S., Argilaguet, J. M., ... & Segalés, J. (2013). Standardization of pathological investigations in the framework of experimental ASFV infections. Virus research, 173(1), 180-190.

Gallardo, C., Soler, A., Nieto, R., Sanchez, M. A., Martins, C., Pelayo, V., Carrascosa, A., Revilla, Y., Simon, A., Briones, V., Sanchez-Vizcaino, J. M., & Arias, M. (2015). Experimental Transmission of African Swine Fever (ASF) Low Virulent Isolate NH/P68 by Surviving Pigs. Transboundary and Emerging Diseases, 62, 612-622.

Gomez-Villamandos, J. C., Bautista, M. J., Sanchez-Cordon, P. J., & Carrasco, L. (2013). Pathology of African swine fever: the role of monocyte-macrophage. Virus research, 173(1), 140-149.

Kim, H. J., Cho, K. H., Lee, S. K., Kim, D. Y., Nah, J. J., Kim, H. J., ... & Kim, Y. J. (2020). Outbreak of African swine fever in South Korea, 2019. Transboundary and emerging diseases, 67(2), 473-475.

King, D. P., Reid, S. M., Hutchings, G. H., Grierson, S. S., Wilkinson, P. J., Dixon, L. K., ... & Drew, T. W. (2003). Development of a TaqMan® PCR assay with internal amplification control for the detection of African swine fever virus. Journal of

virological methods, 107(1), 53-61.

Maclachlan, N. J., & Dubovi, E. J. (Eds.). (2010). Fenner's veterinary virology. Academic press. 167-172.

McVicar, J. W. (1984). Quantitative aspects of the transmission of African swine fever. American journal of veterinary research, 45(8), 1535-1541.

Montgomery, R. E. (1921). On a form of swine fever occurring in British East Africa (Kenya Colony). Journal of comparative pathology and therapeutics, 34, 159-191.

Pietschmann, J., Guinat, C., Beer, M., Pronin, V., Tauscher, K., Petrov, A., ... & Blome, S. (2015). Course and transmission characteristics of oral low-dose infection of domestic pigs and European wild boar with a Caucasian African swine fever virus isolate. Archives of virology, 160(7), 1657-1667.

Pikalo, J., Zani, L., Hühr, J., Beer, M., & Blome, S. (2019). Pathogenesis of African swine fever in domestic pigs and European wild boar–Lessons learned from recent animal trials. Virus research, 271, 197614.

Quembo, C. J., Jori, F., Vosloo, W., & Heath, L. (2018). Genetic characterization of African swine fever virus isolates from soft ticks at the wildlife/domestic interface in Mozambique and identification of a novel genotype. Transboundary and emerging diseases, 65(2), 420-431.

Reid, S. M., Hutchings, G. H., Ferris, N. P., & De Clercq, K. (1999). Diagnosis of foot-and-mouth disease by RT-PCR: evaluation of primers for serotypic characterisation of viral RNA in clinical samples. Journal of virological methods, 83(1-2), 113-123.

Rowlands, R. J., Michaud, V., Heath, L., Hutchings, G., Oura, C., Vosloo, W., ... & Dixon, L. K. (2008). African swine fever virus isolate, Georgia, 2007. Emerging infectious diseases, 14(12), 1870.

Salas, M. L., & Andrés, G. (2013). African swine fever virus morphogenesis. Virus research, 173(1), 29-41.

Sánchez-Cordón, P. J., Floyd, T., Hicks, D., Crooke, H. R., McCleary, S., McCarthy, R. R., ... & Núñez, A. (2021). Evaluation of Lesions and Viral Antigen Distribution in Domestic Pigs Inoculated Intranasally with African Swine Fever Virus Ken05/Tk1 (Genotype X). Pathogens, 10(6), 768.

Sánchez-Vizcaíno, J. M., Laddomada, A., & Arias, M. L. (2019). African swine fever virus. Diseases of swine, 443-452.

Sehl, J., Pikalo, J., Schäfer, A., Franzke, K., Pannhorst, K., Elnagar, A., ... & Breithaupt, A. (2020). Comparative pathology of domestic pigs and wild boar infected with the moderately virulent African swine fever virus strain “Estonia 2014”. Pathogens, 9(8), 662.

Van Phan Le, D. G. J., Yoon, S. W., Kwon, H. M., Trinh, T. B. N., Nguyen, T. L., Bui, T. T. N., ... & Song, D. (2019). Outbreak of African swine fever, Vietnam, 2019. Emerging infectious diseases, 25(7), 1433.

Zakaryan, H., Karalova, E., Voskanyan, H., Ter-Pogossyan, Z., Nersisyan, N., Hakobyan, A., ... & Karalyan, Z. (2014). Evaluation of hemostaseological status of pigs experimentally infected with African swine fever virus. Veterinary microbiology, 174(1-2), 223-228.

Zhou, X., Li, N., Luo, Y., Liu, Y. E., Miao, F., Chen, T., ... & Hu, R. (2018). Emergence of African swine fever in China, 2018. Transboundary and emerging diseases, 65(6), 1482-1484.

GENERAL CONCLUSION

African swine fever virus (ASFV) is a large, icosahedral, enveloped, linear double strand DNA virus, causes hemorrhagic disease in domestic pigs and wild boars, and has been present in Asia since 2018. The objective of this thesis was to reveal the pathogenesis of ASF occurring in Asia through viral genetic characterization, pathological investigation of outbreak cases, and experimental reproduction of the disease in animals.

In Part I, an Asian strain of ASFV was successfully isolated using primary kidney cells and genetically characterized from Vietnam. The isolate had high genetic homology with other isolates found in Asia and belonged to genotype II which was prevalent in eastern Europe. These results revealed that ASF outbreaks in Asia were probably due to a single introduction of the ASFV genotype II that spread slowly eastward and not from the introduction of additional virus genotypes.

In Part II, a pathological evaluation of five major organs confirmed that the ASFV genotype II that is currently prevalent in Asia caused an acute form of ASF in Vietnam. The disease-affected pigs developed typical lesions of acute ASF based on lymphoid destruction and tissue hemorrhages. The pigs showed high levels of viral antigens in monocytes/macrophages lineage cells as well as in hepatocytes and tubular epithelial cells.

In Part III, temporal pathology of acute ASF was established in domestic pigs experimentally infected with the Asian isolate of ASFV. The developmental pattern of tissue lesions observed in temporal pathology confirmed that ASFV circulating in Asia is highly virulent and sufficient to cause acute ASF in animals via the oral route. Also, the antigen distribution of ASFV confirmed by IHC revealed that

monocyte/macrophage cell lineage is the main target of the virus, and may play a major role in the acute ASF induction.

Conclusively, this dissertation suggested that ASF occurring in Asia is an acute clinical form of disease caused by genotype II ASFV, and that the monocyte/macrophage lineage plays a major role in the acute course of the disease. Through this study, an integrated methodology was presented for the elucidation of the pathogenesis of ASF. Whole genome sequencing and comparative pathological studies of newly discovered virus isolates continue to be needed in case other ASFV genotypes enter Asia in the future.

국문 논문 초록

아시아에서 발생하는 아프리카 돼지 열병의 병인론

(지도 교수: 채찬희, 수의사, 수의학박사)

오 태 환

서울대학교 대학원
수의학과 수의병인생물학 및 예방수의학 전공

아프리카 돼지 열병 바이러스(African Swine Fever Virus; ASFV)는 20면체의 외피를 가진 큰 크기의 선형 이중 가닥 DNA 바이러스로 사육 돼지와 야생 멧돼지에서 출혈성 질환을 유발하며 2018년부터 아시아에 유행하고 있다. 이 연구의 목적은 바이러스의 유전적 특성 규명과 더불어 발병 사례의 병리학적 조사 및 질병의 실험적 재현을 통해 아시아에서 발생하는 아프리카 돼지 열병(African Swine Fever; ASF)의 병인론을 밝히는 것이다.

첫 번째 연구에서는 아시아에서 유행하는 ASFV의 역학적 특성을 밝히기 위해 최근 베트남에서 발견된 바이러스에 대하여 유전적 특성 분석을 수행하였다. 먼저, 야외에서 발견된 바이러스를 실험실 내에서 돼지

신장 세포를 이용하여 분리배양하고 성공적으로 증식시켜 바이러스 분리주를 확보하였다. 새로운 ASFV 분리주에 대해 바이러스 주요 구조 단백질 p72, p54, p30 유전자의 부분 염기서열을 분석한 결과, 다른 아시아 국가에서 유래한 모든 분리주들과 높은 유전적 상동성을 보이며 유전형 Ⅱ로 분류되었다. 또한, 이 아시아 분리주의 해당부분 염기서열은 지난 2007년 이후 조지아와 동유럽에서 발견된 분리주의 것과 동일했다. 이러한 결과는 다른 유전형의 유입없이 ASFV 유전형 Ⅱ가 단독으로 천천히 동쪽으로 확산되며 아시아에서 ASF가 발병했을 가능성을 시사한다.

두 번째 연구에서는 아시아에서 자연적으로 발생하는 ASFV 유전형 Ⅱ 감염의 병인론을 밝히기 위해 최근 베트남에서 발생한 연속적인 감염사례에 대해 병리학적 조사를 수행하였다. 부검한 돼지의 5개의 주요 기관(폐, 간, 신장, 비장 및 림프절)을 평가하였는데, 가장 두드러진 육안 병변으로 비장 종대, 출혈성 림프절, 신장의 점상 출혈이 있었다. 또한, 광범위한 조직 출혈과 림프계 조직 손상을 기반으로 하는 현미경 병변이 공통적으로 관찰되었다. 바이러스 항원의 분포는 면역조직화학염색법을 통해 평가하였는데, 단핵구/대식세포 계통 세포들과 더불어 간세포 및 세뇨관 상피 세포에서 항원이 관찰되었다. 이 병리학적 조사를 통해 아시아에서 자연적으로 발생하는 ASF는 감염된 돼지에서 바이러스 항원이 광범위하게 분포되는 급성 형태라는 것을 알 수 있었다.

세 번째 연구에서는 20두의 돼지에게 ASFV 유전형 II 아시아 분리주를 경구로 접종하고, 접종 후 1일, 3일, 5일, 7일, 9일에 각각 4마리씩 돼

지를 희생하여 경시적 병리학 모델을 확립하였다. 접종 후 3일부터 5개 주요 장기(폐, 간, 신장, 비장 및 림프절)에서 출혈 및 림프계 조직 손상을 기반으로 하는 육안 및 현미경 병변이 관찰되었다. 이들 병변은 접종 후 5일에 두드러졌고, 접종 후 9일에 가장 심각하였다. ASFV 항원은 주로 단핵구/대식세포 계통에서 접종 후 3일부터 관찰되었지만 간세포 및 세뇨관 상피 세포와 같은 다른 유형의 세포에서는 감염 후기인 감염 후 7일에 관찰되었다. 이는 아시아에서 유행하는 ASFV가 매우 독성이 있고 경구 경로를 통해 급성 형태의 ASF를 유발할 수 있다는 것을 증명하는 결과이다. 또한, 단핵구/대식세포 계통이 바이러스 감염 초기 단계에서 급성 ASF의 유도에 중요한 역할을 할 수 있다는 것을 시사한다.

결론적으로, 이 연구는 아시아에서 발생하는 ASF가 ASFV 유전형 II에 의해 유발되는 급성 임상 형태의 질병이며, 단핵구/대식세포 계통이 질병의 급성 경과에 중요한 역할을 한다는 사실을 밝혔다. 본 연구는 ASF의 병인론 규명을 위해 통합적인 연구방법론을 제시하였다는 점에서 학술적 의의가 있다. 향후, 다른 ASFV 유전형이 아시아에 유입될 경우에 대비하여 새로 발견되는 바이러스 분리주에 대한 전체 유전자 분석 및 비교 병리학적 연구가 지속적으로 필요할 것이다.

주요어: 아프리카 돼지 열병 바이러스; 병인론; 유전적 특성 규명; 병리학적 조사; 항원분포

학 번: 2018-22255