Successful Elbow Contracture Release Secondary to Melorheostosis. A Case Report

Hyun Sik Gong, Kyung Hak Lee, Joo Han Oh, Jin-Haeng Chung, Goo Hyun Baek and Moon Sang Chung
J Bone Joint Surg Am. 2008;90:1106-1111. doi:10.2106/JBJS.G.00961

Successful Elbow Contracture Release Secondary to Melorheostosis

A Case Report

By Hyun Sik Gong, MD, PhD, Kyung Hak Lee, MD, Joo Han Oh, MD, PhD, Jin-Haeng Chung, MD, PhD, Goo Hyun Baek, MD, PhD, and Moon Sang Chung, MD, PhD

Investigation performed at the Departments of Orthopedic Surgery and Pathology, Seoul National University Bundang Hospital, Seongnam, South Korea

Melorheostosis is a rare, noninheritable developmental dysplasia of cortical bone that is often characterized by a classic radiographic pattern of flowing hyperostosis along the cortex of long bones[1]. Patients with this condition may have joint pain, stiffness, deformity, and restricted range of motion due to soft-tissue contracture[2]. Involvement usually follows a sclerotomal distribution[3] and usually affects only one extremity[4,5]. Joint contracture occurs when the abnormal ossification in the cortex of the long bone involves the soft tissues and extends into the joint, resulting in soft-tissue fibrosis and contracture[2,5,6]. There is no specific treatment for this condition; options range from nonsurgical management (e.g.,

Fig. 1
Anteroposterior (left) and lateral (right) radiographs demonstrating cortical hyperostosis of the proximal part of the ulna and specked calcification of the triceps insertion.

Disclosure: The authors did not receive any outside funding or grants in support of their research for or preparation of this work. Neither they nor a member of their immediate families received payments or other benefits or a commitment or agreement to provide such benefits from a commercial entity. No commercial entity paid or directed, or agreed to pay or direct, any benefits to any research fund, foundation, division, center, clinical practice, or other charitable or nonprofit organization with which the authors, or a member of their immediate families, are affiliated or associated.

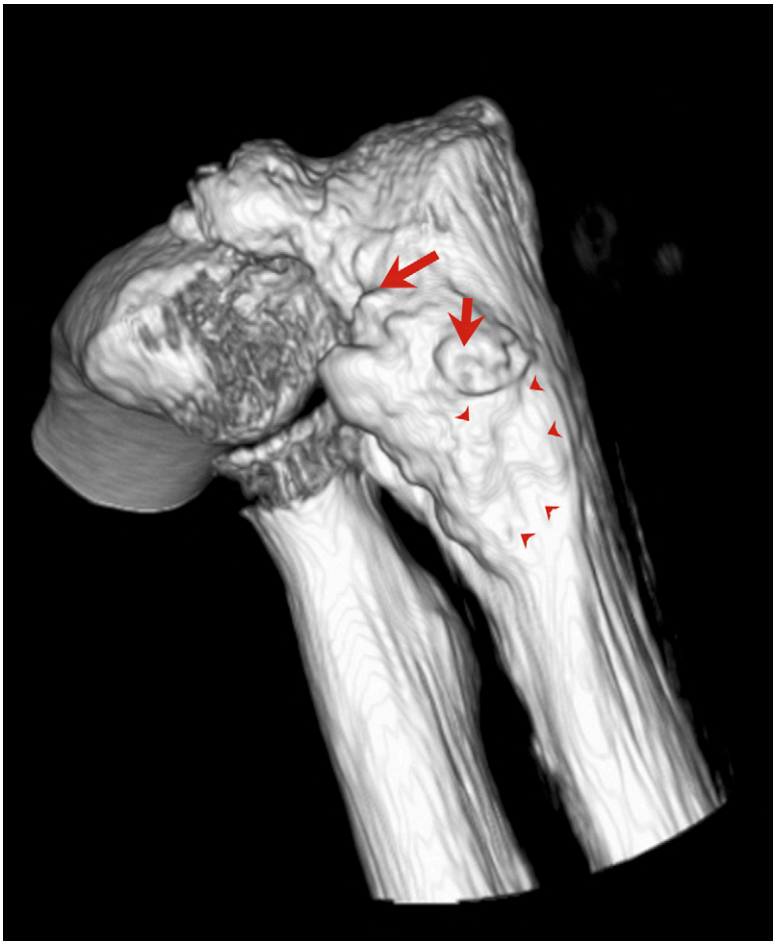

Fig. 2
Posterior view of a three-dimensional computed tomography scan showing nodularity of the periosteal bone formation (arrows) as well as a short segment that has the appearance of flowing candle-wax (arrowheads).

splinting and early training in making optimal use of the unaffected extremity) to various types of surgical management (e.g., tendon lengthening, sympathectomy, implant arthroplasty, or even amputation[2]. The literature indicates that surgical release of a joint contracture may be difficult and that recurrence of the deformity is frequent[2,4-6].

Melorheostosis of the elbow is rare compared with that of the lower extremity, and a thorough search of the literature revealed no reports on surgical release of a stiff elbow caused by this condition. We report the case of a thirty-seven-year-old man who had a fixed flexion contracture of the elbow as a result of isolated melorheostotic involvement of the proximal part of the ulna and who obtained a functional range of motion after open release of the elbow. The patient was informed that data concerning the case would be submitted for publication, and he consented.

Case Report

A thirty-seven-year-old man presented with limitation of motion of the left, nondominant elbow. He reported that pain and limited elbow motion had developed after he played a game of squash five years previously. There was no history of elbow trauma or infection. The pain had decreased with time, but limitation of elbow motion had continued to increase and had resulted in a fixed flexion deformity of 90° two years before the patient presented to us. Physical examination revealed no decrease in the range of supination and pronation of the left forearm when compared with that of the right. The patient had no ulnar nerve symptoms; sensibility in the ulnar nerve distribution was normal, and there was no intrinsic atrophy or clawing of the hand.

Plain radiographs of the affected elbow showed cortical hyperostosis of the proximal part of the ulna and speckled calcification of the distal insertion of the triceps (Fig. 1). A computed tomographic scan revealed nodularity of the periosteal bone formation and the presence of a flowing candle-wax pattern on a short segment of bone (Fig. 2). Magnetic resonance imaging demonstrated low signal intensity in all sequences (a classic sign of bone changes) and synovial inflammation without joint destruction or muscle atrophy

Fig. 3
T2-weighted sagittal magnetic resonance image showing areas of low signal intensity, indicating bone changes (long arrows). The articular cartilage (arrowheads) is intact.

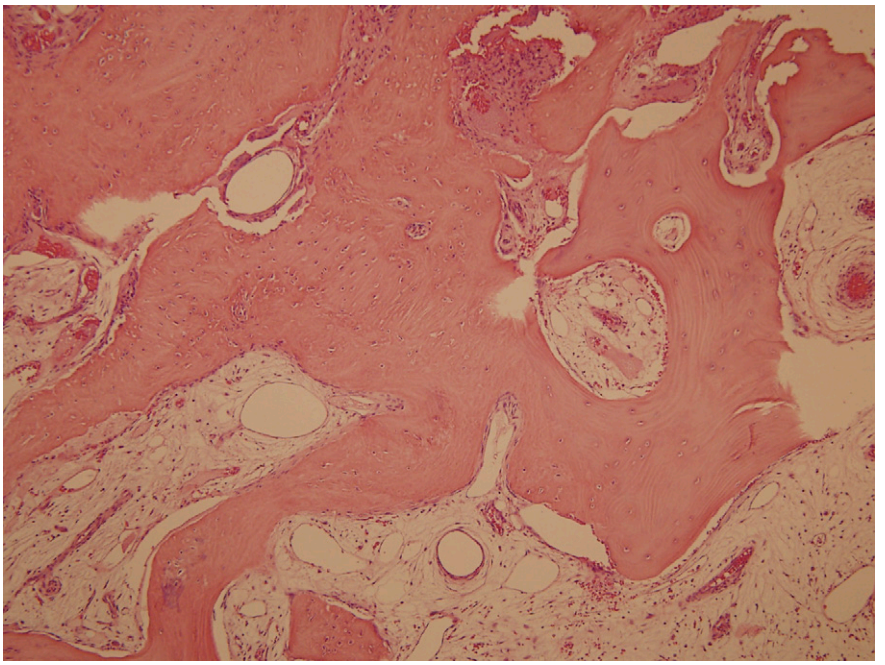

Fig. 4
Histologic examination revealed irregular, dense, hyperostotic, cortical bone trabeculae of varying thicknesses. The histologic features are consistent with melorheostosis (hematoxylin and eosin, ×100).

Fig. 5
Anteroposterior (left) and lateral (right) radiographs showing no recurrence of pathologic bone two years after the operation.

(Fig. 3). A diagnosis of melorheostosis of the proximal part of the ulna was made on the basis of the findings from these imaging studies.

Because splinting and physical therapy had proven to be ineffective and because the patient had severe limitation of functional use of the extremity, we recommended surgical release of the contracture.

The procedure was performed through a medial approach to the elbow[7,8]. The ulnar nerve was identified and mobilized. There were no adhesions along the ulnar nerve. With care taken to preserve the anterior oblique bundle of the medial collateral ligament, we resected all medial fibrotic, contracted capsuloligamentous structures. At this point, passive range of motion of the elbow was from 20° of flexion to 110° of flexion. The dissection was extended posteriorly through the interval between the triceps and the posterior aspect of the humerus. Contracted fibrous tissue was removed along with the calcification in the area of the triceps insertion. There was synovial thickening in the olecranon fossa, but the osseous contour was intact. We obtained 140° of elbow flexion without further release of the triceps fascia or muscle. Because extension was still limited, an anterior release was performed. The flexor-pronator muscle mass was found to be contracted, therefore necessitating release of the common origin of these muscles by Z-plasty. To achieve full extension, the brachialis muscle was elevated from the anterior aspect of the humerus and the anterior part of the elbow capsule was resected under direct visualization. After hemostasis was obtained, the flexor-pronator muscle was repaired in a lengthened position and the ulnar nerve was transposed subcutaneously. The wound was closed over suction drains, and the elbow was immobilized in an extended position.

The hyperostotic cortical lesion of the proximal part of the ulna was partially excised for tissue diagnosis during the operation. Histologic examination of the tissue revealed dense bone, which was consistent with the diagnosis of melorheostosis (Fig. 4).

Three days postoperatively, the elbow was mobilized with use of a continuous-passive-motion machine. The anterior cubital area developed a large bulla, which stabilized and resolved. The patient was discharged seven days postoperatively with a passive range of motion from 20° of flexion to 100° of flexion. Under the supervision of a therapist, gentle range of motion was encouraged for the next six weeks. An extension splint was worn at night during this time. Two years postoperatively, the range of motion was 20° of flexion to 135° of flexion and there was no sign of recurrence of the contracture (Fig. 5).

Discussion

Melorheostosis involving the upper extremity is not as common as that involving the lower extremity. Most reported cases involving the upper extremity are focused on the hand[6,9-12] or on the sclerotomal distribution pattern[3,13,14]. This report describes the case of a patient who had melorheostosis with isolated involvement of the proximal part of the

ulna and an associated fixed 90° elbow contracture. Following contracture release, there was substantial improvement in the arc of elbow motion. The diagnosis of our patient was made on the basis of radiographic findings that showed hyperostosis along one side of the ulnar cortex. The nodularity of periosteal bone formation visualized on the three-dimensional computed tomography scan was unlike the structured laminated bone that is seen with myositis ossificans[15]. Freyschmidt[15] reviewed twenty-three cases of melorheostosis and described different radiographic patterns besides the classic one, which has been compared to dripping or flowing candle wax on the surface of the bone. The most frequent radiographic pattern described by Freyschmidt was "osteoma-like," wherein the hyperostosis is located on the endosteal surface. Our patient had both endosteal hyperostosis on the posterior inner cortex of the ulna and nodular periosteal bone formation. A periosteal pattern of hyperostosis oriented in the long axis of the bone (as seen in our patient) is usually seen in adults, whereas an endosteal pattern of hyperostosis marked by streakiness of the long bones and spotting of the small bones prevails in children[11,12]. The biopsy specimen obtained from our patient revealed dense benign bone that was consistent with melorheostosis and did not show features of myositis ossificans or parosteal osteosarcoma, both of which should be considered in the differential diagnosis.

Although bone scintigraphy was not acquired in the case of our patient, it may be useful in confirming the diagnosis when other tests are equivocal or for the purpose of ruling out other types of asymptomatic sclerosing dysplasia[16], such as pyknodysostosis, osteopoikilosis, and osteopathia striata[17]. The magnetic resonance imaging scan did not demonstrate ligamentous or capsular calcification in our patient; however, it was effective in demonstrating a normal elbow joint and no atrophy of the muscles preoperatively. Judkiewicz et al.[18] reported that intra-articular extension of melorheostosis occurred in 35% of patients and that this finding may be associated with mineralization of the articular cartilage or with mechanical cartilage damage. It is also recognized that the longer that intervention is delayed, the more contracted the muscles become, and that the articular cartilage may also degenerate[19].

Surgical treatment for this condition includes tendon lengthening, excision of fibrous and osseous tissue, fasciotomy, capsulotomy, sympathectomy, corrective osteotomy, Ilizarov lengthening, arthrodesis, implant arthroplasty, and even amputation of severely affected limbs with vascular ischemia[2]. We were unable to find published reports of successful elbow contracture release in association with this condition. As the understanding of elbow anatomy and exposures improves, the results of the surgical treatment of heterotopic bone about the elbow are improving[7,19]. We used the medial approach to release the ulnar nerve in our patient because, when flexion is limited to 90° prior to elbow release, ulnar neuritis frequently develops as patients regain flexion, which may limit further flexion following release of an elbow contracture[20]. The medial approach is also helpful in addressing any fibrous contracture of the posterior oblique ligament of the medial collateral ligament[7,8]; this approach was helpful in addressing the contracture found close to the hyperostotic lesion in our patient. It is notable that proximal release of the flexor-pronator muscle facilitated the approach to the anterior capsule and Z-plasty was effective in overcoming the long-standing muscle contracture.

Recurrence is a major concern following contracture release in patients with melorheostosis. Younge et al.[5] noted that the soft-tissue contractures and periarticular fibrotic changes seen in patients with melorheostosis resemble those seen in patients with arthrogryposis multiplex congenita, in which the contractures are rigid and do not stretch with growth, thus causing recurrence of deformities. Only one of sixteen soft-tissue releases in their series was successful. Campbell et al. also reported that deformity recurred in five of eight joints[4]. However, similar to the good result reported in the case of our patient, positive results have been reported anecdotally in adult patients who underwent surgical debulking of the hyperostotic cortex[21] or who had total resection of the lesion[22]. ■

Hyun Sik Gong, MD, PhD
Kyung Hak Lee, MD
Joo Han Oh, MD, PhD
Jin-Haeng Chung, MD, PhD
Goo Hyun Baek, MD, PhD
Moon Sang Chung, MD, PhD
Departments of Orthopedic Surgery (H.S.G., K.H.L., J.H.O., G.H.B., M.S.C.) and Pathology (J.-H.C.), Seoul National University Bundang Hospital, Seoul National University College of Medicine, 300 Gumi-dong, Bundang-gu, Seongnam-si, Gyeonggi-do, 463-707, South Korea.
E-mail address for H.S. Gong: hsgong@snu.ac.kr

References

1. Léri A, Joanny J. Une affection non décrite des os: hyperostose ''en coulée'' sur toute la longueur d'un membre ou ''mélorhéostose''. Bull Mem Soc Med Hosp Paris. 1922;46:1141-5.

2. Greenspan A, Azouz EM. Bone dysplasia series. Melorheostosis: review and update. Can Assoc Radiol J. 1999;50:324-30.

3. Murray RO, McCredie J. Melorheostosis and the sclerotomes: a radiological correlation. Skeletal Radiol. 1979;6:57-71.

4. Campbell CJ, Papademetriou T, Bonfiglio M. Melorheostosis. A report of the clinical, roentgenographic, and pathological findings in fourteen cases. J Bone Joint Surg Am. 1968;50:1281-304.

5. Younge D, Drummond D, Herring J, Cruess RL. Melorheostosis in children. Clinical features and natural history. J Bone Joint Surg Br. 1979;61:415-8.

6. Pruitt DL, Manske PR. Soft tissue contractures from melorheostosis involving the upper extremity. J Hand Surg [Am]. 1992;17:90-3.

7. Moritomo H, Tada K, Yoshida T. Early, wide excision of heterotopic ossification in the medial elbow. J Shoulder Elbow Surg. 2001;10:164-8.

8. Wada T, Ishii S, Usui M, Miyano S. The medial approach for operative release of post-traumatic contracture of the elbow. J Bone Joint Surg Br. 2000;82:68-73.

9. Böstman OM, Bakalim GE. Carpal tunnel syndrome in a melorheostotic limb. J Hand Surg [Br]. 1985;10:101-2.

10. Caudle RJ, Stern PJ. Melorheostosis of the hand. A case report with long-term follow-up. J Bone Joint Surg Am. 1987;69:1229-31.

11. Sommer A, Voelker T, Scheer I, Roth J, Keitzer R, Amthauer H, Stöver B. Melorheostosis of the hand in a 7-year-old girl. Pediatr Radiol. 2005;35:1215-9.

12. von Gossler C, Kall S, Christopoulos G, Prommersberger KJ. [Melorheostosis of the hand. A case report]. Handchir Mikrochir Plast Chir. 2001;33:328-31. German.

13. Kawabata H, Tsuyuguchi Y, Kawai H, Yasui N. Melorheostosis of the upper limb: a report of two cases. J Hand Surg [Am]. 1984;9:871-6.

14. Ostrowski DM, Gilula LA. Mixed sclerosing bone dystrophy presenting with upper extremity deformities. A case report and review of the literature. J Hand Surg [Br]. 1992;17:108-12.

15. Freyschmidt J. Melorheostosis: a review of 23 cases. Eur Radiol. 2001;11:474-9.

16. Green AE Jr, Ellswood WH, Collins JR. Melorheostosis and osteopoikilosis, with a review of the literature. Am J Roentgenol Radium Ther Nucl Med. 1962;87:1096-111.

17. Vanhoenacker FM, De Beuckeleer LH, Van Hul W, Balemans W, Tan GJ, Hill SC, De Schepper AM. Sclerosing bone dysplasias: genetic and radioclinical features. Eur Radiol. 2000;10:1423-33.

18. Judkiewicz AM, Murphey MD, Resnik CS, Newberg AH, Temple HT, Smith WS. Advanced imaging of melorheostosis with emphasis on MRI. Skeletal Radiol. 2001;30:447-53.

19. Ring D, Jupiter JB. Operative release of complete ankylosis of the elbow due to heterotopic bone in patients without severe injury of the central nervous system. J Bone Joint Surg Am. 2003;85:849-57.

20. Antuña SA, Morrey BF, Adams RA, O'Driscoll SW. Ulnohumeral arthroplasty for primary degenerative arthritis of the elbow: long-term outcome and complications. J Bone Joint Surg Am. 2002;84:2168-73.

21. Ameen S, Nagy L, Gerich U, Anderson SE. Melorheostosis of the hand with complicating bony spur formation and bursal inflammation: diagnosis and treatment. Skeletal Radiol. 2002;31:467-70.

22. Chanda B, Millner RW. Surgical resection of melorheostosis in the ribs. Ann Thorac Surg. 2007;83:1518-9.