

Detection of Matrix Metalloproteinase -1, -2, -3 in pulpal and periapical pathosis

Su-Jung Shin, DDS, Seung-Ho Baek DDS, MSD, Ph.D, Sung-Sam Lim, DDS, MSD, Ph.D
Department of Conservative Dentistry, College of Dentistry, Seoul National University

ABSTRACT

치수 및 치근단 병소에서 기질금속단백분해효소(matrix metalloproteinase) -1, -2, -3의 분포에 관한 연구

신수정 · 백승호 · 임성삼
서울대학교 치과대학 치과보존학교실

목 적

기질금속단백분해효소(matrix metalloproteinase)는 조직의 염증 및 치유과정에서 숙주세포에서 생성, 분비되어 세포외기질(extracellular matrix)의 분해에 작용한다. 다양한 염증반응에 기질금속단백분해효소가 중요한 역할을 하는 것으로 보고되고 있으나 치수 및 치근단 질환에서의 그 역할은 거의 알려져 있지 않은 상태이다.

본 연구에서는 염증이 있는 사람의 치수 및 치근단 조직을 채취하여 Enzymeimmunoassay 및 면역조직화학적 검사를 통해 제1형, 2형, 3형 기질금속단백분해효소의 수준 및 그 분포를 측정하여 치수 및 치근단 병소에서 이 효소의 작용을 알아보는 것을 목적으로 한다.

방 법

연구재료는 근관치료를 위해 서울대학교 병원 치과 진료부 보존과에 내원한 환자를 대상으로 34개의 치아에서 통상의 근관치료 중 발수한 치수조직과 치근단 수술중 얻은 치근단 병소(n=10)를 이용하였다. 치수는 발수 전에 임상진단을 통해 급성 치수염(n=12), 만성 치수염(n=12), 정상 치수(n=10)로 구분하고 정상치수로 진단된 것을 대조군으로 설정하였다.

채취된 표본은 둘로 나누어 절반은 30분 이내에 5 μ m 두께로 동결절단을 시행하여 조직표본을 제작하였고 deep freezer에 보관하였다가 헤마톡실린-에오신 염색 및 면역조직화학적 검사를 시행하였다. 나머지 조직은 ELISA를 위해 액체 질소에 보관하였다. ELISA를 시행하기전 표본의 단백질 정량을 시행하여 모든 표본의 단백질 양을 50mg/ μ l로 일치시키고 Amersham 사의 ELISA kit를 사용하여 제1형, 2형, 3형의 기질금속단백분해효소의 양을 측정하였으며 그 결과를 Mann-Whitney U test를 사용하여 각 군간의 통계학적 유의성을 검증하였다.

결 과

1. ELISA의 결과 제1형 기질금속단백분해효소의 농도는 모든 실험군에서 대조군보다 유의성있게 높게 나타났다(p<.05). 또한 급성치수염군의 제1형 기질금속단백분해효소의 농도가 다른 실험군보다 유의성있게 높았다(p<.05).
2. 제2형 기질금속단백분해효소의 경우 급성치수염군과 대조군에서만 유의성있는 차이를 보였다(p<.05).
3. 제3형 기질금속단백분해효소의 경우 급성치수염군에서 대조군이나 만성치수염군보다 유의성 있는 높은 수치를 보였다(p<.05).
4. 면역조직화학적 검사 결과 염증성 치수에 존재하는 급성 및 만성염증세포 주위로 기질금속단백분해효소에 대한 면역반응이 존재하였으며 주로 제1형과 제3형 기질금속단백분해효소의 경우 대식세포 및 림프구 주위로 강한 발색제의 침윤양상이 관찰되었다.
5. 치근단병소의 면역조직화학적 검사 결과 만성염증 세포 주변으로 미약한 발색제의 침윤양상이 관찰되었다.

주요어 : 치수, 치근단병소, 기질금속단백분해효소, 면역조직화학적검사, ELISA, immunohistochemistry

I. INTRODUCTION

Early inflamed dental pulp contains various microbial antigens. The cells of these lesions respond to bacterial lipopolysaccharides (LPSs) and they are capable of producing various inflammatory cytokines. Inflammatory cytokines may in turn initiate and augment inflammatory processes in pulpal lesions. Localized accumulation of bacterial components in the pulp could stimulate macrophages/monocytes present in the area to produce cytokines. The secreted cytokines in turn could inhibit the differentiation of the pulp cells into odontoblasts and stimulate the pulp cells to produce matrix-degrading enzymes. This would directly affect the host's ability to synthesize reparative dentin, which would otherwise decrease the likelihood that the carious lesion would reach the pulp tissue and cause an acute pulpitis²⁹⁾.

Degeneration of matrix proteins is thought to occur in pulpal inflammation. And matrix turnover requires the activity of many different endopeptidases acting on variety of compositionally distinct proteins. Consequently, it is not surprising that over the past decades numerous proteinases of distinct gene families have been characterized³⁾. The spatially and temporally removal and remodeling of connective tissue are critical to several developmental homeostatic and reparative process.

The proteolytic enzymes are indispensable for the degradation of extracellular matrix and can be subdivided into three classes on the basis of their action on target molecules: 1) serine proteinase 2) cysteine proteinase 3) matrix metalloproteinase (MMP). Serine proteinases include plasminogen activators (PAs), leukocyte elastase, and cathepsin G^{3,4)}. In pulps and periapical lesions the mechanisms of the activation of serine proteinase were well known whereas the other proteinases have not been fully understood.

Matrix metalloproteinases (MMPs) are an important group of zinc enzymes responsible for degradation of the extracellular matrix components, such as collagen and proteoglycans. The MMPs are a family of zinc-dependent proteinases. They are secreted or released by host cells (ie, PMN, macrophage, bone cell, fibroblast) as proenzymes and require proteolytic

cleavage to become activated. There are multiple members of the family, including interstitial collagenase (MMP-1), neutrophil collagenase (MMP-8), Stromelysin-1 (MMP-3), Stromelysin-2 (MMP-10), Gelatinase A (MMP-2) and Gelatinase B (MMP-9). Recently membrane-type MMPs have been identified. The extracellular matrix substrates of MMP-1 and MMP-8 are collagen type I, II, III, VI, X and gelatin. MMP-8 is mainly expressed by PMN leukocytes whereas the highly homologous MMP-1 is expressed by fibroblast, keratinocyte, endothelial cell, monocyte/macrophage, osteoblast, chondrocyte^{7,8,10)}. About MMP-2 and MMP-9, their substrates are gelatin, collagen type IV, V, VII, X, denatured collagen, elastin and fibronectin. MMP-2 is perhaps the most widely distributed of all MMPs and has been identified in fibroblast, keratinocyte, endothelial cell, monocyte/macrophage, osteoblast and chondrocyte²⁴⁾. MMP-9 is produced by PMN leukocyte, keratinocyte and monocyte/macrophage and occasionally by fibroblast³⁴⁾. The substrates of MMP-3 and MMP-10 are proteoglycan core protein, fibronectin, laminin, collagen type IV, V, IX, X^{4,23)}. MMP-3 is expressed by stromal cells either constitutively or after induction by growth factors/cytokines or phorbol esters⁵⁾. MMP-10 is less abundant and does not appear to respond to growth factors.

In recent years MMPs have gained considerable attention in many studies. A role for collagenase on mediating collagen degradation in periodontal diseases has been recognized for more than three decades. Many researchers have been demonstrated that collagenolytic activity in gingival crevicular fluid might increase with the severity of clinical inflammation^{6,16,26)}. And Meikle et al. proposed that a major cause of tissue resorption in periodontal disease is the interaction between bacterial antigens and inflammatory cells leading to the production of cytokines²¹⁾. However, its production and regulation in pulpal lesion has not been elucidated. Several studies demonstrated the possibilities of involvement of MMPs in pulpal and periapical pathoses. In 1998 O'boskey and Panagakos proposed that cytokines stimulate the production of elevated levels of MMP-2 and MMP-9 by human pulp cells in long-term culture and that these MMPs may play a role in pulpal

inflammation²⁶⁾. Tjaderhane et al suggested that host MMPs are activated by bacterial acids and have a crucial role in the destruction of dentin by caries³⁴⁾. And Lee et al demonstrated that TGF- β and MMP-1 might be involved in tissue remodeling and have an important role in progress or mediation of periapical lesions¹⁷⁾.

There are several possibilities for the functional role of MMPs in dental tissues. Prior to mineralization the components of organic matrix of dentin are secreted and the matrix is processed and organized in predentin. Another possible role for MMPs in dentin may be the regulation of peritubular dentin formation. Also during the caries progression MMPs may be required for the degradation of the matrix demineralized beyond the possibility for remineralization. Finally MMPs of the dentin-pulp complex may be needed for the remodeling of pulpal connective tissue³⁰⁾.

Dental pulp tissue is a connective tissue and is composed of resident cells, including fibroblast-like pulpal cells and vascular endothelial cells and extracellular matrix components such as collagens and proteoglycans. The extracellular matrices of the pulp are the same as those of other connective tissues. In dental pulp major extracellular matrix proteins are type I and III collagens. And the intercellular spaces contain a fine network of reticular fibers, which may become transformed into collagen. High levels of type III collagen may in part be a reflection of the vascularity of the tissue¹⁷⁾.

Microfibrils are ubiquitous connective tissue elements: some of these small diameter fibrils are specific matrix components- fibronectin, proteoglycans and collagens. But little information is available concerning the glycoproteins in dental pulp apart from fibronectin³²⁾.

We hypothesized that MMP-1 might have more significant roles in pulpal and periapical tissue destruction than other MMPs because the extracellular matrices of dental pulp and periapical lesion are mainly type I and III collagens. The detection of MMP-2 was performed because the denatured collagen and fibronectin are the substrates of MMP-2. MMP-3 is known to digest various components of extracellular matrix, and the detection of MMP-3

was also included.

The purpose of this study was to detect the tissue levels of MMP-1, MMP-2, MMP-3 and their distribution in inflamed dental pulps and periapical lesions.

II. MATERIALS & METHODS

1. Tissue Samples

Pulps and periapical tissues were obtained from pulps by routine endodontic treatment and periapical lesions by periapical surgery at the Department of Conservative Dentistry in Seoul National University Dental Hospital between March 1st, 1999 and June 30th, 1999. 12 acute inflamed pulps, 12 chronic inflamed pulps, 10 periapical tissues and 10 normal pulps as control were examined. Before pulp extirpation clinical diagnoses were performed. The tests for clinical diagnoses were as follows:-cold test, hot test, electric pulp test, pain history taking including pain duration and severity, periodontal pocket probing, and percussion test.

Samples were subjected to enzyme-linked immunosorbent assay (ELISA) and/ or immunohistochemistry using specific antibodies to MMP-1, MMP-2 and MMP-3. They were then each divided into two parts when the sample was a sufficient amount: One part was cryosectioned, stained with hematoxylin and eosin, and processed for immunohistochemistry. The other one was snap-frozen in liquid N₂ and used for protein estimation and ELISA.

In the case that the volume of the sample was too small to be divided, it was used only for ELISA.

2. Histological Study and Immunohistochemistry

Specimens were embedded in OCT compound (Miles INC, Elkhart, Indiana, USA) within 30 minutes after sampling procedure and 5 μ m frozen-sections taken. For histological study the sections were stained with hematoxylin and eosin (H & E). And for immunohistochemistry they were fixed in 99.9% acetone for 10 minutes and incubated in Tris-buffer saline (TBS, pH 7.2-7.4) for 10 minutes.

Sections were incubated for 12 hours in 4°C moist chamber with the primary antibody, which was diluted

ed 1:200 with Antibody Diluents (DAKO, Copenhagen, Denmark). Antibodies used in this study were mouse monoclonal antibodies to MMP-1 (clone 41-1E5, Calbiochem, San Diego, California, USA), MMP-2 (clone 42-5D11, Calbiochem, San Diego, California, USA) and MMP-3 (clone 55-2A4, Calbiochem, San Diego, California, USA).

The negative control immunohistochemical procedures involved omission of the primary antibody from the staining protocol. They were treated with a reagent based on streptavidin-biotin complex/ alkaline phosphatase method. (LASB II kit, DAKO, Copenhagen, Denmark).

The immunohistochemical reactions were developed in freshly prepared fast red (DAKO, Copenhagen, Denmark) to produce a red color at the sites of reactivity. The specimens counterstained with hematoxylin (DAKO, Copenhagen, Denmark) for 20 seconds and mounted in soluble medium and examined using a light microscope ($\times 40, 100, 200, 400$).

3. Protein estimation and ELISA

Collected samples were homogenized in 200 μ l of 50 mM Tris buffered saline (50 mmol/l Tris/HCl, pH 7.5, 100 mM NaCl) placed in crushed ice to maintain the temperature below 4°C.¹⁸⁾ The homogenized sample was then centrifuged at 15,000g for 10 minutes, and the supernatant diluted 10 fold with the protein content was measured against bovine serum albumin using BCA protein assay reagent (Pierce, Rockford, Illinois, USA). Protein was diluted to 50 μ g/ml for the test.

The Amersham Biotrak MMP-1, MMP-2 and MMP-3 human ELISA system were used to determine of MMP-1, MMP-2, MMP-3 concentrations in the supernatants according to the manufacturers instructions.

The purified precursor form of human MMP-1, -2, -3 provided in the ELISA kit were used for standardization purposes. A microplate reader was used to measure the absorbance at 450nm. The MMP concentration of each sample was calibrated according versus a standard prepared by measuring a known concentration of MMP.

4. Statistical Analysis

Results from ELISA were analyzed using the Mann-Whitney rank sum test and presented as P values. Values less than .05 were considered to be significant.

III. RESULTS

1. Histological study

The figures 1~3 show the histological appearances of acute pulpitis, chronic pulpitis and periapical lesion. In acute pulpitis, the main cells were chronic inflammatory cells whereas PMNs were infiltrated slightly (Fig. 1). In the case of chronic pulpitis due to previous pulpal exposure, inflammatory cells were present in the coronal pulp, but no pathologic change was detected in the radicular portion (Fig. 2).

There were many differences among samples of periapical lesions. 2 samples were diagnosed as periapical abscesses-pus formation and inflammatory cell infiltration. The majority of cases in the periapical lesion group involved periapical granulomas containing lymphocytes and occasionally plasma cells (Fig. 3). Fibrosis as healing process was also detected.

2. Immunohistochemistry

Immunoreactivity to MMP-1, -2, -3 was evaluated on frozen sections of 2 normal pulps, 8 acute pulpitis, 5 chronic pulpitis and 7 periapical lesions (Fig. 4~6).

The MMP-1 and MMP-3 localized predominantly in the infiltrating PMNs and macrophages of acute pulpitis whereas the chronic inflammatory cells of acute pulpitis and chronic pulpitis were stained weakly. Immunoreactivity of MMP-1 and MMP-3 were stronger and more frequent than that of MMP-2, which was weakly expressed in the inflammatory cells and fibroblasts of all experimental groups.

Immunoreactivity to MMP-1, MMP-2, and MMP-3 of periapical lesion group was expressed in chronic inflammatory cells-plasma cells, lymphocytes, and macrophages. And Immunoreactivity in the periapical lesion with inflammatory cell infiltration showed different expression to that in periapical lesions without

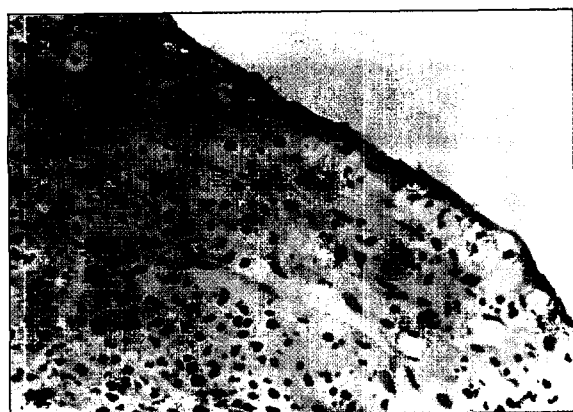

Fig. 1. Acute pulpitis (H&E, ×200).



Fig. 2. Chronic pulpitis (H&E, coronal portion ×200).

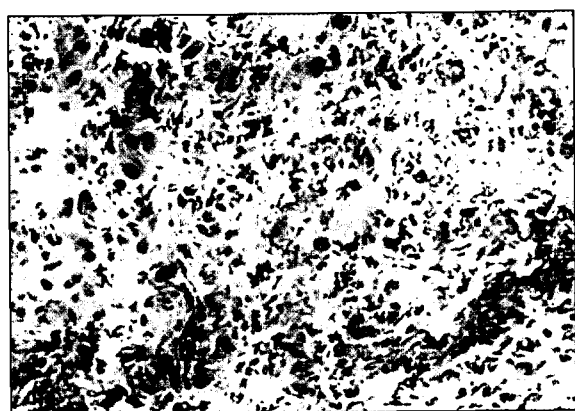


Fig. 3. Periapical lesion (H&E, ×200).



Fig. 4. Immunoreactivity of acute inflamed pulp to MMP-1 (MMP-1, ×200).

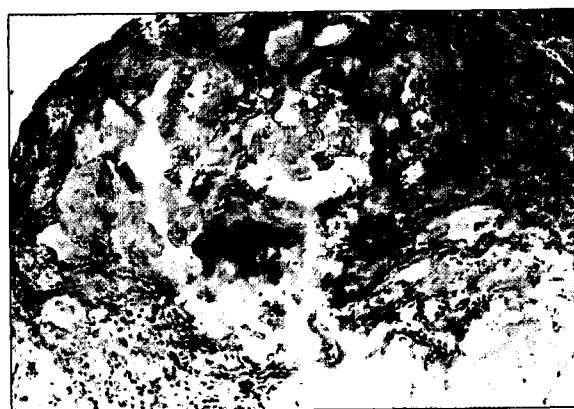


Fig. 5. Immunoreactivity of acute inflamed pulp to MMP-3 (MMP-3, ×100).

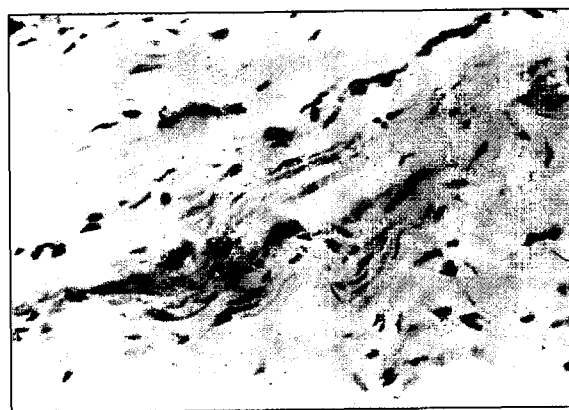


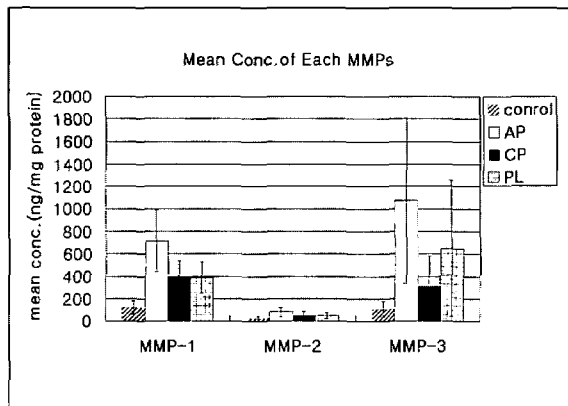
Fig. 6. Immunoreactivity of chronic inflamed pulp to MMP-1 (MMP-1, ×200).

inflammatory cell infiltration. There was little immunoreactivity in the specimen showing fibrotic change during healing process.

3. ELISA

The data from ELISA were as follows (Table 1, 2). The concentrations of MMP-1 in all experimental

Table 2. Mean concentration of each MMP-1, MMP-2, and MMP-3 AP : acute pulpitis, CP : chronic pulpitis, PL : periapical lesion



groups were significantly higher than in the control group ($p<0.05$), and the concentration of MMP-1 in the acute pulpitis group was higher than that of other groups ($p<0.05$). The concentration of MMP-1 in the periapical lesion group was somewhat higher than that in chronic pulpitis, but the difference between these groups was not statistically significant ($p>0.05$).

MMP-2 was significantly higher in the acute pulpitis group than in the control. The levels of MMP-3 were significantly higher in the acute pulpitis and periapical lesion groups than in the control ($p<0.05$).

IV. DISCUSSION

In this study pulps were divided into 3 groups by clinical diagnoses: acute pulpitis, chronic pulpitis, and normal pulp. In histopathological aspect, pulpal inflammation is not static nor does it progress in an orderly way from one stage to another. Various phases of acute and chronic inflammation may be mixed together. In addition, acute inflammation in the pulp can become chronic; conversely chronic inflammations may on occasion become acute. Therefore tissue sections both acute and chronic pulpitis may be found at the same time^{30,32}. Actually pulpal inflammation is not a simple pathway. So many factors are involved in pulpal pathosis.

In our present study clinical diagnosis did not always correlate to histologic appearance. Most cases

Table 1. Mean concentration of each MMP-1, MMP-2, and MMP-3

Group	Mean Con. \pm SD (ng/mg protein)		
	MMP-1	MMP-2	MMP-3
Control (n=10)	120.4 \pm 58.4	22.2 \pm 20.4	108.6 \pm 71.6
Acute Pulpitis (n=12)	713.2 \pm 273.8	81.4 \pm 42.6	1072.0 \pm 734.0
Chronic Pulpitis (n=12)	386.6 \pm 153.2	45.4 \pm 40.4	308.0 \pm 276.6
Periapical Lesion (n=10)	388.2 \pm 141.0	47.6 \pm 26.2	648.2 \pm 604.2

of acute pulpitis showed chronic inflammatory cell infiltration. In several cases no pathologic change was observed in the cases diagnosed as chronic pulpitis.

In terms of the criteria of clinical diagnoses subjective symptoms (i. e., pain) were thought to be the most reliable parameters. Mitchell and Tarplee suggested that severity and duration of pain appear to be partially related to the status of the pulp, but subjective symptoms are occasionally misleading³⁰.

In addition to the inaccuracy of clinical diagnoses, procedural errors should be considered. Thermal and mechanical stimuli during sampling procedure-pulp extirpation and tooth extraction-might do harmful effect on pulp samples. Nevertheless the sampling procedure used in this study is thought to be a simple available method if only the data should be interpreted carefully.

Immunohistochemically MMP-1 and -3 are localized in the extracellular matrix around the inflammatory cells of the acute pulpitis group. These results suggest that MMP-1, and -3 may be secreted by inflammatory cells- PMNs, macrophages, plasma cells, and lymphocytes in inflamed pulps and periapical lesions. About MMP-2 no detectable differences were examined between acute pulpitis and chronic pulpitis. Kim and Lim reported the immunoreactivity to MMP-3 of endothelial cells and inflammatory cells in inflamed pulps and these results are not consistent with those of present study¹³.

In periapical lesions the histological appearances were different from sample to sample, so the subdivi-

sion would be needed. In this study the periapical lesions were composed of 1 periapical abscess, 7 periapical granulomas and 2 periapical cysts. Weak immunoreactivity to MMPs around inflammatory cells, mainly plasma cells and macrophages, was detected.

Only pulps were used as the source of MMPs, so odontoblast and pulp-dentin complex were not considered in this study. In fact several studies showed that the pulp-dentin complex may secrete MMPs and have intimate relations with pulpal tissue destruction³⁴.

Our ELISA results demonstrate that the concentrations of MMP-1, -2, and -3 in the acute pulpitis group were significantly higher than those of the control, which suggests that MMPs may play a role in the progress of pulpal inflammation and pulp tissue destruction. MMPs were also detected in the chronic pulpitis and periapical lesion groups, but their role are believed to be less important than in acute pulpitis.

However, ELISA includes both active form and latent form of MMPs, so elevated MMP concentration does not always indicate the state of tissue destruction.

Actually MMP secretion is not a simple pathway and it is known that it is regulated by several gates, and that the transcription of most MMP genes is regulated by endogenous growth factors and cytokines². The transcriptional effects of growth factors and cytokines are mediated through complex signaling pathways. IL-1 α , IL-1 β , and TNF- α were reported to be capable of inducing MMP production. Growth factors and cytokines characteristically result in 20-50-fold increases in both mRNA and protein levels.^{2,21,31} Among growth factors and cytokines particular interest is focused on IL-1 and TNF- α because of their dramatic inductive effect on MMP expression in both immigrant and resident cells. IL-1 appears to be the most potent cytokine with activity at concentrations as low as 10-10M. In most in vitro systems TNF- α requires at least 10-fold higher concentrations to elicit the same response⁹. Ko and Lim demonstrated that tissue levels of IL-1 α , IL-1 β , TNF- α were elevated in inflamed pulps and periapical lesions¹⁴. MMP secretion may also have a correlation with these cytokine levels of pulps and periapical lesions. The

intercellular interactions mediated by these and other immunoregulatory cytokines during inflammation are complex. Further study about the relationship between MMPs and cytokines in inflamed pulps and periapical lesions will be needed.

And several studies showed that human MMPs could participate in the degradation of dentin organic matrix after demineralization in caries lesion. They demonstrated that the combined effects of multiple MMPs including MMP-8, MMP-2 and MMP-9 most likely caused the degradation of collagen. And after demineralization activated host MMPs ultimately destroy the dentin matrix³⁴.

In this study MMPs appear to be positively related to the patient's subjective symptoms. But symptoms were variable in individuals, and the severity of pain was difficult to be evaluated. It was not possible to compare MMP level with symptoms.

Several studies have found that prostaglandins (PGs) influence the secretion of proteolytic enzymes by direct and/or indirect mechanism. There are several possibilities of positive relation between patient symptoms and MMP level. These might be due to elevated PGE2 levels in symptomatic pulpitis. McCarthy et al demonstrated that PGE2 potentially induced expression of collagenase in macrophages (but not fibroblasts or keratinocytes) through a cAMP-dependent signaling mechanism^{11,20,38}. Macrophages are known to play an important role in regulating the turnover of extracellular matrix (ECM) in both normal and pathologic condition, by the secretion of proteases including MMPs, protease inhibitors and cytokines. Several studies have suggested that MMP expression in macrophages might be dependent on prostaglandin E2. PGE2 is synthesized from arachidonic acid and cyclooxygenase (COX) is the rate-limiting enzyme in this pathway. Arias-Nagrete et al showed that the activation of macrophages was correlated with the induction of COX-2. Macrophages expressing COX-2 are known to produce eicosanoids that have proinflammatory effects, increasing vascular permeability, promoting chemotaxis and favoring cell proliferation and cholesterol ester retention³⁵. In our previous study Son and Lim demonstrated increased level of PGE2 in acute pulpitis group. Furthermore, the immunohistochemi-

cal results demonstrated that the main source of PGE2 in periapical pathosis might be endothelial cell³³⁾. However, Myauchi et al showed the presence of immunoreactivity to PGE2 in macrophages²²⁾. In this study there were little immunoreactivity to MMPs in endothelial cells of experimental groups. These findings indicate that the major source of MMPs in inflamed pulps and periapical lesions is inflammatory cells not endothelial cell. And these results are not concordant with those of our previous Son and Lim's study. Further study on the interaction between MMPs and prostaglandins in macrophages and endothelial cells is needed.

Of additional interest is the possibility that the prostaglandin inhibitors may be used to decrease MMP activity. McCarthy et al reported that inhibition of the LPS-induced synthesis of PGE by indomethacin results in both a significant reduction of macrophage cAMP levels as well as an inhibition of production of collagenase^{20,36)}. However, the relationship between PG inhibitor and MMP activity needs to be evaluated in further study.

The results of present study support a role of MMPs in inflamed pulpal and periapical tissue destruction, and a close relationship between prostaglandins and MMPs.

In conclusion, MMPs were expressed in inflamed pulps and periapical pathosis, which suggest that MMPs play an important role in pulpal and periapical inflammation, especially in symptomatic pulpitis.

V. CONCLUSION

According to this study we could summarize as follows:

1. The concentrations of MMP-1 in all experimental groups were significantly higher than in the control ($p<0.05$). And the concentration of MMP-1 in the acute pulpitis group was significantly higher than in other groups ($p<0.05$).
2. The acute pulpitis and control groups were significant different in terms of their MMP-2 levels ($p<0.05$).
3. The concentration of MMP-3 in the acute pulpitis group was significantly higher than those of the control and chronic pulpitis groups ($p<0.05$).
4. Immunohistochemically the MMP-1 and MMP-3 were localized strongly in the infiltrating PMNs and macrophages of the acute pulpitis group, whereas the chronic inflammatory cells of the acute and chronic pulpitis groups were stained weakly.

These results suggest that MMPs play a more important role in pulp tissue destruction of acute pulpitis than chronic pulpitis. And MMPs may have positive relations with the symptoms of pulpitis.

REFERENCES

1. Arias-Negrete S, Keller K, Chadee K. Proinflammatory cytokines regulate cyclooxygenase-2 mRNA expression in human macrophages. *Biochem Biophys Res Commun*. 1995 Mar 17;208(2):582-9.
2. Birkedal-Hansen H. Role of cytokines and inflammatory mediators in tissue destruction. *J Periodontol Res*. 1993 Nov;28:500-10.
3. Birkedal-Hansen H, Moore WG, Bodden MK, Windsor LJ, Birkedal-Hansen B, DeCarlo A, Engler JA. Matrix metalloproteinases: a review. *Crit Rev Oral Biol Med*. 1993;4(2):197-250.
4. Birkedal-Hansen H. Role of matrix metalloproteinases in human periodontal diseases. *J Periodontol*. 1993 May;64(5 Suppl):474-84.
5. Chin JR, Murphy G, Werb Z. Stromelysin, a connective tissue-degrading metalloendopeptidase secreted by stimulated rabbit synovial fibroblasts in parallel with collagenase. Biosynthesis, isolation, characterization, and substrates. *J Biol Chem*. 1985 Oct 5;260(22):12367-76.
6. Clohisy JC, Connolly TJ, Bergman KD, Quinn CO, Partridge NC. Prostanoid-induced expression of matrix metalloproteinase-1 messenger ribonucleic acid in rat osteosarcoma cells. *Endocrinology*. 1994 Oct;135(4):1447-54.
7. Gangbar S, Overall CM, McCulloch CA, Sodek J. Identification of polymorphonuclear leukocyte collagenase and gelatinase activities in mouthrinse samples: correlation with periodontal disease activity in adult and juvenile periodontitis. *J Periodontol Res*. 1990 Sep;25(5):257-67.
8. Goldberg GI, Wilhelm SM, Kronberger A, Bauer EA, Grant GA, Eisen AZ. Human fibroblast collagenase. Complete primary structure and homology to an oncogene transformation-induced rat protein. *J Biol Chem*. 1986 May 15;261(14):6600.
9. Heikinheimo K, Salo T. Expression of basement membrane type IV collagen and type IV collagenases (MMP-2 and MMP-9) in human fetal teeth. *J Dent Res*. 1995 May;74(5):1226-34.
10. Herron GS, Banda MJ, Clark EJ, Gavrilovic J, Werb Z. Secretion of metalloproteinases by stimulated capillary endothelial cells. II. Expression of collagenase and stromelysin activities is regulated by endogenous inhibitors. *J Biol Chem*. 1986 Feb 25;261(6):2814-8.
11. Hong BK, Kwon HM, Lee BK, Kim D, Kim IJ, Kang

- SM, Jang Y, Cho SH, Kim HK, Jang BC, Cho SY, Kim HS, Kim MS, Kwon HC, Lee N. Coexpression of cyclooxygenase-2 and matrix metalloproteinases in human aortic atherosclerotic lesions. *Yonsei Med J*. 2000 Feb;41(1):82-8.
12. Ingman T, Sorsa T, Michaelis J, Konttinen YT. Immunohistochemical study of neutrophil- and fibroblast-type collagenases and stromelysin-1 in adult periodontitis. *Scand J Dent Res*. 1994 Dec;102(6):342-9.
 13. Kim JW and Lim SS: A study on the activity of proteinase and proteinase inhibitor in pulpal and periapical pathosis. *A thesis for doctorate*, 2000.
 14. Ko HJ and Lim SS: Tissue levels of IL-1 α , IL-1 β and TNF- α in pulpal and periapical pathosis. *J of Korean academy of Cons Dent*, 1997;23:316-3270.
 15. Kryshtalskiy E, Sodek J, Ferrier JM. Correlation of collagenolytic enzymes and inhibitors in gingival crevicular fluid with clinical and microscopic changes in experimental periodontitis in the dog. *Arch Oral Biol*. 1986;31(1):21-31.
 16. Larivee J, Sodek J, Ferrier JM. Collagenase and collagenase inhibitor activities in crevicular fluid of patients receiving treatment for localized juvenile periodontitis. *J Periodontal Res*. 1986 Nov;21(6):702-15.
 17. Lee SJ et al: A study of the expression of TGF- β and MMP-1 in periapical lesion. *J of Korean academy of Cons Dent*, 1999;24:1:200-211.
 18. Lichtinghagen R, Breitenstein K, Arndt B, Kuhbacher T, Boker KH. Comparison of matrix metalloproteinase expression in normal and cirrhotic human liver. *Virchows Arch*. 1998 Feb;432(2):153-8.
 19. Lindsey JD, Kashiwagi K, Boyle D, Kashiwagi F, Firestein GS, Weinreb RN. Prostaglandins increase proMMP-1 and proMMP-3 secretion by human ciliary smooth muscle cells. *Curr Eye Res*. 1996 Aug;15(8): 869-75.
 20. McCarthy JB, Wahl SM, Rees JC, Olsen CE, Sandberg L, Wahl LM. Mediation of macrophage collagenase production by 3'-5' cyclic adenosine monophosphate. *J Immunol*. 1980 May;124(5):2405-9.
 21. Meikle MC, Hembry RM, Holley J, Horton C, McFarlane CG, Reynolds JJ. Immunolocalization of matrix metalloproteinases and TIMP-1 (tissue inhibitor of metalloproteinases) in human gingival tissues from periodontitis patients. *J Periodontal Res*. 1994 Mar;29(2):118-26.
 22. Miyauchi M, Takata T, Ito H, Ogawa I, Kobayashi J, Nikai H, Ijuhin N. Immunohistochemical demonstration of prostaglandins E2, F2 α , and 6-keto-prostaglandin F1 α in rat dental pulp with experimentally induced inflammation. *J Endod*. 1996 Nov;22(11):600-2.
 23. Nakata K, yamasaki M, Iwata T, Suzuki K, Nakane A and Nakamura H. Anaerobic bacterial extracts influence production of matrix metalloproteinases and their inhibitors by humane dental pulp cells. *J Endodon* 2000;Jul: 26:7:410-13.
 24. Nigase H et al: Nomenclature and glossary of the matrix metalloproteinases In: H.Birkedal-Hansen et al: Matrix metalloproteinases and inhibitors. Stuttgart Gustav Fischer Verlag. 1992:421-424
 25. O' Boskey FJ Jr, Panagakos FS. Cytokines stimulate matrix metalloproteinase production by human pulp cells during long-term culture. *J Endod*. 1998 Jan;24(1):7-10.
 26. Overall CM, Wiebkin OW, Thonard JC. Demonstration of tissue collagenase activity in vivo and its relationship to inflammation severity in human gingiva. *J Periodontal Res*. 1987 Mar;22(2):81-8.
 27. Overall CM, Sodek J. Initial characterization of a neutral metalloproteinase, active on native 3/4 -collagen fragments, synthesized by ROS 17/2.8 osteoblastic cells, periodontal fibroblasts, and identified in gingival crevicular fluid. *J Dent Res*. 1987 Jul;66(7):1271-82.
 28. Palosaari H, Wahlgren J, Larmas M, Ronka H, Sorsa T, Salo T, Tjaderhane L. The expression of MMP-8 in human odontoblasts and dental pulp cells is down-regulated by TGF- β 1. *J Dent Res*. 2000 Jan;79(1):77-84.
 29. Panagakos FS, O' Boskey JF Jr, Rodriguez E. Regulation of pulp cell matrix metalloproteinase production by cytokines and lipopolysaccharides. *J Endod*. 1996 Jul;22(7):358-61.
 30. Reizo I et al: Dynamic aspects of dental pulp-molecular biology, pharmacology and pathophysiology. Published by Chapman and Hall, 1990.
 31. Salo T, Lyons JG, Rahemtulla F, Birkedal-Hansen H, Larjava H. Transforming growth factor- β 1 up-regulates type IV collagenase expression in cultured human keratinocytes. *J Biol Chem*. 1991 Jun 25;266(18):11436-41.
 32. Selzer S and Bender IB: The dental pulp. 3rd. ed., published by JB Lippincott Company.
 33. Son WJ, Baek SH and Lim SS: The concentrations of prostaglandin E2, 6-keto-prostaglandin F1 α and leukotriene B4 in pulpal and periapical lesions. *J of Korean Acad of Cons Dent*, 2000;25(2): 193-201.
 34. Tjaderhane L, Larjava H, Sorsa T, Uitto VJ, Larmas M, Salo T. The activation and function of host matrix metalloproteinases in dentin matrix breakdown in caries lesions. *J Dent Res*. 1998 Aug;77(8):1622-9.
 35. Villela B, Cogen RB, Bartolucci AA, Birkedal-Hansen H. Collagenolytic activity in crevicular fluid from patients with chronic adult periodontitis, localized juvenile periodontitis and gingivitis, and from healthy control subjects. *J Periodontal Res*. 1987 Sep;22(5): 381-9.
 36. Wahl LM, Lampel LL. Regulation of human peripheral blood monocyte collagenase by prostaglandins and anti-inflammatory drugs. *Cell Immunol*. 1987 Apr 1;105(2):411-22.
 37. Wahl LM, Olsen CE, Sandberg AL, Mergenhagen SE. Prostaglandin regulation of macrophage collagenase production. *Proc Natl Acad Sci* 1977 Nov;74(11):4955-8.
 38. Zahner G, Harendza S, Muller E, Wolf G, Thaiss F, Stahl RA. Prostaglandin E2 stimulates expression of matrix metalloproteinase 2 in cultured rat mesangial cells. *Kidney Int*. 1997 Apr;51(4):1116-23.