

Infantile Hemangiopericytoma (A Case Report)

Sang Hoon Han, Chul Gyoo Park and Je G. Chi*

Department of Plastic and Reconstructive Surgery and Department of Pathology
College of Medicine, Seoul National University, Seoul 110, Korea*

=Abstract=A case of cellular angioma of infancy occurring in a 2 year old girl is reported. This small tumor of the great toe was removed by a local wide excision. Histologically it was a typical example of cellular angioma of infancy and its ultrastructural characteristics are described.

Key words: *Infantile hemangiopericytoma, Cellular angimoa of infancy*

Hemangiopericytoma is a rather uncommon neoplasm that was first described and named by Stout and Murray in 1942. The tumor was characterized by a proliferation of capillaries surrounded by spindle-shaped or round cells, the pericytes.

In 1976, Enzinger separated congenital or infantile hemangiopericytoma from ordinary hemangiopericytoma as a definite entity having benign prognosis as well as distinct histology.

The diagnosis of hemangiopericytoma rests mainly on recognition of its architectural pattern. And in the absence of an ultrastructural study it is often difficult to distinguish this tumor from other richly vascular neoplasm such as glomus tumor, hemangioendothelioma, etc. An additional problem is the morphologic unpredictability of the biological behavior and the difficulty on a histological basis to separate the malignant from the benign variants.

This paper reports a case which had light microscopic and ultrastructural features of infantile hemangiopericytoma (cellular angioma of infancy), and the importance of accurate diagnosis, successful treatment, and necessity of long-term follow up are discussed.

CASE REPORTS

A 2-year-old Korean girl came to the clinic because of a nodule on the dorsum of the right great toe. The nodule was noticed since 1 week after birth and found to be enlarged more recently, along with nail dystrophy of the corresponding toe. It was single soft nodule in the subcutaneous tissue and was not fixed to the skin. There was no spon-

aneous pain or tenderness. Other physical examination was unremarkable except for the nail dystrophy. The biopsy taken at Dermatology Service showed cellular angioma of infancy. Later a wide excision including nail plate and nail bed was performed at Plastic Surgery Department and the raw surface was covered with local rotation flap (Fig. 1). The postoperative course was uneventful and she is free from the tumor at the time of this report, 6 months afterwards.

Histologically the tumor was composed of numerous small round or elongated vascular channels with flattened or plump endothelial cells that were surrounded by ovoid perithelial cells arranged concentrically around them. In areas, these ovoid pericytes became elongated or spindle shaped and grew in small cellular sheets (Fig. 2). The collagen fibers were widely scattered around the blood vessels and enveloped the tumor cells. There were no necrotic or hemorrhagic foci. Under the electron microscope the tumor consisted of both well-formed vascular structures and solid crests of cells. The plump endothelial cells showed large irregular nuclei and the cytoplasm contained poorly developed endoplasmic reticulum. The endothelial cells were separated by a basement membrane from the underlying pericytes. But no basement membrane was noted between individual endothelial cells. The endothelial cells also showed proliferation. The pericytes showed usually elongated irregular nuclei and their cytoplasm contained numerous mitochondria and endoplasmic reticulum. Numerous pinocytotic vesicles were noted (Fig. 3, 4, 5).

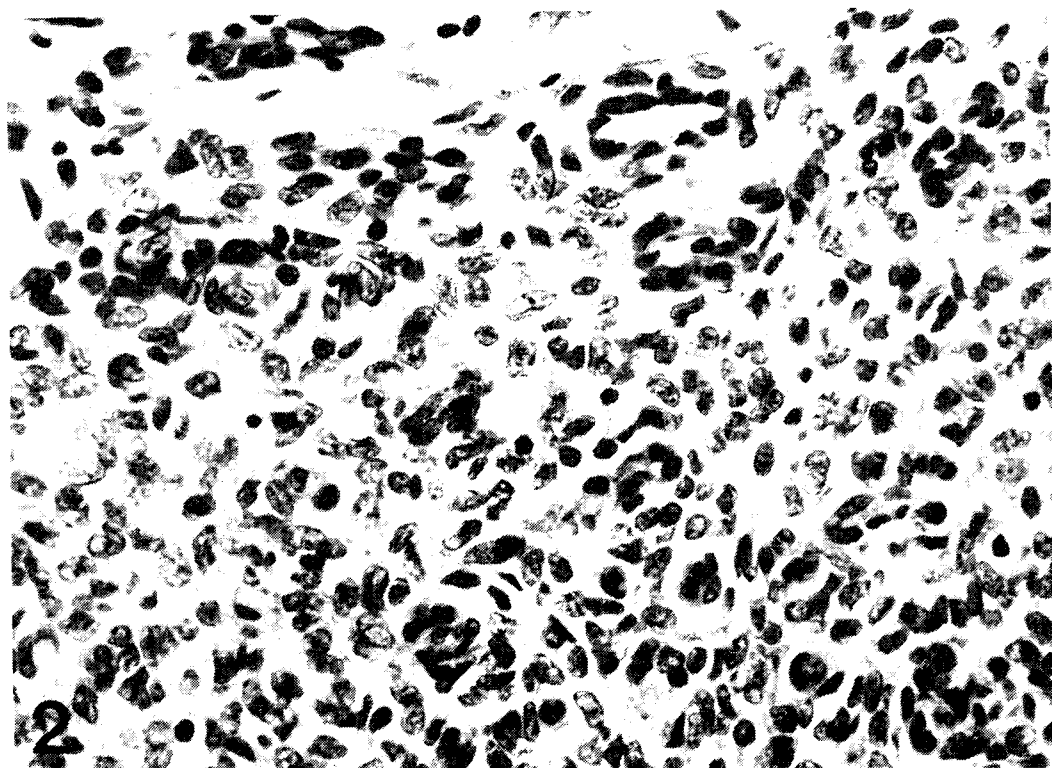
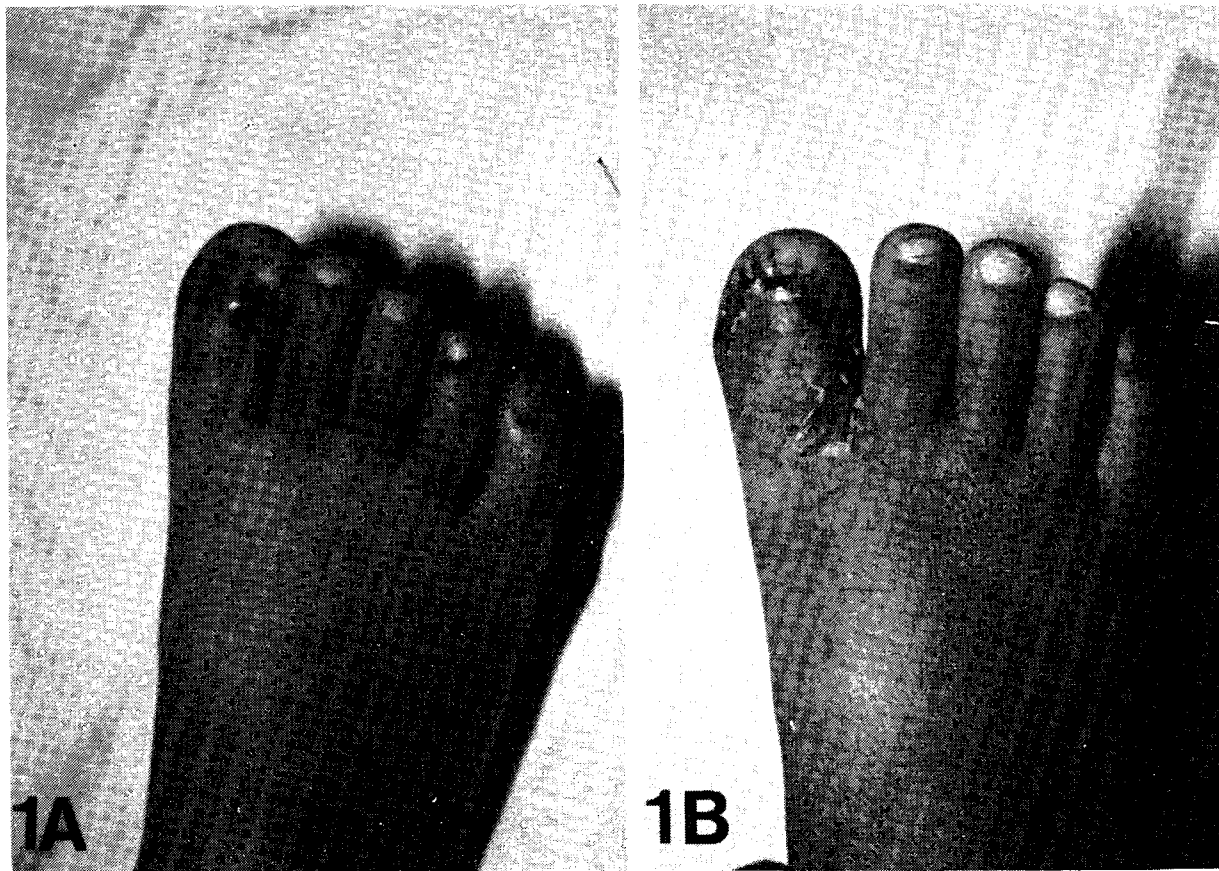


Fig. 1A. Gross appearance of the tumor. It looks like a vascular tumor. Nail dystrophy is seen.
Fig. 1B. 3 weeks after operation. The raw surface was well reconstructed using local rotation flap after tumor excision and the secondary donor defect was closed with split-thickness skin graft at the web space of the great toe.
Fig. 2. Photomicrograph of the tumor, showing small round capillaries and surrounding ovoid to fusiform tumor cells.
H & E \times 100

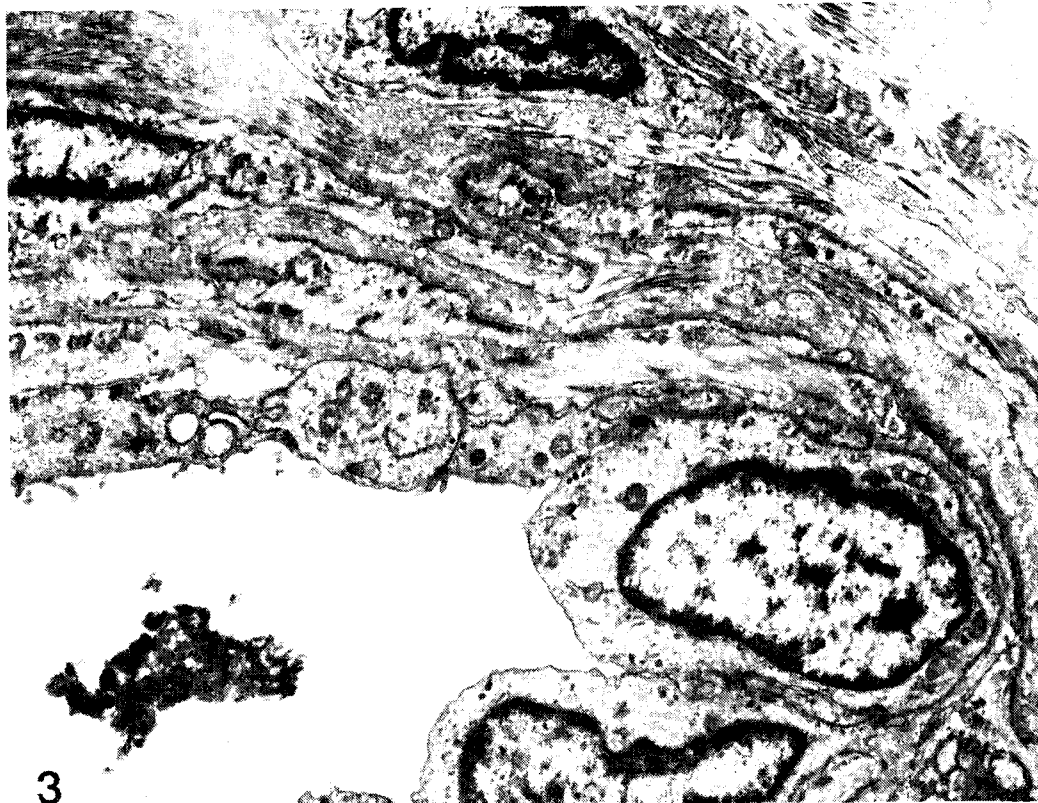


Fig. 3. Electron micrograph showing vessels and surrounding pericytes. Endothelial proliferation is noted ($\times 9,800$).

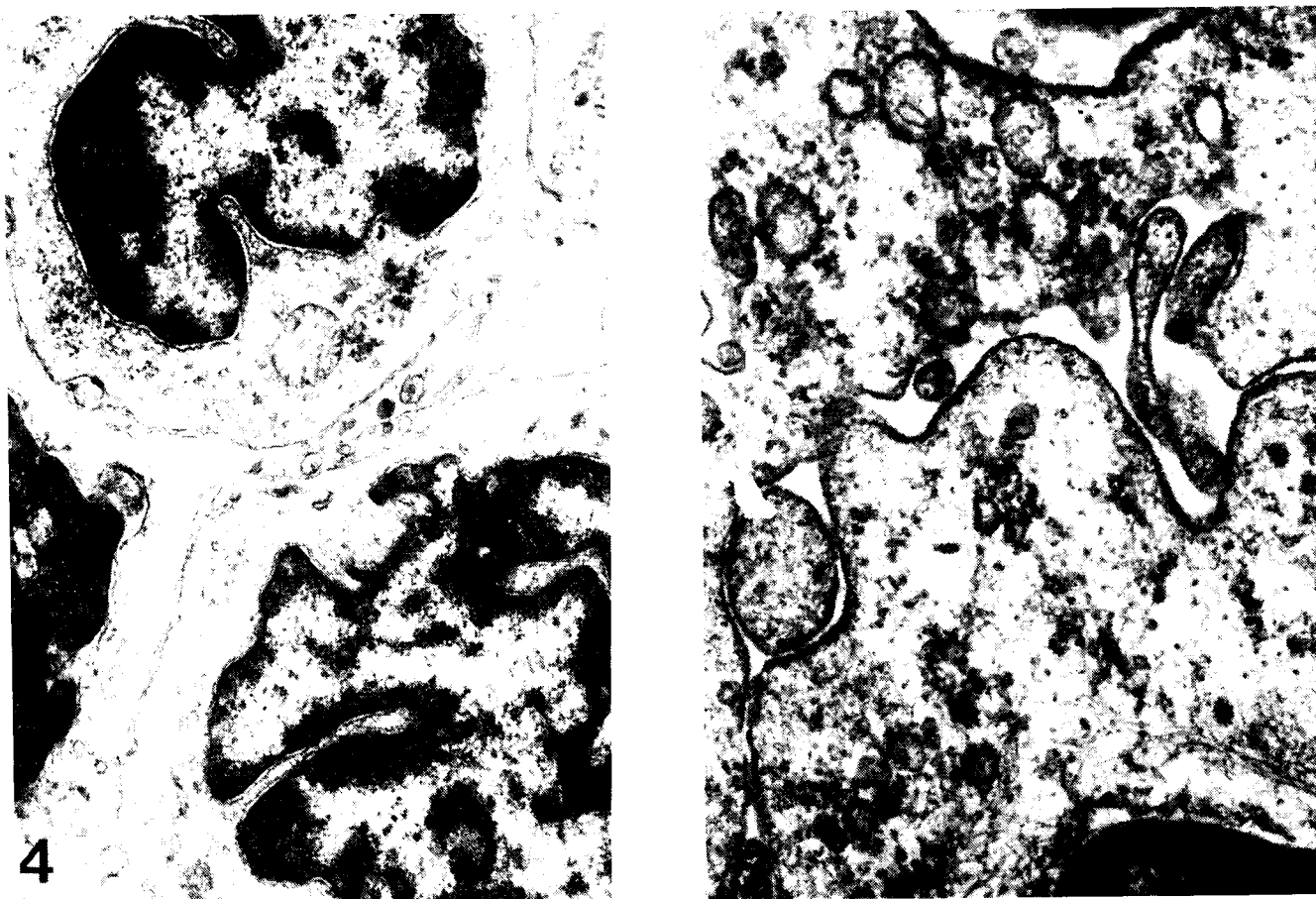


Fig. 4. Electron micrograph of tumor. Note wide separation of tumor cells showing irregular nuclear margin and sparse cytoplasmic organelles ($\times 14,400$)

Fig. 5. Electron micrograph showing numerous pinocytotic vesicles of the pericytes ($\times 45,000$)

DISCUSSION

A specific diagnosis of hemangiopericytoma is important because the tumor is sometimes aggressive and infiltrative. Hemangiopericytoma may be entirely self-limited and completely benign, may be locally invasive or may metastasize widely.

Enzinger and Smith (1976) delineated the infantile hemangiopericytoma clearly as a separate entity. In contrast to adult form of hemangiopericytoma these tumors are benign, occur mostly in the subcutis and are multilobulated (Eimoto 1977; Taxy and Gray 1979). Microscopically the tumor differed by frequent proliferation of endothelial cells and increased mitotic activity. Clinically the tumor occurred in both sexes with equal frequency. Most of the patients with this tumor complained of slowly enlarging painless mass. Tenderness and pain were infrequent but occurred only during movement of exercise. The tumor was most common in the lower extremities.

Characteristically under electron microscope the individual cells were separated from the adjacent endothelial cells by a distinct and sometimes multilayered basal lamina (Kuhn and Rosai 1969; Battifora 1973; Popoff *et al.* 1974). In 1960, Kauffman and Stout reviewed their experience with 31 tumors in children. They noted the presence of numerous mitotic figures, overt anaplasia of tumor cells, and a sparse reticulin network usually indicated a malignant clinical course. However the lack of these histological features, singularly or collectively, did not necessarily indicate a benign clinical course.

There is no success in the treatment of recurrent and metastatic lesion by means of radiotherapy or chemotherapy such as actinomycin D, cyclophosphamide and vincristine (McMaster *et al.* 1975; Ortega *et al.* 1971; Wong and Yagoda 1978). So borderline and malignant hemangiopericytoma should be treated by wide local excision through normal tissue content at the first time of treatment (Kauffman and Stout 1960; Gerner *et al.* 1974; McMaster *et al.* 1975).

Another feature of hemangiopericytoma is the necessity of long term follow up before one can be certain about its biological behavior because local recurrence or metastasis may occur longer than 5 years after successful treatment (Kauffman and Stout 1960; O'Brien and Braffield 1965; McMaster

et al. 1975). The case reported here is corresponding to benign hemangiopericytoma and fulfills the criteria of Enzinger (1976) although multilobulation was not evident in our case. The tumor was treated by complete surgical excision and we believe this patient is cured by this measure. However, long-term follow up will be made mainly because of the unpredictability of the biological behavior with its morphology.

REFERENCES

- Battifora H. Hemangiopericytoma; ultrastructural study of five cases. *Cancer* 1973, 31: 1414-1432
- Eimoto T. Ultrastructure of an infantile hemangiopericytoma. *Cancer* 1977, 40: 2161-2170
- Enzinger FM, Smith BH. Hemangiopericytoma, an analysis of 106 cases. *Human pathology* 1976, 7:61-82
- Fu YS, Perzin KH. Non-epithelial tumors of the nasal cavity, paranasal sinuses, and nasopharynx; a clinicopathologic study. *Cancer* 1974, 33: 1275-1288
- Gerner RE, Morre GE, Pickren JW. Hemangiopericytoma. *Ann. Surg.* 1974, 179: 128-132
- Hahn MJ, Dawson R, Esterly JA, Joseph DJ. Hemangiopericytoma. An ultrastructural study. *Cancer* 1973, 31: 255-261
- Kauffman SL, Stout AP. Hemangiopericytoma in children. *Cancer* 1960, 13:695-710
- Kuhn III C, Rosai J. Tumors arising from pericytes. *Arch. Path.* 1969, 88: 653-663
- McMaster MJ, Soule EH, Ivins JC. Hemangiopericytoma. *Cancer* 1975, 36: 2232-2244
- Nunnery EN, Hahn LB, Reddick RL, Lipper S. Hemangiopericytoma; A light microscopic and ultrastructural study. *Cancer* 1981, 47: 906-914
- O'Brien P, Brasfield RD. Hemangiopericytoma. *Cancer* 1965, 18: 249-252
- Ortega JA, Finklestein JZ, Issacs H, Hittle R, Hasting N. Chemotherapy of malignant hemangiopericytoma of childhood. *Cancer* 1971, 27: 730-735
- Popoff NA, Malinin TI, Rosomoff HL. Fine structure of intracranial hemangiopericytoma and angiomatous meningioma. *Cancer* 1974, 34:1187-1197
- Ramsey HJ. Fine structure of hemangiopericytoma and hemangioendothelioma. *Cancer* 1966, 20:205-218
- Silverberg SG, Willson MA, Board JA. Hemangiopericytoma of uterus; an ultrastructural study. *Amer. J. Obstet. Gynec.* 1971, 110: 397-404
- Stout AP, Murray MR. Hemangiopericytoma. *Ann. Surg.* 1942, 116: 26-33
- Taxy JB, Gray SR. Cellular angiomas of infancy. *Cancer* 1979, 43: 2322-2331
- Wong PP, Yagoda A. Chemotherapy of malignant hemangiopericytoma. *Cancer* 1978, 41: 1256-1260

= 국문초록 =

유아성 혈관 외피 세포종

서울대학교 의과대학 성형외과학교실 및 병리학교실*

한상훈 · 박철규 · 지제근*

유아성 혈관 외피 세포종은 매우 드문 종양으로 조직학적으로 모세혈관의 증식과 그 주위에 밀집되어 있는 종양세포로 구성된다. 전자현미경 소견으로는 내피세포로 이장된혈관 주위에 구형 혹은 타원형의 종양세포가 있으며 이 종양세포와 내피세포 사이에는 특징적으로 기저막이 단층 혹은 여러층으로 존재하고 종양세포는 세포질 돌기를 길게 내어 서로 감싸고 있다. 저자들은 2세 여아의 우측 제1족지 배부에 발생한 유아성 혈관 외피종을 광범위 국소절제술로 치험한 예를 보고하고 본 종양의 임상적 특수성, 진단 및 치료에 관계된 중요성에 대하여 언급하였다.