

Congenital Biliary Atresia A Histological Analysis of 40 Operated Cases[†]

Je G. Chi*, Chul Woo Kim*, Woo Ki Kim** and Kwi Won Park**

Departments of Pathology and Pediatric Surgery,** Seoul National University Children's Hospital and
Departments of Pathology and Surgery, College of Medicine, Seoul National University, Seoul 110, Korea*

=Abstract= Based on 40 cases of biliary atresia that were operated for portoenterostomy histopathological analysis was carried out with special reference on liver changes. Seven cases of neonatal hepatitis and 6 cases of choledochal cyst were included in the materials to elucidate the differentiating characteristics among them.

The liver in biliary atresia showed a wide range of pathological features from minimal triaditis to advanced cirrhosis. To quantitate the degree of progressive widening of portal tracts, bile duct proliferation index was calculated to show a significant difference among cases of biliary atresia, neonatal hepatitis and choledochal cyst.

Histopathological changes of extrahepatic biliary tree in biliary atresia were characterized by fibrosing inflammation with productive fibrosis involving entire biliary system. The findings were more pronounced in proximal portion than in distal portion, thus suggesting inflammation-fibrosis sequence in a proximal-to-distal direction.

The patient age at the time of operation and the size of bile duct in proximal most portion of hepatic duct appeared to be two most important factors in determining the long term survival after operation. Bile ducts larger than 200 μ m in diameter seemed to be an important indicator for better prognosis. Hepatitis B seropositivity was present in 9 of 19 cases of biliary atresia that were examined. However, none of the livers that were stained with anti-HBsAg and anti-HBcAg was positive in immunohistochemical stains.

Key words: *Biliary atresia, Neonatal hepatitis, Choledochal cyst, Congenital atresia*

INTRODUCTION

Although there is no conclusive result available at present it appears to be generally accepted that the great majority of so-called "congenital" biliary atresia is not the real congenital malformation but is a progressive obstructive cholangiopathy (Landring 1974; Anderson 1978; Hays and Kimura 1981)

One of the histologic characteristics that has been consistently observed in biliary atresia in the liver was the giant cell transformation of the liver

cells. This phenomenon together with active inflammatory infiltrate was often seen in neonatal (giant cell) hepatitis as well (Dehner 1975). Accordingly the differential diagnosis between biliary atresia and neonatal hepatitis became important not only on clinical grounds but also from pathological standpoint.

Detailed histopathological studies on biliary atresia have been performed by Japanese workers (Kasai 1975; Kasai *et al.* 1962) and many new facets were uncovered. However, the issue of the inter-relationship between biliary atresia and neonatal hepatitis has not been settled yet. Despite the close similarities between these two diseases it is generally agreed they are separate disease entities, the single most important differentiating point being the presence or absence of extrahepatic bile duct

[†] This work is supported in part by China Medical Board research grant and Seoul National University Hospital research grant (1985).
Author for correspondence: Je G. Chi

obstruction.

This study was undertaken to elucidate the factors that are important for the differential diagnosis between these conditions and to find histopathological clues for the prognostication of biliary atresia.

MATERIALS AND METHODS

This study is based on operative specimens of 40 cases of biliary atresia, 6 cases of choledochal cyst and 7 cases of neonatal hepatitis. These cases were collected during a period of 7 years, from January 1978 to December 1984, at the Department of Pathology of the Seoul National University Hospital. Forty cases of biliary atresia had been operated for Kasai procedure of hepatic portoenterosotomy by Dr. Woo Ki Kim and his associates at the Pediatric Surgery Division of the Seoul National University Hospital. In these cases liver wedge biopsies and entirely removed extrahepatic biliary tree were available for study.

The biliary trees including the gallbladder was step-sectioned and labeled (Fig. 1). Seven cases of neonatal hepatitis consisted of two autopsies and five liver wedges. Six cases of choledochal cyst were included to compare the liver changes with those of biliary atresia. Routine histological preparations were made and stained with hematoxylin & eosin, reticulin and Masson's trichrome stains.

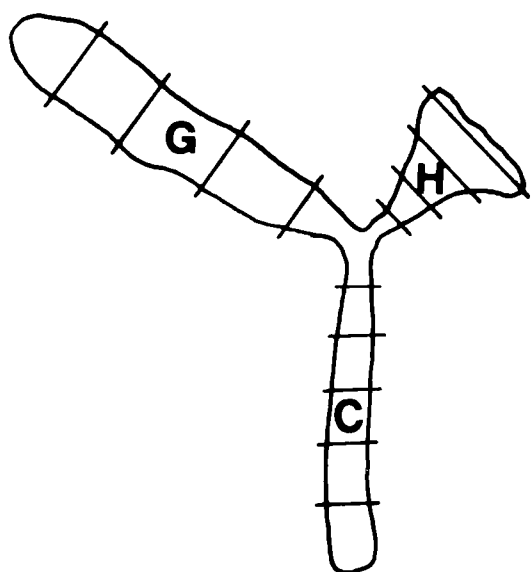


Fig. 1. A Schematic drawing of extrahepatic biliary system for histological study. G: Gallbladder, H: Hepatic duct, C: Common bile duct.

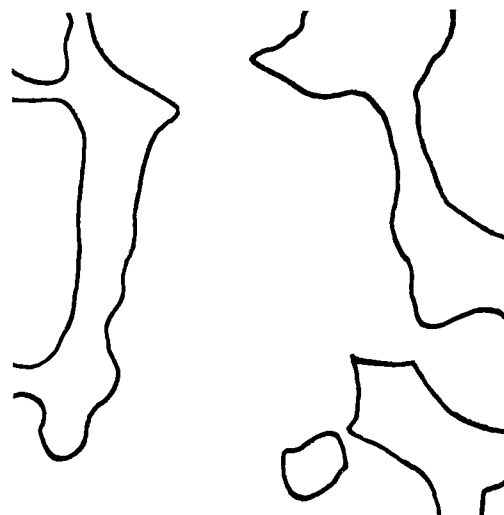


Fig. 2. Drawing of outlines of portal tracts in the liver of a case of biliary atresia (x40).

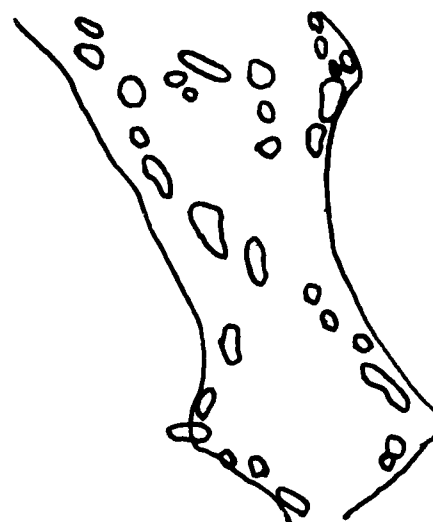


Fig. 3. Drawing of bile duct structures within a portal tract in a higher magnification of Figure 2 (x100).

For the quantitation of the degree of bile duct proliferation, outlines of portal tract and bile ducts in the livers are traced using drawing attachment (American Optical) (Figs. 2 and 3). Total areas of portal tracts and bile ducts in each case were calculated, and the ratio of bile duct area against whole liver area with multiplication 10,000 are expressed as bile duct proliferate index (BDPI).

Immunohistochemical study for HBsAg and HBcAg on the liver sections were done with peroxidase-antiperoxidase technique using Dako kit.

For the evaluation of prognosis we divided the whole patients into good and bad groups. The cases that survived more than one year after opera-

Table 1. Summary of clinical data and histology in biliary atresia

Age at operation	Fibrotic remnant in porta hepatis		Prognosis			Giant cells in liver (%)
			Fair	Poor	Unknown	
<2 months (n=8)	I*	4	4			6(75)
	II	4	2	2		
2 to 3 months (n=17)	I	11	4	4	3	15(88)
	II	6	5		1	
>3 months (n=15)	I	11	1	7	3	10(67)
	II	4	1	2	1	
Total(40)			17	15	8	31(78)

* I: bile duct diameter less than 200 μ m
II: bile duct diameter more than 200 μ m

tion were grouped as “fair” and the cases who died less than a year after operation were grouped as “poor”.

RESULTS

1. Livers of biliary atresia in different age group

In the group of patients whose ages were less than 2 months at the time of operation the pathologic findings were confined to the hepatic lobules. They showed giant cell formation and hepatocellular degeneration of moderate severity and a mild degree of bile duct proliferation and fibrosis together with a few mononuclear cell infiltration in portal spaces. Cholestasis was often seen in the bile canaliculi as flocculent brown green material. Feathery degeneration with bile pigmentation was also seen in the hepatocytes (Plate 1). Extramedullary erythropoiesis was occasionally seen in several cases.

In 15 of 17 cases, giant cell formation was noted in the patients whose ages ranged from 2 months to 3 months, although the severity was less marked. Hepatocellular ballooning and feathery degeneration were seen more diffusely. Moderate degree of bile duct proliferation, fibrosis, and bile pluggings were observed in portal spaces (Plate 2-4).

In the group of patient whose ages were older than 3 months at the time of biopsy, giant cells were observed in 10 of 15 cases. The nuclei of these giant cells were counted up to 30 per cell. Most cases of this group showed changes of early biliary cirrhosis. Diffuse fibrosis with portal to portal bridging and pronounced bile ductular proliferation in portal spaces were present (Plate 5).

Repeat biopsies were available in 3 cases of the second group. The biopsies were done about 2 weeks after the first operation. The hepatic pathology was progressed in all cases compared to the first biopsy, and the findings were comparable to those seen in the corresponding age group. One repeat biopsy done about 4 years later, showed peculiar inactive cirrhotic lesion with many dilated lymphatic channels instead of proliferated bile ducts in portal spaces (Plate 6).

2. Pathology of extrahepatic bile duct

The histological features of the extrahepatic biliary system in biliary atresia were characterized by fibrosing cholangitis. Inflammatory exudate and productive fibrosis were seen in every single case of biliary atresia (Plate 7, 8). The degree of atresia could not be correlated to the age of the patients. The sections from the proximal most portion of porta hepatis from the removed biliary tree showed multiple small bile ducts ranging in number from two to ten, that were embedded in the proliferating fibrous mass. The superimposed inflammatory exudate was composed of small round cells and large mononuclears with some degree of edema and fibrous tissue in the wall, and the lining epithelium was a tall columnar epithelium. Some degree of smooth muscle hypoplasia and mild small round cell infiltration in the wall of the gallbladder were present. Comparable reaction in the hepatic duct was not encountered.

3. Neonatal hepatitis

Ages were distributed from 70 days to 6 months in 7 cases of neonatal hepatitis. There were 4 males and 3 females. In 3 cases, jaundice and clay-colored stool were present from birth, and in another 4 cases, symptoms started between 2

weeks and one month of age. Transplacental viral hepatitis was suspected in two cases, because both the patients and their mothers showed seropositivity for hepatitis B virus. One of 2 cases revealed pathologic findings of submassive hepatic necrosis. The remaining 6 cases showed basically the same histological findings regardless of age at operation. All of them showed hepatocellular degeneration, giant cell transformation, and a diffuse cholestasis in the parenchyme. Also noted were inflammatory cell infiltration, mainly lymphocytes and eosinophils, of more than moderate degree in portal spaces. Bile duct proliferation however was remarkably minimal or none (Plate 9, 10).

4. Choledochal cyst

Six cases of choledochal cyst ranged in age from 1 1/2 year to 10 years. Male-female ratio was 1 : 1. The histological changes of the liver appeared to be correlated with size of the cyst. In general histopathological abnormalities were more pronounced in patients who had larger size of the choledochal cyst. The morphology of the liver varied from normal range to overt cirrhosis. This finding was correlated with the degree of biliary obstruction and also duration of illness. Giant cell formation was not evident in any of these cases. In 3 cases, moderate degree of fibrosis and bile duct proliferation were observed in portal spaces (Plate 11). Choledochal cysts were composed of thick irregular wall organized by collagen bundles. In most cases no recognizable epithelial lining was seen. However, smooth muscle bundles were often detected in the wall. The inner surface of them was usually lined by fibrin clot, but foci of cuboidal shaped epithelial cells were noted in a few young patients.

5. Morphometric analysis of degree of bile duct proliferation

There was a significant difference among different group. The index was less than 50 in cases of neonatal hepatitis, while the number was at least 100 in biliary atresia and choledochal cyst. This BDP index progressively increased as the patients age increased from 129.3 for those less than 2 months of age to 297.1 for those more than 3 months of age. Choledochal cyst showed 192.0 in average.

Among the groups in biliary atresia the BDP index value was tested by Kruskal-Wallis test and the differences were statistically significant ($X^2=7.46$, d.f=2, $p<0.05$). Wilcoxon rank sum tests were utilized for the comparison between neonatal hepa-

Table 2. Bile Duct Proliferation(BDP) index in biliary atresia, neonatal hepatitis and choledochal cyst

Disease	BDP index
1. Biliary atresia	
a. <2 months (n=8)	129.3
b. 2 to 3 months (n=13)	197.3
c. >3 months (n=10)	297.1
2. Neonatal hepatitis (n=6)	14.6
3. Choledochal cyst (n=6)	192.0

BDP index: Bile Duct Proliferation index=

$$\frac{\text{Total area of bile duct in portal tract}}{\text{Total area (of liver)}} \times 10,000$$

titis and biliary atresia less than 2 months of age and between choledochal cyst and biliary atresia more than 3 months of age. The tests showed significant difference between neonatal hepatitis and biliary atresia less than 2 months of age ($p<0.05$). But there was no significant difference between choledochal cyst and biliary atresia of more than 3 months of age.

6. Immunohistochemical study for HBsAg and HBcAg

Nine cases of biliary atresia, showed seropositivity for hepatitis B virus. The specimens of liver and atretic hepatic duct of these 9 patients were stained with peroxidase-antiperoxidase method against hepatitis B surface antigen and hepatitis B core antigen. None of these cases showed positive cells either in the liver or in the hepatic duct.

A total of 19 cases of biliary atresia was checked for hepatitis B seropositivity. Among these, 9 were positive for HBsAg and/or HBcAg. Eight of 9 cases were in the fair group, and 1 was in poor group. One case that showed positivity against hepatitis A was in poor group. 10 cases of seronegative patients were divided into fair and poor groups in equal number.

DISCUSSION

This study uncovers a few facts that are important in prognosis for patients with biliary atresia. The age at operation and the size of bile ducts in

atretic extrahepatic bile ducts particularly at the level of portoenterostomy appear to be two most critical determinants of long survival. We found the duct measuring larger than 200 μm in diameter tended to be continuous all the way down to papilla, while smaller ones are discontinuous at different levels. Therefore one would recommend measuring the diameter of the largest bile duct in the specimen from proximal most portion for the prognosis. For long term survivors, ascending cholangitis might be another factor affecting prognosis (Hays and Kimura 1981).

In evaluating prognosis of the patients in this series, we set the criterion of favorable group for those who survived more than one year after portoenterostomy. This is based on the fact that most patients in uncorrected state survive for approximately 16 months after the diagnosis (Hays and Kimura 1981). And most cases of favorable group in this study showed immediate clinical improvement after operation.

It was interesting to note the bile duct proliferation index of the liver is very much comparable between biliary atresia and choledochal cyst. Although features of parenchymal damage were slightly more prominent in biliary atresia, these two conditions might share common pathogenesis at least in some aspects.

Giant cells seen in the liver of patients with biliary atresia were indistinguishable from those seen in neonatal hepatitis, and were seen in 32 out of 40 cases of biliary atresia. However, distortion of hepatic cell plates, variation in size and shape of hepatocytes, as well as ballooning or granular degeneration of liver cells were fairly characteristic in neonatal hepatitis. Besides, progressive fibrosis, bile duct proliferation and bile plugging were seldom seen in neonatal hepatitis while occurring commonly in biliary atresia. It was our impression that livers in biliary atresia and neonatal hepatitis could be distinguished in most cases, except for occasional cases less than 50 days of age. However, if one utilizes the bile duct proliferation index even these cases could be distinguished easily. Therefore we feel that in those difficult cases calculation of the index will be valuable. If the index turns out to be above 100 one should diagnose biliary atresia rather than neonatal hepatitis.

The pathological features of the extrahepatic biliary system in biliary atresia could best be characterized by fibrosing cholangitis. Inflammatory exudate and productive fibrosis were seen in every case of

biliary atresia. The degree of atresia could not be correlated to the age of the patients. The sections from the proximal most portion of porta hepatis showed multiple small bile ducts ranging in number from two to ten, embedded in proliferating fibrous mass. The superimposed inflammatory exudate was composed of small round cells and large mononuclears with some degree of edema. When comparing fibrosis of hepatic duct from most proximal portion to the liver bed with more distal portion, the former was definitely more fibrotic than the latter, therefore suggesting that the transformation of inflammation-fibrosis sequence was gradually extended from proximal to distal portion of biliary system as advocated by Bill *et al.* (1974) and Gautier and Eliot (1981).

There was no difference in liver changes between seropositive and seronegative patients against hepatitis virus B. and it appears that liver lesions in biliary atresia are not directly related to the hepatitis B virus infections based on immunohistochemistry. And HB seropositivity of the patients with biliary atresia did not appear to be related to poor prognosis.

ACKNOWLEDGEMENT

Authors would like to thank Dr. Joon Park and Dr. Seong Chul Lee who helped us for this study. We also thank Miss Kyung Sook Choi for the typographic assistance.

REFERENCES

- Anderson KD. Biliary atresia. Clinics in Perinatology. 1978, 5:19-28
- Bill AH, Haas JE, Foster GL. Biliary atresia: Histopathologic observations and reflections upon its natural history. J. Pediatr. Surg. 1977, 12:977-982
- Dehner LP. Pediatric surgical pathology. The C. V. Mosby Company, Saint Louis, 1975, 340-345
- Gautier M, Eliot N. Extrahepatic biliary atresia. Arch. Pathol. Lab. Med. 1981, 105:397-402
- Hays DM, Kimura K. Biliary atresia: New concepts of management. Current problems in Surgery. Year Book Medical Publishers Inc. Chicago London, 1981, 18:543-607
- Kasai M, Yakovac MC, Koop CE. Liver in congenital biliary atresia and neonatal hepatitis. Arch. Pathol. 1962, 74:152-158
- Kasai M. Treatment of biliary atresia with special reference to hepatic portoenterostomy and its modifications. Prog. Pediatr. Surg. 1975, 6:2-52
- Landing BH. Considerations of the pathogenesis of neonatal hepatitis, biliary atresia and choledochal cyst: The concept of infantile obstructive cholangiopathy.

=국문초록=

선천성 간외담관폐쇄의 병리조직학적 관찰

서울대학교 의과대학 병리학교실 및 외과학교실*

지제근 · 김철우 · 김우기* · 박귀원*

선천성 간외담관폐쇄로 수술한 40예의 간생검과 담관을 병리조직학적으로 검색하였다. 한편 간외담관폐쇄의 간변화가 신생아간염 및 담관낭의 간변화와 어떻게 차이가 있는지를 알아보기 위하여 신생아간염 7예와 담관낭 6예를 아울러 관찰하였다.

간외담관폐쇄의 간 소견은 다양하였고 이는 수술시 환자의 나이와 밀접한 관계가 있었다. 즉 2개월 이하의 나이에서는 신생아간염과의 감별이 어려울 만큼 거대세포형성, 염증세포 침윤, 담즙울체등이 나타났으나 문맥강의 담관증식계수를 내어보면 쉽게 구별되었다. 문맥강 섬유화 및 담관증식은 환자의 연령의 증가에 따라 점진적으로 심하여져서 3개월을 고비로 상당히 심하여 담성경화증의 소견을 나타내기 시작하였다.

수술후 환자의 좋은 예후에 중요한 인자는 간의 조직학적 소견 즉 환자의 나이가 3개월 이전에 하는것과 수술시 담관 특히 문맥장관 문합술 부위 (최근위부)에서의 담관의 크기가 $200\mu\text{m}$ 이상이라는 점이라고 생각되었다. 40례의 간외담관폐쇄 환자중 9례가 B바이러스 간염혈청 양성이었는데 이들 증례의 간 및 담관 조직의 면역 조직화학적 검사를 HBsAg와 HBcAg에 대하여 시행한 결과 모두 음성이었다.

LEGENDS FOR PLATES

- Plate 1.** Liver of biliary atresia, less than 2 months, showing active giant cell transformation and feathery degeneration. (x200, HE)
- Plate 2.** Portal space in the liver of biliary atresia, between 2 to 3 months of age, showing fibrosis and bile duct proliferation. (x100, HE)
- Plate 3.** Portal space of the liver in biliary atresia, between 2 to 3 months of age, showing a moderate degree of bile duct proliferation and heavy infiltration of small round cells. (x100, HE)
- Plate 4.** Portal space in the liver of biliary atresia of a patient of 2 1/2 months of age, showing a marked proliferation of bile ducts especially along the limiting plate. (x100, HE)
- Plate 5.** Liver of biliary atresia, over 3 months of age, showing secondary biliary cirrhosis with complete septal fibrosis. (x40, HE)
- Plate 6.** Liver of a case of biliary cirrhosis, biopsied 4 years after the initial surgery, showing a marked proliferation of lymphatics. Note sparsity of bile ducts in the portal space. (x100, HE).
- Plate 7.** Hepatic duct remnant in biliary atresia, showing active inflammatory process around the degenerative bile ductules. (x100, HE)
- Plate 8.** Hepatic duct remnant in a case of biliary atresia, showing active fibrosis and forked tubules. (arrow indicates 100 μ m). (x40, HE)
- Plate 9.** Liver of neonatal hepatitis, showing diffuse giant cell transformation of the hepatocytes and inflammatory cell infiltration in the portal spaces. (x100, HE)
- Plate 10.** Liver of neonatal hepatitis, showing piecemeal necrosis, hepatocellular degeneration and giant cell formation along with portal inflammation. (x100, HE).
- Plate 11.** Liver of choledochal cyst, showing widened portal tracts due to inflammatory cell infiltrates together with a mild bile duct proliferation. Parenchymal change is minimal. (X100, HE)

