

Vascular Ring: Report of an Autopsy Case

Chong Jai Kim, Jeong Wook Seo, Je G. Chi, Keun Hee Chung* and Jin Keun Chang*

*Department of Pathology, Seoul National University Children's Hospital and College of Medicine, Seoul National University, Seoul 110-744, Korea and *Department of Pediatrics, Hanil General Hospital*

= Abstract = Authors describe an autopsy case of a 1 month old female infant with symptomatic vascular ring of the aortic arch. The vascular ring was formed by the right aortic arch and left-sided ductus arteriosus connected to the distal part of left aortic arch. Proximal part of aortic arch was not recognizable. Major branches of the arch were, from before backward, the left common carotid artery, the right common carotid artery, the right subclavian artery, and the left subclavian artery arising from a diverticulum of the aorta into which the left ductus inserted. The intracardiac anomalies of ventricular septal defect and persistent foramen ovale were present. The patient suffered from dyspnea, cough, cyanosis on crying and signs of pneumonia, and they could be explained partly by the tracheoesophageal compression of the vascular ring.

Key words: *Aortic arch anomaly, Vascular ring, Aspiration pneumonia*

INTRODUCTION

Anomalies of the aortic arch complex form a diverse group in their anatomic and clinical manifestations. Major problems related to these malformations are the anatomic types, compression of trachea and esophagus, and associated cardiac anomalies. The morphologic types and classifications are based on the hypothetical double aortic arch proposed by Edwards (1974). By the morphologic types of the malformed aortic arch system, trachea and esophagus can be compressed and clinical syndrome of "vascular ring" is built up.

There have been reports of various types of associated cardiovascular or visceral deformities (Chi *et al.* 1965; Berman *et al.* 1977; Binet *et al.* 1981; Whitman *et al.* 1982; Pirtle *et al.* 1983; Minami *et al.* 1986; Blatchford *et al.* 1987). The associated anomalies are also related to the morphologic types.

We recently experienced an autopsy case of a 1 month old infant who died with mild signs of

pneumonia. The aortic arch anomaly of the infant was not suspected during premortem period. The major anomaly was a vascular ring, and its retroesophageal segment strongly suggested the symptomatogenic nature of the condition.

CASE REPORT

Clinical findings:

This 43 days old female infant presented with coughing and failure to thrive of 15 days duration. She was born by spontaneous vaginal delivery at the gestational period of 41 weeks. Her birth weight was 3.0 kg and there was no specific perinatal problem. Since 15 days prior to the hospital visit, she had suffered from failure to thrive, dyspnea, cyanosis on crying and cough. She visited a local clinic and was managed conservatively without symptomatic improvement. She was referred to Hanil General Hospital for the further treatment and was admitted to Pediatric ward. Family and past medical histories were unremarkable except maternal history of unidentified drug ingestion during the first trimester of this pregnancy. Her body measurements were below 3rd percentile (Body weight; 3.11 kg, height; 49.2 cm, head circumference;

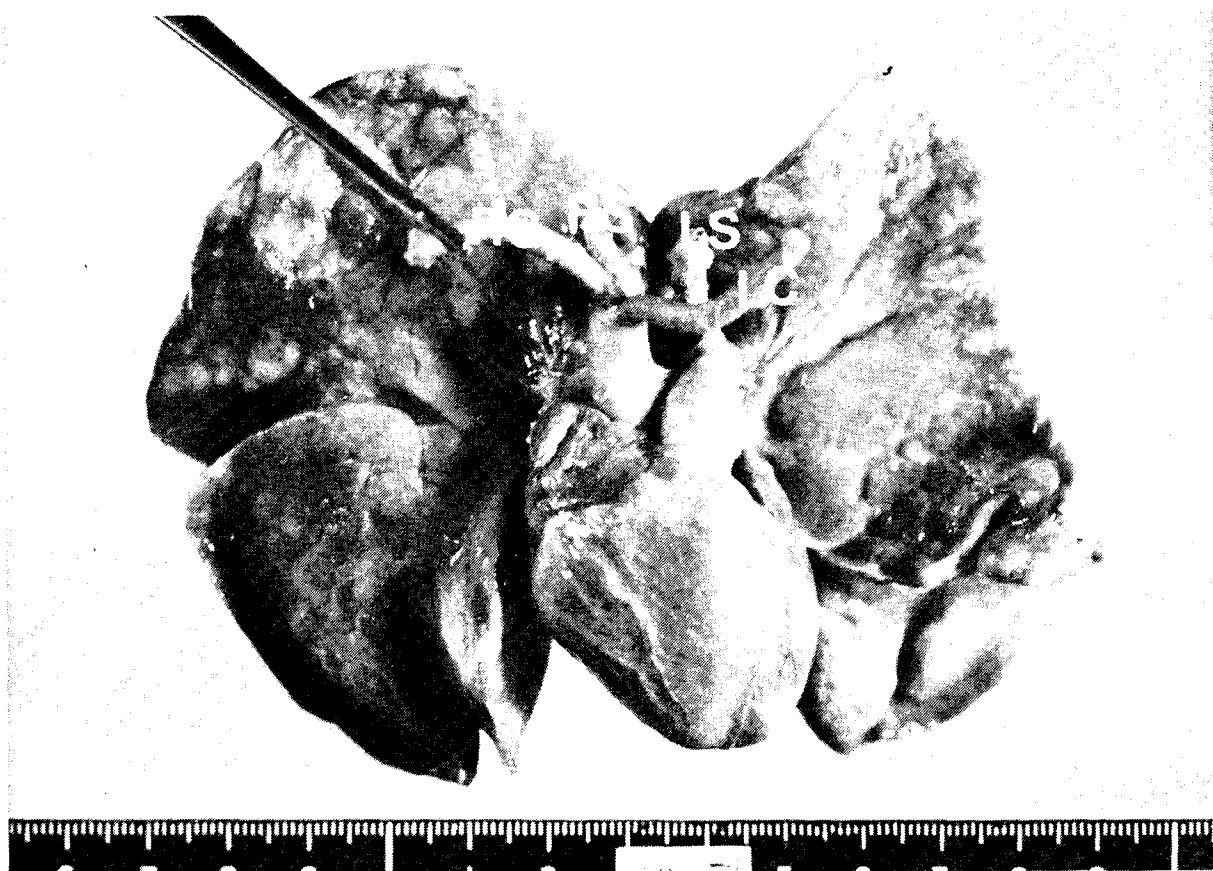


Fig. 1. The anterior view of the cardiopulmonary system. The lungs show patchy dusky discoloration due to aspiration pneumonia.

34.4 cm, chest circumference; 30.4 cm). On physical examination, cyanosis on crying, incomplete cleft palate, grade II systolic murmur along the left lower sternal border, and crackles on bilateral lung fields were found. The liver margin was palpated at 3.5 cm below the right costal margin. Vital signs were relatively stable except mild and persistent tachycardia. The laboratory findings were unremarkable. Chest X-ray revealed hyperinflation of the lungs and ventricular and atrial septal defects were found on echocardiography. EKG findings were those of right ventricular hypertrophy.

She persistently suffered from cough and cyanosis on crying, and under the clinical impression of congestive heart failure, digitalization was started. There was symptomatic relief during two days but the clinical course suddenly deteriorated and she died without specific causative episode. The result of chromosomal analysis was 46, XX pattern.

Pathologic findings:

Postmortem examination revealed retroesophageal left descending aorta causing compress-

ion of midesophagus. Ascending aorta was connected to left-sided descending aorta through right aortic arch. To the left descending aorta, left ductus arteriosus was connected. The vascular ring was formed by ascending aorta, right aortic arch, left descending aorta, left ductus arteriosus, and main pulmonary artery, from right to the left. The branches of vascular ring were, from before backward, the left common carotid artery, the right common carotid artery, the right subclavian artery, and the left subclavian artery arising from a diverticulum of the aorta into which the left ductus inserted (Fig. 1, 2). The left ductus was patent on probing but functional closure was demonstrated on silicate casting. On opening the heart, perimembranous ventricular septal defect, measuring 0.8 cm in diameter, was present and foramen ovale was patent. The lungs were slightly consolidated and showed patchy, dusky red discoloration. The microscopic examination of the lungs showed features of bronchopneumonia associated with evidence of aspiration such as intraalveolar squames and unidentified, refractile ovoid foreign bodies. Other

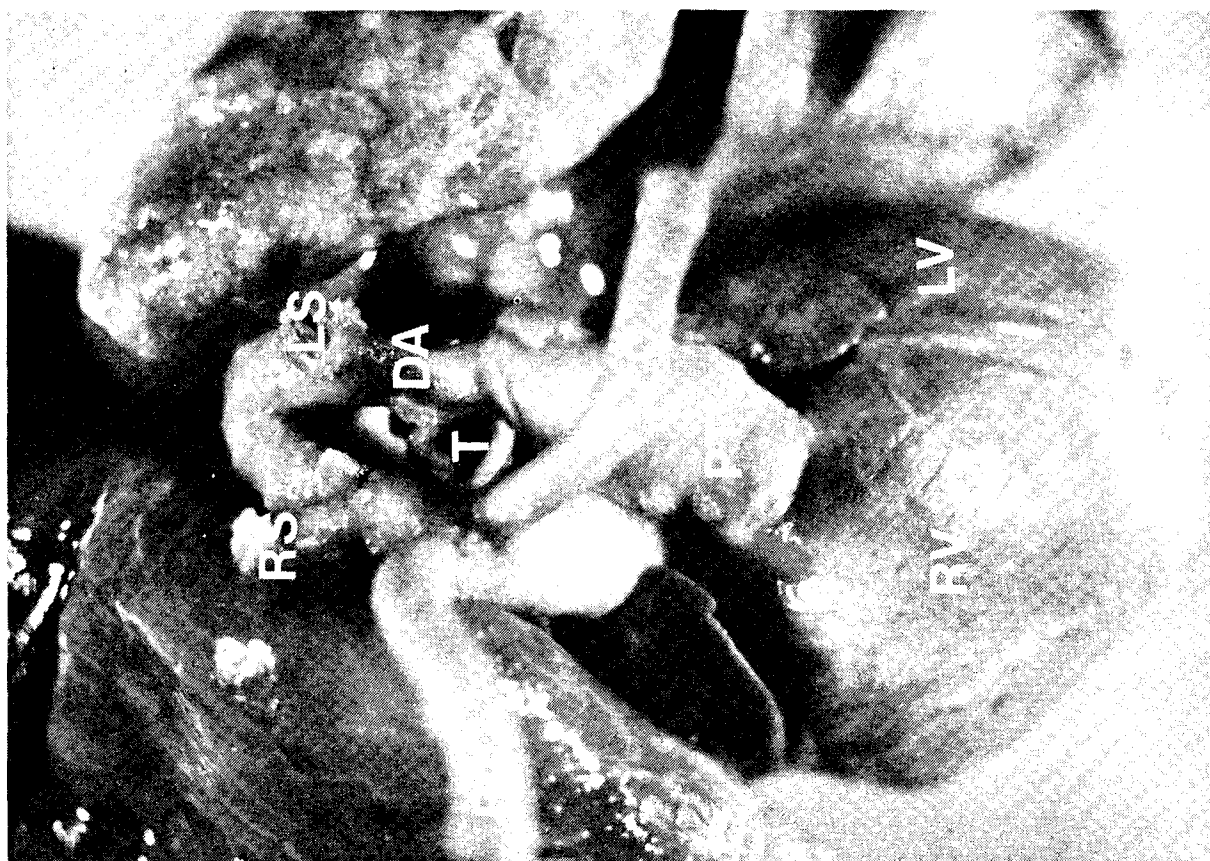

Fig. 2. Superior view of the vascular ring. The tracheoesophageal tree is encircled by a vascular ring formed by both common carotid arteries (LC, RC), right subclavian artery(RS), left subclavian artery(LS), and ductus arteriosus(DA).
PT: pulmonary trunk, A: Aorta

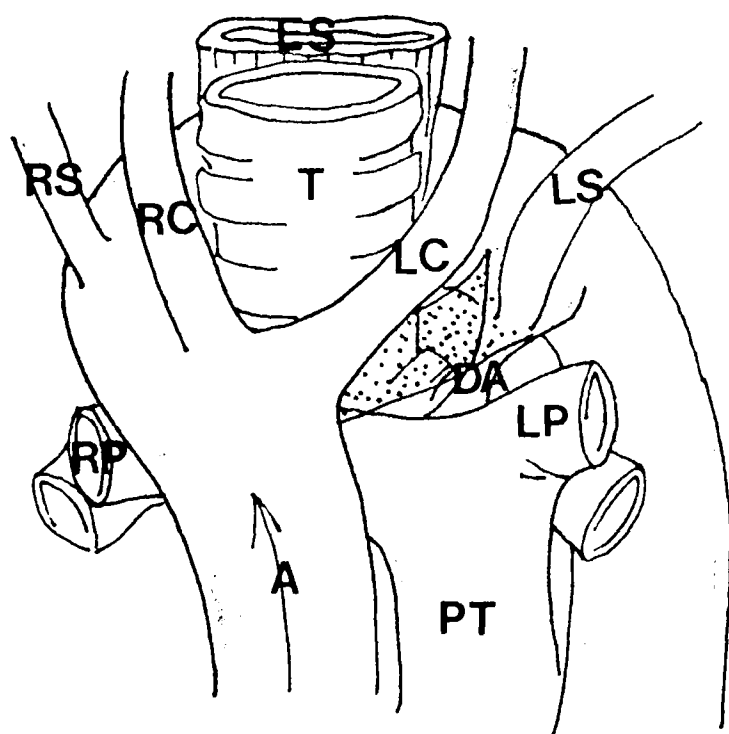


Fig. 3. The interrupted left arch in the present case is expressed in dots. □

minor positive findings were scattered calcifications in the kidney and left ovary, and bilateral extraadrenal cortical nodules.

DISCUSSION

Bilateral aortic arch system connected to both ascending and descending aorta forms complete vascular ring around the esophagus and trachea. But anomalies of aortic arch causing mechanical compression of the esophagus and trachea are collectively called as "Vascular Ring". Therefore, those with left arch and retroesophageal right subclavian artery or right arch with left ductus connected to descending aorta are included in the broad sense of vascular ring.

Edwards (1974) conceived those malformations derived from a functional double aortic arch with bilateral ductus arteriosus, and categorized aortic arch anomalies into four morphogenetic types by the location of ductus and left descending aorta. Anomalies derived from double aortic arch with left ductus and left descending aorta

are the commonest type and the present case belongs to this category. From the hypothetical double aortic arch system, segmental atresia of certain portion of either right or left aortic arch results in the abnormal aortic arch system. Our case can be classified into right aortic arch with retroesophageal component and the ductus is usually connected to the distal part or 'diverticulum' of left arch. The interruption of the left arch can occur at sites lying either between the carotid and subclavian artery as in the present case or distal to the subclavian branch which remains to be hypothetical. The schematic presentations of the left arch in the present case was summarized in Figure 3.

Associated cardiac anomalies vary by the morphologic types of aortic arch anomalies. Double aortic arch is almost always associated with cyanotic congenital heart disease such as tetralogy of Fallot and transposition of great arteries. Left aortic arch with retroesophageal subclavian artery is frequently associated with tetralogy of Fallot. Right aortic arch is frequently seen in cases of tetralogy of Fallot especially when double ductus arteriosus is present. However, right aortic arch with left ductus connected to left innominate artery and right aortic arch with retroesophageal component (as in the present case) are not frequently associated with cardiac defects. One review on the right arch with retroesophageal component revealed 88% of cases without intracardiac defect (Stewart *et al.* 1983). The cardiac anomalies in the present case were ventricular septal defect and patent foramen ovale. Though ductus arteriosus could be probed forcefully, nonfilling on silicate casting of the arch strongly suggested its functional closure.

The vascular ring may be symptomatic or asymptomatic, but some of asymptomatic cases in infancy may become symptomatic as the size of the arch increases (Binet *et al.* 1977). Commonly associated manifestations of the vascular ring include both respiratory and digestive symptoms such as stridor, dyspnea, cyanosis, and feeding difficulties with aspiration, and rarely some types can be a focus of traumatic rupture (Mozzi *et al.* 1979). Those symptoms are mainly due to the tracheoesophageal compression by anomalous circle of the vascular ring. Retrospectively, cyanosis on crying, cough, and dysp-

nea in the present case are thought to be the result of tracheoesophageal compression, because her intracardiac anomalies were not of cyanotic nature.

The vascular ring in this case caused no significant hemodynamic derangement, and the condition rarely need surgical correction, unless the symptom is severe enough to be disabling. Division of ductus or fibrous cord at the site of atretic segment will provide loosening of the ring. Final autopsy results couldn't elucidate the definite cause of death, but the aspiration pneumonia and related processes due to compression of tracheoesophageal tree by the vascular ring would be the most plausible explanation.

Because the condition is not exceptionally rare, the patients with unexplained respiratory or digestive manifestations should be evaluated for the possibility of vascular ring whether they have congenital heart disease or not.

REFERENCES

- Berman W, Yabek SM, Dillon T, Nal JF, Akl B, Burstein J. Vascular ring due to left aortic arch and right descending aorta. *Circulation* 1981, 63:458-460
- Binet JP, Langlois J. Aortic arch anomalies in children and infants. *J. Thorac. Cardiovasc. Surg.* 1977, 73:248-252
- Blatchford JW, Franciosi RA, Singh A, Edwards JE. Vascular ring in interruption of the aortic arch with bilateral patent ductus arteriosi. *J. Thorac. Cardiovasc. Surg.* 1987, 94:596-599
- Chi JG, Lee JY, Lee SK, Hong CY. Vascular ring with Eisenmenger complex. An autopsy case report. *Kor. Cent. J. Med.* 1965, 5:577-580
- Edwards JE. Anomalies of the aortic arch system. In *the heart*. ed. by Edwards JE, Lev M, Abell MR. Williams and Wilkins, Baltimore, 1974, pp. 332-348
- McKay R, Stark J, Leval MD. Unusual vascular ring in infant with pulmonary atresia and ventricular septal defect. *Br. Heart J.* 1982, 48:180-183
- Minami K, Sagoo KS, Matthies W, Meyer H, Korfer R. Left aortic arch, retroesophageal aortic segment, right descending aorta and right patent ductus arteriosus—A very rare "Vascular Ring" malformation. *Thorac Cardiovasc Surgeon* 1986, 34: 395-397
- Mozzi P, Bortolotti U, Casarotto D, Betti D, Fracasso A, Gallucci V. Traumatic rupture of a retro-esophageal aortic arch with congenital vascular ring. *Thorax* 1979, 34:276-278
- Pirtle T, Clarke E. Vascular ring. Unusual cause of unilateral obstructive pulmonary hyperinflation. *A.J.R.* 1983, 140:1111-1112

Stewart JR, Kincaid OW, Titus JL. Right aortic arch; Plane film diagnosis and significance. Am. J. Roentgenol. Radium. Ther. Nucl. Med. 1966, 97:377, cited by Sissman NJ(1983)

Sissman NJ. Anomalies of the aortic arch complex. In: Heart disease in infancy, children, and adolescents, ed. by Moss AJ, Adams FH. Williams and Wilkins, Baltimore, 1983, pp. 199-215

Symbas PN, Shuford WH, Edwards FK, Sehdeva JS. Vascular ring-Persistent right aortic arch, patent proximal left aortic arch, and left ligamentum arteriosum. J. Thorac. Cardiovasc. Surg. 1971, 61:149-153

Whitman G, Stephenson LW, Weinberg P. Vascular ring: Left cervical aortic arch, right descending aorta, and right ligamentum arteriosum. J. Thorac. Cardiovasc. Surg. 1983, 83:311-315

= 국문초록 =

혈관환 : 1 부검례 보고

서울대학교 소아병원 병리과 및 서울대학교 의과대학 병리학교실, *한일병원 소아과

김종재 · 서정욱 · 지제근 · *정근희 · *장진근

저자들은 가벼운 상기도 감염 증상 및 울음시의 청색증, 기침을 주소로 치료중 사망한 1개월 여아의 부검중 발견된 심실중격 결손 및 양측의 흡인성폐렴의 소견과 동반된 혈관환을 보고하는 바이다.

본 혈관환은 Edwards의 분류상 제1유형에 속하는 형태로 그 구성은 전측으로부터 좌총경동맥, 우총경동맥, 우쇄골하동맥, 좌쇄골하동맥, 좌동맥관으로 이루어져 있었다.

혈관환은 비교적 흔하지 않은 대동맥궁의 선천성 기형의 한 형태로 기도 및 식도의 압박에 따른 임상증상을 발현할 수 있는 바 본 예에서도 유사 임상증상 및 흡인성 폐렴이 증명되어 그에 관련된 임상적 및 병리학적인 소견을 기술하였다.