

Preliminary Experience of Amnioinfusion

Woo Jin Kim, Bo Hyun Yoon, Sook Hyun Ki, Me Lee Lee, Jong Kwan Jeon,
Hee Chul Syn and Syng Wook Kim

Department of Obstetrics and Gynecology, Seoul National University
College of Medicine, Seoul 110-744, Korea

= Abstract = Oligohydramnios is considered as one of the major obstetrical dilemmas for the multiple serious complications associated with the condition. The condition hampers an appropriate ultrasonographic evaluation of the fetal anatomy and frequently causes variable fetal heart rate decelerations by compressing the fetal cord, often to incur irreversible damage to the fetus. Based on precedent reports regarding the effect of amnioinfusion in managing oligohydramnios-complicated pregnancies, we report here our experience of amnioinfusion in 8 cases complicated by oligohydramnios which we have experienced from November of 1990 to May of 1993 at Seoul National University Hospital(SNUH). The procedure was applied largely for three purposes, viz., diagnostic(3cases), therapeutic(4cases), and prophylactic(1case) with favorable results. We concluded that amnioinfusion can be of important use in the detection of fetal anomalies, relief of abnormal fetal heart rate pattern, and prevention of intrapartum fetal complications.

Key Words: *Oligohydramnios, Fetal heart rate decelerations, Amnioinfusion*

INTRODUCTION

Oligohydramnios, etiologies of which consist of genitourinary tract obstruction, renal dysfunction, premature rupture of membranes, fetal-growth retardation, and more, is one of the major obstetrical perplexities as it usually forebodes poor fetal outcome and at the same time does not allow good ultrasonographic evaluation of the fetus to take appropriate measures at the

right time. Complications associated with oligohydramnios are multiple, but two are well known. One is the predisposition to umbilical cord compression which results in variable fetal heart rate decelerations and another is its deleterious effect on the development of fetal lungs to play a major role in causing oligohydramnios syndrome or tetrad consisting of pulmonary hypoplasia, or orthopedic deformities, Potter's facies and fetal growth retardation(Stringer *et al.* 1990).

For the aforementioned oligohydramnios-associated complications, the procedure of amnioinfusion has the advantages of offering diagnostic, therapeutic and further prophylactic solutions. Amnioinfusion, which is the process of

Received July 1993, and in final form August 1993.

서울대학교 의과대학 산부인과학교실: 김우진, 윤보현, 기숙현, 이미리, 전종관, 신희철, 김승욱

instilling fluid, usually normal saline, into the amniotic cavity, enhances ultrasonographic visualization by providing an acoustic window for an improved resolution and freeing the fetus from the flexed position incidental to oligohydramniotic state; and also relieves variable fetal heart rate decelerations by forming amniotic pockets around the compressed cord and placenta, thereby reducing cord and placental compression. Improved ultrasonographic visualization makes it possible to recognize any existing anatomical problem and makes differential diagnosis possible for appropriate intervention where needed. Relief of fetal heart rate decelerations could result in improvement in fetal metabolic state to allow labor to proceed without operative intervention. Reports of successful amnioinfusion have already been made by many groups after Miyazaki and Taylor(1983) who performed this procedure on humans for the first time.

Thus far there have been no reports on amnioinfusion in Korea and here we report our experiences of amnioinfusion in 8 cases accumulated since 1990 where the procedure was performed for diagnostic, therapeutic and prophylactic purposes.

MATERIAL AND METHODS

Study Population: Amnioinfusions of this report were performed from November of 1990 to May of 1993 on the patients diagnosed ultrasonographically to have oligohydramnios defined to be the absence of at least one amniotic fluid pocket measuring greater than 1 × 1cm. The gestational ages of the amnioinfused patients ranged from as early as 17 weeks to as late as 42 weeks of gestation.

The procedure was performed at the discretion of the attending doctor on a case by case basis and not according to any strict criteria, after receiving an informed consent from the patient and the family. The procedure was employed largely for three purposes, viz., diagnostic(cases 1,2, and 3), therapeutic(cases 4,5,6

and 7), and prophylactic(case 8).

Methods of amnioinfusion: Routes of amnioinfusion employed were either transabdominal or transcervical. For the cases with rupture of membranes the transcervical route was used. The basic infusion equipment consisted of intravenous extension tubing, a three-way stopcock, and 1,000ml of normal saline solution warmed to 37° C with blood warmer. For the transabdominal route, 21 gauge spinal needle was employed for puncture and conduit. Throughout the infusion process, the mother was kept in the left lateral position with adequate oxygen supply via facial oxygen mask and constant monitoring of the uterine contraction and fetal heart tone were made by external tocodynamometer(115 Fetal Monitor, Corometrics Medical System, inc). Whenever possible, the infusion was maintained at a rate of 10 to 20ml per minute and until the amniotic fluid index reached a value of 8. Amniotic fluid index and biophysical profile were assessed according to the descriptions made by Manning *et al.*(1980). Table 1 demonstrates the clinical characteristics and methods of amnioinfusion of the 8 cases.

CASE REPORT

CASE 1

A 22-year-old woman, gravida 1, para 0 was referred to our Department at 24⁺⁴ weeks of pregnancy with oligohydramnios on November 18, 1992. At the time of visit, amniotic fluid index was 4.3 with both kidneys appearing normal. On November 30, the amniotic fluid index was further decreased to 3.7 and she was admitted. Amnioinfusion of 500ml of normal saline was performed transabdominally on the next day to bring up the amniotic fluid index to 7.7. Ultrasonographic follow up made on December 3rd showed absence of both kidneys and bladder but a cystic lesion measuring 1.2 to 1.5cm in diameter was observed. On December 7th, amniotic fluid index was measured at 3.0 and a second attempt at amnioinfusion was made to increase the amniotic fluid index to 10.0. However on a repeat sonographic assessment

Table 1. Clinical characteristics and method of amnioinfusion of the 8 cases

Case	Gestational age at the diagnosis of oligohydramnios	Additional pre-amnio infusion problems	Method of infusion			Post-infusion outcome	Fetal outcome
			Amount	Route	No. of infusion		
<u>Diagnostic</u>							
1	25 Week	(–)	500ml	Transabdominal	2	Detection of polycystic kidney on the second trial of amnioinfusion	1.22kg, female, stillborn terminated
2	22 Week	(–)	600ml	Transabdominal	1	Detection of fetal hydrocephalus and absence of fetal heart tone	540g, male, stillborn terminated
3	17 Week	Huge abdominal cyst(USG)	1st-560ml	Transabdominal	1	Visualization of both kidneys after cyst aspiration Chorioamnionitis (probably due to infusion)	290g, male, stillborn
			2nd-300ml	Transabdominal	1		
<u>Therapeutic</u>							
4	34 Week	FGR, low bio-physical profile` score, late decelerations, compromised cord blood gas status	350ml	Transabdominal	1	Improved variability and disappearance of decelerations	980g, male, AS(5 to 6), premature spontaneous vaginal delivery
5	39 Week	FGR, variable decelerations	250ml	Transcervical	1	Reduction in variable decelerations	2.28kg, male, AS(9 to 10), spontaneous vaginal delivery
6	39 Week	Early decelerations	450ml	Transcervical	1	Decreased frequency of early decelerations	2.09kg, female, AS(7 to 8), spontaneous vaginal delivery
7	42 Week	Rupture of amniotic membranes, variable decelerations	500ml	Transabdominal	1	Disappearance of decelerations, improved variability	3.51kg, male, AS(3 to 6), C/S due to dystocia

Table 1. (Continued)

Case	Gestational age at the diagnosis of oligohydramnios	Additional pre-amnio-infusion problems	Method of infusion			Post-infusion outcome	Fetal outcome
			Amount	Route	No. of infusion		
<u>Prophylactic</u>							
8	33 Week	Premature rupture of membranes	250ml	Transcervical	1	Uneventful labor course	1.95kg, male, AS(7 to 8), premature spontaneous vaginal delivery

FGR-Fetal growth retardation,USG - Ultrasonography, IVP - Intravenous pitocin, AS-Apgar score, C/S-Cesarean section

on December 8th, the diagnosis of polycystic kidney with oligohydramnios and a subsequent decision to terminate the pregnancy were made. On December 11th, following the use of Nalador®, a female infant weighing 1.22kg was stillborn. The patient was further managed and discharged uneventfully. Subsequent autopsy findings revealed the fetus to have bilateral renal dysplasia (Potter type IIc cystic disease) and hypoplasia of the urinary bladder

CASE 2

A 29-year-old woman, gravida 2, para 1 was referred to our Department on January 14th, 1993 at 21⁺³ weeks of pregnancy with oligohydramnios. Ultrasonographic examination then revealed the amniotic fluid index to be 0.8 with breech presentation and a low-lying placenta. Two days later 600ml of normal saline was infused transabdominally into the amniotic cavity. Ultrasonography two hours following the infusion showed an absent fetal heart beat and fetal hydrocephalus.

On the next day, laminaria was inserted for termination and a male infant weighing 540g was stillborn on January 28th. The infant was grossly free but there was only a single artery, as opposed to the normal two arteries, and a vein in the umbilical cord.

CASE 3

A 25-year-old woman, primigravida was referred to our unit on May 3rd, 1993 with suspected short fetal extremity at 16⁺⁵ weeks of pregnancy.

As the ultrasonographic finding at the time of the visit consisted of significantly decreased amniotic fluid (amniotic fluid index of less than 1) and a huge abdominal cyst measuring 7.5 × 7.9 × 7.0cm, she was admitted under the impression of fetal urethral obstruction. On the next day, the cyst was aspirated of 315ml to greatly reduce the size of the cyst to 1.6 × 1.1 × 1.2cm and amnioinfusion with 560ml of normal saline was performed to evaluate detailed anatomy. The components of the aspirated fluid were similar to urine.

A second trial of cyst aspiration for 40ml to further decrease the size of the cyst to 0.7 × 1.4 × 0.9cm and amnioinfusion with 300ml of normal saline were performed on May 7th.

On 11th of May, fetal echocardiography revealed the heart to be free of any significant disease and the size of the cyst to be again increased to 5.6 × 4.1 × 4.5cm, a solution to manage for which vesicoamniotic shunt tube insertion was suggested but the procedure

could not be performed as premature rupture of membrane accompanied by ultrasonographic diagnosis of absence of fetal heart movement soon took place. Subsequent to the rupture of membrane, a male infant weighing 290g with abdominal distension as the only gross anomaly was stillborn.

Autopsy findings were imperforate cloacal membrane with ureteral atresia(right), polycystic kidney (type IV) with ureteral atresia(left), and acute suppurative chorioamnionitis of the placenta.

CASE 4

A 26-year-old primigravida was referred on November 13, 1990 to our Department from an outside hospital at 33⁺³ weeks of pregnancy with oligohydramnios.

According to the ultrasonographic examination, the fetus was severely growth retarded with an amniotic fluid index of 4.6. She was admitted on the next day and follow up of amniotic fluid index was made. The amniotic fluid index was further decreased to 3.2 on the admission day and then to 1.5 on the day following. On the third admission day, cordocentesis for rapid karyotyping and cord blood acid-base and gas analysis due to severe intrauterine growth retardation and amnioinfusion for oligohydramnios were performed. Preceding the two procedures, the biophysical profile of the fetus were: non-stress test (0); fetal breathing movement (0); fetal movement (0); fetal tone (2); and amniotic fluid volume (0). During the non-stress test, late decelerations with even a drop of fetal heart rate to below 50 beats per minute was observed and there was almost no variability of fetal heart rate (Fig.1). The blood gas analysis of the umbilical venous blood obtained by cordocentesis were: pH (7.23); PCO₂ (49 mmHg), PO₂(36 mmHg), and HCO₃(20mmol/l). The infusion made was 350ml of 37° C normal saline. Immediately following infusion, ultrasonographic findings were : amniotic fluid index (8); non-stress test (unsatisfactory); fetal breathing movement(1); fetal movement (1); fetal tone(1); and amniotic fluid volume(2).

Following the infusion, a dramatic improvement in the variability of fetal heart rate as well as disappearance of deceleration were observed almost immediately as shown in Fig. 2 and a vaginal prostaglandin suppository was inserted into the posterior fornix of the vagina for labor induction as the fetus was considered to be in severe acidosis(Lucie *et al.*1990), but late decelerations later showed up with contractions to consider an emergency cesarean delivery. Unfortunately the guardian refused the procedure and intravenous Yutopar was started to relieve the deceleration. Labor progressed and a 980g male infant with an Apgar score of 5 to 6 was delivered. The infant was then managed at neonatal intensive care unit with a sole complication of intraventricular hemorrhage(Gr.II), but 11 days later the baby was taken home against medical advice.

CASE 5

A 35-year-old woman, gravida 6, para 0, was admitted on November 19,1990 at 38⁺⁴ weeks of pregnancy with oligohydramnios, fetal growth retardation, gestational diabetes mellitus and hyperthyroidism. The ultrasonographic finding prior to amnioinfusion consisted of a biophysical profile score of 8 out of total score of 10, amniotic fluid index of 4.8 and a fetal heart rate of 145/min without any decelerations. On November 21, during tococardiographic recording, variable decelerations appeared and to relieve the stress, 250ml of 37° C normal saline was infused into the amniotic cavity first to cause reduced frequency of variable decelerations and as there was no point delaying delivery,intravenous pitocin induction was started to give vaginal birth to a male infant weighing 2.28kg with an Apgar score of 9 to 10 on the same day. Both the mother and infant were discharged following an uneventful hospital course

CASE 6

A 28-year-old, nulligravida was admitted on November 20, 1990 at 38⁺⁴ weeks of pregnancy due to oligohydramnios and for induction of

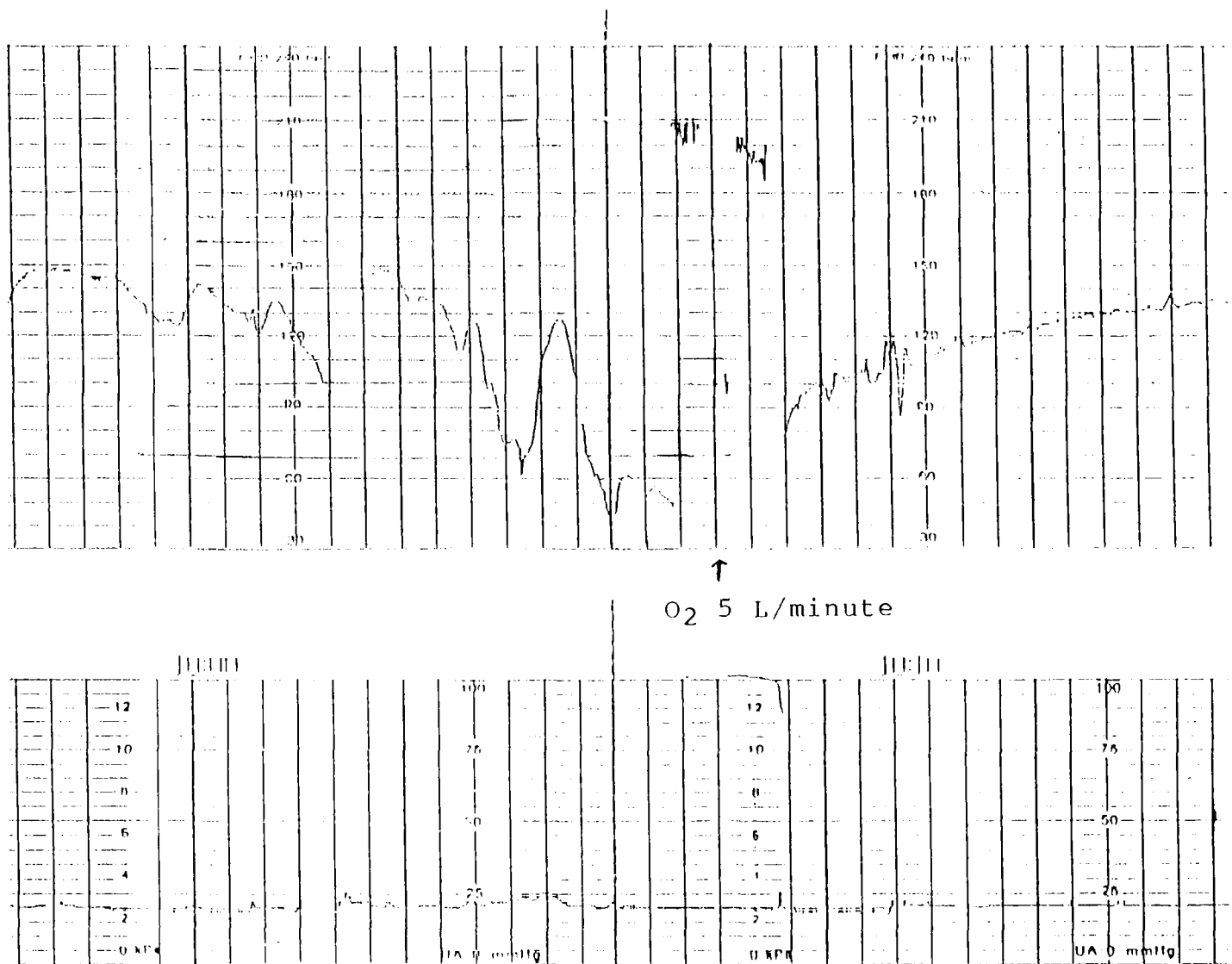


Fig. 1. Monotonous fetal heart rate pattern with severe late decelerations(as low as 45 beats/min) is shown (approx. 1 hour of pre-amnioinfusion).

labor. Her amniotic fluid index was first detected to be severely decreased(5.1) at 37⁺⁵ weeks of pregnancy and hence follow up of it was made thenceforth. On November 19th and 20th all measured amniotic fluid pockets were slit-like and there was no change in the oligohydramniotic state. On November 20th, with the start of intravenous pitocin induction, early deceleration showed up on tococardiographic monitoring and after artificial rupture of the membrane, amnioinfusion of 450ml of normal saline was made, frequency of early deceleration decreased to a significant degree and a female infant weighing 2.09kg with an Apgar score of 7 to 8 was normally delivered vaginally. Both mother and infant were discharged following an uneventful hospital

course

CASE 7

A 31-year-old woman, gravida 2, para 1 was admitted on May 5th, 1991 due to rupture of membrane at 41⁺² weeks of pregnancy. Intravenous pitocin was infused from 6th to 8th of May with no success. On May 9th, 500ml of normal saline was amnioinfused. Pre-amnioinfusion findings consisted of variable decelerations(Fig. 3) and an amniotic fluid index of 1.0 and following the infusion, the decelerations disappeared and variability also showed improvement (Fig.4). Flow of her amniotic fluid showed meconium staining and under an impression of failure to progress, an emergency cesarean section was

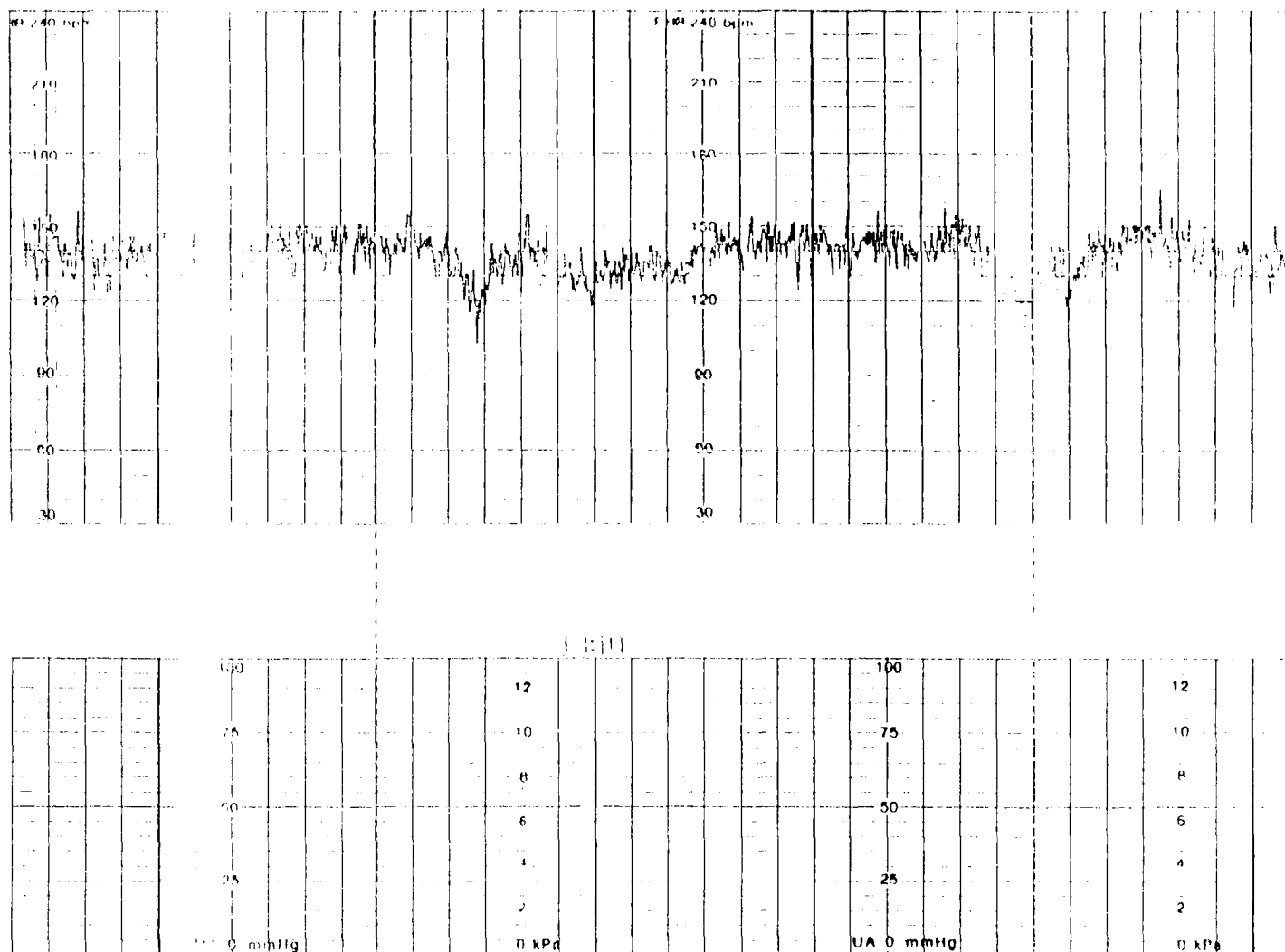


Fig. 2. After the start of amnioinfusion, a dramatic improvement in the variability as well as disappearance of the decelerations can be seen.

made to give birth to a 3.51kg male infant with an Apgar score of 3 to 6. Both mother and infant were later discharged uneventfully.

Case 8

A 28-year-old woman, nullipara was admitted on May 16, 1993 at 32⁺⁴ weeks of pregnancy with preterm labor pain and premature rupture of membranes. Upon admission, the preterm labor pain was managed with intravenous Yutopar.

On the 2nd admission day, the amniotic fluid index was measured at 4.1 and amniocentesis was performed to obtain a lecithin/sphingomyelin ratio of 4.2; and on the next day amnioinfusion was made with 250ml of normal saline by transcervical route for the purposes to induce delivery and reduce fetal distress whilst labor. Following the amnioinfusion, labor soon began and a male infant weighing 1.95kg with

an Apgar score of 7 to 8 was prematurely delivered vaginally. The infant was then well taken care of at neonatal intensive care unit, where his course was uneventful.

DISCUSSION

The first case of amnioinfusion was experimented with monkeys (Gabbe *et al.* 1976). For the experiment, amniotic fluid was first removed to induce variable deceleration and by infusing normal saline, disappearance of the deceleration was observed. The first report of amnioinfusion in human was made by Miyazaki and Taylor in 1983, in which they observed recovery of variable fetal heart rate deceleration with amnioinfusion in about half (Miyazaki and Taylor 1983).

Miyazaki and Nevareze (1985) emphasized that the procedure is simple and requires only

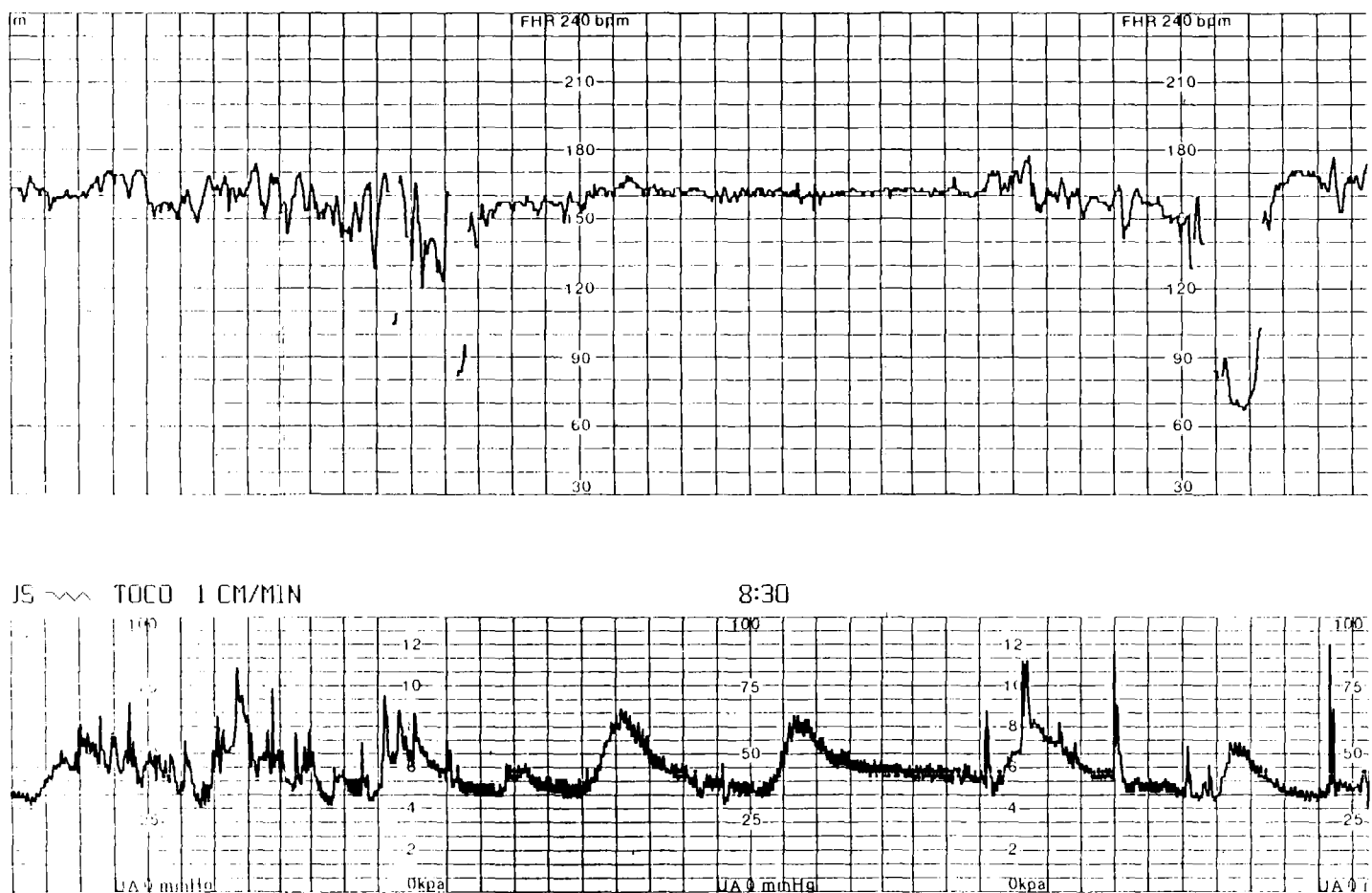


Fig. 3. With increasing frequency of contractions, variable decelerations appeared.

minimal equipment which is a three-way stop-cock to divert the passage from the intrauterine pressure catheter tube to the intravenous extension tubing of the amnioinfusion solution bottle.

The modes of amnioinfusion known are many and the commonly employed ones are vesicoamniotic shunting (Manning *et al.* 1986), fluid infusion via an indwelling transcervical catheter (Imanaka *et al.* 1989), and serial trans-abdominal fluid infusion (Nicolini *et al.* 1989). In 1986, Manning *et al.* had attempted vesicoamniotic shunting in urinary tract obstruction, but the result was not satisfactory as the problem of pulmonary dysplasia persisted. As a solution to the problem, Fisk *et al.* (1991) suggested sequential amnioinfusion in the cases of urinary tract obstruction. Another important factor for a successful amnioinfusion is the proper placement of infusion needle and for those cases where this is not feasible, the recommended sites are between extremities, back, and the nape of the neck (Stringer *et al.* 1990)

In 1988, Gembruch and Hansman (1988) attempted amnioinfusion in an effort to enhance ultrasonographic resolution. Fisk *et al.* (1991) pointed out the diagnostic uses of amnioinfusion in improving delineation of anatomic structure and also in determining rupture of membrane. In cases 1, 2 and 3 of the current report it was possible to make a diagnosis of gross fetal anomalies through amnioinfusion to make early interventions in the pregnancies. If fetal anomaly is detected in the early part of gestation with the help of amnioinfusion, termination should be recommended. Romero *et al.* (1988) advises termination of pregnancies suspected to have renal agenesis.

During the process of amnioinfusion, it is also possible to concurrently carry out chromosomal analysis to rule out any major fetal anomalies and this procedure is especially meaningful to perform in second trimester oligohydramniotic cases where 5-10% show chromosomal anomaly. In case of premature rupture of mem-

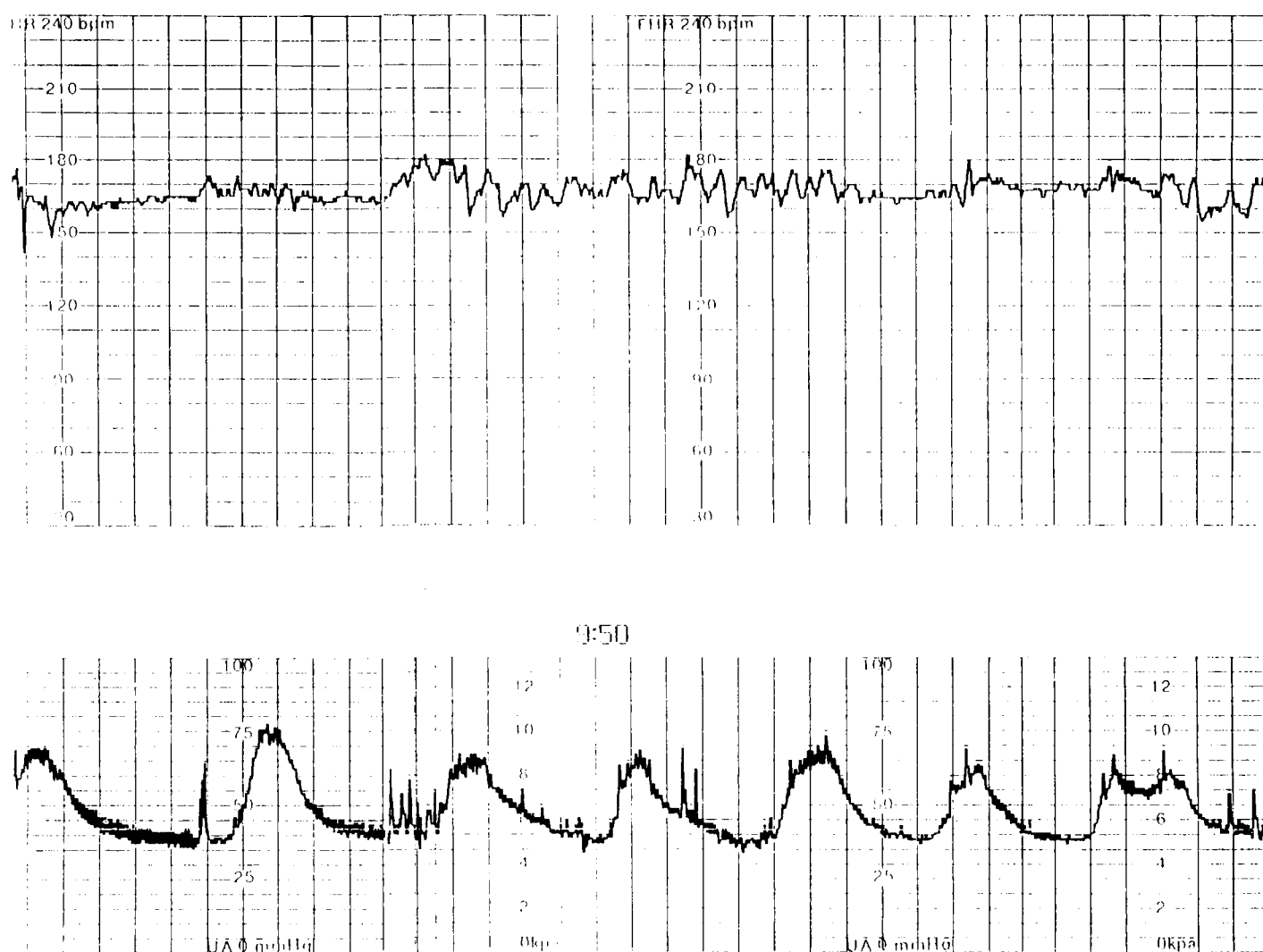


Fig. 4. Following the start of infusion, no more decelerations were observed.

branes, with amnioinfusion, the presence of leakage can be determined by indigocarmine dye injection(Fisk *et al.* 1991).

Among the cases of this report, in case 4, to briefly review the pre-amnioinfusion fetal gas and metabolic status, according to Lucie *et al.* (1990) the 5th percentile of umbilical vein pH of 33.5 week old fetus is 7.360 meaning the fetus concerned was in severe acidemia, and PCO_2 and PO_2 for a 34 week old fetal umbilical vein are considered both high and low if 41 and 25.4, respectively, and into which categories the fetus belonged; however it was possible to observe a much improved biophysical profile score and return of variability of fetal heart rate and also disappearance of decelerations upon amnioinfusion to validate the effect of the procedure in improving fetal distress.

Amnioinfusion in oligohydramnios is known to bring about improvement in severe variable deceleration by forming amniotic pockets in the periphery of the umbilical cord which relieves the cord from the pressure effect. Miyazaki and Nevareze(1985) obtained a success rate of 51% as compared to 4.2% of non-amnioinfusion cases. However, according to a report by Goodlin *et al.*(1990), the procedure guarantees a success rate of only 15% and still is uncertain to predict. Decelerations in cases 4, 5, and 7 had initially been late in case 4, and variable in cases 5 and 7, and following amnioinfusion disappearance of decelerations were noted.

Nageotte *et al.*(1985) prophylactically performed amnioinfusion in cases of premature rupture of membranes and reported a significant decrease in the incidence of variable fetal heart

rate deceleration. Also in 1990, Strong *et al.* (1990) suggested that prophylactic amnioinfusion in term oligohydramnios is relatively a simple, safe, and economical procedure to reduce occurrence of perinatal morbidity. In case 8, the amnioinfusion was prophylactically made and the infant was delivered without any intrapartum complications usually expected of with oligohydramniotic cases. Wenstrom and Parsons (1989) suggested that amnioinfusion during labor could help prevent meconium aspiration.

There have also been reports that amnioinfusion, although clinically may not be that effective in improving variable deceleration, but can improve the metabolic state of the fetus, and thereby reduce the incidence of perinatal morbidity. In contrast, MacGregor *et al.* (1991) report that prepartum amnioinfusion in oligohydramniotic cases does not help reduce the incidence of fetal metabolic derangement or perinatal morbidity.

Contrary to all the good reasons to performing amnioinfusion, as there are a few risks accompanying the procedure such as infection, as probably resulted in case 3, triggering of preterm labor pain, and causing uterine overdistension and elevation of intrauterine pressures to have adverse fetal effects (Tabor and Maier, 1987), it is important to take every necessary heed.

It has been possible to see how amnioinfusion can be of important use in early detection of fetal anomalies, relief of fetal distress and prevention of intrapartum fetal complications. Early diagnosis of fetal anomalies can help in making decisions such as termination or taking operative intervention to prevent further aggravation of the recognized condition and save the fetus. The procedure can be performed to relieve fetal distress and make normal vaginal delivery possible as opposed to operative intervention which the situation would usually call for. In the cases where fetal distress is predictable during the course of labor, it is suggested the procedure be performed prophylactically to avoid unnecessary complications. Particularly for second trimester

oligohydramniotic cases, it is suggested that amnioinfusion should be more intensively performed for both diagnostic and treatment purposes.

REFERENCES

- Fisk NM, Ronderos DD, Soliani A, Nicolini U, Vaughan J, Rodeck CH. Diagnostic and therapeutic trans-abdominal amnioinfusion in oligohydramnios. *Obstet Gynecol* 1991; 78:270-8
- Gabbe SG, Ettinger BB, Freeman RK. Umbilical cord associated with amniotomy: Laboratory observations. *Am J Obstet Gynecol* 1976;126:353-5
- Gembruch U, Hansmann M. Artificial instillation of amniotic fluid as a new technique for the diagnostic evaluation of cases of oligohydramnios. *Prenatal Diagn* 1988; 8:33-45
- Goodlin RC, Ingram M. Ultrasonic study of amnioinfusion. A report of two cases. *J Reprod Med* 1990; 35: 439-40
- Imanaka M, Ogita S, Sugawa T. Saline solution amnioinfusion for oligohydramnios after premature rupture of the membranes. *Am J Obstet Gynecol* 1989; 161:102-6
- Lucie SMR, Rosalinde JMS, Nicolaidis KH, Visser GHA. Relationship of fetal biophysical profile and blood gas values at cordocentesis in severely growth-retarded fetuses. *Am J Obstet Gynecol* 1990; 163: 569-71
- MacGregor SN, Banxhaf WC, Silver RK, Depp R. A prospective randomized evaluation of intrapartum amnioinfusion. Fetal acid-base status and cesarean delivery. *J Reprod Med* 1991; 36:69-73
- Manning FA, Harrison MR, Rodeck CH, and members of the International Fetal Medicine and Surgery Society. Catheter shunts for fetal hydronephrosis and hydrocephalus. *N Engl J Med* 1986; 315:336-40
- Manning FA, PLatt LD, Sipos L. Antepartum fetal evaluation: Development of fetal biophysical profile. *Am J Obstet Gynecol* 1980; 136:787-95
- Miyazaki FS, Taylor NA. Saline amnioinfusion for relief of variable or prolonged decelerations. *Am J Obstet Gynecol* 1983; 146:670-8
- Miyazaki FS, Nevarez F. Saline amnioinfusion for relief of repetitive variable deceleration: a prospective ran-

- domized study. *Am J Obstet Gynecol* 1985; 153: 301-6
- Nageotte MP, Freeman RK, Garite TJ, Dorechester W. Prophylactic intrapartum amnioinfusion in patients with preterm premature rupture of membrane. *Am J Obstet Gynecol* 1985; 153:557-61
- Nicolini U, Fisk NM Rodeck CH, Talbert DG, Wigglesworth JS. Low amniotic pressure in oligohydramnios-is this the cause of pulmonary hypoplasia? *Am J Obstet Gynecol* 1989;161:1098-101
- Romero R, Pilu G, Jeanty P, Ghidini A, Hobbins JC. Prenatal diagnosis of congenital anomalies by ultrasound. Norwalk, Connecticut:Appleton and Lange, 1988:263-4
- Stringer M, Librizzi R,Weiner S. Management of midtrimester oligohydramnios: a case for amnioinfusion. *J Perinatol* 1990; 10:143-5
- Strong TH Jr, Hetzler G, Sarno AP, Paul RH. Prophylactic intrapartum amnioinfusion: a randomized clinical trial. *Am J Obstet Gynecol* 1990; 162: 1370-4.
- Tabor BL, Maier JA. Polyhydramnios and elevated intrauterine pressure during amnioinfusion. *Am J Obstet Gynecol* 1987; 156:130-1
- Wenstrom KD, Parsons MT. The prevention of meconium aspiration in labor using amnioinfusion. *Obstet Gynecol* 1989; 73:647-51