



Frontalis sling operation using silicone rod for the correction of ptosis in chronic progressive external ophthalmoplegia

J Ahn, N J Kim, H K Choung, et al.

Br J Ophthalmol 2008 92: 1685-1688 originally published online September 11, 2008

doi: 10.1136/bjo.2008.144816

Updated information and services can be found at:

<http://bjo.bmj.com/content/92/12/1685.full.html>

These include:

References

This article cites 15 articles, 4 of which can be accessed free at:

<http://bjo.bmj.com/content/92/12/1685.full.html#ref-list-1>

Email alerting service

Receive free email alerts when new articles cite this article. Sign up in the box at the top right corner of the online article.

Topic collections

Articles on similar topics can be found in the following collections

[Muscles](#) (154 articles)

[Neurology](#) (1922 articles)

Notes

To order reprints of this article go to:

<http://bjo.bmj.com/cgi/reprintform>

To subscribe to *British Journal of Ophthalmology* go to:

<http://bjo.bmj.com/subscriptions>

Frontalis sling operation using silicone rod for the correction of ptosis in chronic progressive external ophthalmoplegia

J Ahn,¹ N J Kim,^{1,2} H K Choung,^{1,3} S W Hwang,⁴ M Sung,¹ M J Lee,¹ S I Khwarg¹

¹ Department of Ophthalmology, Seoul National University College of Medicine, Seoul Artificial Eye Center, Clinical Research Institute, Seoul National University Hospital, Seoul, Korea; ² Department of Ophthalmology, Seoul National University Bundang Hospital, Seongnam, Gyeonggi, Korea; ³ Department of Ophthalmology, Seoul Metropolitan Boramae Hospital, Seoul, Korea; ⁴ Department of Ophthalmology, Dongguk University International Hospital, Goyang, Gyeonggi, Korea

Correspondence to:
Dr H K Choung, 395
Shindaebang 2dong Dongjakgu
Seoul 156-012, Korea;
hokyung@medimail.co.kr

Accepted 29 July 2008
Published Online First
11 September 2008

ABSTRACT

Aims: The aim of the study was to evaluate the results of the frontalis sling operation using silicone rod for the correction of ptosis in chronic progressive external ophthalmoplegia patients.

Methods: Chronic progressive external ophthalmoplegia patients who received the frontalis sling operation using silicone rods from 1999 to 2006 were included in this study. The medical records were retrospectively reviewed and the clinical characteristics and postoperative surgical results of these patients were analysed. This study was a retrospective, non-randomised, interventional case series and the main outcome measures were margin reflex distance, eyelid contour and corneal status.

Results: Seven patients were recruited (one male and six female). The mean age at the time of operation was 29.6 (range 15–62) years. Two patients had unilateral ptosis and five patients had bilateral ptosis. The mean follow-up period was 22.7 (range 1–61) months. Satisfactory lid height was achieved in all patients. Although corneal erosions were detected in five patients 1 month after surgery, these findings eventually resolved in three patients 2 months later, after the use of artificial tear eyedrops and ointments.

Conclusion: The frontalis sling operation using silicone rod can safely and effectively correct ptosis in chronic progressive external ophthalmoplegia patients without serious corneal complications.

Chronic progressive external ophthalmoplegia (CPEO) is a mitochondrial myopathy most often involving the levator, orbicularis oculi muscle and extraocular muscles. Clinical findings are slowly progressing ptosis, extraocular movement disorders, poor Bell's phenomenon and poor lid closure.^{1,2} Surgical treatment for ptosis in these patients is generally considered when the visual axis is obscured by the ptotic eyelid or when the ptosis is cosmetically unacceptable.³ Due to the weak Bell's phenomenon and lagophthalmos, CPEO patients are more susceptible to postoperative exposure keratopathy, and ptosis surgery is usually performed with great care.

The frontalis sling operation is generally performed in patients with severe ptosis and poor levator function (<4 mm).⁴ Among the many suspension material currently available, silicone rods have the advantage of excellent elasticity enabling good eye blinking movement and easy adjustability in case of a revision surgery.⁵ Surgical results of ptosis correction have also been comparable with other suspension materials, with numerous reports of successful ptosis correction without

significant ptosis recurrence or complication incidence.^{6–8}

Previously, there have been only two case series and one case report on the use of the frontalis sling operation for the correction of ptosis in specifically CPEO patients.^{3,9,10} Only one has reported the efficacy of using the silicone rod as a suspension material in the frontalis sling operation.⁹ Here we report the surgical results of the frontalis sling operation using silicone rod in CPEO.

METHODS

Patients who had been diagnosed with CPEO and received frontalis sling operation with silicone rod for ptosis correction from 1999 to 2006 were recruited. The clinical characteristics and surgical results were retrospectively reviewed. Data collected included the sex, age at operation, margin reflex distance (MRD), levator function, Bell's phenomenon, extraocular movement, corneal status, type of surgery performed, type of suspension material used, postoperative management, postoperative surgical results and the incidence of corneal complications during the follow-up period. Routine systemic work-up tests, including basic neurological examination and electrocardiograms, were also performed to rule out mitochondrial myopathy involving other organ systems.

Surgery was performed under local anaesthesia. The upper eyelid, brow and lower forehead were injected with 2% lidocaine mixed with 1:100,000 epinephrine (adrenaline). The operative steps are described in fig 1. Five horizontal incisions were made in the shape of a pentagon – three above the eyebrow and two 3 mm above the upper eyelid margin. Two small horizontal stab incisions were made at the upper eyelid margin and dissection through the orbicularis muscle was carried out until the tarsal plate was exposed. Two 6-0 polypropylene sutures were pre-placed within the stab incisions, passing the tarsal plate in partial thickness. The Wright fascia needle was passed just above the tarsus, resultantly placing the silicone rod (Visitec, BD Ophthalmics, New Jersey, USA) under the pretarsal orbicularis muscle, and the silicone rod was fixated to the tarsus by tying the previously placed polypropylene sutures. The medial and lateral ends of the silicone rod were passed through the orbital septum toward the nasal and temporal brow incision respectively and redirected, subcutaneously, toward the central apex incision with the Wright fascia needle. The ends of the silicone rod were brought together within a silicone sleeve and the eyelid was pulled

Table 1 Demographics and clinical data of patients with chronic progressive external ophthalmoplegia before and after frontalis sling with silicone rod

No.	Sex/age (years)	Laterality	PreOP MRD (mm)	PreOP LF (mm)	Follow-up period (months)	PostOP MRD (mm)	MRD at last f/u (mm)	Corneal complications
1	F/20	B	-2.5	0	11	0.3	0	Recurrent keratopathy*
2	M/16	B	-3.0	2	1	0	-0.5	Resolved keratopathy
3	F/39	R	-3.0	3	26	1.0	-0.5	None
4	F/30	B	-3.25	3	61	0.3	-0.5	None
5	F/19	B	-2.5	3.5	8	0.8	1	Resolved keratopathy
6	F/65	B	-0.5	4	12	0.5	1.5	Recurrent keratopathy*
7	F/36	L	-0.5	6	40	1.0	1.0	None

*Mild corneal erosions controlled with artificial teardrops applied four times daily.

B, both eyes; F, female; f/u, follow-up; L, left eye; LF, levator function; M, male; MRD, margin reflex distance; PreOP, preoperative; PostOP, postoperative; R, right eye.

up until the intraoperative MRD was +1.0 mm. The silicone sleeve was tied with 6-0 polypropylene sutures and placed in the central apex incision.

Artificial tear ointment and eyedrops were initiated immediately after surgery and applied alternatively every hour to prevent exposure keratopathy. Antibiotic ointment was applied on the surgical wound twice a day. Patients were followed up 1 week, 1 month, 3 months and 9 months after surgery. Postoperative MRD, eyelid contour and cornea exposure were assessed at each follow-up. Artificial teardrop and ointment were tapered according to corneal findings.

RESULTS

Seven CPEO patients (one male and six female) were recruited for this study. No patient showed any abnormalities on the routine systemic work-up tests. Frontalis sling operation using silicone rod for the correction of ptosis was performed on 12 eyelids of seven patients. Five patients had bilateral ptosis and two patients had unilateral ptosis, right and left, respectively. The mean age was 32 (range 16 to 65) years. The mean preoperative MRD was -2.2 (range -0.5 to -3.5) mm and the mean MRD at 1 day after surgery was +0.5 (range 0 to +1.0) mm. The mean MRD at 3 months after surgery was +0.3 (range -0.25 to +1.0) mm. A cosmetically satisfactory or acceptable eyelid height was achieved in all patients. Corneal erosions were noted in one patient 1 week after surgery and consequently more frequent lubrication was recommended. At 1 month after surgery, corneal erosions were found in four additional patients. Patients were instructed to use artificial lubricants more frequently and at 3 months after surgery, corneal findings in two patients resolved. Corneal findings eventually resolved at

last follow-up in one patient. In the other two patients, corneal erosion persisted but did not lead to pathological corneal changes and the subjective symptom was not severe. Clinical data, pre- and postoperative results, and complication incidence are summarised in table 1.

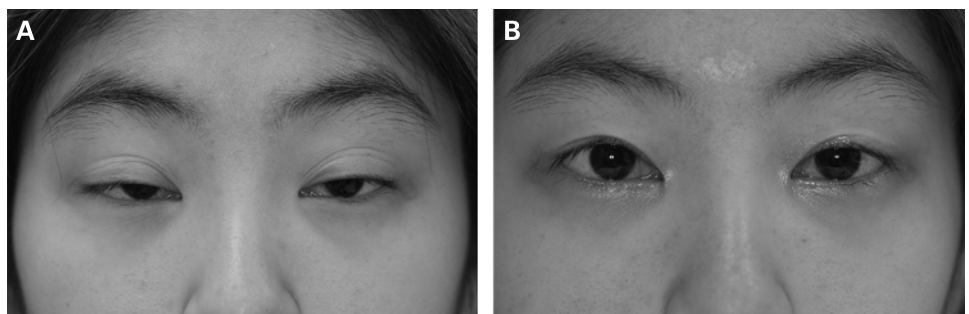
The MRD of the three patients with persistent corneal erosion 3 months after surgery were +1.5, +1.0 and +0.25 at last follow-up. Another patient with a relative large MRD of +1.0 maintained a clear cornea during follow-up.

DISCUSSION

CPEO is a group of mitochondrial dysfunction disorders characterised by extraocular motility impairment, ptosis and generalised weakness. Insidious progression to almost total ophthalmoplegia and loss of levator function is common.¹¹ Bilateral progressive ptosis is the most common presenting symptom and may precede ophthalmoplegia by months to years.¹² CPEO patients usually develop good vision with a compensatory backward head tilt and do not have diplopia because ocular movement limitations are bilateral.¹²

Frontalis sling procedure is the treatment of choice in patients with severe ptosis and poor levator function. Both autogenous and non-autogenous materials are available for frontalis suspension. Although autogenous fascia is considered the material of choice¹³ due to lower ptosis recurrence and complication rate in general ptosis surgery, silicone rods have superior adjustability and the elastic nature allows good eyelid approximation, minimising lagophthalmos and decreasing the likelihood of postoperative corneal exposure.¹⁴ Moreover, silicone rods are not incorporated into surrounding tissues, cause minimal adhesion and are easily removable in case of a

Figure 2 A 20-year-old woman with chronic progressive external ophthalmoplegia and bilateral ptosis. (A) Preoperative appearance with a MRD of -3/-2. (B) Eighteen months after bilateral frontalis sling with silicone rod, with a MRD of +0.5/+0.5.



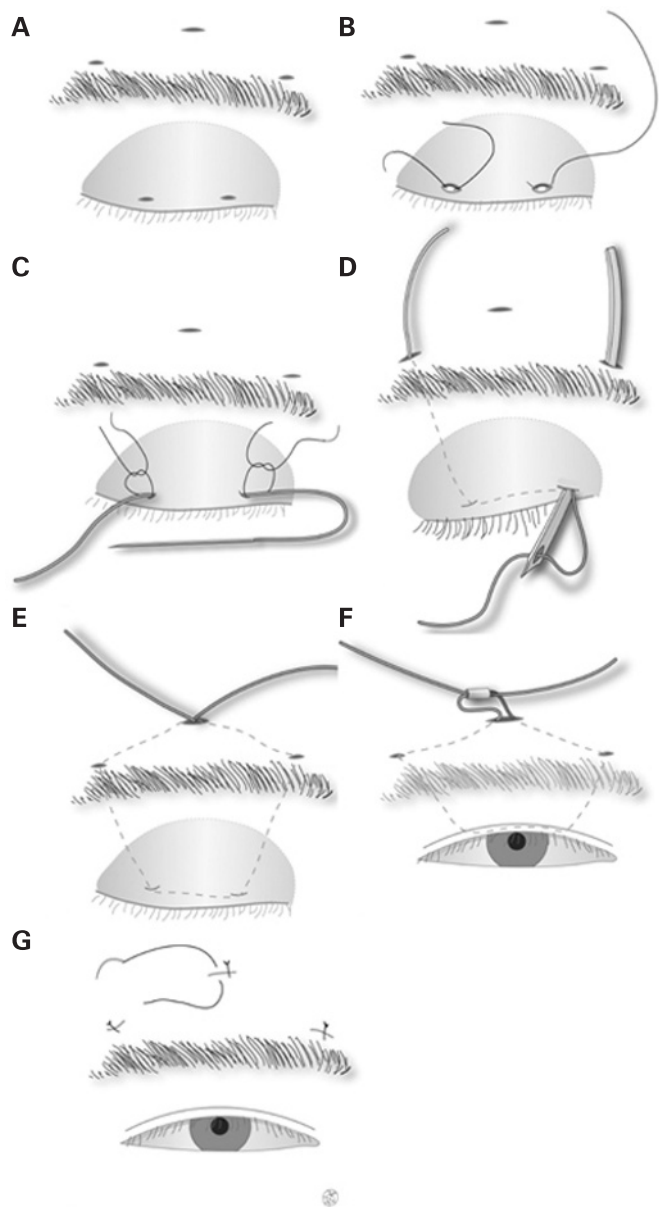


Figure 1 The frontalis sling operation using silicone rod for ptosis correction in chronic progressive external ophthalmoplegia. (A) Indication of five horizontal stab incisions, three above the eyebrow, two 3 mm above the eyelid. (B) Two 6-0 polypropylene sutures pre-placed within the stab incisions, passing the tarsal plate in partial thickness. (C) Passage of the silicone rod through the two eyelid incision sites with indication of the previously placed 6-0 polypropylene sutures. (D) Passage of the medial and lateral ends of the silicone rod through the orbital septum toward the nasal and temporal incisions. (E) Exit of both ends of the silicone rod through the central apex incision. (F) Ends of the silicone rod brought within a silicone sleeve. (G) Completion of the surgical procedure with skin closure.

revision surgery in patients with severe exposure keratopathy, which can often be expected in CPEO patients.^{8,9}

Due to reduced levator function and absent Bell's phenomenon, there is an increased risk of corneal exposure and exposure keratopathy in the correction of ptosis in CPEO.¹⁵ Previous consensus in ptosis repair for CPEO has been reluctance toward corrective surgery, with some groups recommending surgery only if the ptosis interferes with vision or causes considerable

social embarrassment.³ Half-correction is generally agreed to be the optimal correction target in CPEO.

Bernardini *et al* reported the surgical results of the frontalis sling operation using silicone rod in 16 eyes of ten patients affected by ptosis secondary to myasthenia gravis, CPEO or mitochondrial myopathy.¹⁴ All patients had severe ptosis (MRD <2 mm), poor levator function (<5 mm), poor or absent Bell's phenomenon and reduced orbicularis function. Frontalis sling using silicone rod was performed in all patients. Postoperatively, the upper eyelid margin was above the pupil in all patients and most patients were reported to be satisfied with the surgical results. Only one patient required revision surgery due to medically resistant corneal exposure. However, the exact number of CPEO patients was not specifically disclosed and we cannot know if surgical success was achieved in this group of patients.

Soejima *et al* reported a case of ptosis repair in a CPEO patient using combination of blepharoplasty and frontalis sling using monofilament suture.¹⁰ The upper eyelid margin stayed above the pupil 9 months postoperatively and exposure keratitis was managed effectively with artificial tear ointment applied at night. Since blepharoplasty was performed in addition to the frontalis sling procedure the efficacy of the frontalis sling procedure alone in correcting ptosis cannot be determined for certain. Additionally, higher rates of ptosis recurrence and complications such as suture granulomas have been reported with the use of monofilament sutures and the employment of this suspension material may be an additional limiting factor in this case report.^{8,16}

Conversely, Daut *et al* have reported cases of chronic exposure keratopathy following ptosis surgery in CPEO patients.¹¹ Each presented with chronic corneal ulceration and one patient subsequently underwent penetrating keratoplasty due to failure in response to medical therapy. The authors stress the importance of close clinical follow-up and careful discussion of the potential risks and benefits of the procedure with the patient. However, the type of ptosis surgery performed in these patients is not specified and the fact that corneal complications may have arisen due to the inadequate choice of ptosis surgery type is overlooked.

We agree that heed should always be taken since the clinical characteristics of these patients place them at a greater risk of severe exposure keratopathy. However all patients in our study were able to achieve optimal lid height without major corneal complications with the frontalis sling procedure using silicone rod, and none required revision surgery. Analysis between the MRD and corneal exposure incidence shows no specific correlation and factors such as lid elasticity or patient compliance in lubricant application may have played a role, showing that MRD alone is not responsible for the development of corneal complications.

We believe this procedure to be the operation of choice in correcting ptosis in chronic progressive external ophthalmoplegia patients. In conclusion, the frontalis sling operation using silicone rod can safely and effectively correct ptosis in chronic progressive external ophthalmoplegia patients without serious corneal complications.

Funding: None.

Competing interests: None.

Ethics approval: The study was approved by the institutional review board and adhered to the tenets of the Declaration of Helsinki.

Patient consent: Obtained.

REFERENCES

1. **Danta G**, Hilton RC, Lynch PG. Chronic progressive external ophthalmoplegia. *Brain* 1975;**98**:473–92.
2. **Eshaghian J**, Anderson R, *et al*. Orbicularis oculi muscle in chronic progressive external ophthalmoplegia. *Arch Ophthalmol* 1980;**98**:1070–3.
3. **Lane CM**, Collin JR. Treatment of ptosis in chronic progressive external ophthalmoplegia. *Br J Ophthalmol* 1987;**71**:290–4.
4. **Crawford JS**. Frontalis sling operation. *J Pediatr Ophthalmol Strabismus* 1982;**19**:253–5.
5. **Oh JY**, Kim C, Chung HK, *et al*. Frontalis sling operation using silicone rod in congenital blepharoptosis patients. *J Korean Ophthalmol Soc* 2005;**46**:573–80.
6. **Rowan PJ**, Hayes GS. Silicone sling for ptosis. *South Med J* 1977;**70**:68–9.
7. **Leone CR Jr**, Shore JW, Van Gemert JV. Silicone rod frontalis sling for the correction of blepharoptosis. *Ophthalmic Surg* 1981;**12**:881–7.
8. **Carter SR**, Meecham WJ, Seiff SR. Silicone frontalis sling for the correction of blepharoptosis. *Ophthalmology* 1996;**103**:623–30.
9. **Older JJ**, Dunne PB. Silicone slings for the correction of ptosis associated with progressive external ophthalmoplegia. *Ophthalmic Surg* 1984;**15**:379–81.
10. **Soejima K**, Sakurai H, Nozaki M, *et al*. Surgical treatment of blepharoptosis caused by chronic progressive external ophthalmoplegia. *Ann Plast Surg* 2006;**56**:439–42.
11. **Daut PM**, Steinemann TL, Westfall CT. Chronic exposure keratopathy complicating surgical correction of ptosis in patients with chronic progressive external ophthalmoplegia. *Am J Ophthalmol* 2000;**130**:519–21.
12. **Miller NR**. Myopathies and disorders of neuromuscular transmission. In: *Walsh and Hoyt's clinical neuro-ophthalmology*. 4th edn. Philadelphia: Williams and Wilkins, 1985:785–852.
13. **Ben Simon GJ**, Macedo AA, Schwarcz RM, *et al*. Frontalis suspension for upper eyelid ptosis: evaluation of different surgical designs and suture material. *Am J Ophthalmol* 2005;**140**:877–85.
14. **Bernardini FP**, Concillio C, Devoto MH. Frontalis suspension sling using a silicone rod in patients affected by myogenic blepharoptosis. *Orbit* 2002;**21**:195–8.
15. **De Wilde F**, D'Haens M, Smet H, *et al*. Surgical treatment of myogenic blepharoptosis. *Bull Soc Belge Ophthalmol* 1995;**225**:139.
16. **Wasserman B**, Sprunger DT, Helveston EM. Comparison of materials used in frontalis suspension. *Arch Ophthalmol* 2001;**119**:687–91.