The Seoul Journal of Medicine
Vol. 29, No. 3:305-314, September 1988

An Early Human Fetus (9 Weeks)

Je G. Chi and Jong Ho Ahn

Department of Pathology, College of Medicine, Seoul National University, Seoul 110-460, Korea

= Abstract =A human fetus was obtained from an adnexectomy specimen of a 36-year-old woman. The fetus was serially sectioned and studied with regard to its developmental status. The developmental characteristics of the organs were well correlated with those of the fetus of 9 weeks of fertilization age.

The specimen was 43 mm in crown-rump length and 5.6 grams in weight.

Key words: ***Fetus, Development***

INTRODUCTION

In the study of human embryo and early fetus one can find difficulty in determining the age of the specimen, because the last menstrual period of the mother is not specific for the precise date of fertilization and because specimens of the same age do not necessarily show the same developmental features. Therefore Streeter introduced the concept of the developmental stage, the idea that the age of an embryo be correlated with the development of the internal organs. Streeter stage XXIII is the last stage of development as an embryo and corresponds to 8 weeks of gestational age. Although the end of the 8th week is the cut off point between embryo and fetus, the early fetus is not very different from the late embryo. In this study we describe the transitional features of the embryo into the fetus.

CASE REPORT

A 36 year old woman had right adnexectomy at Seoul National Unviersity Hospital on February 3, 1986, because of an ectopic gestation. The fetus was found in the salpingectomy specimen, intact in the ovisac. It measured 43 mm in crown-rump length and weighed 5.6 grams after fixation in 10% formalin. The specimen was then embedded in paraffin, sectioned sagittally to obtain 161 slides in 4 μm thickness and stained with hematoxylin and eosin (Plate 1).

External Appearance : The head is round and the organs of the head, i.e. eyes, nose, ears and mouth, are well developed. The markings of the rib cage are seen on the surface. The extremities show not only the prominent digital rays, but also bendings at the knee and the elbow. Hands are placed in front of the sternum and the feet at the level of the umbilicus (Fig. 1, Plate 2).

Respiratory system : The right lung is divided into 3 lobes and the left lung into 2 lobes. The cartilages are developed from the larynx to the stem bronchi. The changes of the epithelial lining of the tracheobronchial tube system enable us to classify them into 2 parts; the proximal part lined with the pseudostratified ciliated columnar epithelium with subnuclear vacuoles; the distal part of the simple columnar epithelium with subnuclear and supranuclear vacuoles. The mesenchyme of the lung shows peritubular condensation, but there is no evidence of lobulation or the formation of alveoli (Plate 3).

Cardiovascular system : The heart is composed of 4 chambers. The ventricles are located anteroinferior to the atria. The right and left ventricles are completely separated from each other, but the atria communicate through the defect in the interatrial septum. The right ventricle, located in front of the left ventricle, is connected to the right atrium and the pulmonary trunk, which is again connected to the smaller pulmon-

Received 23/6/88; revised 29/8/88; accepted 2/9/88

Fig. 1. Schematic reconstruction of the fetus in this report. Thet number represents the number of section slide.

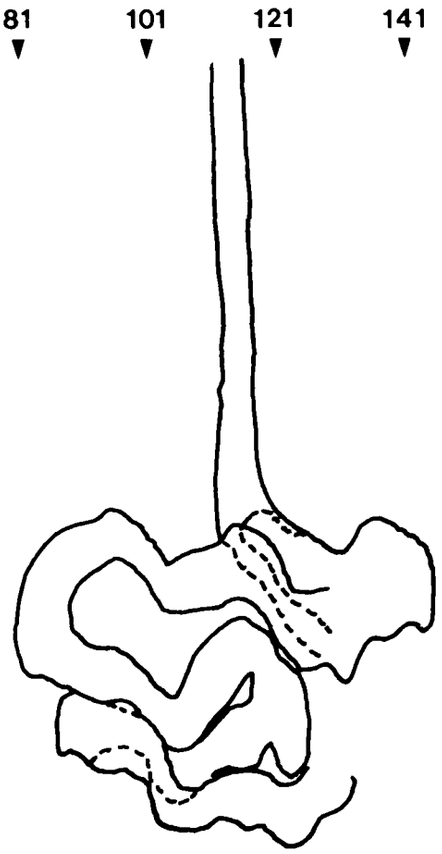

Fig. 2. Schematic reconstruction of digestive system of the fetus.

ary arteries and the larger ductus arteriosus. The left ventricle is connected to the left atrium and the aorta. Two groups of cells are found in the heart; one group with relatively clear cytoplasm, distributed mainly in the valve area and the descendent of the endocardial cushion; others with eosinophilic fibrils and intracytoplasmic vacuoles, distributed in the wall of the heart. The myocardial cells show striation.

Digestive system : The digestive system presents the left-sided stomach, duodenal C-loop, loops of the small intestine and anorectal canal with perforated anal membrane (Fig. 2, Plate 4). In the histologic study the epithelium of the digestive tract shows gradual changes that can be arbitrarily divided into 3 parts: from the pharynx to the esophagus of the stratified epithelium with subnuclear vacuoles; the stomach of the tall columnar cells; from the pyloric part of the stomach to the entrance of physiologically herniated intestine, lined by columnar cells with subnuclear and supranuclear vaculoes; the physiologically herniated intestine of high cellularity; from the end of physiologically herniated part to the sigmoid colon lined by columnar epithelium with vertically elongated nuclei; anorectal canal lined by the epithelium of indefinable type. Most of the herniated intestine return to the peritoneal cavity, leaving the transional part between small and larege intestine still herniated.

The pancreas is located within the duodenal C-loop. The dorsal and the ventral parts are completely fused. Definite acini and ducts are identified (Plate 5). However, the islets of Langerhans are not identified.

The parenchyme of the liver is composed of

cell cords with large euchromatic nuclei and sinusoids with prominent hematopoietic features (Plate 6). The bile passage presents the common hepatic duct, the cystic duct, the common bile duct of simple cuboidal epithelium.

Urogenital system : The parenchyme of the kidney can be divided into 2 parts; the outer part of immature structure and the inner part of well-differentiated large glomeruli and tubules of eosinophilic cells (Plate 7). The ureters run from the renal pelvis to the urinary bladder retroperitoneally.

The mesonephros contains some glomeruli and the mesonephric duct runs from the remnant of the mesonephros to the urinary bladder. The right and left mesonephric ducts join in the midline before they open into the urinary bladder. the paramesonephric ducts begin in the lateral side of the mesonephroi, run anterior to the mesonephric ducts and end blindly. The gonads are located anteromedially to the mesonephroi and show large sex cord cells with mesenchymal cells forming fibrous septa between the sex cord cells (Plate 8). There is a suggestive formation of tunica albuginea showing condensation of spindle cells in parallel to the surface. The sex cords are arranged to the direction of future seminiferous tubule formation and oriented radially from the hilus of the gonad. These findings are quite contrast from ovarian differentiation of the same age where pregranulosa cells surround primitive germ cells. There is a definite phallic process through which urethral passage is observed.

The urorectal septum descended completely and the urogenital membrane has been ruptured (Plate 4).

Central nervous system : The diverticulization and the formation of flexures is normally developed. There are zonal differentiations in the telencephalon; ventricular, subventricular, intermediate, and marginal zones and the cortical plate (Plate 9). In the ventral area of the cerebrum there are well-developed corpora striata.

The cerebellum shows nothing but a dispersed cell mass coated with the band area of high cellularity.

The pineal gland is a round solid nest of undifferentiated cells in the roof of pineal diverticulization of the 3rd venticle (Plate 10).

In the pituitary gland the lumen of the Rathke's pouch remains. The histologic findings show undifferentiated cells, cells with eosinophilic cytoplasm, and chromophobic cells (Plate 11).

The optic cup shows an inner layer of increased cellularity, composed of highly cellular, less cellular, and acellular areas, and the outer layer with high content of granular pigments and blood vessels. The lumen of the lens vesicle is obliterated. The cornea consists of the endothelial layer, the epithelial layer and the substantia propria of 15-cell-thickness, and is continuous with the sclera (Plate 12). The posterior part of the tunica vasculosa lentis is formed by the hyaloid artery. The cochlea make two and a half turns (Plate 13).

Other organs : The thyroid gland shows some early but definite follicles with lumen, well developed cell cords, and vasculature (Plate 14).

The thymus is located from the 6th tracheal ring to the upper border of the heart. Any notable microscopic feature is not detected except the cellular aggregations.

The submandibular gland shows long ducts, many branches and lumina deep in glands (Plate 15).

The adrenal glands are cell masses of the kidney size, composed of the primordium of the permanent cortex, the fetal cortex and infiltrating nests of cells of dense nuclei (Plate 6). The scattered nests of dark cells represented neuroblastic cells to form the adrenal medulla.

The spleen is located posterolateral to the stomach and connected to the tail of the pancreas. There is nothing special except cellular aggregations.

The bony trabeculae and the bone marrow formation are detected in the clavicle, the humerus and the femur. The osseous bands are also well-developed (Plate 17).

DISCUSSION

We have tried to estimate the age of the specimen with the crown-rump length and the developmental status of the lung, intestine, thyroid and femur.

At 56 days after fertilization the reference range of crown-rump length of normal embryo is 27.0-31.0 mm. The average of the crown-rump length of 9-week-old fetuses falls on 50 mm and that of 10-week-old fetuses on 61 mm

(Moore 1982). The crown rump length of this specimen is 43 mm after fixation with 10% formalin and can be estimated to be 45.3-47.8 mm before fixation, considering the retraction of specimen by 5-10% during the process of fixation, which is compatible with 9 week old fetus. In the histologic findings of the lung the embryo of 8 weeks shows the tubules of the pseudostratified epithelium and cartilages in the stem-bronchi, and the fetus of 9 to 12 weeks show the glandular appearance and the serial changes of the epithelium of the tubules. This specimen is compatible with the fetus of 9 to 12 weeks.

During the 6th week the elongated intestinal loops begin to herniate into the umbilical cord. In the 8th week most of the small and large bowels are herniated. In the 9th week the herniated intestine returns to the peritoneal cavity but the terminal ileum and cecum are still herniated. The herniated intestine returns fully to the abdominal cavity in 10th week. The degree of herniation in this specimen is compatible also with 9 weeks fetus (Suh 1988).

In the development of the thyroid the embryo of 8 weeks shows the cell cords with subnuclear vacuoles and lacunae, but still no follicles (Suh *et al* 1975). The fetus of 9 weeks shows the primitive follicles with the lumen occasionally. The fetus of 10 weeks shows the mixture of the primitive follicles and the cell cords and much increased vascularity than before. Therefore one can presume that the thyroid morphology of this fetus is also compatible with 9 weeks of gestation. In the histologic findings of the femur Suh *et al.* described that the embryo of 8 weeks showed the primary bony collar and the elongated cartilage model, whereas the fetus of 9 weeks showed a primary ossification center and endochondral ossification. The fetus of 10 weeks showed the femur of adult shape. This specimen is compatible with the fetus of 9 weeks. All of the above observations lead us to conclude that this specimen has definitely beyond the range of the embryo, and is very early fetus, probably 9 weeks of age.

Based on the observation that the gonad shows tunica albuginea and the radial arrangement of sex cord cells, the mesonephric ducts open into urogenital sinus, and the paramesonephric duct ends blindly, with finding of a phallic prominence through which the urethral passage is running, we determined that the fetus is male.

REFERENCES

Chi JG, Yoon AY. A human embryo of Streeter Age Group XIII. Seoul J. Med. 1984, 25(2):261-270

Lee HJ, Chi JG, Ko KW. Morphologic development of the human fetal lung. Seoul J. Med. 1986, 27(1):-75-90

Moore KL. The Development Human, clinically oriented, 3rd ed., Saunders, Philadelhia, 1982

Sadler TW. Langman's medical embryology, 5th ed., Wiliams & Wilkins, Baltimore, 1985.

Streeter GL. Developmental horizon in Human Embryos. Description of age group XIX, XX, XXI, XXII and XXIII, being the fifth issue of a survey of the Carnegie Collection. Contrib. to Embryology, 1948, 32:165-196

Suh EH, Park SH, Chi JG. Histologic Observations on Human Thyroid. Kor. J. Path. 1975, 19:27-36

Suh YL. Morphologic Observation on the Prenatal Development of the Human Gastrointestinal Tract. Ph. D. thesis Seoul National University, 1988

Suh YL, Chi JG. Morphologic Observation on the prenatal Development of Human Femur, K. J. Path. 1985, 19:377-390

= 국문초록 =

초기태아(9주)의 연속절편 관찰

서울대학교 의과대학 병리학교실

지제근 · 안종호

저자들은 36세 여자의 우측 난소 난관 적출표본에서 태아를 관찰하고 이를 시상면에 평행하게 4 μm 두께의 연속 종단 절편 161매를 만든다음, Hematoxylin and Eosin 염색을 하여 관찰한 결과 본 태아가 9주에 해당한다고 판단되는 바 이를 기술한다.

본 태아는 10% 포르말린에 고정한후의 정둔장이 43 mm이었고 무게는 5.6 gram이었다.

LEGENDS FOR PLATES

Plate 1. The photograph of a sagittal section of the fetus (Slide #110).
Plate 2. The gross appearance of the fetus.
Plate 3. The lung (Slide #100 ×100).
Plate 4. The anorectal canal (A), theurogenital sinus (Us) andthe mesonephric duct (Md) (Slide ×79 ×100)
Plate 5. The pancreas (Slide #79 ×100).
Plate 6. The liver (Slide #127 ×200).
Plate 7. The kidney (Slide #119 ×100).
Plate 8. The gonad (G), the mesonephric duct (Md) andthe paramesonephric duct (Pd) (Slide #97 ×100).
Plate 9. The cerebral cortex (Slie #78 ×100).
Plate 10. The pineal gland (Slide #106 ×200).
Plate 11. The pituitary gland (Slide #116 ×100).
Plate 12. The cornea (Slide #66 ×250).
Plate 13. The cochlea (Slide #88 ×40).
Plate 14. the thyroid (Slide #123 ×200).
Plate 15. The submandibular gland (Slide #96 ×100).
Plate 16. The adrenal gland (Slide #76 ×100).
Plate 17. The humers (Slide #6 ×100).

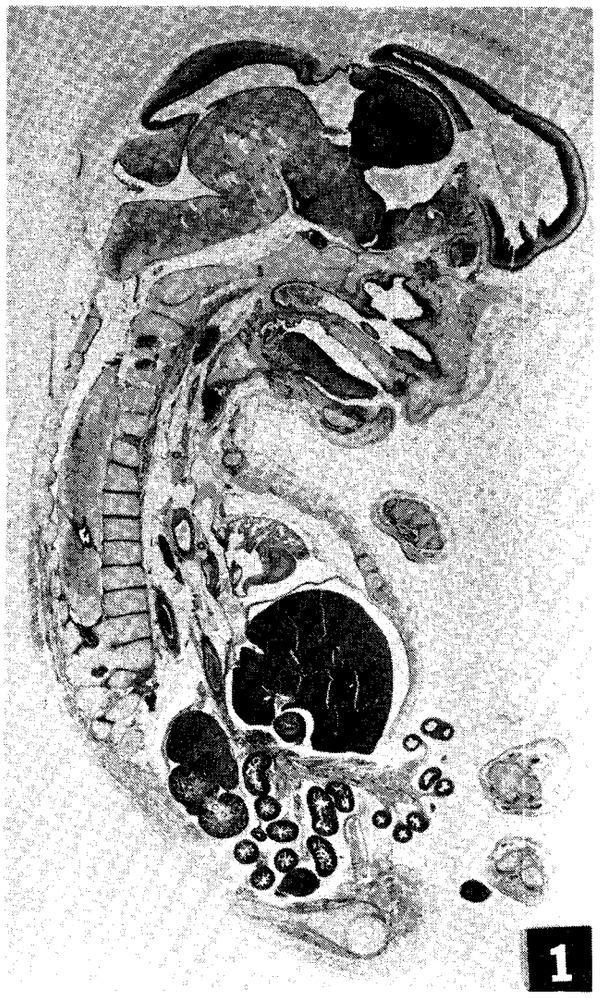
1

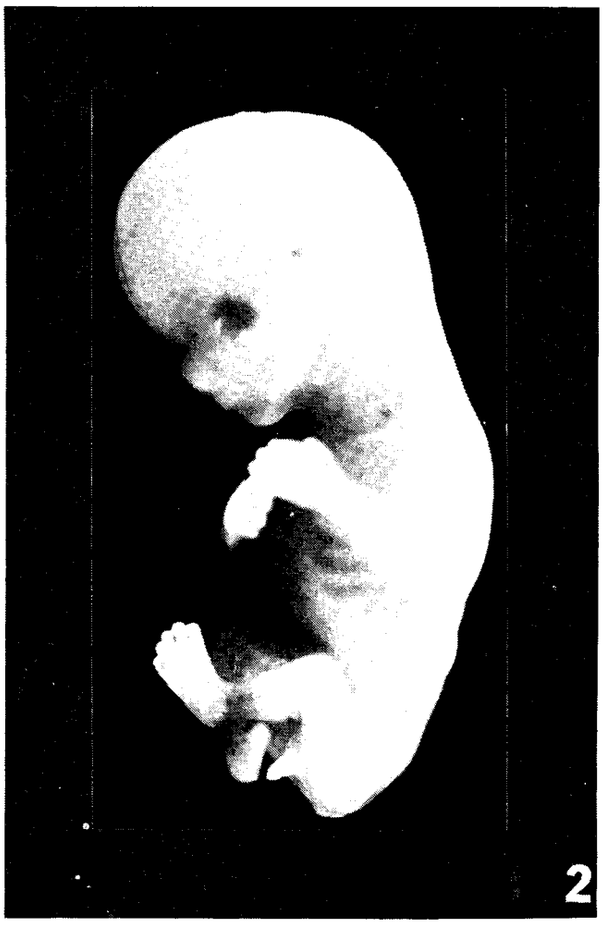
2

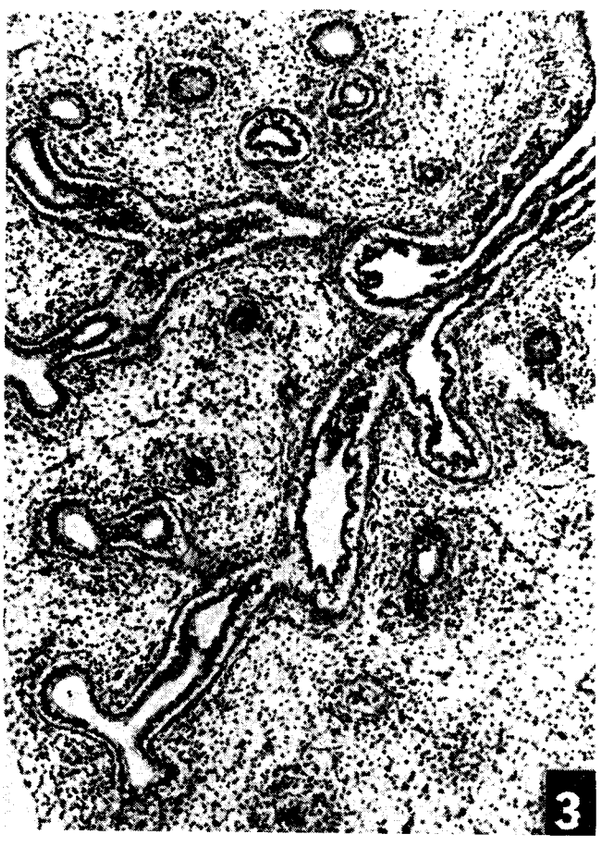
3

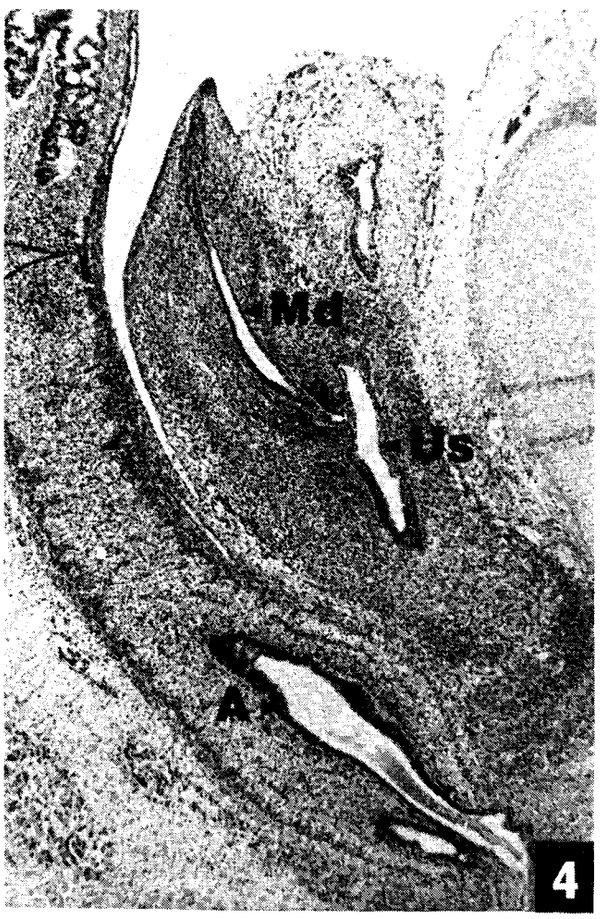
Md
Us
4

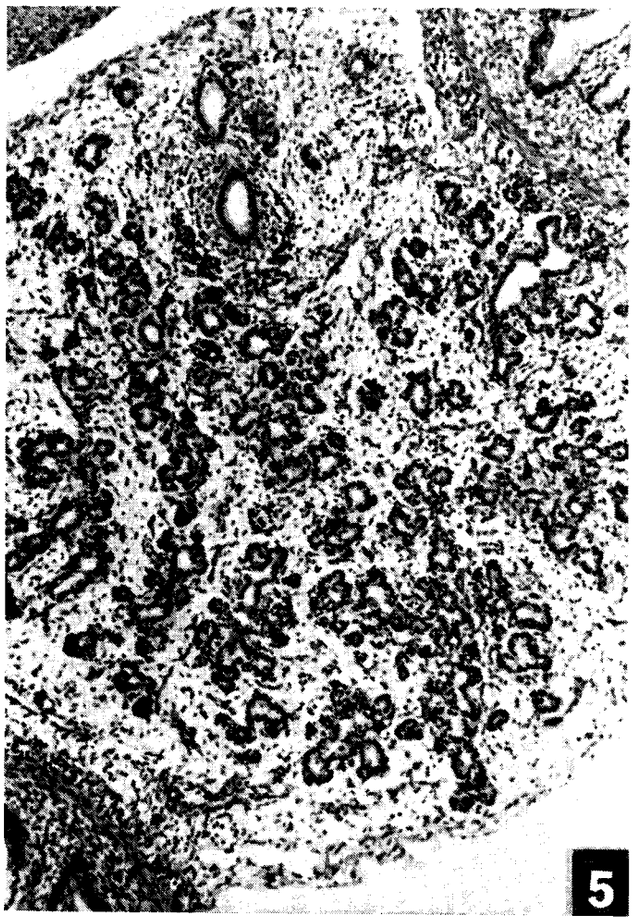
5

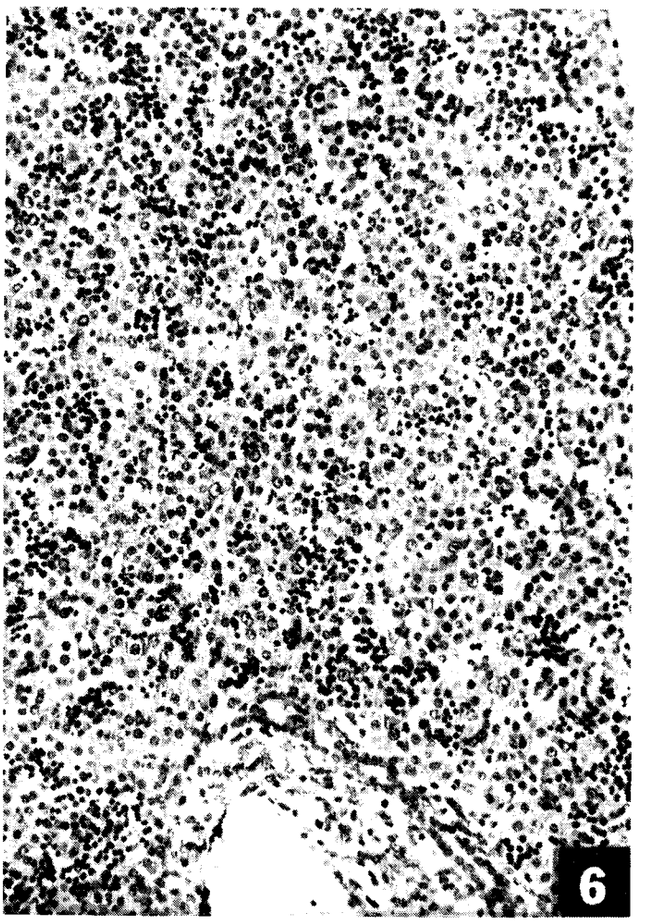
6


7


Pd
Md
8


9


10


11

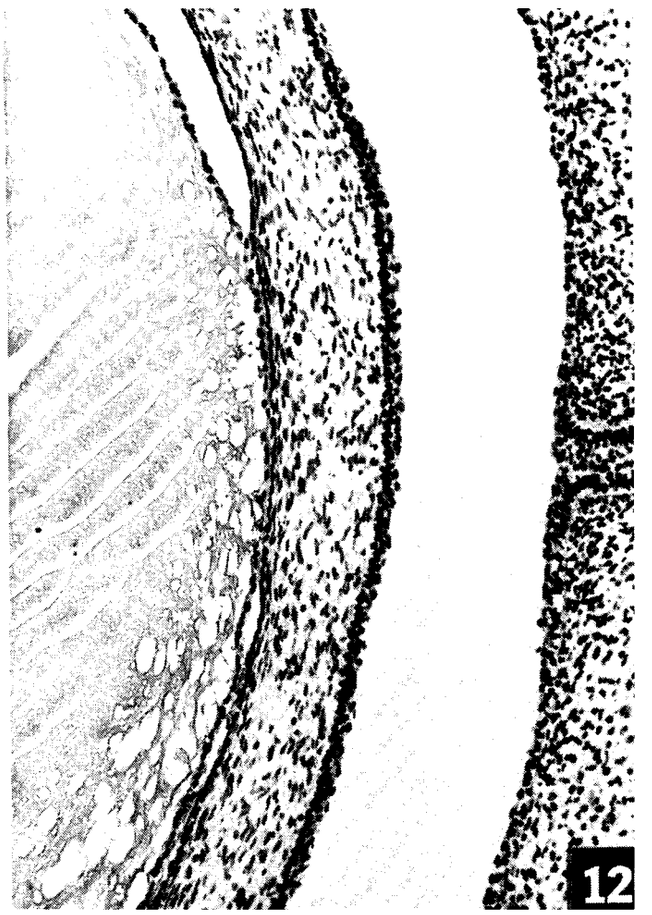
12


13

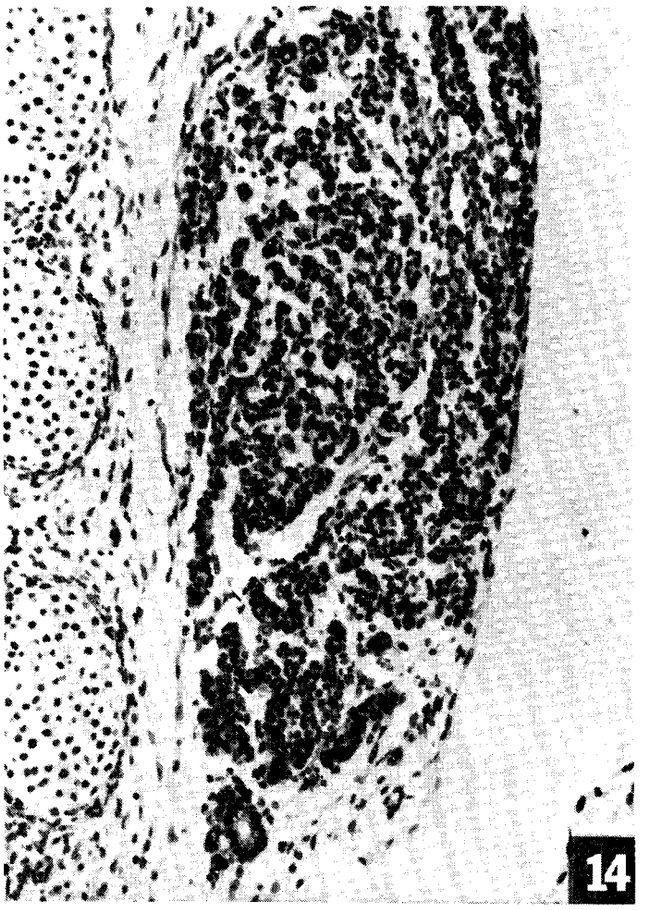
14

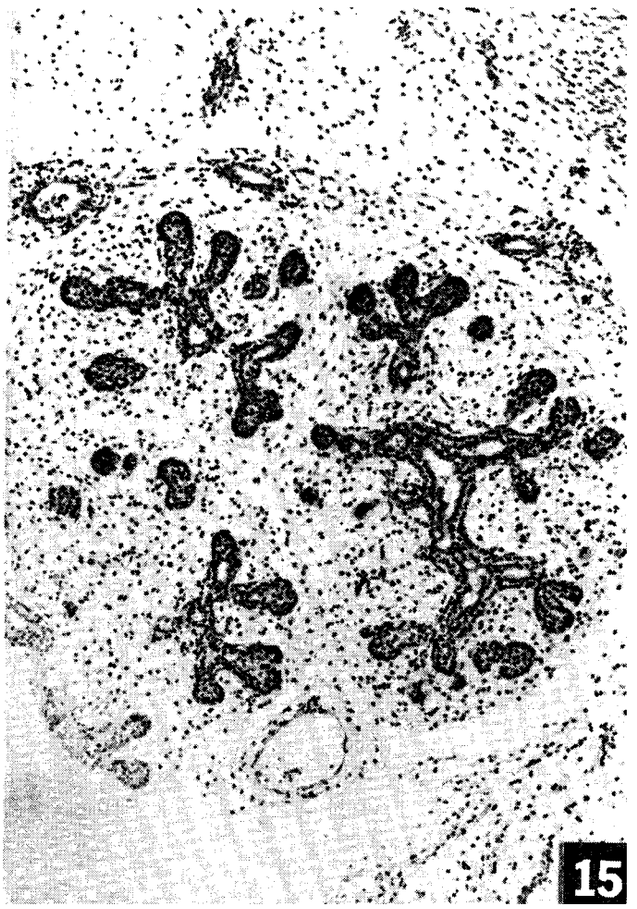
15

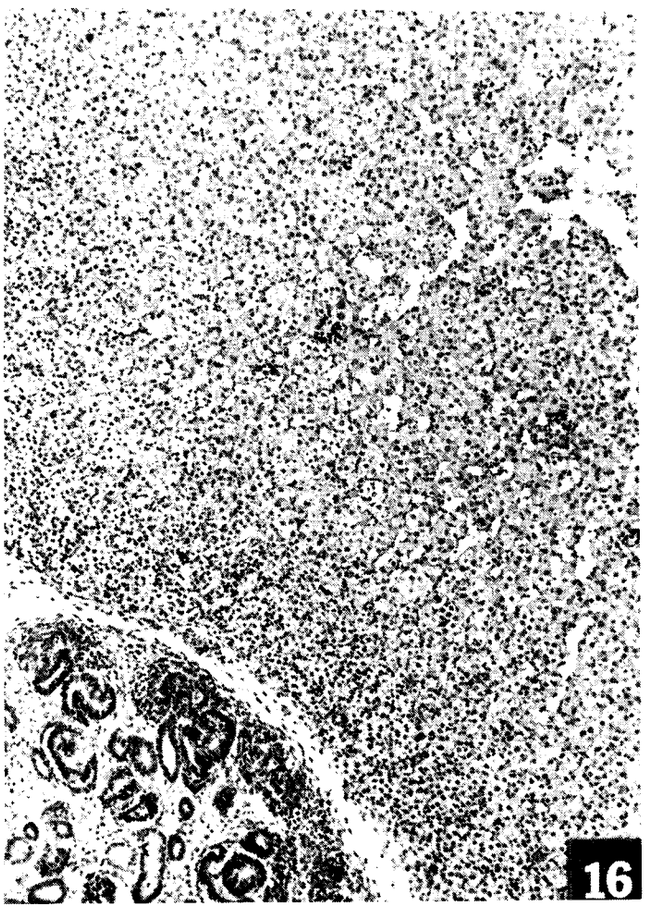
16

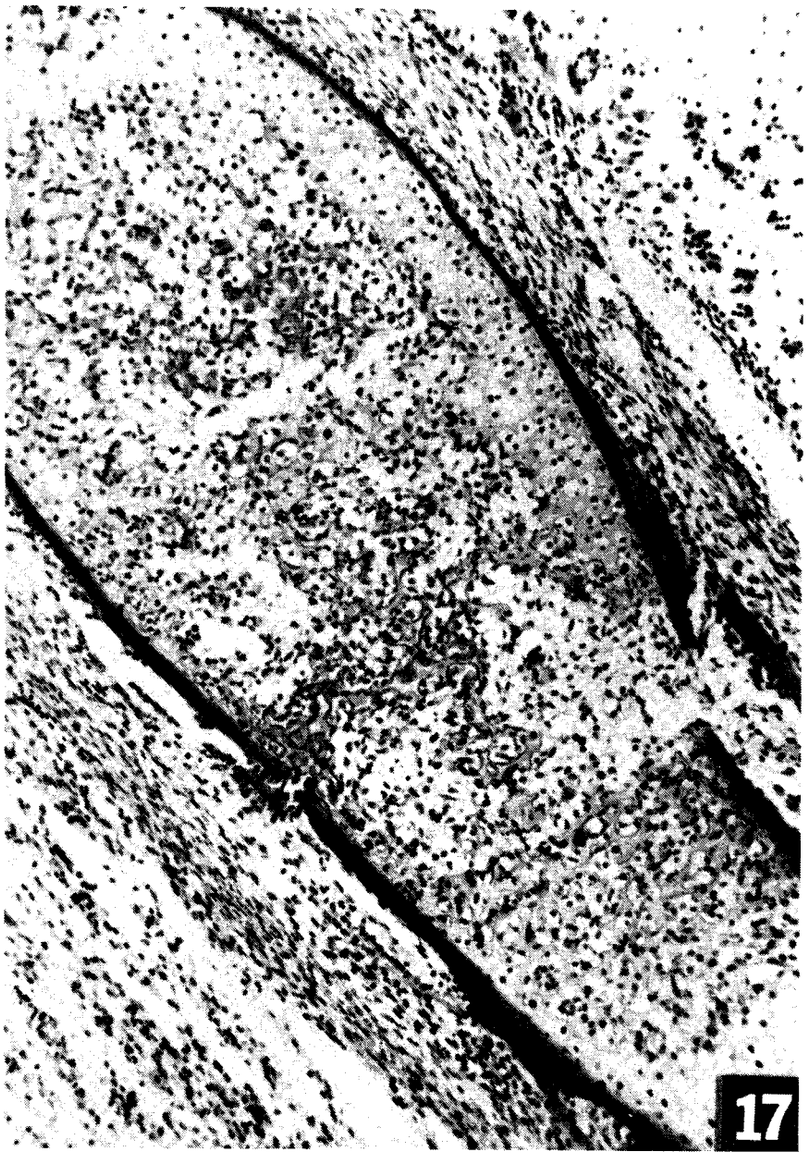
17