

## Exencephalus Found in A Human Embryo

Je G. Chi\* and Young Wan Moon

*Department of Pathology, Seoul National University Children's Hospital and College of Medicine,  
Seoul National University, Seoul 110, Korea*

**= Abstract =** An exencephalic embryo was incidentally found in a hysterectomy specimen. It was studied morphologically based on serial sections of the embryo. The embryo was clearly exencephalic showing herniated brain without cranial coverage. Interestingly, remaining brain tissue was morphologically normal although direct continuity of ependyma with skin was identified. These findings are strongly suggestive of the hypothesis that exencephaly is a variant of anencephaly, the only difference being the magnitude of remaining brain tissue in acranic head. There were no associated anomalies in this embryo except for a small intestinal diverticulum. The remainder of the tissue was compatible with Streeter age group XXI.

**Key words:** *Exencephaly, Anencephaly, Embryo*

### INTRODUCTION

Exencephalus is usually defined as an abnormal development of the cranium and brain in which all or part of the lesion is situated outside the skull (Emery and Kalhan 1970). The amount and degree of organization of the exposed brain tissue vary greatly in different cases. Sometimes the distinction of exencephaly from anencephaly is very difficult. In fact there are many authors who advocate that these two conditions are basically the same differing only in degree of involvement (Emery and Kalhan 1970; Ko *et al.* 1987). In this regard, morphological study of the neural tube defect detected during the intrauterine period is very important to elucidate the interrelationship of these anomalies.

This report deals with a case of exencephaly found in a hysterectomized specimen, that showed relatively intact structure of the exposed portion, suggestive of an early stage of neural tube defect which might eventually and potentially terminate as anencephaly.

### CASE REPORT

An embryo (C82-131) was incidentally found in the hysterectomized specimen at Chung-Ang Hospital, Seoul, and was sent to the Department of Pathology of Seoul National University for examination. No other details of the clinical findings in this case were available. This specimen was already fixed in formalin when received. The embryo was then embedded in paraffin, sectioned sagittally in 7  $\mu$ m thickness, and stained with hematoxylin and eosin.

#### 1. External Appearance

The embryo was 18 mm in CR length and an abnormal mass was extruding from the right side of the head without any coverage. In the cephalic portion the eyelid was formed and the oral cavity opened. The nasal prominence was seen. The forelimb had extended ventrally, covering the thorax and the hand plate had separated fingers. The hind limb had also extended ventrally, the soles of the feet facing medially and the foot plate had webbed toes. In the abdominal region was a large prominence due to the liver and the intestinal loop herniated into the umbilical cord. The remnant of the tail fold was persistent at the caudal end (Plate 1,2,3).

---

\* Author for correspondence

## 2. The Central Nervous System

On the right side of the head, a single layer of ependymal cells kept continuity with the skin of the future forehead. Posteriorly a mass of brain tissue was extruding and curving to the left and downward in front of the forehead (Plate 4). The herniating brain was composed of four histologically distinct layers, which were ependymal, mantle, marginal, and meningeal layers, and had two ventricle-like cavities which were lined by the ependymal layer (Plate 4,5). There was no skin overlying the brain. The upper one was like a lateral ventricle and the lower one resembled the 4th ventricle (Plate 4). On the left side of the head, choroid plexus-like structures lined by modified ependymal cells were in continuity with the future skin and there was no protruding mass of brain tissue (Plate 6). There were no definite flexures which divided the brain into telencephalon, diencephalon, mesencephalon, metencephalon and myelencephalon (Plate 4). The superior surface of the proximal part of the exposed brain tissue was lined by ependymal cells which would be ventricular lining if it were covered by a roof plate (Plate 7).

There were no definite optic chiasma, mammillary body, olfactory bulb and pineal gland observed. The hypophysis revealed no pars neuralis but only proliferating anterior lobes which was being invaded by vessels and a thread-like remnant of persisting Rathke's pouch passing through the sphenoid bone (Plate 8). The optic nerve was not connected to the brain and had an ependymal remnant at its proximal part. At the midline of the eye, the cornea was composed of a compact mesodermal sheet, three to four cells thick (Plate 9). The cochlear duct was well developed with its lining epithelium consisting of 6 to 7 layers and its tip was turning down for the second time (Plate 10). The vestibular and trigeminal ganglia were located at the anterior part of semicircular canals (Plate 10). Anterior to the adenohypophysis was located a U-shaped mass of ependymal cells which resembled a recessus opticus (Plate 8). The spinal cord was extended to the lowest level of the vertebral canal, the paravertebral ganglia were already formed and the nerve fibers going through the intervertebral foramen were observed.

## 3. The Cardiovascular System

The heart was composed of four chambers, the right and left atria at the posterior side, and the right and left ventricles at the anterior portion of the heart. The heart was enclosed by a pericardial sac.

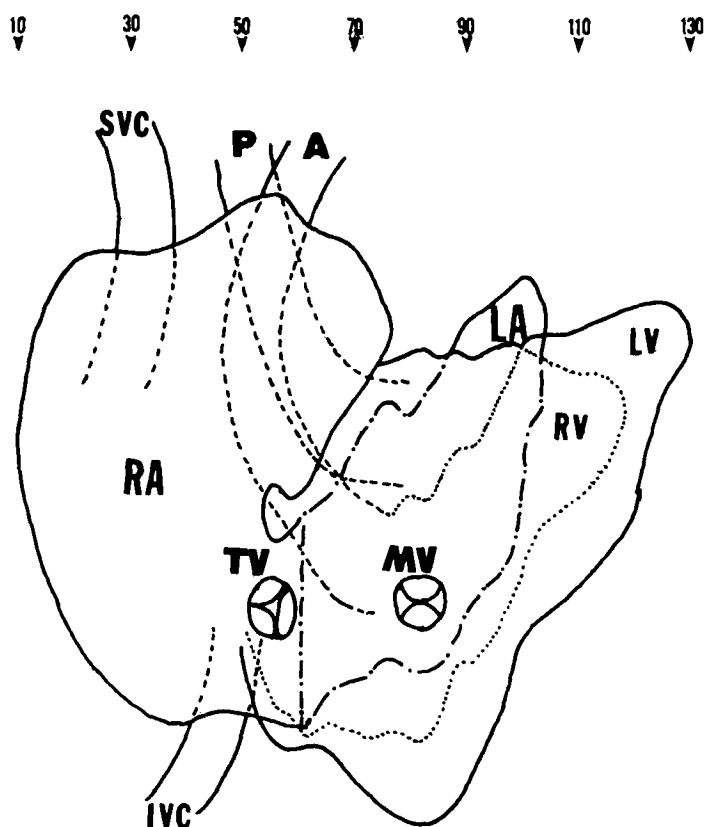


Fig. 1. Schematic reconstruction of the heart of the embryo. RA: right atrium, LA: left atrium, RV: right ventricle, LV: left ventricle, TV: tricuspid valve, SVC: superior vena cava, IVC: inferior vena cava, P: pulmonary artery, A: aorta.

The right and left ventricles were separated completely by the inter ventricular septum. There were a number of trabeculae at the inner surface of the ventricular wall, and also the cross striation were observed in the ventricular wall (Plate 12). The aorta and pulmonary artery were connected to left and right ventricles respectively, and the aortic and pulmonary valves were seen at their bases. The mitral and tricuspid valves were also found connected to the papillary muscles by the chordae tendinae (Plate 11). On the left section of the inlet of the inferior vena cava was the tricuspid valve, and the superior vena cava was found on the section to the right (Fig. 1).

## 4. The Respiratory System

The main bronchi branched out into the segmental bronchi: ten on the right and eight on the left lung, respectively (Fig. 2). The segmental bronchi continued to branch out further, so that more than four ramification were found. Although there was no definite cartilage recognized around the trachea, the condensation of the mesenchymal tissue differentiating into cartilage could be seen (Plate 13). The epithelium of the trachea and bron-

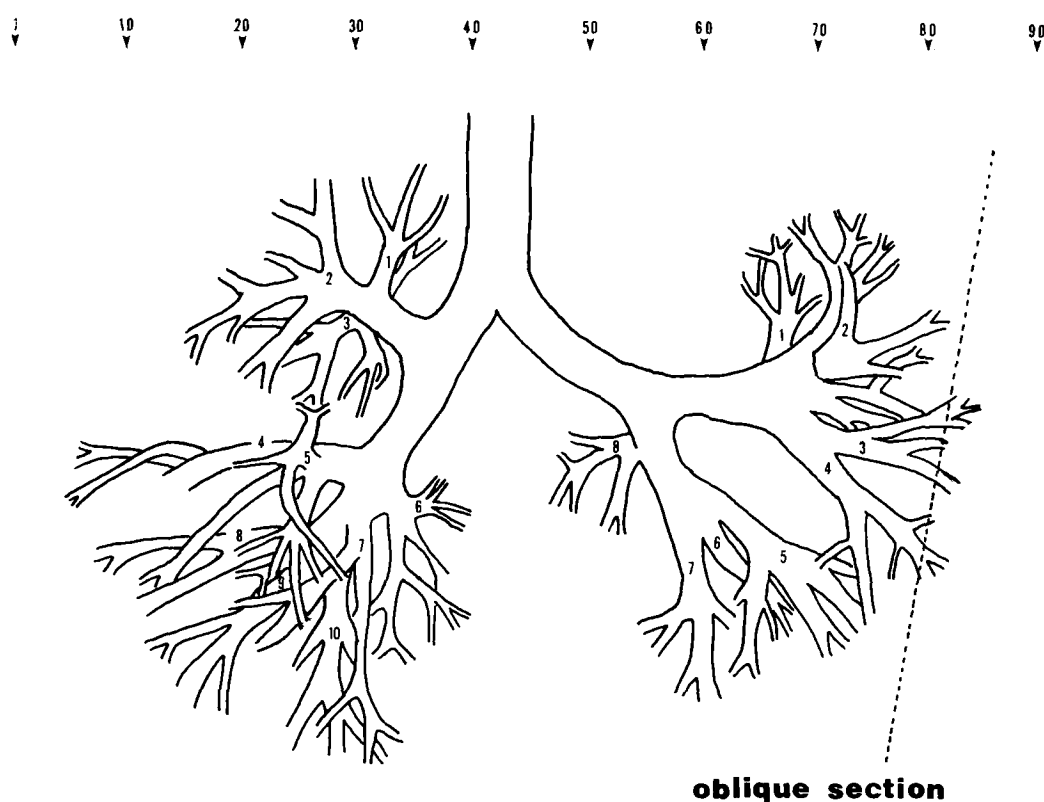


Fig. 2. Schematic reconstruction of the lungs of the embryo.

chi were lined with pseudostratified columnar epithelial cells with dark nuclei, but cilia were not found (Plate 11,13).

### 5. The Digestive System

Four layers were observed throughout the whole length of the digestive tract. At the bottom of the oral cavity, the foramen cecum was observed and the pharynx compressed dorsoventrally (Plate 14). The covering epithelium of the esophagus was in the phase of cribriform plate. The stomach was shifted to the left and rotated 90 degrees about its long axis. Along the greater curvature of the stomach the dorsal mesogastrium connected the spleen and the stomach (Plate 12). The ventral and dorsal pancreatic duct had their orifices at different parts of the duodenum (Plate 15). Unfortunately, it was impossible to recognize whether or not the common bile duct met the ventral pancreatic duct because some planes of that part were missing. The liver filled most of the abdominal cavity and was in an active hemopoietic phase. The urorectal septum descended completely in the hindgut, dividing the cloaca into the rectum and the urogenital sinus (Plate 16). The anal membrane still persisted (Plate 16). In addition to the appendix near the midgut loop, an abnormal diverticulum was observed in the hindgut (Plate 17,18, Fig. 3).

### 6. The Urogenital System

On the posterior abdominal wall, the metanephroi were observed to have spoon-shaped Bowman's capsules without large glomeruli (Plate 19). The ureters started from the metanephroi, descended along the posterior abdominal wall and finally attached to the superolateral side of the urinary bladder (Plate 16). The adrenal glands were located in the antero-superior sides (Plate 19). The mesonephric ducts started from their posterolateral portion of the mesonephroi. Crossing the ureters, they descended medially, and then opened into the medial portion of the urinary bladder postero-inferior to the ureteric buds (Fig. 4). The location of the gonads were anterior to the mesonephroi, and they had primitive medullary cords which were to be seminiferous tubules. Beneath the germinal epithelium was a conspicuous zone of young connective tissue which was the start of a layer which in the adult is called the tunica albuginea (Plate 20). The urorectal septum descended completely, and the urogenital membrane had been already ruptured (Plate 16).

### 7. Other Organs

The submandibular gland had completed the secondary branching of the duct and had a definite lumen in the oral part of the duct (Plate 21).

The notochord was still persistent at some ver-

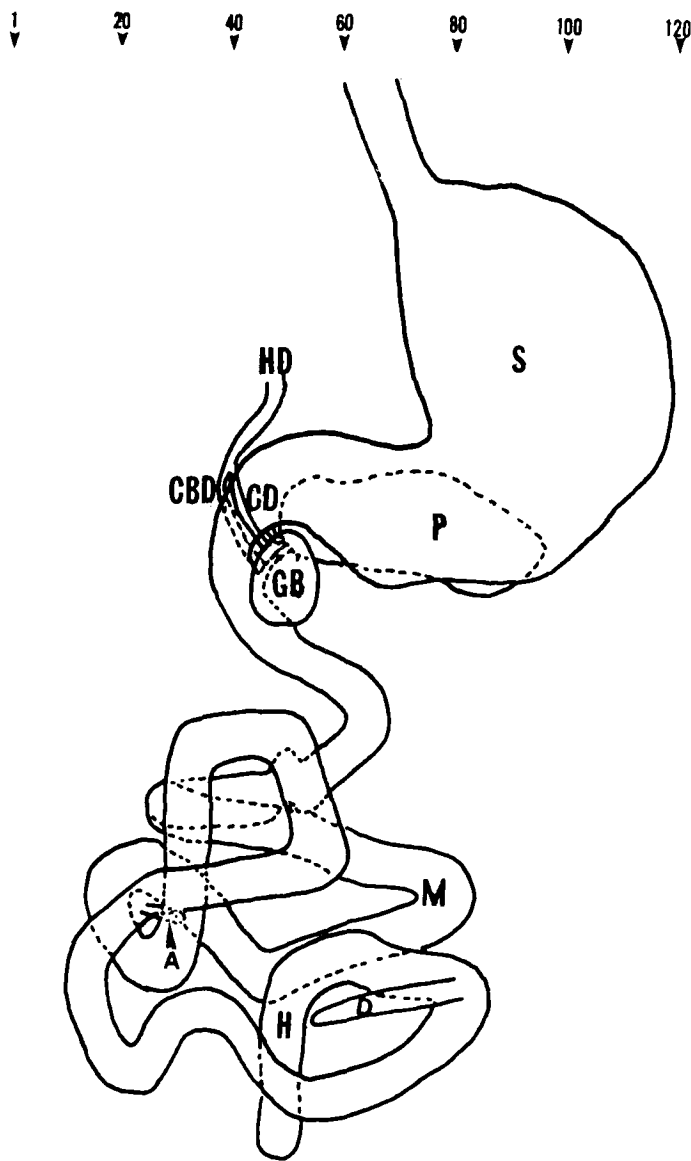


Fig. 3. Schematic reconstruction of the digestive system of the embryo. S: Stomach, M: midgut, H: hindgut, A: appendix, D: abnormal diverticulum, HD: hepatic duct, CBD: common bile duct, CD: cystic duct, GB: gallbladder, P: pancreas.

tebral bodies in the cervical and coccygeal part of the vertebral column (Plate 22).

The thyroid gland, which had grown downward from a median endodermal thickening in the floor of primitive pharynx, was observed at the level of the first five tracheal rings and in front of thyroid cartilage. The latter part was thought to be the future pyramidal lobe (Plate 13,23). The cells formed clusters, some of which had a clear zone and whose nuclei were vesicular. The thyroglossal duct had disappeared, but its original opening persisted as a vestigial pit, the foramen cecum of the tongue (Plate 14).

Below the thyroid gland was the parathyroid III

originated from the 3rd pharyngeal pouch separated from the thymus (Plate 13).

The thymic primordia were observed symmetrically below the parathyroid III, had lost their lumen and had not fused yet.

The adrenal gland was composed of mostly cortex and clusters of ganglial cells penetrating the cortex from the adjacent sympathetic ganglia (Plate 24). The inner part of the cortex was composed of compact polygonal cells with plump eosinophilic cytoplasm. Outside the provisional cortex was a zone of much less differentiated cells which constituted the so-called "permanent cortex".

The femur had not begun osteoblast formation (Plate 25).

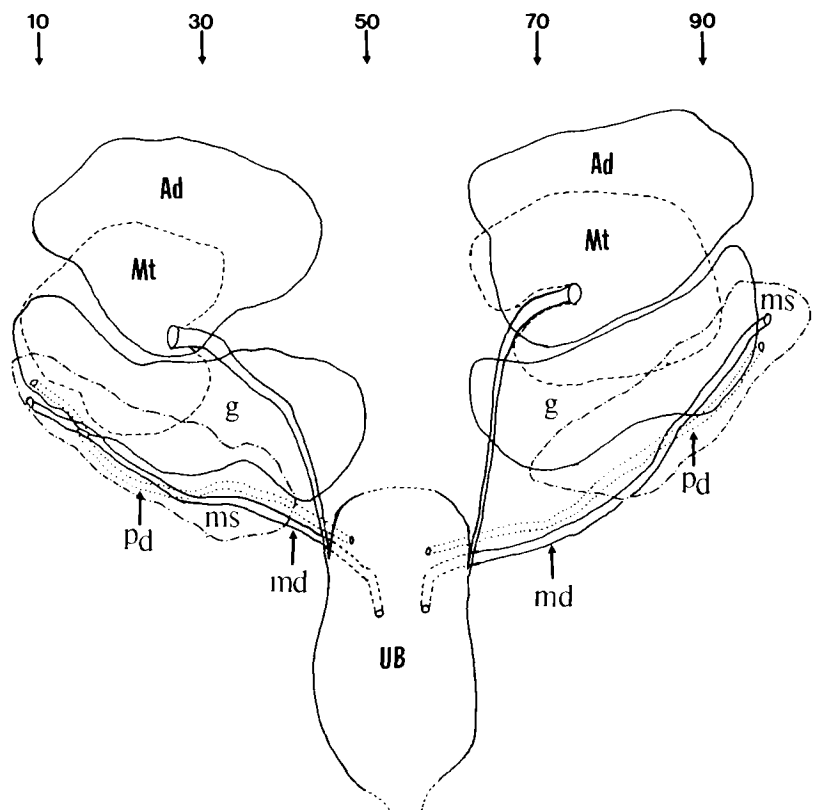
### DISCUSSION

Exencephalus is a variant of anencephaly. It probably sits morphologically between classic anencephaly and encephalocele. A significant portion of prosencephalon can be recognized in the head where vertex structure is regularly missing. Diencephalon and rhombencephalon are fairly well preserved in almost every case. Microscopically, isocortical lamination is present and cerebral vessels are relatively well developed.

In exencephaly the vault of the skull is always missing with replacement of the neural tissue by spongy amorphous mass. Owing to the exposure to amniotic fluid and possibly to the lack of protection by the skull, the neural tissue undergoes secondary degeneration in utero to produce the characteristic feature (Langman and Welch 1966; Smith and Huntington 1981). The fact that eyeball development in this embryo is normal indicates that at least up to this time of development diencephalic diverticulation is not involved. Since every case of anencephaly shows well formed eyeball including retina it is presumed that anencephaly probably results from an intrauterine encephaloclastic process. The embryo under discussion clearly supports this view.

The embryo described in this report appears to be normal except for exencephaly and a minor diverticular protrusion of the hindgut. Exencephalus is seldom associated with multiple major anomalies involving the extraneural systems. Spina bifida, cleft palate and umbilical hernia are occasionally associated with exencephalus (Emery and Kalhan 1970; Chu and Chi 1980).

Experimental neural tube defects induced with hypervitaminosis A in rats produced exencephaly,



**Fig. 4.** Schematic reconstruction of the urogenital system of the embryo.  
Ad: adrenal, Mt: metanephros, G: gonad, Ms: mesonephros, Pd: paramesonephric duct, MD: mesonephric duct, UB: urinary bladder.

anencephaly and malformations ranging from the former to the latter. Degenerative changes and necrosis were observed in many cases of exencephaly in the experiment, which suggested that exencephaly is a precursor of the anencephaly (Ko *et al* 1987). In view of this, this embryo may give valuable information on the initial malformation of anencephaly, which would not be available in anencephalic infants born at term or in older fetuses.

This is the first case report on exencephalic embryo in Korea. Case report on exencephaly at this age is not easily referred in the literature.

To determine the exact age of this embryo and to confirm the normalcy of the development of various organs and tissues, one has to use the conventional analysis method, i.e., Streeter's developmental horizon. The overall microscopic observations of this case could be summarized based on eight key organs on which was the basis for establishing the proper developmental horizon.

The cornea was composed of a compact mesodermal sheet, three to four cells thick, which coincided with the age group XXI of Streeter's develop-

mental horizon. Along the stalk of optic nerve, remnants of ependyma were present corresponding with age group XXI (Plate 10). The tip of the cochlear duct was turning down for the second time and the hypophysis had thread-like stalk in the sphenoid bone, both findings are indication that the embryo belongs to group XXI. Meanwhile the submandibular gland had definite lumen in the oral part of the duct, compatible with group XXII. The kidney had spoon-shaped Bowman's capsules without large glomeruli, the fibrous zone of the femur was not very distinct from the osteoblastic zone and the vomeronasal organ had a shallow, blind sac with reduced oral opening, all of which made the embryo appear younger than horizon XXI (Plate 26). For this, Streeter proposed criteria of developmental age group XIX to XXIII by the sum of scoring points for each key organ. We have done this, and according to this, this embryo belonged to group XXI.

**REFERENCES**

**Ballantyne JW.** Manual of anatenatal pathology and hygiene. The Edinburgh; W. Green and Sons (1904).

- Chi JG, Kim YT. A human embryo of Streeter age group XX. Seoul J. Med. 1985, 26:297-307.
- Chi JG, Lee JE, Lee HK. A human embryo of Streeter age group XXI. Seoul J. Med. 1983, 24:267-279.
- Chi, JG, Lee YI, Lee HK. A human embryo of Streeter age group XXI. Seoul J. Med. 1984, 25:623-632.
- Chu SJ, Chi JG. Exencephalus (Two autopsy cases report). The Korean J. Pathol. 1980, 14:56-61.
- Dekaban AS. Anencephaly in early human embryos. J. Neuropathol. Exp. Neurol. 1963, 22:533-548.
- Emery JL, Kalhan SC. The pathology of exencephalus. Develop. Med. Child neurol. 1970, 12:51-64.
- Forestus (1950). Cited by Emery JL and Kalhan Sc.
- Ko YC, Chi JG, Choi KS. Experimental neural tube defects induced with hypervitaminosis A in rats. Seoul J. Med. (in press).
- Langman J, Welch GW. Effect of vitamin(a) on development of the central nervous system. J. Comp. Neurol 1966, 128:1-16
- Smith MT, Huntington HW. Morphogenesis of experimental anencephaly. J. Neuropathol Exp. Neurol 1981, 40:20-31
- Streeter GL. Developmental horizon in human embryos. Description of age groups XIX. XX, XXI, XXII and XXIII, being the fifth issue of a survey of the Carnegie collection. Contrib. Embryol. 1951, 34:165-196.
- Streeter GL. Developmental horizon in human embryos. Description of age groups XV, XVI, XVII and XVIII, being the third issue of a survey of the Carnegie collection. Contrib. Embryol. 1949, 32:113-203.

= 국문초록 =

## 사람배아 (Streeter 연령군 XXI)에서 발견된 외반뇌증의 1례

서울대학교 의과대학 병리학교실

지제근 · 문영완

저자들은 자궁 척출 표본에서 외반뇌증인 배아를 우연히 발견하고 이를 시상면에 나란하게 7  $\mu$ m 두께의 연속종단절편 157매를 만든 다음 H-E 염색하여 현미경으로 관찰한 결과 두개없이 뇌가 노출된 외반뇌증이 명백하게 밝혀졌다. 흥미롭게도 본 배아는 상의층이 피부와 연속성을 가졌지만 조직학적으로는 정상 뇌발달과 유사하였다. 이러한 소견은 남아있는 뇌조직이 많다는 차이점 말고는 외반뇌증이 무뇌증의 한 변형이라는 가설을 강력히 시사해준다. 본 배아는 후장에 작은 게실이 있는것 외에는 다른 동반 기형이 없었으며 나머지 조직은 Streeter 연령군 XXI에 해당되었다.

## LEGENDS FOR PLATES

- Plate 1.** Gross appearance of the embryo, right lateral view. The embryo is 18 mm in CR length and has his toes separated.
- Plate 2.** Gross appearance of the embryo, left lateral view. The remnant of the tail fold is presistent at the caudal end.
- Plate 3.** Gross appearance of the embryo, posterior view. An abnormal mass is extruding from the right side of the head.
- Plate 4.** A mass of extruding brain tissue with two ventricle-like cavities. The arrow indicates a single layer of ependymal cells keeping continuity with the future skin. X2.5 (#21)
- Plate 5.** Four histologically distinct layers of brain; ependymal, mantle, marginal and meningeal layers. X25 (#40)
- Plate 6.** Choroid plexus-like structures in continuity with the future skin on the left side of the head. The arrow heads indicates the junction between the former and the latter. X10 (#21)
- Plate 7.** The proximal part of the exposed brain tissue. The arrow head indicates the ependymal layer. X5 (#21)
- Plate 8.** The adenohypophysis (AH). The upper arrow indicates a U-shaped mass of ependymal cells. The lower one indicates a thread-like remnant of Rathke's pouch.
- Plate 9.** The right eye. The cornea is composed of a compact mesodermal sheet, three to four cells thick (arrow head). X20 (#23)
- Plate 10.** The trigeminal ganglion (T), vestibular ganglion (V), semicircular canal (S) and cochlear duct (C). The arrow indicates the proximal part of the optic nerve with ependymal remnant. X10 (#69)
- Plate 11.** The heart and lung. The pulmonary valve (PV) and mitral valve (MV). X10 (#73)
- Plate 12.** The heart, spleen (SP) and stomach (ST). The arrow indicates the dorsal mesogastrium connecting the spleen and stomach. X5 (#940)
- Plate 13.** Neck organs of the embryo. The thyroid (TH), parathyroid (P), thymus (T) and trachea (TR). X20 (#46)
- Plate 14.** The foramen cecum (C), X10 (X50)
- Plate 15.** The ventral pancreatic duct (VPD) and dorsal pancreatic duct (DPD). X10 (#47)
- Plate 16.** The paramesonephric duct (PD), ureter (U), mesonephric duct (MD), urogenital sinus (US) and hindgut (H). The arrow head indicates the persistent anal membrane. X10 (#46)
- Plate 17.** The appendix (A). X10 (#28)
- Plate 18.** An abnormal diverticulum (arrow head) at the hindgut. X10 (#75)
- Plate 19.** The adrenal gland (AD), metanephros (MT), gonad (G), stomach (S) and pancreas (P). X10 (#79)
- Plate 20.** The gonad. A conspicuous zone of young connective tissue beneath the germinal epithelium (GE). X50 (#78)
- Plate 21.** The submandibular gland (SM) has a definite lumen in the oral part of the duct. X10 (#49)
- Plate 22.** The notochord (arrow) at the cervical vertebra. X10 (#44)
- Plate 23.** The thyroid (T) and its pyramidal lobe (arrow). X10 (#58)
- Plate 24.** The arrows indicate clusters of chromaffin cells. X25 (#40)
- Plate 25.** The femur. It has not begun osteoblast formation yet. X25 (#14)
- Plate 26.** The vomeronasal organ (V) has a shallow, blind sac with reduced oral opening. X10 (#70)

