

A Human Embryo of Streeter Age Group XV

Je G. Chi and Yun Kyung Kang¹

Department of Pathology, College of Medicine, Seoul National University, Seoul 110-744, Korea

= Abstract = A human embryo considered to belong to stage XV of Streeter's developmental horizon is presented. The embryo was obtained surgically from tubal pregnancy. The crown-rump (CR) length was 8.5 mm. A total of 600 serial sections were made through the frontal plane and the following distinguishing features of the key organs were found. There was closure of the lens vesicle, evagination of the endolymphatic duct, overgrowth of the second branchial arch, well formed endocardial cushions, secondary bronchial subdivisions, ureteric bud inducing early metanephric blastema, and the appearance of ventral pancreatic bud. Beginning of pigmentation in the outer layer of the retina was the only finding that did not strictly meet the criteria of stage XV.

Authors classified the embryo in the late age group XV of Streeter's developmental horizon.

Key words: *Human embryo, Streeter's developmental horizon*

INTRODUCTION

The first eight weeks are the most important and interesting period in human development, because the embryo changes dramatically almost every day to form critical organs and tissues. Accordingly estimating the gestational age during this rapid changeable period is also a very tricky and attractive one. In 1948 Streeter introduced the concept of "developmental horizon". Based upon his time-consuming observations and experiences he divided the embryonic period into stage I to XXIII with an interval of 2 to 3 days and described morphological characteristics of each stage.

However, there are still certain individual variation as well as other temporal characteristics in every single embryo. In this study, a human embryo was sectioned serially and microscopic observation was made to reconstruct the major organ systems. Then we classified the developmental stage of the embryo according to Streeter's criteria.

CASE REPORT

The embryo (ESR # 82) was acquired from the right uterine tube that was removed for ectopic pregnancy in a 34-year-old woman whose menstrual history was not available in any certainty. After measuring its CR length, it was fixed in 10% neutral formalin en bloc, embedded in paraffin, and serially sectioned in the frontal plane from dorsal side to ventral in 4 μ m thickness. A total of 600 sections were obtained, prepared into 100 slides and stained with Hematoxylin-Eosin. During the embedding procedure the position of embryo was tilted slightly to the right side.

External view of embryo

Right lateral view of the embryo is presented in Fig. 1. The embryo is flexed ventrally, the contour of neural tube and somite are visible. In cephalic portion, the medial and lateral nasal prominences, eyes, two branchial arches, and auricular hillocks are found. The first branchial arch produces two elevations, i.e., maxillary and mandibular. The second arch overgrows the third and fourth. The heart and liver are seen through the ventral wall of the embryo. Upper limbs consist of proximal and distal segments, but lower limbs have no visible segmentations. (Plate 1).

Received 20/4/88; revised 18/5/88; accepted 20/5/88

¹Senior medical student, College of Medicine, Seoul National University.

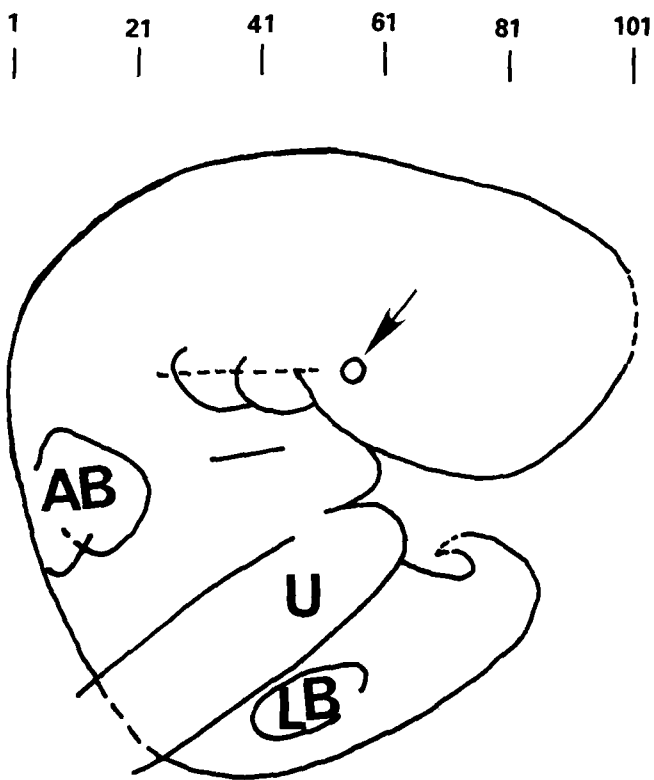


Fig. 1. Schemeatic reconstruction of the whole embryo(right lateral view). Number represents the number of section slide. AB: arm bud, LB: leg bud, U: umbilical cord, arrow: lens vesicle.

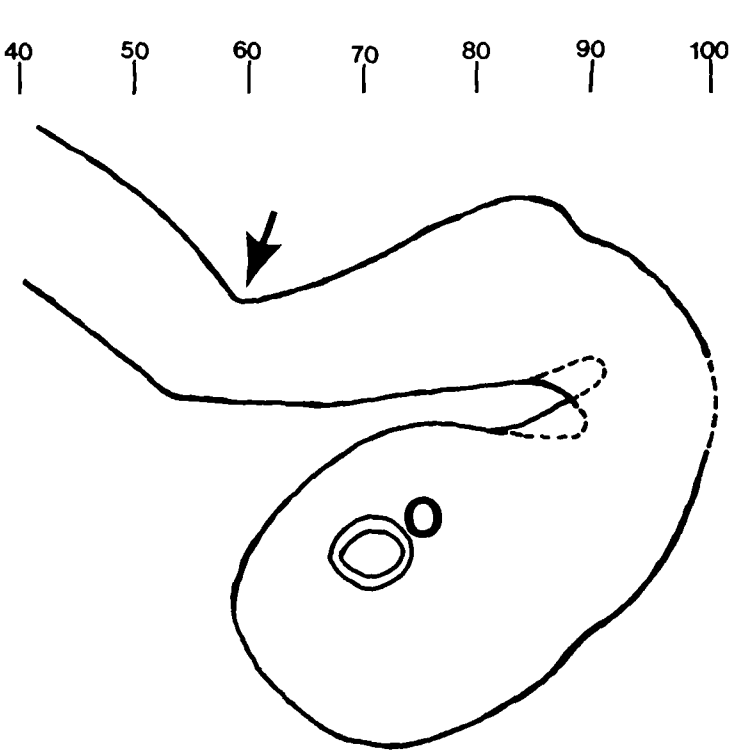


Fig. 2. Schematic reconstruction of the brain vesicle. O: optic cup, arrow: pontine flexure.

Central nervous system and sensory organs

Lateral evaginations of 2 cerebral hemispheres are found in the forebrain. Pontine flexure is prominent to divide the hindbrain into the metencephalon and myelencephalon (Fig. 2). The 4th ventricle is covered by thin ependymal roof and capillaries.

The Rathke's pouch which has evaginated from the roof of the stomodeum grows toward the brain and still has connection with the oral cavity. Ventral downgrowth of the diencephalon is not observed (Plate 2 and Plate 3). As the lens vesicle forms, the optic vesicle which has projected from the side of the forebrain invaginates and becomes double walled optic cup. The outer thinner layer of it begins to possess some pigment granules. The lens vesicle is seen as spherical body and separated from the surface ectoderm (Plate 4). A hollow diverticulum grows out from the medial side of the ectodermal otic vesicle to form the endolymphatic duct. The otic ganglion of the 8th cranial nerve is also found (Plate 5). The mesenchymal condensations of future auditory ossicles are observed (Plate 6). The nasal placode is seen on each side of the lower part of the frontonasal prominence (Plate 7).

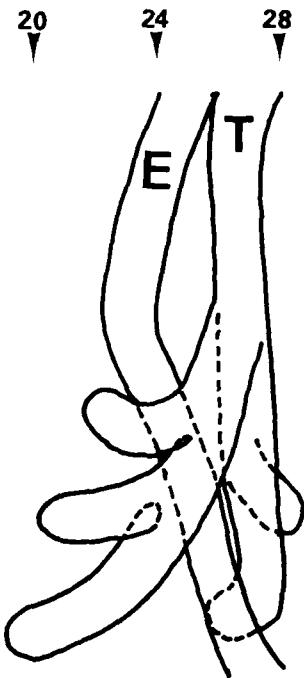


Fig. 3. Schematic reconstruction of the lung and esophagus. E: esophagus, T: trachea.

Cardiovascular system

The heart is within the pericardial envelope and is subdivided into 4 chambers by incomplete septa. The dorsal and ventral endocardial cushions which

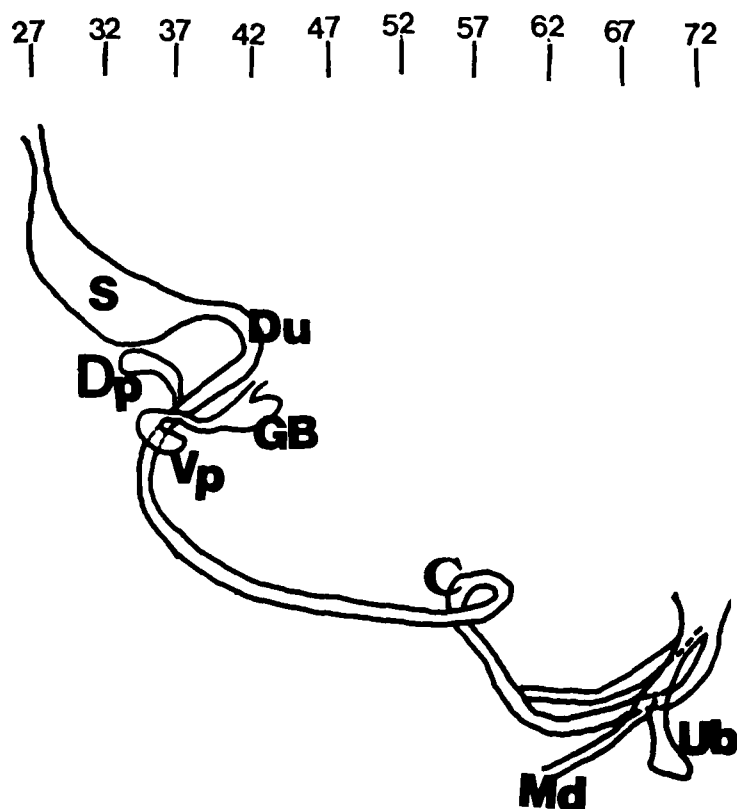


Fig. 4. Schematic reconstruction of the digestive and urogenital system. S: stomach, Du: duodenum, GB: gallbladder, Dp: dorsal pancreas, Vp: ventral pancreas, C: cecum, Md: mesonephric duct, Ub: ureteric bud.

separate posterior two atria from anterior two ventricles are still not fused (Plate 8). The septum primum grows ventrally from the roof of the primitive atrium and almost contacts with the endocardial cushions, thus ostium primum is smaller than ostium secundum (Plate 9). Immediately to the right of the septum primum begins to grow the fold of the septum secundum. The muscular interventricular ridge and external interventricular groove are observed near the apex. The truncus arteriosus shows its dorsal and ventral valve swellings and fusion of the swellings begins (Plate 10). The heart wall consists of three layers; epicardium, myocardium and endocardium. In the myocardium, multi-layered cell with centrally located nuclei and trabeculations are found.

Respiratory system

The respiratory diverticulum which outpouched from ventral wall of foregut has already separated from the dorsal esophagus by the esophagotracheal septum. It gives rise to the trachea and divides into two main bronchi. The main bronchi extends dorsally beside the esophagus and further di-

vides into secondary bronchi; 3 for the right and 2 for the left (Plate 11 and plate 12, Fig. 3). The lining of respiratory tubule is pseudostratified columnar epithelium, and yet does not have cilia.

Digestive system

The pharyngeal gut which contributes greatly to the formation of the head and neck has four pouches, and they are seen to grow actively. The thyroglossal duct connects the downgrowing thyroid gland and the foramen cecum. The thyroid gland divides into the right and left lobe by the isthmus portion (Plate 13). The hepatic diverticulum is fairly prominent. Its proliferating endodermal cells give rise to the primordia of hepatic cord, intrahepatic biliary apparatus and the hepatic sinusoids. The gallbladder is observed at caudal part of the hepatic diverticulum (Plate 14). The dorsal and ventral pancreatic buds are still separated from each other (Plate 14). The dorsal and ventral pancreatic buds are still separated from each other (Plate 15). There is no herniation of midgut into the extraembryonic coelom. The intestinal loop has undergone counterclockwise rotation up to 70°, which holds the cecum left side of the omphalomesenteric duct (Plate 16). The expanded terminal part of the hindgut along with the lateral mesonephric ducts form cloaca (Fig. 4). The whole gastrointestinal tract is lined by columnar cells and surrounded by a zone of primitive splanchnic mesodermal condensations.

Urogenital system

The proximal part of mesonephric tubule forms the Bowman's capsule, the cluster of capillaries projects into it, and they together form a mesonephric corpuscle. The distal part of mesonephric tubule is continuous with the mesonephric duct (Plate 17). The dorsal outgrowth of the mesonephric duct forms the ureteric bud which induces metanephric blastema (Plate 18). There is no prominent gonadal ridge identified.

DISCUSSION

After the observations and reconstructions of major organ systems, the embryo could best be placed in Streeter age XV. Streeter's descriptions about characteristic external form of this stage include; closure of the lens vesicle, beginning of submerging of the olfactory placode, first appearance of the primordium of the antitragus, distal and proximal subdivision of arm bud, beginning of regional differentiation of leg bud. The size of the embryo

for the most part ranges from 6.5 to 8.5 mm. Other criteria are no definite pigmentation in the outer layer of retina, distinct but short endolymphatic appendage, no developing neurohypophysis, still not fused dorsal and ventral endocardial cushions, and the appearance of ventral pancreas. Gross and microscopic examinations of the embryo all meet these criteria, except for the early pigmentation in the outer layer of retina which is one of the important criteria of stage XVI. The CR length of 8.5 mm, well formed endocardial cushions, definite secondary bronchial subdivisions and nearly contacting two pancreatic buds, are features that assure us that the embryo belongs to late stage XV rather than early stage XVI.

According to Streeter, the ovulation age of stage XV ranges from 31 to 32 days. Unfortunately, in our case we could not estimate the ovulation age, because previous menstrual period and the last

menstrual period were not precisely recorded in the record. Furthermore, there was irregular spotting for the last several weeks. There are no abnormal features observed through this embryo, and therefore we feel this was a normal embryo.

REFERENCES

- Streeter GL.** Developmental horizons in human embryos. Description of age groups XV, XVI, XVII and XVIII, being the third issue of a survey of the Carnegie collection. Contrib. to Embryol. 1948, 32:113-203
- Chi JG, Choi MR, Lee HK.** A human embryo of streeter age group XIV. Seoul J. Med. 1983, 24:329-336
- Chi JG, Chee HK.** A human embryo fo streeter age group XV. Seoul J. Med. 1986, 27:39-46
- Moore KL.** The Developing Human, clinically oriented embryology, 3rd ed., Saunders, Philadelphia, 1982
- Salder TW.** Langman's medical Embryology, 5th ed., The Williams and Wilkins, Baltimore, 1985

= 국문초록 =

사람배아(Streeter 연령군 XV)의 1예

서울대학교 의과대학 병리학교실

지제근 · 강윤경

34세된 여자환자의 난관임신으로 절제된 우측 난관에서 얻은 8.5 mm크기의 배아를 연속절편하고 재구축하여 그 발생학적 특징을 기술하였다. 본 배아에서는 렌즈 소포의 폐쇄, endolymphatic duct의 돌출, 제2인두궁의 과성장, 잘 형성된 심내막 융기, 2차 기관지의 분리, 요관뢰의 형성과 metanephric blastema의 유도, 복측 체장의 출현, 신경하수체의 미분화, 근위부로부터 점차 분강되기 시작하는 동맥간, 망막외층에 색소과립의 출현시작, 반시계방향으로 약 70°회전한 intestinal loop들의 소견이 관찰되었다. 위의 소견 중 망막외층의 색소과립은 Streeter연령군 XVI의 기준이지만, 그 외의 다른 소견은 연령군 XV에 적합하므로, 저자들은 본 배아를 연령군 XV의 후기에 해당하는 것으로 생각하여 보고하는 바이다.

LEGENDS FOR PLATES

- Plate 1.** Gross appearance of the embryo, left lateral view.
- Plate 2.** The Rathke's pouch (arrow) evaginated from the roof of the stomodeum, TE: tracheoesophageal trunk. X100 (#27).
- Plate 3.** The diencephalon (D) and the proximal part of the Rathke's pouch (R). X100 (#66).
- Plate 4.** The optic vesicle (O) and the lens vesicle (L). X100 (#71).
- Plate 5.** The otic vesicle (O), the endolymphatic appendage (E) and the otic ganglion (G). X100 (#46).
- Plate 6.** The otic vesicle (O), the auditory tube (AT) and the mesenchymal condensations of auditory ossicles (OS). X100 (#44).
- Plate 7.** The left nasal placode (arrow). X100 (#66).
- Plate 8.** The dorsal (D) and ventral (V) endocardial cushions. X100 (#39).
- Plate 9.** The septum primum (S), the ostium primum (arrow) and the endocardial cushions (E). X100 (#34).
- Plate 10.** The truncus arteriosus; the aortic trunk (A) and the pulmonary trunk (P). X100 (#36).
- Plate 11.** The left trachea (T) and its secondary bronchi (U: upper and L: lower), E: esophagus. X100 (#27).
- Plate 12.** The right secondary bronchi (U: upper, M: middle and L: lower). X100 (#22).
- Plate 13.** The thyroid gland (T) and the second pharyngeal pouch (arrow). X100 (#37).
- Plate 14.** The gallbladder (arrow) and the liver (L), D: duodenum. X100 (#39).
- Plate 15.** The pancreas (Dp: dorsal and Vp: ventral), p: portal vein. X100 (#33).
- Plate 16.** The intestinal loop: midgut (M) and cecum (C). X100 (#56).
- Plate 17.** The mesonephros: mesonephric tubule (T), mesonephric duct (D) and glomerulus (G), M: midgut. X100 (#37).
- Plate 18.** The ureteric budding (arrow) and metanephric blastema (B), H: hindgut. X100 (#67).

