

## A Postoperative Ventilatory Failure

Seong Deok Kim, Sea Wook Sung and Kyung Phill Suh\*

*Department of Anesthesiology and Department of Thoracic and Cardiovascular Surgery\*,  
College of Medicine, Seoul National University, Seoul 110, Korea*

**= Abstract =** A case of severe ventilatory failure with PaCO<sub>2</sub>, as high as 197 torr is reported postoperatively in a 3-year-old male patient who has received open heart surgery for total correction of known TOF (Tetralogy of Fallot). Many procedures were tried to treat the ventilatory failure but failed. Eventually we noticed malfunctioning of the humidifier assembled in Bear Cub infant pressure-limited ventilator. Vigorous endotracheal suction combined with saline irrigation improved the ventilatory failure successfully.

**Key Words:** *Ventilatory insufficiency, TOF, Humidifier, Respiratory care*

Inadequate physiologic ventilation would be an arterial PCO<sub>2</sub> above an acceptable range which is a condition referred to as ventilatory failure or respiratory acidosis.

Assessment of the adequacy of physiologic ventilation can be accomplished only by blood gas analysis (Shapiro *et al.* 1982). Inadequate alveolar ventilation (PaCO<sub>2</sub> above an acceptable limit) reflects a failure to remove CO<sub>2</sub> adequately through the lungs. When such a "ventilatory failure" is accompanied by acidemia (arterial pH below an acceptable limit), the failure must be of recent origin (acute) and, therefore, a direct threat to cardiopulmonary homeostasis. Acute ventilatory failure may be defined arbitrarily as PaCO<sub>2</sub> above 50 torr coincidental with an arterial pH below 7.30 (Shapiro *et al.* 1985). Recently we experienced a case of severe acute ventilatory failure during mechanical ventilatory support, which was treated successfully with vigorous endotracheal suction combined with saline irrigation.

### CASE REPORT

A 3-year-old male patient underwent an open heart surgery of TOF under general anesthesia composed of N<sub>2</sub>O-O<sub>2</sub>-Halothane with intermittent intravenous injection of morphine. After successful operation, he was transferred to RICU (Respiratory Intensive Care Unit) in intubated state and con-

nected to Bourns infant volume ventilator (F<sub>I</sub>O<sub>2</sub> 0.7, tidal volume 110 ml, respiratory rate 25/min.). ABGA (Arterial Blood Gas Analysis) was within normal limit. On the postoperative 2nd day, bilateral pulmonary edema and pleural effusion were detected by a chest roentgenogram (Fig. 1). Chest tubes were inserted. 5 cmH<sub>2</sub>O of PEEP (Positive End-Expiratory Pressure) was applied. On the 6th day, ventilator was switched to Bear Cub infant ventilator because of danger of pulmonary barotrauma. Airway pressure was 35 cmH<sub>2</sub>O under 12 cmH<sub>2</sub>O of PEEP. Endotracheal pinkish and frothy secretion and pulmonary edema were still present. On the 11th day, ABGA showed pH 6.90, PaCO<sub>2</sub> 197 torr and PaO<sub>2</sub> 104 torr at F<sub>I</sub>O<sub>2</sub> 1.0, respiratory rate 60/min. and PEEP 5 cmH<sub>2</sub>O. Airway pressure was 45 cmH<sub>2</sub>O. Repeated attempts of endotracheal suction and manual ventilation with Ambu resuscitator were unsuccessful to correct the acidosis and ventilatory failure. A suction catheter could not be inserted beyond a certain point through trachea. A chest roentgenogram confirmed the diagnosis of bilateral pneumothorax, indicating pulmonary barotrauma (Fig. 2). On the postoperative 12th day, it was noted that the humidifier attached to Bear Cub infant ventilator was malfunctioning, and after several attempts of vigorous endotracheal suction and saline irrigation, aggregated blood clots and secretions were expelled. Thoracic movement got better and airway pressure was dropped from 50 cmH<sub>2</sub>O to 40 cmH<sub>2</sub>O immediately after then. Acute

\* Author for Correspondence: Dr. Seong Deok Kim

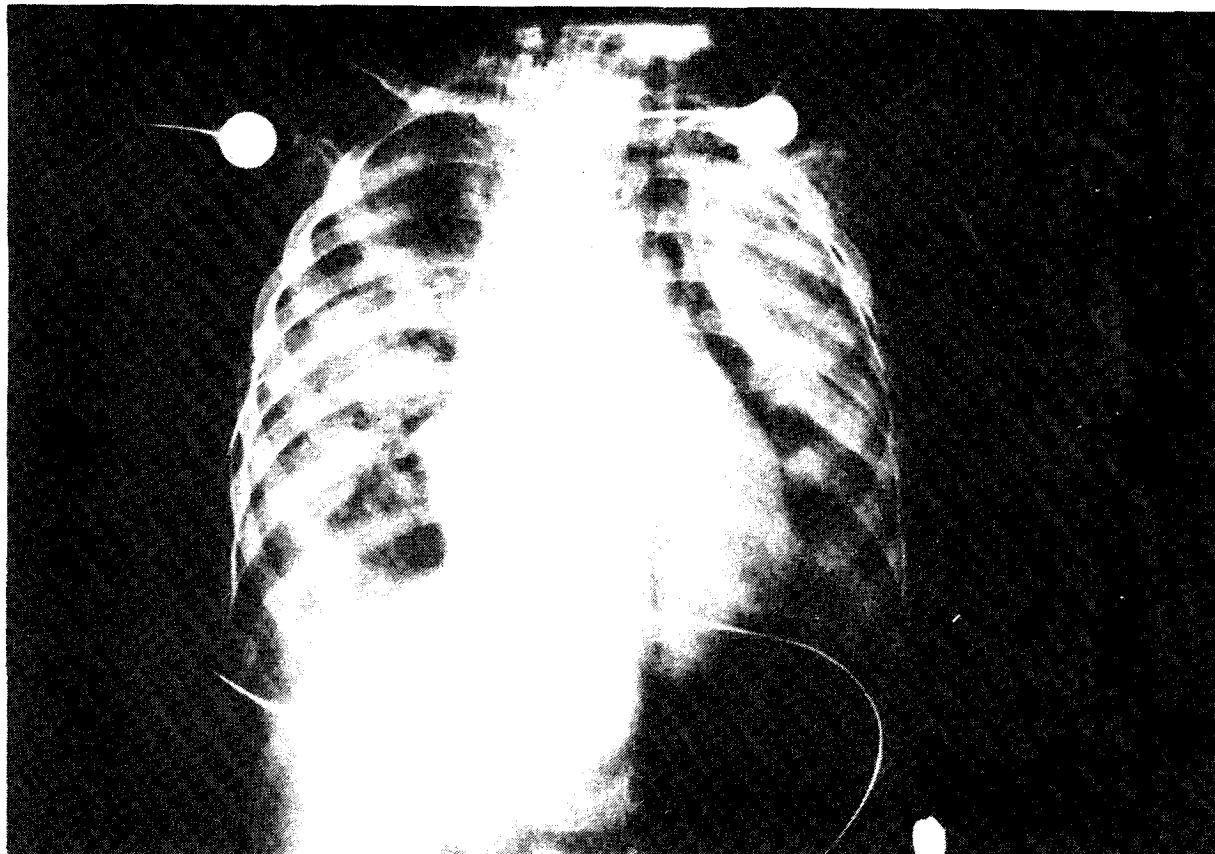


Fig. 1. Diffuse bilateral alveolar consolidation is seen in both lung fields, suggesting pulmonary edema. Linear radiolucency in left upper portion of mediastinum suggests localized pneumomediastinum. Chest tubes are inserted in both sides.

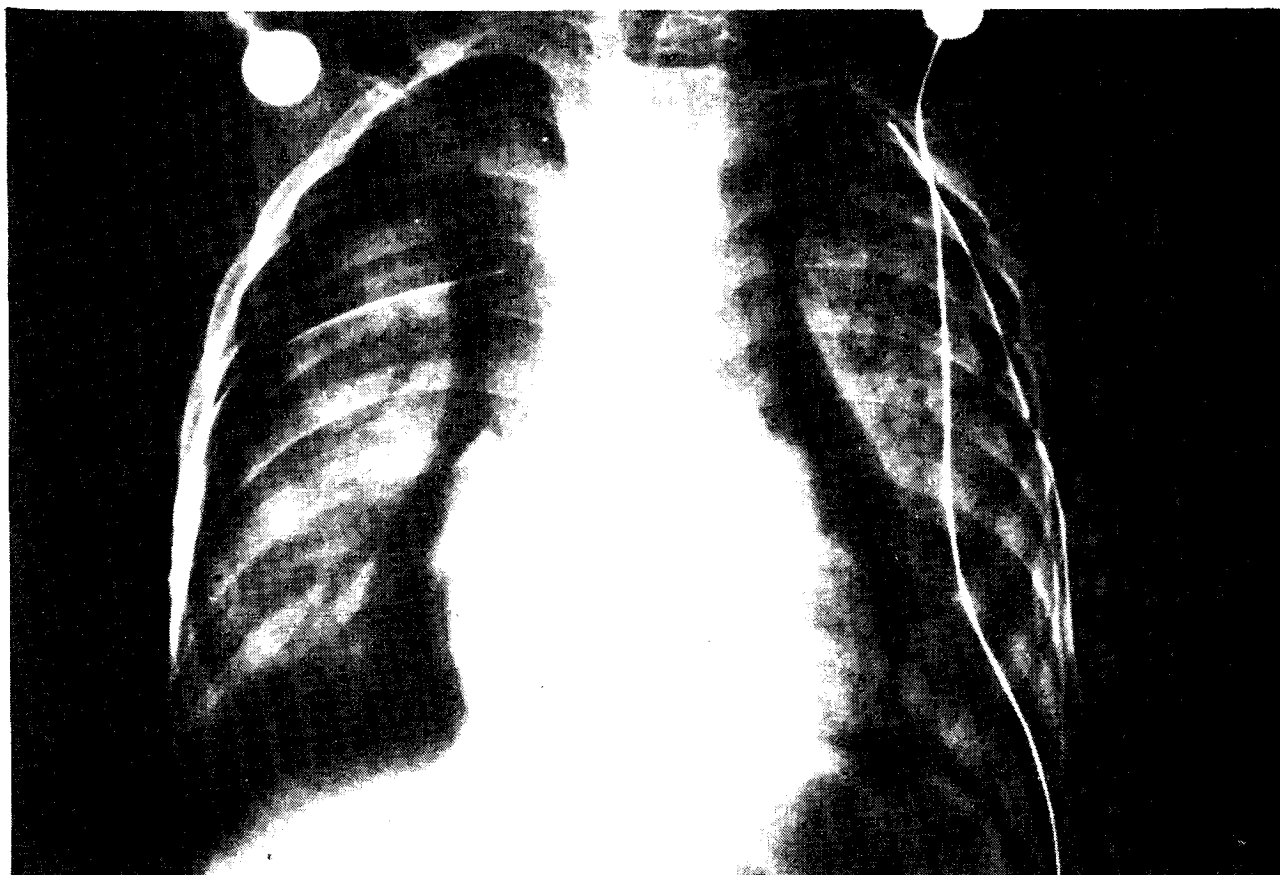


Fig. 2. Extensive bilateral pneumothorax is seen, suggesting pulmonary barotrauma. Pulmonary edema shows no significant interval change compared with Fig. 1. Bilateral chest tubes are inserted.

**Table 1.** Postoperative changes of arterial blood gas

POD	ABGA		F <sub>I</sub> O <sub>2</sub>	V <sub>T</sub> (ml)	f/min.	PEEP (cmH <sub>2</sub> O)	AP (cmH <sub>2</sub> O)	Ventilation
	pH-PaCO <sub>2</sub> -PaCO <sub>2</sub> (torr) (torr)							
1	7.41-	41-214	0.7	110	25		NC	Bourns
2	7.53-	41- 67	0.5	110	25	5	NC	"
5	7.48-	42- 69	0.7	130	30	8	NC	"
6	7.39-	53- 54	1.0	130	40	12	NC	"
	7.38-	37- 83	1.0	NC	50	12	35	Bear
11	7.40-	51- 75	0.8	NC	60	5	40	"
	6.90-	197-104	1.0	NC	60	5	45	"
12	7.04-	142- 51	0.8	NC	45	5	50	"
	7.59-	30- 98	0.5	NC	40	8	40	"
	7.56-	32-230	0.5	130	30	5	NC	Bourns
16	7.45-	38-130	0.3	120	5		NC	"

POD:Postoperative day

AP :Airway pressure

NC :not checked

f :Respiratory frequency

ABGA:Arterial blood gas analysis

F<sub>I</sub>O<sub>2</sub>:Fraction of inspired oxygen

V<sub>T</sub> :Tidal volume

ventilatory failure was treated completely. ABGA was pH 7.59, PaCO<sub>2</sub> 30 torr and PaO<sub>2</sub> 98 torr at F<sub>I</sub>O<sub>2</sub> 0.5, respiratory frequency 40/min. and PEEP 5 cmH<sub>2</sub>O in Bear Cub infant ventilator. The ventilator was switched to Bourns infant volume ventilator which was set at tidal volume 130 ml, frequency 30/min., PEEP 5 cmH<sub>2</sub>O and F<sub>I</sub>O<sub>2</sub> 0.5. In this situation, ABGA was pH 7.56, PaCO<sub>2</sub> 32 torr, PaO<sub>2</sub> 230 torr and bicarbonate 28 mEq/L, showing respiratory alkalosis combined with mild metabolic alkalosis. Continuous high PaCO<sub>2</sub> caused excitability which made assisted ventilation very difficult and PaCO<sub>2</sub> higher and higher. Because of these factors and for the purpose of life-saving, continuous muscle relaxation with pancuronium and sedation with diazepam and morphine were performed, which prevented us from full evaluation of mental state. We tried to decrease intracranial pressure with intravenous furosemide, mannitol and steroid, and used intravenous infusion of sodium thiopental for cerebral protection (Michenfelder and Theye 1973). Throughout the ventilatory insufficiency, we couldn't stop intravenous infusion of dopamine (2-10 μg/kg/min.), suggesting that severe hypercapnia resulted in cardiovascular depression. On the 16th day, weaning from ventilator was performed successfully without any problems. Postoperative changes of arterial blood gases and mechanical ventilatory supports were summarized in Table 1. He was completely normal neuropsychologically in

the following check at OPD.

### DISCUSSION

The prognosis in patients with acute respiratory failure treated with mechanical ventilation has improved since the advent of the respiratory intensive care unit. However, as experience with mechanical ventilation has increased, so has the number of recognized complications. Although some of these are relatively minor, such as nasal necrosis with use of nasotracheal intubation, and mild hyperthermia, others, such as massive gastric distention, tracheal erosion, pneumothorax, and nasocomial pulmonary infection, may be severe and, not rarely, fatal.

The approach to the management of patients with assisted ventilation aimed at the recognition and prevention of complications should lead to a further increase in survival. Such an approach should be based upon knowledge of the spectrum and incidence of complications associated with assisted ventilation, particularly those in which morbidity and mortality have been demonstrated.

Zwillich *et al.* (1974) has reported the following complications of assisted ventilation in a prospective study of 354 consecutive episodes. The complications attributable to intubation and extubation were prolonged intubation attempt, intubation of right mainstem bronchus, premature extubation and self extubation. The complications associated

with endotracheal or tracheostomy tubes were tube malfunction and nasal necrosis. The complications attributable to operation of the ventilator were machine failure, alarm failure, alarm found off, inadequate nebulization or humidification and over heating of inspired air. The medical complications occurring during assisted ventilation were alveolar hypoventilation and hyperventilation, massive gastric distention, pneumothorax, atelectasis, pneumonia and hypotension.

The complications noticed in this case were pulmonary edema, pleural effusion, pneumothorax and severe acute ventilatory failure (pH 6.90, PaCO<sub>2</sub> 197 torr). Pulmonary edema and pleural effusion probably associated with heart failure were treated successfully with diuretics, fluid restriction, inotropics, colloid, morphine, PEEP and insertion of chest tube. Overpressure applied in airway to overcome aggravating CO<sub>2</sub> retention eventually resulted in pneumothorax. As mentioned previously, severe acute ventilatory failure was mainly caused by airway obstruction resulted from blood clots and debris, secondary to inadequate humidification of inspired air. Inadequate humidification was associated with low dial setting of humidifier, so we could not observe water vapor or droplets in inspiratory rim of ventilator.

The contributing factors to influence the incidence of pneumothorax during continuous ventilatory support are volume-cycled ventilator, chronic obstructive lung disease, excessive tidal volume, increased end-inspiratory pressure, PEEP and percutaneous subclavian venipuncture during pressure breathing (Steier *et al.* 1971).

Problems with humidifiers during mechanical ventilation may be thermal hazards, electrical and electromagnetic interference problems, contaminants in the humidifier or nebulizer, mechanical or structural failures, inaccuracy in delivered oxygen concentrations, marking or labeling problems, damage caused by the sterilization process, connector failure, human factors, engineering problems, and complaints about the response of manufacturers to reported problems (Bancroft 1982).

Mental changes characteristic of carbon dioxide retention has various correlation to degrees of

hypercapnia. In clinical studies of Dulfano and Ishikawa (1965), mental changes occurred at PaCO<sub>2</sub> from 48 to 148 torr, and no obvious correlation could be established between the severity of the mental changes and degree of hypercapnia. In this case, excitability, anxiety and semicomatous state were observed mental disturbances, but no papilledema and seizure.

The effects of hypercapnia on cardiovascular system may be stimulatory in early and acute stage, but inhibitory in late and chronic stage. The fact that we could stop infusion of dopamine after correction of severe hypercapnia indicates that hypercapnia might cause cardiovascular depression.

The purpose of this report is not to discourage the use of ventilatory support but to alert anesthesiologists who use the technique to the occurrence of complications, the importance of early diagnosis, and means of preventing such complications.

## REFERENCES

- Bancroft ML.** Problems with humidifiers. In Rendell Baker L(Ed) International Anesthesiology Clinics (problems with anesthetics and respiratory therapy equipment), Vol. 20, No. 3, Little, Brown and Company, Boston, 1982:pp. 95-102
- Dulfano MJ, Ishikawa S.** Hypercapnia: Mental changes and extrapulmonary complications. An expanded concept of the "CO<sub>2</sub> intoxication" syndrome. *Ann. Int. Med.* 1965, 63:829-841
- Michenfelder JD, Theye RA.** Cerebral protection by thiopental during hypoxia. *Anesthesiology* 1973, 39:510-517
- Shapiro BA, Harrison RA, Kacmarek RM, Cane RD.** Clinical application of respiratory care. 3rd Ed., Year Book Medical Publishers, Inc., Chicago, 1985, pp. 367-368
- Shapiro BA, Harrison RA, Walton JR.** Clinical application of blood gases. 3rd Ed., Year book Medical Publishers, Inc., Chicago, 1982, pp. 257-260
- Steier M, Ching N, Roberts EB, Nealon, HR. TF** Pneumothorax complicating continuous ventilatory support. *J. Thorac. Cardiovasc. Surg.* 1974, 67:17-23
- Zwillich CW, Pierson DH, Creagh CE, Sutton FD, Schatz E, Petty TL.** Complications of assisted ventilation—A prospective study of 354 consecutive episodes. *Am. J. Med.* 1974, 57:161-170

= 국문초록 =

## 수술후 발생한 환기 부전증

서울대학교 의과대학 마취과학교실 및 흉부외과학교실\*

김성덕 · 성시욱 · 서경필\*

활로씨 4 증후군이란 진단하에 개심술을 시행한 3세된 남자 환자의 술후 인공호흡과정에서 심한 급성환기부전증 1례를 체험하였다. 수술후 합병증으로 폐수종, 늑막삼출이 흉부 X-선 소견상 인지되고 인공호흡 시행과정에서 기흉이 발생하였고 급기야는 pH 6.90, PaCO<sub>2</sub> 197 torr의 심한 급성환기부전이 발생하였는 바, 인공호흡기에 부착된 가습기의 조작미숙으로 인한 가습기의 기능저하가 혈액 및 분비물의 응고를 촉진시키고 결국은 기도를 폐쇄한 것이 원인이었던 것으로 판명되었으며 기관내 이물질의 강한 음압흡인과 생리식염수를 사용한 세척으로 후유증없이 치료되었다.

본 증례보고의 목적은 인공호흡중 발생가능한 합병증의 종류, 합병증의 조기진단의 중요성 및 그 예방에 대해 담당의에게 다시 한번 경각심을 일깨우는데 있다.