

Experimental Neural Tube Defect Induced with Hypervitaminosis A in the Rat

Young Cho Koh[†], Je G. Chi^{*} and Kil Soo Choi

Departments of Neurosurgery and Pathology, College of Medicine, Seoul National University, Seoul 110, Korea*

= Abstract = The causes of human neural defect (NTD) are not clarified yet and there is a multitude of theories on the morphogenesis of this malformation.

This experiment was carried out to develop a model for NTD in animal and elucidate the morphogenesis of NTD with particular emphasis on the relationship between exencephaly and anencephaly.

With exposure to 150,000 IU of vitamin A on various periods of gestation, ranging from the 7th to the 10th days, not only NTDs but a variety of other systemic malformations such as anophthalmia, exophthalmia, anotia, maxillary and/or mandibular hypoplasia, tail and/or genital agenesis, anal atresia and limb defects were produced.

Occurrence of these malformations was more related to the time of exposure than the dose of vitamin A, *i.e.* NTD could be induced only with exposure on the 8th and 9th days of gestation. It was also possible to mention that the critical period of ex-/anencephaly is the 8th day of gestation and that of spina bifida the 9th day in rats.

In addition to the teratogenicity 150,000 IU of vitamin A caused marked increase in fetal mortality and growth retardation if administered before the 10th day of gestation.

Observations of the degenerative changes and necrosis in the exencephalic brains in variable extent made it possible to conclude that the classical anencephalic features result from the spontaneous necrosis of the exencephalic malformation.

Key words: *Neural tube defect, Exencephaly, Anencephaly, Spina bifida, Fetal mortality, Critical period, Gestational period*

INTRODUCTION

By far the most frequent malformations of the central nervous system in the human fetus are 'neural tube defects' (Dekaban 1963). Neural tube defects (abbreviated as NTDs) present a wide variety of clinical and pathological manifestations ranging from spina bifida occulta to anencephaly (Warkany 1971). Even though there is a diversity of clinical and pathological conditions of NTDs, it is generally assumed that the pathogenesis of these entities is closely related (Caldarelli *et al.* 1985). The presence of various associated defects and the

morphological heterogeneity of these defects, however, suggests a variety of factors are implicated (Warkany 1971; Wilson and Fraser 1979; Khoury *et al.* 1982). So far, nutritional deficiencies such as folic acid or pantothenic acid, metabolic imbalances, irregularities in physical environment and a variety of chemical and pharmacological teratogens have been implicated in the pathogenesis of NTDs (Warkany 1971; McCormick 1971; Larroche 1984).

Since Cohlman (1953) introduced hypervitaminosis A as a model for the experimental production of NTDs, excessive administration of vitamin A to pregnant animals has proven one of the most effective means for the induction of these defects as well as many other types of malformations in various ex-

perimental animals (Cohlan 1953; Kalter and Warkany 1961; Marin-Padilla and Ferm 1965; Langman and Welch 1966; Morriss 1972; Shenefelt 1972; Theodosis and Fraser 1978; Smith *et al.* 1978; Selter *et al.* 1979; Smith *et al.* 1981; McLone *et al.* 1983; Caldarelli *et al.* 1985). There already have been reported over 70 types of congenital malformations including ex-/anencephaly and spina bifida by means of maternal administration of large doses of vitamin A to rodents (Shenefelt 1972). Most of the investigators agreed that the nature of the hypervitaminosis A induced malformations seemed to depend more upon the stage of embryonic development at the time of exposure to this teratogen than it does upon the species of animal or the dosage of this teratogen (Kalter and Warkany 1961; Langman and Welch 1966; Caldarelli *et al.* 1985).

Only a few articles described specific malformations associated with NTDs in detail, and many of these anomalies simulated congenital malformations known to occur in human NTD cases. Therefore it seemed worthwhile to report briefly upon the production of such developmental defects in experimental animals. This experiment was carried out to develop a model for NTDs in animals and elucidate the morphogenesis of NTD with particular emphasis on the relationship between exencephaly and anencephaly as well as the morphologic characteristics of those malformations associated with NTDs.

MATERIALS AND METHODS

Experimental animals

Female virgin Sprague-Dawley rats were housed under standard conditions and allowed a standard laboratory diet and water *ad libitum* until they weighed 180-250 gm, when they were mated with proven breeder males of the same strain. The presence of sperm on the vaginal smear, which was performed on the next morning, was used to denote the day 0 of gestation. A single dose of 150,000 IU of vitamin A high concentrate (manufactured by MUCOS Emulsionsges. mbH 8192 Geretsried, West Germany) was administered per specially designed gavage tube to groups of impregnated rats in the morning hours of the 7th, 8th, 9th and 10th day of gestation. Control group of animals were administered equal volume of corn oil instead of vitamin A high concentrate.

Among the 100 impregnated vitamin A treated or corn oil administered animals only 60 remained at

the time of sacrifice, which constituted this study. All the animals were sacrificed by cervical dislocation on the 20th day of gestation, one day before the expected time of delivery. After opening the abdomen, the resorption sites and dead fetuses were counted immediately. Live fetuses were weighed and fixed in Bouin's solution for about 2 weeks. After adequate fixation the fetuses were cleaned thoroughly, observed for external malformations, if any, and were subjected to measurements of crown rump length (CRL), biparietal diameter (BPD), tail length (TL), limb lengths and weight. Discrimination of sex was performed by external observation.

The vitamin A treated fetuses were grouped into 4 units according to the time of exposure to this teratogen and corn oil administered fetuses were considered as a single control group regardless of the time of exposure. Observations of the gross malformations were done in a systematic manner from the head to the tail with naked eye or under dissecting microscope. After examining the external malformations all of the fetuses were cut in slices according to the method of Warkany with razor blades in 1-2 mm thickness to observe the visceral malformations. After thorough examinations under dissecting microscope, these specimens were processed for histological examination.

In this study the 'fetal mortality' was expressed as the percentage of the number of resorption sites and dead fetuses divided by the total implantation sites. The 'incidence of fetal malformation' was expressed as the percentage of the number of the malformed fetuses divided by the total number of implantation sites. The percentage of the malformed fetuses over live fetuses represented the 'rate of malformed fetuses'.

RESULTS

Table 1 contrasts the treatment results of the control with those of the experimental groups. Eleven impregnated rats of group I which were exposed to 150,000 IU of vitamin A on the 7th day of gestation produced 82 implantation sites in total including 31 resorption sites, one dead fetus and 50 live fetuses, all were without gross malformations. 10 pregnant rats of group II which were exposed to vitamin A on the 8th day of gestation produced 72 implantation sites in total including 26 resorption sites, 3 dead fetuses and 43 live fetuses of which 32 had gross malformations including exencephaly or anencephaly. The total implantation

Table 1. Pregnancy outcome of vitamin A administered and control groups

Groups	No. of dams	Total No. of implan- tation	No. of resorp- tion	No. of dead fetuses	No. of live fetuses	No. of malformed fetuses	Fetal* morta- lity(%)	Incidence** of fetal malforma- tion (%)	Rate of*** malformed fetuses
Group I	11	82	31	1	50	0	39.0	0	0
Group II	10	72	26	3	43	32	40.3	44.4	74.4
Group III	9	89	20	1	68	60	23.6	67.4	87.0
Group IV	10	100	5	0	95	83	5.0	83.0	87.4
Control	20	245	9	0	236	0	3.7	0	0

* Fetal mortality: No. of resorption + No. of dead fetuses/Total no. of implantations

** Incidence of fetal malformation: No. of malformed fetuses/Total no. of implantations

*** Rate of malformed fetuses: No. of malformed fetuses/No. of live fetuses

sites of the 9 impregnated rats of group III which were exposed to vitamin A on the 9th day of gestation were 89 including 20 resorption sites and 68 live fetuses. The total implantation sites of 10 pregnant dams of group IV which were exposed to vitamin A on the 10th day of gestation were 100 in number including 5 resorption sites and 95 live fetuses of which 83 fetuses were grossly malformed. 20 control dams produced 245 implantation sites in total including 9 resorption sites and 236 live fetuses without any demonstrable malformations.

The fetal mortality was 39.0% in group I, 40.3% in group II, 23.6% in group III, 5.0% in group IV and 3.7% in control group, which were of high statistical significance (Z_i , Z_{ii} , Z_{iii} = 8.37, 8.40, 5.62, all were in probability below 0.01) except for group IV. The incidences of fetal malformation were 44.4% in group II, 67.4% in group III, and 83.0% in group IV, which were statistically significant in comparison with control group as well as each other among the treated groups (Z_{ii-iii} , $ii-iv$, $iii-iv$ were 2.93, 5.30, 2.49, in probabilities below 0.01). The 'rate of malformed fetuses' among the treated groups were 74.4% in group II, 87.0% in group III and 77.4% in group IV.

The sensitivity of rat embryos to the teratogenic effects of vitamin A expressed by the sum of 'fetal mortality' and the 'incidence of fetal malformation' on different days of gestation is shown in Fig. 1. These sensitivities were 39.0% in group I, 84.7% in group II, 91.0% in group III and 88.0% in group IV. From this finding it could be said that the sensitivities of rat embryos to the vitamin A occurred rather regularly throughout the period between the 8th and 10th day of gestation, although the increasing tendencies of 'fetal mortality' and the 'inci-

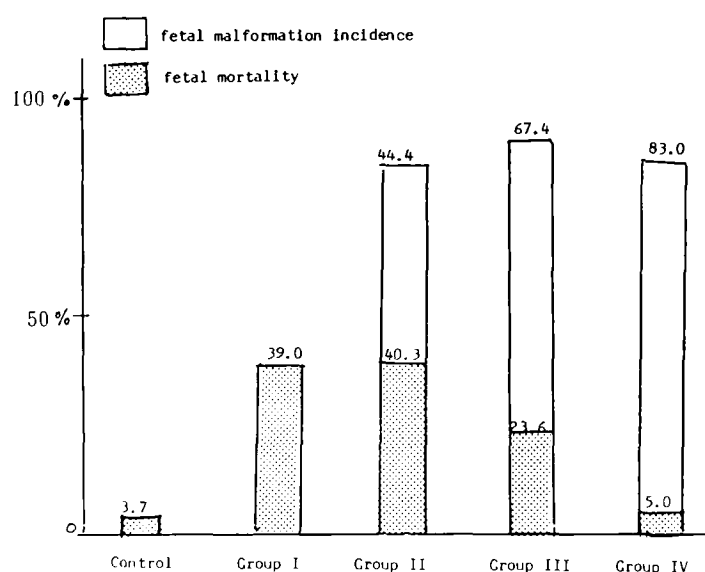


Fig. 1. Sensitivity of rat embryos to vitamin A 150,000 IU as the percentage of fetal mortality and fetal malformation incidence.

dence of fetal malformation' had opposite directions during this period.

Discrimination of sex was possible in most of the cases but some fetuses with urogenital anomalies associated with spina bifida. There were no differences in sex ratios between treated and control groups except with group II, where female preponderance was observed owing to the abundance of female ex-anencephalic fetuses by 2 to 1 over male ones.

Fetal measurements of Wt., CRL, BPD, TL, and FLL & HLL were used to denote generalized or localized retardation of fetal growth (Table 2). With this finding it could be said that 150,000 IU of vitamin A administered on the 7th, 8th and 9th day

Table 2. Fetal measurements and sex ratio (260)

Groups	No. of fetuses	BPD(mm)	CRL(mm)	FLL(mm)	HLL(mm)	TL(mm)	Wt(gm)	Sex ratio
Group I	50	7.97±0.35	28.47±1.25	8.05±0.25	7.92±0.47	10.82±0.65	2.48±0.33	50 : 50
Group II	43	6.87±0.63	27.64±3.54	7.83±0.70	7.74±0.84	10.33±1.25	2.30±0.79	42 : 58
Group III	68	7.94±0.57	28.17±2.91	8.27±0.68	6.16±2.30	-*	2.88±0.70	52 : 48
Group IV	47	9.49±0.87	35.96±4.22	8.33±1.95	8.85±1.95	12.94±3.31	4.93±0.96	48 : 52
Control	52	7.61±0.60	34.61±2.60	8.27±0.43	8.27±0.41	12.65±0.99	4.29±0.60	50 : 50

BPD: biparietal diameter, CRL: crown rump length, FLL: forelimb length, HLL: hindlimb length, TL: tail length

* TL in group III: Most of the group III fetuses are without tail.

Table 3. Varieties and incidence of gross malformations related to the time of vitamin A administration

Malformation type	Group II (43)	Group III (68)	Group IV (95)
Ex-/Anencephaly	27 (62.8%)	5 (7.3%)	0
Spina bifida	2 (4.7%)	59 (86.8%)	1 (1.1%)
Microcephaly*	5 (11.6%)	3 (4.4%)	0
Exophthalmos	4 (9.3%)	47 (69.1%)	61 (64.2%)
An-/Microphthalmia	16 (37.2%)	7 (10.3%)	17 (17.9%)
An-/Microtia	3 (7.0%)	60 (88.2%)	2 (2.1%)
Low set ears	0	0	23 (23.1%)
Maxillary/Mandibular hypoplasia	21 (48.9%)	25 (36.8%)	14 (14.7%)
Cleft mandible	1 (2.3%)	22 (32.3%)	14 (14.7%)
Tail agenesis	1 (2.3%)	53 (77.9%)	10 (10.5%)
Anal atresia	2 (4.7%)	59 (86.8%)	7 (7.4%)
Genital agenesis	2 (4.7%)	27 (39.7%)	1 (1.1%)
Club foot	1 (2.3%)	26 (38.2%)	1 (1.1%)
Caudal regression	0	7 (10.3%)	0
Micromelia	0	0	6 (6.3%)
Sirenomelia	0	5 (7.4%)	0
Microstomia	0	0	5 (5.3%)
Umbilical hernia	1 (2.3%)	3 (4.4%)	0
Atresia of UGS**	0	20 (29.4%)	0
Renal agenesis	0	9 (13.2%)	2 (2.1%)
HAP or Cleft palate	6 (14.0%)	5 (7.4%)	15 (15.8%)
Others	1 (2.3%)	9 (13.2%)	1 (1.1%)

* Microcephaly was defined by below 2 SD from average BPD/CRL of control.

** UGS: urogenital system

gestation caused significant retardation of general fetal growth ($Z_i = 18.77$, $Z_{ii} = 13.95$, $Z_{iii} = 11.62$, which were all in probabilities below 0.001). The ratio of BPD/CRL was used to denote selective retardation of brain growth and was significantly low in group II ($Z = 4.29$, p value below 0.01). In group III, TL and HLL were significantly different from other treated groups ($Z = 6.53$, p value be-

low 0.01).

Types and percentages of malformations induced with 150,000 IU of vitamin A on various gestation days are shown in Table 3. No grossly malformed fetus was observed in group I and control group. There occurred over 30 types of gross malformations including several forms of NTDs.

NTDs occurred only in group II and group III and

most of the NTDs of group II were in the form of exencephaly or anencephaly in contrast to most of the group III NTDs which were spina bifida.

Exencephaly or anencephaly

There were 32 ex-/anencephalic malformations of which 27 were in group II and 5 in group III. In group II, exencephaly was the most frequent gross malformation (62.8%). There was no significant morphological difference between exencephaly and anencephaly except for the amount of exposed brain tissue and the degree of degenerative changes. As it were, the exencephalic brains ranged from entirely exposed brains with little degenerative changes, to moderate or marked degenerative changes eventually to become typical anencephalic brains (Plates 2,3,4,7,8 and 9).

One of the exencephalic fetus was associated with spina bifida in group II. There was a case of craniorachischitic fetus with marked retardation of general growth (Plate 6). As a whole, most of the NTDs in group II were exencephalic fetuses with few examples of anencephalic ones. In group III there were only 5 ex-/anencephalic fetuses (7.3%), a much lower incidence than that of group II and this difference was very significant statistically (Chi square was 94.13, $df = 2$, p value was below 0.001).

A variety of malformations associated with ex-/anencephaly, of which maxillary/mandibular hypoplasia and an-/microphthalmia were of high statistical significance (Chi square value were 33.48, 24.76, $df = 2$, p values were below 0.005). Excluding the exencephalic or anencephalic fetuses there were only 5 microcephalics according to the criteria of 2 SD below average in BPD/CRL ratio in group II only with a high statistical significance (Chi square was 10.80, $df = 2$, p value below 0.005).

Spina bifida, a caudal counterpart of ex-/anencephaly was observed exclusively in group III fetuses, which was very significant statistically (Chi square was 155.22, $df = 2$, p value below 0.005). All the malformations of spina bifida were observed in the lumbosacral area in varying extent except a case of craniorachischitic fetus with an opened whole neuraxis. A variety of malformations such as anotia, anal atresia, tail and genital agenesis and club foot deformity were observed in association with spina bifida in statistically meaningful percentages (Chi square were 142.57, 138.44, 108.80, 60.75, 65.99, $df = 2$, p values were below 0.005). Though the incidences were not very high, the association of sirenomelia or symmelia, where both

hindlimbs were fused like a tail of a siren, with spina bifida, was of highly specific significance. A complex of multiple malformations, involving the caudal part of the fetus simulating 'caudal regression syndrome' in humans, was noted in the incidence of 10.3% associated with only severe forms of spina bifida (Plate 11, 12).

Exophthalmos, either bilateral or unilateral, was the most frequently observed malformation among the treated groups regardless of the time of exposure. In spite of this high incidence (Table 3) there was no significant critical period as in the cases of ex-/anencephaly or spina bifida. Except for the protrusion of unilateral or bilateral eyeballs there was no significant abnormality of eyeball itself (Plate 18, 20).

Anophthalmia or microphthalmia, either bilateral or unilateral, was observed less frequently than exophthalmos among all of the treatment groups, but showed a strong tendency of association with an-/exencephalic malformation (Table 3, plate 19, 20), which was very significant statistically (Chi square was 14.46, $df = 2$, p value below 0.005). Small low set ears, another type of ear anomaly, were observed only in group IV with a high statistical significance.

Maxillary and/or mandibular hypoplasias were observed in moderately high incidences in group II and III but with a lower incidence in group IV. Though there was no significant critical period, their association with ex-/anencephalics was of high statistical significance (Chi square was 19.54, $df = 2$, p value below 0.01).

Tail agenesis, anal atresia and genital tubercle agenesis were exclusively observed in group III especially in association with spina bifida, which was very significant statistically (Chi square values were 108.78, 140.36, 55.65, $df = 2$, p values were all below 0.005).

Extremity malformations occurred in three types, *i.e.*, clubfoot deformity with hindlimb hypoplasia, sirenomelia or symmelia and micromelia (Plates 13, 14, 16). Among these malformations the former two types were specifically associated with spina bifida and the latter was observed only in group IV, all of them were of high statistical significance (Chi square values are 52.53, 10.4, 7.22 $df = 2$, p values are below 0.01, 0.05).

Other malformations with low incidences such as cleft mandible, cleft palate, cleft lip, umbilical hernia and cryptorchism occurred uncommonly with little statistical significance.

Visceral malformations were observed in cut sections. With this method, renal agenesis or agenesis of entire urogenital system was observed in association with spina bifida with a high significance. In brain cut sections, the exencephalic brain seemed to arise from the diencephalon or mesencephalon eventually to be everted like a mushroom cap over the basal brain (Plates 21, 22). Degenerative changes and necrosis were noted not uncommonly in the exencephalic brains especially at the junctions of everted brain and the normal brain (Plate 22).

In cases of spina bifida the malformed spinal cord was transposed superficially from a higher position of the vertebral and skin defect. As in the case of anencephaly the exposed spinal cord underwent some degenerative changes eventually to be replaced by a scar tissue or rather unchanged opened spinal cord in a opened book fashion (Plate 23, 24).

MICROSCOPIC FINDINGS

The microscopic findings of exposed brains presented a very characteristic feature. The surface of exencephalic brain was either covered by ependymal cells or choroid plexus epithelium which was in direct continuation with surface epithelium (Plate 25). In some cases of anencephaly or exencephaly, the brain tissue was devoid of normal cellular layering or differentiation in that part of exposed brain mixed with hemorrhagic necrotic foci or degenerative changes.

Although no characteristic abnormality was observed in exophthalmic eyes, the microscopic findings of anophthalmia or microphthalmia were characterized by abortive lens tissue and scattered epithelial cell nests (Plate 26).

The photomicroscopic finding of spina bifida presented extensive abnormalities not limited to spinal cord but a variable extent of mesodermal changes such as notochordal degeneration, displacement of spinal ganglia, degeneration and atrophic changes of paraspinal muscles and defects of vertebra with some degenerative changes (Plate 27). The surface of the exposed spinal cord was lined by ependymal cells in a open book fashion, which is very suggestive of nonclosure of neural tube. There was also loss of normal arrangements of gray and white matter in this exposed segment of spinal cord (Plate 28).

DISCUSSION

The critical periods for NTDs have been reported

as the 8th day of gestation in mice (Kalter and Warkany 1961; Seller *et al.* 1979), in hamsters (Marin-Padilla and Ferm 1965), and in rats (Morriss 1972). Some investigators reported the period between the 8th and 10th days of gestation as the critical period for the NTDs (Smith *et al.* 1978, 1981). Langman and Welch (1966) reported the same period in mice and rats. Shenfelt (1972) reported the period between the 7 1/2 and 7 3/4 day of gestation as the critical period for anencephaly or exencephaly and between the 7 3/4 and 8 1/4 day for spina bifida.

In this experiment we administered a single dose of 150,000 IU of vitamin A according to the data of a preliminary study. The time of exposure to the vitamin A was varied from the 7th to the 10th days of gestation according to the result of a preliminary study that showed NTDs occurred only during the 8th day and 9th day of gestation in the exposure groups. The incidences of NTDs in the 8th (62.8%) and 9th (86.8%) day of gestation were considerably higher than those reported in the literature. This high rate of NTDs in this study may be ascribed to the higher dose of vitamin A which caused higher ratio of resorption and dead fetuses. The incidence of ex-/anencephaly was 62.8% in the 8th day exposure group in contrast to 7.3% in the 9th day group. The incidence of spina bifida was reversed in these two groups showing 4.7% in the 8th day and 86.8% in the 9th day exposure group, respectively. With above results, it was possible to ascertain that the critical period of ex-/anencephaly and spina bifida is the 8th day and the 9th day of gestation respectively, which is in accordance with most of the reports in the literature (Giroud and Martinet 1956; Kalter and Warkany 1961; Langman and Welch, 1966; Marin-Padilla, 1966; Smith *et al.*; 1978; Seller *et al.* 1979). Regarding the critical period, care must be taken in counting the gestational age. The presence of sperm on the vaginal smear was used to denote gestational day zero in this study, but several reports in the literature do not specifically define the first day of gestation (Marin-Padilla and Ferm 1965; Kochhar 1967; Smith *et al.* 1981). In addition to the teratogenic effect, administration of vitamin A at the dose of 150,000 IU caused significant retardation of general fetal growth when exposure occurred on the 7th, 8th and 9th days of gestation. This finding is coincident with that of Steele *et al.* (1983). It was also interesting to observe the female preponderance in ex-/anencephalic fetuses

by 2 to 1, as is the ratio in human cases. The study of Seller *et al.* (1979) have mentioned about this point. Administration of 150,000 IU of vitamin A on the 8th, 9th and 10th day of gestation induced a variety of malformations including NTDs at high rates indicating that vitamin A treatment can be used in studying the morphogenesis of NTDs. There was little difficulty in deciding whether a certain malformation was present or not in the 20 day old fetus except for some visceral abnormalities involving cardiac or pulmonary systems, if any.

The sensitivity of rat embryo to vitamin A was expressed as the sum of the 'fetal mortality' and the 'incidence of fetal malformation' in this study, a little different from that used in the study of Marin-Padilla and Ferm (1965). They used the 'rate of malformed fetuses' instead of 'incidence of fetal malformation'. But it seemed irrational to follow their instruction because the sum may exceed 100% in our study. Moreover, the sensitivities were observed rather evenly throughout the 8th, 9th and 10th days of gestation by 84.7%, 91.0% and 88.0% respectively (Fig. 1). Many of the malformations associated with ex-/anencephaly seemed to share similar characteristics with clinical findings occurring in humans (Anderson *et al.* 1967; Warkany 1971; Larroche 1984). But the association of an-/microphthalmia with NTDs in a rate over 50% seems quite contrary to findings in human cases (Anderson *et al.* 1967; Warkany 1971; Nakano, 1973). The intactness of eye development in cases of anencephaly has been the morphogenetic clue that the degenerative process of the brain tissue starts after its differentiation into telencephalon and diencephalon (Warkany 1971; Nakano 1973). Few investigators have reported the association of anophthalmia or microphthalmia with experimental anencephaly or exencephaly induced by the hypervitaminosis A model. Though comparison with other reports seems to be impossible, significance of the association of anophthalmia with ex-/anencephaly remains to be clarified.

The association of facial skeletal abnormalities such as exophthalmos, maxillary and/or mandibular hypoplasia with tongue protrusion, cleft mandible, cleft lips and cleft palates may be the result of the effect of vitamin A on the chondromesoderm and neural crest cells in the cephalic region (Shenefelt 1972; Fantal *et al.* 1977; Hendricks *et al.* 1980; Newell-Morris *et al.* 1980; Yip *et al.* 1980). Exophthalmos was the most frequently observed single anomaly in 7th, 8th, 9th and 10th day of gesta-

tion groups without any significant critical period. Being absent any morphological abnormalities except for the smallness of orbits, it was postulated as the result of effect of vitamin A on the cephalic mesoderm. The low incidence of cleft palate, cleft lip and microstomia in this study could be explained by the fact that the administration of vitamin A was limited to within 10 days after conception. In fact, treatment at the 10 days after conception produced greatly different malformations from those resulting from earlier treatments (Shenefelt, 1972). Most characteristic malformations produced by the treatment at the 10th day of gestation were low set ears (Plate 15) and micromelia (Plate 16), which is comparable to those of Shenefelt (1972).

The association of a variety of malformations with spina bifida was much more characteristic and impressive than with anencephaly or exencephaly. Anal atresia, anotia, tail agenesis, agenesis of external genital tubercle, exophthalmos and club foot deformity were associated with spina bifida in a rate from 45% to 97% in decreasing order of frequencies. Anotia might be the result of the effect of vitamin A on the chondromesoderm and neural crest cells reinforcing the mesoderm of the first and second branchial arches (Yip *et al.* 1980). Anal atresia, genital agenesis, tail agenesis and club foot deformity associated with spina bifida in this experiment had similar characteristics to those occurring in humans (Warkany 1971; Sadovnick and Baird 1986). Though the incidences were not so high (7%, 10%), the association of sirenomelia or symmelia and caudal regression syndrome with spina bifida deserves special attention because few investigators have demonstrated these malformations with the hypervitaminosis A model.

For the underlying mechanism of NTDs the majority of investigators favor the hypothesis of von Recklinghausen, the 'failure of the neural folds to close' (Patten, 1953; Dekaban 1963; Marin-Padilla and Ferm 1965; Langman and Welch 1966; Smith *et al.* 1981). Controversy is still present, however, as to whether the basic morphological abnormality causing the failure of the neural folds to close is the primary neuroectodermal lesion or the secondary to the supporting mesodermal lesion. In the study of the effect of vitamin A on development of CNS, Langman and Welch (1965) postulated the primary defect of neuroepithelium with the findings of accumulation of dividing neuroepithelial cells near the inner surface followed by disruption of internal limiting membrane resulting in nonclosure

of the neural tube. Smith *et al.* (1981) identified a microfocal necrosis located in the head fold epithelium near the anterior neuropore in the 8 day embryo. Subsequent to this initial neuroepithelial lesion, they found the exencephalic malformation developed as brain folds extending vertically from the diencephalon.

On the contrary, Marin-Padilla (1966) asserted the most prominent structural abnormalities encountered in the embryonic stages of exencephaly are those involving the nonsegmented mesoderm especially in the cephalic region. He postulated the presence or absence of schisis (failure to close of neural folds) will depend on the particular developmental stage of the neural folds, affected by the mesodermal insufficiency. He postulated the elevation of the neural folds depends on the progressive accumulation of nonsegmented mesodermal cells and closing process begins by the approximation of the neural folds following the closure of surface ectoderm and its adjacent mesodermal layer, after which actual fusion and closure of the neuroectoderm occurs (Marin-Padilla and Ferm 1965). Some investigators have observed mesodermal changes consisting of ultrastructural widening of extracellular space and concomitant cell shrinkage and cell death, thereby, interfering with neural tube closure (Morriss 1972).

A variety of hypotheses have been proposed as to the basic pharmacological and biochemical effects of vitamin A causing such numerous malformations including NTDs. It would appear that the maternally administered excessive dose of vitamin A affects the embryonic cells directly, and the lipoprotein membrane of cells has been postulated as the site of action of this teratogen (Theodosis and Fraser 1978). Vitamin A might interfere with mitosis, thus causing an accumulation of dividing cells near the inner surface and may also interfere with DNA synthesis resulting in a decrease in the number of cells, or may prevent the formation of neuroblasts causing overproduction of neuroepithelial cells (Langman and Welch 1966). Large amounts of vitamin A may inhibit the synthesis of chondroitin sulfate and dissolution of that already formed (Langman and Welch 1966). McLone *et al.* (1983) proposed that vitamin A interferes with the synthesis of glycosaminoglycans, a complex carbohydrate essential for the biological processes related to the neurulation. Caldarelli *et al.* (1985) postulated that vitamin A promotes an increase in the glycosylation of the cell surface and decrease

the synthesis and production of glycosaminoglycan such as chondroitin sulfate, which plays a major role in bridging the gap between the neural folds (McLone *et al.* 1983; Caldarelli *et al.* 1985). Moreover the effects of increasing fetal mortality, growth retardation and various malformations might be the results of direct action of vitamin A on the protein synthesis eventually leading to cellular necrosis, interference of cellular interaction and mechanical disruption of embryonal tissue (Kochhar 1967, 1973; Morriss 1973, 1974; Wilson and Fraser 1978; Nakamura 1978; Yip *et al.* 1980; Steele *et al.* 1983; Goodman 1984).

Some investigators proposed all the abnormalities involving the CNS, skeletal system, notochord, musculature, neural crest-derived tissues and other associated malformations are the results of axial mesodermal insufficiency, characterized by pronounced abnormalities of the skull base, vertebral column and the notochord.

The exencephalic nature of the involved brain is caused by the inadequacy of the cranial and spinal cavities to lodge the developing brain and spinal cord (Marin-Padilla 1966).

The predominance of exencephalic malformations over anencephalic ones in this study shares common characteristics with other reports in the literature (Cohlan 1953; Marin-Padilla and Ferm, 1965; Langman and Welch 1966; Shenefelt 1972; Smith *et al.* 1978; Warkany, 1971; Larroche 1984; Caldarelli *et al.* 1985). This is contrasted to human cases of NTDs that the most distinctive morphological feature is the advanced degenerative process, together with the destruction of the unclosed and exposed areas of the brain (anencephaly). This discrepancy between the experimental NTDs and the clinical ones could be ascribed to the short gestation period in experimental animals. Observing various degrees of degenerative processes and necrosis on the exposed (exencephalic) brains as well as some typical anencephalic features, it was possible to conclude that the classical anencephalic features result from the spontaneous necrosis of the exencephalic malformation. Exencephaly, therefore, represents an early developmental stage of anencephaly.

ACKNOWLEDGEMENT

We would like to thank Dr. Yeon-Lim Suh, Miss Hae Young Choi and all the members of the Department of Pediatric Pathology and Mr. Nam Soo Kim of animal laboratory room for their invaluable

advice and technical assistances during the course of this experiment. We also thank Miss Kyung Sook Choi for her typographic assistance.

REFERENCES

- Anderson SR, Bro-Rasmussen F, Tygstrup I.** Anencephaly related to ocular development and malformation. *Am. J. Ophthalmol.* 1967, 64:559-566
- Caldarelli M, McLone DG, Collins JA, Jun SH, Knepper PA.** Vitamin A induced neural tube defects in the mouse. *Concepts Pediat. Neurosurg.* 1985, 6:161-171
- Cohlan SQ.** Excessive intake of vitamin A as a cause of congenital anomalies in the rat. *Science* 1953, 117:535-536
- Dekaban AS.** Anencephaly in early human embryos. *J. Neuropathol. Exp. Neurol.* 1963, 22:533-548
- Fantal AG, Shepard TH, Newell-Morris L, Moffett BC.** Teratogenic effects of retinoic acid in pigtail monkeys (*Macaca nemestrina*). *Teratology* 1977, 15(1): 65-71
- Giroud A.** Anencephaly. In *Handbook of Neurology*, edited by Vinken PJ & Bruyn GW, North-Holland Publishing company, New York, 1977, 30:173-208
- Goodman DS.** Vitamin A and retinoids in health and disease. *New Engl. J. Med.* 1984, 310(16):1023-1031
- Hendrickx AG, Silverman S, Pellegrini M, Steffek AJ.** Teratological and radiocephalometric analysis of craniocerebral malformations induced with retinoic acid in Rhesus monkeys (*Macaca mulata*). *Teratology* 1980, 22:13-22
- Kalter H, Warkany J.** Experimental production of congenital malformations in strain of inbred mice by maternal treatment with hypervitaminosis A. *Am. J. Pathol.* 1961, 38:1-21
- Khoury MJ, Erickson JD, James LM.** Etiologic heterogeneity of neural tube defects: clues from epidemiology. *Am. J. Epidemiol.* 1982, 115:538-548
- Kochhar DM.** Limb development in mouse embryos. I. Analysis of teratogenic effects of retinoic acid. *Teratology* 1973, 7:289-298
- Kochhar DM, Johnson EM.** Morphological and autoradiographic studies of cleft palate induced in rat embryos by maternal hypervitaminosis A. *J. Embryol. Exp. Morph.* 1965, 14(3):223-238
- Langman J, Welch GW.** Effect of vitamin A on development of the central nervous system. *J. Comp. Neurol.* 1966, 128:1-16
- Langman J, Welch GW.** Excess vitamin A and development of the cerebral cortex. *J. Comp. Neurol.* 1967, 131:15-26
- Larroche JC.** Malformations of the nervous system. In *Greenfield's Neuropathology*, 4th edition, edited by Adams JH, Corsellis JAN, Duchen LW, Wiley Medical Publication, New York, 1984:385-398
- Marin-Padilla M.** Mesodermal alterations induced by hypervitaminosis A. *J. Embryol. Exp. Morph.* 1966, 15(3):261-269
- Marin-Padilla M, Ferm VH.** Somite necrosis and developmental malformations induced by vitamin A in the golden hamster. *J. Embryol. Exp. Morph.* 1965, 13(1):1-8
- McCormick WF.** Is anencephaly a single entity? A brief note on the morphologic heterogeneity of anencephaly. In Bergsman(ed) *Birth defects: Original article series*. Vol 7, National Foundation March of Dimes, New York, 1969:94-96
- McLone DG, Jun S, Collins JA, Poznanski S, Knepper PA.** Neurulation: Biochemical and morphological studies on primary and secondary neural tube defects. *Concepts Pediat. Neurosurg.* 1983, 4:15-29
- Morriss GM, Steele CE.** The effect of excess vitamin A on the development of rat embryos in culture. *J. Embryol. Exp. Morph.* 1974, 32(2):241-250
- Morriss GM.** Morphogenesis of the malformations induced in rat embryos by maternal hypervitaminosis A. *J. Anat.* 1972, 113(2):241-250
- Morriss GM.** Ultrastructural effects of excess maternal vitamin A on the primitive streak stage rat embryo. *J. Embryol. Exp. Morph.* 1973, 30(1):219-240
- Nakamura H.** Digital anomalies in the embryonic mouse limb cultured in the presence of excess of vitamin A. *Teratology* 1978, 16:195-202
- Nakano NK.** Anencephaly: A review. *Dev. Med. Child. Neurol.* 1973, 15:383-400
- Newell-Morris L, Sirianni JE, Shepard TH, Fantel AG.** Teratogenic effects of retinoic acid in pigtail monkeys (*Macaca nemestrina*) II. Craniofacial features. *Teratology* 1980, 22:87-101
- Padgett DH.** Neuroschisis and human embryonic maldevelopment. New evidence on anencephaly, spina bifida and diverse mammalian defects. *J. Neuropathol. Exp. Neurol.* 1970, 29:192-215
- Patten BM.** Embryological stages in the establishing of myeloschisis with spina bifida. *Am. J. Anat.* 1953, 93:365-389
- Sadovnick adm Baird PA.** Congenital malformations associated with anencephaly in liveborn and stillborn infants. *Teratology* 1985, 32:355-361
- Seller MJ, Emburg S, Polani PE, Adinelfi M.** Neural tube defects in curly-tail mice. II. Effect of maternal administration of vitamin A. *Proc. R Soc Lond B.* 1978, 206:95-107
- Shenefelt RE.** Treatment of various species with a large dose of vitamin A at known stages in pregnancy. *Am. J. Pathol.* 1972, 66(3):589-592
- Shenefelt RE.** Morphogenesis of malformations in hamsters caused by retinoic acid: relation to dose and stage at treatment. *Teratology* 1972, 5:103-118
- Smith, Wissinger JP, Smith CG, Huntington HW.** Experimental dysraphism in the rat. *J. Neurosurg.* 1978, 49:725-729
- Smith MT, Huntington HW.** Morphogenesis of ex-

- perimental anencephaly. J. Neuropathol. Exp. Neurol. 1981, 40(1):20-31
- Steele CE, Trasler DG, New DAT.** An *in vivo/vitro* evaluation of excess vitamin A. Teratology 1983, 209-914
- Theodosius DT, Fraser CF.** Early changes in the mouse neuroepithelium preceeding exencephaly induced by hypervitaminosis A. Teratology 1978, 18:219-232
- Warkany J.** Congenital malformations, Notes and comments. Yearbook Medical Publishers, Chicago, 1971:189-243, 273-295, 401-411, 357-361, 621-627
- Wilson JG, Roth CB, Warkany J.** An analysis of the syndrome of malformations induced by maternal vitamin A deficiency. Effects of restoration of vitamin A at various times during gestation. Am. J. Anat. 1953, 92(2):47-95
- Wilson JG, Fraser FC.** Handbook of teratology, Current status of teratology. Plenum Press, New York and London 1974:47-95
- Wilson JG, Warkany J.** Teratology. Principles and techniques. The University of Chicago Press, Chicago and London, 1965:1-20, 251-277
- Yip JE, Gokich VG, Shepard TH.** The effect of high doses of retinoic acid on prenatal craniofacial development in *Macaca nemestrina*. Teratology 1980, 21:29-38

= 국문초록 =

Vitamin A 過量投與가 胎仔의 神經管 缺損에 미치는 영향에 관한 實驗的 研究

서울大學校 醫科大學 神經外科學教室 및 病理學教室

高英超 · 池堤根 · 崔吉洙

人體의 神經管 缺損症은 아직껏 그 發生 原因과 發生機轉이 明確히 밝혀지지 않은, 致死率과 罹患率에 있어서 가장 심각한 中樞神經系 畸形이다. 본 實驗에서는 妊娠한 白鼠에 過量의 비타민 A를 여러가지 條件으로 投與한 후 그 胚仔 및 胎仔에 發生하는 中樞神經系 畸形을 肉眼的, 解剖顯微鏡的 및 病理組織學的 관찰을 通하여 神經管 缺損症의 發生 頻度, 形態 및 발생기전을 추구하고자 하였다.

妊娠한 Sprague-Dawley 系 흰쥐 100마리를 妊娠期에 따른 여러 조건에서 과량(150,000 IU)의 비타민 A를 투여한 후 神經管 缺損症을 비롯한 여러가지 畸形을 유발시켰다. 神經管 缺損症은 주로 外翻腦症 혹은 無腦症의 형태나 脊椎 二分症의 형태로 發生하였다. 中樞 神經系 畸形 외에도 眼球, 外耳, 顔面骨, 四肢, 꼬리, 肛門 및 外性器 畸形이 높은 빈도로 관찰되었는데, 이러한 畸形의 발생빈도와 내용은 비타민 A의 投與 用量 뿐 아니라 投與 時期와도 밀접한 상관이 있었다. 즉 비타민 A 150,000 IU의 用量은 妊娠 白鼠에 상당한 催畸形性을 나타내어, 受胎 제 8, 제 9, 및 제 10 일에 단 1회 投與했을 때 각각 74.4%, 87.0%, 87.4%의 胎仔에서 畸形이 發生하였다.

神經管 缺損症은 受胎 제 8일과 제 9일에 投與했을 때 각각 67.5%와 94.1%의 胎仔에서 發生하였는데, 外翻腦症은 주로 제 8일 투여군에서 발생하였고 脊椎 二分症은 대부분 제 9일 투여군에 발생하여 이들 기형이 뚜렷한 危害時期를 갖고 있음을 알 수 있었다. 神經管 缺損症에는 여러가지 特徵적인 기형이 동반되었는데, 외번뇌증에는, 上·下악 發育不全症과 小眼球症 혹은 無眼球症이 특이하였고, 脊椎 二分症에는 外耳 無形成症, 肛門 閉鎖症 및 꼬리 無形成症이 거의 전 예에서 동반되었으며, 外性器 閉鎖症, 彎曲足, 泌尿生殖系 形成不全症, 人魚體 畸形(sirenomelia) 그리고 尾部 退行(caudal regression)症候群 등의 기형이 동반된 것이 특이하였다.

150,000 IU의 비타민 A는 催畸形性뿐 아니라 높은 胎仔 致死率을 보였는데, 受胎 제 7, 제 8 및 제 9일 투여군의 胎仔 致死率이 각각 39.0%, 40.3% 그리고 23.6%로 대조군 3.7%와 제 10일 투여군의 5.0%에 비해 현저하게 높았다.

150,000 IU의 비타민 A는 胎仔 致死率을 높이고 催畸形性을 보일 뿐 아니라, 受胎 제 7, 제 8 및 제 9일 투여군에서는 胎仔의 전반적인 成長 지연 效果를 나타내어 體重, 兩頭頂徑(biparietal diameter) 및 머리-둔부 길이(crown rump length)가 대조군에 비해 유의하게 작았다.

神經管 缺損症 중에서 外翻腦症의 암수의 성비는 약 2:1로 암컷의 發生頻도가 더 높았으나 脊椎 二分症에서는 이러한 차이가 觀察되지 않은 점이 특이하였다.

形態學的 特徵으로 無腦症의 形態 보다는 外翻腦症의 形態를 보인 예가 大部分으로, 노출된 腦의 壞死와 退行性 病變의 정도에 따라 완전한 外翻腦症에서부터 전형적인 無腦症에 이르기까지 여러 단계의 모습이 觀察되어, 外翻腦症이 無腦症의 前驅 畸形일 可能性을 강력히 시사하였다.

LEGENDS FOR PLATES

- Plate 1.** The control rat fetus, 20 days old.
- Plate 2.** An exencephalic rat fetus of Group II.
- Plate 3.** A typical exencephalic anomaly of Group II. Note associated malformations such as anophthalmia and maxillary/mandibular hypoplasia.
- Plate 4.** An exencephalic rat fetus of Group II. Note anophthalmia, severe mandibular hypoplasia and oblique facial cleft.
- Plate 5.** An exencephalic rat fetus of Group III with spina bifida, tail agenesis and hind limb hypoplasia.
- Plate 6.** The craniorachischitic rat fetus of Group II with marked growth retardation and maxillomandibular hypoplasia.
- Plate 7.** A rather anencephalic rat fetus of Group II.
- Plate 8.** An anencephalic rat fetus with maxillomandibular hypoplasia and anophthalmia.
- Plate 9.** The severest form of anencephaly with association of spina bifida, stunted growth of limbs and face in addition to anophthalmia.
- Plate 10.** A typical malformed fetus of Group III showing spina bifida and tail agenesis.
- Plate 11.** A characteristic malformation of sirenomelia associated with spina bifida, exophthalmos and exencephaly.
- Plate 12.** Another characteristic malformation of caudal regression associated with spina bifida. Note the absence of tail and hind limb.
- Plate 13.** Exophthalmos associated with cleft mandible, spina bifida and club foot deformity.
- Plate 14.** Sirenomelia associated with spina bifida, anophthalmia and anotia.
- Plate 15.** Exophthalmos and low set ear deformity of Group IV rat fetus.
- Plate 16.** A characteristic malformation of micromelic rat fetus of Group IV.
- Plate 17.** Dissecting microscopic view of control rat fetus.
- Plate 18.** Bilateral exophthalmos of Group III rat fetus.
- Plate 19.** Bilateral anophthalmia of Group II rat fetus.
- Plate 20.** Unilateral anophthalmia and exophthalmos of Group III rat fetus.
- Plate 21.** Dissecting microscopic view of exencephalic brain.
- Plate 22.** Exencephalic brain with some necrotic changes along the base.
- Plate 23.** Dissecting microscopic view of spina bifida.
- Plate 24.** Advanced degenerative change with cyst formation under the exposed spinal cord.
- Plate 25.** Photomicrograph of anencephalus, showing a minute amount of brain remnant on hypoplastic sphenoid bone and nasal cavity (Nc). A few papillary projections suggestive of abortive choroid plexus are seen that are directly continuous to the skin surface (arrows in junctions). H&E X70.
- Plate 26.** Microscopic finding of coronal section of orbit, in a case of anophthalmos, showing abortive lens tissue (arrow) and scattered epithelial nests. H&E X100.
- Plate 27.** Transverse section of spine in a case of rachischisis, showing abnormal development of vertebral bone (V) and cartilage, associated with abnormally formed spinal cord (arrow) which is barely covered with skin. H&E X70.
- Plate 28.** Photomicrograph of bifid spinal cord (Sc), exposing central canal as a opened book fashion. Note also abnormal arrangement of neurons versus fibers in this abnormal segment of spinal cord. H&E X70.

