

## Lethal Form of Congenital Short Limbed Dwarfism; (Morphological Analysis of 14 Autopsy Cases) ·

Yeon-Lim Suh and Je G. Chi<sup>1</sup>

*Department of Pathology, Seoul National University Children's Hospital, and Department of Pathology,  
College of Medicine, Seoul National University, Seoul 110, Korea*

**= Abstract =** We examined the clinico-pathologic features and radiographic findings of a total of 14 autopsy cases of congenital short-limbed dwarfism in an attempt to identify the morphological features of diagnostic significance. They included one case each of achondrogenesis type I, achondroplasia, short rib-polydactyly syndrome, chondrodystrophia calcificans congenita, and 3 cases of thanatophoric dwarfism, and 8 cases of osteogenesis imperfecta fetalis. All cases were born dead or died in a first few days of life because of respiratory distress produced by short and narrow thoraces. Birth weights were generally low for their gestational age. A striking feature was the discrepancy between the relatively long, narrow trunk and the extremely short extremities. They had a relatively large head with frontal bossing, and flattened nasal bridge. The pathological observation of these materials demonstrated that the majority of chondrodysplasia were distinct abnormalities in the endochondral ossification. There were subtle but definite differences in the degree of involvement of endochondral ossification. We presented clinical, radiological and morphologic features observed in six different types of osteochondrodysplasia and discussed characteristic differential features of congenital short limbed dwarfism.

**Kew words:** *Skeletal dysplasia, Short limbs dwarfism, Osteogenesis imperfecta achondrogenesis, Chondrodystrophia calcificans congenita, Short rib-polydactyly syndrome, Thanatophoric dwarfism, Achondroplasia.*

### INTRODUCTION

The short limbed dwarfism or dysplasia recognized in a stillborn and newborn infants is a heterogeneous group of conditions characterized by disordered growth of the various components of the skeleton, leading to disproportionate short stature (Sillence *et al.* 1979). These anomalies belong to a condition named the osteochondro-dysplasia or skeletal dysplasia that means abnormalities of cartilage and/or a bone growth and development (Sillence 1975). Among these disorders short limbed dwarfism shows striking discrepancy between the trunk and extremities; markedly short extremities and trunk of essentially normal length. The lethal

form of short limbed dwarfism includes short rib-polydactyly syndrome, thanatophoric dysplasia, lethal perinatal osteogenesis imperfecta, achondrogenesis (Revell 1986). These conditions are incompatible with life because of a respiratory distress producing by associated thoracic abnormalities such as small and short thorax. All reported cases were within either stillborn or died in the neonatal period (Karfman *et al.* 1970). The present nomenclature and distinction of various dysplasia are largely based on the clinical, genetic and radiographic characteristics of each of the dysplasia (Caffey 1978). Therefore, there are many impacts on the description and further delineation of disorder of skeletal growth. Further delineation of these conditions has occurred when specific morphologic defects have been demonstrated (Rimoin

---

<sup>1</sup> Author for correspondence.

*et al.* 1976; Hwang *et al.* 1979). In this investigation, we have reviewed the clinico-pathological features and postmortem radiographs of a total of 14 autopsy cases of congenital short limbs dysplasia in an attempt to identify morphological features of diagnostic significance.

## MATERIALS AND METHODS

Fourteen cases of different forms of short limbs dwarfism obtained from the autopsy files of Department of Pathology, College of Medicine, Seoul National University. They were collected over a period of 18 years (1960 to 1987). They consisted of one case each of achondrogenesis type I, achondroplasia, short rib-polydactyly syndrome, chondrodystrophia calcificans congenita, and 3 cases of thanatophoric dwarfism and 7 cases of osteogenesis imperfecta fetalis. Five out of 4 cases, a case of achondrogenesis, type I and four cases of osteogenesis imperfecta had been previously reported by one of us (Kang *et al.* 1979; Chi *et al.* 1980; Kim *et al.* 1982). We reviewed clinical information and autopsy findings obtained from the autopsy records. External appearance and skeletal characteristics of every case were analysed on the basis of photographs and radiographs taken at the time of autopsy. Microscopic examination of hematoxylin and eosin stained sections was performed on the long bones (femur, tibia, fibula and humerus), all skulls, ribs and vertebrae in some cases. In the glass slide review special attention was paid to the degree of disturbance of cartilage cell maturation in the endochondral plate, together with change of trabeculae in the metaphyses and cortical bone of the diaphyses.

## RESULTS

### 1. Clinical features

Clinical findings including age, sex, gestational age, birth weight, height, head circumference and family history were summarized in Table 1. The majority of patients were born dead or died within the first few days of life. Eleven patients were male. Birth weights were generally low for their gestational age. The overall body length varied from 31.2 cm to 52 cm and the heads were relatively large. There was no family history of dwarfism or other anomalies except for a case of chondrodysplasia calcificans congenita. The patient with chondrodysplasia calcificans congenita had a brother who died immediately postpartum with the same morphologic characteristics.

### 2. External appearance and associated visceral abnormalities

The external appearance of all patients were quite similar. But in the cases of osteogenesis imperfecta there were few similarities with other chondrodysplastic patients. The chondrodysplastic patients showed relatively large head in relation to body and had frontal bossing and depressed nasal bridge (Fig. 1-3). The thorax was narrow and small. The narrow thorax appeared barrel shaped in achondrogenesis rather than pear shaped in the thanatophoric dwarfism. The short rib-polydactyly syndrome showed a narrow and elongated thorax, simulating a cylinder. The abdomen was protuberant in general. The most striking features were shortening of four limbs. The skin of four limbs was thick with abundant subcutaneous fat and had many skin creases. The fingers were short and thick. The thighs were abducted and externally rotated. Fetuses and neonates with osteogenesis imperfecta showed that thighs were characteristically broad and fixed at right angles to the trunk, with short, bent and deformed extremities (Fig. 6). Facial appearance of osteogenesis imperfecta was typical with a marked lack of ossification of the whole cranial vault which by palpation, consisted of numerous small plates of bone. There was the apparent hypotelorism with a small, beaked nose in a somewhat triangular face. The skin was excessively thin and fragile. The case of achondrogenesis showed soft and membranous calvarium, and widely set and bulged eyes. The case of short rib-polydactyly syndrome showed external and visceral anomalies. They included polysyndactyly, cleft lip and palate, and low set and enlarged ears (Fig. 4). The variety of visceral anomalies were dysplastic kidneys, hydrocolpos with urethrovaginal fistula, atresia of both vaginal and urethral orifice, malrotation of intestine with shortened small bowel and colon. The patient with chondrodystrophia calcificans congenita showed generalized dry and scaly skin, especially prominent in the hands (Fig. 5). Also flexion contractures of wrist and ankle joints and fingers were also seen. Both eyeballs showed thin and blue sclera. We could find cerebral gyri through excessively thin dura. The skull bones were fairly thin and easily fractured. In the remaining cases, there was no anomalies except for nonaerated small lungs, microscopically normally developed.

### 3. Postmortem radiographic findings

Thanatophoric dwarfism showed a relatively large

Table 1. Clinical summary of 14 cases of congenital short-limbed dwarfism

Case No(Autopsy No)	Disease	Age/Sex	Gestation age (wks)	Birth weight (gm)	CH/CR length (cm)	HC-CC-AC (cm)	Family history	Remark
1 (A86-24)	Thanatophoric Dwarfism	5hr/M	35	2580	34/	36.5-26-29	Nil	hydramnios
2 (A86-47)	Thanatophoric Dwarfism	3hr/F	32	1450	36/28	28-20-25	Nil	
3 (A86-55)	Thanatophoric Dwarfism	1hr/M	38	2400	38/31	35-25-29.5	Nil	
*4 (RCM # 138)	Achondrogenesis Type I	6min/M	40	2250	38.5/21	32-26-31	Nil	
5 (A76-?)	Achondroplasia	SB/F	37	?	34.5/21	32-26-31	Nil	
6 (A84-45)	Short rib-Polydactyly syndrome	SB/F	36	2470	35/26	32-22-33	Nil	
7 (A87-1)	Chondrodystrophia calcificans congenita	11d/M	38	1400	43/25.3	30.4-20.5-22.5	Sibling	
*8 (RCM # 302)	Osteogenesis imperfecta fetalis	4hr/F	38	1700	39.5/29.5	?	Nil	
*9 (A69-69)	Osteogenesis imperfecta fetalis	10d/M	?	?	?	?	Nil	
*10 (A80-32)	Osteogenesis imperfecta fetalis	ND/M	40	?	52/39	?	Nil	
*11 (A81-55)	Osteogenesis imperfecta fetalis	SB/M	30	855	31.2/27	not checked	Nil	
12 (A83-9)	Osteogenesis imperfecta fetalis	SB/M	32	670	33	not checked	Nil	breach
13 (A83-82)	Osteogenesis imperfecta fetalis	SB/M	?	1275	30/22	35-26-28	Nil	PROM breech
14 (A84-20)	Osteogenesis imperfecta fetalis	ND/M	38	1580	36.5/30.5	29.5-26.7-23.5	Nil	

Key: SB, stillborn; ND, neonatal death; RCM, registry of congenital malformation; CH/CR, crown-heel/crown-rump; HC-CC-AC, head circumference-chest circumference-abdominal circumference; \*published case; PROM, premature rupture of membranes.

head with short base and small foramen magnum. Markedly flattened vertebral bodies and increased intervertebral space characterized the vertebral column (Fig. 7). The ribs were short with wide and cupped ends. The overall pelvic configuration was short and broad with short and broad pubic and ischial bones. The sacrosciatic notch was small. The long bones of extremities were very short, relatively broad and incurved near their ends. Metaphyseal end was flared and irregular. The small bones of the hands and feet were very short and broad. Achondrogenesis showed prominent soft tissue shadow of whole body (Fig. 8) Almost total absence of ossification was noted in the vertebral bodies, pelvic bones, calcaneus and talus. The long bones of extremities, inferior border of the right ribs, clavicle and the right scapula showed partially ossified densities. Achondroplasia showed short, broad and slightly bowed long bones with metaphyseal flaring (Fig. 9). Radiographs of the skull, rib, vertebral body and pelvis of this case were not available. Short rib-polydactyly syndrome showed markedly short and horizontally oriented ribs with widened anterior ends, very short and thick tubular bones with distinct corticomedullary junction, and polydactyly of hands and feet (Fig. 10). Their metaphyseal ends were irregular, somewhat widened and had marked longitudinal spurs, notably the femur, tibia and humerus. The pelvic bone was short craniocaudally with irregular and horizontal acetabular roof. The vertebral bodies appeared normal in shape, but irregular in their margins. The skull base was short. Chondrodystrophia calcificans congenita showed multiple punctate calcific densities in the both proximal epiphyses of humerus, posterior ribs, pubic bone and tarsal bones (Fig. 11). The long bones were slightly shortened with metaphyseal flaring. Small bones of hands and feet were rather short and broad. Osteogenesis imperfecta showed generalized osteoporosis with multiple fractures (Fig. 12). The continuous beading of ribs were noted in 4 cases (9,10,11,14). The facial bones were very poorly ossified. The skull bone showed soft tissue density without ossification and calcification. The long bones were deformed with bowing, angulating and fractures, and showed narrowed central segment of shaft and flared metaphyseal ends.

#### **4. Histopathologic examinations of long bones**

**Thanatophoric dwarfism:** The long bones were very short and broad with thick metaphysis. They

were curved near the metaphyseal-diaphysis junction resembling the telephone-receiver form (Fig. 13). Histologically, the chondro-osseous junction of the long bones showed relatively normal resting cartilage with extensive, generalized disruption of endochondral ossification. In most areas there was no column formation and no orderly progression of chondrocyte evolution (Fig. 18). In some areas, there were slightly increase in the size of chondrocytes that had neither cloning nor halo of new matrix about the clone. There were scattered hypertrophic chondrocytes without column formation, some of which were not degenerated and remained in the provisional calcification zone and bony trabeculae. Vascular invasion of the growth plate occurred at irregular and wide intervals, resulting in an irregular array of short, blunt or slender spicules of endochondral bony trabeculae. In areas horizontally aligned trabeculae and cartilagenous islands were seen. Diaphyses showed well developed periosteal membranous ossification, and its projection beyond metaphyseal margin in the form of bony spur caused a cup-like appearance of the metaphyseal ends.

**Achondrogenesis:** The long bones were very short and stubby with very thick or widened metaphysis. The bowing of bones were not evident. The diaphyses showed cartilagenous density of medullary cavity without normal bone marrow (Fig. 14). Microscopic examination showed markedly disorganized endochondral ossification without normal maturation of chondrocytes. The resting chondrocytes appeared unaltered. There were marked proliferation and enlargement of chondrocytes that failed to align in column. But irregular foci with more columnar arrangement of the chondrocytes were found (Fig. 19). The chondrocytes were large, and there was relative paucity of surrounding matrix. Most of hypertrophic chondrocytes did not degenerate completely, and abnormally extended to a long distance into the bony trabeculae formed from the epiphyseal plate. Therefore the majority of bony trabeculae consisted mainly of hypertrophic chondrocytes and cartilagenous matrix covered by a thin layer of osteoid. The zone of provisional calcification was scarcely seen. The metaphysis could not be defined. Instead, a fibrous band of periosteal membrane interposed between the metaphysis and epiphysis. There were few longitudinal trabeculae and most of these were arranged transversely or were irregularly oriented. The diaphyses were poorly developed, and the trabeculae were abnormally

oriented with islets of cartilage dispersed between them. Some of these trabeculae were haphazardly fused or anastomosed in the diaphyses. The bone marrow was scanty, containing much connective tissue and only few hematopoietic foci. The periosteum was thick, having abundant primitive mesenchymal tissue in some areas. Prominent cupping of the epiphyseal cartilage resulted from prolongation of periosteal cortical bone in the form of bony spur.

**Achondroplasia:** The long bones were decreased in length, the greatest shortening being proximally, and they appeared rather wide and squat with slight bowing. The metaphyses had some flaring. Histologically, the chondro-osseous junction showed irregular and short growth zone with deranged endochondral ossification (Fig. 20). There was deficiency of proliferative chondrocytes. Definite hypertrophic zone was not seen, but some chondrocytes were slightly enlarged in area corresponding to hypertrophic zone. These enlarged chondrocytes were irregularly and singularly scattered without clustering or columnization, and were separated by abundant matrix substance. The growth plate was unevenly invaded by wide vascular marrow process. In metaphyses bony trabeculae were short and thick, and scanty with irregular orientation. Periosteal bone formation was normal and there was periosteal overgrowth resulting in cupping of the epiphyseal cartilage.

**Short rib-polydactyly syndrome:** It showed very short and thick long bones without bowing. The length of epiphyseal cartilage was longer than the width. The tibia was characteristically short with round contour (Fig. 15). Histologically, resting zone contained a large number of round, normal appearing cartilage cells and abundant basophilic matrix. Some of chondrocytes were irregularly in clusters rather than in columns, separated by wide septa of cartilage matrix. There were hypertrophic cartilage with reduced numbers of chondrocytes and disorganized columns. A few of the hypertrophic cells, however, had small areas of fairly regular columnar alignment (Fig. 21). The vascular invasion of the growth plate was uneven. The bony trabeculae in the metaphyses were unevenly stained with hematoxylin and consisted of mainly cartilaginous matrix covered by the thin osteoid. Some of the primary trabeculae were transversely oriented. The epiphyseal cartilage extended laterally toward the diaphysis along the periosteum. The cortical architecture of the diaphysis was normal, but there was cartilage islands in the marrow cavity and in

the subperiosteal area of the diaphysis.

**Chondrodystrophia calcificans congenita:** The long bones were slightly shortened, with relatively expanded epiphyses and slender shafts (Fig. 16). They were fragile, but not bowed. Cut surface showed relatively preserved metaphyseal end. Microscopically, the epiphyses showed irregular and patchy calcification and increased vascularization with areas of myxoid matrix and fibrosis (Fig. 22). The growth plate showed deficiency of proliferative cartilage and small number of hypertrophic chondrocytes without column formation (Fig. 23). A calcification zone was evident and vascular invasion was irregular. The metaphyseal bony trabeculae were slender and decreased in number, and were longitudinally oriented. Periosteal bone formation was evident with rather normal membranous bone.

**Osteogenesis imperfecta:** The long bones were variable in length and width due to deformity and multiple fractures. But the majority of them was extremely short and bent with deformity characterized by multiple fractures and callus formation (Fig. 17). Microscopically, growth plate showed a good degree of organized sequential progression of chondrocyte evolution, proliferation, hypertrophy and calcification. But zones of chondroosseous transformation were severely affected (Fig. 24). Scanty bone was formed at the cartilage scaffold and few primary trabeculae were formed. These trabeculae were very slender with a minimal deposition of the osteoid. The periosteal membrane was prominent with a cellular cambium layer. Many osteoblasts were evident, but their productions were scanty and primitive. Intramedullary trabeculae and callus were composed of primitive woven bone.

## DISCUSSION

The short-limbed dwarfism with rather normal sized head and trunks was described by Parrot in nineteenth century as "achondroplasia" (Warkany 1971). These dwarfs could be distinguished easily from other dwarfs, so that achondroplasia was considered a well defined entity for many decades. With increasing interest in systemic skeletal disorders and through investigation of their pathologic, radiologic and chemical properties, it evolved that the term "achondroplasia" actually covered many different entities such as thanatophoric dwarfism, achondrogenesis, chondrodystrophia calcificans congenita, and osteogenesis imperfecta (Graff 1972). These disorders must be differentiated and



Table 3. Differential features of the 14 cases of congenital short-limbed dwarfism

Disease	Gross Features		Microscopic Features			
		Epiphyseal cartilage	Growth zone	Metaphyseal trabeculae	Periosteal bone	
Thanatophoric dwarfism	telephone receiver like deformity irregular metaphyseal end	unaltered	no proliferating cell, slightly enlarged chondrocyte without columnization	irregularly aligned slender	well formed	
Achondrogenesis type I	ill-defined & thick metaphysis cartilaginous appearance of medullary cavity	unaltered	abnormal increase of proliferative and hypertrophic cells, irregular columnization irregular & scanty provisional calcification zone	haphazardly aligned large chondrocytes and minimal osteoid	primitive mesenchymal tissue	
Achondroplasia	slight bowing	unaltered	deficiency of proliferating cells, some hypertrophic cells without columnization without	irregular array	well formed	
Short rib-polydactyly syndrome type III	no bowing extension of epiphysis along periosteum	periosteal extension laterally	variable segments of hypertrophic cells forming short abortive columns	slender, cartilage island	well formed cartilage islands	
Chondrodystrophia calcificans congenita	no bowing expanded epiphysis thin shaft fragile	irregular vascularization fibrosis, scattered calcifications, pools of myxoid matrix	deficiency of proliferating cells, some hypertrophic cells without columnization	scantly, slender	well formed	
Osteogenesis imperfecta fetalis	deformity, multiple fractures thin shaft, fragile	normal	well organization of endochondral ossification	scanty, slender absence or minimal deposit of osteoid	primitive woven bone	

can be distinguished by their clinicopathologic and radiographical features previously described in the literatures (Langer *et al.* 1967; Han *et al.* 1973). But there are still some debates on some findings described in a number of recent publications (Rimoir *et al.* 1970).

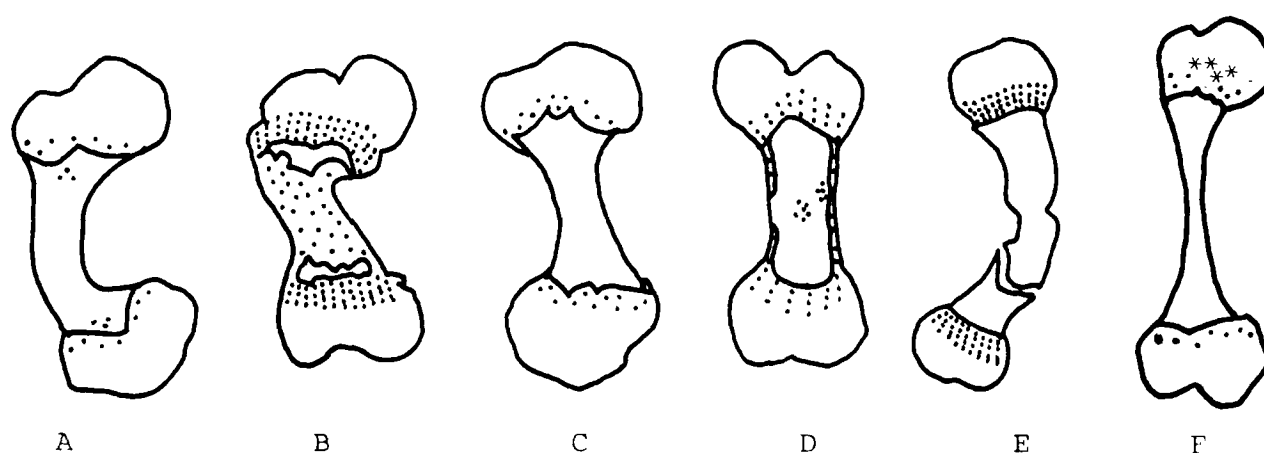
We attempted to draw morphologic features which are helpful in differential diagnosis of the lethal forms of congenital short limbed dwarfism. The differential diagnostic features of these disorders are presented in the Table 2 and 3. The infants with chondrodysplasia showed similar external appearances; shortening of four limbs, relatively large head with frontal bossing and depressed nasal bridge, and protuberent abdomen. But the external appearance of the osteogenesis imperfecta was distinctly different from that of chondrodysplasia. They showed typical facial appearances with hypotelorism, small beaked nose in a triangular face, and excessively fragile and thin skin. Associated anomalies also aid in diagnosis of the short rib-polydactyly syndrome (SRP). This disease consists of a number of lethal skeletal dysplasias, SRP I (Saldino-Noonan), SRP II (Majewski), SRP III (Verma-Nanmoff and others). SRP I is differentiated clinically from SRP II by a high frequency of cloacal abnormalities (anal atresia, urogenital sinus and postaxial polydactyly in the former compared with the high incidence of cleft upper lip or palate, multiple internal anomalies including a hypoplastic epiglottis, cardiovascular defects and pre- as well as postaxial polydactyly in the latter (Richardson *et al.* 1977; Cherstvoy *et al.* 1980). But in SRP II no abnormalities of skull or the spine has been reported. In SRP I tubular bones are structureless, without corticomedullary demarcation, and are pointed at both ends. The cranial base was not shortened. Our case of SRP fit SRP III characterized by short cranial base, forehead bulging, flat nose and occiput, abnormal vertebral column and pelvic bones (Naumoff *et al.* 1977). In chondrodystrophia calcificans congenita ichthyosis and asymmetrical shortening of lower extremity are diagnostic. In association with this abnormality there are usually other defects in reported cases. Congenital cataracts are noted in one-third to one-fourth of all the cases reviewed by Josephson. (Josephson 1961; Hammond *et al.* 1970; Ryan 1970). Cutaneous lesions are noted in approximately 25% of the cases. These are generally of a dyskeratotic variety from seborrheic dermatitis to ichthyosis and follicular atrophoderma with pseudopelade (Selva-

kovich 1956). The clinical, skeletal and pathological characteristics of thanatophoric dwarfism closely resemble those of the achondroplasia.

In the past, thanatophoric dwarfism has been confused with achondroplasia (Langer *et al.* 1969). Practically this confusion exists only in the case of heterozygous achondroplasia in which both parents are of normal stature, similar to the situation existing in thanatophoric dwarfism. The radiological features are distinct to permit differentiation from achondroplasia (Langer *et al.* 1969). In achondroplasia vertebral bodies are not as flat as in thanatophoric dwarfism. The long bones of extremities are not as short as in thanatophoric dwarfism. They are not prominently bowed and do not have irregular flared ends. Distinctive and diagnostic radiographic features are also seen in the achondrogenesis, short rib-polydactyly syndrome, osteogenesis imperfecta, and chondrodystrophia calcificans congenita. Achondrogenesis showed total absence of ossification in the vertebral bodies, sacrum, ischial and pubic bones, calcaneus and talus. Multiple punctate calcific densities in the epiphyseal areas preformed in cartilage are typical radiologic findings of chondrodystrophia calcificans congenita. The radiologic feature often called "stippled epiphyses" is a striking feature in the chondrodystrophia calcificans congenita. However, it is also present in a number of different disorders, including multiple epiphyseal dysplasia, mucopolysaccharidoses, trisomy 18, trisomy 21, anencephaly, cretinism and peripheral resistance to thyroxine. In osteogenesis imperfecta, multiple fractures with callus formation, generalized osteoporosis and thin cortex of long bone seem to be helpful for differentiation.

The long bone is formed through a combination of both processes of intramembranous and endochondral ossifications. The former is responsible for progressive thickening of a diaphyseal shaft, resulting of appositional bone growth from the outer periosteum. The latter is responsible for growth in length. Thus, failure of endochondral ossification is presumably related to a short limbs dwarfism. Endochondral ossification is a highly organized sequential transformation of cartilage into trabecular bone, which occur at the growth end of long bone. The cartilage of growth zone has been divided into resting, proliferative and hypertrophic zones. The latter is itself sometimes subdivided into zones of maturation, degeneration and provisional calcification (Bogumill 1984). Chondrodysplasia represents





- |   |   |
|---|---|
| A: Thanatophoric dwarfism                               | B: Achondrogenesis, type I.                 |
| C: Achondroplasia                                       | D: Short rib-polydactyly syndrome, type III |
| E: osteogenesis Imperfecta Fetalis                      | F: Chondrodystrophia calcificans congenita  |
| ...: degree of cartilage maturation at the growth plate |   |
| ***: abnormal calcification                             |   |

Fig. 25. Differential morphological features of long bone in congenital short-limbed dwarfism.

failure of endochondral ossification, and osteogenesis imperfecta represents abnormal bone formation, both endochondral and intramembranous ossifications. Variations of these basic defects may account for the various forms of congenital short-limbed dwarfism. The characteristic face and nose of the chondrodysplastic patients can be explained as resulting from the stunted growth of the bones of the base of the skull and face, bone which form in part from cartilage, in contrast to the calvarium which ossifies in membrane and develops normally (Ponseti 1970). The pathologic observation of the long bone of these materials demonstrated that the majority of chondrodysplasias are distinct abnormalities in the endochondral ossification. There are subtle differences in the degree of involvement of endochondral ossification among various of these disorders. In some disorders, histopathological abnormalities appear to be characteristic and can be used as diagnostic criteria.

Morphological features of the long bones observed in this study are shown as a schematic drawing (Fig. 25). The height of long bones are well below the normal range for their age in all patients. Thanatophoric dwarfism and osteogenesis imperfecta show extremely short long bone. Bowing is very severe in the thanatophoric dwarfism and osteogenesis imperfecta, and is less severe in the achondroplasia. Metaphyseal cupping is seen in the thanatophoric dwarfism, achondroplasia, chon-

drodystrophia calcificans congenita and achondrogenesis. In these disorders the rate of endochondral ossification appears to be reduced, periosteal ossification is normal and thus relatively increased in rate, resulting in periosteal bone extending past the growth plate onto the periosteum in form of metaphyseal cupping. The metaphyseal cupping is more easily identifiable on the radiologic examination, and is not specific for the diagnosis. Characteristic gross findings for achondrogenesis are as follows; metaphyseal widening, ill-defined and irregular metaphyseal end, cartilaginous appearance of medullary cavity without normal bone marrow and wide band of periosteal connective tissue separated the expanded epiphysis from the adjacent distorted diaphysis. In the cases of thanatophoric dwarfism, chondrodystrophia calcificans congenita and achondroplasia, growth plate seems to be severely affected. The resting zone of these disorders, is unaltered except for the case of chondrodystrophia calcificans congenita, in which stippled periacicular calcifications, areas of mucoid degeneration and fibrosis, and increased numbers of blood vessels in the cartilage canal are seen. These disorders showed deficiency of proliferative and hypertrophic cartilage with lack of columnization. There are only small number of slightly enlarged chondrocytes, and infrequently focal areas of fairly regular columnization of chondrocytes. But this is not followed by orderly hypertrophy.

The case of short rib-polydactyly syndrome shows short zone of proliferative and hypertrophic cartilage with areas of short abortive columns. This cartilage columns show mild degree of divergence from the usual parallel arrangement. The epiphyseal cartilage extending laterally toward diaphysis along the periosteum seems to be characteristic histopathologic finding for short rib-polydactyly syndrome. This histopathologic finding has not been described in the cases reported till now. In the case of achondrogenesis, the zones of proliferative and hypertrophic cartilages are abnormally increased. Large chondrocytes remained in the metaphysis appear to be specific. And it may be related to the defect of matrix calcification with subsequent interfering with degeneration of chondrocyte. From the scanning electron microscopy study by Xanthekos *et al.* (1973), it seems obvious that in Achondrogenesis type I, the defect arises probably in the mesenchyme, thus maturation of chondrocyte, matrix formation and calcification of chondrocyte are defective. Calcification and collagen synthesis in periosteal bone are also affected. Achondrogenesis and thanatophoric dwarfism are previously mistaken for examples of severe achondroplasia (Saldino *et al.* 1971). The clinical features of these two diseases overlap, but they can be clearly separated by the histopathologic findings mentioned above. Achondrogenesis was first described in 1936 by Parenti, who thought this disorder represented a variant of osteogenesis imperfecta (Xanthakos).

The inheritance of these short-limbed dwarf could not be evaluated due to limitation of small number of cases. The present evidence suggests that it most sporadic. The patient with chondrodystrophia calcificans congenita had only one sibling who was presumed to have the same disease. This suggests a possibility of a autosomal dominant inheritance although the parents of affected infant have been apparently normal. In the chondrodystrophia calcificans congenita, the family history is very important because three different conditions may be defined clearly by their inheritance pattern. The three genetic conditions that can be distinguished are a severe autosomal recessive rhizomelic form, an autosomal dominant form (Conradi-Hünermann), and a mild, recently delineated, X-linked form. The present case is inherited in autosomal dominant fashion on the basis of family history as well as asymmetry of extremities, particularly in the lower limbs. The latter is characteris-

tic for the dominantly inherited variety. In the rhizomelic type extremities is symmetrically shortened and is more severe in degree. Achondroplasia is known to be inherited as an autosomal dominant trait, and achondrogenesis and short rib-polydactyly syndrome as an autosomal recessive trait, although the majority of cases are of sporadic occurrence (Ornøy *et al.* 1976; Chervovoy 1980). Osteogenesis imperfecta fetalis is recessive and is the most frequent form to affect the patients who are usually stillborn or die during the neonatal period (Sillence 1981).

In view of the diagnostic value of chondroosseous morphology in the differentiation of the lethal skeletal dysplasia, meticulous postmortem examination is mandatory. Specimens from the growth plate, i.e., costochondral junction, long bones, vertebral body, iliac crest, should be preserved for morphologic study including electron microscopic study, as these tissues are not always examined as part of the routine autopsy. Furthermore since the present nomenclature and distinction between various dysplasia are largely based on the radiographic findings, a full series of skeletal radiographs are needed for the differential diagnosis. These views should include anteroposterior and lateral views of skull, chest and spine, and anteroposterior views of the pelvis and extremities with separate views of hands and feet. Because many of these skeletal dysplasia are very rare in occurrence it may take long times to collect a number of sample sufficient to document their characteristic morphologic abnormalities. In view of these problems, it is essential to establish a national registry for the collection, processing and analysis of chondro-osseous tissue in the group of disorders.

## REFERENCES

- Bogumill GP, Schwamm HA. Orthopedic pathology. A synopsis with clinical and radiographic correlation. W. B. Saunders Company, Philadelphia, 1984
- Cathey J. Pediatric x-ray diagnosis. 7th edition, Year Book Medical Publishers, London, 1978
- Chervovoy ED, Lurie IW, Shved IA, Lazjuk GI. Ostrowskaya TI, Usoev SS. Difficulties in classification of the short rib-polydactyly syndromes. Eur. J. Pediatr. 1980, 133:57-61
- Chi JG, Kim JR, Lee JB. Osteogenesis imperfecta congenita. Two autopsy case report. Seoul J. Med. 1980, 21:209-217
- Graff G, Chemke J, Lancet M. Familial recurring thanatophoric dwarfism. Obstet. Gynecol. 1972, 39:515-520

- Hammond A.** Dysplasia epiphysialis punctata with ocular anomalies. *Brit. J. Ophthal.* 1970, 54:755-758
- Han CW, Rha CP, Rha JY.** Case of achondroplasia. *New Medical J.* 1973, 16:135-138
- Hwang WS, Tock EPC, Tan KL, Tan LKA.** The pathology of cartilage in chondrodysplasias. *J. Methol.* 1979, 127:1-18
- Josephson BM, Oriatti MD.** Chondrodystrophia calcificans congenita. Report of a case and review of the literature. *Pediatr.* 1961, 28:425-435
- Kang MJ, Chi JG, Park WJ.** Achondrogenesis type 1. An autopsy case report. *J. Korean Med. Assoc.* 1979, 22:389-397
- Kaufman RL, Rimoin DL, McAlister WH, Kissane JM.** Thanatophoric dwarfism. *Amer. J. Dis. Child.* 1970, 120:53-57
- Kim WH, Lee BD, Chi JG.** Osteogenesis imperfecta type II. Two autopsy cases. *Seoul J. Med.* 1982, 23:501-508
- Langer LO Jr, Baumann PA, Gorlin RJ.** Achondroplasia. *Am. J. Roentgenol.* 1967, 100:12-26
- Langer LO Jr, Spranger JW, Greinacher I, Herdman RC.** Thanatophoric dwarfism. *Radiology* 1969, 92:285-294
- Naumoff P, Young LW, Mazer J, Amortegui AJ.** Short rib-polydactyly syndrome type 3. *Radiology.* 1977, 122:443-447
- Ornoy A, Sekeles E, Smith P, Simkin A, Kohn G.** Achondrogenesis type 1 in three sibling fetuses. Scanning and transmission electron microscopic studies. *Am. J. Pathol.* 1976, 82:71-84
- Ponseti IV.** Skeletal growth in achondroplasia. *J. Bone Joint Surg.* 1970, 52:701-716
- Revell PA.** Pathology of bone. Springer-Verlag, Berlin Heidelberg New York Tokyo, 1986
- Richardson MM, Beaudet AL, Wagner ML, Malini S, Rosenberg HS.** Prenatal diagnosis of recurrence of Saldino-Noonan dwarfism. *J. Pediatr.* 1977, 91:467-473
- Rimoin DL, Hughes GN, Kaufman RL, Rosenthal RE, McAister WH, Silberberg R.** Endochondral ossification in achondroplastic dwarfism. *New Engl. J. Med.* 1970, 283:728-735
- Rimoin DL, Silberberg R, Hollister DW.** Chondro-osseous pathology in the chondrodystrophies. *Clin. Orthop.* 1976, 114:137-152
- Ryan H.** Cataracts of dysplasia epiphysialis punctata. *Brit. J. Ophthal.* 1970, 54:197-199
- Saldino RM.** Lethal short-limbed dwarfism: achondrogenesis and thanatophoric dwarfism. *Am. J. roentgenol.* 1971, 112:185-197
- Selvakovich WG, White JW.** Chondrodystrophia calcificans congenita. *J. Bone and Joint Surg.* 1955, 37-A:1271-1277
- Sillence D.** Genetic skeletal dysplasias. In Vaughan VC, McKay RJ, Nelson WE (Ed) *Nelson textbook of pediatrics*, 3rd edition, W. B. Saunders Company, Philadelphia, 1975:pp.356-369
- Sillence D.** Osteogenesis imperfecta. An expanding panorama of variants. *Clin. Orthop.* 1981, 159: 11-25
- Sillence DO, Horton WA, Rimoin DL.** Morphologic studies in the skeletal dysplasias. *Am. J. Pathol.* 1979, 96:813-870
- Warkany J.** Congenital malformations. Notes and comments. Year Book Medical Publishers, Chicago, 1971:pp.767-779
- Xanthakos UF, Rejent MM.** Achondrogenesis: Case reports and review of the literature. *J. Pediatr.* 1973, 82:658-663

= 국문초록 =

## 단지층을 특징으로 하는 선천성 골격 이형성증 (14부검례의 형태학적 분석)

서울대학교 의과대학 병리학교실 및 서울대학교 병원 소아병리과

서연림 · 지제근

골격 이형성은 연골 및 골의 성장과 발달이상으로 골격계의 여러구성요소간에 성장불균형을 초래한다. 이들은 임상 및 방사선 소견으로 구분이 가능한 여러유형의 이종 질환들로 구성되어 있으므로 감별진단을 필요로 하며 이들에 대한 형태학적 연구는 정확한 진단과 발생기전을 밝히는데 큰 역할을 한다.

저자들을 출생전 또는 직후에 사망한 치명적인 유형의 심한 단지층을 특징으로 하는 선천성 골격형성장애를 보였던 14부검례를 토대로 그들의 외부소견 및 장골의 형태학적 특성과 사후 X-선 소견을 기술하였고 감별진단에 도움이 되는 형태적 특성에 관하여 토의하였다. 관찰대상에 무연골형성증 제1형, 연골발육부전증, 선천적 석회화 연골 이형성증, short rib-polydactyly syndrome 각각 1례와 Thanatophoric dwarfism 3례 및 선천성 골형성 부전증 6례였다. 이들은 저체중아로 대부분 출생전후에 사망하였고 선천성 석회화 연골 이형성증은 상염색체성 우성 유전을 시사하는 가족력이 있었다. 이들의 몸통은 정상크기이나 상하지가 모두 짧고 머리가 상대적으로 크고 전두부 돌출과 납작한 코와 작고 짧은 흉곽들을 특징으로 하였다. 선천성 골형성 부전증은 삼각형 모양의 얼굴과 작고 뾰족한 코, hypotelorism, 그리고 얇은 피부를 보였다.

장골의 병리조직학적 검사를 통해 연골 이형성증은 모두 연골내 골화과정에 특히 연골세포의 성숙과정에 결손 및 이상소견을 보였다. 특히 thanatophoric dwarfism, 연골발육부전증, chondrodystrophia calcificans congenita에서 그 정도가 심하여 증식 및 성숙 연골세포 및 골주화가 거의 없었다. Chondrodystrophia calcificans congenita는 골단 연골내 혈관의 증식, 섬유화 연골기질의 점액양 변성 및 석회화가 특징적이었다. Short rib-polydactyly syndrome은 부분적으로 연골세포의 수는 감소되었으나 정상적인 연골 골화 과정을 보였고, 골단연골이 양측 골막을 따라 연장되었다.

무연골형성증은 증식 및 비후성 연골세포의 수가 정상보다 증가되어 있으나 규칙적인 배열이 없고 일시적 석회화대가 거의 없었다. 선천성 골형성 부전증의 골단부는 정상 연골내 골화를 보였으나 연골에서부터 골로 전환되는 일차골주와 골막하 골의 형성이 미약하였고 대개 섬유골로 구성되었다.

감별진단에 도움이 되는 X-선 소견으로 thanatophoric dwarfism은 극도로 납작한 척추와 상대적으로 넓어진 척추간격이 연골발육부전증과 감별되는 특징이었다. 무연골형성증은 늑골과 쇄골일부만 골형성이 있고, 두개골, 상하지골, 척추 및 골반골의 골화가 없었다. 선천성 골형성 부전증은 다발성 골절과 가골형성 골다공증 및 두개골의 골화가 없는 점등이 감별에 도움을 준다. Short rib-polydactyly syndrome은 수반된 기형이 진단에 도움을 주는데 다지증, 토순 및 구개파열, 비뇨생식기 및 소화관의 기형을 수반하였다.

## LEGEND FOR FIGURES

- Fig. 1. Thanatophoric dwarf (case 2). Note the relatively large head, depressed nasal bridge, small and narrow thorax and extremely short limbs.
- Fig. 2. Achondrogenesis patient. External appearance showing narrow thorax, distended abdomen, marked micromelia and excessive skin folds.
- Fig. 3. Achondroplastic patient. Note the relatively large head with frontal bossing, flat nose, small thorax and short limbs.
- Fig. 4. Patient with short rib-polydactyly syndrome. Note the polysyndactyly, cleft lip and palate, low set ears, cylindrical thorax and micromelia.
- Fig. 5. Infant with chondrodystrophia calcificans congenita. Note the large head with frontal bossing, low set ear, depressed nasal bridge, asymmetrical shortening of lower extremities with joint contractures and pigmented scaly skin.
- Fig. 6. Infant with osteogenesis imperfecta. External appearance showing marked deformity of the extremities and peculiar face.
- Fig. 7. Lateral projection of thanatophoric dwarf (case 2), showing short limbs with metaphyseal flaring, shortened skull base and ribs, and extremely flattened vertebral bodies, and markedly increased intervertebral spaces (inset).
- Fig. 8. Postmortem x-ray of achondrogenesis patient showing no demonstrable bony densities of whole body.
- Fig. 9. Specimen radiograph of lower limb of achondroplastic infant showing shortening, slight bowing and metaphyseal flaring.
- Fig. 10. Postmortem radiograph of short rib-polydactyly syndrome patient. Anterior-posterior projection showing extremely short ribs, shortened and squared iliac wing, vertebra with irregular outline and shortening of long bones.
- Fig. 11. Postmortem radiograph of infant with chondrodystrophia calcificans congenita showing multiple punctate calcific densities in the upper humeral epiphysis, posterior rib, acetabular region of the pelvis and tarsal bone.
- Fig. 12. Postmortem radiograph of infant with osteogenesis imperfecta (case 12). Extremity bones and ribs show multiple fracture and deformity. Basal skull and jaw bones are barely seen in the head.
- Fig. 13. Long bones of upper and lower extremities of thanatophoric dwarf (case 2), showing marked shortening and bowing.
- Fig. 14. Cut surfaces of femur in the achondrogenesis patient (left) and in age matched newborn infant. Note the ill-defined metaphyseal end and cartilagenous appearance of marrow cavity.
- Fig. 15. Specimen radiograph of long bones of four limbs of short rib-polydactyly syndrome showing shortening without bowing, metaphyseal widening and extension of epiphyseal cartilage along periosteum.
- Fig. 16. Long bones of lower limb of chondrodystrophia calcificans congenita patient showing slender and fragile shaft and relatively expanded epiphysis.
- Fig. 17. Specimen radiograph of long bones of osteogenesis imperfecta patient (Case 10) showing deformity with multiple fractures and callus formation, thin cortex and osteoporosis.
- Fig. 18. Thanatophoric dwarf. Photomicrograph of epiphyseal growth plate from femur showing lack of orderly endochondral ossification and irregularly oriented bony trabeculae. (H&E, X100)
- Fig. 19. Achondrogenesis. Section of proximal femur showing abnormally increased numbers of proliferating and hypertrophic chondrocytes with areas of column formation and abnormal extension into the bony trabeculae. The zone of provisional calcification is not seen. (H&E X40)
- Fig. 20. Achondroplasia. Costochondrial junction of femur showing deficiency of proliferative and hypertrophic chondrocytes with no columnization. (H&E, X100)
- Fig. 21. Short rib- polydactyly syndrome. Growth plate from femoral epiphysis showing hypertrophic cartilage with reduced numbers of chondrocytes and small areas of fairly regular columnar alignment. (H&E X100)
- Fig. 22. Chondrodystrophia calcificans congenita. Epiphysis of the femur showing large numbers of cartilage canal with fibrosis and areas of calcification (arrowhead). (H&E X100)
- Fig. 23. Chondrodystrophia calcificans congenita. Growth plate of femoral epiphysis showing markedly disorganized endochondral ossification. (H&E X100)
- Fig. 24. Osteogenesis imperfecta. Growth plate of femoral epiphysis showing well organized of cartilage maturation with abnormal chondro-osseous transformation. Few primary trabeculae are formed and are very slender with minimal deposit of osteoid. (H&E, X100)



