

Brainstem Auditory Evoked Responses in Brainstem Stroke

Jong Sung Kim, Kwang Woo Lee and Ho Jin Myung

Department of Neurology, College of Medicine, Seoul National University, Seoul 110, Korea

Abstract—Brainstem auditory evoked responses (BAERs) were studied in eighteen patients with brainstem strokes, and the results were correlated with the clinical and radiological localization.

The absence of all ipsilateral waves (or all except wave I) was caused by acute, relatively extensive lesions impinging on the inferolateral part of the pons.

The late wave abnormalities (III-V delay or poor wave V formation) which more often occurred on the contralateral side of the lesions, generally resulted from dorsally situated pontomesencephalic lesions.

The pontomesencephalic lesions sparing dorsal or inferolateral areas as well as medullary lesions tended to produce normal BAERs.

We conclude that BAER is an effective clinical aid in localizing brainstem stroke if it is interpreted with respect to the three dimensional brainstem auditory pathway.

Key words: BAER, Brainstem stroke, Localization

INTRODUCTION

There are few convincing diagnostic aids in evaluation of brainstem strokes especially the ischemic ones. Among them BAER has recently emerged as a potentially useful test, and is claimed by some to supercede CT scan in sensitivity (Faught and Oh 1985).

The five subsequent wave forms of BAER have been the subject of investigation in the hope that each wave could be correlated with a specific anatomic structure. Evidences to date, although subject to oversimplification, indicate that the primary generators of waves I,II,III,IV, and V are the eighth nerve, the cochlear nucleus, the superior olivary complex, the lateral lemniscus, and the inferior colliculus respectively (Starr and Achor 1975; Stockard and Rossiter 1977; Hashimoto *et al.* 1979).

However, clinical application of this rule is not simple since there are at least three levels of crossings in brainstem auditory pathway (Crosby *et al.* 1962). The majority of human clinicopathologic studies indicate that at least the first four waves of BAER are generated ipsilateral to the active ear (Chiappa *et al.* 1980; Brown *et al.* 1981; Stern *et*

al. 1982; Faught and Oh 1985). But the results are not consistent with respect to the laterality of wave V.

Another unsettled matter even in the largest series, is whether or not BAER has any value in rostrocaudal localization. The good rostrocaudal correlation between brainstem signs and abnormal BAERs observed by Faught and Oh (1985) is at variance with the series published by Stern *et al.* (1982).

In an attempt to resolve some of these questions, the authors correlated the BAER results to the clinical and radiological localization in eighteen patients with brainstem strokes.

MATERIALS AND METHODS

Patient selection

The study population consisted of eighteen patients with brainstem strokes who were admitted to the Neurology Service of Seoul National University Hospital. Their ages ranged from 24 to 70 (mean 55). Twelve were males and six were females. All underwent BAER evaluation, three of them on two occasions. Detailed neurological examination was done on each patient by the same physician

Table 1. Clinical features and summary of BAER abnormalities

Case no. (Sex/Age)	Main clinical features	Lesion (Horl)*(+ or -)**	Right BAER	Left BAER
1 (F/60)	Vertigo, Hoarseness Rt;facial paresthesia, Ataxia Lt;Limb hypesthesia	Rt lateral medulla (I)(-)	Normal	Normal
2 (M/35)	Vertigo Rt;Horner syndrome, Ataxia Lt;Limb hypesthesia	Rt lateral medulla (I)(-)	Normal	Normal
3 (M/55)	Vertigo, Hoarseness RtLimb hypesthesia Lt;Horner syndrome, Ataxia	Lt lateral medulla (I)(-)	Normal	Normal
4 (M/61)	Rt;Internuclear ophthalmoplegia, De- creased soft palate movement	Rt medial-dorsal pons (I)(-)	Normal	Normal
5 (M/24)	Rt;Facial palsy Lt;Hemiparesis	Rt inferior-lateral pons (I)(-)	Normal	Normal
6 (M/67)	Dysarthria, Dizziness Lt;Limb paresthesia, Ataxia	Rt paramedian mid pons (H)(+)	Normal	Normal
7 (M/50)	RT;Hemiparesis, Facial palsy	Lt medial mid- pons(I)(-)	Normal	Normal
8 (F/63)	Rt;Hemiparesis, Facial palsy	Lt medial mid- pons(I)(+)	Normal	Normal
9 (M/28)	Horizontal gaze palsy Rt;Hemiparesis, Hypesthesia Lt;Facial palsy, Ataxia	Lt inferolateral mid-dorsal pons (H)(+)	Normal	Normal
10 (F/51)	Eyeball deviation to Lt., Auditory hal- lucination Rt;Horner syndrome, Facial palsy, Facial hypesthesia Lt;Hemiplegia, Hypesthesia	Rt inferolateral mid-dorsoventral pons (H)(+)	No potentials except wave I Prolonged III-V# Poor wave V	Prolonged III-V Poor wave V Prolonged III-V# Poor wave V
11 (M/55)	Deep stupor Lt;Hemiplegia	Rt lateral ventral pons (I)(+)	No potentials Normal#	Prolonged I-III Poor wave III Normal#
12 (M/48)	Semicoma Horizontal gaze palsy Ocular bobbing	Central medial- dorsal pons (H)(+)	Prolonged III-V Poor wave V	Prolonged III-V Poor wave V
13 (M/65)	Stupor, Eyeball deviation to Rt Rt;Hemiplegia Lt;Suspicious third nerve palsy	Lt dorsoventral ponto-midbrain (H)(+)	Prolonged III-V Poor wave III and V	No potentials
14 (M/48)	Rt;Hemihypesthesia, Ataxia Lt;One and a half syndrome	Lt superomedial dorsal pons (H)(+)	Poor wave V	Prolonged III-V

Table 1. (continued)

Case no. (Sex/Age)	Main clinical features	Lesion (Horl)*(+or-)**	Right BAER	Left BAER
15 (M/70)	Rt;Hemiparesis, Hypesthesia Lt;One and a half syndrome	Lt mid-superior medial dorso- ventral pons (l)(+)	Prolonged III-V Poor wave V	Prolonged I-V Poor wave V
16 (F/66)	Rt;Hemiparesis Lt;Third nerve palsy	Lt midbrain (l)(-)	Normal	Normal
17 (M/38)	Lt;Third nerve palsy	Lt midbrain (H)(+)	Prolonged I-V Poor wave V Normal#	Prolonged I-III Poor wave III Prolonged I-III#
18 (F/57)	Rt;Third nerve palsy Lt;Hemiparesis	Rt midbrain (l)(+)	Poor wave V	Normal

* H or l; Hemorrhage or infarction

** + or -; Detected by CT scan or not

#; The results obtained several weeks after the initial one

(J.S.Kim) at the time when BAER was performed. All had a CT scan, and six of them also underwent MRI scanning. In only one of the eighteen patients, was there a failure of correlation between the clinical signs and the radiological findings. The principal sites of involvement were identified as midbrain, pons, medulla. When possible, involved areas were further subdivided as to dorsoventral and mediolateral aspects according to the description of Adams and Victor (1985).

The clinical findings are summarized in Table 1.

BAER Method

The test machine used was the Nicolet Pathfinder II. The BAER was recorded simultaneously from a central vertex (Cz) electrode referred to the ear ipsilateral to the click stimulus (Ai), and in a separate channel, to the ear contralateral to the stimulus (Ac). Ground electrodes were placed on the forehead.

The auditory stimulus employed was a square wave rarefaction click with a pulse duration of 0.1 msec. The stimulus was presented monaurally at a rate of 11.1 per second. The click intensity was 60dB above the patient's subjective threshold. In three patients who were too drowsy to obtain a reliable and reproducible threshold, an absolute 95dB click sound was used. The contralateral ear was masked with white noise at 40dB less than the intensity of the click stimulus.

The responses were amplified to a gain of 10^4 , and filtered with a bandpass of 150 to 3000 Hz. More than 2000 trials were done at each time, and two obtained responses were superimposed to de-

monstrate reproducibility.

The results were compared to our normative data from thirty volunteers of various ages. Latencies were judged as prolonged when the normal mean was exceeded by two standard deviations. Since all of the patients in the series had intrinsic brainstem lesions, prolonged interpeak latencies between the two waves were more emphasized than the delays of individual waves. Generally no comment was made about amplitude. Instead, when the wave forms were barely detectable or two superimposed waves did not correspond, they were interpreted as 'poor wave formation'

RESULTS

Eight of the 18 patients in the study group exhibited various abnormalities in brainstem auditory evoked responses. The BAER findings are summarized in Table 1.

1. Total absence of ipsilateral wave formation

Three patients with pontine lesions showed absence of ipsilateral wave I,II,III,IV,V (case 11,13) or all waves except wave I (case 10). Two (case 10,13) had hemorrhage, and the other one, infarction. Patient 10 complained of auditory hallucination, and the other two were stuporous. In all of them, clinical and radiological findings indicated relatively extensive ipsilateral lesions encompassing inferolateral portion of the pons where cochlear nuclei are believed to be located.

These abnormalities were not persistent. Follow up BAERs performed on two of the cases, reverted to normal (case 11), or showed prolongation of

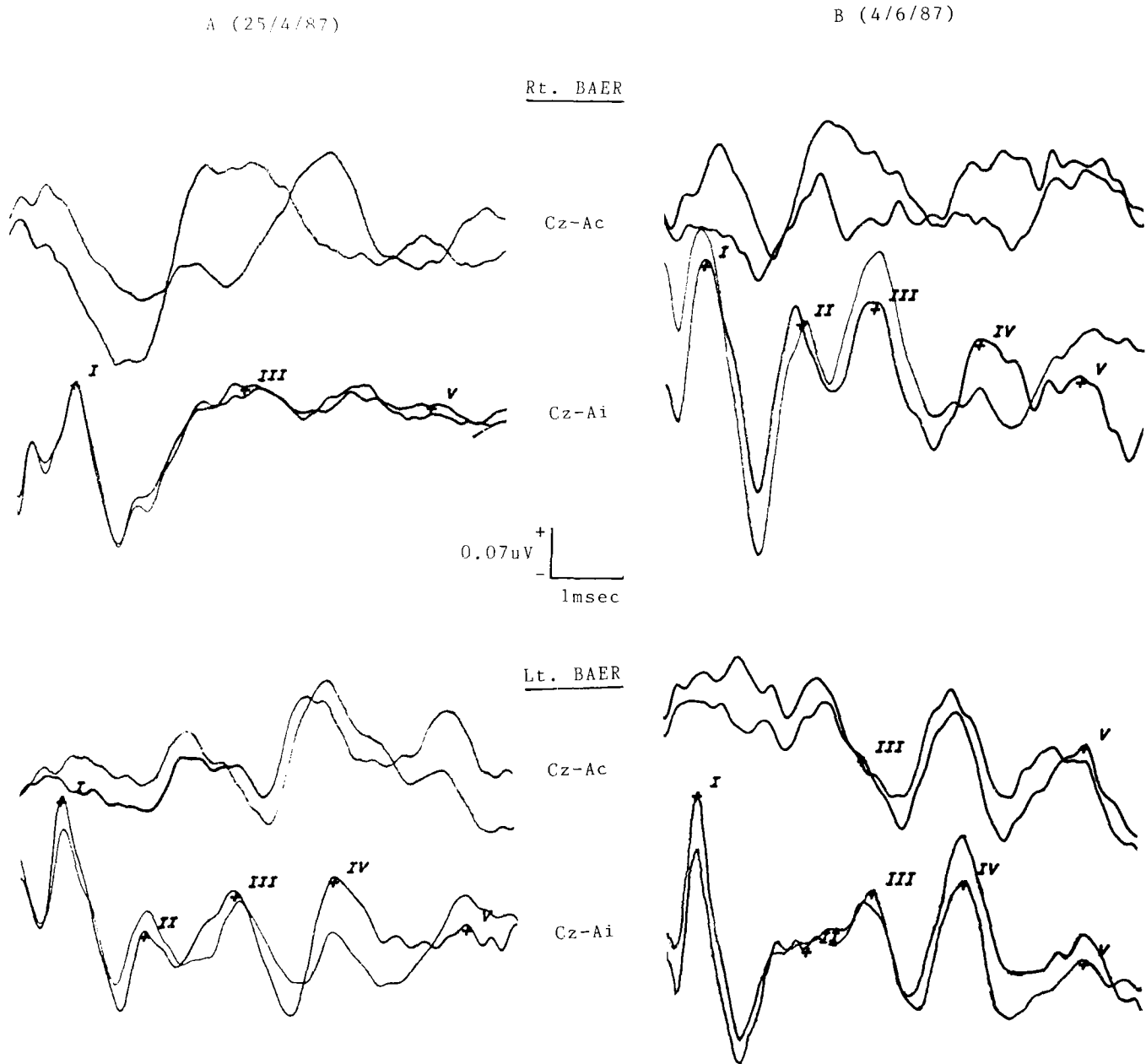


Fig. 1. BAER findings in patient 10 with right lateral pontine hemorrhage. Initially (A), no waves after wave I are identifiable in Cz-Ai recording of right BAER, and III-V interpeak latency is prolonged in Cz-Ai recording of left BAER. 40 days later (B), early waves are restored in right BAER, but III-V interpeak latencies remain prolonged in bilateral Cz-Ai recordings.

III-V interpeak latency with poor wave V formation (case 10, Fig. 1).

2. Prolongation of interpeak latencies

All three pontine lesions with absence of ipsilateral wave generation produced the prolongation of I-III (case 11), or III-V (case 10,13) interpeak latencies in contralateral recording montage although clinical signs were restricted to one side. Other pontine lesions did not produce I-III prolongation or wave III abnormalities. A man with midbrain hemorrhage was the only one who showed ipsilateral I-III delay and poor wave III formation. Follow up test two weeks later still re-

vealed I-III prolongation, but the shape of the wave III was restored (case 17, Fig. 2).

All five patients with III-V delay suffered from pontine strokes impinging on dorsal area where center for horizontal eye regulation is thought to be located (case 10,12,13,14,15). As to the laterality of III-V delay, the abnormalities reside in ipsilateral (case 14), contralateral (case 15), bilateral (case 10), and contralateral or bilateral (case 13) side of the lesions. In case 12, where the lesion was located in midline, late waves were abnormal bilaterally (Fig. 3).

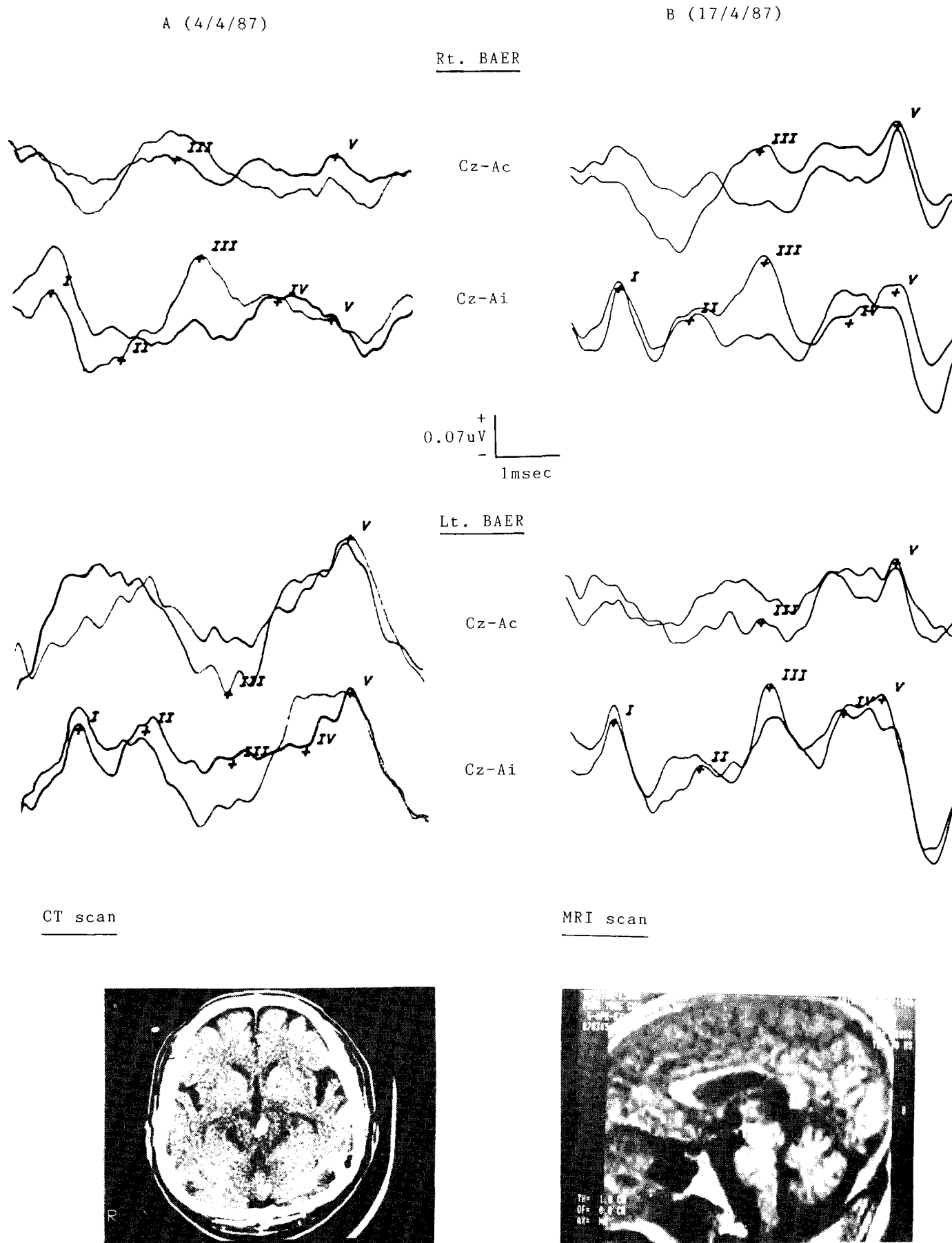


Fig. 2. BAERs, CT scan, and MRI scan in patient 17. CT and MRI scan show a tiny hemorrhage restricted in the left midbrain. The initial BAERs (A) reveal poor wave III formation with prolonged I-III interpeak latency in Cz-Ai recording of left BAER, and poor wave V formation in Cz-Ai recording of right BAER. 13 days later (B), abnormal waves are restored, but slight prolongation of I-III interpeak latency remains.

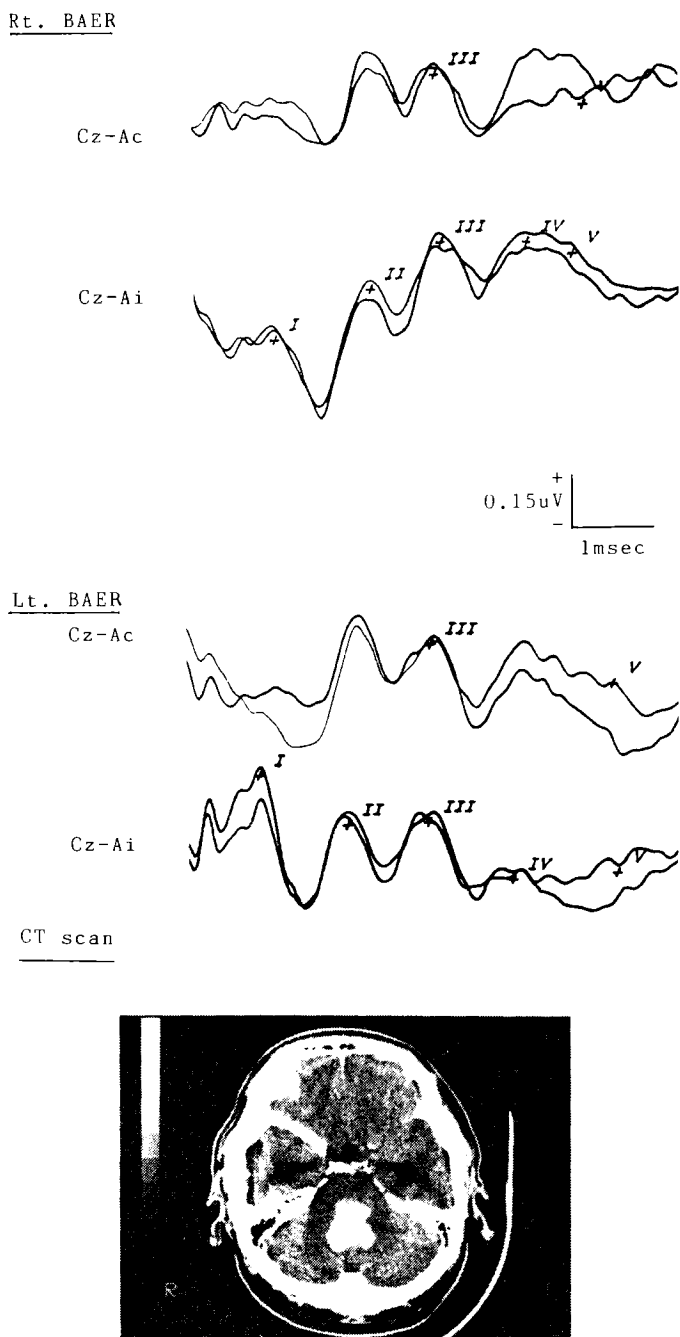


Fig. 3. BAERs and CT scan in patient 12. CT scan shows dorsally situated pontine hemorrhage. BAERs reveal abnormalities of the late waves (poor wave V formation, III-V interpeak prolongation) bilaterally.

3. Poor wave formation of wave III or V

The two deep stuporous patients who showed total absence of ipsilateral wave forms (case 11,13) revealed contralateral poor wave III formation. Except them, abnormality of wave III was observed only in the early test of case 17 as mentioned above.

All five cases of pontine lesions with III-V prolongation showed poor wave V on the side of the prolonged interpeak latencies except case 14, the

only one with III-V delay on the same side of the lesion. Thus, with respect to the laterality of wave V, none showed abnormalities on the ipsilateral side of the pontine lesions.

Poor wave V formation was also observed in two patients with midbrain strokes (case 17,18), where III-V interpeak latencies were within normal range. In case 17, where I-III prolongation with poor wave III formation was also shown ipsilaterally, the wave V abnormality was on the contralateral side of the lesion, and was transient (Fig. 2). In case 18, however, it was on the same side as the lesion.

4. Normal BAER findings in brainstem stroke

All three patients with lateral medullary syndromes (case 1,2,3) exhibited normal BAERs.

Among twelve patients with pontine lesions, six revealed no abnormalities. In three of them (case 6,7,8), the lesions did not involve the dorsal or lateral part of the pons. In case 4 and 5, although they showed clinical evidence of dorsal or infero-lateral involvement, the symptoms were restrictive and transient. Besides, the lesions were so small as to escape CT detection. In another young man (case 9), who showed various clinical signs including dorsolateral pontine syndromes, the BAER was not performed until one year after the initial stroke so that the initial BAER abnormalities, whatever they might have been, were possibly resolved.

Among three patients with midbrain strokes, one woman with a left Weber syndrome showed normal BAER finding (case 16). Her symptoms were transient, and the CT finding was normal as opposed to the other two cases.

DISCUSSION

Although the correlation between clinical findings and BAER abnormalities has been studied extensively, the results vary from study to study (Starr and Achlor 1975; Gilroy *et al.* 1977; Stockard and Rossiter 1977; Hashimoto *et al.* 1979; Chiappa *et al.* 1980; Kjaer 1980; Lee *et al.* 1987). The discrepancies stem mainly from several, generally unavoidable problems.

First, BAER waves may be dependent on multiple rather than single generators as suggested by several authors (Hashimoto *et al.* 1981; Achor and Starr 1980a; Achor and Starr 1980b). Allen and Starr (1978), working with monkey scalp recordings, concluded that wave I and V represented single generator, but other three, bilateral structures.

Second, as Stern *et al.* (1982) noticed, in pa-

tients with totally absent wave generation or disrupted wave III, interwave latency measurement is frequently difficult or impossible.

Third, brainstem lesions, especially the hemorrhagic ones, may compress surrounding structures in various directions, thus yielding confusing results.

Fourth, the time interval between the onset of the stroke and BAER examination was not constant in previous studies. Since BAER abnormalities can be changed in the early stage of stroke as seen in case 10,11, and 17, the results obtained from BAERs performed at different intervals in the different courses of the patients are not quite valid for comparison.

Finally, since the brainstem auditory pathway is a three dimensional one, the dorsoventral and mediolateral aspects must also be evaluated in addition to rostrocaudal one. This approach has been generally ignored in many of the previous series, especially the large ones.

Although this study does not avoid all of these shortcomings, by analyzing the individual findings in detail, we were able to avoid at least the last detractor. As a consequence, we believe that several facts are made more clarified.

As for the laterality of wave V, the previous results were conflicting. Faught and Oh (1985) reported that in the patients who had delays of wave V, the delay was observed only with the stimulation of the ear ipsilateral to the stroke. But Chiappa (1983), showing three pontine strokes with absence of wave V on the contralateral side of the lesions, suggested restricted, high focus lesion may produce abnormalities, more marked contralaterally.

In our study, among six patients with poor wave V formation, including the one with III-V delay on the same side as the lesion, the side of the abnormalities was generally contralateral or bilateral to the main lesion. The only one exception was case 18 with a right Weber syndrome. These inconsistencies possibly result from the wave generator in the opposite side being affected by compression from the main lesion.

As for the laterality of wave III, our findings are in agreement with the previous concept of ipsilateral representation because in three cases with abnormalities from early waves (case 10,11,13), the side of abnormalities was all ipsilateral to the lesion.

The peculiar example of ipsilateral wave III and contralateral wave V representation was case 17 (Fig. 2). He, a 38 year old businessman, had a tiny

hemorrhage in the left midbrain with his symptom restricted to the left third nerve palsy. Initial BAER showed ipsilateral I-III prolongation with poor wave III formation and contralateral poor wave V formation. Two weeks later, when the symptom was remarkably improved, BAER reverted to normal aside from slight ipsilateral I-iii delay.

Thus it is likely that the early part of BAER waves, despite their several crossings, mainly represent ipsilateral side of the brainstem. The late waves seem to cross more to the contralateral side.

With respect to the rostrocaudal representation of the waves, the largest recent series differ in their views. Considering wave III representing the superior olivary complex (pons), and wave V, inferior colliculus (midbrain), Faught and Oh (1985) saw their BAER findings agree fairly well with the clinical signs. However three of their patients with mid to lower pontine signs had abnormal wave V instead of wave III, and the opposite 'caudal shift' of abnormal waves were seen in as many as five patients with upper brainstem lesions. In Kjaer's (1980) series of fifteen patients with brainstem strokes, differentiation between low and high localization with BAER was possible in less than half of the cases.

Stern *et al.* (1982), showing no cases of mesencephalic lesion with primary III-V delay, concluded that it is impossible to establish a pattern consistently relating medullary, pontine, or mesencephalic lesions to specific BAER abnormalities.

Our study, although done with smaller members, was more analytic with regard to spatial localization, as compared to the cited series.

The three patients with lateral medullary syndromes all had normal BAERs, which agrees with Faught and Oh's (1985) results, and indicates that the lesions involved are located caudal to the area of eighth nerve entrance, thereby sparing the brainstem auditory pathway.

In cases of pontine and mesencephalic syndromes, the interpretation was more difficult. The three patients with absence of ipsilateral wave generation (case 10,11,13) shared common features. The lesions were relatively large, and were impinging on infero-lateral part of the pons where cochlear nuclei and eighth nerve fascicles are thought to be located. These abnormalities can be transient ones as seen in two of them, and other two cases with inferolateral pontine signs, but with normal BAERs, might have corrected their initial BAER abnormalities (case 5,9). As expected, their CT find-

ings were negative or did not correlate with the clinical signs. Therefore if the lesions are strategically located to affect inferolateral pons, and if they are large enough, BAERs fail to be generated in the ipsilateral recordings, especially in the early stage of the stroke.

Including case 10, where initial absence of ipsilateral wave II, III, IV, and V had changed into bilateral III-V delay, the five patients with III-V delay had main lesions in pons. Among three patients with midbrain lesions, two also showed wave V abnormalities, but in one, with concomitant wave III abnormality and I-III delay. Thus it is unlikely that wave III or V has any rostrocaudal localizing value. What was more impressive to us was the fact that all five cases of III-V delay showed clinical and radiological evidence of dorsal pontine involvement (Fig. 3). Other pontine lesions without dorsal signs did not show abnormalities of the late waves. One possible exception was case 4 in which the BAER was normal despite signs of internuclear ophthalmoplegia. Because the symptoms were transient, and the CT scan was negative, the ischemic lesion was thought to be too soft to influence the generator of wave V. These findings suggest that at least in pontomesencephalic lesions, the wave III and V have dorsoventral rather than rostrocaudal correlations.

This statement does not imply that the generator of wave V is located within the pons. As was mentioned, two midbrain strokes also produced poor wave V formations. Hashimoto *et al.* (1979), reported a case of pineal tumor with absence of wave V and thought that inferior colliculus was the wave V generator. Stern *et al.* (1982), however, found no patient with a midbrain lesion who had primarily a III-V delay. These discrepancies could be resolved if the lesion in Hashimoto's patient was located more dorsally, a possibility that seems highly likely.

Because the brainstem auditory pathway traverses ventrodorsally in a tiny area of less than 4 cm (Chiappa 1983; Carpenter and Sutin 1983), we believe that dorsally situated pontomesencephalic lesions are more likely to affect the later part of BAER waves. Here again, case 17 is a critical example. In this case, the primary lesion in midbrain (area of third nucleus) extended somewhat ventrodorsally (Fig. 2), probably along the later part of brainstem auditory pathway. The BAER results were, as mentioned previously, abnormality of ipsilateral wave III and contralateral wave V.

Including this illustrative case, our study is generally in accordance with Buchwald and

Huang's (1975) experimental results in cats. They reported that wave III is generated by the superior olivary complex activated by projections crossing the midline and that wave IV is generated by the lateral lemniscus activated equally by crossed and uncrossed projections. Wave V, being generated by the inferior colliculus, was concluded to be primarily activated by crossed projections.

When brainstem strokes spare the auditory pathway, as Kjaer (1980) already pointed out, the BAER findings are generally normal. Stated another way, the abnormal BAERs, if produced at all, permit the clinician to localize, though not very precisely, the involved lesion if he considers the three dimensional nature of the brainstem auditory pathway.

REFERENCES

- Adams RD, Victor M. Principles of Neurology. 3rd ed., McGraw-Hill, New York, 1985.
- Achor LJ, Starr A. Auditory brain stem responses in the cat. II. Effects of lesions. *Electroencephalogr Clin Neurophysiol.* 1980b, 48:174-190
- Allen AR, Starr A. Auditory brain stem potentials in monkey and man. *Electroencephalogr Clin Neurophysiol.* 1978, 45:53-63
- Brown RH, Chiappa KH, Brooks EB. Brainstem auditory evoked responses in 22 patients with intrinsic brainstem lesions. Implications for clinical interpretation. *Electroencephalogr Clin Neurophysiol.* 1981, 51:38
- Buchwald JS, Huang CM. Far field acoustic response. Origins in the cat. *Science.* 1975, 89:382-384
- Carpenter MB, Sutin J. Human neuroanatomy. 8th ed. Williams and Wilkins, Baltimore, 1983
- Chiappa KH, Harrison JL, Brooks EB, Young RR. Brainstem auditory evoked responses in 200 patients with multiple sclerosis. *Ann Neurol.* 1980, 7:135-143
- Chiappa KH. Evoked potentials in clinical medicine. Raven Press, New York, 1983
- Crosby EC, Humphrey T, Lauer EW. Correlative anatomy of the nervous system. Macmillan, New York, 1962
- Faught E, Oh SJ. Brainstem auditory evoked responses in brain stem infarction. *Stroke.* 1985, 16:701-705
- Gilroy J, Lynn GE, Ristow GE, Pellerin RJ. Auditory evoked brain stem potentials in a case of "locked-in syndrome". *Arch Neurol.* 1977, 34:492-495
- Hashimoto I, Ishiyama K, Tozuka G. bilaterally recorded brain stem auditory responses, their asymmetric abnormalities and lesions of the brain stem. *Arch Neurol.* 1979, 36:161-167
- Hashimoto I, Ishiyama Y, Yoshimoto T, Nemoto S. Brainstem auditory evoked potentials recorded directly from human brainstem and thalamus. *Brain.* 1981, 104:841-859

Kjaer M. Localizing brain stem lesions with brainstem auditory evoked potentials. Acta Neuro Scand. 1980, 61:265-274

Lee KW, Park SH, Myung HJ. Studies on brainstem auditory evoked responses in vertebral-basilar transient ischemic attack. The J Korean Neurol Asso. 1987, 4:

Oh SJ, Kuba T, Soyer A, Choi IS, Bonikowski FP, Vitek J. Lateralization of brain stem lesions by brainstem auditory evoked potentials. Neurology. 1981,

31:14-18

Starr A, Achlor LJ. Auditory brain stem responses in neurological disease. Arch Neurol. 1975, 32:761-768

Stern BJ, Krumholz A, Weiss HD, Goldstein P, Harris KK. Evaluation of brainstem stroke using brainstem auditory evoked responses. Stroke. 1982, 13:705-711

Stockard JJ, Rossitor VS. Clinical and pathological correlates of brain stem auditory response abnormalities. Neurology. 1977, 27:316-325

=국문초록=

뇌간 뇌졸중 환자에서의 뇌간 청각 유발전위에 관한 연구

서울대학교 의과대학 신경과학교실

김종성 · 이광우 · 명호진

저자들은 뇌간 뇌졸중 환자 18명을 대상으로 뇌간 청각 유발전위 검사를 실시하여 그 결과를 환자의 임상 증상 및 방사선 소견으로 유추한 병변의 위치와 비교 분석하여 다음과 같은 결과를 얻었다.

1. 유발전위 검사상 이상 소견을 나타낸 환자는 8명이었으며, 연수(medulla)에 국한된 병변을 갖는 환자에서는 검사 소견이 모두 정상이었다.
2. 청각 유발전위의 5개의 파형 혹은 첫번째 파형을 제외한 4개의 파형이 모두 나타나지 않는 경우는, 파형이 소실된 동측 뇌교(pons)의 하외부(inferolateral)에 비교적 큰 병변이 있는 경우였다.
3. 파형의 후반부의 이상(Ⅲ-V 정점간 시간의 지연, 파형 V 생성의 장애)이 보이는 경우는 주로 뇌교 혹은 중뇌(midbrain)의 배부(dorsal side)에 병변이 있는 경우였으며, 이 경우 파형의 이상은 병변의 반대측에 나타나는 경향이였다.
4. 뇌교에 병변이 있더라도 배부 혹은 하외부에 손상이 없거나 병변이 작은 경우, 증상이 일시적인 경우 등은 대체로 정상적인 뇌간 청각 유발전위 소견을 나타내었다.

결론적으로 뇌간 청각 유발전위는, 임상가가 뇌간의 청각 전달 경로를 삼차원적으로 고려하여 해석할 때, 뇌간 뇌졸중 환자의 병변의 국소화(localization)에 중요한 검사가 될 수 있을 것으로 생각된다.