

Simple compressive method for treatment of auricular haematoma using dental silicone material

Y H CHOUNG, DDS, MD, K PARK, MD, P H CHOUNG DDS*, J H OH, MD

Abstract

Most of the previous treatment methods for auricular haematoma are inconvenient for both patients and doctors because they are time-consuming and complex and must be performed under sterile conditions. The purpose of this study was to evaluate the effectiveness of a simple compressive method using a dental (silicone) impression material and comparing it with other methods for treatment of auricular haematomas. The authors aspirated a haematoma and then placed a mixed base and catalyst of silicone putty material on the anterior and posterior surfaces of the auricle in the shape of an inverted U for seven days.

From the 24 cases managed with this method, 23 cases (95.8 per cent) were successfully healed. Eight patients were treated with a collodion-cotton wool cast and 16 of 19 patients were successfully treated with dental cotton-wool rolls. The average number of those visiting the hospital was 2.7 for the collodion-cotton wool cast, 6.9 for the dental cotton-wool roll, and 3.1 for dental silicone. The mean treatment durations were 8.1 days for the collodion-cotton wool cast, 13.8 days for the dental cotton-wool roll, and 8.6 days for dental silicone. The authors believe that this compressive method using dental silicone material is simple and appropriate for the treatment of auricular haematoma.

Key Words: Ear, External; Haematoma; Surgical Procedures, Operative

Introduction

Haematoma of the auricle is commonly encountered in the otolaryngological clinic. It is due to blunt trauma of the auricle and, if not treated properly, the blood clot can organize and become permanently thickened producing a 'cauliflower' ear deformity. The early removal of the haematoma combined with a pressure dressing has been the standard treatment. Auricular decompression by needle aspiration without compression is ineffective because it results in recurrence of the haematoma.^{1,2} Plaster mould,³ cotton wool bolster,⁴ collodion-cotton wool cast,⁵ White Wool and Webril,⁶ cotton wool bolster and hearing aids,⁷ and dental cotton-wool rolls¹ have all been used as compression techniques. These methods are inconvenient for both patients and doctors because they are time-consuming and complex and must be performed under sterile conditions. The patients require frequent dressing changes to prevent infection. Many patients are reluctant to have sutures or wear bulky compressive dressings. Thus, the authors have developed a new simple compression method that can be used easily in private clinics and hospitals. This method, using dental silicone material, is

similar to the method introduced by Quine in 1996.⁸ The aim of this article is to introduce a simple compressive method for effective treatment of auricular haematomas using dental silicone impression material and to evaluate the effectiveness of this compressive method compared with other methods.

Patients and methods

The subjects included 65 patients with auricular haematoma, who visited Ajou University Hospital from June, 1994 to December, 2003. The average age was 39.6 years old (ages ranged from 16–76 years) and the subjects were composed of 49 males and 16 females. Fifty-nine patients were treated randomly by several different methods and six were not treated. Eight patients were treated by the aspiration technique without any compression, and another eight by the collodion-cotton wool cast method⁵ from 1994 to 1996, 19 were treated by the dental cotton-wool roll method¹ from 1997 to 1998, and 24 were treated by a compressive method using dental silicone material from 1999 to 2003. Based on historical data in the out-patient charts, the effectiveness of the methods was analysed.

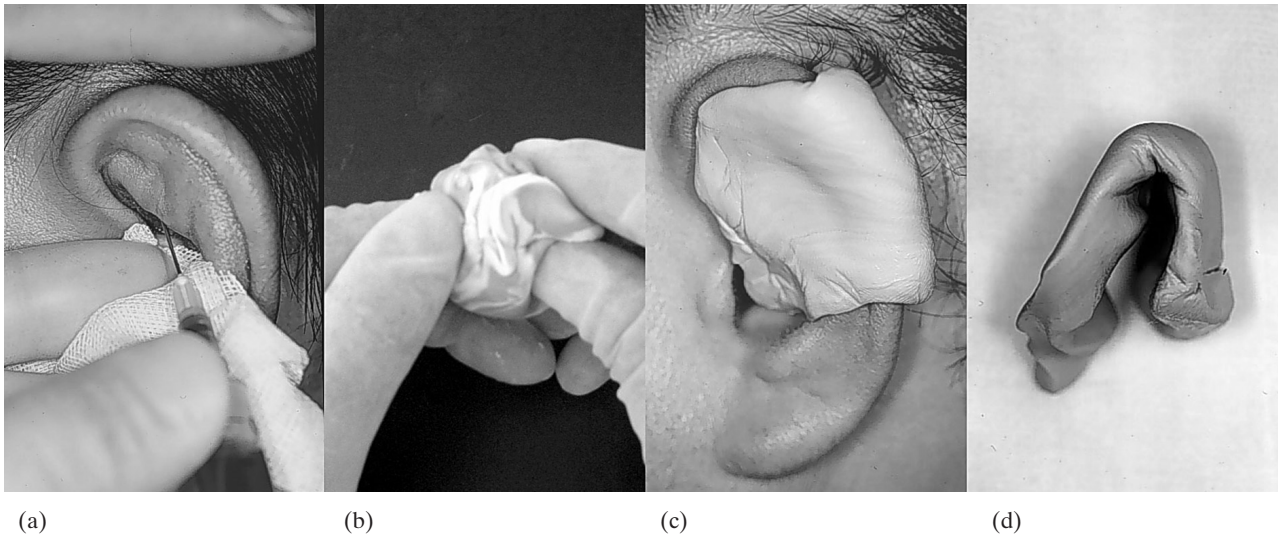


FIG. 1

The technique for treatment of auricular haematoma using dental impression material. (a) The haematoma is aspirated with an 18–20 gauge needle and syringe after cleansing the auricle. (b) The impression material is prepared using equal parts (one scoop) of base and catalyst of Exaflex®. Both materials are kneaded in the hands for 1 minute or until it is uniform in colour. (c) The mixed impression material is placed on both the anterior and posterior surface of the auricle. (d) The dental impression material is contoured into the shape of an inverted U which acts to stabilize the frame.

This simple method of using dental silicone material for the compressive treatment of auricular haematoma does not require an operating-theatre setting. The only instruments required are an aspiration syringe with an 18–20 gauge needle, or a No.15 scalpel to evacuate the haematoma, and dental impression material for the pressure dressing. The authors used the silicone impression material called Exaflex® type O putty (very high viscosity) (GC America Inc., Illinois), which is composed of vinyl polysiloxane and is spontaneously cured after mixing base and catalyst.

Firstly, the ear was cleansed with a Betadine solution. The haematoma was aspirated with a large bore needle (18–20 gauge). The most inferior (most dependent) area of the haematoma was aspirated (Figure 1(a)). Anaesthesia was not used for the aspiration. Occasionally when an organized haematoma remains after aspiration, the haematoma needs to be incised and curetted out. In these cases, the auricle is anaesthetized with 1 per cent Xylocaine with 1:100 000 epinephrine. After aspiration, the auricle is cleaned again with a Betadine solution or

an antibiotic ointment. The dental impression material is then prepared with equal parts (approximately one scoop) of Exaflex® base (yellow colour) and catalyst (blue colour). The components are mixed and kneaded in the hands for one minute or until it is homogenous in colour (Figure 1(b)). The mixed impression material is then placed on both the anterior and posterior surfaces of the auricle in the shape of an inverted U. The anterior surface of the auricle should be covered, including the cavum concha area, in order to maintain the normal contour of the auricle (Figure 1(c)). The inverted U shape is also important to the stability of the impression material (Figure 1(d)). It takes about three to five minutes for the Exaflex® mixture to cure spontaneously.⁹ The cured dental frame is fixed and stabilized with paper tape and then dressed simply with gauze. Oral antibiotics are not necessary. The patient is checked again three days after the procedure, and then on day 7 the impression material is removed.

Results

Treatment results and complications (Figure 2)

Only three (37.5 per cent) of eight cases managed with the aspiration technique, without compression, were completely healed. Two cases showed ear deformities following the treatment, and three cases had to be treated with other methods because of frequent recurrence. All eight cases managed with the collodion-cotton wool cast recovered successfully. Sixteen (84.2 per cent) of 19 cases managed with dental cotton-wool roll application completely recovered, but the three remaining cases developed auricular deformities. Two of these three cases had pressure necrosis following dental roll sutures.

From the 24 cases managed with the compression technique of dental silicone material (Table I),

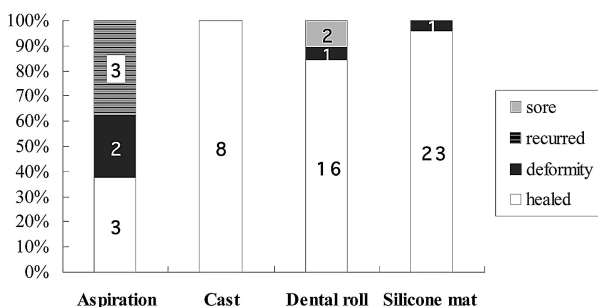


FIG. 2
Results of treatments.

23 cases (95.8 per cent) were successfully healed (Figures 3(a) and 3(b)). However, just one case (patient 10 in Table I) showed some deformity on the auricle at the end of treatment. It was noted that before visiting this hospital, this patient had had a recurrent haematoma and had been previously treated for nine months in other clinics with several different methods including aspiration, compression and a triamcinolone injection. In addition, 19 other cases had received several aspiration therapies in private ENT clinics prior to visiting this hospital for treatment. Eighteen cases out of 24, managed with dental silicone, were aspirated only once. Five cases were aspirated twice to remove accumulated fluid, and one of these five cases had a recurrence after two weeks of management. This finally healed when the dental silicone was reapplied. One case was aspirated three times but the final appearance was cosmetically good.

The number of patients visiting hospital and treatment duration

The average number of those visiting the hospital was 2.7 for the collodion-cotton wool cast, 6.9 for the dental cotton-wool roll, and 3.1 for dental silicone. The mean treatment durations according to the methods were 8.1 days for the collodion-cotton wool cast, 13.8 days for the dental cotton-wool roll, and 8.6 days for dental silicone (Table II). Four cases among those managed with the dental roll had been admitted especially for treatment.

Discussion

The goal of management for auricular haematoma is to prevent permanent deformity from recurrence

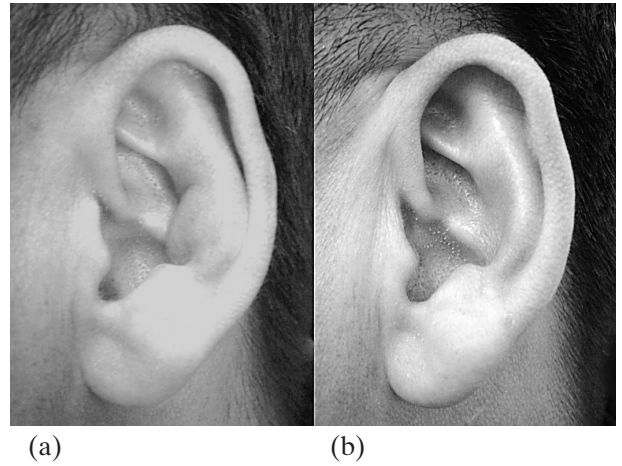


FIG. 3

The results of treatment of auricular haematoma using dental impression material. (a) Recurrent auricular haematoma involving the cymba of the concha after it had been aspirated in another clinic. (b) Same patient as in (a), 1 month after treatment using dental impression material showing good cosmetic result.

and infection, and also to enable the patient to continue his social life.^{2,7,10} These goals sometimes prove difficult, however, and many different techniques have been tried, including simple aspiration and the use of collodion-cotton wool casts or dental rolls to compress the ear. All have met with only limited success.

Needle aspiration without any compression is an easily used technique for the control of auricular haematoma in out-patient clinics. However, as just three of eight in this study showed success, the simple aspiration technique is not adequate for preventing recurrence. Soft compressive dressings such as wet

TABLE I

THE PATIENTS WITH AURICULAR HAEMATOMA TREATED WITH DENTAL SILICONE MATERIAL

No.	Age/Sex	Duration (days)	Previous Tx (frequency)	No. of Aspirations (volume)	No. of Visits	Duration of Tx (days)	Results
1	51/M	10		2(5cc)	4	14	healed
2	29/M	1		1(0.5cc)	5	10	healed
3	34/M	30	Asp(2)	1(3.8cc)	2	7	healed
4	54/M	7	Asp(1)	1(3cc)	2	4	healed
5	34/M	10		1(0.5cc)	3	14	healed
6	24/M	30		1(2cc)	5	14	healed
7	58/M	2		1(2cc)	2	3	healed
8	54/M	26		2(5.7cc)	3	7	healed
9	54/M	33	Asp(1)	1(1.5cc)	2	3	healed
10	39/M	270	Asp(4)	2(2cc)	3	10	deformity
11	35/M	10	Asp(1)	1(2cc)	3	7	healed
12	62/M	30	Asp(5)	3(1cc)	6	30	healed
13	38/F	23	Asp(2)	1(0.2cc)	2	3	healed
14	35/M	21	Asp(1)	1(0.9cc)	3	7	healed
15	46/F	120	Asp(8)	1(0.2cc)	2	7	healed
16	30/F	14	Asp(10)	1(1cc)	3	7	healed
17	30/M	30	Asp(4)	1(0.7cc)	3	7	healed
18	30/F	30	Asp(3)	2(0.5)	3	7	healed
19	44/F	180	Asp(10)	1(2cc)	3	12	healed
20	41/F	7	Asp(4)	1(1cc)	4	7	healed
21	48/F	20	Asp(7)	1(1.3cc)	3	7	healed
22	44/F	7	Asp(3)	2(1cc)	4	16	healed
23	36/F	30	Asp(4)	1(0.5cc)	2	5	healed
24	73/F	30	Asp(2)	1(3.5cc)	2	7	healed

No. = number; Tx = treatment; Asp = aspiration; M = male; F = female

TABLE II

THE NUMBER OF PATIENTS VISITING HOSPITAL AND TREATMENT DURATION FOR AURICULAR HAEMATOMA

	Collodion-cotton wool cast	Dental roll	Silicone material
Number of visits	2.7	6.9	3.1
Treatment duration (days)	8.1	13.8	8.9

cotton wool or Vaseline gauze were sometimes used, but proved to be not effective. Stuteville⁵ introduced the collodion-cotton cast for a hard compressive dressing. In this study, this method was used for eight patients, all of whom showed successful results. However, this technique has significant shortcomings such as difficulties for aseptic technique, a long operating time (about 30–60 minutes), and inconvenience for private clinics. Davis⁴ used cotton bolsters and Sculler¹ used dental rolls for stitch dressings. In the case of wrestlers, especially, the stitch dressings using a dental roll allowed them to continue their wrestling schedule and has been the standard of treatment for auricular haematoma.^{1,2} But this technique requires an aseptic procedure, anaesthesia and frequent, daily dressings.¹ The patients frequently complained of auricular pain for several days after the stitch procedure. The compressed stitch dressings can sometimes lead to pressure necrosis of the auricle as was seen in two of 19 in this study. Thus, this procedure was considered by ENT doctors to be cumbersome, particularly in private clinics.

As described, most of the previously used techniques are not effective for the control of auricular haematoma and inconvenient for doctors and patients. Thus, the authors developed the simple compressive technique using silicone material that is normally used for taking impressions in dental clinics. The authors' technique is similar to the method that Quine⁸ introduced in 1996, but his was unsuccessful. In contrast to Quine's technique, a silicone frame was made in the shape of U without the use of antibiotics.

The authors used Exaflex[®]. Silicone consists of vinyl polysiloxane, and is cured by mixing base and catalyst, producing a low heat without any additional products. Silicone impression materials are usually supplied in four different types of viscosity (low, medium, high, and very high) depending on the consistency. The authors used the very high viscosity type because it has a short setting time (3–5 minutes) and enough hardness and tensile strength to maintain the contour of the auricle. This type also has the smallest 'dimensional change' (–0.14 per cent) at 24 hours after setting, and 0.2–0.5 per cent of 'permanent deformity'.⁸ These properties allow the material to maintain the anatomical contour of the auricle and prevent recurrence of the haematoma after decompression.

The technique using Exaflex[®] dental impression material is simple and convenient for both patients and doctors. It can be performed in approximately 10 minutes and only requires three (average 3.1) follow-up visits to ensure there has been no recurrence of the haematoma. In the authors' experience, this technique showed excellent cosmetic results (23 of 24 cases) without any complications. If the size of the haematoma exceeds 5 ml or if it has a long history of recurrence, the fluid may have to be aspirated several times. In these cases, it was better to re-fix the auricle with new materials than to use the previous frame. In this study, there was no infection after treatment. The authors do not believe this procedure is appropriate for combined cases of an open wound and haematoma because there is a possibility of chondritis. Occasionally some frames had to be adjusted on day 3 because they were too loose.

Conclusion

The authors believe that this technique using dental impression material is appropriate for the treatment of auricular haematoma. It showed excellent cosmetic results and is simple and convenient for both patients and doctors.

Acknowledgement

We thank Mrs. Jean Noffke for her help with the preparation of this manuscript. This study was supported in part by a grant of the Korean Health 21 R&D project, Ministry of Health & Welfare: Musculoskeletal Bioorgans Center (0405-B001-0204-0006).

- **This paper presents a series of 65 patients with auricular haematoma treated over a nine-year period by means of aspiration followed, in the majority of cases, by application of a pressure dressing**
- **When a dressing was utilized this was either a dental cotton-wool roll, collodion and cotton wool or dental silicone**
- **The patients were not randomized**
- **The number of visits to the hospital and the duration of treatment was highest when a dental cotton-wool roll was used and the complication rate was also relatively high with this technique**
- **Similar results were found when either dental silicone or collodion-cotton casts were used. However, the operating time was significantly increased with collodion-cotton wool and was not aseptic. The authors therefore conclude that dental silicone is the dressing of choice following aspiration of an auricular haematoma**

References

- 1 Schuller DE, Dankle SD, Strauss RH. A technique to treat wrestlers' auricular haematoma without interrupting training or competition. *Arch Otolaryngol Head Neck Surg* 1989;**115**:202-6
- 2 Clemons JE, Severeid LR. Trauma to the auricle. In: Cummings CW, Fredrickson JM, Harker LA, Krause CJ, Richardson MA, Schuller DE, eds. *Otolaryngology Head and Neck Surgery*. St Louis: CV Mosby, 1996;2987-94
- 3 Escart M. Simplified treatment of haematoma of the ear. *Otorhinolaryngol Int* 1946;**30**:181-2
- 4 Davis PK. An operation for haematoma auris. *Br J Plastic Surg* 1971;**24**:277-9
- 5 Stuteville OH, Janda C, Pandya NJ. Treating the injured ear to prevent a 'cauliflower ear'. *Plast Reconstr Surg* 1973;**52**:534-7
- 6 Gernon WH. The care and management of acute haematoma of the external ear. *Laryngoscope* 1980;**90**:881-5
- 7 Giffin CS. The wrestler's ear (acute auricular haematoma). *Arch Otolaryngol* 1985;**111**:161-4
- 8 Quine SM, Roblin DG, Cuddihy PJ, Tomkinson A. Treatment of acute auricular haematoma. *J Laryngol Otol* 1996;**110**:862-3
- 9 Craig RG. *Restorative Dental Materials*. St. Louis: CV Mosby, 1989;309-25
- 10 Ohlsen L, Skoog T, Sohn S. Pathogenesis of cauliflower ear: An experimental study in rabbits. *Scand J Plast Reconstr Surg* 1975;**9**:34-9

Address for correspondence:
Yun-Hoon Choung, DDS, MD,
Department of Otolaryngology,
Ajou University School of Medicine,
San 5, Wonchon-dong,
Youngtong-gu,
Suwon 442-721,
Republic of Korea.

Fax: +82 (31) 219 5264
E-mail: yhc@ajou.ac.kr

Dr Yun-Hoon Choung takes responsibility for the integrity of the content of the paper.
Competing interests: None declared
