

Tracheal atresia: A Case Report

Je G. Chi, Young K. Shong and Chul Woo Kim

Department of Pathology, College of Medicine, Seoul National University

Atresia of trachea is a rare congenital malformation and is uniformly fatal. Recently we encountered an autopsy case of this anomaly in a stillborn fetus. Approximately 42 cases have been reported in the world literature (Payne, 1900; Devenis and Otis, 1957; Devi and More, 1966; Ashley, 1972; Effmann et al., 1975; Donovan and Friedman, 1979; Faro et al., 1979; Alfery et al., 1980). In this paper, we report an additional case, and a brief review on the embryonic base of this anomaly is made.

REPORT OF A CASE (RCM #516)

This male baby was born to a 24 year old primigravida after 31 weeks of gestation. During pregnancy the mother neither took any medicine nor suffered from any viral illness. Weight gain during pregnancy was normal and no evidence of polyhydramnios was observed. The delivery was complicated by premature rupture of the membrane, but progressed spontaneously to vaginal delivery. At birth, there was no sign of life.

An autopsy revealed a male baby weighing 1,350gm; CR length of 28cm; and CH length of 43cm. The face showed bilateral cleft lips and cleft palates, and a rudimentary right ear. Otherwise the external appearance was normal. In the cranial cavity, a subarachnoid hemorrhage was found. In the respiratory system, the upper airway was developed normally to the larynx, but just below the inferior margin of

the vocal cord the tracheal lumen was abruptly narrowed and obstructed. Both main bronchi joined at the carina, and there was a small 1.2 cm stump of distal trachea. Between the larynx and the carina was a thin narrow fibrous and cartilaginous cord considered as tracheal remnant. There was no evidence of a fistula between the trachea and the esophagus. At microscopic examination, the atretic segment revealed an abnormally tortuous cartilage. The tracheal lumen was completely occluded and only residual epithelial tissue was observed. The hyoid bone was not identified. No vocal

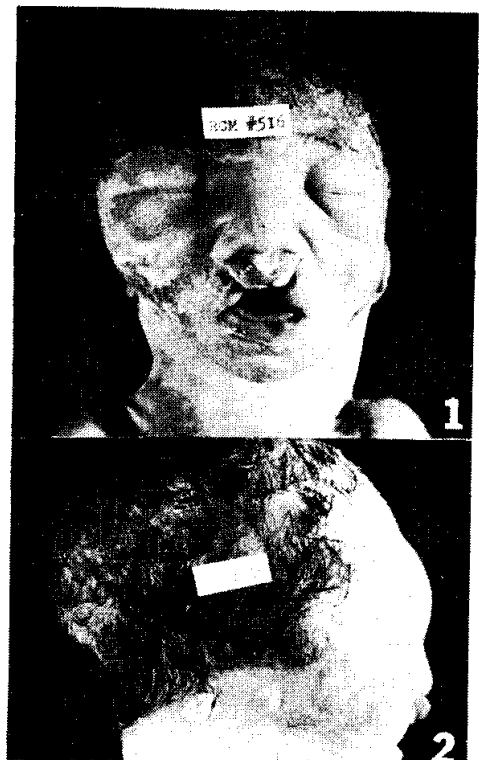

Fig. 1 & 2. Anterior and right lateral views of the face showing bilateral cleft palate and anomalous ear.

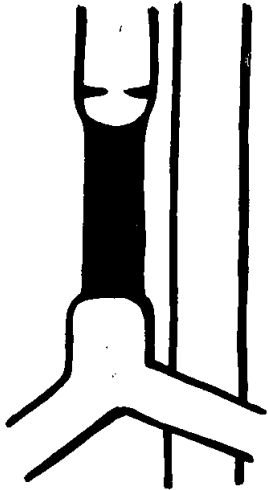


Fig. 3. A schematic representation of the anomalous trachea in this report. Dark area represents the atretic segment. No fistula between the trachea and the esophagus is noted.

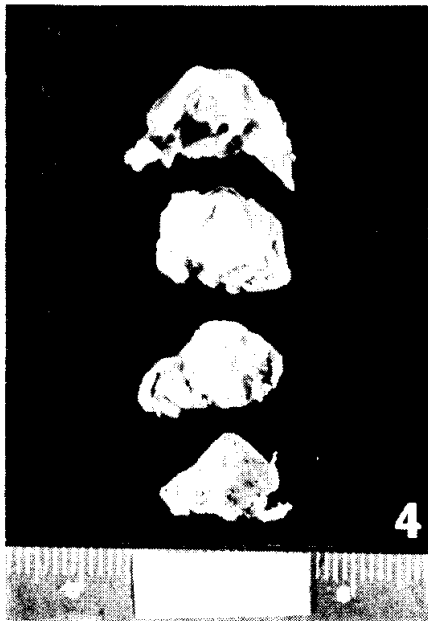


Fig. 4. Step sections of the atretic segment. No lumen is visible.

cord structure was seen. The occluded portion was microscopically composed of fibrocollagenous tissue with occasional and irregular islands of mucous glands. No other element was seen. The cartilage of larynx was also abnormally formed.

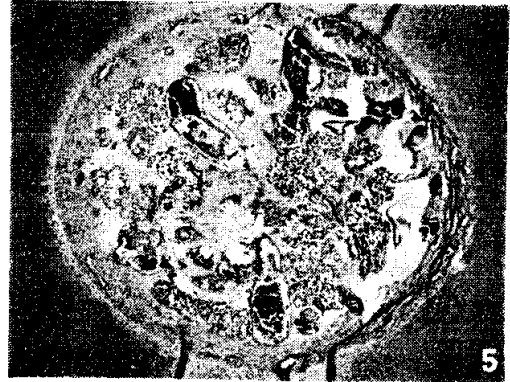

Fig. 5. Microscopic section of the atretic segment. Abnormal development of tracheal cartilage and occasional epithelial remnants are seen.

Thyroid-like structure was recognized near the thyroid cartilage level. The right lung was bilobed and on both pleural surfaces petechial hemorrhages were noted. Although the lungs showed no evidence of aeration, normal fetal development of alveoli was noted.

There was a large patent ductus arteriosus, and the left ventricle and aortic arch were hypoplastic. In the liver a minor fissure was present in the gallbladder fossa. The gastrointestinal tract showed mild stenosis of the duodenum due to an annular pancreas, and a Meckel's diverticulum 74 cm above the rectum.

DISCUSSION

Atresia of trachea has been very infrequently reported since the first case reported by Payne in 1900. In 1979 Faro et al. collected 38 cases in the literature and classified them into 7 types. According to Faro's classification (Faro et al., 1979), type A is total tracheopulmonary agenesis; type B is tracheal agenesis in which the main bronchi arise directly from the esophagus; type C is tracheal agenesis in which there are fused main bronchi with bronchoesophageal fistula; type D is tracheal agenesis in which the larynx is joined to the distal trachea through an atretic strand and a tracheoesophageal

fistula is present; type E is upper tracheal agenesis in which there is a direct tracheoesophageal communication; type F is tracheal agenesis in which there is a blind bronchial bifurcation and no esophageal communication; and type G is short segment tracheal agenesis. Our case seems to be unique in that the larynx was joined to the distal tracheal stump. There was no tracheoesophageal fistula.

We found additional 3 cases tracheal agenesis in the English literature (Ashley, 1972; Donovan and Friedman, 1979; Alfery et al., 1980). Alfery's(1980) and Ashley's(1972) cases seemed to belong to Faro's type E, but they had esophageal atresia in addition. Donovan's case(1979) seems to belong to Faro's type D. In Faro's review, associated anomalies were present in almost all of the cases, especially cardiac and genitourinary anomalies.

The pathogenesis of tracheal atresia is unknown. Although Keith and Spicer(1907) and many other authors (Rosenthal, 1931; Smith, 1957) contributed tracheal and esophageal anomalies to the failure of the tracheoesophageal groove to form a septum between the trachea and the esophagus. It seems unlikely that such a view held true since comparing with the frequencies of esophageal anomalies, tracheal anomaly is only rarely seen. Fluss and Poppen (1951) suggested that the tracheoesophageal anomalies occur in association with anomalous blood vessels, but there is no convincing evidence. Devenis(1957) suggested that in the stretching out process the trachea becomes eliminated and the common portion becomes the esophagus. Willis(1958) suggested that a tracheal rudiment was present in the embryo and must have atrophied later. However, this explanation also appears unlikely as no structures resembling tracheal tissue were found in most of the cases. But in our case, there was fibrocartilagenous cord considered to be an atretic tracheal remnant,

and on histologic examinations there appeared rudimentary respiratory epithelial tissues although the lumen was completely occluded. Donovan(1979) suggested it is possible that the bronchi and pulmonary parenchyma have a separate embryonic origin from the larynx and trachea, because in most of the cases lungs and bronchial trees developed normally even through tracheal aplasia occurred without any elements of degenerated trachea.

Effmann et al (1975) suggested that in view of the many associated malformations, tracheal atresia occurred between the fourth and the sixth weeks of embryonic development and the presence of the multisystemic anomalies would not be random. Devenis (1957) and Devi (1966) also proposed an external factor influencing on the crucial embryonic stage might be the cause of this anomaly and these malformations would not be interrelated. It is presumed that such a complex malformation might occur due to an unknown external insult during the embryonic period. At this time there is no definitive conclusive evidence nor a readily available explanation regarding the reported cases.

SUMMARY

A rare congenital anomaly, tracheal atresia associated with multisystemic malformation is reported. The larynx was developed normally and just below the vocal cord the tracheal lumen was completely occluded. The larynx was connected to the distal trachea by a thin fibrocartilagenous cord that was considered to be a tracheal remnant.

The two main bronchi were fused at the carina. No tracheoesophageal fistula was present. The embryonic basis of this anomaly is briefly reviewed. In view of the associated multisystemic malformation, the pathogenesis is presumed to be an insult in a critical embryonic stage,

not a simple mechanism.

＝국문초록＝

기관폐착증(1부검증례)

서울대학교 의과대학 병리학교실
지제근 · 송영기 · 김철우

대단히 드문 선천기형으로서 여러 장기의 기형을 동반한 기관폐착증의 부검예를 보고한다. 후두는 정상적으로 발달되었으나, 성대의 바로 아래에서 기관의 내강이 완전히 막혀있었고, 기관의 흔적으로 생각되어지는 가는섬유성 연결이 후두와 원위부의 기관을 연결하고 있었다. 양쪽의 주기관지는 carina에서 만났다. 기관식도누공은 발견되지 않았다. 이 기형의 발생학적 기본원인을 간단히 살펴보았다. 동반된 여러 기관의 기형에 비추어 보아 기관지폐색의 원인은 아마 어느 결정적인 배아시기에의 충격에 있는 듯하며 단순한 기전은 아닌 듯 하다.

REFERENCES

Alfery, D.D., Ward, C.F., Plumer, M.H. and Lynch, F.: *Management of tracheal atresia with tracheoesophageal fistula. Anesthesiology*, 53:242-244, 1980.

Ashley, D.J.B.: *A case of congenital tracheal obstruction with esophageal atresia. J. Pathol.*, 108:261-263, 1972.

Devenis, A.M. and Otis, R.D.: *Tracheal atresia*

associated with tracheoesophageal fistula. J. Thoracic Surg., 34:405-408, 1957.

Devi, B. and More, J.R.S.: *Total tracheopulmonary agenesis. Acta Paediatr. Scand.*, 55:107-116, 1966.

Donovan, T.J. and Friedman, W.H.: *Aplasia of the trachea. Ear Nose Throat J.*, 58:92-99, 1979.

Effmann, E.L., Spackman, T.J., Berdon, W.E., Kuhn, J.P. and Leonidas, J.C.: *Tracheal agenesis. Am. J. Roentgenol. Radium. Ther. Nucl. Med.*, 125:767-781, 1975.

Faro, R.S., Goodwin, C.D., Organ, C.H. Jr., Hall, R.T., Holder, T.M., Ashcraft, K.W. and Amoury R.A.: *Tracheal agenesis. Ann. Thoracic Surg.*, 28:295-299, 1979.

Fluss, Z. and Poppen, K.J.: *Embryogenesis of tracheoesophageal fistula and esophageal atresia. Arch. Pathol.*, 52:168-181, 1951.

Keith, A. and Spicer, J.E.: *Three cases of mal formation of tracheoesophageal septum. J. Anat. Physiol.*, 41:52:55, 1907.

Payne, W.A.: *Congenital absence of trachea. Brooklyn Med. J.*, 14:568, 1900.

Rosenthal, A.H.: *Congenital atresia of esophagus with tracheoesophageal fistula. Arch. Pathol.*, 12:756-772, 1931.

Smith, E.I.: *Early development of trachea and esophagus in relation to atresia of esophagus and tracheoesophageal fistula. Contrib. Embryol. Carnegie Inst.*, 36:41-57, 1957.

Willis, R.A.: *The borderland of embryology and pathology, 2nd ed. Butterworth, London. 1958. p. 194,*