

Soft Tissue Thickness for Placement of an Orthodontic Miniscrew Using an Ultrasonic Device

Bong-Kuen Cha^a; Yeon-Hee Lee^b; Nam-Ki Lee^c; Dong-Soon Choi^c; Seung-Hak Baek^d

ABSTRACT

Objectives: To evaluate area- and gender-related differences in the soft tissue thickness of potential areas for installing miniscrews in the buccal-attached gingiva and the palatal masticatory mucosa.

Materials and Methods: The sample consisted of 61 Korean young adults. An ultrasonic gingival-thickness meter was used to measure the soft-tissue thickness in the buccal-attached gingiva just adjacent to the mucogingival junction of the upper and lower arches and 4 mm and 8 mm below the gingival crest in the palatal masticatory mucosa. Independent *t*-test, paired *t*-test, and one-way analysis of variance were used for statistical analysis.

Results: Buccal-attached gingiva thickness in the upper arch was significantly greater in men than in women, but buccal-attached gingiva thickness in the lower arch and palatal masticatory mucosa thickness 4 and 8 mm below the gingival crest did not show gender differences. Significantly thicker soft tissue occurred in the anterior areas in the upper arch and in the posterior areas in the lower arch. In the palatal masticatory mucosa, significantly thicker soft tissue was found 4 mm below the gingival crest in the anterior areas and 8 mm below the gingival crest in the posterior areas. The areas between the canines and the premolars showed higher values than other areas 4 mm below the gingival crest. However, the soft-tissue thickness 8 mm below the gingival crest showed a progressive increase from the anterior to the posterior areas.

Conclusion: Measurements of the soft-tissue thickness using an ultrasonic device could help practitioners select the proper orthodontic miniscrew in daily clinical practice.

KEY WORDS: Soft-tissue thickness; Orthodontic miniscrew; Attached gingiva; Palatal masticatory mucosa; Ultrasonic device

INTRODUCTION

Use of orthodontic miniscrews (OMSs; also known as micro- or mini-implants) to reinforce orthodontic an-

chorage and decrease the need for patient compliance has increased dramatically. In addition, these devices occasionally permit orthodontic treatments previously thought to be difficult or impossible without surgery.¹⁻¹⁰

The stability of an OMS depends on the site of implantation, the angulation of the OMS to bone, the quality and quantity of the cortical bone, the insertion and removal torque, the degree of the bone-OMS contact, the degree of inflammation of the peri-OMS tissue, the thickness and mobility of the soft tissue, the craniofacial morphology, and the screw dimensions.¹¹⁻¹⁷

For the soft-tissue component of stability, risk of failure for OMS surrounded by nonkeratinized mucosa has been reported to be higher than that for OMS surrounded by keratinized mucosa.¹³ Therefore, in the buccal side of the alveolus, the OMS has usually been placed in the interdental areas of the attached gingiva (AG) just adjacent to the mucogingival junction of the upper and lower arches. In the palate, the whole area of the palatal masticatory mucosa (PMM) is made up of the keratinized tissue in which the OMS can be re-

^a Associate Professor, Department of Orthodontics, College of Dentistry, Kangnung National University, Kangnung, Kangwondo, Republic of Korea.

^b Graduate student (PhD), Department of Orthodontics, College of Dentistry, Kangnung National University, Kangnung, Kangwondo, Republic of Korea.

^c Full-time lecturer, Department of Orthodontics, College of Dentistry, Kangnung National University, Kangnung, Kangwondo, Republic of Korea.

^d Associate Professor, Department of Orthodontics, School of Dentistry, Dental Research Institute, Seoul National University, Seoul, Republic of Korea.

Corresponding author: Dr Seung-Hak Baek, Department of Orthodontics, School of Dentistry, Dental Research Institute, Seoul National University, Yeonkum-dong #28, Jongro-ku, Seoul, 110-768, South Korea (e-mail: drwhite@snu.ac.kr)

Accepted: July 2007. Submitted: May 2007.

© 2008 by The EH Angle Education and Research Foundation, Inc.

liably installed. However, the PMM is known to be at least two to three times thicker than the AG on the buccal side,¹⁸ and different areas of the buccal AG have different soft-tissue thicknesses. Therefore, the soft tissue in the candidate areas for OMS installation might be one of the important factors of successful implantation.

If OMSs with the same length are used in areas with different thicknesses of soft tissue, the length of OMS inserted in the bone is different. Therefore, the soft-tissue thickness of the oral mucosa must be measured before OMS installation.

Three methods are currently used to measure the soft-tissue thickness of the oral mucosa. One is direct measurement using a needle or periodontal probe with an endodontic file stopper under local anesthesia.¹⁹ The second is indirect measurement using computed tomography, which is expensive, involves radiation exposure and has limited resolution due to slice thickness.^{20,21} Finally, there is direct measurement using an ultrasonic device such as an ultrasonic gingival-thickness meter (SDM, KRUPP Corporation, Essen, Germany; Figure 1), which has excellent convenience, repeatability, reliability, and accuracy.²²⁻²⁹ The SDM ultrasonic gingival-thickness meter works by measuring the time between when an ultrasonic wave is emitted and when it has passed through the oral mucosa and is reflected back from the bone surface. The meter's monitor displays the soft-tissue thickness.

The purpose of this study was to evaluate area- and gender-related differences in the soft-tissue thickness of the candidate areas for installing OMS in the buccal AG and the PMM with direct intraoral measurement using an ultrasonic device.

MATERIALS AND METHODS

The sample consisted of 61 Korean young adults (28 men and 33 women; mean age = 25.3 years; age range = ~19 to 35 years old) who had not had orthodontic or prosthodontic treatment or tooth extraction (except the third molars). Patients did not have gingival swelling, destructive periodontal disease, or severe crowding and ectopically positioned teeth, and they had not taken medications that affect the periodontal tissue, such as cyclosporin A, a calcium channel blocker, or phenytoin.

Soft-tissue thickness was measured at the interdental areas of the buccal AG just adjacent to the mucogingival junction of the upper and lower arch and at the level of 4 mm and 8 mm below the gingival crest in the PMM, respectively (Figure 2). Measurements at 4 and 8 mm below the gingival crest in the PMM were chosen because (1) 4 mm was easy to mark as the diameter of the sensor was 3 mm, (2) 4 mm was near

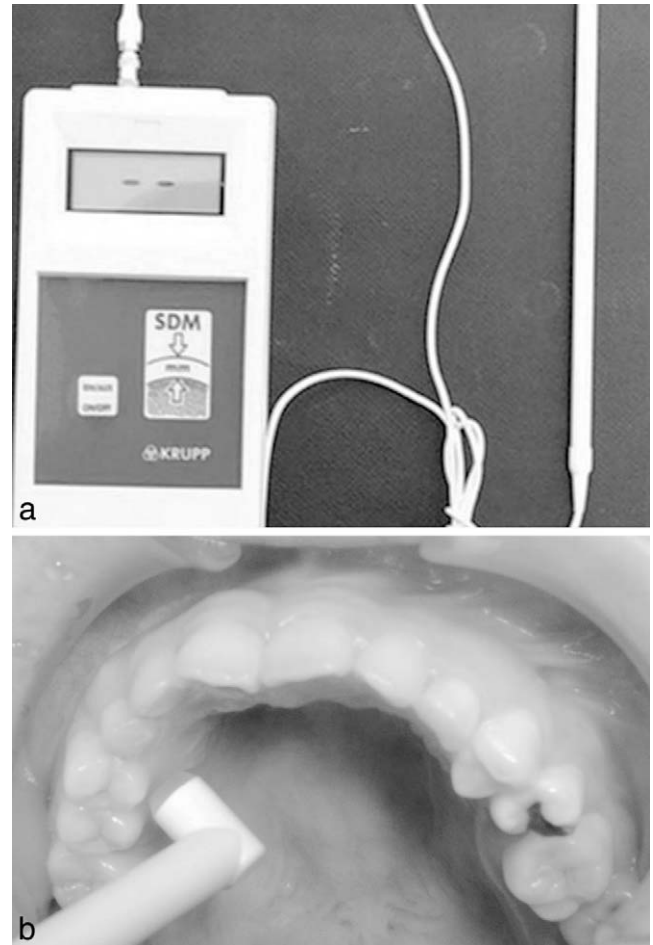


Figure 1. (a) SDM ultrasonic gingival thickness meter (KRUPP Corporation, Essen, Germany); (b) measurement of the interdental area in the palatal masticatory mucosa thickness at 4 mm below the gingival crest.

the trifurcation area, and (3) 8 mm was almost half of the upper first molar root from the lateral cephalogram tracing. These areas were marked with an indelible pencil (Albrecht Durer, Faber-Castell, Nurnberg, Germany). Soft tissue on the midpalatal area, the retro-molar pad, and the maxillary tuberosity were not measured because of limited accessibility to the sensor.

Soft-tissue thickness of the interdental areas was measured intraorally using an ultrasonic gingival thickness meter (SDM, KRUPP Corporation; range of measurement = 0.3 to 8.0 mm; resolution = 0.1 mm; ultrasonic frequency = 5 MHz; sensor diameter = 3.0 mm). One investigator did the measurements, with minimal pressure on the soft tissue and in a wet environment.

The same person remeasured 10 randomly selected samples 2 weeks later to determine any measurement error. A paired *t*-test did not show any significant difference. Therefore, the first measurements were used for this study. There was no difference between the

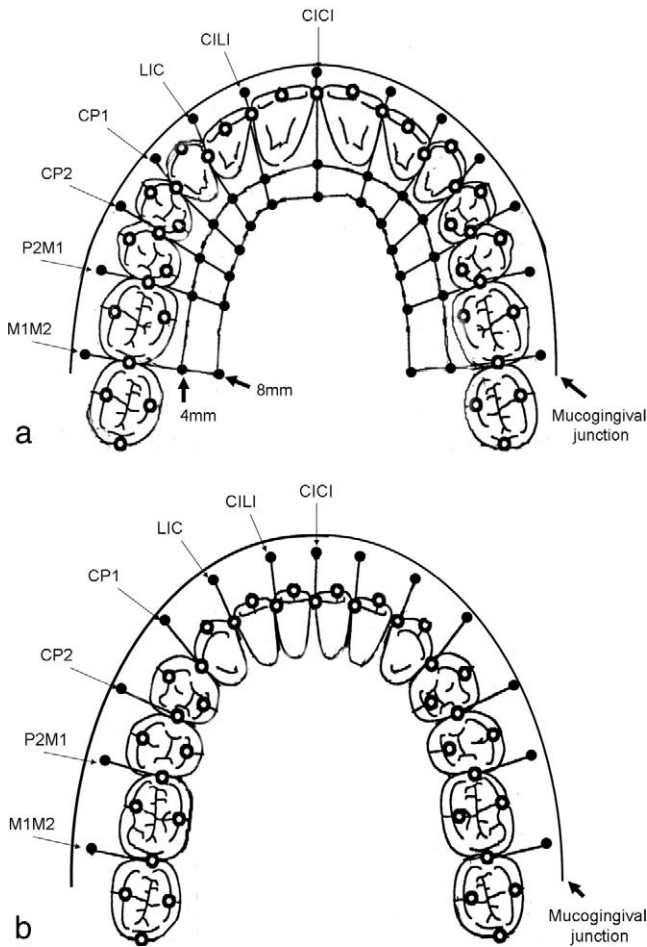


Figure 2. Location of measurement points. (a) the maxillary arch, (b) the mandibular arch. CICI indicates area between the central incisors; CILI, area between the central and lateral incisors; LIC, area between the lateral incisor and the canine; CP1, area between the canine and the first premolar; P1P2, area between the first and second premolars; P2M1, area between the second premolar and the first molar; M1M2, area between the first and second molars. The mean vertical levels of the attached gingiva from the interproximal papilla tip were maxillary arch: CICI, 8.17 ± 1.32 mm; CILI, 8.93 ± 1.13 mm; LIC, 9.06 ± 1.00 mm; CP1, 9.10 ± 1.22 mm; P1P2, 7.87 ± 1.17 mm; P2M1, 7.87 ± 1.20 mm; M1M2, 8.02 ± 1.63 mm; mandibular arch: CICI, 6.86 ± 1.01 mm; CILI, 7.45 ± 1.15 mm; LIC, 7.74 ± 1.15 mm; CP1, 7.23 ± 0.99 mm; P1P2, 6.65 ± 0.92 mm; P2M1, 6.80 ± 0.81 mm; M1M2, 6.36 ± 1.01 mm.

right and left sides in a paired *t*-test, so average values of the variables of both sides were used.

Independent *t*-test, paired *t*-test, and one-way analysis of variance were used for statistical analysis to find out area- and gender-related differences.

RESULTS

Although there was no gender difference in the buccal AG thickness of the lower arch, men had a greater buccal AG than women in four areas:

- between the central and lateral incisors (CILI, $P < .01$);
- between the lateral incisor and the canine (LIC, $P < .05$);
- between the canine and the first premolar (CP1, $P < .05$); and
- between the second premolar and the first molar (P2M1, $P < .05$) of the upper arch (Table 1).

Both men and women showed a similar pattern of difference in the buccal AG thickness between the upper and lower arches. The areas between the anterior teeth and the premolars in the upper arch showed higher values of soft-tissue thickness than did the lower arch (men: area between the central incisors [CICI], $P < .05$; CILI, $P < .001$; area between the first and second premolars [P1P2], $P < .001$; women: CICI, $P < .001$; CILI, $P < .001$; P1P2, $P < .05$) (Table 1). However, the lower arch had significantly thicker soft tissue in the area between the first and second molars than did the upper arch (men and women, $P < .001$) (Table 1).

No gender difference was found in the PMM thickness at 4 mm and 8 mm below the gingival crest except at 8 mm below the gingival crest between the first and second premolars ($P < .01$) (Table 2). There was an opposite tendency in the change of the soft-tissue thickness from 4 mm to 8 mm below the gingival crest and a decrease of thickness in the areas between the anterior teeth (men: CICI, $P < .05$; CILI, $P < .001$; women: CICI, $P < .05$; CILI, $P < .05$; LIC, $P < .01$) and an increase in the areas between the posterior teeth (men: CP1, $P < .05$; P1P2, $P < .001$; P2M1, $P < .001$; M1M2, $P < .001$; women: P2M1, $P < .001$; M1M2, $P < .001$) (Table 2).

Men and women showed a similar pattern of change in the soft-tissue thickness according to areas in the buccal AG. In the upper arch the areas between the anterior teeth (incisors and canines) showed higher values than did other areas ($P < .001$) (Table 3). In the lower arch, the areas between the first and second molars and between the lateral incisor and canine showed higher values ($P < .001$) (Table 3).

In the PMM, 4 mm below the gingival crest, the areas between the canine, the first premolar, and the second premolars showed higher values than other areas ($P < .001$) (Table 3). However, the soft-tissue thickness 8 mm below the gingival crest showed a progressive increase from the anterior to the posterior areas ($P < .001$) (Table 3).

DISCUSSION

Accuracy and reliability of ultrasonic assessments of soft-tissue thickness in different parts of the oral cavity may depend on placing the device precisely and re-

Table 1. Thickness of the Buccal-Attached Gingiva of the Upper and Lower Arches^a

| Buccal-Attached Gingiva | | Men (N = 28) | | Women (N = 33) | | P ^b |
|-------------------------|------|--------------|------|----------------|------|----------------|
| | | Mean | SD | Mean | SD | |
| Upper arch | CICI | 1.20† | 0.18 | 1.28†† | 0.17 | .0931 |
| | CILI | 1.84†† | 0.53 | 1.48†† | 0.48 | .0077** |
| | LIC | 1.48 | 0.44 | 1.26 | 0.31 | .0232* |
| | CP1 | 1.14 | 0.23 | 1.05 | 0.15 | .0496* |
| | P1P2 | 1.25†† | 0.32 | 1.12† | 0.25 | .0830 |
| | P2M1 | 1.23 | 0.32 | 1.09 | 0.20 | .0383* |
| | M1M2 | 1.11†† | 0.21 | 1.05†† | 0.15 | .1815 |
| Lower arch | CICI | 1.07 | 0.26 | 1.09 | 0.29 | .7866 |
| | CILI | 1.07 | 0.18 | 1.18 | 0.33 | .1154 |
| | LIC | 1.27 | 0.40 | 1.24 | 0.36 | .7928 |
| | CP1 | 1.09 | 0.24 | 1.06 | 0.17 | .5825 |
| | P1P2 | 1.02 | 0.09 | 1.02 | 0.09 | .9078 |
| | P2M1 | 1.09 | 0.20 | 1.05 | 0.15 | .3202 |
| | M1M2 | 1.61 | 0.44 | 1.53 | 0.45 | .5035 |

^a Paired *t*-test to compare the variables between upper and lower arches; † *P* < .05; †† *P* < .001; men: *P* value of CICI, 0.0411; of CILI, 0.0000; of P1P2, 0.0002; of M1M2, 0.0000; women: *P* value of CICI, 0.0003; of CILI, 0.0002; of P1P2, 0.0326; of M1M2, 0.0000.

^b Independent *t*-test to compare the variables between men and women; * *P* < .05; ** *P* < .01; CICI, area between the central incisors; CILI, area between the central and lateral incisors; LIC, area between the lateral incisor and the canine; CP1, area between the canine and the first premolar; P1P2, area between the first and second premolars; P2M1, area between the second premolar and the first molar; M1M2, area between the first and second molars.

Table 2. Thickness of the Palatal Masticatory Mucosa at 4 mm and 8 mm Below Gingival Crest^a

| Palatal Masticatory Mucosa | | Men (N = 28) | | Women (N = 33) | | P ^b |
|----------------------------|------|--------------|------|----------------|------|----------------|
| | | Mean | SD | Mean | SD | |
| 4 mm below gingival crest | CICI | 2.39† | 0.79 | 2.73† | 0.84 | .1158 |
| | CILI | 2.70†† | 0.52 | 2.50† | 0.57 | .1677 |
| | LIC | 2.80 | 0.64 | 2.82†† | 0.77 | .9368 |
| | CP1 | 3.14† | 0.68 | 3.21 | 0.57 | .6671 |
| | P1P2 | 3.20†† | 0.80 | 3.26 | 0.56 | .7274 |
| | P2M1 | 2.88†† | 0.72 | 2.77†† | 0.81 | .6065 |
| | M1M2 | 2.43†† | 0.90 | 2.67†† | 0.85 | .2940 |
| 8 mm below gingival crest | CICI | 2.00 | 0.90 | 2.18 | 1.24 | .5211 |
| | CILI | 2.07 | 0.60 | 2.11 | 0.69 | .8374 |
| | LIC | 2.75 | 0.69 | 2.53 | 0.65 | .2046 |
| | CP1 | 3.43 | 0.73 | 3.17 | 0.60 | .1278 |
| | P1P2 | 3.79 | 0.70 | 3.26 | 0.70 | .0046** |
| | P2M1 | 3.39 | 0.77 | 3.30 | 0.85 | .6694 |
| | M1M2 | 4.14 | 1.68 | 4.35 | 1.66 | .6332 |

^a Paired *t*-test to compare the variables between upper and lower arches; † *P* < .05; †† *P* < .001; men: *P* value of CICI, 0.0249; of CILI, 0.0000; of CP1, 0.0468; of P1P2, 0.0003; of P2M1, 0.0003; of M1M2, 0.0000; women: *P* value of CICI, 0.0198; of CILI, 0.0152; of LIC, 0.0058; of P2M1, 0.0013; of M1M2, 0.0000.

^b Independent *t*-test to compare the variables between men and women; * *P* < .05; ** *P* < .01; CICI, area between the central incisors; CILI, area between the central and lateral incisors; LIC, area between the lateral incisor and the canine; CP1, area between the canine and the first premolar; P1P2, area between the first and second premolars; P2M1, area between the second premolar and the first molar; M1M2, area between the first and second molars.

peatedly at the specified location.²⁶ Therefore, areas that are difficult to access with the sensor, such as the midpalatal area, the retromolar pad, and the maxillary tuberosity where the third molars could be located under the soft tissue, were excluded in this study. These areas also have considerable variation in soft-tissue thickness.^{27,28}

Although Eger et al²⁴ reported no differences in means and standard deviations between different age

groups, we restricted this study to samples from adults younger than 30 years to be certain that there were no age-related effects on soft-tissue thickness.

In the upper arch, men had thicker buccal AG than did women (Table 1), in accord with the results of former studies.^{23,27,28} However, the lower arch did not show significant difference between men and women (Table 1).

When we compared the buccal AG thickness be-

Table 3. Comparison of the Soft-Tissue Thickness in the Buccal-Attached Gingiva and the Palatal Masticatory Mucosa According to Areas^a

| | | | CICI (1) | CILI (2) | LIC (3) | CP1 (4) | P1P2 (5) | P2M1 (6) | M1M2 (7) | <i>P</i> | Multiple Comparison |
|--|---|--|-------------|-------------|------------|------------|-------------|-------------|-------------|---------------------------------|---|
| Men | Buccal-at- tached gingiva | Upper arch | 1.20 | 1.84 | 1.48 | 1.14 | 1.25 | 1.23 | 1.11 | .0000*** | (7, 4, 1, 6, 5) < 3 < 2 |
| | | Lower arch | 1.07 | 1.07 | 1.27 | 1.09 | 1.02 | 1.09 | 1.61 | .0000*** | (5, 1, 2, 4, 6) < 3 < 7 |
| | Palatal mastica- tory mu- cosa | 4 mm be- low the gingival crest | 2.37 | 2.70 | 2.80 | 3.14 | 3.20 | 2.88 | 2.43 | .0000*** | (1, 7, 2) < (7, 2, 3) < (2, 3, 6) < (3, 6, 4, 5) |
| 8 mm be- low the gingival crest | | 2.00 | 2.07 | 2.75 | 3.43 | 3.79 | 3.39 | 4.14 | .000*** | (1, 2) < 3 < (6, 4, 5) < (5, 7) | |
| Women | Buccal-at- tached gingiva | Upper arch | 1.28 | 1.48 | 1.26 | 1.05 | 1.12 | 1.09 | 1.05 | .0000*** | (4, 7, 6, 5) < (3, 1) < 2 |
| | | Lower arch | 1.06 | 1.18 | 1.24 | 1.06 | 1.02 | 1.05 | 1.53 | .0000*** | (5, 6, 1, 4) < (6, 1, 4, 2) < (2, 3) < 7 |
| | Palatal mastica- tory mu- cosa | 4 mm be- low the gingival crest | 2.73 | 2.50 | 2.82 | 3.21 | 3.26 | 2.77 | 2.67 | .0000*** | (2, 7, 1, 6, 3) < (4, 5) |
| | | 8 mm be- low the gingival crest | 2.18 | 2.11 | 2.53 | 3.17 | 3.26 | 3.30 | 4.35 | .0000*** | (2, 1, 3) < (4, 5, 6) < 7 |

One-way analysis of variance test to compare the variables among areas in men and women; Post-hoc test by Duncan; means for groups in homogeneous subsets are displayed. *** $P < .001$; CICI, area between the central incisors; CILI, area between the central and lateral incisors; LIC, area between the lateral incisor and the canine; CP1, area between the canine and the first premolar; P1P2, area between the first and second premolars; P2M1, area between the second premolar and the first molar; M1M2, area between the first and second molars.

tween the upper and lower arches, the areas between the anterior teeth and the premolars in the upper arch and the area between the molars in the lower arch had significantly thicker soft tissue than did the corresponding areas in the lower and upper arches, respectively (Table 1). This suggests that the different failure ratios of OMS in those areas between the upper and lower arches¹⁶ might be related to soft-tissue thickness.

In the PMM at 4 mm and 8 mm below the gingival crest, there was no difference in thickness based on gender (Table 2). This was in accord with the results of a former study.²⁵

The PMM thickness between 4 mm and 8 mm below the gingival crest, the areas between the anterior teeth at the level of 4 mm below the gingival crest, and the areas between the posterior teeth at the level of 8 mm below the gingival crest had significantly thicker soft tissue than did the corresponding areas (Table 2). Wara-aswapati et al¹⁹ reported results similar to those of this study. These findings suggest that thickness of the PMM changes from the gingival margin toward the mid-palate, with the opposite tendency in the anterior and posterior areas, respectively.

When we compared the buccal AG thickness among

different areas in the upper and lower arches, the areas between the lateral incisor and canine in the upper arches and the areas between the first and second molars in the lower arch had significantly thicker soft tissue than did the other areas in both men and women (Table 3).

Although the stability of OMSs depends on the quality and quantity of the cortical bone, areas of thin soft tissue are more suitable for implantation because the likelihood of inflammation is lower.¹⁸ Maximum retention can be obtained when OMSs are placed in areas of thin soft tissue and thick cortical bone. If the AG in those regions is not large enough, it is best to place the OMS coronally or mesio-distally in the same area or to look for the different area with more support of the AG.

In the PMM the areas between the canine and the first premolar and between the first and second premolars showed higher values than other areas at the level of 4 mm below the gingival crest (Table 3), which was in accord with the results of former studies.^{27,28} The soft-tissue thickness at the level of 8 mm below the gingival crest showed a progressive increase from the anterior to the posterior areas (Table 3). This was also in accord with the results of a former study.¹⁹

On the palatal side, variations of the soft-tissue thickness were greater than were variations of the cortical bone thickness.¹⁸ Therefore, when OMSs are implanted in the palatal side clinicians have two options: (1) An OMS longer than conventional ones could help compensate for the thicker soft tissue in the areas between the canine and the first premolar, between the first and second premolars at 4 mm below the gingival crest, and between the posterior areas at 8 mm below the gingival crest; and (2) OMSs should be placed in areas where the soft tissue is thinner at the level of 4 or 8 mm below the gingival crest.

CONCLUSION

- Measurements of the STT (soft tissue thickness) of the BAG (buccal attached gingiva) and the PMM (palatal masticatory mucosa) using an ultrasonic device could help to select the proper orthodontic miniscrew in daily clinical practice.

REFERENCES

- Kanomi R. Mini-implant for orthodontic anchorage. *J Clin Orthod.* 1997;31:763–767.
- Park HS, Bae SM, Kyung HM, Sung JH. Micro-implant anchorage for treatment of skeletal Class I bialveolar protrusion. *J Clin Orthod.* 2001;35:417–422.
- Bae SM, Park HS, Kyung HM, Kwon OW, Sung JH. Clinical application of micro-implant anchorage. *J Clin Orthod.* 2002;36:298–302.
- Kyung SH, Hong SG, Park YC. Distalization of maxillary molars with a midpalatal miniscrew. *J Clin Orthod.* 2003;37:22–26.
- Kyung HM, Park HS, Bae SM, Sung JH, Kim IB. Development of orthodontic micro-implants for intraoral anchorage. *J Clin Orthod.* 2003;37:321–328.
- Kyung SH, Choi JH, Park YC. Miniscrew anchorage used to protract lower second molars into first molar extraction sites. *J Clin Orthod.* 2003;37:575–579.
- Lee JS, Kim DH, Park YC, Kyung SH, Kim TK. The efficient use of midpalatal miniscrew implants. *Angle Orthod.* 2004;74:711–714.
- Chung K, Kim SH, Kook Y. C-orthodontic microimplant for distalization of mandibular dentition in class III correction. *Angle Orthod.* 2005;75:119–128.
- Heymann GC, Tulloch JF. Implantable devices as orthodontic anchorage: a review of current treatment modalities. *J Esthet Restor Dent.* 2006;18:68–79.
- McGuire MK, Scheyer ET, Gallerano RL. Temporary anchorage devices for tooth movement: a review and case reports. *J Periodontol.* 2006;77:1613–1624.
- Deguchi T, Takano-Yamamoto T, Kanomi R, Hartsfield JK Jr, Roberts WE, Garetto LP. The use of small titanium screws for orthodontic anchorage. *J Dent Res.* 2003;82:377–381.
- Miyawaki S, Koyama I, Inoue M, Mishima K, Sugahara T, Takano-Yamamoto T. Factors associated with the stability of titanium screws placed in the posterior region for orthodontic anchorage. *Am J Orthod Dentofacial Orthop.* 2003;124:373–378.
- Cheng SJ, Tseng IY, Lee JJ, Kok SH. A prospective study of the risk factors associated with failure of mini-implants used for orthodontic anchorage. *Int J Oral Maxillofac Implants.* 2004;19:100–106.
- Kim JW, Ahn SJ, Chang YI. Histomorphometric and mechanical analyses of the drill-free screw as orthodontic anchorage. *Am J Orthod Dentofacial Orthop.* 2005;128:190–194.
- Cho HJ. Clinical applications of mini-implants as orthodontic anchorage and the peri-implant tissue reaction upon loading. *J Calif Dent Assoc.* 2006;34:813–820.
- Park HS, Jeong SH, Kwon OW. Factors affecting the clinical success of screw implants used as orthodontic anchorage. *Am J Orthod Dentofacial Orthop.* 2006;130:18–25.
- Kuroda S, Sugawara Y, Deguchi T, Kyung HM, Takano-Yamamoto T. Clinical use of miniscrew implants as orthodontic anchorage: success rates and postoperative discomfort. *Am J Orthod Dentofacial Orthop.* 2007;131:9–15.
- Kim HJ, Yun HS, Park HD, Kim DH, Park YC. Soft-tissue and cortical-bone thickness at orthodontic implant sites. *Am J Orthod Dentofacial Orthop.* 2006;130:177–182.
- Wara-aswapati N, Pitiphat W, Chandrapho N, Rattanayatikul C, Karimbux N. Thickness of palatal masticatory mucosa associated with age. *J Periodontol.* 2001;72:1407–1412.
- Poggio PM, Incorvati C, Velo S, Carano A. “Safe zones”: a guide for miniscrew positioning in the maxillary and mandibular arch. *Angle Orthod.* 2006;76:191–197.
- Deguchi T, Nasu M, Murakami K, Yabuuchi T, Kamioka H, Takano-Yamamoto T. Quantitative evaluation of cortical bone thickness with computed tomographic scanning for orthodontic implants. *Am J Orthod Dentofacial Orthop.* 2006;129:721. e7–12.
- Lost C, Irion KM, Nussle W. Ultrasonic B-scans of the facial/oral periodontium in pigs. *J Clin Periodontol.* 1989;16:534–538.
- Uchida H, Kobayashi K, Nagao M. Measurement in vivo of masticatory mucosal thickness with 20 MHz B-mode ultrasonic diagnostic equipment. *J Dent Res.* 1989;68:95–100.
- Eger T, Muller HP, Heinecke A. Ultrasonic determination of gingival thickness. Subject variation and influence of tooth type and clinical features. *J Clin Periodontol.* 1996;23:839–845.
- Studer SP, Allen EP, Rees TC, Kouba A. The thickness of masticatory mucosa in the human hard palate and tuberosity as potential donor sites for ridge augmentation procedures. *J Clin Periodontol.* 1997;68:145–151.
- Muller HP, Schaller N, Eger T. Ultrasonic determination of thickness of masticatory mucosa: a methodologic study. *Oral Surg Oral Med Oral Pathol Oral Radiol Endod.* 1999;88:248–253.
- Muller HP, Heinecke A, Schaller N, Eger T. Masticatory mucosa in subjects with different periodontal phenotypes. *J Clin Periodontol.* 2000;27:621–626.
- Muller HP, Schaller N, Eger T, Heinecke A. Thickness of masticatory mucosa. *J Clin Periodontol.* 2000;27:431–436.
- Schulze RK, Curic D, d’Hoedt B. B-mode versus A-mode ultrasonographic measurements of mucosal thickness in vivo. *Oral Surg Oral Med Oral Pathol Oral Radiol Endod.* 2002;93:110–117.