



A clinical study on the alveolar crest height after secondary alveolar bone graft in the cleft alveolus patients : Preliminary Study

Jin-Young Choi, Myung-Jin Kim, Su-Gon Kim, Jung-Ju Eune, Pill-Hoon Choung
Dept. of Oral & Maxillofacial Surgery, College of Dentistry, Seoul National University

ABSTRACT

치조 파열 환자에 있어서 이차성 골이식술 후의 치조정 높이 변화에 관한 임상적 연구 : 예비적 연구

최진영, 김명진, 김수곤, 윤정주, 정필훈

서울대학교 치과대학 구강악안면외과학교실

목적 : 치조파열 환자에 있어서 이차 치조골 이식술을 시행한 후 그 결과를 알아보고자 방사선학적 분석을 통하여 평가하였다. 본 연구의 목적은 수술전 골결손부 인접치아의 치조정 높이와 수술후 골결손부 인접치아의 치조정 높이를 근심측과 원심측에서 각각 측정함으로써 치조정의 높이가 과연 통계적으로 유의성 있게 증가하는지와 치조골 이식술의 성공률이 치조열의 너비와 상관관계가 있는지의 여부를 알아보는 것이다.

환자 및 방법 : 1991년부터 1999년까지 서울대학교병원 구강악안면외과에서 자가장골 채취 후 분쇄피질망상골 형태 또는 block 피질망상골 형태로 이식한 편측성 치조열을 가진 환자 중 최소한 6개월이 경과한 환자 56명을 연구대상으로 하였고 두 술자에 의해 시술되었다. 수술전 골결손부 인접치아의 치조정의 높이와 치조열의 너비 및 수술후 이식한 골의 높이와 절흔의 양은 치과용 파노라마 방사선 사진을 이용하여 측정하였고, 치조열의 너비는 모델이나 환자의 골결손부 근심치아의 근원심 폭경을 이용하여 환산하였다. 그리고 이식한 골의 높이와 절흔의 양을 1995년 Long이 제시한 방법으로 측정하여 술전의 측정치와 비교하였다.

결과 : 치조열의 너비는 평균 6.9mm(1.9mm-12.1mm) 였다. 근심에서의 치아는 골이식 당시 중절치가 52개(92.9%), 측절치가 4개(7.1%)였고, 49명의 환자에서 완전맹출을, 6명의 환자에서 부분맹출(측절치 2개, 중절치 4개)을 보였다. 원심측에서의 치아는 골이식 당시 측절치가 25개(44.6%), 견치가 29개(51.8%), 소구치가 2개(3.6%)였고, 완전 맹출이 32.1%, 부분 맹출이 57.2%, 미맹출이 10.7%로서 완전히 맹출하기 전에 골이식한 경우가 67.9%였다. 모든 환자에 있어서 bony bridge가 나타났고, 절흔이 인접치 아래로 연장되지 않았으며, 치조골 이식술 후 oronasal fistula를 보인 환자는 한 명도 없었으므로 성공률은 100%였다. 술후 근심측에서의 치조정의 높이는 근심측 치아 치근길이의 79%(평균), 원심측에서의 치조정의 높이는 원심측 치아 치근길이의 87%(평균)로서 통계적으로 유의성 있게 증가하였다.

결론 : 이차 치조골 이식술을 시행한 후 치조정의 높이는 골결손부 근심측과 원심측에서 모두 유의성 있게 증가하였고, 근심측에서보다 원심측에서 통계학적으로 더 유의성 있게 증가하였다. 치조열의 너비와 절흔의 양, 치조정의 높이 및 치조골이식 성공률과는 유의성 있는 관련성이 없었다.

주요어: 치조 파열, 이차성 골이식, 치조성 높이

* 본 연구는 1999년도 서울대학교병원 임상 공동 연구비 보조로 이루어졌음

I. Introduction

Secondary alveolar bone grafting was first described by Boyne and Sands in 1972, 1976.^{1,2)} Use of the technique has become accepted as a means of uniting and stabilizing the segments of the maxilla prior to definitive orthodontic and restorative dental treatment.³⁾ Ideally, the technique is performed early enough to allow eruption of the permanent canine into the grafted bone.⁴⁾ Assessing the success of the graft radiographically has previously been carried out on a long-term basis. Bergland et al. focused on the height of the interdental septum adjacent to the erupted canine, and used radiographs taken at least 1 year after surgery for the assessment. In 64% of 450 grafted clefts, a normal height of interdental septum was achieved, and the cleft space was closed in 90% of cases.^{4,6)} Kim et al. have evaluated the height of interdental septum using Bergland index after secondary alveolar bone graft in cleft alveolus patients,^{7,8)} but have not examined the contour of grafted bone using modified method of Long. The purpose of this study is to examine (1) cleft width, (2) eruption stage and status of teeth in the proximal and distal segments, (3) bone contour adjacent to the cleft and change of the alveolar crest height after bone graft, (5) correlation between cleft width and the bone graft success.

II. Patients and Methods

1. Patients

This was a retrospective study using records of patients managed by two surgeons at department of oral and maxillofacial surgery in Seoul National University from 1991 to 1999. Only cases with complete clinical records, and orthopantomogram of sufficient quality to assess bone attachment and alveolar crest heights were included in this study. Fifty-six unilateral cleft patients were selected. Thirty-six patients were male and twenty patients were female.

The average age at the time of bone grafting was 12.9 years, with a range of 5 to 30 years(see Table 1). The average age at follow-up was 14.0 years with a range of 9 to 31 years. The average time of follow-up after grafting was 17 months ranging from 6 months to 66 months.

The requirement for the postoperative follow-up period was a minimum of 6 months.

Bones used for grafting were taken from the iliac bone in 56 cases. The procedure for harvest of iliac bone was as follows: While iliac bone was harvested as particulated corticocancellous bone or corticocancellous block bone, the cleft area was exposed subperiosteally through the vertical incisions along the edges of the cleft on the labial side. Harvested particulated corticocancellous bone or corticocancellous block bone was inserted into the alveolar cleft defect area.^{7,8,9)}

Table 1. Distribution of Age at Operation

Ages	No. of Patients(%)
2-5	1(1.8%)
6-15	44(78.6)%
16 <	11(19.6)

2. Methods

1) Cleft Width Measurement

One of the authors measured the distance from CEJ to alveolar crest and cleft width using presurgical orthopantomography like Fig.1. A distortion correction was attempted by determining the ratio of the radiographic width of the tooth adjacent to the cleft of proximal segment compared with the actual width of this tooth measured on study models. The radiographic width was then multiplied by this factor to approximate true cleft width.

2) Eruption Stage and Status of Teeth in the Proximal and Distal Segments

Presurgical orthopantomogram was used to determine eruption stage of teeth, status of teeth in the proximal and distal segments.

The eruption stages of the teeth adjacent to the cleft were determined from the radiographs and noted as follows:

1. Unerupted - Crown of the tooth completely encased in bone.
2. Partially erupted - A part of the crown had emerged through the bone; this was determined by a break in the radiopaque outline of the dental follicle.
3. Fully erupted - Tooth in its final erupted position in the arch; represented on the radiographs with a uniform width of periodontal ligament around the root.⁶⁾

3) Measurement of Bone Contour and Alveolar Crest Height

A modified method of assessing bone architecture of the graft as reported by Helms et al.(1987) was used(Fig. 2, Long, 1995). However, in addition to the direct measurement taken from the radiograph, for the purpose of statistical analysis and to avoid the potential

distortion factors of radiographic elongation or foreshortening, all measurements were converted to ratio measurements using the various measures of alveolar bone height(variables B, C, D, F, and G in Fig. 2) as the numerator and the root length of teeth adjacent to the cleft(variables A and E in Fig. 2) as the denominator. In this series of patient, bone coverage at the apex of the root in the proximal segment did not always occur, so bone height could not always be measured from the apex of this tooth. In addition, therefore, to the measurements of the bone attachment, represented by the ratios B/A and F/E in the proximal and distal segments respectively, alveolar crest height, as reflected by its approximation to the cemento-enamel junction, was measured as the ratio C/A for the tooth in the proximal segment and G/E for the tooth in the distal segment. Using this method, the failure of the establishment of a bony bridge would be represented in one of two ways : (1) when there was no bone support present on either root adjacent to the cleft(i.e., no measurement for B or F) or (2) when notching of the grafted alveolus extended to or below the apex of the root adjacent to the cleft. This was reflected by the measurement $D/A > 1.6$

4) Statistical Analysis

We used paired t-test to assess whether the height of alveolar crest increases after alveolar bone grafting into the alveolar cleft. In order to assess if cleft width and the success of the bone graft as determined by the previously mentioned radiograph measurements, linear regression statistics were used. A level of $p < 0.05$ was set to determine a relationship that would be considered statistically significant.

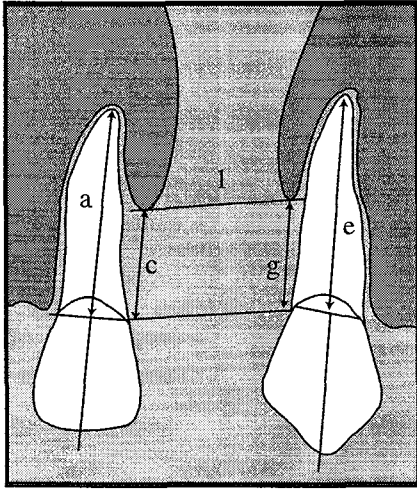


Fig. 1. Preop. measurement

l : Cleft width
 a = length of proximal segment anatomic root from apex to cemento enamel junction
 c = the location of alveolar crest bone on the distal surface of the proximal segment root
 e = length of distal segment anatomic root (from apex to cemento enamel junction)
 g = the location of alveolar crest bone on the mesial surface of the distal segment root

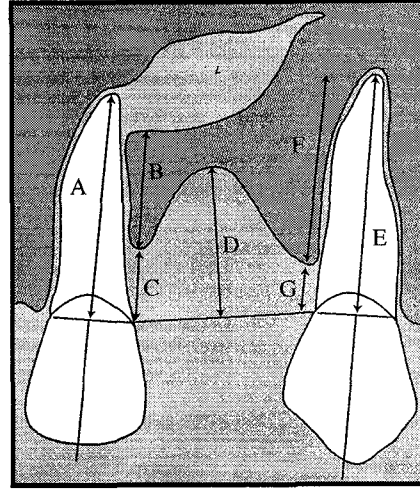


Fig. 2. Postop. measurement

A = length of proximal segment anatomic root (from apex to cemento enamel junction) : B = the most coronal attachment of bone along the distal surface of the proximal segment root : C = the location of alveolar crest bone on the distal surface of the proximal segment root : D = the amount of notching of bone graft : E = length of distal segment anatomic root (from apex to cemento enamel junction) : F = the most coronal attachment of bone along the mesial surface of the distal segment root : G = the location of alveolar crest bone on the mesial surface of the distal segment root (Long et al, Cleft Plate Craniofac J, 1995)

III. Results

1. Cleft Width

A total of 56 cleft sites was observed. The mean cleft width was 6.9 mm with a range of 1.9 mm to 12.1 mm.

2. Teeth in the Proximal and Distal Segments

The tooth in the proximal segment was a central incisor in 92.9%(52 cases) of the clefts. The incidence of a lateral incisor occurring as the tooth in the proximal segment was 7.1%(4

cases). The proximal tooth was fully erupted in 49 cases, and partially erupted in 6 cases(4 central incisors, 2 lateral incisors), and unerupted in 1 case(1 case) at the time of surgery (see Table 2). The eruption stage of the teeth in the distal segment was varied. In the distal segment, 51.8 %(29 cases) of teeth were canines. At the time of bone grafting, 20.7%(6 cases) of the canines were unerupted, 48.3%(14 cases) were partially erupted, and 31.0%(9 cases) of the canines had erupted completely into the arch. The distal tooth was a lateral incisor in 44.6%(25 cases) of the sample. At

Table 2. Eruption Stage of the Teeth in the Proximal Segment

Eruption Tooth	Eruption Stage			Total
	Fully Erupted	Partially Erupted	Unerupted	
Central Incisor	47(90.4%)	4(14.8%)	1(3.7%)	52(92.9%)
Lateral Incisor	2(50.0%)	2(50.0%)	0	4(7.1%)
Total	49(87.5%)	6(10.7%)	1(1.8%)	56(100%)

Table 3. Eruption Stage of the Teeth in the Distal Segment

Eruption Tooth	Eruption Stage			Total
	Fully Erupted	Partially Erupted	Unerupted	
Canine	9(31.0%)	14(48.3%)	6(20.7%)	29(51.8%)
Lateral Incisor	7(28.0%)	18(72.0%)	0	25(44.6%)
Premolar	2(100%)	0	0	2(3.6%)
Total	18(32.1%)	32(57.2%)	6(10.7%)	56(100%)

the time of bone grafting, 72.0%(18 cases) of the lateral incisors were partially erupted, and 28.0%(7 cases) of the lateral incisors had erupted completely into the arch. The distal tooth was a premolar in 3.6%(2 cases) of the sample. Therefore 38 teeth(67.9%) in the distal segment were unerupted at the time of alveolar bone grafting (see Table 3).

3. Bone Graft Contour and Change of the Alveolar Crest Height

The amount of bone, at the distal surface of the tooth adjacent to the cleft in the proximal segment, usually relates to the success of the bone graft in providing alveolar support for this tooth. This characteristic was expressed in the ratios of B/A and C/A. The mean figure for the ratio B/A was 0.79 and for C/A, 0.20. The apex of the proximal root lacked bone coverage in 7.1%(4 cases) of the clefts. This was shown when the sum of ratios B/A and C/A was less than 1. The ratio D/A measured the amount of

notching of the alveolar ridge at the grafted site. D was taken from the greatest depth in the alveolar ridge measured along the perpendicular to the intersection of the line between the cemento-enamel junctions of the teeth adjacent to the cleft, C and G. The mean ratio for this sample, indicative of alveolar notching, was 0.37. Postoperative elimination of the characteristic notching, evident in patients prior to bone grafting, is a measure of the effectiveness of the bone graft in creating a more esthetic ridge. The similar analysis of the bone support for the tooth closest to the cleft in the distal segment is described by the ratios F/E and G/E. The mean for the former was 0.87 and for the latter 0.13.

Our sample achieved a bony bridge in 100% of the cases, and the success rate was 100% : (1) In all cases there were bone supports present on either root adjacent to the cleft. (2) In any case notching of the grafted alveolus did not extend to or below the apex of the root

Table 4. Comparison of the Alveolar Bone Height Pre- and Postoperatively

	c/a	C/A	g/e	G/E
Mean	0.58	0.20	0.28	0.13
SD	0.25	0.14	0.20	0.11
p value	< 0.0002	< 0.0031		

adjacent to the cleft. (3) In all cases there was no oronasal fistula after secondary alveolar bone grafting into the alveolar clefts.

There was statistically significant increase of alveolar bone height after alveolar bone grafting into the alveolar cleft (see Table 4).

4. Cleft Width and Bone Graft Success

A statistically significant correlations was not found between increasing cleft widths and simultaneous increase in notching(D/A) of the alveolar ridge following bone graft, and between increasing cleft width and decreasing alveolar bone support(B/A, F/E) of teeth adjacent to the cleft, and between increasing cleft width and increasing alveolar bone resorption(C/A, G/E) of teeth adjacent to the cleft. There was no statistically significant correlation between presurgical cleft width and the success of the alveolar bone grafting into the alveolar cleft.

IV. Discussion

The main objectives of alveolar bone grafting into the alveolar cleft include the following: (1) to stabilize the maxillary segments, especially the mobile premaxilla in bilateral cleft cases, (2) to eliminate the need for a prosthesis or at least improve the vestibular soft tissue relationship and alveolar contour and thus facilitate the final prosthetic restoration, (3) to close an oronasal fistula if present and eliminate irregularities in mucosal contour, with subsequent favorable

effect on speech if the fistula is large, (4) to provide bone into which the canine and other adjacent teeth could erupt or be moved orthodontically and, in addition, give the adjacent teeth bony support, (5) to restore the canine eminence, thus providing bone support for the alar base and possibly helping to eliminate nasal asymmetry and relieve obstructed airways, and (6) to consolidate the maxilla so as to facilitate secondary corrective surgery, such as orthognathic surgery.¹⁰⁾

The best time to perform alveolar bone grafting is vigorously debated. The main issue is the desire to accomplish the goals as early as possible without causing adverse effects on the growth of the maxilla or damage to the tooth buds. Secondary alveolar bone grafting is performed after cleft palate repair, and can be organized into early, intermediate, and late timing. Boyne and Sands said primary bone grafting is less than two years of age, early secondary bone grafting is between the ages of 2 and 5 years, secondary bone grafting is between the ages of 6 and 15 years, late secondary bone grafting is mature adults.^{1,2)} Turvey reported the graft should be placed before eruption of the permanent canine to maximize the periodontal benefits, this should take place when approximately 1/2 to 2/3 of the canine root has formed and before eruption into the arch. The age of 8 to 10 year is the usual time for surgery.¹¹⁾ Enemark said that optimum time for alveolar bone graft of the unilateral cleft alveolus is when maxillary growth was

almost complete(8 to 9 years of age), prior to the eruption of the permanent canine tooth.¹²⁾

The mean age of this sample at 12.9 years is above the ideal suggested by the previous research, compared to the Norwegian mean age of 11.6 years, and mean age of sample studied by Long et al. at 11.1 years. We think that it was likely due to the inclusion of several older patients in our study.

Many factors must be considered in attempting to determine the ideal timing for secondary grafting. Chronologic age is not as important as bone age and dentofacial developmental stage to provide bony support of the succedaneous(adult) fissural(next to the graft) teeth. The classically described timing for secondary alveolar bone grafting is when one fourth to three fourths of the succedaneous canine root is formed radiographically. This development is typically seen between 7 and 11 years of age when the majority of transverse and sagittal maxillary growth has already occurred.¹³⁾ Late grafting performed after exposure of the cementum may lead to root resorption and ankylosis of the teeth, predisposing to tooth loss and complicating later orthodontic management. Graft resorption is also increased in grafts placed after eruption of the teeth adjacent to the cleft. This resorption results in a diminished crestal level of the bony interdental septum and, therefore, less support. For these reasons, late grafting is least desirable. A trend toward earlier secondary grafting has developed because of the desire to accomplish the goals of bone grafting earlier and because most of the maxillary growth in the region of the cleft is complete by 5 or 6 years of age.¹⁴⁾ Additionally, earlier grafting provides support to the earlier erupting lateral or even central incisor. The presence and condition of the lateral incisor are pivotal to consideration of earlier timing. If the lateral incisor is absent or

dysmorphic to the point of being nonfunctional(i.e., a "peg" lateralis), the support around the central incisor should be evaluated. When there is adequate bone on the cleft side of the central incisor, grafting is delayed until the canine is near eruption(7 to 11 years of age). If support for the central incisor is lacking, however, grafting at as early as 4 to 6 years of age may be necessary to support this tooth. If the morphology and location of the lateral incisor are adequate, grafting is performed when two thirds to three fourths of its root is formed(6 to 7 years of age).

In the case of 67.9% among our patients, secondary alveolar bone grafting into the alveolar cleft was done before fully eruption of tooth in the distal segment(see Table 3), compared to 83% of Long et al. Similarly we think that it was likely due to the inclusion of several older patients in our study.

In our study the mean cleft width was 6.9 mm with a range of 1.9 mm to 12.1 mm, compared to 5.2 mm with a range of 1.0 mm to 11.2 mm of Long et al. The timing of radiographs in this study showed a large variation. The variation was largely caused by unreliable patient attendance. It is possible that this variation in timing of the radiographs caused inaccurate assessment of bone levels due to the possibility of resorption or remodeling. However, Lija at al. suggested that bone levels do not change significantly between 3 months and 1 year after surgery, unless there has been flap dehiscence. Presurgical orthodontic expansion of maxillary segments, which has the potential to increase substantially the width of the cleft, could be considered as a possible factor influencing the difference of cleft width.

In terms of the success rate of the procedure, our sample achieved a bony bridge in 100% of the cases. In all our cases there was bone support on either root adjacent to the cleft. In

any case notching of the grafted alveolus did not extend to or below the apex of the root adjacent to the cleft. In all our cases there was no oronasal fistula after secondary alveolar bone grafting into the alveolar clefts. Kindelan et al. reported that 5% of the sample were assessed as having no bony bridge across the cleft. Amanat and Langdon reported 6.4% of the grafts being completely resorbed in a similar series of patients.^{6,15} Long et al. reported on a sample of 46 cleft sites, of which 95% had a bony bridge across the cleft after grafting and the success rate for achieving a bony bridge across the cleft was 91%.⁵)

The analysis of bone contour in our study depicts, in the majority of cases, adequate bone support generated for both teeth adjacent to the cleft. The average alveolar crest level was consistently higher for the tooth in the distal segment, indicated by the average G/E ratio being less than C/A (see Table 4). However, the proximal tooth also had good alveolar crest height (mean C/A = 0.20), although with a lower mean than G/E. This concurred with the findings of Teja et al., showing that the alveolar crest height for the tooth in the proximal segment is consistently lower than that of the tooth in the distal segment. They attributed this difference to the eruption of the proximal segment tooth into an unfavorable position prior to alveolar bone grafting ; subsequent presurgical orthodontic manipulation could also have contributed to compromised bone levels. In addition, eruption of the canine tooth through the bone graft in many cases, might have a positive effect on alveolar crestal height. Another interesting observation was that the apex of the proximal root was not always covered by bone. This lack of bone did not occur for any of the teeth in the distal segment (see Table 4). Where there is little bone coverage over the root adjacent to the cleft,

minimal presurgical orthodontics should attempt so as not to jeopardize the integrity of the root apex and its investing bone.^{6,16})

In our results, no significant correlation was not found between presurgical cleft width and the alveolar bone attachment of teeth adjacent to the grafted cleft site and between presurgical cleft width and notching of the alveolar ridge in the region of the bone graft. In the study of Long et al. who measured contours of the grafted bone from radiographs of 46 cleft sites to examine correlation between cleft width and the success of alveolar bone grafting, he reported that there was significant, but low, negative correlation between presurgical cleft width and alveolar bone attachment of teeth adjacent to the grafted cleft site, and notching of the alveolar ridge in the region of the bone graft had a statistically significant low positive correlation with increasing cleft widths, but presurgical cleft width had little or no impact on the success of alveolar bone grafts.⁶)

V. Conclusion

The findings of this study indicate the followings:

1. There was statistically significant increase of alveolar bone height at both proximal segment and distal segment after alveolar bone grafting into the alveolar cleft.
2. The alveolar crest height for the tooth in the proximal segment is lower than that of the tooth in the distal segment in the statistical analysis.
3. There was no statistically significant correlation between presurgical cleft width and the success of the alveolar bone grafting into the alveolar cleft.
4. Secondary alveolar bone grafting resulted in the formation of alveolar process

bridging the maxillary cleft and eliminating oronasal fistula in 100% of the cases.

5. The bone graft provided adequate bone support to the teeth adjacent to the cleft site.

VI. References

1. Boyne PJ, Sands NR : Secondary bone grafting of residual alveolar and palatal defects. *J Oral Surg*;30:87-92, 1972.
2. Boyne PJ, Sands NR : Combined orthodontic-surgical management of residual palato- alveolar cleft defect. *Am J Orthod*; 78:20- 37,1976.
3. Enemark H, Krantz-Simonsen E, Schramm JE : Secondary bone grafting in unilateral cleft lip palate patients: indications and treatment procedure. *Int J Oral Surg* Feb;14(1):2-10, 1985.
4. Bergland O, Semb G, Åbyholm F, Borchgrevink H, Eskeland G : Secondary bone grafting and orthodontic treatment in patients with bilateral complete clefts of the lip and palate. *Ann Plast Surg* Dec;17(6):460-474, 1986.
5. Long RE Jr, Spangler BE, Yow M : Cleft width and secondary alveolar bone graft success. *Cleft Palate Craniofac J* Sep;32(5): 420-427, 1995.
6. Kindelan JD, Nashed RR, Bromige MR : Radiographic assessment of secondary autogenous alveolar bone grafting in cleft lip and palate patients. *Cleft Palate Craniofac J*. May;34(3):195-198, 1997.
7. Kim MJ, Lee JK, Nam KW : A clinical study on the prognosis after secondary osteoplasty in the cleft alveolus patient. *J Kor Asso Oral Maxillofac Surg* 21(2): 183-194, 1995.
8. Kim MJ, Lee JK, Nam KW, Kang NR : A clinical study on the prognosis after secondary bone graft using iliac PMCB in the cleft alveolus patients. *J Kor cleft lip and palate Asso* 1(1):81-87, 1998.
9. Choung PH, Hong JR, Yun PY, Kang NR : Stimulation implant installation with bone graft in cleft alveolus patients. *J Kor cleft lip and palate Asso* 1(1):55-64, 1998.
10. McCanny CM, Roberts-Harry DP : A comparison of two different bone-harvesting techniques for secondary alveolar bone grafting in patients with cleft lip and palate. *Cleft Palate Craniofac J*. Sep;35(5):442-446, 1998.
11. Turvey TA, Vig K, Moriarty J, Hoke J : Delayed bone grafting in cleft maxilla and palate:A retrospective multidisplinary analysis. *Am J Orthod* 86(3):244-256, 1984.
12. Enemark H, Sindet-Pedersen S, Bundgaard M : Long-term results after secondary bone grafting of alveolar clefts. *J Oral Maxillofac Surg* Nov;45(11):913-919, 1987.
13. Cohen M, Polley JW, Figuerosa AA : Secondary alveolar bone grafting. *Clin Plast Surg* 87:423-427, 1991.
14. Hall DH, Werther JR : Conventional alveolar cleft bone grafting. *Oral Maxillofac Surg* 16:41-53, 1988.
15. Amanat N, Langdon JD : Secondary alveolar bone grafting in clefts of lip and palate. *J Craniomaxillofac Surg* 19:7-14, 1991.
16. Teja Z, Persson R, Omnell ML : Periodontal status of teeth adjacent to non-grafted unilateral alveolar clefts. *Cleft Palate Craniofac J* 29:357-362, 1992.

저자 연락처

서울시 종로구 연건동 28번지 서울대학교 치과대학 구강악안면외과 최진영 우편번호)110-744

전화 02-760-3992 E-mail jinychoi@plaza.snu.ac.kr