ORIGINAL ARTICLE

KOREA. J. ORTHOD.
2002. : 32(6) : 455 - 66

Histological Periodontal Tissue Reaction to Rapid Tooth Movement by periodontal Distraction in Dogs

Young-Il Chang[1], Tae-Woo Kim[2], Hee-Young Choi[3]

The objective of this study was to evaluate the changes that occurred over time in the distracted periodontal ligament space following the rapid retraction of a tooth by periodontal distraction after bone undermining surgery had been conducted in the dogs. The upper second premolars were extracted on the left and right side in 4 male beagle dogs. Immediately after extraction, the interseptal bone distal to the upper first premolar was thinned and undermined by grooving to decrease the bone resistance. Activating an individualized distraction appliance at the rate of 0.225 mm twice a day, the upper first premolar was retracted rapidly toward the extraction socket. Periodontal distractions were performed for 5, 10, and 20 days, and 20-day-distraction cases were followed by maintenance periods of 0, 14, 28, and 56 days. After 20 days of rapid retraction, the average distal movement of the upper first premolar was 5.02 mm, and the average mesial movement of the upper third premolars serving as an anchorage unit was 0.58 mm.

On histological examination, the regeneration of bone occurred in a highly organized pattern. Distracted periodontal ligament space was filled with newly formed bone oriented in the direction of the distraction, and this was followed by extensive bone remodeling. This result was similar to those observed in other bones after distraction osteogenesis. In the periodontal ligament, the relationship between collagen fibers and cementum began to be restored 2 weeks after the distraction was completed, and showed almost normal features 8 weeks after the completion of the periodontal distraction. However, on the alveolar side, the new bone formation was still in process and collagen fiber bundles and Sharpey's fibers were not present 8 weeks after the completion of the periodontal distraction. Reactions in the periodontal ligament of the anchorage tooth represented bone resorption on the compressed side and new bone deposition on the tension side as occurred in conventional orthodontic tooth movement. In conclusion, the results of this study showed that periodontal structures on the distracted side of the periodontal ligament were regenerated well histologically following rapid tooth movement.

Key words : Periodontal distraction, Rapid retraction, Bone undermining surgery

[1]Professor, Department of Orthodontics, College of Dentistry, Seoul National University.
[2]Associate Professor, Department of Orthodontics, College of Dentistry, Seoul National University.
[3]Private clinician, Dr.Choi's Orthodontic Clinic.
This study was supported by Ministry of health and welfare (number : 00PJ1-PG3-20500-0039) in 2001-2002.

Reprint requests to : **Young-Il Chang**
Department of Orthodontics, College of Dentistry, Seoul National university.
28-2 Yoenkun-dong, Chongno-Ku, Seoul, Korea Zip 110-749
82-2-760-2678 / doctorchang@plaza.snu.ac.kr

Orthodontic tooth movement is based on a biological response, which involves a tissue reaction in the periodontium. Clinical tooth movement requires the periodontal ligament, and forces applied to the teeth are mediated through the periodontal ligament, resulting in the remodeling of the periodontal tissues. On the tension side of tooth movement, changes are characterized by an initial increase in the width of the periodontal ligament following the stretching of the periodontal ligament fibers, then followed by alveolar bone deposition. On the compression side of the periodontal ligament, the mechanical forces induce either direct bone resorption (frontal bone resorption) or hyalinization with undermining bone resorption.[1-9]

Rapid palatal expansion was introduced as a method of rapidly altering the transverse relationships between the teeth, and between the teeth and the jaw. The method is characterized by widening (distracting) the midpalatal suture through lateral movements of the two horizontal processes of the maxilla.[10-12] The method can be regarded as a mode of distraction osteogenesis, a surgico-orthopedic method for lengthening bone by separating or distracting a fracture callus, and utilizing the natural healing mechanism to generate new bone.[13-15] Conceptually, the sutural connective tissue apparatus and the tooth-supporting periodontal tissues are identical in nature, functioning under rapid intermittent loading as a bioelastic shock-absorbing system.[16] When an optimal tensile force is exerted on these sutures, tissue regeneration with associated bone growth can be induced.

Liou and Huang[17] proposed a new concept called "periodontal distraction" in 1998. This was a method of performing rapid canine retraction by distracting the periodontal ligament with a distraction device. The authors suggested that the process of osteogenesis induced in the periodontal ligament during orthodontic tooth movement was similar to the osteogenesis in the midpalatal suture during rapid palatal expansion. They reported 26 cases of rapid canine retraction that were conducted successfully without any particular complication. Canines were moved bodily 6.5 mm into the extraction space within 3 weeks in these cases.

Even though these researchers showed clinically successful rapid retraction, animal experiments and histological studies of this method had not been fully undertaken. During the rapid canine retraction, periodontal ligaments could be torn and injured more severely than during conventional orthodontic tooth movement, and the repair of the periodontium depends largely on the severity and nature of the damage inflicted.[18] Rapid periodontal distraction may be considered as a type of tissue damage and it is of our concern whether this form of periodontal distraction allows the periodontal tissue the opportunity to completely regenerate all tissues involved in tooth support. Therefore, this study was undertaken to evaluate the changes that occur over time in the distracted periodontal ligament space and in the alveolar bone after the rapid retraction of a tooth through periodontal distraction in dogs.

MATERIALS AND METHODS

1. Experimental Design

Four male beagle dogs, aged 12 to 18 months and weighing between 10 and 12 Kg, were used as experimental subjects. All dogs had a healthy periodontal status. The right and left upper first premolars (single rooted) in each dog were chosen for the rapid retraction, and the right and left lower second premolars were moved using the conventional orthodontic method with Ni-Ti coil springs. Because the lower first premolars were too small to construct an orthodontic appliance, the lower second premolars were used for conventional orthodontic tooth movement.

In a pilot study using two dogs, the surgical technique and the design of the appliance were refined to overcome distraction failures. Nonetheless, rapid retraction in two sides failed in this study, so that the periodontal distractions succeeded in six cases only.

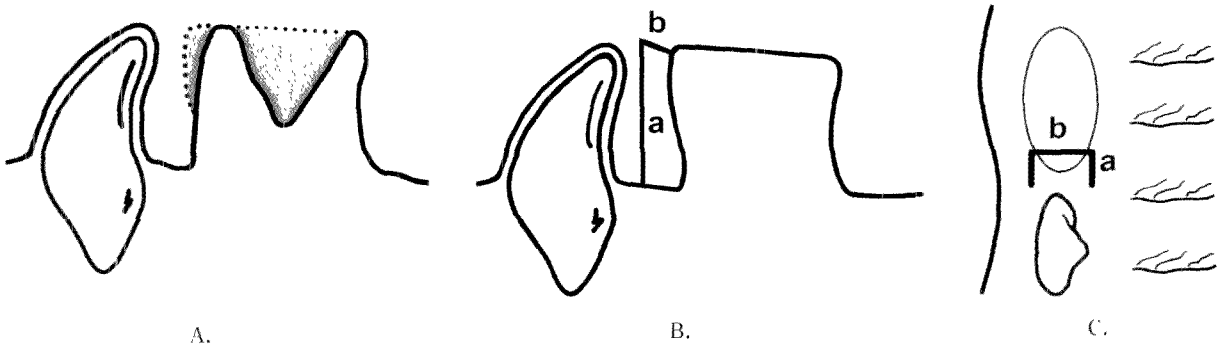

Fig. 1. Schematic drawing of the surgical technique. A. Removal of interradicular septal bone in the extraction socket of the upper second premolar and thinning of interseptal bone distal to the upper first premolar. B, C. Undermining grooves to reduce bone resistance. a: vertical groove, b: oblique groove.

2. Experimental Methods

1) Preparation of the distraction device

All of the experimental procedures were performed under general anesthesia after an intramuscular injection of Ketalar® (Ketamine HCl, Yuhan Co., Korea) and Rompun® (Xylazine HCl, Bayer Korea, Korea) mixture.

A week before surgery, impressions of the upper and lower dental arches were taken using rubber impression material and individual partial trays which were constructed from alginate impression. Full-cast metal crowns were made on the upper first and third premolars, and a distraction screw was soldered on to the crowns. The distraction screw was designed to move 0.45 mm per turn. In the mandibular arches, the crowns of the second and fourth premolars were constructed to distally move the second premolar.

2) Surgical procedures and periodontal distraction protocol

The upper second premolar and the lower third premolar were extracted after a hemisection on the same side of each dog. Immediately after the extraction, the interradicular septal bone in the extraction socket of the upper second premolar was removed with a surgical bur. Because the interseptal bone of the dogs was denser and thicker than that in human beings, the apical third of the interseptal bone distal to the upper first premolar was

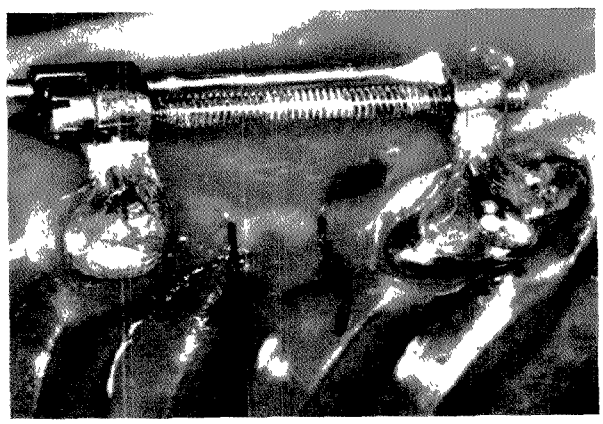

Fig. 2. Distraction appliance for rapid movement of the upper first premolar. The upper third premolar served as anchorage unit.

undermined and thinned to one half of its thickness. The interseptal bone distal to the upper first premolar was then undermined, by grooving vertically inside the extraction socket, along the buccal and lingual sides, and extending this obliquely toward the base of the interseptal bone, as suggested by Liou and Huang[7] (Fig. 1).

Immediately after the surgical procedure, the extraction sockets were sutured, enamels were polished, and the custom-made intraoral distraction device was cemented in place with glass ionomer cement (Fig. 2). In the lower arch, the second and the fourth premolar crowns were also cemented. A NiTi closed coil spring (Ormco, U.S.A.) was then connected

between the buccal hooks on the second and the fourth premolar crowns, and 150-200 gm of force exerted.

A day after these surgical procedures, the activation of the distraction device began at a rate of 0.225 mm (1/2 turn) twice a day for 5 days (1 case), 10 days (1 case), and 20 days (4 cases). After 20 days of activation, these were followed by a maintenance period of 0, 14, 28, and 56 days.

3) Records and Measurements

The amount of tooth movement was measured intraorally with digital calipers at the time of device cementation and every 5 days until the periodontal distraction was completed. The horizontal distances between the cusp of a moved tooth (the upper first premolar, or the lower second premolar) and the canine reference point, and between the cusp of the upper anchor tooth (the upper third premolar) and the upper fourth premolar reference point were measured. Reference points of the upper and lower canines and the upper fourth premolar were grooved on the enamels at the height of of the cusps of the moved teeth (the upper first and lower second premolar) and anchor tooth (the upper third premolar) when the crowns were cemented.

4) Tissue preparation

Throughout the monitoring period, all tested animals were sacrificed by perfusion with 4% paraformaldehyde and their maxillas and mandibles were removed. After removing the soft tissues around the jaw bones, the bones were fixed in 4% paraformaldehyde for 48 hours. The bones were then trimmed of the tissues around the upper first premolars, the upper third premolars, and the lower second premolars.

For staining, specimens were decalcified with 10% EDTA at room temperature for four weeks, dehydrated by increasing concentrations of ethanol, and embedded in paraffin wax. The paraffin-embedded specimens were then sectioned in a mesiodistal plane at 4μm and stained with hematoxylin and eosin to examine the histological changes. Masson's Trichrome staining was used to observe changes in the periodontal ligament fibers and bone regeneration.



Fig. 3. The upper first premolar was distracted distally about 6 mm after 3 weeks of distraction.

RESULTS

1. Tooth movement

In the mandibular arches using the conventional retraction method with a Ni-Ti coil spring, the mean total tooth movement during the first 5 days was 0.38 mm, with the discontinuation of tooth movement was noted in the following 15 days. Thereafter, the rate of tooth movement increased slightly, and amount of movement for 76 days was 1.89 mm.

In the maxillary arches, the first premolars were retracted rapidly by the periodontal distraction (Fig. 3). The amount of tooth movement of the distracted upper first premolar was 1.73 mm and 3.22 mm after 5 and 10 days of distraction, respectively. In the four samples which were distracted for 20 days, the amount of rapid retractions showed large individual differences, and the teeth were moved distally 2.94 mm, 3.71 mm, 6.56 mm and 6.87 mm. The average amount of tooth movement through distraction of the periodontal ligament for 20 days was 5.02 mm.

The mesial movement of the upper third premolars, which served as an anchorage unit for the periodontal

Table 2. Average amount of movement of distracted teeth and anchor teeth in the maxilla.

Duration of distraction(days)	N	The upper first premolar(distraction, mm)	The upper third premolar(anchor teeth, mm)
5	6	1.40 ± 0.50	0.38 ± 0.08
10	5	2.58 ± 1.01	0.44 ± 0.07
15	4	3.54 ± 1.46	0.51 ± 0.09
20	4	5.02 ± 1.99	0.58 ± 0.11

distraction was negligible, and the mean anchorage loss was 0.58 mm in 20 days. This amount of anchorage loss was similar to that experienced in conventional tooth movement in the lower arch. Table 2 presents the mean amounts of dental movement by periodontal distraction and anchorage loss.

2. Histological findings

1) Conventional orthodontic retraction

On the pressure side of the lower second premolar on which force was exerted for 5 days, the periodontal ligament space was compressed and cell free hyalinized tissue stained eosinophilically was observed particularly in the cervical third of the distal side of the distal root. On the tension side, the periodontal ligament increased in thickness and collagen fibers were stretched. Blood vessels were distended and increased in number. However, the formation of new bone was not observed.

In the zone of compression in the specimen retracted for 10 days, the periodontal ligament remained hyalinized, and signs of bone resorption were significant. In the zone of tension, collagen fibers were torn, arranged irregularly, and finer. Small blood vessels increased in number, and newly formed osteiods were observed.

Osteoclasts and the sites of bone resorption were more increased on the compressed side of the tooth retracted for 20 days, and osteoblasts and newly formed osteoids were more progressed on the tension side than in the earlier stages.

In the specimens subjected to force for 5, 7, and 11 weeks, lacunae formed by bone resorption were marked on the compression side. On the tension side, new bone was generated near the stretched periodontal ligament, and previously formed immature bones had matured gradually.

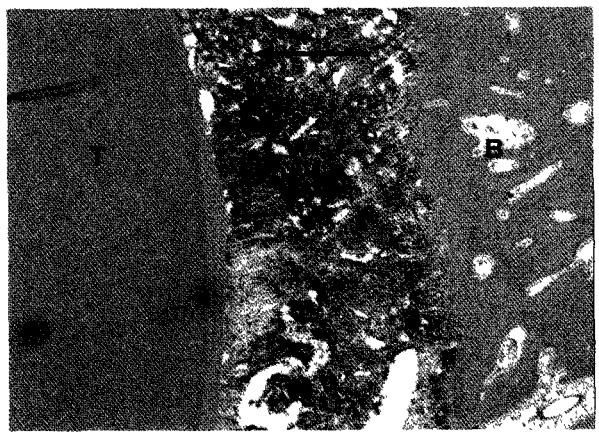

Fig. 4. Distracted periodontal ligament space of the upper first premolar after 5 days of distraction (H-E, ×40). The arrow indicates direction of periodontal distraction. T : tooth, B : alveolar bone.

2) Periodontal distraction

a) Rapid retraction (the upper first premolar)

After 5 days of periodontal distraction, the distance between the upper canine and the first premolar was still greater than that experienced through of conventional methods. The periodontal ligament in this area showed signs of injury such as bleeding infiltration and severe hemorrhage. Collagen fibers were stretched, torn, and detached from the tooth and the alveolar bone. Blood vessels were distended and increased in number. Bone regeneration was not observed (Fig. 4).

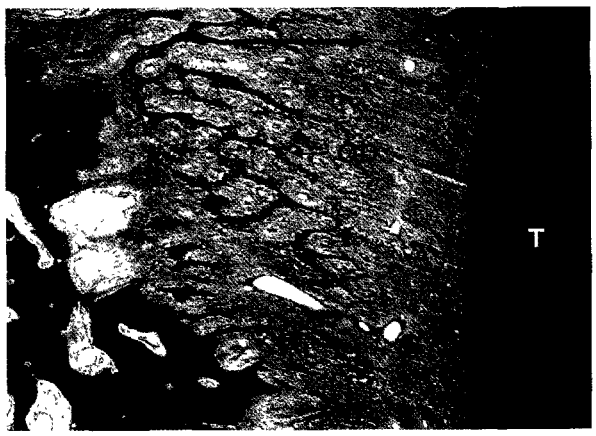

Fig. 5. Distracted periodontal ligament space of the upper first premolar after 10 days of periodontal distraction (Masson's trichrome, ×40). The arrow indicates direction of periodontal distraction. OD : newly formed osteoids.

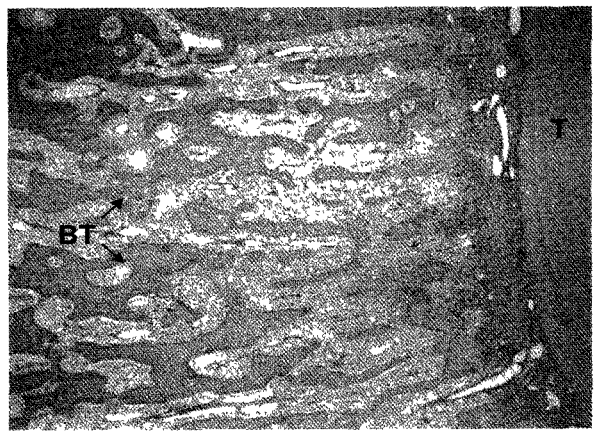

Fig. 6. Distracted periodontal ligament space of the upper first premolar after 20 days of periodontal distraction (H-E, × 40). BT : bone trabeculae.

After 10 days of periodontal ligament distraction, osteoids appeared in the distracted periodontal ligament space. These newly formed osteoids took the form of slender spicules, and were oriented parallel to the direction of the tooth movement, extending from the interseptal bone distal to the canine toward the fibrous zone mesial to the first premolar (Fig. 5). In the distracted periodontal area mesial to the retracted tooth, the width of the periodontal ligament was greater than in the normal periodontal ligament, and blood vessels were abundant. Collagen fibers regenerated, but their orientations were generally irregular.

At the At the conclusion of the periodontal distraction (after 20 days of distraction), new bone formation was more evident, and oriented in the direction of the distraction. These oriented trabeculae showed a woven pattern and were covered by osteoblasts (Fig. 6) . The periodontal ligament space mesial to the retracted tooth was still wide, and the collagen fibers had an irregular pattern.

Two weeks after the completion of rapid retraction, the newly formed trabeculae underwent resorption and remodeling, to convert them into thicker trabeculae (Fig. 7). These trabeculae showed not only osteoblastic bone formation but also osteoclastic resorption on the surface.

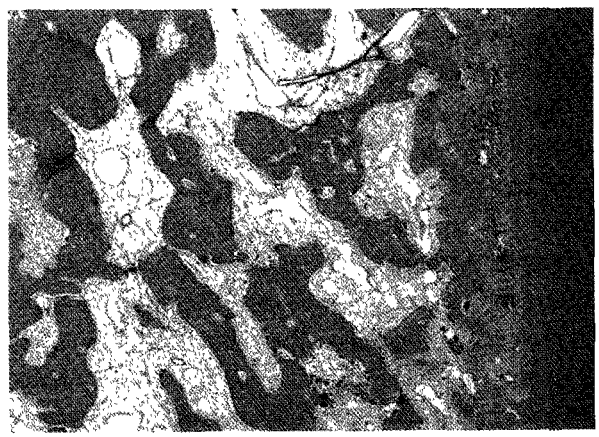

Fig. 7. Distracted periodontal ligament space of the upper first premolar, 2 weeks after completion of periodontal distraction (H-E, ×40).

However, the osteoblastic activity was lower than that recorded in the previous stages, except in the region near the periodontal ligament. Collagen fibers of the periodontal ligament became denser than in the previous stages, and only partially, demonstrated a similar orientation to normal fibers, and a bundled form of collagen fibers had been incorporated into the cementum. However, the insertion of fibers into the newly formed bone was not evident.

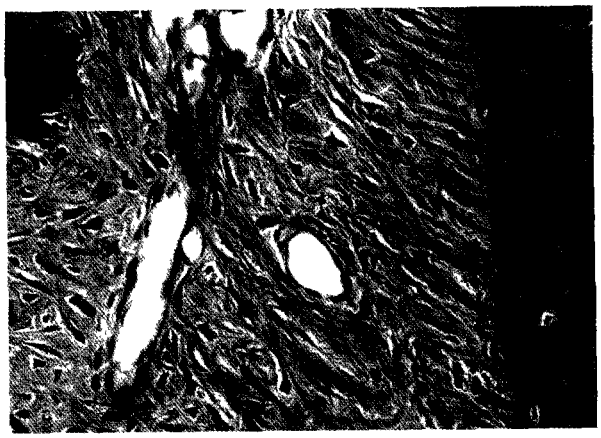

Fig. 8. Distracted periodontal ligament space of the upper first premolar, 4 weeks after completion of distraction (Masson's trichrome, ×400). C : cementum, F : bundle form of collagen fibers.

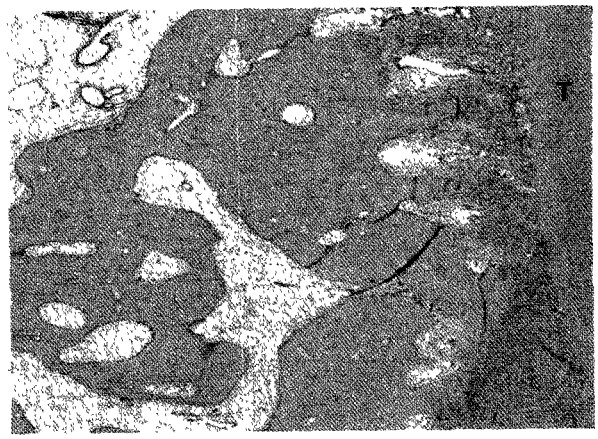

Fig. 9. Distracted periodontal ligament space of the upper first premolar, 8 weeks after completion of distraction (H-E, ×40). T : tooth

Four weeks after the completion of the distraction, bone trabeculae were still noticed in the bone marrow cavity; these had matured through remodeling. The new bones adjacent to the canine had matured more than those close to the distracted tooth. In the fibrous tissue between the first premolar and the trabeculae, osteoblastic bone formation was still in process. On the tooth side, normal features between the cementum and the collagen fiber bundles were seen in the half of the root length (Fig. 8).

Eight weeks following the completion of the rapid retraction, bone trabeculae increased in thickness and demonstrated a decreased longitudinal orientation than previously. The marrow spaces separating trabeculae were much looser and bigger than those recorded in the earlier stages (Fig. 9). On the bony side periodontal space, immature bone was still regenerating, and fiber anchorage to the alveolar bone and bundle forms of collagen fibers were not seen. On the tooth side of the periodontal ligament, bundle forms of collagen fibers were observed along the whole root surface anchored to the cementum.

b) Anchor tooth (the upper third premolar)

The upper third premolar, which served as an anchorage unit for the periodontal distraction revealed the tissue reactions typically manifested in the conventional orthodontic tooth movement.

After five days of periodontal distraction, the mesial sides of the root surface were compressed and the hyalinization of the periodontal ligament was evident. Osteoclasts were observed in the bone marrow, but bone resorption was not obvious. On the distal sides of the root surface, the periodontal ligament spaces had collagen fibers showed evidence of tearing. After ten days of distraction, osteoclasts appeared in the compressed areas and resorption lacunae were observed. In the tension site itself, new bone formation was observed. Finally, at the end of the distraction period (after 20 days of rapid retraction), osteoclastic bone resorption was more active on the compressed side, and new bone formation markedly increased on the tension side. On the completion of the distraction the periodontal ligament of the anchor tooth did not show any specific tissue reaction.

DISCUSSION

It is no exaggeration to say that the history of orthodontics represents a description of the search for

the process to move teeth more efficiently. However, there is no common agreement on how to move teeth most effectively. In terms of orthodontic tooth movement brought about by the bony response mediated by the periodontal ligament, the magnitude of the force applied to the tooth has become the focus of interest. Although the relationship between the amount of force and the rate of tooth movement may be optimized, further increases in the magnitude of the force do not increase the rate of tooth movement.[19-21] A recent experimental study has suggested that the magnitude of the force is not decisive in determining the rate of the bodily movement of a tooth, but that tooth movement is governed by individual characteristics, such as bone density, bone metabolism, and the turnover in the periodontal ligament.[21]

If this is the case, it is possible that reducing the resistance of the bone to tooth migration offers another means of moving the tooth more rapidly. In several animal studies, rapid orthodontic tooth movements were successfully achieved through immature bone newly created by distraction osteogenesis.[22-24] Because the dogs' premolars which were moved in these studies had two roots oriented mesiodistally and an interradicular septal bone in which bone remodeling could should occur rapidly, limitations on the rate of tooth movement were observed.

Therefore, periodontal distraction, a new concept of distracting the periodontal ligament to induce rapid canine retraction in 3 weeks,[17] deserves attention. Although the authors of this above study have discussed only clinically successful cases, their results have not supported the biologic basis of this method. It is important to attempt moving a tooth orthodontically without causing irreversible injuries to tissues, such as the periodontal ligament, alveolar bone, root, pulp or the gingival tissue. Therefore, our study was conducted to evaluate periodontal tissue reactions during and after periodontal distraction.

In this study, the right and left upper first premolars of 4 beagle dogs were distracted using the method presented by Liou and Huang.[17] Only single rooted teeth can be utilized in rapid tooth movement by periodontal distraction. The root of the canine in the dog is so large and curved that bone undermining surgery cannot be performed. On the other hand, the incisors of a dog are small and the interdental spaces are narrow, making them unsuitable for experimentation. Moreover, though the lower first premolar has a single root, the crown is too small to become the object of the force of a distraction appliance. Therefore, the upper first premolar was the only tooth that could be properly used in this experiment. Although beagle dogs are generally accepted as a good model to undertake comparison with human beings,[21] the alveolar bone of dogs is generally denser than in humans,[6] and a further reduction of the interseptal bone is needed to distract the periodontal ligament.

After 20 days of periodontal distraction, the average distance of tooth displacement was 5.02 mm. Four cases distracted for 20 days showed different distal displacement rates. The two cases that moved the lesser distance were on both the left and right sites of one dog. One of the reasons for this result might be explained by a tooth position in which the right and left premolars were rotated buccolingually. In the maxilla of the dog, the shape of the buccal curvature between the canine and the fourth premolar is concave and buccal and palatal cortical plates are quite thin. Moreover, the tooth of the dog is wider mesiodistally than buccolingually. Therefore, the root surface of the rotated upper first premolar is wider than the buccolingual width of the extraction socket of the upper second premolar, and the rate of tooth movement might be limited due to resistance from the cortical plates. Other factors, such as insufficient bone undermining and differences in bone density might also be responsible for the reduced distraction rate.

In this study, the amount of anchorage loss in the periodontal distraction was similar to that in the tooth movement undertaken by conventional orthodontic methods. After the initial movement of the tooth within its socket during the first five days, the discontinuation of tooth movement occurred and was probably associated with hyalinization in the periodontal

ligament.[3,4,21] The force exerted on the anchorage tooth during periodontal distraction disappeared prior to the acceleration phase of tooth movement in which biologic processes involved in the remodeling of the periodontal ligament and alveolar bone reach their maximum capacity,[21] and the anchorage loss was not significant compared with the amount of rapid retraction. However, on histological examination, bone resorption on the compressed side was markedly progressed, so that duration of distraction might be a critical factor of anchorage. The area of Hyalinization in the periodontal ligament of the anchorage tooth appeared more extensive than that in the periodontal ligament of tooth moved by conventional method. This result indicates that the distraction of the periodontal ligament exerts a more heavy force on the tooth than conventional orthodontic methods. This increased hyalinized tissue may reduce the rate of anchorage loss.

The process of bone formation in the wake of periodontal distraction appeared to be similar to osteogenesis during membranous bone lengthening.[25,26] Karp et al.[25] showed four discrete zones of bone formation during mandibular lengthening : the zone of fibrous tissue, the zone of extending bone formation, the zone of bone remodeling, and the zone of mature bone. In the case of distraction osteogenesis, two bone edges are gradually separated in opposite directions, and the zones of new bone formation form a mirror image with a fibrous zone in the center. During the distraction of the periodontal ligament, only the tooth is moved in one direction, and therefore, the tissue reaction did not reflect these symmetrical features. With this as an exception, osteogenesis during periodontal distraction is similar to that which occurs during distraction osteogenesis in the long bone and in the membranous bone. After 5 days of periodontal distraction, the distracted space appeared to be severely damaged. As distraction continued, newly formed bone was longitudinally oriented parallel to the direction of the tooth movement. Early bone formation and its maturation was initiated from the canine side, and extended towards the distracted first premolar.

In this study, new bone formation in the distracted periodontal ligament, the extraction socket and on the tension side of the anchor tooth and the lower second premolar was observed after 10 days of distraction, and was most active in the distracted area. As shown by Roberts and Jee,[27] the end result of the stimulation of the periodontal ligament was bone formation. They suggested that although the stimulated periodontal ligament system had a complex sequence of responses, resulting in the need for cellular activity to repair torn fibers and fill spaces created between the fibers in the ligament, the final response was the formation of new bone along the alveolar border proximal to the tooth.

The newly formed bone underwent extensive remodeling and typically could not be distinguished from the normal adjacent tissues 8 weeks after the completion of distraction, except in the case of newly formed bone near periodontal ligament. Considering the condition of the newly formed osteoids on the periodontal side by 8 weeks after the completion of distraction, it should take more than an additional 8 weeks for the bone in this area to mature. According to Claflin,[28] extraction wound healing was faster in the dogs than in the humans, and a three week old extraction wound in a human was equivalent to an extraction wound nine or ten days old in the dog. Therefore, the healing process after periodontal distraction in human requires significantly more time.

In terms of the healing of the extraction socket, previous studies have showed new bone being laid down on the alveolar bone and its progression towards the center of the socket until the socket is filled.[29,30] However, in this study, one side of the lining wall of the extraction socket was partially removed and the tooth was rapidly moved into the extraction socket, so that bone deposition occurred from the bottom and the distal alveolar wall to the center. New bone formation in the extraction socket did not show the parallel arrangement of the trabeculae with direction of distraction as in the distracted periodontal ligament. This result indicated that the direction of the tensile force exerted an influence upon the direction of bone formation.

The linkage of the teeth to the alveolar bone proper by the periodontal ligament may be both the medium of force transfer and the means by which alveolar bone remodels in response to applied forces. Periodontal fibers form a meshwork that stretches out between the cementum and the bone and is firmly anchored by Sharpey's fibers.[31] In order to adapt to the positional changes of the teeth, the fiber systems in the periodontal ligament must be broken down. Because the collagen in the periodontal ligament appears to form a complex meshwork, the breakdown processes can occur at different sites without compromising tissue integrity. Thus, there is flexibility in the system to permit adaptive changes by breaking down short stretches of collagen fiber bundles or single fibrils while leaving others intact.[31] In this study, specimen obtained after 5 days of periodontal distraction showed that collagen fibers were torn and had almost lost their anchorage to the cementum and the alveolar bone. In a periodontal space widened by distraction, granulation tissue is replaced gradually by fibrous tissue. However, bundle forms of collagen fibers at the cementum and at the alveolar bone remained after 5 days of distraction. After 10 days of distraction, these bundle forms of collagen fibers were not seen. Injury due to the distraction of the periodontal ligament should induce an inflammatory reaction and the degradation of damaged tissue.

In this study, the tissue in the periodontal space during the distraction procedure was fibrous in nature, and did not possess the characteristics of periodontal ligaments, such as bundle formation or Sharpey's fibers. The attachment between the tooth surface and collagen fibers of the periodontal ligament was partially observed 2 weeks after the completion of distraction. 4 weeks after the completion of the distraction, normal features between the cementum and collagen fiber bundles were seen half of the root length. 8 weeks after the completion of the distraction, bundle forms of collagen fibers were observed along the whole root surface. However, the relationship between collagen fibers and the alveolar bone was not fully restored 8 weeks after the completion of distraction. Therefore, it is likely that the rapid tooth movement caused by distracting the periodontal ligament causes collagen fibers of the periodontal ligament to lose anchorage to the tooth and the alveolar bone. Reattachment of collagen fibers to the tooth or the alveolar bone is achieved earlier on the tooth surface than on the bone surface during the maintenance period after rapid retraction has been completed. In addition, it may be assumed that on the alveolar bone side, the reattachment begin to occur after the complete regeneration of bone and the recurrence of a normal range of periodontal ligament space.

The results of this study demonstrated that the periodontal structures on the distracted side of the periodontal ligament were regenerated well histologically in response to rapid tooth movement. However, more extensive studies are needed to investigate the biological aspects such as the responses of the root, pulp, and the surgical sitde, and the biomechanical aspects such as the distraction rate, appliances, and the surgical method, before the routine clinical application of periodontal distraction.

CONCLUSION

Distraction of the periodontal ligament, based on the principles of rapid maxillary expansion and distraction osteogenesis, is a new technique to complete the distal retraction of a canine within 3 weeks. This involves distracting the periodontal ligament after bone undermining surgery to reduce bone resistance. In this study, the upper first premolars of the dog were distracted and the histological changes were evaluated. The regeneration of bone occurred in an organized pattern. Space in the wake of the distracted tooth was filled with newly formed bone oriented toward the direction of the distraction, and this was followed by extensive remodeling. In the periodontal ligament, the relationship between collagen fibers and cementum began to be restored after the distraction was completed, and showed almost normal features 8 weeks after the distraction of the periodontal ligament. On the alveolar

bone side, the formation of new bone was in process and collagen fiber bundles and Sharpey's fibers were not seen 8 weeks after distraction of the periodontal ligament. This evidence supports the hypothesis that it takes a longer time to restore the relationship between collagen fibers and the alveolar bone than that with the on the tooth surface. In conclusion, the results of this study indicate that the periodontal structures on the distracted side of the periodontal ligament histologically well in response to rapid tooth movement.

REFERENCES

1. Reitan K. Some factors determining the evaluation of force in orthodontics Am J Orthod 1957 : 43 32-45.
2. Reitan K. Tissue behavior during orthodontic tooth movement Am J Orthod 1960 : 46 · 881-900
3 Reitan K. Effects of force magnitude and direction of tooth movement on different alveolar bone types. Angle Orthod 1964 : 34 : 244-55
4 Reitan K. Clinical and histological observation on tooth movement during and after orthodontic treatment. Am J Orthod 1967 53 · 721-45
5. Storey E. The nature of tooth movement Am J Orthod 1973 · 63 : 292-314.
6. Reitan K, Kvam E. Comparative behavior of human and animal tissue during experimental tooth movement. Angle Orthod 1971 : 41 · 1-14
7. Azuma M. Study on histologic changes of periodontal membrane incident to experimental tooth movement. Bull Tokyo Med Dent Univ 1970 17 : 149-78.
8 Rygh P. Ultrastructural changes in tension zones of rat molar periodontium incident to orthodontic tooth movement. Am J Orthod 1976 · 70 : 268-81.
9. DeAngelis V. Observations on the response of alveolar bone to orthodontic force. Am J Orthod 1970 : 58 · 284-94.
10. Haas AJ. Rapid expansion of the maxillary dental arch and nasal cavity by opening of the midpalatal suture. Angle Orthod 1961 · 31 : 73-90.
11. Haas AJ Palatal expansion : Just the beginning of dentofacial orthopedics. Am J Orthod 1970 : 57 : 219-55.
12. Deguchi T, Kuroda T, Hunt NP, Graber TM. Long-term application of chincup force alters the morphology of the dolichofacial Class III mandible Am J Orthod Dentofac Orthop 1999 · 116 · 610-15
13. Schudy FF The vertical dimension of the human face. Houston : D. Armstrong Co. 1992
14. Schudy FF. Vertical growth versus anteroposterior growth as related to function and treatment. Angle Orthod 1964 34 · 75-93
15. Ilizarov GA. The tension-stress effect on the genesis and growth of tissue II The influence of the rate and frequency of distraction Clin Orthop 1989 · 239 : 263-285
16. Storey E. Tissue response to the movement of bones Am J Orthod 1973 · 64 · 229-47.
17. Liou EJW, Huang S. Rapid canine retraction through distraction of the periodontal ligament. Am J Orthod Dentofac Orthop 1998 114 : 372-82.
18 Ten Cate AR repair and regeneration of dental tissue. In Ten Cate AR ed. Oral histology-Development, structure, and function. St Louis · CV Mosby, 1994.
19. Boester C, Johnston L. A clinical investigation of the concepts of differential and optimal force in canine retraction Angle Orthod 1974 · 44 · 113-9.
20. Quinn R, Yoshikawa D. A reassessment of force magnitude in orthodontics. Am J Orthod 1985 88 : 252-60.
21. Pilon JJGM, Kuijpers-Jagtman AM, Maltha JC Magnitude of orthodontic forces and rate of bodily tooth movement. An experimental study. Am J Orthod Dentofac Orthop 1996 : 110 · 16-23
22. Liou EJW, Polley JW, Figueroa AA. Distraction osteogenesis · The effects of orthodontic tooth movement on distracted mandibular bone J Craniofac Surg 1998 : 9 : 564-71
23. Cope JB, Harper RP, Samchukov ML Experimental tooth movement through regenerate alveolar bone · A pilot study. Am J Orthod Dentofac Orthop 1999 · 116 501-5
24. Liou EJW, Figueroa AA, Polley JW Rapid orthodontic tooth movement into newly distracted bone after mandibular distraction osteogenesis in a canine model. Am J Orthod Dentofac Orthop 2000 117 : 391-8
25. Karp NS, McCarthy JG, Schreiber JS, Sissons HA, Thorne CH. Membranous bone lengthening A serial histological study Ann Plast Surg 1992 29 : 2-7.
26. Komuro Y, Takato T, Hani K, Yonemara Y. The histologic analysis of distraction osteogenesis of the mandible i rabbits. Plast Reconstr Surg 1994 94 · 152-9.
27. Roberts WE, Jee W. Cell kinetics of orthodontically stimulated and non-stimulated periodontal ligament in the rat. Archs Oral Biol 1974 19 · 17-21.
28. Claflin RS Healing of disturbed and undisturbed extraction wounds JADA 1936 23 945.
29. Amler MH, Johnson PL, Salman I. Histological and histochemical investigation of human alveolar socket healing in undisturbed extraction wounds. J Am Dent Assoc 1960 : 61 ·32-44.
30. Huebash RF, Hansen LS A histopathologic study of extraction wounds in dogs. Oral Surg, Oral Med & Oral Path 1969 · 28 187-96.
31 Beertsin W, Mc Culloch CAG, Sodec J. The periodontal ligament· a unique, multifunctional connective tissue. Periodontology 2000 1997 13 · 20-40

국문초록

치주인대 신장에 의한 치아의 급속 견인 시 성견 치주조직의 변화

장영일, 김태우, 최희영

서울대학교 치과대학 치과교정학 교실

본 연구의 목적은 periodontal distraction을 통해 급속 견인된 치아의 치조골과 치주인대에서 일어나는 변화를 조직학적으로 관찰하고, 치주조직이 정상적으로 재생될 수 있는지를 규명하는 것이다. 4 마리의 성견을 대상으로 하여, 좌우 상악 제2소구치를 발치 후에 상악 제1소구치 원심측 치간골에 홈을 주는 치조골 수술을 통해 골 저항을 약화시키고 제1소구치와 제3소구치에 periodontal distraction 장치를 장착하였다. 장치는 0.225 mm 씩, 하루에 2회 활성화시키며 상악 제1소구치를 발치와 공간으로 급속 견인하였다. 치아의 급속 견인은 5 일, 10 일, 20 일간 시행하였으며, 20 일간 견인한 대상에서는 2 주, 4 주, 8 주 후까지 유지기간을 두었다. 20 일간의 periodontal distraction을 통해 상악 제1소구치는 평균 5.02 mm 원심 이동하였고, 고정원인 제3소구치는 0.58 mm 근심 이동하였다.

조직학적 검사에서 distraction된 치주인대 공간에서는 골 재생과 개조가 빠르게 일어나, 견인 10 일에 유골조직이 치아의 견인방향에 평행하게 생성되었고, 새로운 골 조직의 형성과 골 개조를 통한 골 성숙은 periodontal distraction 방향을 따라 활발히 진행되었으며, 이는 다른 골의 distraction osteogenesis에서 나타나는 결과와 비슷하였다. 급속 견인된 치아의 치주인대는 상당히 넓게 나타났고, 교원섬유와 치아간의 정상 관계는 급속 견인이 끝난 후 2주에 나타나기 시작하여 8주에 거의 회복되었다. 그러나, 치주인대의 골 쪽에서는 치아 급속 견인 후 8주까지도 새로운 골이 계속 형성되고 있었고, 교원섬유속이나 Sharpey 섬유는 보이지 않았다. 고정원으로 이용된 치아 주위의 조직반응은 통상적인 교정치료에서와 같이 압박 측에서의 골 흡수와 신장 측에서의 골 형성 소견을 나타냈다. 이상의 결과로 볼 때, periodontal distraction을 통한 치아의 급속 견인 시, 치주인대 조직은 잘 반응하여 치주조직의 재생이 활발히 일어남을 알 수 있었다.

주요 단어 : 치주인대 신장, 급속 견인, 치조골 수술