[Title page]

Bone formation around zirconia implants combined with rhBMP-2 gel in the canine mandible

Byung-Chul Lee[*1], DDS, MSD, Graduate Student

In-Sung Yeo[*1], DDS, MSD, PhD, Assistant Professor

Dae-Joon Kim[†], Professor

Jai-Bong Lee[*], DDS, MSD, PhD, Professor

Sung-Hun Kim[*], DDS, MSD, PhD, Associate Professor

Jung-Suk Han[*], DDS, MS, PhD, Professor

[*] Department of Prosthodontics, School of Dentistry and Dental Research Institute, Seoul National University, Seoul, Korea

[†] Department of Advanced Materials Engineering, Sejong University, Seoul, Korea

[1] These authors contributed equally to this work.

Correspondence to:

Jung-Suk Han, DDS, MS, PhD

Department of Prosthodontics, School of Dentistry

Seoul National University

Daehakro 101, Jongno-gu

Seoul, 110-749, Korea

Tel: +82-2-2072-2661

Fax: +82-2-2072-3860

E-mail: proshan@snu.ac.kr

Running title: Bone formation at zirconia implants combined with rhBMP-2 gel

Key words: Zirconia implant, alumina toughened zirconia, bone morphogenetic protein-2, canine model, bone response

Abstract

Objective: The aim of this study was to estimate the effects of zirconia implants and recombinant human bone morphogenetic protein-2 (rhBMP-2) gel on the acceleration of local bone formation and osseointegration in the canine mandible.

Materials and Methods: Four groups of 48 implants with identical geometry were installed in the mandibles of beagle dogs: alumina-blasted zirconia implants applied with rhBMP-2, alumina-blasted zirconia implants applied with demineralized bone matrix (DBM), alumina-blasted zirconia implants, and resorbable blast media-treated titanium (Ti) implants. For the first two groups, zirconia implants were inserted after the surgical sites were filled with rhBMP-2 or DBM gel. For the other two groups, zirconia or Ti implants were installed with no adjunctive treatment. Fluorescent bone markers were administered to monitor bone remodeling at weeks 2, 4 and 5 post-implantation. After healing periods of 3 weeks and 6 weeks, the animals were sacrificed and fluorescent microscopy, histology and histomorphometric analyses were performed.

Results: Fluorescent microscopy showed that bone formation around the zirconia implants installed with rhBMP-2 gel was the most prominent at 2 weeks post-implantation ($p < 0.05$), while the Ti implants acquired bone apposition mainly at week 5. No significant differences were found in bone area and bone-to-implant contact among the groups ($p > 0.05$).

Conclusions: The zirconia implants with alumina-blasted surfaces may achieve osseointegration in much the same manner as well-established Ti implants. The area influenced by rhBMP-2 gel, including the alveolar crest, may cause active remodeling and early bone formation.

Introduction

Titanium (Ti) is the current material of choice for dental implants because of its excellent biocompatibility and mechanical properties. However, the dark color of Ti gives rise to aesthetic problems, especially if the soft tissue has a thin biotype or recedes gradually. Apical bone loss and gingival recession expose parts of the metal implant or show a bluish discoloration of the overlying gingiva. Additionally, allergic reactions, sensitivities and corrosion products of Ti have been reported (Lalor et al. 1991; Schliephake et al. 1993; Urban et al. 2000; Valentine-Thon & Schiwara 2003). A possible solution to this situation would be to use tooth-colored material for dental implants, such as zirconia.

Zirconia ceramics may be a good alternative material to Ti for dental implants. Zirconia has suitable characteristics for dental implants, such as a high bending strength (~1200MPa), minimal thermal conductivity, a high elastic modulus (~200GPa), excellent biocompatibility, less bacterial adhesion, a tooth-like color, and no mechanical problems in the implant loading condition (Akagawa et al. 1998; Akagawa et al. 1993; Andreiotelli & Kohal 2009; Andreiotelli et al. 2009; Kohal et al. 2004). Several *in vivo* studies conducted in animal models have shown that zirconia implants can achieve osseointegration like well-known Ti implants (Depprich et al. 2008; Dubruille et al. 1999; Gahlert et al. 2007; Koch et al. 2010; Langhoff et al. 2008; Lee et al. 2009; Rocchietta et al. 2009; Sennerby et al. 2005; Shin et al. 2011). Continued studies have focused their attention on surface modifications to increase the BIC ratio and to accelerate osseointegration, which would make it possible for earlier function of the implants (Depprich et al. 2008; Gahlert et al. 2007; Langhoff et al. 2008; Lee et al. 2009; Rocchietta et al. 2009; Sennerby et al. 2005). Surface roughness is considered one of the factors that cause zirconia implants to induce stronger and faster bone responses. Zirconia implants with a rough surface have been shown to be superior to those with a machined surface both in resistance to torque forces and in histomorphometry (Depprich et al. 2008; Gahlert et al. 2007; Langhoff et al. 2008; Lee et al. 2009; Sennerby et al. 2005).

The factor of bioactive materials, like bone morphogenetic proteins (BMPs), would be useful to

accelerate the osseointegration of rough-surfaced zirconia implants. The BMPs, originally identified by their presence in extracts of demineralized bone, originate from the TGF- family and include at least 18 different proteins (Urist 1965). As BMP-2 possesses a high osteoinductive potential, it is considered to promote local bone formation and osseointegration without the additional use of bone grafts or other biomaterials for regeneration of the alveolar bone. Many studies have reported that applying BMPs onto Ti implant surfaces (either by coating BMP-2 onto the Ti implant surface or by the direct application on alveolar bone defects with absorbable collagen sponges or various carriers) may enhance osseointegration and local bone remodeling (Becker et al. 2006; Bessho et al. 1999; Koide et al. 1999; Leknes et al. 2008; Liu et al. 2007; Matin et al. 2003; Salata et al. 2007; Schliephake et al. 2005; Sykaras et al. 2004; Sykaras et al. 2001; Wikesjo et al. 2008). However, little data regarding the bone response to the BMP-2 applied surface of a zirconia implant exist.

The purpose of this study was to evaluate the effect of the zirconia (alumina-toughened zirconia) implant and recombinant human BMP-2 (rhBMP-2) gel on the acceleration of local bone formation and osseointegration in the canine mandible. The null hypothesis was that the zirconia implant with rhBMP-2 gel would have no different effect on the surrounding bone response compared with the zirconia or Ti implants without the application of rhBMP-2.

Materials and Methods

Preparation of the specimens

Experimental Ti implants (grade 4) and zirconia (alumina-toughened yttria and niobia co-doped tetragonal zirconia polycrystalline, Al_2O_3/Y(Nb)-TZP) implants were custom-made to the same dimensions with a diameter of 3.3 mm and a length of 8 mm. The Ti implants were pre-treated with resorbable blast media (RBM; calcium phosphate ceramic), and the alumina-toughened zirconia (ATZ) implants were sandblasted with 50 µm Al_2O_3 at 3 bar for 1 minute to make a rough surface. To handle the implants during installation, every implant had a head of 1.5 mm (Fig. 1). We measured the surface topography quantitatively by confocal laser scanning micrography (LSM 5 Pascal, Zeiss,

Obercochen, Germany). Surface roughness of three implants from each group was determined (Table 1).

***In vivo* surgery**

Six healthy beagle dogs, weighing 10 - 15 kg each, were used in this study. This experiment was approved by the Institutional Animal Care and Use Committee, School of Dentistry, Seoul National University (approval number: SNU-090502-2) and all experiments were done in accordance with the Institute of Laboratory Animal Resources guidelines of Seoul National University.

All surgical procedures were performed aseptically under general anesthesia accomplished by sedation with 2% xylazine hydrochloride (Rumpen®, Bayer Korea, Seoul, Korea) and ketamine hydrochloride (Ketalar, Yuhan, Seoul, Korea). Local anesthesia was performed with 2% lidocaine containing epinephrine (1:100,000) (Lignospan, Septodont, Cedex, France) at the surgical sites.

All premolars and first molars of the mandible were surgically extracted non-invasively. After a healing period of 12 weeks, Ti and ATZ implants were installed into the healed alveolar ridge of the mandible. A mid-crestal incision from the distal surface of the canine to the mesial surface of the second molar was made to reflect buccal and lingual mucoperiosteal flaps. The preparation of the bone took place under copious irrigation with sterile physiologic saline using standard, commercially available drills for all implant types. Osteotomy sites were prepared to a final diameter of 3.0 mm. Following bone preparation for the implants, the surgical site was filled with rhBMP-2 gel, demineralized bone matrix (DBM) gel, or no gel at all, then the ATZ implants were installed. The ATZ implants installed with rhBMP-2 gel were denoted as ATZ-B, those with DBM gel were denoted as ATZ-D, and the ATZ implants only inserted without any gel were denoted as ATZ-N. The rhBMP-2 gel (Rafugen™ BMP-2 gel, Korea Bone Bank, Seoul, Korea) was a mixture of rhBMP-2 and DBM. For elimination of the effect of DBM, zirconia implants with DBM gel (Rafugen™ DBM gel, Korea Bone Bank, Seoul, Korea) without rhBMP-2 were assigned to another group in this study. The constituents of rhBMP-2 and DBM gels are shown in Table 2. The Ti implants were also placed with

no adjunctive treatment for control.

The investigated implants were assigned randomly to canine mandibles. Following installation of the implants of each group, the gingiva was sutured over the submerged implants. After surgery, appropriate antibiotics and analgesics were administered. Seven days after surgery, the sutures were removed.

Evaluation of bone remodeling and osseointegration

To evaluate the rate and extent of bone remodeling, fluorescent bone markers were administered at a chosen week. For three animals sacrificed at week 6, oxytetracycline hydrochloride (Merck, Amsterdam, The Netherlands; 20 mg/kg SQ) was administered at week 2 after implant installation, xylenol orange (Sigma, Zwijdrecht, The Netherlands; 90mg/kg SQ) at week 4, and calcein blue (Sigma, Zwijdrecht, The Netherlands; 90 mg/kg SQ) at week 5 to research bone remodeling at each week. Another three animals that were sacrificed at week 3 had received only oxytetracycline hydrochloride at week 2.

After a healing period of 3 and 6 weeks, each the three dogs were anesthetized and sacrificed. Block sections including implants and adjacent alveolar bone were collected and immediately fixed in 4% neutral formaldehyde. The mandibular bone was then separated using a diamond-coated saw into segments that contained one implant each. The specimens were embedded in light-curing resin (Technovit 7200 VLC, Kultzer, Wehrheim, Germany). The embedded sections were prepared using cutting-grinding technique (EXAKT Apparatebau, Norderstedt, Germany) and were ground and polished to a thickness of approximately 50 µm for fluorescence microscopy examination.

To monitor bone remodeling, the specimens acquired were examined using confocal microscopy equipment (Fluoview 300 Confocal Laser Scanning Microscope, Olympus, Tokyo, Japan). After examination with fluorescence microscopy, the specimens were stained with hematoxylin and eosin (HE-staining).

The histological and histomorphometric examinations were performed with an Olympus BX microscope (Olympus Optical, Osaka, Japan) connected to an IBM personal computer. After

microscopic examination, a photograph of each slide was taken using a digital camera (Olympus Optical, Osaka, Japan), and the resulting images were used for histomorphometric analysis. Using an automated image analysis system (Tomoro Scope Eye 3.6 Image Analyser, Techsan Digital Imaging, Seoul, Korea), we measured each tissue component.

For histomorphometric analysis, the following measurements were analyzed on the buccal and lingual surfaces for each implant:

1. **Bone area (BA)**: Ratio of mineralized bone to fibrovascular tissue and marrow within the three most coronal threads of the implant surface from the bone cortex.
2. **Bone-to-implant contact (BIC):** Ratio of bone-implant contact along the three consecutive threads of the implant surface from the bone cortex.

Statistical analysis

A statistical software package (SPSS ver. 12.0 for Windows, Chicago, IL, USA) was used for the statistical analysis. The mean ± standard deviation values of the BIC and BA of the all groups at week 3 and week 6 were calculated, and the Mann-Whitney U Test was used to ascertain statistical differences between the ATZ-N and the Ti implants, and also between the ATZ-B and the ATZ-D groups. A difference was considered statistically significant if $p < 0.05$.

Results

Histology

All animals survived the surgical procedures, and all 48 implants healed uneventfully. None of the implants were lost during the healing period. One implant showed a premature exposure after three weeks of implantation.

For all experimental groups, gross examination of the light microscopic sections showed bone formation and integration of implants with surrounding bone. The ingrowth of bone from the surrounding bone was observed to osseointegrate. Islets of mineralized bone were often seen in

intimate contact with the surface layer.

After a 3-week healing period, the specimens exhibited a clear borderline between the existing cortical bone and the new bone growing in between the threads. In addition, distinct gaps between the implant surfaces and the bone were observed, and matrix-like tissue had filled in the gaps.

The existing cortical bone clearly showed a compact, lamellar appearance with the presence of osteons, while the newly formed bone appeared to be less organized and less lamellar and instead was more consistent with woven bone. In the groups using DBM with or without rhBMP-2, a demineralized bone matrix was shown in the distinct gap between the implants threads and the existing alveolar bone (Fig. 2).

After 6 weeks of healing, the specimens from all groups showed tighter contact to the surrounding alveolar bone than the specimens that were only allowed to heal for 3 weeks. Newly formed bone had matured to adopt a lamellar structure in direct contact to the implant surfaces adjacent to the zirconia implants of all groups, as well as in the Ti implants. The demarcation between existing bone and newly formed bone was not clearly observable. Unresolved demineralized bone matrices of ATZ-D and ATZ-B groups at week 3 were hardly present at week 6 (Fig. 3).

Fluorescent microscopy

In the specimens allowed to heal for 6 weeks post implantation, remodeled bone was observed within and outside the thread area of implants of all experimental groups. Fluorescent bone markers indicated bone remodeling at distinct time periods by yellow (oxytetracycline, week 2), red (xylenol orange, week 4) and blue (calcein blue, week 5). Apparent bone formation around the ATZ-B implants was observed after 2 weeks by abundant yellow markers (week 2, oxytetracycline yellow), while little bone formation at week 5 was observed (narrow calcein blue markers). The Ti implants had acquired bone apposition mainly during week 4 (red marker, xylenol orange) rather than week 2. The newly formed bone exhibited high density. The recently formed bone accumulated outside the earlier remodeled bone and had direct contact with the implant threads (Fig. 4).

Also, in the specimens that were allowed to heal for 3 weeks post implantation, the ATZ-B implants

showed more bone remodeling immediately outside of the implants (wide yellow marker) than did the ATZ-D implants. In particular, the alveolar crest and upper third of the ATZ implants, where the rhBMP-2 gel was mainly applied, showed abundant bone formation during week 2 post-implantation (Fig. 5).

Histomorphometry

Results of the histomorphometric analysis are shown in Table 3. After a 3-week healing period, ATZ-B group exhibited a mean BIC of 0.28 ± 0.10, which was not significantly different than the ATZ-D group (0.35 ± 0.15). In a comparison between Ti and ATZ-N groups, ATZ-N implants, although not statistically significant, showed more bone contact than Ti implants (p = 0.149). The mean bone area of the ATZ-B and ATZ-D groups was not significantly different. The ATZ-N group had a mean BA of 0.35 ± 0.06, again exhibiting no significant difference from the Ti group (0.30 ± 0.13).

In all experimental groups, both the BIC and BA increased as the healing period increased from 3 weeks to 6 weeks. No significant differences in BIC were found between the ATZ-B and ATZ-D implants. The ATZ-N and Ti implants also showed no significant differences in BIC. There were no significant differences in BA between either ATZ-N and Ti implants or ATZ-B and ATZ-D implants.

Discussion

The fluorescence microscopic results of this study indicated that there was an enormous amount of bone formation immediately outside of the implant threads and on the alveolar crestal bone where the rhBMP-2 gel was mainly applied at the early stage of healing. Therefore, in a clinical situation with an alveolar defect in need of additional bone grafts, if rhBMP-2/DBM gel was applied, retained and released appropriately in the defect, earlier formation and remodeling of the bone immediately outside the implants could be achievable, and the newly formed bone would be osseointegrated to the esthetic zirconia implant surface. Zirconia implants may be more suitable in the restoration of anterior teeth in spite of some case reports that used zirconia implants in the posterior region (Pirker et al. 2011). In

situations with missing anterior teeth, earlier restoration is very important. The prerequisite for early loading of implants is the maintenance of stability achieved by early bone formation. Application of rhBMP-2 onto the implant surface can play an important role in accelerating and enhancing new bone formation as well as modification of the implant surface.

This study tried to minimize the effect of surface roughness factors in the investigated implants. To date, surface roughness is known to be important for osseointegration of zirconia implants as is the case with the well-documented Ti implants (Depprich et al. 2008; Gahlert et al. 2007; Langhoff et al. 2008; Lee et al. 2009; Sennerby et al. 2005). This study used the ATZ implants whose surface was sandblasted with Al_2O_3 to render it moderately rough (R_a=1.76 ± 0.33μm), similarly to the Ti implants (R_a =1.64 ± 0.33μm).

Focusing on early bone formation induced by rhBMP-2 in healed socket, this research was performed without any intentional osseous defects, and as such, there was no space for carriers like absorbable collagen sponge containing rhBMP-2. The rhBMP-2 gel was used onto the cervical area of the prepared alveolar bone for applying rhBMP-2 to the alveolar bone around the implants in this study. Coating rhBMP-2 onto the implant surfaces instead of the gel application is another option and has been previously studied, but this technique requires additional sensitive procedures consisting of preparation of rhBMP-2 solution with an experimental concentration, incubation of the implants in rhBMP-2 solution, and air-dry for several hours before implant installation (Schliephake et al. 2005; Wikesjo et al. 2008).

The ATZ implants without rhBMP or DBM showed comparable osseointegration with the Ti implants. These results were in accordance with earlier reports that used rough-surfaced zirconia implants (Depprich et al. 2008; Lee et al. 2009). In the evaluation of rhBMP-2, the ATZ implants with rhBMP-2 gel showed no apparent differences of BIC or BA compared to implants without rhBMP-2. There are several possible explanations for these results.

The first is the absence of the defects around the implants. In the studies that reported an excellent ability of rhBMP-2 to accelerate osseointegration, this growth factor was applied to the bone with an

intentionally prepared defect, and the bone formation induced by rhBMP-2 was more prominent (Leknes et al. 2008; Matin et al. 2003; Sykaras et al. 2001). However, this study was performed in rather dense bone without any intentional defect, so the osteoinductive ability of rhBMP-2 may not have been as apparent as in other studies that included defect models. The results of some studies were similar to those of this study (Schliephake et al. 2005; Wikesjo et al. 2008). Although rhBMP-2 adsorbed onto Ti implant surfaces showed accelerated peri-implant bone remodeling, the BIC of these implants was lower than that of the Ti surfaces without the adsorbed rhBMP-2 (Wikesjo et al. 2008). This previous study also suggested that the absence of an osseous defect might be a contributing factor (Wikesjo et al. 2008). Another investigation, where the implants with rhBMP-2 did not show enhanced osseointegration in an osseous defect model, proposed that the size of osseous defects in that experimental model was rather small for testing the osteoinductive ability of rhBMP-2 (Salata et al. 2007).

Secondly, the concentration and the delivery mode of the rhBMP-2 seemed to influence the rate of bone formation. A previous study reported that the addition of rhBMP-2 by coating had not been shown to increase peri-implant bone formation in the dog model without any osseous defect (Schliephake et al. 2005). The concentration of rhBMP-2 solution used for coating was suggested to be too low to elecit prominent bone formation. On the contrary, rhBMP-2 immobilized by covalent and non-covalent methods on an acid-treated implant surface was reported to promote direct bone apposition in a concentration dependent manner even under the low concentrations of rhBMP-2 (Becker et al. 2006). In the present study, the concentration of the rhBMP-2 gel was 50 μg/ml and the amount of rhBMP-2 at the surgical site was theoretically 2.83 μg, which was larger than that of the previous investigations. Because this experiment was performed without any intentional defect, there was insufficient space for carrying the rhBMP-2 gel. The rhBMP-2 might have been unstably contained and subsequently released in a burst rather than slowly released. Therefore, this variable could have had an effect on the area of the alveolar bone and subsequently the local concentration of rhBMP-2, which influenced the efficacy of bone formation. Liu et al. reported that the osteoconductivity of implant surfaces can be significantly modulated by rhBMP-2 and its mode of

delivery (Liu et al. 2007). Implant osteoinductivity was less effective when rhBMP-2 was present as a burst-release profile, while rhBMP-2 seemed to execute its influence via slow-release systems, such as when incorporated into surface-treated implants. The application modes of rhBMP-2 would influence the released concentration of rhBMP-2 to peri-implant tissues. Depending on the dose, rhBMP-2 might attract various cell types such as the osteoclast (Koide et al. 1999; Reddi & Cunningham 1993; Sykaras et al. 2004).

Though the gel system provides a simple method to apply rhBMP-2 to the bone and needs no additional procedure like coating, it was difficult to retain and release rhBMP-2 to an adequate target area, especially when there is inadequate contained space for the rhBMP-2 gel. In conditions without any defect where accelerated osseointegration of the zirconia implants is needed (such as replacement of anterior teeth), rhBMP-2 that is firmly attached to the zirconia implants and slowly released will likely be more appropriate than the rhBMP-2 gel system used in this investigation. Further studies are required to determine if the rhBMP-2 gel system would be useful in defect models, and if zirconia implants with firmly attached rhBMP-2 could accomplish accelerated osseointegration and osteoinduction.

In conclusion, the rhBMP-2 gel application to the site where the implant is placed may help the prepared bone to heal quickly and the inserted implant to osseointegrate by active bone formation and remodeling. The data also indicates that the ATZ implants may show similar bone response to the Ti implants when both the implants have comparable surface roughness.

Acknowledgement

This research was supported by Basic Science Research Program through the National Research Foundation of Korea (NRF) funded by the Ministry of Education, Science and Technology (2011-0024170 & R01-2007-000-10977-0).

References

Akagawa, Y., Hosokawa, R., Sato, Y. & Kamayama, K. (1998) Comparison between freestanding and tooth-connected partially stabilized zirconia implants after two years' function in monkeys: A clinical and histologic study. *Journal of Prosthetic Dentistry* **80**: 551-558.

Akagawa, Y., Ichikawa, Y., Nikai, H. & Tsuru, H. (1993) Interface histology of unloaded and early loaded partially stabilized zirconia endosseous implant in initial bone healing. *Journal of Prosthetic Dentistry* **69**: 599-604.

Andreiotelli, M. & Kohal, R. J. (2009) Fracture strength of zirconia implants after artificial aging. *Clinical Implant Dentistry and Related Research* **11**: 158-166.

Andreiotelli, M., Wenz, H. J. & Kohal, R. J. (2009) Are ceramic implants a viable alternative to titanium implants? A systematic literature review. *Clinical Oral Implants Research* **20 Suppl 4**: 32-47.

Becker, J., Kirsch, A., Schwarz, F., Chatzinikolaidou, M., Rothamel, D., Lekovic, V., Laub, M. & Jennissen, H. P. (2006) Bone apposition to titanium implants biocoated with recombinant human bone morphogenetic protein-2 (rhbmp-2). A pilot study in dogs. *Clinical Oral Investigations* **10**: 217-224.

Bessho, K., Carnes, D. L., Cavin, R., Chen, H. Y. & Ong, J. L. (1999) Bmp stimulation of bone response adjacent to titanium implants in vivo. *Clinical Oral Implants Research* **10**: 212-218.

Depprich, R., Zipprich, H., Ommerborn, M., Naujoks, C., Wiesmann, H. P., Kiattavorncharoen, S., Lauer, H. C., Meyer, U., Kubler, N. R. & Handschel, J. (2008) Osseointegration of zirconia implants compared with titanium: An in vivo study. *Head & Face Medicine* **4**: 30.

Dubruille, J. H., Viguier, E., Le Naour, G., Dubruille, M. T., Auriol, M. & Le Charpentier, Y. (1999) Evaluation of combinations of titanium, zirconia, and alumina implants with 2 bone fillers in the dog. *International Journal of Oral and Maxillofacial Implants* **14**: 271-277.

Gahlert, M., Gudehus, T., Eichhorn, S., Steinhauser, E., Kniha, H. & Erhardt, W. (2007) Biomechanical and histomorphometric comparison between zirconia implants with varying surface textures and a titanium implant in the maxilla of miniature pigs. *Clinical Oral Implants Research* **18**: 662-668.

Koch, F. P., Weng, D., Kramer, S., Biesterfeld, S., Jahn-Eimermacher, A. & Wagner, W. (2010)

Osseointegration of one-piece zirconia implants compared with a titanium implant of identical design: A histomorphometric study in the dog. *Clinical Oral Implants Research* **21**: 350-356.

Kohal, R. J., Weng, D., Bachle, M. & Strub, J. R. (2004) Loaded custom-made zirconia and titanium implants show similar osseointegration: An animal experiment. *Journal of Periodontology* **75**: 1262-1268.

Koide, M., Murase, Y., Yamato, K., Noguchi, T., Okahashi, N. & Nishihara, T. (1999) Bone morphogenetic protein-2 enhances osteoclast formation mediated by interleukin-1alpha through upregulation of osteoclast differentiation factor and cyclooxygenase-2. *Biochemical and Biophysical Research Communications* **259**: 97-102.

Lalor, P. A., Revell, P. A., Gray, A. B., Wright, S., Railton, G. T. & Freeman, M. A. (1991) Sensitivity to titanium. A cause of implant failure? *Journal of Bone and Joint Surgery. British Volume* **73**: 25-28.

Langhoff, J. D., Voelter, K., Scharnweber, D., Schnabelrauch, M., Schlottig, F., Hefti, T., Kalchofner, K., Nuss, K. & von Rechenberg, B. (2008) Comparison of chemically and pharmaceutically modified titanium and zirconia implant surfaces in dentistry: A study in sheep. *International Journal of Oral and Maxillofacial Surgery* **37**: 1125-1132.

Lee, J., Sieweke, J. H., Rodriguez, N. A., Schupbach, P., Lindstrom, H., Susin, C. & Wikesjo, U. M. (2009) Evaluation of nano-technology-modified zirconia oral implants: A study in rabbits. *Journal of Clinical Periodontology* **36**: 610-617.

Leknes, K. N., Yang, J., Qahash, M., Polimeni, G., Susin, C. & Wikesjo, U. M. (2008) Alveolar ridge augmentation using implants coated with recombinant human bone morphogenetic protein-2: Radiographic observations. *Clinical Oral Implants Research* **19**: 1027-1033.

Liu, Y., Enggist, L., Kuffer, A. F., Buser, D. & Hunziker, E. B. (2007) The influence of bmp-2 and its mode of delivery on the osteoconductivity of implant surfaces during the early phase of osseointegration. *Biomaterials* **28**: 2677-2686.

Matin, K., Senpuku, H., Hanada, N., Ozawa, H. & Ejiri, S. (2003) Bone regeneration by recombinant human bone morphogenetic protein-2 around immediate implants: A pilot study in rats. *International Journal of Oral and Maxillofacial Implants* **18**: 211-217.

Pirker, W., Wiedemann, D., Lidauer, A. & Kocher, A. A. (2011) Immediate, single stage, truly anatomic zirconia implant in lower molar replacement: A case report with 2.5 years follow-up. *International Journal of Oral and Maxillofacial Surgery* **40**: 212-216.

Reddi, A. H. & Cunningham, N. S. (1993) Initiation and promotion of bone differentiation by bone morphogenetic proteins. *Journal of Bone and Mineral Research* **8 Suppl 2**: S499-502.

Rocchietta, I., Fontana, F., Addis, A., Schupbach, P. & Simion, M. (2009) Surface-modified zirconia implants: Tissue response in rabbits. *Clinical Oral Implants Research* **20**: 844-850.

Salata, L. A., Burgos, P. M., Rasmusson, L., Novaes, A. B., Papalexiou, V., Dahlin, C. & Sennerby, L. (2007) Osseointegration of oxidized and turned implants in circumferential bone defects with and without adjunctive therapies: An experimental study on bmp-2 and autogenous bone graft in the dog mandible. *International Journal of Oral and Maxillofacial Surgery* **36**: 62-71.

Schliephake, H., Aref, A., Scharnweber, D., Bierbaum, S., Roessler, S. & Sewing, A. (2005) Effect of immobilized bone morphogenic protein 2 coating of titanium implants on peri-implant bone formation. *Clinical Oral Implants Research* **16**: 563-569.

Schliephake, H., Reiss, G., Urban, R., Neukam, F. W. & Guckel, S. (1993) Metal release from titanium fixtures during placement in the mandible: An experimental study. *International Journal of Oral and Maxillofacial Implants* **8**: 502-511.

Sennerby, L., Dasmah, A., Larsson, B. & Iverhed, M. (2005) Bone tissue responses to surface-modified zirconia implants: A histomorphometric and removal torque study in the rabbit. *Clinical Implant Dentistry and Related Research* **7 Suppl 1**: S13-20.

Shin, D., Blanchard, S. B., Ito, M. & Chu, T. M. (2011) Peripheral quantitative computer tomographic, histomorphometric, and removal torque analyses of two different non-coated implants in a rabbit model. *Clinical Oral Implants Research* **22**: 242-250.

Sykaras, N., Iacopino, A. M., Triplett, R. G. & Marker, V. A. (2004) Effect of recombinant human bone morphogenetic protein-2 on the osseointegration of dental implants: A biomechanics study. *Clinical Oral Investigations* **8**: 196-205.

Sykaras, N., Triplett, R. G., Nunn, M. E., Iacopino, A. M. & Opperman, L. A. (2001) Effect of

recombinant human bone morphogenetic protein-2 on bone regeneration and osseointegration of dental implants. *Clinical Oral Implants Research* **12**: 339-349.

Urban, R. M., Jacobs, J. J., Tomlinson, M. J., Gavrilovic, J., Black, J. & Peoc'h, M. (2000) Dissemination of wear particles to the liver, spleen, and abdominal lymph nodes of patients with hip or knee replacement. *Journal of Bone and Joint Surgery* **82**: 457-476.

Urist, M. R. (1965) Bone: Formation by autoinduction. *Science* **150**: 893-899.

Valentine-Thon, E. & Schiwara, H. W. (2003) Validity of melisa for metal sensitivity testing. *Neuro Endocrinology Letters* **24**: 57-64.

Wikesjo, U. M., Xiropaidis, A. V., Qahash, M., Lim, W. H., Sorensen, R. G., Rohrer, M. D., Wozney, J. M. & Hall, J. (2008) Bone formation at recombinant human bone morphogenetic protein-2-coated titanium implants in the posterior mandible (type ii bone) in dogs. *Journal of Clinical Periodontology* **35**: 985-991.



Fig. 1. (a) The Ti and ATZ implants used in this study are shown. Note that they are equal in dimension. The SEM images (×1000) of the Ti (b) and ATZ implants (c) similarly display the characteristic irregularities of blasted surfaces. Both the blasted surfaces were comparable in surface roughness.
158x40mm (300 x 300 DPI)

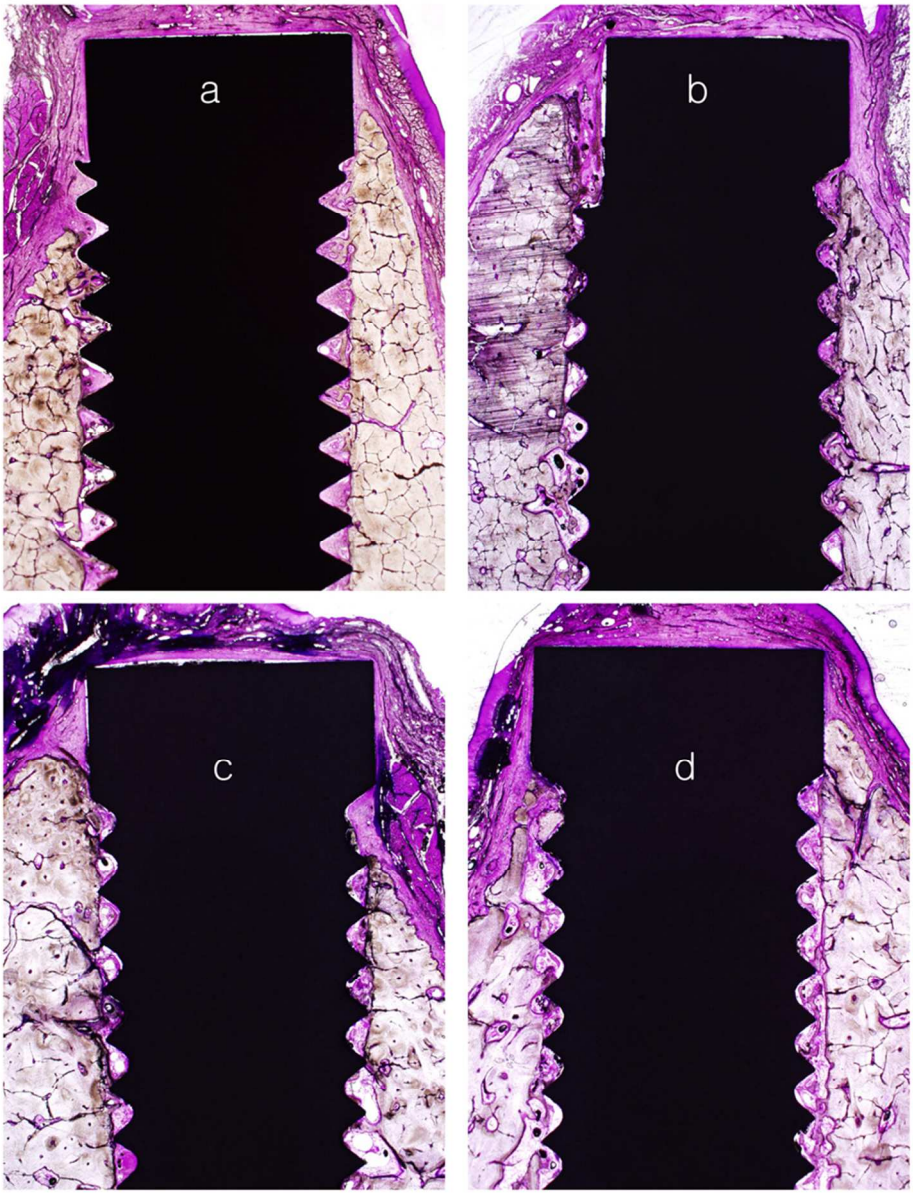

Fig. 2. Histologic images of a (a) Ti implant without any adjunctive treatment, (b) ATZ-N implant, (c) ATZ-D implant, and (d) ATZ-B implant at 3 weeks after implant insertion (×20). All the specimens of each group exhibited a clear borderline between the existing cortical bone and the new bone growing in between the threads.
76x98mm (300 x 300 DPI)



Fig. 3. Histologic images of a (a) Ti implant without any adjunctive treatment, (b) ATZ-N implant, (c) ATZ-D implant, and (d) ATZ-B implant at 6 weeks after implant insertion (×20). The specimens from all groups showed more bone formation within the threads than those of week 3 and newly formed bone had a mature structure in direct contact to the implant surfaces.
74x97mm (300 x 300 DPI)

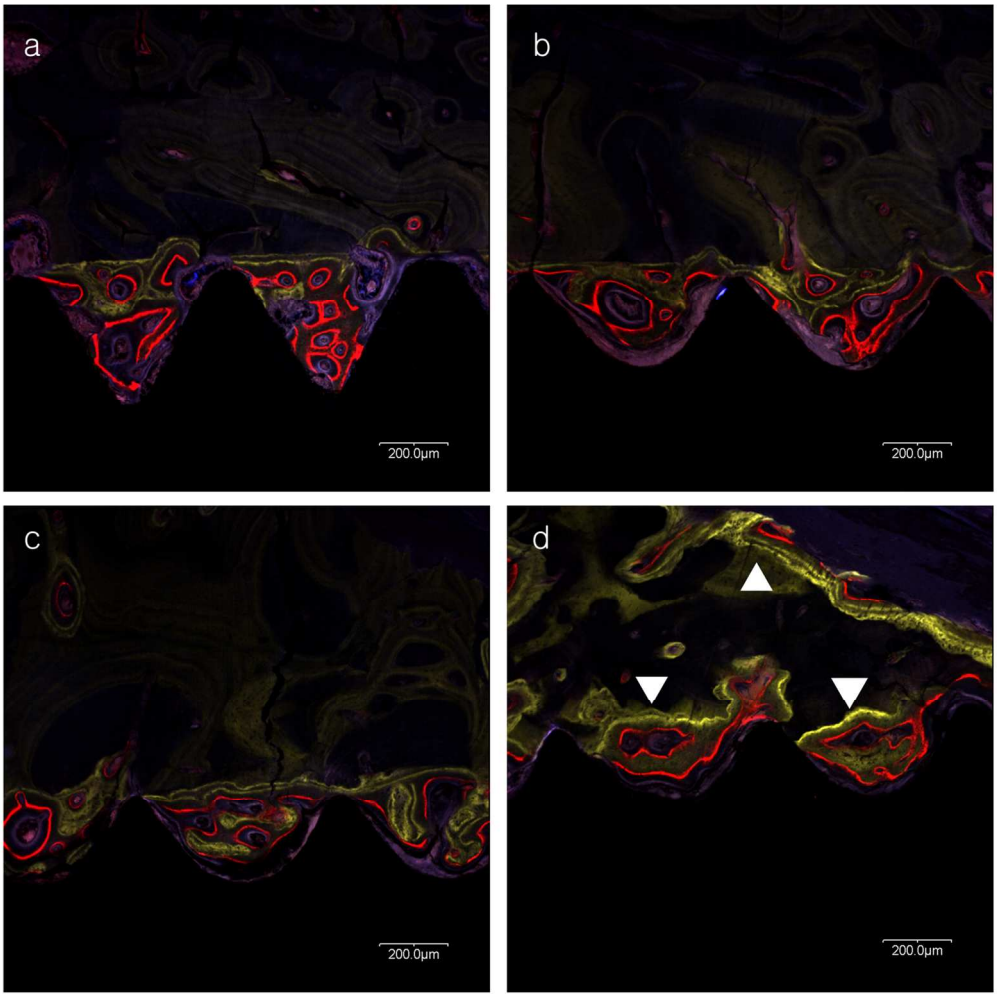

Fig. 4. Fluorescent microscopic images of a (a) Ti implant without any adjunctive treatment, (b) ATZ-N implant, (c) ATZ-D implant, and (d) ATZ-B implant at 6 weeks after implant insertion. Oxytetracycline hydrochloride (yellow marker) administered at week 2, xylenol orange (red marker) at week 4, and calcein blue (blue marker) at week 5 showed bone remodelling at each week. Apparent bone formation around the alveolar crest of the ATZ-B implant was observed after 2 weeks by abundant yellow marker (arrows). The ATZ-D implants showed bone formation mainly within the threads.
135x135mm (300 x 300 DPI)

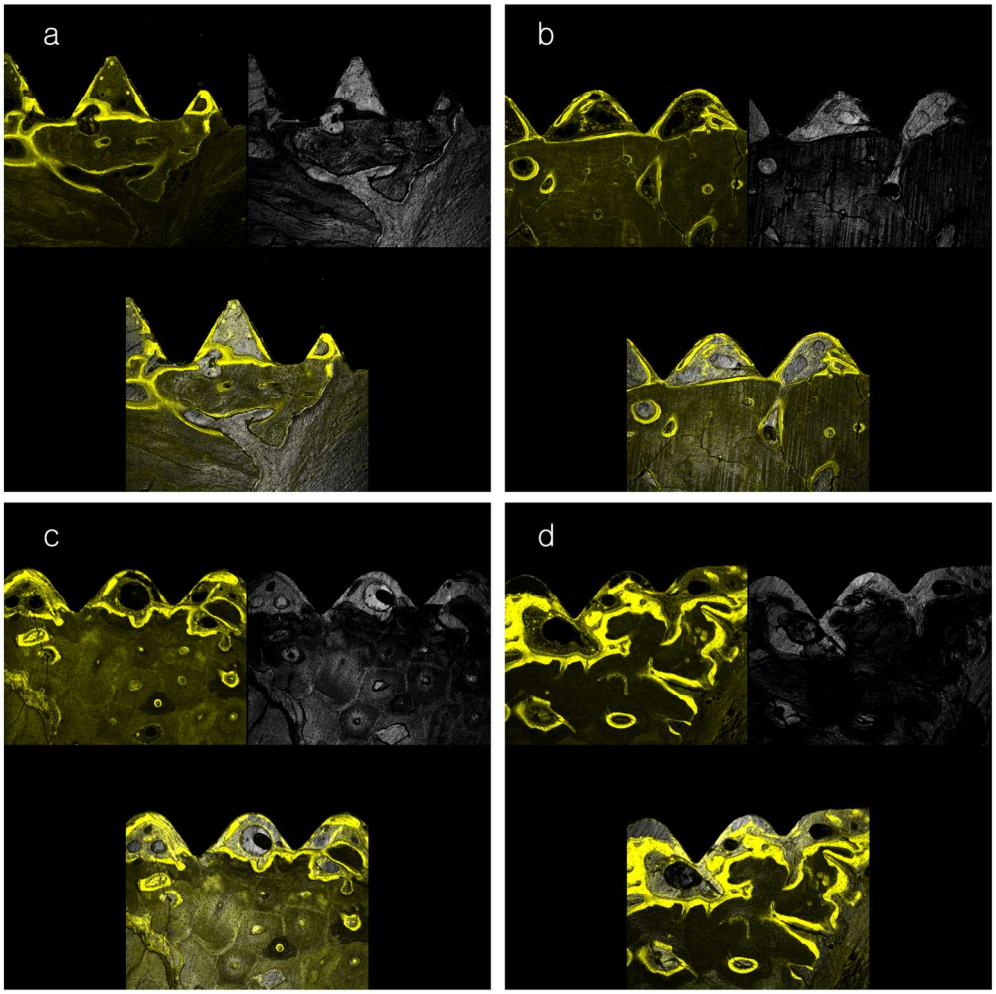

Fig. 5. Fluorescent microscopic images of a (a) Ti implant without any adjunctive treatment, (b) ATZ-N implant, (c) ATZ-D implant, and (d) ATZ-B implant at 3 weeks after implant insertion. Oxytetracycline hydrochloride (yellow markers) administered at week 2 showed bone formation at week 2. The zirconia implants with rhBMP-2 (the ATZ-B implants) showed broad bone formation outside of implant surface, while the implants without any adjunctive gel showed thin yellow band on threads and existing bone.
169x168mm (300 x 300 DPI)

Table 1. Topographic analyses of the implants surface roughness (R_a* values)

	Total measurements	Top of fixture treads	Valley of fixture treads
Ti implant	1.64 µm ± 0.33 µm	1.84 µm ± 0.29 µm	1.37 µm ± 0.10 µm
ATZ implant	1.76 µm ± 0.33 µm	1.94 µm ± 0.29 µm	1.47 µm ± 0.14 µm

* R_a: arithmetic mean deviation of all profile height values

Table 2. The ingredients of BMP-2 gel and DBM gel

Rafugen™ BMP-2 gel	Rafugen™ DBM gel
25% human DBM	30% human DBM
22.5% carboxymethyl cellulose	
52.5% porcine collagen gel	70% porcine collagen gel
50 μg/ml rhBMP-2	

Table 3. Means and standard deviations of bone-to-implant contact and bone area.

Implants	Bone-to-implant contact				Bone area			
	week 3	*n*	week 6	*n*	week 3	*n*	week 6	*n*
Ti	0.36 ± 0.05	*4*	0.65 ± 0.08	*4*	0.30 ± 0.13	*4*	0.65 ± 0.15	*4*
ATZ-N	0.47 ± 0.13	*4*	0.65 ± 0.18	*4*	0.35 ± 0.06	*4*	0.73 ± 0.15	*4*
ATZ-D	0.35 ± 0.15	*8*	0.61 ± 0.13	*8*	0.31 ± 0.13	*8*	0.71 ± 0.06	*8*
ATZ-B	0.28 ± 0.10	*8*	0.53 ± 0.09	*8*	0.27 ± 0.13	*8*	0.65 ± 0.07	*8*