

가
DP
10 (rotational component)
3,4,23 DP
3
53% (tonic posturing)
4,5 DP 15%
6
DP 1997 1 2001 12
가
(fornix) (stria terminalis)
(ventral striatum)
가 (premotor area), (lateral premotor area), (supplementary motor area)
3,4 (anterior cingulum) DP (anterior temporal lobectomy with amygdalohippocampectomy)
3,7 (tonic posturing)가 DP SPECT DP DP
(primary motor cortex) DP DP non - DP
(clonic movement) DP 32 DP 15 (6 , 9),
DP 21 Non - DP 17 (7 , 10) ,
DP가 10 DP 25.9 11 Engel class 1
SPECT가 (Table 1).
(ictal hyperperfusion) 2. SPECT
2 subtracted SPECT 가 SPECT 25 mCi ^{99m}Tc - ethylcys
(putamen) 가 DP teinate dimer(ECD) 30~60 three -
DP DP Butterworth filter back - projection
DP DP (attenuation correction)

Table 1. Patients information

	DP (N=15)	Non-DP (N=17)	p
M: F	6:9	7:10	-
Right: Left (mesial TLE)	10:5	11:6	-
Age of seizure onset (years)	8.6 ± 5.2	15.7 ± 9.3	0.015*
Duration of epilepsy (years)	19.0 ± 10.5	11.2 ± 6.2	0.015*
Frequency of seizures (per month)	3.6 ± 2.1	3.7 ± 8.8	0.128
Age on ictal SPECT (years)	28.4 ± 10.8	27.4 ± 9.6	0.702
Hippocampal sclerosis	100% (15/15)	82.3 (14/17)	0.087
Febrile convulsion	60% (9/15)	41.1% (7/17)	0.288
Post-surgery follow up period (months)	25.9 ± 9.5	25.9 ± 9.2	0.920

*p<0.05, chi-square test for hippocampal sclerosis and febrile convulsion, *t* - test for age of seizure onset, duration of epilepsy, frequency of seizures, age on ictal SPECT and post-surgery follow up period, DP; patients with ictal dystonic posturing, Non-DP; patients without ictal dystonic posturing

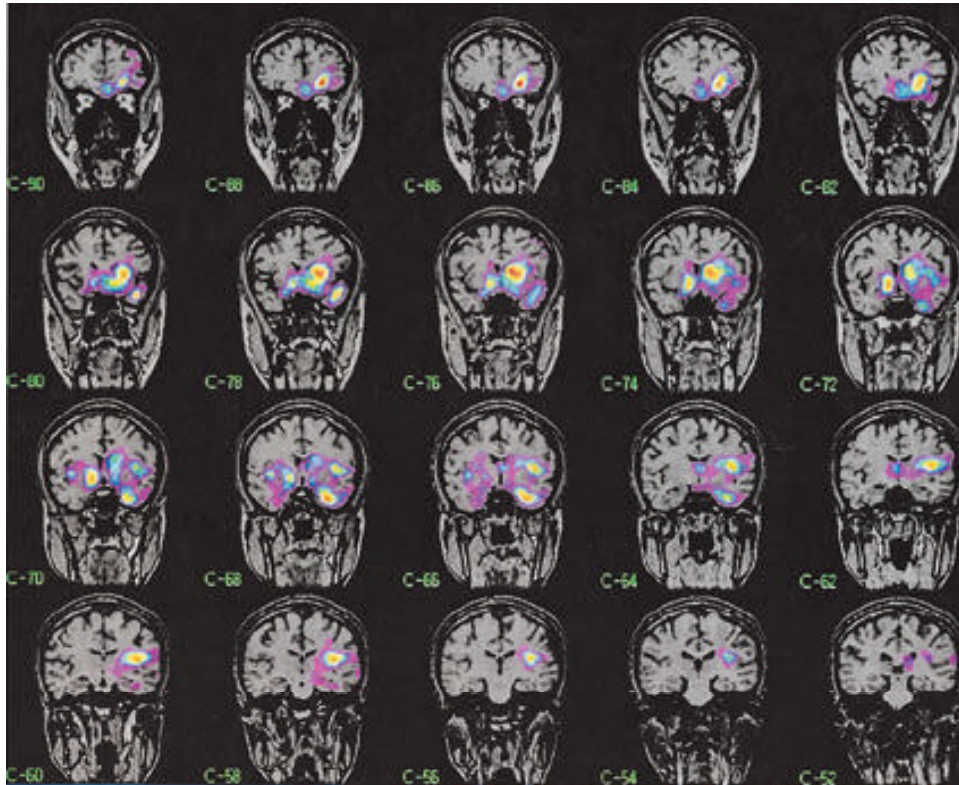


Figure 1. The subtracted SPECT of a patient with dystonic posturing. Ictal hyperperfusion on left temporal lobe with ipsilateral basal ganglia (caudate nucleus, putamen, globus pallidus) in a 32 year-old woman with left mesial TLE who had complex partial seizure with ictal dystonic posturing.

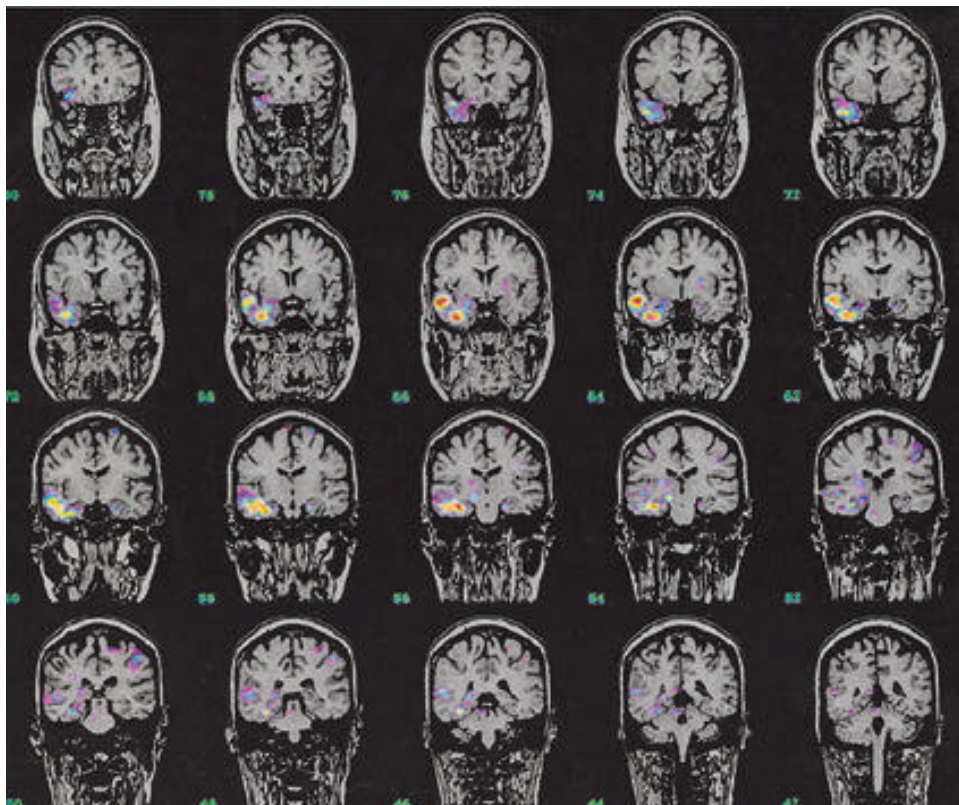


Figure 2. The subtracted SPECT of a patient without dystonic posturing. Ictal hyperperfusion on right temporal lobe in a 31 year-old man with right mesial TLE who had complex partial seizure without ictal dystonic posturing.

Chang's method(=0.12cm¹) . scanner consoles Unix 4 mm
SPECT 24 , SPECT 가
, 가 SPECT
ECD . -
, 1) - SPECT (ictal - interictal
가 ECD가 SPECT SPECT registration)
SPECT SPECT
, 3 SPECT가
3. SPECT , root mean square dis -
tance(RMSD) 1 .
MRI GE Signa 1.5 Tesla (GE Medical Systems, Milwaukee, WI) , SPGR (spoiled gradient recalled in the steady state) volumetric MRI 1.6 mm
, 124 , (TR) 30
msec, (TE) 7 msec
, (FA, flip angle) 45 , FOV (field of view)
22×22 cm, 256×192, (NEX, num -
ber of excitation) 1 . T2
3.0 mm , 0.3 mm, 56
, 5300 msec, 99 msec, 90
, FOV 20 × 20 cm, 256×192, 3
, (coronal voxel dimension)
0.875×1.6 mm . Fluid - attenuated inver -
sion recovery (FLARE) MRI 1.0 mm , 4.0
mm , 32 , TR/TE = 10.002/127.5
ms, 1, (oblique coronal)
, FLAIR (axial image) 2.0 mm
, 5.0 mm
4. SPECT (subtraction) (noise erasing)
, subtracted SPECT
, (standard deviation, SD)
2 SD가
SPECT SUN Ultra 1 Creator
(Sun Microsystems, Palo Alto, CA) 5) MRI - subtracted SPECT (MRI - subtraction
Analyze 7.5 (Biomedical Imaging Resource, SPECT registration)
Mayo Foundation, Rochester, MN, USA) .
(biomedical images) SPECT SPGR MRI

Table 2. The incidence of ictal hyperperfusion on the hemisphere of epileptic side

	DP (N=15)	Non-Dp (=17)	p
Caudate nucleus	80.0 % (12/15)	0 % (0/17)	0.001*
Putamen	93.3 % (14/15)	47.1 % (8/17)	0.005*
Globus pallidus	53.3 % (8/15)	23.5 % (4/17)	0.082
Thalamus	80.0 % (12/15)	41.2 % (7/17)	0.026*
Insular cortex	46.7 % (7/15)	17.6 % (3/17)	0.169
Orbitofrontal cortex	46.7 % (7/15)	35.3 % (6/17)	0.513
Dorsolateral frontal cortex	13.3 % (2/15)	17.6 % (3/17)	0.737
Medial frontal cortex	6.7 % (1/15)	11.8 % (2/17)	0.621
Temporal lobe	93.3 % (14/15)	94.1% (16/17)	0.927

*p<0.05, Fisher exact test, DP; patients with ictal dystonic posturing, Non-DP; patients without ictal dystonic posturing

SPECT - MRI
 3 (: 0.86 × 0.86 × 1.6 mm).

5. Subtracted SPECT

Subtracted SPECT (regional cerebral blood flow) 가 2 SD 가 SPECT가 MRI (3.56 mm × 3 = 10.68 mm)

Subtracted SPECT, DP 가 17 (15/15), Non - DP 가 12 (80%), 가 DP 14 (93.3%), Non - DP 가 8 (53.3%), 가 8 (47%), DP non - DP 가 (p=0.001), 가 (p=0.005) (p=0.004), (p=0.026) , 가가 , SPGR , 가 (Table 2). , DP 6 (40%), Non - DP 7 (41%) 가 (2) , , 가 (3) (insular cortex) , 가 (4) , 가 (orbitofrontal, dorsolateral, medial) 2.

Subtracted SPECT 가

2) (intensity of ictal hyper - perfusion) 가 color lookup table DP 1.67 Non - DP 0 (degree) . 가 DP 2.2, non - DP 1.05 DP 2.0, Non - DP 0.88 DP DP 가 1.2, non - DP 0.65 DP 가 DP 가 Non - DP 가가 , 가가 , 가가 0 1 . 가가 3 2 , 가 1 . 가가 0 1 .

3.

6. SPSS 10.0 Fisher's exact test, Chi - square test student t - test . DP 35.8 , Non - DP 61 , 112 , 27.6

SPECT PET
DP Non - DP , PET
DP DP 19.0 , Non -
DP 11.2 , DP
(p= 0.015). DP
3.6 , Non - DP 3.7
(p=0.128)(Table 1). DP

SPECT SPECT
가 ,
subtracted SPECT
DP
SPECT DP
가 DP
, SPECT MRI
Non - DP 가
) DP (, 가
DP 가 가가
, Non - DP 가
, DP 가
subtraction SPECT MRI
가 DP
SPECT subtracted SPECT
. ¹²⁻¹⁴ subtracted SPECT
가 가
가 . Subtracted SPECT
, (inter - observer reliability),
(sensitivity) (specificity)가
. ^{13,14} subtracted SPECT
가
subtracted SPECT DP 84.6%
가 , DP가
. ¹⁵
SPECT DP
가 가 . ¹¹
SPECT 가 , 가
, 가
DP PET
, DP
. 가 DP dystonia
. ⁴ PET DP
SPECT subtraction DP
. ¹⁶

	Non - DP	subtracted SPECT	DP가
Non - DP	47%	가	가
, DP		가	
Non - DP		가	
DP		가	DP
		가	가
	DP	가	
	가	가	
(frontal horn)		가	
가	가	가	
dystonia 2	가	가 ^{19,20}	
가	(internal capsule)		가
DP	dystonia		
	dystonia		
	가		
	가		
SPECT			
DP		subtracted SPECT	
DP			
DP	Non - DP		가
(DP	8.6 , Non - DP	15.7) ,	
11.2) .	(DP	19.0 , Non - DP	
Non - DP	7.3	Non - DP	3.6 ,
		(p=0.128).	
		가	

REFERENCES

1. Quesney LF. Clinical and EEG features of complex partial seizures of temporal lobe origin. *Epilepsia* 1986;27:27-45.
2. Lang W, Podreka I, Suess E, Muller C, Zeithofer J, Deecke L. Single photon emission computerized tomography during and between seizures. *J Neurol* 1988;235:277-284.
3. Kotagal P, Luders H, Morris HH, Dinner DS, Wyllie E, Godoy J, et al. Dystonic posturing in complex partial seizures of temporal lobe onset: a new lateralizing sign. *Neurology* 1989;39:196-201.
4. Dupont S, Semah F, Baulac M, Samson Y. The underlying pathophysiology of ictal dystonia in temporal lobe epilepsy. an FDG-PET study. *Neurology* 1998;51:1289-1292.
5. Dupont S, Semah F, Boon P, Saint-Hilaire JM, Adam C, Broglin D, et al. Association of ipsilateral motor automatisms and contralateral dystonic posturing. *Arch Neurol* 1999;56:927-932.
6. Newton MR, Berkovic SF, Austin MC, Reutens DC, Mckay WJ, Bladin PF. Dystonia, clinical lateralization, and regional blood flow changes in temporal lobe seizures. *Neurology* 1992;42:371-377.
7. Benett D, Ristanovic R, Morrell F, Goetz C. Dystonic posturing in temporal lobe seizures [Letter to the Editor]. *Neurology* 1989;39:1270-1272.
8. Talairach J, Bancaud J, Geier S, Bordas-Ferrer M, Bonis A, Szikla G, et al. The cingulate gyrus and human behavior. *Electroencephalogr Clin Neurophysiol* 1973;34:45-52.
9. Lim SH, Dinner DS, Pillay PK, Luders H, Morris HH, Klem G, et al. Functional anatomy of the human supplementary sensorimotor area: results of extraoperative electrical stimulation. *Electroencephalogr Clin Neurophysiol* 1994;91:179-93.
10. Chauval P, Trottier S, Vignal J, Bancaud J. Somatomotor seizures of frontal lobe origin. In: Chauval P, Degado-Escueta A, Halgren E, Bancaud J. *Advances in Neurology*. Vol. 57. New York: Raven Press, 1992:185-243.
11. Masahiro M, Yoshihiro S, Kazuya S, AtsukoN, Jyoji N.

-
- Puraminal hyperperfusion in dystonia posturing on subtracted SPECT: A case report. *Ann Nucl Med*. 2001 Jun;15(3):255-7.
12. O'Brien TJ, So EL, Mullan BP, Hauser MF, Brinkmann BH, Jack CR Jr, et al. Subtraction SPECT co-registered to MRI improves postictal SPECT localization of seizure foci. *Neurology* 1999;52:137-146.
 13. O'Brien TJ, So EL, Mullan BP, Hauser MF, Brinkmann BH, Bohnen NI, et al. Subtraction ictal SPECT co-registered to MRI improves clinical usefulness of SPECT in localizing the surgical seizure focus. *Neurology* 1998;50:445-454.
 14. Lee HW, Hong SB, Tae WS. Opposite ictal perfusion patterns of subtraction SPECT: Hyperperfusion and hypoperfusion. *Brain* 2000;123:2150-2159.
 15. Shin WC, Hong SB, Tae WS, Kim SE. Ictal hyperperfusion patterns according to the progression of temporal lobe seizures. *Neurology* 2002;58:373-380.
 16. Savic I, Altshuler L, Baxter L, Engel J JR. Pattern of Interictal hypometabolism in PET scans with fludeoxyglucose F 18 reflects prior seizure types in patients with mesial temporal lobe seizures. *Arch Neurol* 1997;54:129-136.
 17. DeLong MR, Georgopoulos AP, Crutcher MD, Nichell SJ, Richardson RT, Alexander GE. Functional organization of the basal ganglia: contributions of single-cell recording studies. In: Evered D, O'Connor M. *Functions of the basal ganglia: Ciba foundation symposium*. London: Pitman Publishing, 1984;107:64-82.
 18. Nauta WJH, Domesick VB. Afferent and efferent relationships of the basal ganglia. In: Evered D, O'Connor M, eds. *Functions of the basal ganglia: Ciba foundation symposium*. London: Pitman Publishing, 1984;107:3-29.
 19. Burton K, Farrell K, Li D, Calne DB. Lesions of the putamen and dystonia: CT and magnetic resonance imaging. *Neurology* 1984;34:962-965.
 20. Fross RD, Martin WR, Li D, Stoessl AJ, Adam MJ, Ruth TJ, et al. Lesions of the putamen: their relevance to dystonia. *Neurology* 1987;37:1125-1129.
 21. Dreifuss S, Vingerhoets FJ, Lazeyras F, Andino SG, Spinelli L, Delavelle J, et al. Volumetric measurements of subcortical nuclei in patients with temporal lobe epilepsy. *Neurology* 2001;57:1636-1641.