

## Extrathoracic Angio-Follicular Lymphoid Hyperplasia

—Report of a Case with Emphasis on Interfollicular Fibrous Septation—

Hyun Soon Lee, M. D., Sang Jung Shim, M. D.,  
Yong Il Kim, M. D. and Sang Kook Lee, M. D.

*Department of Pathology, College of Medicine, Seoul National University*

### INTRODUCTION

Angiofollicular lymphoid hyperplasia is a very curious pathologic entity and has received diverse nomenclatures since its first description by Castleman<sup>2)</sup> (1954); lymph node hyperplasia<sup>2)</sup>, giant hemolymph node<sup>6)</sup>, lymph nodal hamartoma<sup>1)</sup>, giant intrathoracic lymph nodes<sup>12)</sup>, follicular lymphoreticuloma<sup>14)</sup>, angiofollicular lymphoid hyperplasia<sup>7)</sup>, angiomatous lymphoid hamartoma<sup>13)</sup>, giant lymph node hyperplasia<sup>8)</sup>, and isolated lymphoid tumor<sup>4)</sup>.

Castleman<sup>3)</sup> (1956) originally reported that it is a localized mediastinal tumor and also presented the evidence that the condition is neither neoplastic nor thymic in origin, but rather a form of chronic nonspecific inflammation. Since then, cases of occurrence in extrathoracic sites were documented<sup>4, 5, 8, 10, 13, 14)</sup>, and Abell<sup>1)</sup> (1957) and Lattes<sup>10)</sup> (1962) suggested lymphoid hamartomatous nature as to its histogenesis. But till now, no exact nature is known, except its benign course validated by no recurrence of the tumor in any of the follow-up cases after excision, and by absence of features diagnostic for malignant lymphoma histopathologically.

With a review of all lympho-reticular neoplasm and its allied conditions, we are aware of some difference in incidence among Koreans,

and such speculations may extend to the benign non-neoplastic growth including angiofollicular lymphoid hyperplasia. In the aspect of that no single proven document on this growth was found in Korean literature, the authors present a case of extrathoracic origin who received unnecessary radical operative procedure by fundamental lack of clinician's understanding on this disorder, and showed peculiar histological characteristics in addition to the findings summarized by Lattes et al<sup>10)</sup> (1962).

### REPORT OF CASE

A seventeen year old male was admitted to Seoul National University Hospital on April, 1973, because of a mass in the left side of neck. This mass, noted approximately 10 years previously, had enlarged slowly and progressively with no subjective symptoms. Physical examination on admission revealed a smoothly outlined rubbery firm, hen-egg sized mass in the left side of the neck. It was nontender and slightly mobile without skin fixation. Otherwise, there was no peripheral lymphadenopathy or visceromegaly. The patient's hemoglobin count was 13.5gm/dl, hematocrit 43%, and WBC count 5600/mm<sup>3</sup>. At operation, a huge main mass and variously enlarged hard lymph nodes were found in the anterior and

posterior triangles below the sternocleidomastoid muscle. The mass adhered to the surrounding structures within which was internal jugular vein embedded. In spite of frozen section diagnosis of benign lymphoid tumor, radical left neck dissection was done, retrospectively with impression of that growing pattern and localization appeared malignant. Postoperative course was uneventful and no recurrence was evident for last 6 months.

### **PATHOLOGY**

#### **Gross Findings:**

The submitted tissue consisted of a well encapsulated rubbery-firm, ovoid solid mass, measuring 12×8×4 cm. being surrounded by skeletal muscle groups. Outer surface was smoothly outlined, and on section tumor exhibited homogenously grayish white to pink, partly fish-flesh like appearance. Near the peripheral portion were fine fibrous interdigitations (spurs) to form incomplete trabeculation. With help of a hand magnifier many small grayish white spots stood relatively out. There was neither hemorrhage nor necrosis. Adjacent lymph nodes were slightly enlarged and studded but cut surfaces differed basically from those of the above mass.

#### **Microscopic Findings:**

The lesion was characterized by diffuse lymphoid tissue background with widespread lymphoid follicle formations and presence of vascular structures; the former was composed of small mature lymphocytes in lamellating or concentric pattern to form onion-skin like sheaths. Those pseudofollicular structures varied in size and contained no germinal or reaction center. But corresponding to those areas were laydown of eosinophilic amorphous material often along the hyalinized vascular walls, extending to outer interfollicular space

by serial step section, partly simulating to Hassall's corpuscles. Lymph nodal sinus architectures were completely absent, and instead, rich capillary type of vasculatures were conspicuously seen in interfollicular, and subcapsular cortical spaces, And even, no subcapsular sinus structures were identified by reticulin stain. One of additional and characteristic features was a thick fibro-collagenous trabecular septation separating the follicles and adjacent interfollicular tissue into small nodular growth resembling diffuse fibrosis of Hodgkin's disease at scanning power. Neither atypical nor anaplastic cell were observed throughout.

### **DISCUSSION**

The case here we presented is a case of benign extranodal lymphoid growth of probable hyperplastic nature in the neck; the mass had progressively enlarged for 10 years without any subjective symptoms or other manifestations. Grossly, it was a large well encapsulated, resilient, ovoid mass measuring 12 cm. in maximum dimension, with a faintly lobulated grayish white to pink cut surface. Microscopically, were seen diffuse pseudofollicular lymphoid tissue composed of lamellating small lymphocytes in which were amorphous hyaline substance mimicking Hassall's corpuscles, deposited along the thickened vascular channels accompanied in part by thick fibrous trabecular septations separating lymphoid tissue. Absence of sinus architectures and instead, rich capillary type of vascularized interfollicular and subcapsular cortical spaces indicated extranodal lymphoid growth of hamartomatous nature.

In 1962 Lattes et al<sup>10)</sup> analysed 12 cases of benign lymphoid masses and summarized them clinically and pathologically. According to

their abstract, those cases illustrated clinically 3 outstanding features; first, the lesions were essentially asymptomatic, secondly, the long-standing presence of these lymphoid masses, and thirdly, total absence of any local recurrence or appearance of disseminated disease. And in gross pathological point of view, they exhibited 3 features of note; first, they were of large size, ranging up to 7cm, secondly, the lesions were all either encapsulated or at least relatively well circumscribed, and thirdly, the masses were all solitary, and most were not multinodular. Microscopically, they listed 5 distinguished features; 1) a low power view of the tumor-like lymphoid masses revealing follicular architectures, 2) the presence of follicle centers that bore a vague resemblance to Hassall's corpuscles, 3) a total absence of lymph nodal sinus architectures, 4) a distinctive vascular pattern, both in the lymphoid follicles and interfollicular tissue and 5) none of the cells in those masses were anaplastic or atypical.

In reviewing the above-mentioned criteria, pathologically as well as clinically our case perfectly fits the conditions of former, except an unusual histologic finding of interfollicular thick fibrous trabecular septae. Such a peculiar feature had been hitherto undescribed in literatures and about it we came to the assumption that it is an additional microscopic characteristics, if present, of hamartomatous growth as an extension of subcapsular trabeculae.

As indicated by most of authors, these lymphoid tumors were usually asymptomatic, although association with refractory anemia<sup>1)</sup> thrombocytopenia<sup>9)</sup> growth failure<sup>11)</sup>, and myasthenia gravis<sup>4)</sup> have been emphasized. But hematological as well as biochemical studies showed no abnormalities or even changes

subsequent to extirpation of the mass in this instance. Recently the possibility of possessing a malignant biological potential and presence of Reed-Sternberg cells were described<sup>5)</sup>, but both remain reminiscent until further studies of cases be carried out.

## SUMMARY

The clinico-pathologic features of a seventeen year old male with asymptomatic extrathoracic angiofollicular lymphoid hyperplasia are presented. Morphological characteristics of hamartomatous nature might be strengthened by interfollicular fibrous trabeculation or interdigitations.

—國文抄錄—

### 胸腔外 脈管—濾胞性 淋巴系 組織 增殖症

—偽濾胞間 纖維 膠原性 索帶를 隨伴한  
1 症例 報告—

서울大學校 醫科大學 病理學教室

李賢淳 · 沈相政 · 金勇一 · 李尙國

17歲 男子의 左側 頸部에서 摘出된 脈管—濾胞性 淋巴系 組織 增殖症 1例을 觀察하고, 그 臨床的 및 病理學的 特性을 考察함과 아울러 지금까지 報告되지 않았던 偽濾胞間 纖維 膠原性 索帶를 本 疾患의 過誤腫性 特徵으로 追加 記載 報告하는 바이다.

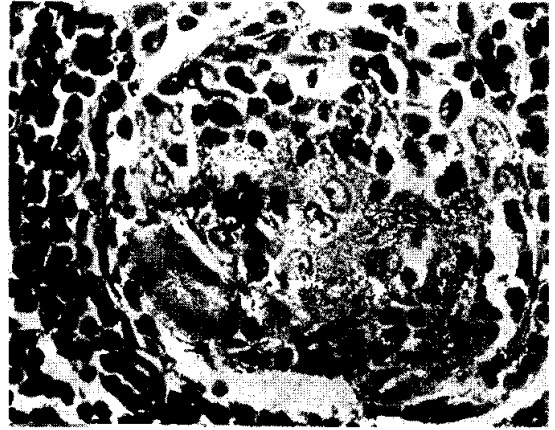
## REFERENCES

1. Abell, M. R.: *Lymph nodal hamartoma versus thymic choristoma of pulmonary hilum.* A. M. A. Arch. Path. 64:584-588, 1957.
2. Castleman, B.: *Massachusetts General Hospital, Case Records: Weekly clinicopathological exercises Case 40011-Hyperplasia of mediastinal lymph nodes.* New Eng. J. Med. 250:26-30. 1954.
3. Castleman, B., Iverson, L., and Menendez, V. P.: *Localized mediastinal lymph node hyperplasia resembling thymoma.* Cancer 9:822-830,

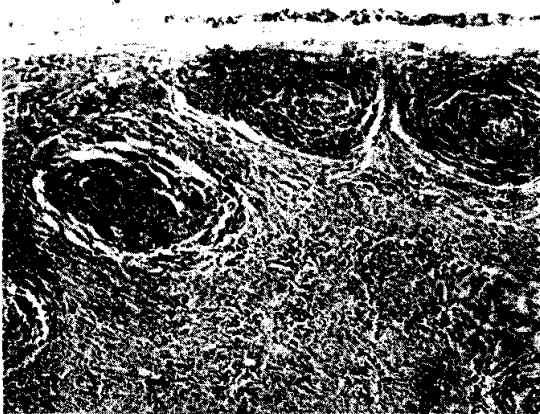
- 1956.
4. Emson H.E.: *Extrathoracic angiofollicular lymphoid hyperplasia with coincidental myasthenia gravis*. *Cancer* 31:241-245, 1973.
  5. Fisher, E.R., Sieracki, J.C. Goldenberg, D.M.: *Identity and nature of isolated lymphoid tumors (So-called nodal hyperplasia, hamartoma and angiomatous hamartoma) as revealed by histologic, electronmicroscopic, and heterotransplantation studies*. *Cancer* 25:1286-1300, 1970.
  6. Grimes, A.E.: *Giant hemolymph node of the left chest: report of case*. *J. Thoracic Surg.* 31:549-353, 1956.
  7. Harrison, E.G., Jr., and Bernatz, P.E.: *Angiofollicular mediastinal lymph node hyperplasia resembling thymoma*. *Arch. Path.* 75:284-292, 1963.
  8. Keller, A.R., Hochholzer, L., and Castleman, B.: *Hyalinevascular and plasma cell types of giant lymph node hyperplasia of the mediastinum and other locations*. *Cancer* 29:670-683. 1972.
  9. Kraznai, G., and Juhasz, I.: *Angiomatous lymphoid tissue hyperplasia*. *J. Pathol.* 97:148-151, 1969.
  10. Lattes, R., and Pachter, M.R.: *Benign lymphoid masses of probable hamartomatous nature*. *Cancer* 15:197-214, 1962.
  11. Lee, S.L., Rosner, F., Rivero, I., Feldman, F., and Hurwitz, A.: *Refractory anemia with abnormal iron metabolism. Its remission after resection of hyperplastic mediastinal lymph nodes*. *New Eng. J. Med.* 272:761-766, 1965.
  12. Mason, C.B.: *Giant intrathoracic lymph nodes*. *J. Thoracic Surg.* 29:251-256, 1959.
  13. Tung, K., & McCormack, L.J.: *Angiomatous lymphoid hamartoma*. 20:525-536, 1967.
  14. Zettergren, L.: *Probably neoplastic proliferation of lymphoid tissue (follicular lympho-reticuloma) Report of 4 cases with a survey of the literature*. *Acta. Pathol. Microbiol. Scand.* 51:113-126, 1961.



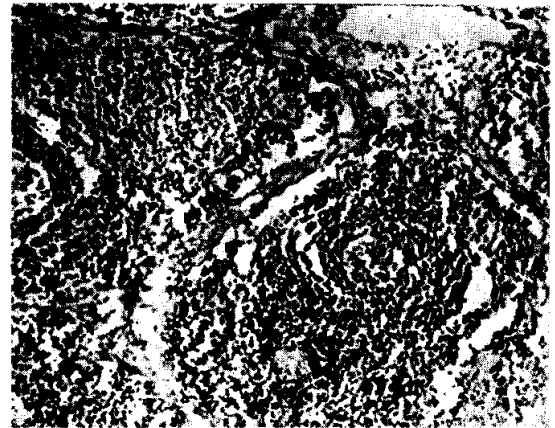
**Fig. 1.** Cut surface of angiofollicular lymphoid hyperplasia. It is well encapsulated and separated from skeletal muscle group. Fibrous spurs divide the lesion into several nodules at periphery.



**Fig. 3.** Central portion of the pseudofollicle, demonstrating deposit of amorphous hyaline substance and small vascular structure, resembling Hassall's corpuscle. H-E x540.



**Fig. 2.** Microphotograph of tumor, illustrating many pseudofollicular lymphoid structures and interfollicular vascularized tissues. No subcapsular sinuses are demonstrable.  
H-E x 120



**Fig. 4.** Fibrocollagenous septae of hamartomatous nature digitating through the interfollicular tissues. H-E x 60