

CASE REPORT

Annular Leukocytoclastic Vasculitis in a Patient with Ulcerative Colitis

Jong Soo Hong, M.D., Seon Pil Jin, M.D., Mira Choi, M.D., Kook Lae Lee, M.D.¹, Jong Hee Lee, M.D., Soyun Cho, M.D.

Departments of Dermatology, ¹Internal Medicine, Boramae Hospital, Seoul National University College of Medicine, Seoul, Korea

Leukocytoclastic vasculitis (LV) is characterized by neutrophilic invasion and fibrinoid necrosis along with endothelial enlargement in postcapillary venules. Annular appearance of LV (ALV) is rare, but it can be accompanied by several systemic diseases. One of these systemic diseases is ulcerative colitis (UC), a subgroup of inflammatory bowel disease. Only one case was previously reported in which ALV was associated with UC, and herein we present one more case. A 66-year-old woman presented with painful polycyclic erythema on both palms, which had been present for 4 days. She had suffered from UC for 5 years. The patient had no fever or other systemic symptoms, and histological examination demonstrated typical LV. 200 mg of oral dapsone was taken daily to rapidly reduce her symptoms and signs, and after 1 week all lesions resolved completely without any adverse events. ALV is not a distinct condition and it can appear in a broad range of small vessel vasculitides. Although ALV in patients with UC is a very rare combination, clinicians need to be aware of this possible association. (**Ann Dermatol 23(S3) S338 ~ S340, 2011**)

-Keywords-

Annular leukocytoclastic vasculitis, Leukocytoclastic vasculitis, Ulcerative colitis

Received February 9, 2011, Revised April 11, 2011, Accepted for publication April 12, 2011

Corresponding author: Soyun Cho, M.D., Department of Dermatology, Seoul National University Boramae Hospital, Seoul National University College of Medicine, 425 Sindaeabang 2-dong, Dongjak-gu, Seoul 156-707, Korea. Tel: 82-2-870-2381, Fax: 82-2-870-3866, E-mail: sycho@snu.ac.kr

This is an Open Access article distributed under the terms of the Creative Commons Attribution Non-Commercial License (<http://creativecommons.org/licenses/by-nc/3.0>) which permits unrestricted non-commercial use, distribution, and reproduction in any medium, provided the original work is properly cited.

INTRODUCTION

Ulcerative colitis (UC) is a subgroup of inflammatory bowel disease (IBD). It is diffusive inflammation limited to the large intestinal mucosa. There can be many extra-gastrointestinal symptoms with the progress of IBD. Skin manifestations such as pyoderma gangrenosum and erythema nodosum usually occur in conjunction with Crohn's disease and UC. However, other skin diseases, such as leukocytoclastic vasculitis (LV) has rarely been reported. Skin manifestations are important clues for diagnosis because they may precede gastrointestinal symptoms¹.

LV is characterized by neutrophilic invasion and fibrinoid necrosis along with endothelial enlargement in post-capillary venules. It is a syndrome in which patients most commonly present with palpable purpura on lower extremities and ankles². An annular variant of LV is rare and to date, only 15 cases have been reported³.

Association between annular leukocytoclastic vasculitis (ALV) and UC is very uncommon and to the best of our knowledge, this is only the second report. We report a case diagnosed as ALV 5 years after the development of UC, which is highly rare.

CASE REPORT

A 66-year-old woman presented with painful polycyclic erythema on both palms. She had been diagnosed with UC 5 years earlier. Her UC had been well controlled with mesalazine and aspirin since June 2006. She was hospitalized in April 2009 due to gastrointestinal tract bloody excrement caused by worsening of the UC. The dose of mesalazine was increased and a fair response to the symptoms of the UC was observed. In June 2009, 4 days before visiting our department, confluent annular ery-

thema appeared on both palms. The pain was not severe, but tenderness was accompanied and the lesions became larger. Therefore, she was referred to our department. Her family history was unremarkable and there was no previous history of any skin disease or skin allergy.

The laboratory test showed elevated erythrocyte sedimentation rate: 66 mm/hr (normal: 0~20) and elevated C-reactive protein: 3.48 mg/dl (normal: 0~0.05). The complete blood count and routine chemistry were within normal range.

Multiple confluent annular erythematous patches were observed on both palms (Fig. 1). A skin biopsy performed on an erythematous part of the palm demonstrated the presence of lymphohistiocytic infiltration around the blood vessels of the upper dermis, edema of endothelial cells and extravasation of erythrocytes (Fig. 2). Diagnosis of ALV was confirmed. The patient was treated with dapsone 200 mg/day, aceclofenac 200 mg/day, levocetirizine 5 mg/day and fexofenadine 180 mg/day for 1 week fol-

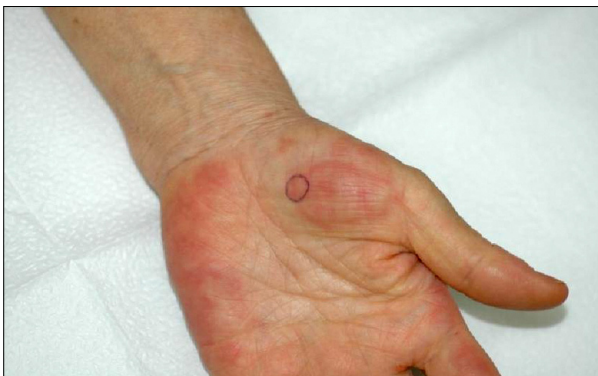

Fig. 1. Multiple confluent annular purpuric erythema with central clearing on both palms.

lowing biopsy. Her symptoms and signs were completely gone without sequelae.

DISCUSSION

Extra-intestinal manifestations of IBDs including mucocutaneous involvement and skin manifestations occur in about 15% of patients with inflammatory bowel disorders⁴. The most common skin manifestations are pyoderma gangrenosum and erythema nodosum, while necrotizing vasculitis, cutaneous polyarteritis nodosa and granulomatous perivascularitis are less frequently observed⁵. In the present case, intestinal manifestations of UC were associated with uncommon skin lesions characterized by confluent annular erythema, which was diagnosed as ALV. Since the skin lesions developed 1~2 months after the UC worsened, we speculated that there may be an association between the two conditions

ALV is not a clear status within LV, classified based on the clinical morphology. Cribier et al. first reported that some patients with ALV constitute a distinct subtype, which satisfies the following criteria⁶. The characteristics are: (1) multiple attacks over years with sudden onset and spontaneous regression after 7~10 days, (2) annular purpuric patches that show centrifugal extension, (3) extension over the limbs and trunk creating polycyclic lesions that clear leaving mild haemosiderin deposition, (4) no extracutaneous symptoms and good general health, (5) histological changes of LV with mild vascular changes and intense polymorphonuclear cell infiltration, and (6) complete clearance of all lesions with dapsone⁶. Our case matches the second, fifth and sixth criteria established by Cribier. Therefore, we cannot classify this case as a "dis-

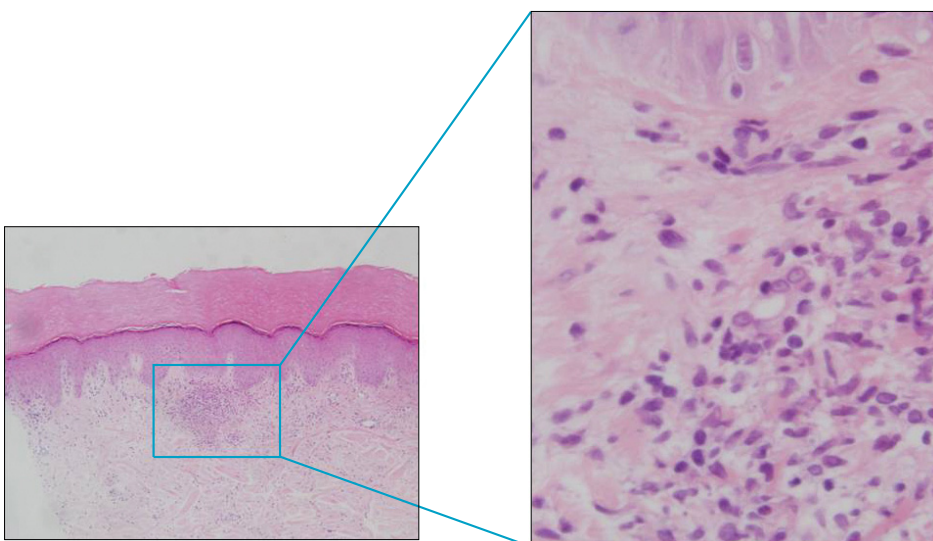


Fig. 2. Leukocytoclastic vasculitis. There was a heavy infiltrate of neutrophils with leukocytoclasia and fibrinoid necrosis of vessel wall (H&E, original magnification $\times 400$).

tinct subtype"; however, we thought that there was enough evidence to categorize this case morphologically as ALV. Also, the most potent treatment for ALV is dapsone.

There have been about 20 cases in the literature describing ALV in association with systemic diseases such as monoclonal gammopathy, sarcoidosis, UC, myelomatosis, pregnancy and chronic hepatitis B^{3,7-10}. Association between ALV and UC is very uncommon and, to the best of our knowledge, this is only the second report.

The etiology of LV with UC is not clear; a partial defect of immunity common to the skin and intestines has been suggested¹¹. The causes of immune activation are believed to be due to the presence of antigens related to infectious agents, drugs, neoplasia, food, or autoantigens¹². Attracted neutrophils due to immune activation release lysosomal enzymes, which induce nitric oxide (NO). NO causes apoptosis of neutrophils leading to leukocytoclasia¹³. At present, the clinical characteristics of ALV, annularity and peripheral spreading, are not known. However, it is possible that inflammatory cells, inflammatory mediators and antigens spread peripherally resulting in an annular pattern of erythema¹⁴.

One possible hypothesis for the association between ALV and UC is that the pathogenesis of both is based on immune mechanisms and deposition of immune complexes in the vascular structure and intestinal mucosa for ALV and UC, respectively¹⁵.

Skin lesions of LV can be treated with corticosteroids, dapsone, colchicine, or immunosuppressive agents². In contrast, in ALV, the most potent and effective treatment is dapsone at a daily dosage of 100 mg to 200 mg.

Although ALV in patients with UC is a very rare combination, clinicians need to be aware of this possible association and the most effective treatment for ALV is dapsone.

REFERENCES

1. Friedman S, Blumberg RS. Inflammatory bowel disease. In: Kasper DL, Braunwald E, Fauci AS, Hauser SL, Longo DL, Jameson JL, editors. *Harrison's principles of internal medicine*. 16th ed. New York: McGraw-Hill Professional, 2005:1776-1789.
2. Hannon CW, Swerlick RA. Vasculitis. In: Bologna JL, Jorizzo JL, Ragini RP, editors. *Dermatology*. 1st ed. Philadelphia: Elsevier, 2003:381-402.
3. Meissner M, Beier C, Gille J, Kaufmann R. Annular leukocytoclastic vasculitis in association with chronic hepatitis B. *J Eur Acad Dermatol Venereol* 2007;21:135-136.
4. Claudy A. Pathogenesis of leukocytoclastic vasculitis. *Eur J Dermatol* 1998;8:75-79.
5. Greenstein AJ, Janowitz HD, Sachar DB. The extra-intestinal complications of Crohn's disease and ulcerative colitis: a study of 700 patients. *Medicine (Baltimore)* 1976;55:401-412.
6. Cribier B, Cuny JF, Schubert B, Colson A, Truchetet F, Grosshans E. Recurrent annular erythema with purpura: a new variant of leukocytoclastic vasculitis responsive to dapsone. *Br J Dermatol* 1996;135:972-975.
7. Branford WA, Farr PM, Porter DI. Annular vasculitis of the head and neck in a patient with sarcoidosis. *Br J Dermatol* 1982;106:713-716.
8. Nousari HC, Kimyai-Asadi A, Stone JH. Annular leukocytoclastic vasculitis associated with monoclonal gammopathy of unknown significance. *J Am Acad Dermatol* 2000;43:955-957.
9. Aram H, Rubinstein N, Granot E. Annular erythema with histologic features of leukocytoclastic vasculitis in ulcerative colitis. *Cutis* 1985;35:250-252.
10. Kelly RI, Cook MG, Marsden RA. Annular vasculitis associated with pregnancy. *Br J Dermatol* 1993;129:599-601.
11. Basler RS. Ulcerative colitis and the skin. *Med Clin North Am* 1980;64:941-954.
12. Basler RS, Dubin HV. Ulcerative colitis and the skin. *Arch Dermatol* 1976;112:531-534.
13. Burgdorf WH. The histiocytoses. In: Wolff K, Austen KF, Goldsmith LA, Katz SI, editors. *Fitzpatrick's dermatology in general medicine*. 6th ed. New York: McGraw-Hill, 2003: 977-979.
14. Chiu CS, Chang YC, Chung WH, Yang LJ, Ho HC, Chen MJ, et al. Annular leukocytoclastic vasculitis induced by chlorzoxazone. *Br J Dermatol* 2004;150:153.
15. Iannone F, Scioscia C, Musio A, Piscitelli D, Lapadula G. Leukocytoclastic vasculitis as onset symptom of ulcerative colitis. *Ann Rheum Dis* 2003;62:785-786.